THIRTEENTH EDITION

Grant's DISSECTOR

THIRTEENTH EDITION

Grant's DISSECTOR

PATRICK W. TANK
Director, Division of Anatomical Education
Department of Neurobiology and Developmental Sciences
University of Arkansas for Medical Sciences
Little Rock, Arkansas



LIPPINCOTT WILLIAMS & WILKINS
A **Wolters Kluwer** Company
Philadelphia • Baltimore • New York • London
Buenos Aires • Hong Kong • Sydney • Tokyo

Executive Editor: Betty Sun
Managing Editors: Amy Oravec and Kathleen H. Scogna
Marketing Manager: Joe Schott
Project Editor: Jennifer Ajello
Designer: Doug Smock
Compositor: Maryland Composition
Printer: RR Donnelley & Sons-Willard

Copyright © 2005 Lippincott Williams & Wilkins

351 West Camden Street
Baltimore, MD 21201

530 Walnut St.
Philadelphia, PA 19106

All rights reserved. This book is protected by copyright. No part of this book may be reproduced in any form or by any means, including photocopying, or utilized by any information storage and retrieval system without written permission from the copyright owner.

The publisher is not responsible (as a matter of product liability, negligence, or otherwise) for any injury resulting from any material contained herein. This publication contains information relating to general principles of medical care that should not be construed as specific instructions for individual patients. Manufacturers' product information and package inserts should be reviewed for current information, including contraindications, dosages, and precautions.

Printed in the United States of America

By J.C.B. Grant and H.A. Cates:
First edition, 1940
Second Edition, 1945
Third Edition, 1948
Fourth Edition, 1953

By J.C.B. Grant:
Fifth Edition, 1959
Sixth Edition, 1967

By E.K. Sauerland:
Seventh Edition, 1974
Eighth Edition, 1978
Ninth Edition, 1984
Tenth Edition, 1991
Eleventh Edition, 1994
Twelfth Edition, 1999

Library of Congress Cataloging-in-Publication Data

Tank, Patrick W., 1950-
Grant's dissector.— 13th ed. / Patrick W. Tank.
p. ; cm.
Rev. ed. of: Grant's dissector / Eberhardt K. Sauerland, Wanda S. Sauerland. 12th ed. c1999.
Includes index.
ISBN 0-7817-5484-4
1. Human dissection—Laboratory manuals. I. Title: Dissector. II. Grant, J. C. Boileau (John Charles Boileau), 1886-1973. III. Sauerland, Eberhardt K., 1933-Grant's dissector. IV. Title.
[DNLM: 1. Dissection—Laboratory Manuals. QS 130 T165g 2005]
QM34.T36 2005
611—dc22

2004063357

The publishers have made every effort to trace the copyright holders for borrowed material. If they have inadvertently overlooked any, they will be pleased to make the necessary arrangements at the first opportunity.

To purchase additional copies of this book, call our customer service department at **(800) 638-3030** or fax orders to (301) 824-7390. International customers should call **(301) 714-2324**.

Visit Lippincott Williams & Wilkins on the Internet: http://www.LWW.com. Lippincott Williams & Wilkins customer service representatives are available from 8:30 am to 6:00 pm, EST.

05 06 07 08 09
1 2 3 4 5 6 7 8 9 10

To Suzanne

FIGURE CREDITS

CHAPTER 1

Modified from Agur A. *Grant's Atlas of Anatomy*, 9E. Baltimore: Lippincott Williams & Wilkins, 1991. Figures 1.05, 1.06.

From Basmajiam: *Grant's Method of Anatomy*, 11E, 1989. Figure 1.10.

Modified from Woodburne: *Essentials of Human Anatomy*, 9E, Oxford University Press,1994, Figure 1.16.

CHAPTER 2

Modified from Netter F. *Netter's Atlas of Human Anatomy*, 3E. Carlstadt, NJ: Icon Learning System, 2002. Figures 2.05, 2.12, 2.27, 2.28, 2.31, 2.32.

CHAPTER 3

Modified from Clemente CD. *Anatomy Dissector*. Baltimore: Lippincott Williams & Wilkins, 2002. Figure 3.17.

Modified from Moore K, Dalley AF. *Clinically Oriented Anatomy*, 4E. Baltimore: Lippincott Williams & Wilkins, 1999. Figures 3.06, 3.07.

Modified from Netter F. *Netter's Atlas of Human Anatomy*, 3E. Carlstadt, NJ: Icon Learning System, 2002, Figures 3.24 and 3.25B.

Modified from Woodburne. *Essentials of Human Anatomy*, 9E, Oxford University Press, 1994. Figure 3.01.

CHAPTER 4

Modified from Agur A, Dalley AF. *Grant's Atlas of Anatomy*, 11E, Baltimore: Lippincott Williams & Wilkins, 2005. Figures 4.20, 4.46, 4.47, 4.53.

Modified from Moore K, Agur A. *Essential Clinical Anatomy*, 2E. Baltimore: Lippincott Williams & Wilkins, 2002. Figure 4.11.

Modified from Moore K, Dalley AF. *Clinically Oriented Anatomy*, 4E. Baltimore: Lippincott Williams & Wilkins, 1999, page 199, Figures 4.16, 4.18, 4.25, 4.48.

Modified from Netter F. *Netter's Atlas of Human Anatomy*, 3E. Carlstadt, NJ: Icon Learning System, 2002. Figures 4.06, 4.09, 4.10, 4.12, 4.19.

CHAPTER 5

Modified from Agur A. *Grant's Atlas of Anatomy*, 9E. Baltimore: Lippincott Williams & Wilkins, 1991. Figures 5.08, 5.18, 5.19, 5.24, 5.33, 5.34.

Modified from Clemente CD. *Anatomy Dissector*. Baltimore: Lippincott Williams & Wilkins, 2002. Figures 5.03, 5.16, 5.30.

Modified from Moore K, Agur A. *Essential Clinical Anatomy*, 2E. Baltimore: Lippincott Williams & Wilkins, 2002. Figures 5.07, 5.13.

Modified from Moore K, Dalley AF. *Clinically Oriented Anatomy*, 4E. Baltimore: Lippincott Williams & Wilkins, 1999. Figures 5.09, 5.23, 5.25, 5.26.

CHAPTER 6

Modified from Netter F. *Netter's Atlas of Human Anatomy*, 3E. Carlstadt, NJ: Icon Learning System, 2002. Figures 6.16, 6.22, 6.23, 6.33.

CHAPTER 7

Modified from Agur A. *Grant's Atlas of Anatomy*, 9E. Baltimore: Lippincott Williams & Wilkins, 1991. Figures 7.02, 7.03, 7.22, 7.27, 7.70, 7.79, 7.92.

Modified from Agur A, Dalley AF. *Grant's Atlas of Anatomy*, 11E, Baltimore: Lippincott Williams & Wilkins, 2005. Figures 7.09, 7.40, 7.53, 7.95.

Redrawn from *Bailey's Textbook of Histology*, 16E, 1978, pshr 697, 22.28 Figure 7.94.

Modified from Clemente CD. *Anatomy Dissector*. Baltimore: Lippincott Williams & Wilkins, 2002. Figures 7.01, 7.13, 7.21, 7.26, 7.28, 7.29, 7.37.

Modified from Hansen. *Essential Anatomy Dissector*, 2E. Baltimore: Lippincott Williams & Wilkins, 2002. Figure 7.76.

Modified from Moore K, Agur A. *Essential Clinical Anatomy*, 2E. Baltimore: Lippincott Williams & Wilkins, 2002. Figure 7.09.

Modified from Moore K, Dalley AF: *Clinically Oriented Anatomy*, 4E. Baltimore: Lippincott Williams & Wilkins, 1999. Figure 7.80.

Modified from Netter F. *Netter's Atlas of Human Anatomy*, 3E. Carlstadt, NJ: Icon Learning System, 2002, Figures 7.56, 7.62, 7.71, 7.84.

Modified from Woodburne. *Essentials of Human Anatomy*, 9E, 1994. Figure 7.41.

PREFACE

The first edition of *Grant's Dissector* appeared in 1940. Its 12 previous editions have been used by countless health professionals for over 60 years. During those years, the time devoted to the study of gross anatomy has diminished dramatically, and the 13th edition of *Grant's Dissector* has been modified with that in mind.

A refocusing of content

Grant's Dissector was originally designed as an instruction manual for dissection by the regional approach. The 13th edition continues in this approach but has been rewritten to make the dissection instructions concise and minimize extraneous material. This refocusing is intended to make the scope and detail of the dissector more appropriate to today's gross anatomy curriculum. The student is encouraged to rely upon *Grant's Dissector* for dissection instructions and to use a textbook such as *Clinically Oriented Anatomy* and a quality atlas such as *Grant's Atlas* to provide anatomical details.

Changes to dissection order

In addition to the refocusing of the dissector's content, the order of dissection has been modified in the 13th edition. The first chapter covers the dissection of the back, followed by the upper limb, thorax, abdomen, pelvis and perineum, lower limb, and head and neck. This change in dissection order was made to accommodate courses that begin by dissecting the back for traditional reasons: The dissection experience is less emotionally traumatic for students if they begin with the body in the prone position. However, the chapters are written so that the dissection units can be used in any order that fits the needs of the individual course.

New chapter organization and other key features

Each chapter in the 13th edition is consistently organized with several new features. First, each chapter begins with a brief study of **surface anatomy**. Then, **osteology** is presented in a concise way to provide the student with important foundation structures that will aid in localization of soft tissue structures. Each dissection unit begins with a brief overview, called "**Before you dissect...,**" of what is to be accomplished during the dissection session. The **dissection instructions** are then presented in numbered sequence so that the dissector can perform a step, then return quickly to the appropriate place on the page to get the next dissection instruction. Lastly, each dissection concludes with a series of review exercises, called "**After you dissect...,**" that highlight the important features of the dissection and encourage the synthesis of information. These modifications are intended to improve student learning and ease of use.

Many new illustrations appear in the 13th edition of Grant's Dissector. A number of these illustrations are designed to show the dissection at various stages of completion. The illustrations are not intended to take the place of atlas figures. The dissection instructions contain references to appropriate illustrations in the four leading anatomical atlases:

- *Grant's Atlas of Anatomy*, 11th edition, by Anne Agur and Ming Lee
- *Atlas of Human Anatomy*, 3rd edition, by Frank H. Netter and John T. Hansen (Consulting Editor)
- *Anatomy: A Regional Atlas of the Human Body*, 4th edition, by Carmine Clemente
- *Color Atlas of Anatomy: A Photographic Study of the Human Body*, 5th edition, by Johannes W. Rohen, Chihiro Yokochi, and Lutjen-Drecoll

Anatomical terminology has been undergoing revision for many years. The terminology used in the 13th edition of *Grant's Dissector* agrees with *Terminologia Anatomica*. This modification brings the manual into alignment with recent editions of textbooks and atlases, thereby reducing one source of confusion for students of gross anatomy.

The changes described above are intended to increase the adaptability of *Grant's Dissector* to a variety of dissection needs. Since the chapters are written to stand alone, the dissection sequence can be modified or regional units may be eliminated with a minimum amount of effort. This increase in flexibility is intended to make *Grant's Dissector* the obvious choice to support comprehensive dissection in a changing curricular environment.

ACKNOWLEDGMENTS

Grant's Dissector has enjoyed many years of success. This is due to excellent writing by Dr. J.C.B. Grant and the masterful way in which Dr. Eberhardt K. Sauerland has edited the most recent 6 editions. It is indeed a daunting task to undertake the editor's role for such a significant work, and I thank Dr. Sauerland for permitting me the privilege.

Students are the reason that a teacher exists and I cannot adequately express their impact on me. For over 25 years, I have had the pleasure of working in the lecture hall and dissection laboratory with literally thousands of very talented students. Nearly every day I find myself learning something new about anatomy and about adult learning processes. To my students of the past I express my gratitude for what they have taught me - lessons that have resulted in the modifications that appear in the 13th edition of *Grant's Dissector*. More specifically, I owe a debt of gratitude to the following members of the class of 2007 who took time from their studies to review portions of the manuscript and provide helpful criticism: James Blachly, Andrew Coble, Rani Haley, Thad Hardin, James Ireland, Patrick Kennedy, Leslye McClelland, Joel McLarry, Catherine Oswald, Ray Peeples, Robin Reed, Kirk Reynolds, Aubrey Slaughter and Tony Terry. A special thanks to Deborah Lieber whose editorial skills are second to none and who gave freely of her time to review large portions of the manuscript.

It is not possible to complete a work of this nature without involving one's colleagues. I would like to acknowledge several individuals with whom I teach gross anatomy, for each is a master of anatomical education in his own right. Thanks to David Davies and Bruce Newton for reviewing selected chapters of the manuscript. Kevin Phelan deserves special recognition for his review of the entire manuscript. Their critical focus and attention to detail was exactly what was needed to make this a better dissection manual, and I thank them for their contributions.

It has been a pleasure to work with the professionals that constitute the Lippincott, Williams & Wilkins team. I want to thank Betty Sun, Executive Editor, for her willingness to iron out the details and give a new author a chance. I gratefully acknowledge the talents of Amy Oravec, Managing Editor, and Kathleen Scogna, Senior Developmental Editor, who kept the project on track. Thanks also to Wayne Hubbel, Illustration Coordinator, and Joe Schott, Marketing Manager. The artwork has undergone major revision. To place a magnifying glass on their enormous artistic talents, I would like to thank Rob Duckwall of Dragonfly Media Group, Mary Anna Barrett-Dimes, and Wayne Hubbel.

Last but most importantly, I want to thank my wife, Suzanne. She never complained as I poured myself into this project over many months at the exclusion of everything else, and she always revived me with kind words of encouragement when fatigue had sent my spirits flagging. She deserves as much credit for the completion of this project as I do.

Patrick W. Tank

CONTENTS

Preface / ix
Acknowledgments / xi

INTRODUCTION

1 THE BACK

- SURFACE ANATOMY / 4
- SKELETON OF THE BACK / 4
- SKIN AND SUPERFICIAL FASCIA / 6
  Before you dissect . . . / 6
  Dissection Instructions / 7
  - *Skin Incisions / 7*
  - *Superficial Fascia / 7*

  After you dissect . . . / 7
- SUPERFICIAL MUSCLES OF THE BACK / 7
  Before you dissect . . . / 7
  Dissection Instructions / 8
  - *Trapezius Muscle / 8*
  - *Latissimus Dorsi Muscle / 8*
  - *Rhomboid Major and Rhomboid Minor Muscles / 9*
  - *Levator Scapulae Muscle / 9*

  After you dissect . . . / 9
- INTERMEDIATE MUSCLES OF THE BACK / 9
  Dissection Instructions / 9
- DEEP MUSCLES OF THE BACK / 9
  Before you dissect . . . / 9
  Dissection Instructions / 10
  - *Splenius Muscle / 10*
  - *Semispinalis Capitis Muscle / 10*
  - *Erector Spinae Muscle / 10*
  - *Transversospinal Group of Muscles / 10*

  After you dissect . . . / 11
- SUBOCCIPITAL REGION / 11
  Before you dissect . . . / 11
  Dissection Instructions / 11
  After you dissect . . . / 12
- VERTEBRAL CANAL, SPINAL CORD AND MENINGES / 12
  Before you dissect . . . / 12
  Dissection Instructions / 12
  - *Spinal Meninges / 12*

  After you dissect . . . / 14

2 THE UPPER LIMB

- SURFACE ANATOMY / 15
- SUPERFICIAL VEINS AND CUTANEOUS NERVES / 15
  Before you dissect . . . / 15
  Dissection Instructions / 15
  - *Skin Incisions / 15*
  - *Superficial Veins / 16*
  - *Cutaneous Nerves / 16*

  After you dissect . . . / 17
- SUPERFICIAL GROUP OF BACK MUSCLES / 17
- SCAPULAR REGION / 17
  Before you dissect . . . / 17
  - *Skeleton of the Scapular Region / 17*

  Dissection Instructions / 18
  After you dissect . . . / 19
- PECTORAL REGION / 19
- AXILLA / 19
  Before you dissect . . . / 19
  Dissection Instructions / 20
  - *Axillary Artery / 20*
  - *Brachial Plexus / 21*

  After you dissect / 22
- ARM AND CUBITAL FOSSA / 22
  Before you dissect . . . / 22
  - *Skeleton of the Arm and Cubital Region / 22*

  Dissection Instructions / 23
  - *Anterior Compartment of the Arm / 23*
  - *Cubital Fossa / 24*
  - *Posterior Compartment of the Arm / 25*

  After you dissect . . . / 26
- FLEXOR REGION OF THE FOREARM / 26
  Before you dissect / 26
  - *Skeleton of the Forearm / 27*

  Dissection Instructions / 27
  - *Superficial Group of Flexor Muscles / 27*
  - *Vessels and Nerves / 28*
  - *Deep Group of Flexor Muscles / 29*

  After you dissect . . . / 29
- PALM OF THE HAND / 30
  Before you dissect . . . / 30
  - *Skeleton of the Hand / 30*

  Dissection Instructions / 30
  - *Superficial Palm / 30*
  - *Carpal Tunnel / 31*
  - *Thenar Muscles / 33*
  - *Hypothenar Muscles / 33*
  - *Deep Palm / 34*

  After you dissect . . . / 35
- EXTENSOR REGION OF THE FOREARM AND DORSUM OF THE HAND / 35
  Before you dissect . . . / 35
  Dissection Instructions / 35
  - *Superficial Group of Extensor Muscles / 35*
  - *Deep Group of Extensor Muscles / 35*

  After you dissect . . . / 36
- JOINTS OF THE UPPER LIMB / 37
  Before you dissect . . . / 37
  Dissection Instructions / 37
  - *Sternoclavicular Joint / 37*
  - *Acromioclavicular Joint / 37*
  - *Glenohumeral Joint / 37*
  - *Elbow Joint and Proximal Radioulnar Joint / 39*

- *Intermediate Radioulnar Joint / 39*
- *Distal Radioulnar Joint / 39*
- *Wrist Joint / 40*
- *Metacarpophalangeal Joints / 40*
- *Interphalangeal Joints / 41*

3 THE THORAX

- SURFACE ANATOMY / 42
- SKELETON OF THE THORAX / 42
- PECTORAL REGION / 43
  Before you dissect. . . / 43
  Dissection Instructions / 43
  - *Skin Incisions / 43*
  - *Breast / 43*
  - *Superficial Fascia / 44*

  After you dissect . . . / 45
- MUSCLES OF THE PECTORAL REGION / 45
  Before you dissect. . . / 45
  Dissection Instructions / 45
  After you dissect . . . / 46
- INTERCOSTAL SPACE AND INTERCOSTAL MUSCLES / 46
  Before you dissect. . . / 46
  Dissection Instructions / 46
  After you dissect . . . / 47
- REMOVAL OF THE ANTERIOR THORACIC WALL / 47
  Before you dissect. . . / 47
  Dissection Instructions / 48
  After you dissect . . . / 48
- PLEURAL CAVITIES / 48
  Before you dissect. . . / 48
  Dissection Instructions / 49
  After you dissect . . . / 49
- LUNGS / 50
  Before you dissect. . . / 50
  Dissection Instructions / 50
  - *Lungs in the Thorax / 50*
  - *Removal of the Lungs / 50*

  After you dissect . . / 51
- MEDIASTINUM / 52
  Before you dissect. . . / 52
  Dissection Instructions / 52
- MIDDLE MEDIASTINUM / 52
  Before you dissect. . . / 52
  Dissection Instructions / 52
  - *Heart in the Thorax / 52*
  - *Removal of the Heart / 54*

  After you dissect . . / 54
- EXTERNAL FEATURES OF THE HEART / 54
  Before you dissect. . . / 54
  Dissection Instructions / 54
  - *Surface Features / 54*
  - *Cardiac Veins / 55*
  - *Coronary Arteries / 55*

  After you dissect . . . / 56
- INTERNAL FEATURES OF THE HEART / 56
  Before you dissect. . . / 56
  Dissection Instructions / 56
  - *Right Atrium / 56*
  - *Right Ventricle / 57*
  - *Left Atrium / 58*
  - *Left Ventricle / 58*

  After you dissect . . . / 59
- SUPERIOR MEDIASTINUM / 59
  Before you dissect. . . / 59
  Dissection Instructions / 60
  After you dissect . . . / 61
- POSTERIOR MEDIASTINUM / 61
  Before you dissect. . . / 61
  Dissection Instructions / 61
  After you dissect . . . / 63

4 ABDOMEN

- SURFACE ANATOMY / 64
- SUPERFICIAL FASCIA OF THE ANTEROLATERAL ABDOMINAL WALL / 65
  Before you dissect . . . / 65
  Dissection Instructions / 65
  - *Skin Incisions / 65*
  - *Superficial Fascia / 65*

  After you dissect . . . / 66
- MUSCLES OF THE ANTEROLATERAL ABDOMINAL WALL / 66
  Before you dissect . . . / 66
  - *Skeleton of the Abdominal Wall / 66*

  Dissection Instructions / 67
  - *External Oblique Muscle / 67*
  - *Internal Oblique Muscle / 67*
  - *Transversus Abdominis Muscle / 69*
  - *Deep Inguinal Ring / 69*
  - *Rectus Abdominis Muscle / 70*

  After you dissect . . . / 72
- LABIUM MAJUS IN THE FEMALE; SCROTUM, SPERMATIC CORD, AND TESTIS IN THE MALE / 72
  Before you dissect . . . / 72
  Dissection Instructions / 72
  - *Male and Female Cadavers / 72*
  - *Male Cadaver / 72*
  - *Spermatic Cord / 72*
  - *Testis / 73*

  After you dissect . . . / 73
- REFLECTION OF THE ABDOMINAL WALL / 73
  Before you dissect . . . / 73
  Dissection Instructions / 74
- PERITONEUM AND PERITONEAL CAVITY / 74
  Before you dissect . . . / 74
  Dissection Instructions / 75
  - *Abdominal Viscera / 75*
  - *Peritoneum / 76*

  After you dissect . . . / 77
- CELIAC TRUNK, STOMACH, SPLEEN, LIVER, AND GALLBLADDER / 77
  Before you dissect . . . / 77
  Dissection Instructions / 77
  - *Celiac Trunk / 78*
  - *Spleen / 80*
  - *Liver / 80*

- *Gallbladder / 81*

After you dissect . . . / 82

■ SUPERIOR MESENTERIC ARTERY AND SMALL INTESTINE / 82
Before you dissect . . . / 82
Dissection Instructions / 82
- *Superior Mesenteric Artery / 82*
- *Small Intestine / 83*

After you dissect . . . / 84

■ INFERIOR MESENTERIC ARTERY AND LARGE INTESTINE / 84
Before you dissect . . . / 84
Dissection Instructions / 84
- *Inferior Mesenteric Artery / 84*
- *Large Intestine / 85*

After you dissect . . . / 86

■ DUODENUM, PANCREAS, AND HEPATIC PORTAL VEIN / 86
Before you dissect . . . / 86
Dissection Instructions / 86
- *Duodenum / 86*
- *Pancreas / 86*
- *Hepatic Portal Vein / 87*

After you dissect . . . / 88

■ REMOVAL OF THE GASTROINTESTINAL TRACT / 88
Before you dissect . . . / 88
Dissection Instructions / 88
After you dissect . . . / 89

■ POSTERIOR ABDOMINAL VISCERA / 89
Before you dissect . . . / 89
Dissection Instructions / 90
- *Kidneys / 90*
- *Suprarenal Glands / 91*
- *Abdominal Aorta and Inferior Vena Cava / 92*

After you dissect . . . / 92

■ POSTERIOR ABDOMINAL WALL / 93
Before you dissect . . . / 93
Dissection Instructions / 93
- *Lumbar plexus / 93*
- *Sympathetic Trunk / 94*

After you dissect . . . / 94

■ DIAPHRAGM / 94
Before you dissect . . . / 94
Dissection Instructions / 94
After you dissect . . . / 95

5 THE PELVIS AND PERINEUM

■ SKELETON OF THE PELVIS / 96

■ ANAL TRIANGLE / 97
Before you dissect. . . / 97
Dissection Instructions / 98
- *Skin Incisions / 98*
- *Ischioanal Fossa / 98*

After you dissect . . . / 99

■ MALE UROGENITAL TRIANGLE / 99
Before you dissect. . . / 99
Dissection Instructions / 99
- *Skin Removal / 99*
- *Superficial Perineal Pouch / 100*
- *Penis / 101*
- *Spongy Urethra / 102*
- *Deep Perineal Pouch / 103*

After you dissect . . . / 103

■ MALE PELVIC CAVITY / 103
Before you dissect. . . / 103
Dissection Instructions / 104
- *Peritoneum / 104*
- *Section of the Pelvis / 104*
- *Male Internal Genitalia / 104*

After you dissect . . . / 105

■ URINARY BLADDER, RECTUM, AND ANAL CANAL / 105
Before you dissect. . . / 105
Dissection Instructions / 105
- *Urinary Bladder / 105*
- *Rectum and Anal Canal / 106*

After you dissect . . . / 107

■ INTERNAL ILIAC ARTERY AND SACRAL PLEXUS / 107
Before you dissect. . . / 107
Dissection Instructions / 107
- *Blood Vessels / 107*
- *Nerves / 108*

After you dissect . . . / 109

■ PELVIC DIAPHRAGM / 109
Before you dissect. . . / 109
Dissection Instructions / 109
After you dissect . . . / 110

■ FEMALE UROGENITAL TRIANGLE / 110
Before you dissect. . . / 110
Dissection Instructions / 110
- *External Genitalia / 110*
- *Skin removal / 110*
- *Superficial Perineal Pouch and Clitoris / 111*
- *Deep Perineal Pouch. . . / 112*

After you dissect . . . / 113

■ FEMALE PELVIC CAVITY / 113
Before you dissect. . . / 113
Dissection Instructions / 113
- *Peritoneum / 113*
- *Section of the Pelvis / 114*
- *Female Internal Genitalia / 115*

After you dissect . . . / 116

■ URINARY BLADDER, RECTUM, AND ANAL CANAL / 116
Before you dissect. . . / 116
Dissection Instructions / 116
- *Urinary Bladder / 116*
- *Rectum and Anal Canal / 117*

After you dissect . . . / 118

■ INTERNAL ILIAC ARTERY AND SACRAL PLEXUS / 118
Before you dissect. . . / 118
Dissection Instructions / 118
- *Blood Vessels / 118*
- *Nerves / 119*

After you dissect . . . / 120

■ PELVIC DIAPHRAGM / 120
Before you dissect. . . / 120

Dissection Instructions / 120
After you dissect . . . / 121

6 THE LOWER LIMB

- SURFACE ANATOMY / 122
- SUPERFICIAL VEINS AND CUTANEOUS NERVES / 122
  Before you dissect . . . / 122
  Dissection Instructions / 122
  - *Skin Incisions / 122*
  - *Superficial Fascia of the Posterior Lower Limb / 123*
  - *Superficial Fascia of the Anterior Lower Limb / 124*

  After you dissect . . . / 125
- ANTERIOR COMPARTMENT OF THE THIGH / 125
  Before you dissect . . . / 125
  - *Skeleton of the Thigh / 125*

  Dissection Instructions / 125
  - *Saphenous Opening / 125*
  - *Femoral Triangle / 126*
  - *Adductor Canal / 128*
  - *Quadriceps Femoris Muscle / 128*

  After you dissect . . . / 129
- MEDIAL COMPARTMENT OF THE THIGH / 129
  Before you dissect . . . / 129
  Dissection Instructions / 129
  After you dissect . . . / 130
- GLUTEAL REGION / 130
  Before you dissect . . . / 130
  - *Skeleton of the Gluteal Region / 130*

  Dissection Instructions / 131
  After you dissect . . . / 133
- POSTERIOR COMPARTMENT OF THE THIGH / 133
  Before you dissect . . . / 133
  - *Skeleton of the Posterior Thigh / 134*

  Dissection Instructions / 134
  - *Posterior Thigh / 134*
  - *Popliteal Fossa / 134*

  After you dissect . . . / 136
- LEG AND DORSUM OF THE FOOT / 136
  Skeleton of the Leg . . . / 136
- ANTERIOR COMPARTMENT OF THE LEG AND DORSUM OF THE FOOT / 137
  Before you dissect . . . / 137
  Dissection Instructions / 137
  After you dissect . . . / 139
- LATERAL COMPARTMENT OF THE LEG / 139
  Before you dissect . . . / 139
  Dissection Instructions / 139
  After you dissect . . . / 139
- POSTERIOR COMPARTMENT OF THE LEG / 140
  Before you dissect . . . / 140
  Dissection Instructions / 140
  After you dissect . . . / 141
- SOLE OF THE FOOT / 142
  Before you dissect . . . / 142
  Dissection Instructions / 142
  - *Plantar Aponeurosis and Cutaneous Nerves / 142*
  - *First Layer of Plantar Muscles / 142*
  - *Second Layer of Plantar Muscles / 143*
  - *Third Layer of Plantar Muscles / 143*
  - *Fourth Layer of Plantar Muscles / 144*

  After you dissect . . . / 144
- JOINTS OF THE LOWER LIMB / 145
  Before you dissect . . . / 145
  Dissection Instructions / 145
  - *Hip Joint / 145*
  - *Knee Joint / 146*
  - *Ankle Joint / 147*
  - *Joints of Inversion and Eversion / 149*

7 THE HEAD AND NECK

- SURFACE ANATOMY / 150
- SKULL / 150
  Anterior View of the Skull / 150
  Lateral View of the Skull / 150
  Superior View of the Skull / 152
- FACE / 152
  Before you dissect . . . / 152
  Dissection Instructions / 153
  - *Skin Incisions / 153*
  - *Superficial Fascia of the Face / 153*
  - *Facial Nerve / 153*
  - *Facial Artery and Vein / 154*
  - *Muscles Around the Orbital Opening / 154*
  - *Muscles around the Oral Opening / 155*
  - *Lower Lip / 155*
  - *Sensory Nerves of the Face / 155*

  After you dissect . . . / 156
- SCALP / 156
  Before you dissect . . . / 156
  Dissection Instructions / 156
  After you dissect . . . / 157
- INTERIOR OF THE SKULL / 158
  Before you dissect . . . / 158
  Dissection Instructions / 158
  - *Removal of the Calvaria / 158*
  - *Removal of a Wedge of Occipital Bone / 158*
  - *Cranial Meninges / 159*

  After you dissect . . . / 161
- REMOVAL OF THE BRAIN / 161
  Before you dissect . . . / 161
  Dissection Instructions / 161
- DURAL INFOLDINGS AND DURAL VENOUS SINUSES / 163
  Before you dissect . . . / 163
  Dissection Instructions / 163
  - *Dural Infoldings / 163*
  - *Dural Venous Sinuses / 163*

  After you dissect . . . / 163
- GROSS ANATOMY OF THE BRAIN / 163
  Before you dissect . . . / 163
  Dissection Instructions / 164
  After you dissect . . . / 164
- CRANIAL FOSSAE / 164
  Before you dissect . . . / 164
  - *Skeleton of the Cranial Base / 164*

  Dissection Instructions / 166
  - *Anterior Cranial Fossa / 166*
  - *Middle Cranial Fossa / 166*

- *Posterior Cranial Fossa / 168*

After you dissect . . . / 168

■ ORBIT / 168
Before you dissect . . . / 168
- *Skeleton of the Orbit / 168*
- *Surface Anatomy of the Eyeball, Eyelids, and Lacrimal Apparatus / 169*

Dissection Instructions / 170
- *Eyelid and Lacrimal Apparatus / 170*
- *Right Orbit from the Superior Approach / 171*
- *Left Orbit from the Anterior Approach / 173*

After you dissect . . . / 174

■ POSTERIOR TRIANGLE OF THE NECK / 174
Before you dissect . . . / 174
Dissection Instructions / 174
- *Skin Incisions / 174*
- *Structures in the Posterior Triangle / 174*

After you dissect . . . / 176

■ ANTERIOR TRIANGLE OF THE NECK / 176
Before you dissect . . . / 176
- *Bones and Cartilages / 176*

Dissection Instructions / 177
- *Superficial Fascia / 177*
- *Muscular Triangle / 177*
- *Carotid Triangle / 178*
- *Submandibular Triangle / 179*
- *Submental Triangle / 180*

After you dissect . . . / 180

■ THYROID AND PARATHYROID GLANDS / 180
Before you dissect . . . / 180
Dissection Instructions / 180
After you dissect . . . / 181

■ ROOT OF THE NECK / 181
Before you dissect . . . / 181
Dissection Instructions / 181
After you dissect . . . / 183

■ PAROTID REGION / 184
Before you dissect . . . / 184
- *Skeleton of the Parotid Region / 184*

Dissection Instructions / 184
After you dissect . . . / 185

■ TEMPORAL REGION / 185
Before you dissect . . . / 185
- *Skeleton of the Temporal Region / 185*

Dissection Instructions / 186
- *Removal of the Zygomatic Arch / 186*
- *Temporal Fossa / 187*
- *Infratemporal Fossa / 187*
- *Temporomandibular Joint / 189*

After you dissect . . . / 189

■ CRANIOVERTEBRAL JOINTS AND REMOVAL OF THE HEAD / 189
Before you dissect . . . / 189
- *Skeleton of the Suboccipital Region / 189*

Dissection Instructions / 190
- *Retropharyngeal Space / 190*
- *Craniovertebral Joints / 190*
- *Removal of the Head / 191*
- *Prevertebral and Lateral Vertebral Regions / 191*

After you dissect . . . / 192

■ PHARYNX / 192
Before you dissect . . . / 192
Dissection Instructions / 192
- *Muscles of the Pharyngeal Wall / 192*
- *Bisection of the Head / 194*
- *Internal Aspect of the Pharynx / 194*

After you dissect . . . / 195

■ NOSE AND NASAL CAVITY / 195
Before you dissect . . . / 195
- *Skeleton of the Nasal Cavity / 195*

Dissection Instructions / 196
- *External Nose / 196*
- *Nasal Cavity / 196*
- *Nasal Septum / 196*
- *Lateral Wall of the Nasal Cavity / 197*

After you dissect . . . / 198

■ HARD PALATE AND SOFT PALATE / 198
Before you dissect . . . / 198
- *Skeleton of the Palate / 199*

Dissection Instructions / 199
- *Soft Palate / 199*
- *Tonsillar Bed / 201*
- *Sphenopalatine Foramen and Pterygopalatine Fossa / 201*

After you dissect . . . / 202

■ ORAL REGION / 202
Before you dissect . . . / 202
- *Surface Anatomy of the Oral Vestibule / 202*
- *Surface Anatomy of the Oral Cavity Proper / 202*

Dissection Instructions / 203
- *Tongue / 203*
- *Bisection of the Mandible and Floor of the Mouth / 203*
- *Sublingual Region / 203*

After you dissect . . . / 204

■ LARYNX / 205
Before you dissect . . . / 205
- *Skeleton of the Larynx / 205*

Dissection Instructions / 206
- *Intrinsic Muscles of the Larynx / 206*
- *Interior of the Larynx / 207*

After you dissect . . . / 207

■ EAR / 208
Before you dissect . . . / 208
- *Temporal Bone / 208*

Dissection Instructions / 208
- *External Ear / 208*
- *Middle Ear / 208*
- *Internal Ear / 210*

After you dissect . . . / 210

CHAPTER 1

THE BACK

The back region contains the **superficial muscles of the back (posterior thoracoappendicular muscles)**, the **intermediate muscles of the back,** and the **deep muscles of the back**. All of these muscles attach to the vertebral column. The vertebral column serves the dual purpose of forming the axis of the body and providing a protective bony covering for the spinal cord.

SURFACE ANATOMY

The surface anatomy of this region may be studied on a living subject or on the cadaver. In the cadaver, fixation may make it difficult to distinguish bone from well-preserved soft tissues. Turn the cadaver to the prone position (face down) and palpate the following structures (Fig. 1.01): **[N 145]**

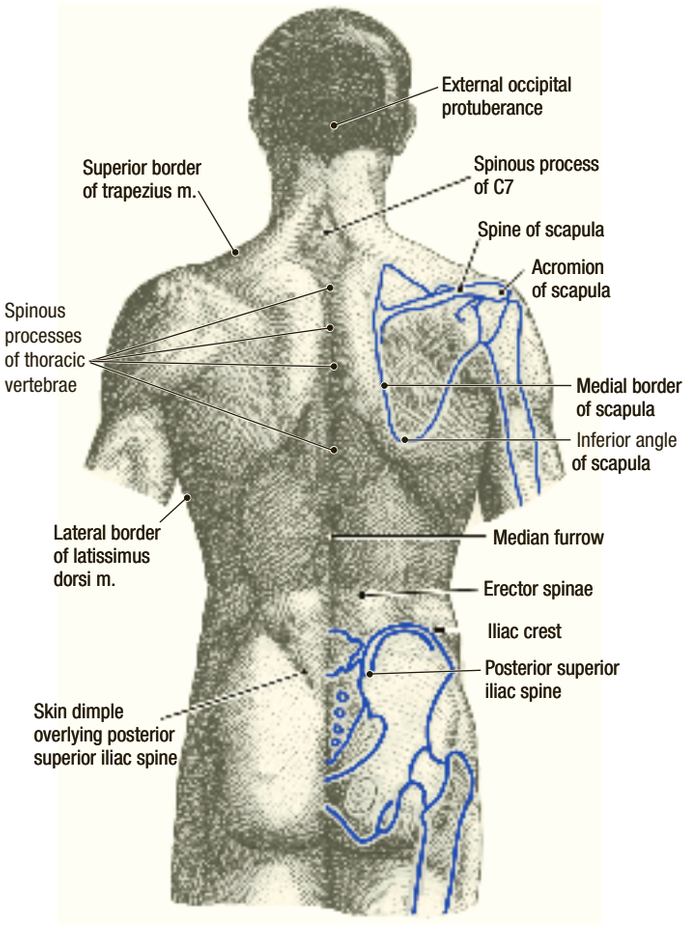

Figure 1.01. Surface anatomy of the back.

KEY TO REFERENCES
G = Grant's Atlas, 11th ed., page number
N = Netter's Atlas, 3rd ed., plate number
R = Rohen's Color Atlas of Anatomy, 5th ed., page number
C = Clemente's Atlas, 4th ed., page number

- **External occipital protuberance**
- **Superior border of the trapezius muscle**
- **Spinous process of the 7th cervical vertebra (vertebra prominens)**
- **Spine of the scapula** (at vertebral level T3)
- **Acromion of the scapula**
- **Medial (vertebral) border of the scapula**
- **Inferior angle of the scapula** (at vertebral level T7)
- **Spinous processes of thoracic vertebrae**
- **Erector spinae muscle** (most noticeable in the lumbar region)
- **Median furrow**
- **Lateral border of the latissimus dorsi muscle (posterior axillary fold)**
- **Iliac crest** (at vertebral level L4)
- **Posterior superior iliac spine**

SKELETON OF THE BACK

Refer to a skeleton. On the **scapula**, identify (Fig. 1.02): **[G 459; N 404; R 359; C 70]**

- **Acromion**
- **Spine**
- **Superior angle**
- **Medial (vertebral) border**
- **Inferior angle**

On the **ilium**, identify (Fig. 1.02): **[G 299; N 152; R 184; C 249]**

- **Iliac crest**
- **Posterior superior iliac spine**

On the **occipital bone**, identify (Fig. 1.02):

- **External occipital protuberance (inion)**
- **Superior nuchal line**

On the **temporal bone**, identify (Fig. 1.02):

- **Mastoid process**

The **vertebral column** (Fig. 1.02) consists of 33 vertebrae: 7 cervical (C), 12 thoracic (T), 5 lumbar (L), 5 sacral (S), and 4 coccygeal (Co). The upper 24 vertebrae (cervical, thoracic, and lumbar) allow flexibility and movement of the vertebral column, whereas the sacral vertebrae are fused to provide rigid support of the pelvic girdle. A typical thoracic vertebra will be described, and the cervical and lumbar vertebrae will be compared to it. **[G 276; N 146; R 189; C 422]**

Refer to a disarticulated **thoracic vertebra** and identify (Fig. 1.03): **[G 286; N 147; R 186; C 423]**

- **Body**
- **Vertebral arch –** formed by the combination of pedicles and laminae
- **Pedicle** (2)
- **Lamina** (2)
- **Vertebral foramen**

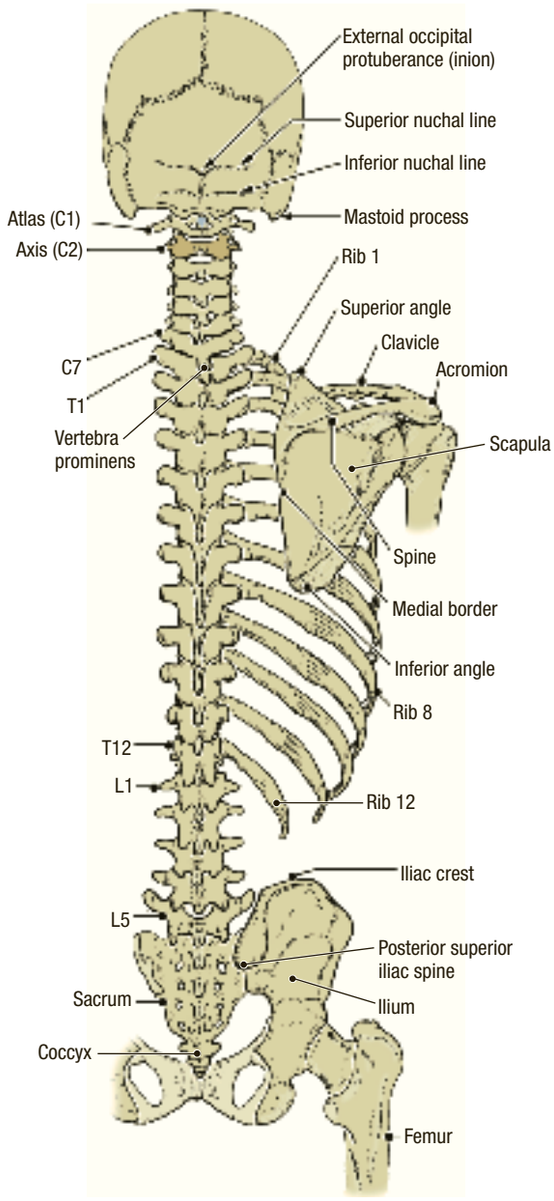

Figure 1.02. Skeleton of the back and vertebral column.

- **Transverse process** (2)
- **Transverse costal facet**
- **Spinous process**
- **Articular processes –** superior and inferior
- **Vertebral notches –** superior and inferior
- **Costal facets –** superior and inferior

The spinous process of a thoracic vertebra is long, slender, and directed inferiorly over the spinous process of the vertebra that is inferior to it. Articulation with ribs is a unique characteristic of thoracic vertebrae. The head of a rib articulates with the bodies of two adjacent vertebrae (Fig. 1.04). The tubercle of a rib articulates with the transverse costal facet of the thoracic vertebra of the same number (i.e., the tubercle of rib 5 articulates with the transverse costal facet of vertebra T5). An **intervertebral disk** and the **articular processes** unite two adjacent vertebrae. The vertebral notches of two adjacent vertebrae combine to form an **intervertebral foramen**. A spinal nerve passes through the intervertebral foramen.

Cervical vertebrae differ from thoracic vertebrae in the following ways (Fig. 1.05): cervical vertebrae have smaller bodies,

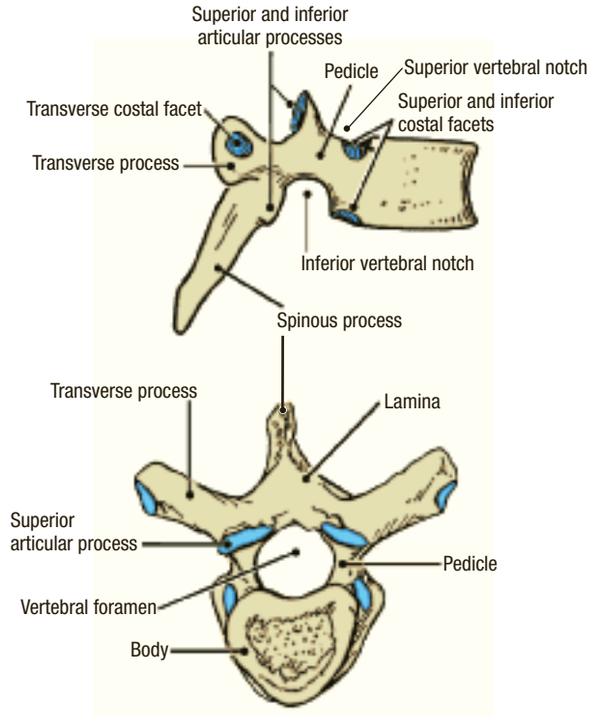

Figure 1.03. Typical thoracic vertebra in lateral and superior view.

larger vertebral foramina, shorter spinous processes that bifurcate at the tip, and transverse processes that contain a foramen transversarium. On an articulated skeleton, identify the following features common to all cervical vertebrae: **[G 284; N 15; R 186; C 418]**

- **Transverse process**
- **Foramen transversarium**
- **Spinous process**

On a skeleton, observe the following features of individual cervical vertebrae:

- **Atlas** (C1) – does not have a body.
- **Axis** (C2) – has the **dens**, which is the body of C1 that has become fused to C2 during development.
- **Vertebra prominens** (C7) – has the most prominent spinous process in the cervical region, hence its name.

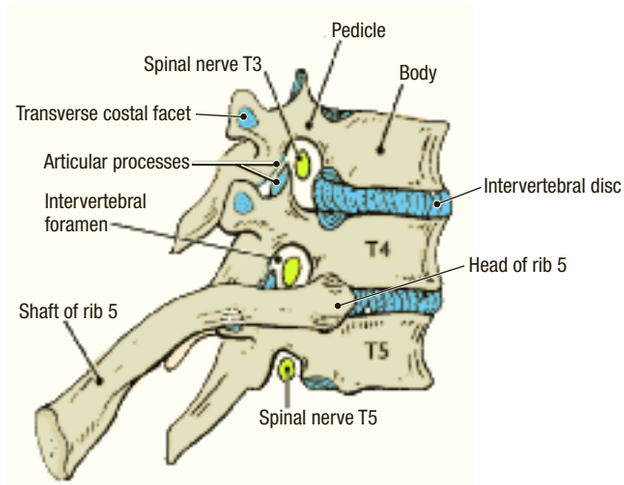

Figure 1.04. Part of the thoracic vertebral column.

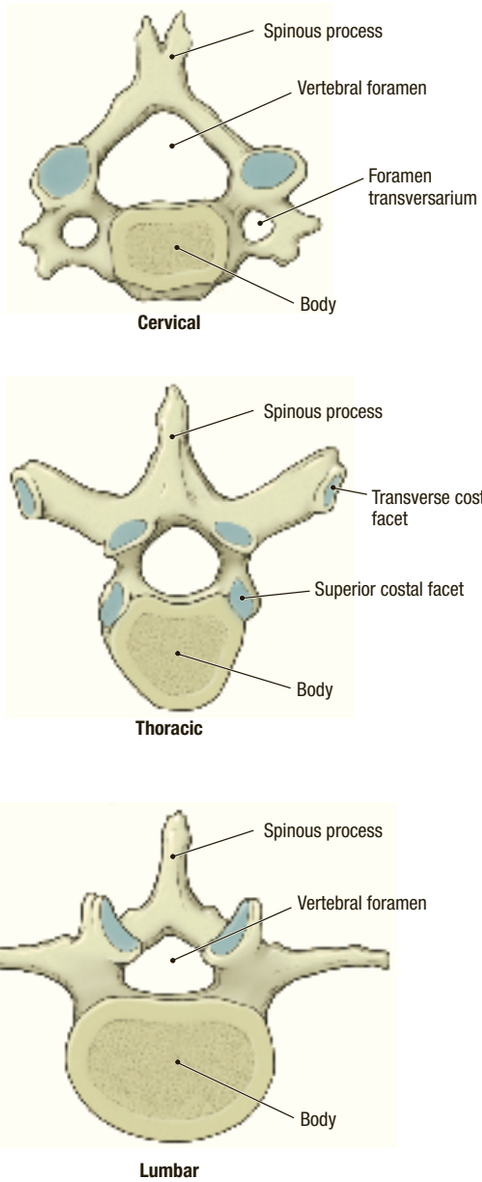

Figure 1.05. Comparison of cervical, thoracic, and lumbar vertebrae.

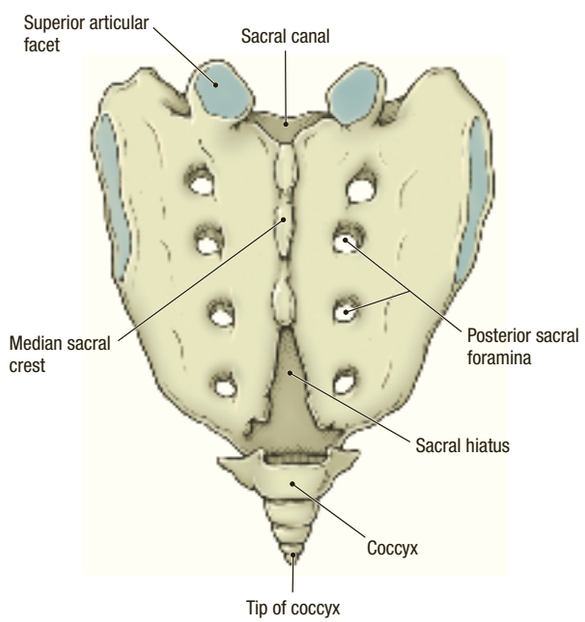

Figure 1.06. Sacrum and coccyx.

Lumbar vertebrae differ from thoracic vertebrae in the following ways (Fig. 1.05): lumbar vertebrae have larger bodies, broad spinous processes that project posteriorly, and they do not have articular facets for ribs. On a skeleton, observe the lumbar vertebrae and notice that their spines do not overlap like the spines of thoracic vertebrae. **[G 289; N 148; R 186; C 426]**

The **sacrum** is formed by five fused vertebrae and it does not have identifiable spines or transverse processes. On the dorsal surface of the sacrum, identify (Fig. 1.06): **[G 293; N 150; R 187; C 428]**

- **Median sacral crest**
- **Posterior (dorsal) sacral foramina**
- **Sacral hiatus**

The **coccyx** is a small triangular bone formed by four rudimentary coccygeal vertebrae that are fused together (Fig. 1.06).

SKIN AND SUPERFICIAL FASCIA

Before you dissect . . .

The order of dissection will be as follows: the skin will be removed from the back, posterior surface of the neck, and posterior surface of the proximal upper limb. Posterior cutaneous nerves will be studied. The superficial fascia will then be removed.

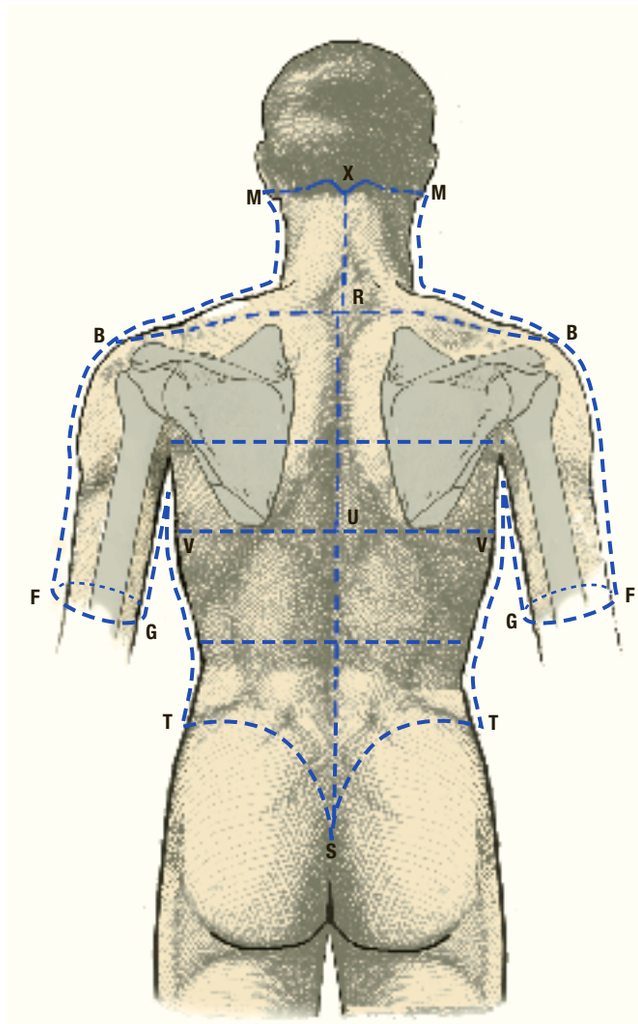

Figure 1.07. Skin incisions.

Dissection Instructions

SKIN INCISIONS

1. Refer to Figure 1.07.
2. Use a scalpel to make a vertical skin incision in the midline from the external occipital protuberance (X) to the tip of the coccyx (S). The skin is approximately 6-mm-thick in this region.
3. Make an incision from S to the midaxillary line (T). This incision should pass approximately 3 cm inferior to the iliac crest.
4. At the level of the inferior angle of the scapula, make a transverse skin incision from the midline (U) to the midaxillary line (V). To facilitate skinning, make a parallel transverse incision above and below this one.
5. Make a transverse skin incision from R to B, superior to the scapula and superior to the acromion. Extend this incision to point F, approximately halfway down the arm.
6. At point F, make an incision around the anterior and posterior surfaces of the arm, meeting on the medial side (G). If the upper limb has been dissected previously, this incision has already been made.
7. Make a skin incision that begins at G on the medial surface of the arm and extends superiorly to the axilla. Extend this incision inferiorly along the lateral surface of the trunk, through V to T.
8. Make a transverse skin incision from the external occipital protuberance (X) laterally to the base of the mastoid process (M).
9. Make an incision along the lateral surface of the neck and superior border of the trapezius muscle (M to B).
10. Remove the skin from medial to lateral. Detach the skin and place it in the tissue container.

SUPERFICIAL FASCIA

1. In the superficial fascia, locate the **occipital artery** and the **greater occipital nerve** (Fig. 1.08). First, find the occipital artery and then look on its medial side for the greater occipital nerve. The greater occipital nerve is the dorsal primary ramus of spinal nerve C2. The greater occipital nerve pierces the **trapezius muscle** approximately 3 cm inferolateral to the **external occipital protuberance**. The deep fascia in this area is very dense and tough. Therefore, it may be difficult to find the greater occipital nerve, even though it is large. **[G 307; N 171; R 212; C 414]**
2. Read a description of the **dorsal primary ramus of a spinal nerve**. The **posterior cutaneous branches** of the dorsal primary rami pierce the trapezius muscle or latissimus dorsi muscle to enter the superficial fascia (Fig. 1.08). To save time, make no deliberate effort to display posterior cutaneous branches of the dorsal primary rami. **[G 20; N 187; R 204]**
3. Reflect the superficial fascia of the back from medial to lateral. Detach the superficial fascia by cutting it along the skin incision lines and place it in the tissue container.

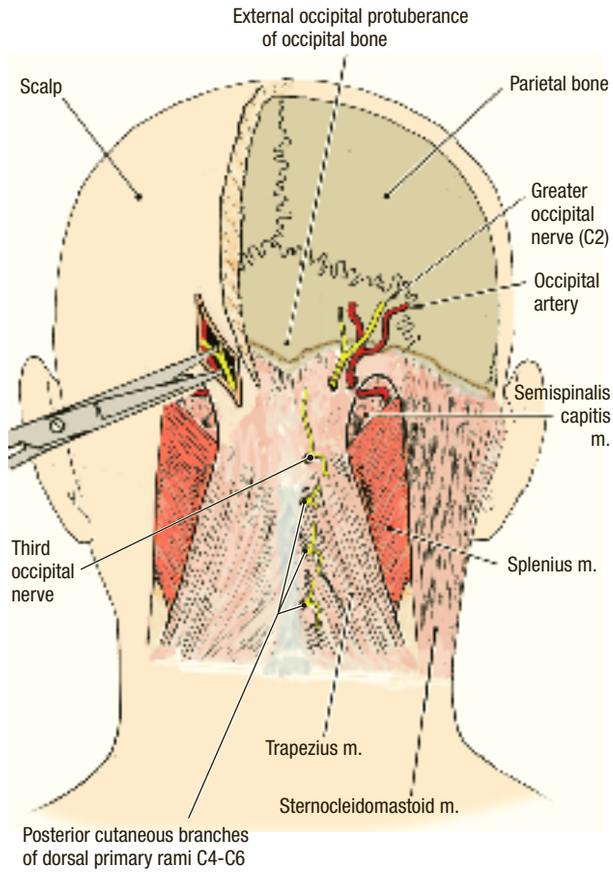

Figure 1.08. Greater occipital nerve and occipital artery.

4. In the neck, reflect the superficial fascia only as far laterally as the superior border of the trapezius muscle. *Do not cut the deep fascia along the superior border of the trapezius muscle*. The accessory nerve is superficial at this location and it is in danger of being cut.

After you dissect . . .

Review the branching pattern of a typical spinal nerve and understand that cutaneous branches of the dorsal primary rami innervate the skin of the back. Study a dermatome chart and become familiar with the concept of segmental innervation. **[G 331; N 157; C 404]**

SUPERFICIAL MUSCLES OF THE BACK

Before you dissect . . .

The **superficial muscles of the back are** also called the **posterior thoracoappendicular muscles** because they attach to the axial skeleton and the upper limb. There are five superficial muscles of the back: **trapezius**, **latissimus dorsi**, **rhomboid major**, **rhomboid minor**, and **levator scapulae**.

The order of dissection will be as follows: the superficial surface of the trapezius muscle will be cleaned. The trapezius muscle will be examined and reflected. The latissimus dorsi muscle will be studied and reflected. The rhomboid major muscle,

rhomboid minor muscle, and levator scapulae muscle will be studied. Dissection of the superficial back muscles should be performed bilaterally.

Dissection Instructions

TRAPEZIUS MUSCLE [G 307; N 167; R 212; C 407]

1. Clean the surface of the **trapezius muscle** (L. *trapezoides*, an irregular four-sided figure) (Fig. 1.09). *Do not disturb the superior border of the trapezius muscle*. Observe the proximal attachment of the trapezius muscle on the external occipital protuberance, the nuchal ligament, and the spinous processes of vertebrae C7 to T12.
2. The trapezius muscle has three parts with distinctly different actions:
   - **Superior part** of the trapezius muscle attaches to the lateral one-third of the clavicle and it elevates the scapula.
   - **Middle part** of the trapezius muscle attaches to the acromion and spine of the scapula and it retracts the scapula.
   - **Inferior part** of the trapezius muscle attaches near the medial end of the spine of the scapula and it depresses the scapula.
3. Reflect the trapezius muscle. Insert your fingers deep to the trapezius muscle, starting at the posterolateral border of the muscle (medial to the inferior angle of the scapula). Break the plane of loose connective tissue between the trapezius muscle and the deeper muscles of the back.

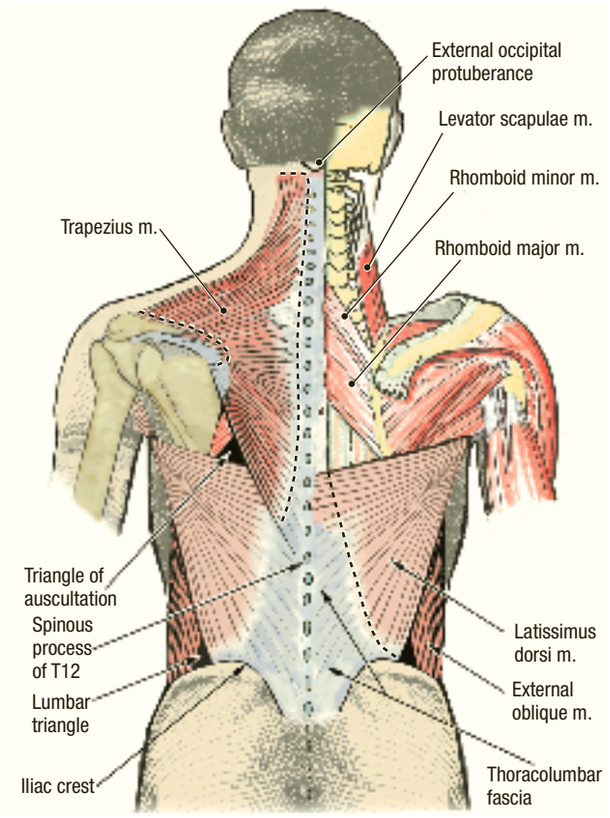

Figure 1.09. How to reflect the muscles of the back.

4. Use scissors to detach the trapezius muscle from its proximal attachment on the spinous processes and the nuchal ligament (dashed line, Fig. 1.09). Start inferiorly and continue the cut superiorly as far as the external occipital protuberance.
5. Use scissors to make a short transverse cut (2.5 cm) across the superior end of the trapezius muscle to detach it from the superior nuchal line. *Spare the greater occipital nerve, and do not extend the transverse cut beyond the border of the trapezius muscle.*
6. Use a scalpel to shave the trapezius muscle from its distal attachments on the spine and acromion of the scapula. Cut very close to the bone. Leave the trapezius muscle attached to the clavicle and cervical fascia.
7. Reflect the trapezius muscle superolaterally. Leave the cervical fascia attached along the superior border of the trapezius muscle to act as a hinge.
8. Study the deep surface of the reflected trapezius muscle. Find the plexus of nerves formed by the **accessory nerve** and **branches of the ventral primary rami of spinal nerves C3 and C4**. The accessory nerve provides motor innervation to the trapezius muscle; the branches of nerves C3 and C4 are sensory (proprioception). The superficial branch of the **transverse cervical artery** accompanies the nerves. Remove the transverse cervical vein to clear the dissection field.
9. The accessory nerve (cranial nerve XI) passes through the posterior triangle of the neck. Do not follow the nerve into the posterior triangle at this time. The posterior triangle will be dissected with the neck.

LATISSIMUS DORSI MUSCLE [G 307; N 167; R 212; C 407]

1. Clean the surface and define the borders of the **latissimus dorsi muscle** (L. *latissimus*, widest) (Fig. 1.09).
2. The proximal attachments of the latissimus dorsi muscle are the spines of vertebrae T7 to T12, the thoracolumbar fascia, and the iliac crest. The latissimus dorsi muscle also attaches to the inferior three or four ribs, lateral to their angles.
3. Note that the distal attachment of the latissimus dorsi muscle is the floor of the intertubercular sulcus on the anterior side of the humerus, but do not dissect this attachment. The latissimus dorsi muscle receives the **thoracodorsal nerve and artery** on its anterior surface near its distal attachment. The distal attachment of the latissimus dorsi muscle, its nerve, and its artery will be dissected with the upper limb.
4. Insert your fingers deep to the superior border of the latissimus dorsi muscle (medial to the inferior angle of the scapula) and break the plane of loose connective tissue between it and deeper structures. Raise the latissimus dorsi muscle enough to insert scissors and cut through its proximal attachment on the thoracolumbar fascia (dashed line, Fig. 1.09). Do not cut too close to the lumbar spinous processes.
5. Reflect the latissimus dorsi muscle laterally. It may have an attacment to the inferior angle of the scapula. Do not disturb its attachment to the scapula or its attachments to the inferior ribs.

RHOMBOID MAJOR AND RHOMBOID MINOR MUSCLES [G 308; N 170; R 212; C 407]

1. Clean the surface and borders of the **rhomboid (rhomboideus) minor muscle** and the **rhomboid major muscle** (Gr. *rhombos*, shaped like a kite). The plane of separation between the rhomboid muscles may not be obvious.
2. The proximal attachments of the rhomboid minor muscle are the nuchal ligament and the spinous processes of vertebrae C7 and T1. The distal attachment of the rhomboid minor muscle is the medial border of the scapula near the spine.
3. The proximal attachments of the rhomboid major muscle are the spinous processes of vertebrae T2 to T5. The distal attachment of the rhomboid major muscle is the medial border of the scapula inferior to the spine.
4. The rhomboid muscles retract the scapula, rotate the scapula to depress the glenoid cavity, and hold the scapula close to the thoracic wall.
5. Reflect the rhomboid muscles. Beginning at the inferior angle of the scapula, insert your fingers deep to the rhomboid major muscle and separate it from deeper muscles.
6. Use scissors to detach the rhomboid major muscle from its proximal attachments. Continue the cut superiorly and detach the rhomboid minor muscle from its proximal attachments. Reflect these two muscles laterally.
7. Examine the deep surface of the rhomboid muscles. Use blunt dissection to find the **dorsal scapular nerve** and **dorsal scapular vessels**. Remove the dorsal scapular vein to clear the dissection field. The dorsal scapular nerve and artery course parallel to the medial border of the scapula. The dorsal scapular artery may branch directly from the subclavian artery, or it may arise from the transverse cervical artery in which case it is also called the **deep branch of the transverse cervical artery**.

LEVATOR SCAPULAE MUSCLE [G 308; N 167; R 214; C 407]

1. Identify the **levator scapulae muscle** (L. *levare*, to raise).
2. Note that the proximal attachments of the levator scapulae muscle are the transverse processes of the upper four cervical vertebrae. Do not dissect its proximal attachments.
3. The distal attachment of the levator scapulae muscle is the superior angle of the scapula. The levator scapulae muscle can be seen only near its distal attachment.
4. The dorsal scapular nerve and artery supply the levator scapulae muscle. The levator scapulae muscle elevates the scapula and rotates the scapula to depress the glenoid cavity.

After you dissect . . .

Replace the superficial muscles of the back in their correct anatomical positions. Use the dissected specimen to review the proximal attachment, distal attachment, action, innervation, and blood supply of each muscle that you have dissected. Review the movements that occur between the scapula and the thoracic wall. Use an illustration to observe the origin of the transverse cervical artery and the dorsal scapular artery. Observe two triangles associated with the latissimus dorsi muscle: The **triangle of auscultation** and the **lumbar triangle (of Petit)** (Fig. 1.09).

CLINICAL CORRELATION

Triangles of the Back [G 4.28, 4.29; N 246]

The **triangle of auscultation** is bounded by the latissimus dorsi muscle, the trapezius muscle, and the rhomboid major muscle. Within the triangle of auscultation, intercostal space 6 has no overlying muscles. This area is particularly well-suited for auscultation (listening to sounds produced by thoracic organs, particularly the lungs).

The **lumbar triangle** is bounded by the latissimus dorsi muscle, the external oblique muscle, and the iliac crest. The floor of the lumbar triangle is the internal oblique muscle of the abdomen. On rare occasions, the lumbar triangle is the site of a lumbar hernia.

INTERMEDIATE MUSCLES OF THE BACK [G 308; N 167; R 219; C 408]

Dissection Instructions

The **intermediate muscles of the back** are the **serratus posterior superior muscle** and the **serratus posterior inferior muscle.** These are very thin muscles, which may be accidentally reflected with the rhomboid muscles or the latissimus dorsi muscle. If you do not see the serratus posterior muscles, look for them on the deep surface of the rhomboid muscles or the latissimus dorsi muscle.

1. The proximal attachments of the **serratus posterior superior muscle** are the nuchal ligament and the spinous processes of vertebrae C7 to T3. Its distal attachments are the superior borders of ribs 2 to 4, lateral to their angles.
2. The proximal attachments of the **serratus posterior inferior muscle** are the spinous processes of vertebrae T11 to L2. Its distal attachments are the inferior borders of ribs 8 to 12, lateral to their angles.
3. The serratus posterior muscles are respiratory muscles, and they are innervated by intercostal nerves.
4. Detach both serratus posterior muscles from the spinous processes. Reflect the muscles laterally, leaving them attached to the ribs.

DEEP MUSCLES OF THE BACK

Before you dissect . . .

The **deep muscles of the back** act on the vertebral column. There are many deep muscles of the back (Fig. 1.10) and only a few will be dissected: **splenius muscle, semispinalis capitis muscle,** and **erector spinae muscle**. All of the deep muscles of the back are innervated by dorsal primary rami of spinal nerves.

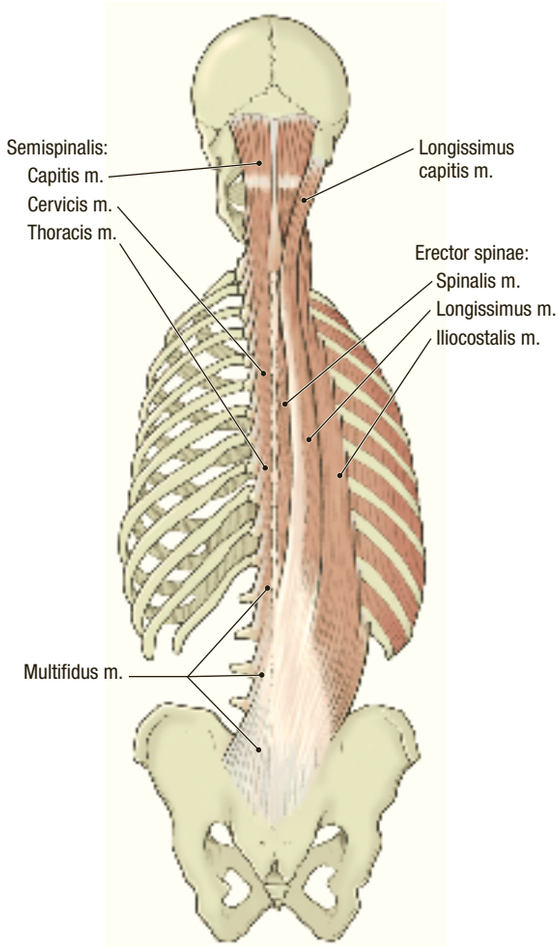

Figure 1.10. Deep muscles of the back.

The order of dissection will be as follows: the deep muscles of the posterior neck (splenius and semispinalis capitis) will be studied. The erector spinae muscle will be dissected and its component parts will be identified.

Dissection Instructions

SPLENIUS MUSCLE [G 309; N 167; R 212; C 408]

1. Identify the **splenius muscle** (Gr. *splenion*, bandage). The splenius muscle lies deep to the trapezius muscle and its fibers course obliquely across the neck. The proximal attachment of the splenius muscle is the nuchal ligament and the spinous processes of vertebrae C7 to T6.
2. The splenius muscle has two parts that are named according to their distal attachments:
   - **Splenius capitis muscle** (L. *caput*, head) is attached to the mastoid process of the temporal bone and the superior nuchal line of the occipital bone.
   - **Splenius cervicis muscle** (L. *cervix*, neck) is attached to the transverse processes of the vertebrae C1 to C4.
3. Detach the splenius muscle from the nuchal ligament and the spinous processes of vertebrae C7 to T6.
4. Reflect the muscle laterally, leaving its distal attachments undisturbed.

SEMISPINALIS CAPITIS MUSCLE [G 311; N 168; R 214; C 409]

1. Identify the **semispinalis capitis muscle** (L. *semi*, half; L. *spinalis*, spine) (Fig. 1.10). The semispinalis capitis muscle lies deep to the splenius muscle and its fibers course vertically, parallel to the long axis of the neck. The inferior attachments of the semispinalis capitis muscle are the transverse processes of the upper thoracic vertebrae.
2. The superior attachment of the semispinalis capitis muscle is the occipital bone between the superior and inferior nuchal lines. Note that the greater occipital nerve passes through the semispinalis capitis muscle.
3. Do not dissect the semispinalis capitis muscle further at this time.

ERECTOR SPINAE MUSCLE [G 309; N 168; R 214; C 409]

1. The erector spinae muscle lies deep to the serratus posterior muscles. The erector spinae muscle is composed of three columns of muscle.
2. Use a scalpel to incise the posterior surface of the **thoracolumbar fascia**. Use blunt dissection to remove it from the posterior surface of the erector spinae muscle.
3. The columns of the erector spinae muscle are fused at the level of their inferior attachments to the sacrum and ilium. Use your fingers to separate the columns at thoracic levels.
4. Identify the **three columns of the erector spinae muscle** (L. *erector*, one who erects) (Fig. 1.10):
   - **Spinalis muscle** forms the medial column of the erector spinae muscle. The inferior attachments of the spinalis muscle are on spinous processes. Its superior attachments are also on spinous processes. The spinalis muscle is present at lumbar, thoracic and cervical vertebral levels.
   - **Longissimus muscle** (L. *longissimus*, the longest) is the intermediate column of the erector spinae muscle. Its inferior attachment is on the sacrum and its superior attachments are the transverse processes of the thoracic and cervical vertebrae. Note that its most superior portion, the **longissimus capitis muscle**, attaches to the mastoid process of the temporal bone.
   - **Iliocostalis muscle** is the lateral column of the erector spinae muscle. Its inferior attachment is the ilium (iliac crest) and its superior attachments are on ribs (L. *costa*, rib).
5. All three columns of the erector spinae muscle extend the vertebral column when both sides work together. If only one side is active, the erector spinae muscle bends the vertebral column laterally toward the side that is active.

TRANSVERSOSPINAL GROUP OF MUSCLES [G 312; N 169; R 215; C 411]

The **transversospinal group of muscles** is located deep to the erector spinae muscle. The muscles in the transversospinal group attach to transverse processes and spinous

processes (Fig. 1.10). The muscles of the transversospinal group cause rotational and lateral bending movements between adjacent vertebrae and act to stabilize the vertebral column. A number of muscles comprise this group: **semispinalis**, **multifidus**, and, more deeply, **rotatores**. The semispinalis capitis muscle has been dissected. Do not dissect the other muscles of the transversospinal group.

After you dissect . . .

Use the dissected specimen to review the location, innervation, and action of each column of muscles in the deep group of back muscles.

SUBOCCIPITAL REGION

Before you dissect . . .

On a skull, identify (Fig. 1.02): **[G 592; N 8; R 50; C 498]**

- **Superior nuchal line**
- **Inferior nuchal line**
- **External occipital protuberance**
- **Foramen magnum**

On the **atlas** (C1 vertebra), identify (Fig. 1.11): **[G 282; N 15; R 193; C 418]**

- **Posterior tubercle**
- **Posterior arch**
- **Groove for the vertebral artery**
- **Transverse process**
- **Foramen transversarium**

On the **axis** (C2 vertebra), identify (Fig. 1.11):

- **Spinous process**
- **Transverse process**
- **Foramen transversarium**

The order of dissection will be as follows: the greater occipital nerve will be identified and followed deeply. The semispinalis capitis muscle will be reflected. The muscles that bound the suboccipital triangle will be identified. The contents of the suboccipital region (vertebral artery and suboccipital nerve) will be studied.

Dissection Instructions

1. Identify the **semispinalis capitis muscle** (Fig. 1.12). **[G 314; N 169; R 227; C 409]**
2. Once again, find the **greater occipital nerve**. Use blunt dissection to trace the greater occipital nerve through the semispinalis capitis muscle. Detach the semispinalis capitis muscle close to the occipital bone and reflect it inferiorly.
3. Deep to the semispinalis capitis muscle, follow the greater occipital nerve to the lower border of the **obliquus capitis inferior muscle**. Note that the greater occipital nerve (C2) emerges between vertebrae C1 and C2.
4. Identify and clean the three muscles that form the **boundaries of the suboccipital triangle** (Fig. 1.12): **[G 317; N 171; R 228; C 417]**
   - **Obliquus capitis inferior muscle** forms the inferior boundary of the suboccipital triangle. Verify that the proximal attachment of the obliquus capitis inferior muscle is the spinous process of the axis (C2). Its distal attachment is onto the transverse process of the atlas (C1).

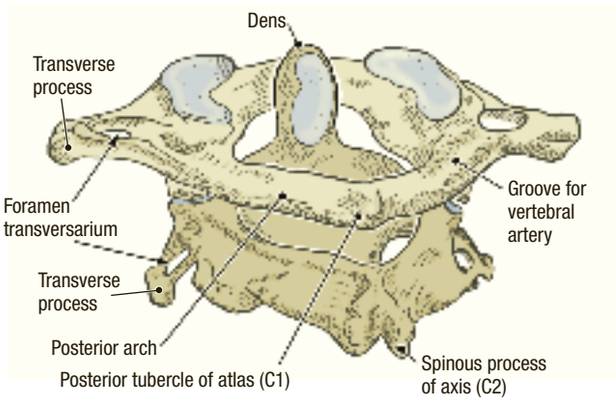

Figure 1.11. Features of the atlas (C1) and axis (C2).

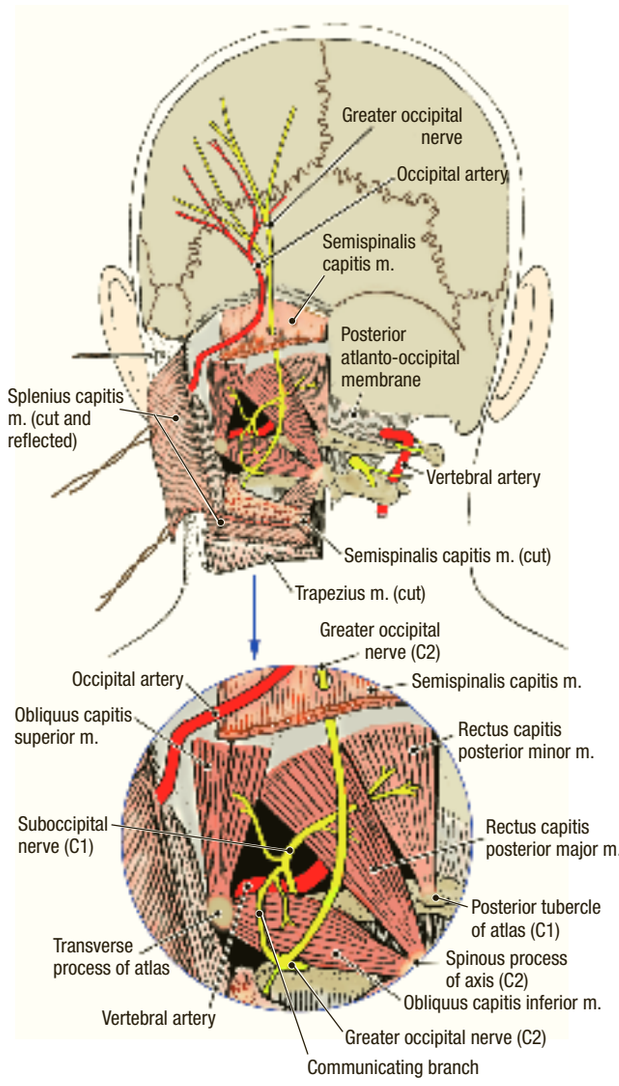

Figure 1.12. Suboccipital region.

- **Rectus capitis posterior major muscle** forms the medial boundary of the suboccipital triangle. Confirm that the proximal attachment of the rectus capitis posterior major muscle is the spinous process of the axis. Its distal attachment is the inferior nuchal line of the occipital bone.
- **Obliquus capitis superior muscle** forms the lateral boundary of the suboccipital triangle. Confirm that the inferior attachment of the obliquus capitis superior muscle is the transverse process of the atlas. Its superior attachment is the occipital bone between the superior and inferior nuchal lines.

5. The muscles that bound the suboccipital triangle produce extension and lateral bending of the head at the atlanto-occipital joints, and rotation of the head at the atlantoaxial joints.
6. The **contents of the suboccipital triangle** are the **suboccipital nerve** and the **vertebral artery** (Fig. 1.12). Note that the suboccipital nerve (dorsal primary ramus of C1) emerges between the occipital bone and vertebra C1. The suboccipital nerve supplies motor innervation to the muscles of the suboccipital region. The suboccipital nerve is unique among dorsal primary rami in that it has no cutaneous distribution.
7. Identify the **vertebral artery**. Use an illustration to study the course of the vertebral artery through the neck and into the skull. **[G 319; N 130; R 166; C 458]**

After you dissect . . .

Review the actions of the suboccipital muscles. Review the distribution of the branches of a thoracic dorsal primary ramus and compare the thoracic pattern to the distribution of the dorsal primary rami of spinal nerves C1 to C3.

VERTEBRAL CANAL, SPINAL CORD, AND MENINGES

Before you dissect . . .

The **vertebral canal** is a bony tube formed by the stacked **vertebral foramina** of the **cervical vertebrae**, **thoracic vertebrae**, **lumbar vertebrae**, and the **sacral canal** (Fig. 1.13). The vertebral canal encloses and protects the **spinal cord**, its membranes (**spinal meninges**), and blood vessels. The spinal cord begins at the foramen magnum of the occipital bone and usually terminates in the adult at the level of the second lumbar vertebra. Because the spinal cord is shorter than the vertebral canal, *the spinal cord segments are found at higher vertebral levels than their names would suggest* (Fig. 1.13).

The spinal cord is not uniform in diameter throughout its length. It has a **cervical enlargement** (Fig. 1.13) that corresponds to spinal cord segments C4 to T1 and a **lumbar enlargement** that corresponds to spinal cord segments L2 to S3. There are 31 pairs of **spinal nerves** (8 cervical; 12 thoracic; 5 lumbar; 5 sacral; 1 coccygeal) (Fig. 1.13), which emerge between adjacent vertebrae. Spinal nerves are numbered according to the vertebra above. However, *in the cervical region, spinal nerves are numbered for the vertebra below, and the C8 spinal nerve does not have a correspondingly numbered vertebra.*

The order of dissection will be as follows: the erector spinae muscles will be removed to expose the laminae of the vertebrae. The laminae will then be cut and removed (laminectomy) to expose the spinal meninges. The spinal meninges will be examined and will be opened to expose the spinal cord. The spinal cord will then be studied.

Dissection Instructions

1. *Wear eye protection for all steps that require the use of a chisel, bone saw, or bone forceps.*
2. Use a scalpel to remove the erector spinae muscles bilaterally from vertebral levels C4 to S3. The laminae must be clearly exposed. Use scraping motions with a chisel to clean the laminae after the muscles have been removed.
3. Use a chisel or power saw to cut the **laminae** of vertebrae T6 to T12 on both sides of the spinous processes (Fig. 1.14). Make this cut at the lateral end of the laminae to gain wide exposure to the vertebral canal. The cutting instrument should be angled at 45 degrees to the vertical.
4. Use a scalpel to cut the interspinous ligaments between vertebrae T5 and T6 and between vertebrae T12 and L1. Leave the remaining interspinous ligaments undisturbed to maintain the laminectomy specimen intact.
5. Use a chisel to pry the six spinous processes and their laminae out as a unit. The dura mater will be undamaged.
6. Observe the **ligamenta flava** on the deep surface of the laminectomy specimen. The ligamenta flava connect the laminae of adjacent vertebrae.
7. Continue the laminectomy procedure superiorly and inferiorly from the opening in the vertebral canal. Exercise caution in lower lumbar and sacral regions, because the vertebral canal curves sharply posteriorly (Fig. 1.15A). Do not drive the chisel or push the saw through the sacrum into the rectum.
8. When finished with the laminectomy, you should see the posterior surface of the dura mater from vertebral levels C4 to S2.

SPINAL MENINGES

1. Observe the **epidural (extradural) space**. Use blunt dissection to remove the **epidural fat** and the **posterior internal vertebral venous plexus** from the epidural space. **[N 163]**

CLINICAL CORRELATION

Vertebral Venous Plexuses

The veins of the vertebral venous plexuses are valveless, permitting blood to flow superiorly or inferiorly depending on blood pressure gradients. The vertebral venous plexuses can serve as routes for metastasis of cancer from the pelvis to the vertebrae, vertebral canal, and cranial cavity.

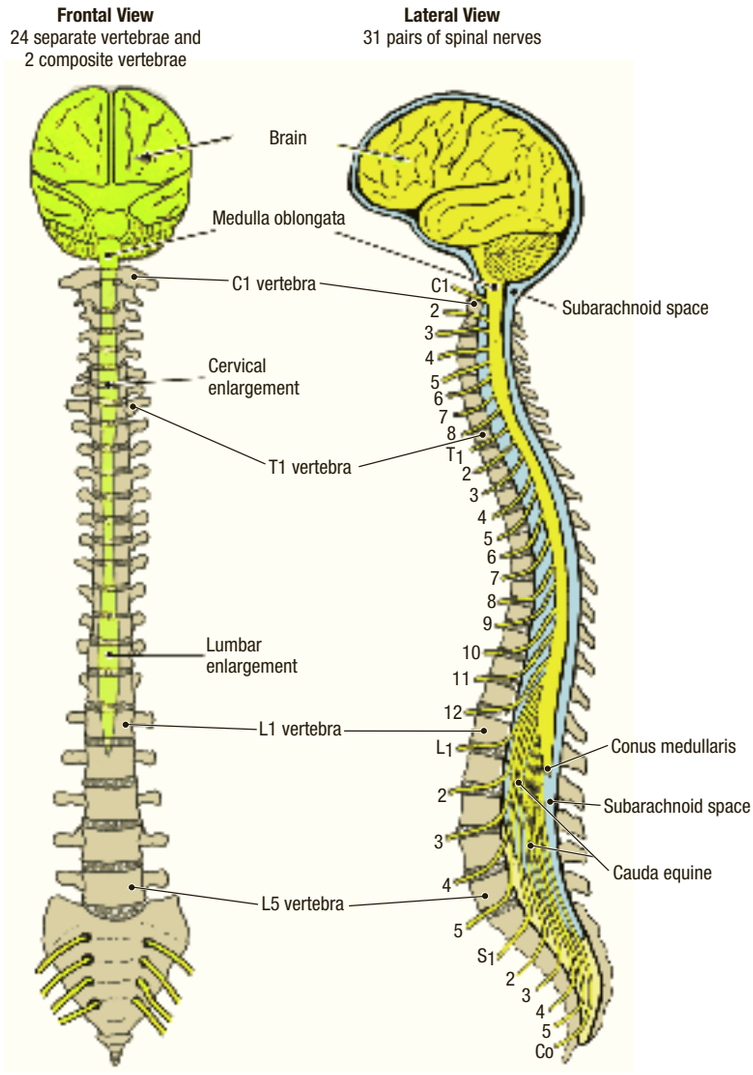

Figure 1.13. The spinal cord within the vertebral canal.

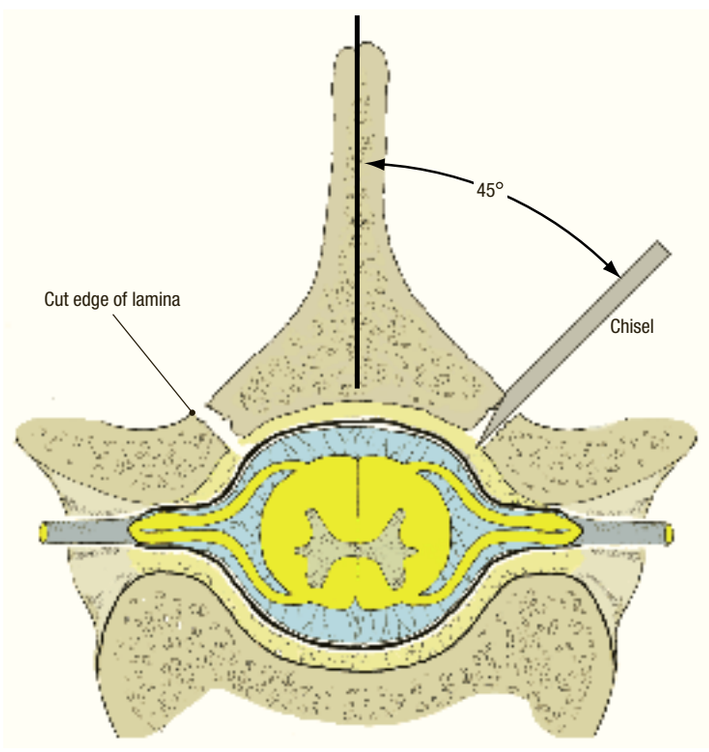

Figure 1.14. How to open the vertebral canal.

2. Identify the **dural sac**, which ends inferiorly at vertebral level S2 (Fig. 1.15A). **[G 324; R 221; C 430]**
3. In the thoracic region, lift a fold of **dura mater** with forceps and use scissors to cut a small opening in its dorsal midline. Use scissors to extend the cut superiorly as far as C4 and inferiorly to S2. Do this without damaging the underlying arachnoid mater. Retract the dura mater and pin it back.
4. Identify the **arachnoid mater** (Fig. 1.16). It is very delicate. Incise the arachnoid mater in the dorsal midline and observe the **subarachnoid space**. The subarachnoid space contains cerebrospinal fluid in the living person but not in the cadaver. **[G 325; N 162; C 431]**
5. Retract the arachnoid mater and observe the **spinal cord**. The spinal cord is completely invested by **pia mater**, which is on the surface of the spinal cord and cannot be dissected from it.
6. Identify the following features of the spinal cord: **[G 322; N 153; R 220; C 430]**
   - **Cervical enlargement** (spinal cord segments C4 to T1) provides nerves to the upper limb.
   - **Lumbar enlargement** (spinal cord segments L2 to S3) provides nerves to the lower limb.
   - **Conus medullaris (medullary cone)** is the end of the spinal cord located between vertebral levels L1 and L2.
   - **Cauda equina** (L., tail of horse) is a collection of ventral and dorsal roots in the lower vertebral canal (Fig. 1.15B).

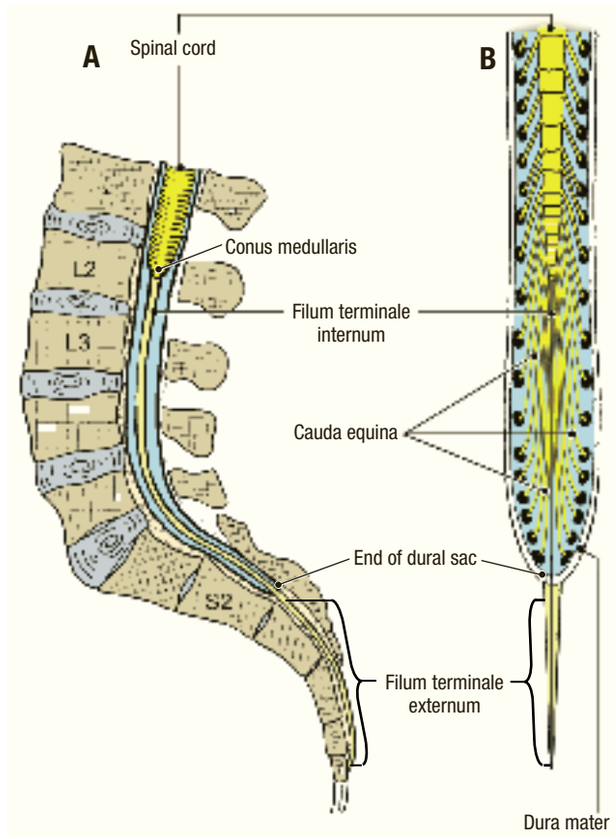

Figure 1.15. Lower portion of the vertebral canal and spinal cord. **A.** Lateral view. **B.** Posterior view.

- **Filum terminale internum** (Fig. 1.15A,B) is a delicate filament continuous with the pia mater. It arises from the inferior tip of the conus medullaris and ends at S2 where it is encircled by the lower end of the dural sac.
- **Filum terminale externum (coccygeal ligament)** (Fig. 1.15A,B) is the continuation of the filum terminale internum below vertebral level S2. The filum terminale externum passes through the sacral hiatus and ends by attaching to the coccyx.

7. The pia mater forms two **denticulate ligaments**, one on each side of the spinal cord (Fig. 1.16). Each denticulate ligament has 21 teeth and each tooth is attached to the inner surface of the dura mater, anchoring the spinal cord. **[G 327; N 162; R 221; C 431]**
8. Use a probe to follow **dorsal roots** and **ventral roots** to the point where they pierce the dura mater and enter the **intervertebral foramen** (Fig. 1.16). The dorsal roots are on the dorsal side of the denticulate ligament and the ventral roots are on the ventral side of the denticulate ligament. The spinal nerve will be formed outside of the vertebral canal by the joining of the dorsal and ventral roots.
9. Observe small **blood vessels** that course along the ventral and dorsal roots. These are branches of posterior intercostal, lumbar, or vertebral arteries, depending on vertebral level. They pass into the vertebral canal through the intervertebral foramen and supply the spinal cord. **[G 329; N 165; C 431]**
10. In the thoracic region, expose one **spinal nerve**. Place a probe into an intervertebral foramen to protect the nerve within it. Use bone forceps to remove the posterior wall of the intervertebral foramen and expose the **spinal ganglion** (dorsal root ganglion) (Fig. 1.16). Distal to the spinal ganglion, identify the spinal nerve and follow it distally to the point where it divides into a **dorsal primary ramus** and a **ventral primary ramus**.

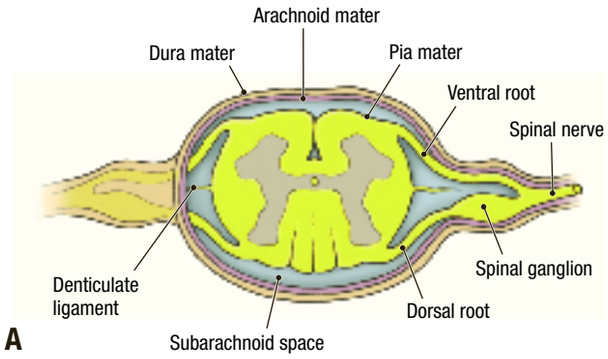

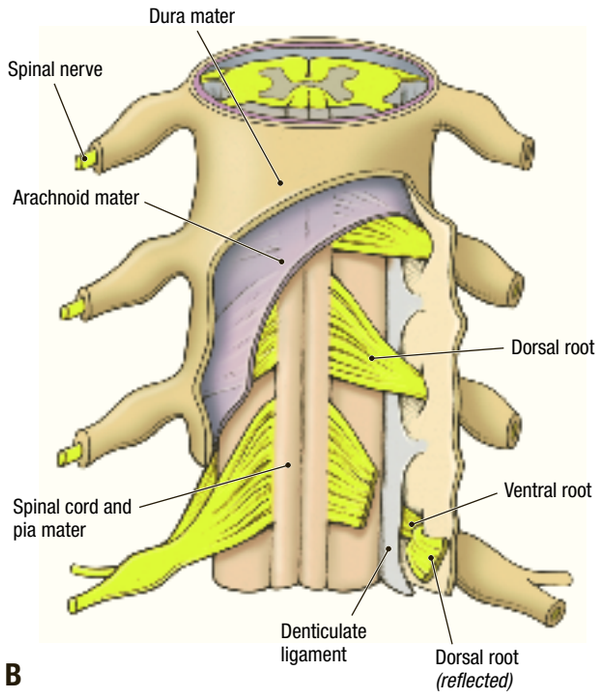

Figure 1.16. Relationships of the meninges to the spinal cord and nerve roots. **A.** Transverse section. **B.** Posterior view.

CLINICAL CORRELATION

Lumbar Puncture

Cerebrospinal fluid (CSF) can be obtained from the subarachnoid space inferior to the conus medullaris (Fig. 1.17). At this level, there is no danger of penetrating the spinal cord with the puncture needle.

After you dissect . . .

Review the formation and branches of a typical spinal nerve. Describe the way that the deep back muscles receive their innervation. Review the coverings and parts of the spinal cord and study an illustration that shows the blood supply to the spinal cord. Consult a dermatome chart and relate this pattern of cutaneous innervation to the spinal cord segments. **[G 331; N 157; C 404]**

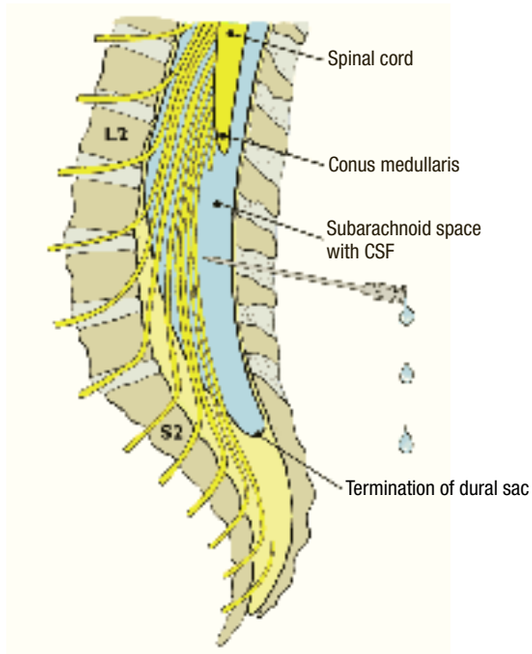

Figure 1.17. Lumbar puncture for removal of cerebrospinal fluid.

CHAPTER 2

THE UPPER LIMB

The function of the upper limb is to place the hand in position to be effective as a grasping tool. As such, the upper limb has adapted into a body part with great freedom of motion. Muscles that control this motion extend across the back and thorax. If the back has previously been dissected, the superficial group of back muscles has been studied. If the thorax has previously been dissected, the pectoral region has been studied. If the upper limb is your first dissection unit, you will be instructed to dissect the superficial group of back muscles and the pectoral region at the appropriate time.

SURFACE ANATOMY [G 465, 475; N 401; C 26]

The upper limb is divided into four regions: **shoulder**, **arm (brachium)**, **forearm (antebrachium)**, and **hand (manus)**. The surface anatomy of the upper limb can be studied on a living subject or on the cadaver. Place the cadaver in the supine position (face up) and palpate the following superficial structures (Fig. 2.01):

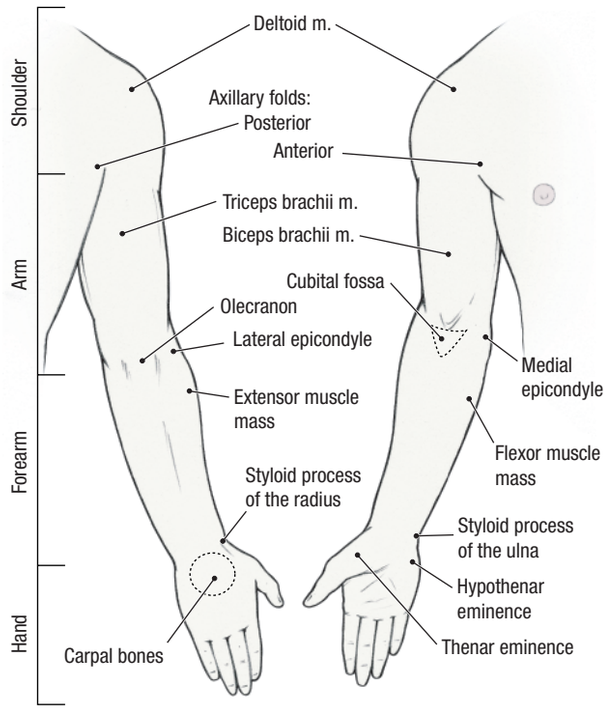

Figure 2.01. Surface anatomy of the upper limb.

KEY TO REFERENCES
G = Grant's Atlas, 11th ed., page number
N = Netter's Atlas, 3rd ed., plate number
R = Rohen's Color Atlas of Anatomy, 5th ed., page number
C = Clemente's Atlas, 4th ed., page number

- **Anterior axillary fold**
- **Posterior axillary fold**
- **Deltoid muscle**
- **Biceps brachii muscle**
- **Triceps brachii muscle**
- **Cubital fossa**
- **Medial epicondyle**
- **Lateral epicondyle**
- **Olecranon**
- **Flexor muscle mass (in the forearm)**
- **Extensor muscle mass (in the forearm)**
- **Carpal bones (on the dorsum of the wrist)**
- **Styloid process of the radius**
- **Styloid process of the ulna**
- **Thenar eminence**
- **Hypothenar eminence**

SUPERFICIAL VEINS AND CUTANEOUS NERVES

Before you dissect . . .

The **superficial fascia** of the upper limb contains fat, **superficial veins,** and **cutaneous nerves**. In the living body, the superficial veins may be conspicuous through the skin. They are frequently used for drawing blood and injecting medications. In the cadaver, the superficial veins are not conspicuous through the skin. The cutaneous nerves of the upper limb pierce the deep fascia to reach the superficial fascia and skin.

The order of dissection will be as follows: the entire upper limb will be skinned. The objective is to remove only the skin, leaving the superficial fascia undisturbed. The superficial veins and selected cutaneous nerves will be dissected. The fat will then be removed so that the deep fascia may be observed. **[G 462, 464; N 462, 463; R 388, 394; C 25]**

Dissection Instructions

SKIN INCISIONS

1. If the back has not been dissected previously, go to page 7, follow the skinning instructions that are provided there, and return to this page.
2. If the thorax has not been dissected previously, go to page 43, follow the skinning instructions that are provided there, and return to this page.
3. Place the cadaver in the supine position (face up).
4. Refer to Figure 2.02. Before cutting, realize that the skin is thin on the anterior surface of the upper limb. *Be careful not to cut too deeply.*

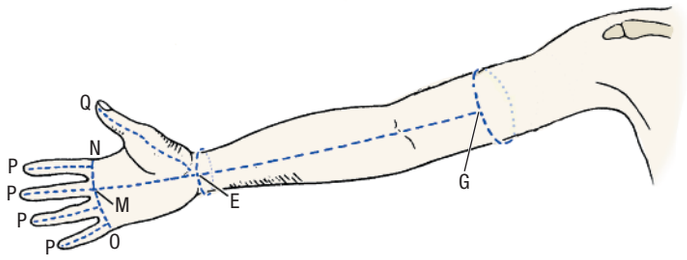

Figure 2.02. Skin incisions.

5. Use a scalpel to make an incision that encircles the arm midway between the shoulder and the elbow (G). If the back has been skinned, this incision has been made previously.
6. Make an incision that encircles the wrist (E). The skin is very thin (2 mm) on the anterior surface of the wrist.
7. Join the two circular incisions with a longitudinal incision on the anterior aspect of the upper limb (E to G).
8. Remove the skin from the arm and forearm and place it in the tissue container. Do not damage the superficial veins and cutaneous nerves in the superficial fascia.
9. Force open the clenched hand and let your dissection partner hold it open.
10. Make a longitudinal incision across the palm (E to M).
11. Make a transverse incision at the level of the webs of the fingers (N to O).
12. Make a longitudinal incision on the anterior surface of digits 2 to 5 (from incision N/O to P).
13. Make a longitudinal incision along the palmar surface of digit 1 (E to Q).
14. Remove the skin from the palmar and dorsal surfaces of the hand and digits 1 to 5. *When skinning the digits, proceed with caution*. Note that the subcutaneous tissue on the palmar surface of the digits is very thin, especially at the skin creases. There are digital nerves, vessels, and fibrous digital sheaths immediately deep to the skin.

SUPERFICIAL VEINS [G 464; N 462, 463; R 386; C 25]

1. Use blunt dissection to demonstrate the superficial veins (Fig. 2.03).
2. On the dorsum of the hand, identify the **dorsal venous arch**. Note that the dorsal venous arch collects venous drainage from the posterior surface of the hand and digits.
3. In the posterior forearm, demonstrate the **basilic vein** and **cephalic vein**, which arise from the dorsal venous arch.
4. Abduct the upper limb and have your dissection partner hold it in the abducted position.
5. Use a probe to follow the cephalic and basilic veins proximally, freeing them from the surrounding fat and connective tissue.
6. Demonstrate that the cephalic and basilic veins are joined across the cubital fossa by the **median cubital vein**. This pattern can be quite variable and should be observed on other cadavers.
7. Follow the cephalic vein proximally into the pectoral region where it courses in the **deltopectoral groove** between the deltoid muscle and the pectoralis major muscle. Near the clavicle, the cephalic vein passes deeply into the **deltopectoral triangle** to join the axillary vein.
8. Follow the basilic vein proximally. Before reaching the axilla, it pierces the deep fascia to join the brachial vein.
9. Use a probe to elevate the superficial veins (Fig. 2.03). Note that **perforating veins** penetrate the deep fascia and connect the superficial veins to deep veins.

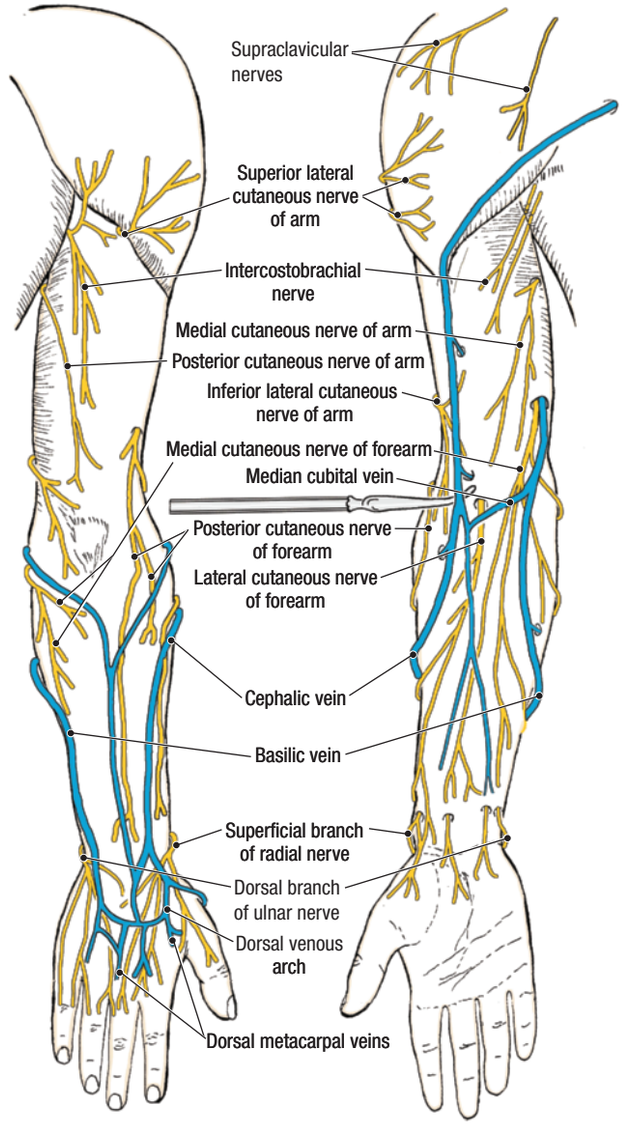

Figure 2.03. Cutaneous nerves and superficial veins.

CUTANEOUS NERVES [G 462; N 462, 463; R 388; C 25]

1. Do not dissect all of the cutaneous nerves of the upper limb. A few (described later in greater detail) are clinically relevant and should be demonstrated by blunt

dissection. Before dissecting, use an illustration to familiarize yourself with the course and distribution of all of the **cutaneous nerves of the upper limb** (Fig. 2.03):

- **Superior lateral cutaneous nerve of the arm**
- **Inferior lateral cutaneous nerve of the arm**
- **Posterior cutaneous nerve of the arm**
- **Intercostobrachial nerve**
- **Medial cutaneous nerve of the arm**
- **Medial cutaneous nerve of the forearm**
- **Lateral cutaneous nerve of the forearm**
- **Posterior cutaneous nerve of the forearm**

2. At the level of the elbow, identify the **lateral cutaneous nerve of the forearm**. It is located in the superficial fascia lateral to the biceps brachii tendon and in close relationship to the cephalic vein or the median cubital vein.
3. At the level of the elbow, identify the **medial cutaneous nerve of the forearm**. It is located on the medial side of the biceps brachii tendon and is in close relationship to the basilic vein.
4. At the lateral side of the wrist, use a probe to dissect the **superficial branch of the radial nerve**. The superficial branch of the radial nerve may be found in the superficial fascia near the styloid process of the radius. Expose only 2 or 3 cm of this nerve.
5. At the medial side of the wrist, identify the **dorsal branch of the ulnar nerve.** The dorsal branch of the ulnar nerve may be found in the superficial fascia near the styloid process of the ulna. Expose only 2 or 3 cm of this nerve.
6. The cutaneous nerves to the digits will be studied with the hand.
7. Remove all remaining superficial fascia, preserving the superficial veins and nerves that you have dissected. Do not disturb the deep fascia. Place the superficial fascia in the tissue container.
8. Examine the **deep fascia** of the upper limb. Note that the deep fascia of the upper limb extends from the shoulder to the fingertips. It attaches to the bones of the upper limb and forms compartments that contain groups of muscles. The deep fascia of the upper limb is regionally named: **brachial fascia** in the arm, **antebrachial fascia** in the forearm, and **palmar fascia** and **dorsal fascia of the hand** in the hand.

After you dissect . . .

Review the superficial fascia of the upper limb. Use the dissected specimen to trace the course of the superficial veins from distal to proximal. Review the location of the cephalic vein, basilic vein, and median cubital vein in the cubital fossa and recall that these are important for venipuncture. Use the dissected specimen to review the four cutaneous nerves that you have dissected. Use an illustration to review the pattern of distribution of the cutaneous nerves that you did not dissect. Compare this pattern of cutaneous nerve distribution to a dermatome chart. Review the deep fascia of the upper limb and name its parts. **[G 462, 463; N 464, 465; C 24]**

SUPERFICIAL GROUP OF BACK MUSCLES

Instructions for dissection of the superficial group of back muscles are found in Chapter 1, *The Back*. If you are dissecting the upper limb before the back, the superficial group of back muscles must be dissected now. Turn to pages 7–9, complete that dissection, and return to this page.

SCAPULAR REGION

Before you dissect . . .

There are six shoulder (scapulohumeral) muscles: **Deltoid**, **supraspinatus**, **infraspinatus**, **teres minor**, **teres major**, and **subscapularis**. The order of dissection will be as follows: the deltoid muscle will be studied, then it will be detached from its proximal attachment and the course of its nerve and artery will be studied. Subsequently, the four muscles arising from the dorsal surface of the scapula (supraspinatus, infraspinatus, teres major, teres minor) will be dissected and their nerves and blood vessels will be demonstrated. The subscapularis muscle will be dissected with the axilla.

SKELETON OF THE SCAPULAR REGION [G 498; N 404; R 359, 361; C 70, 76]

Refer to a skeleton. On the **scapula**, identify (Fig. 2.04):

- **Acromion**
- **Spine**
- **Supraspinous fossa**
- **Suprascapular notch**
- **Infraspinous fossa**
- **Supraglenoid tubercle**
- **Glenoid cavity**
- **Infraglenoid tubercle**
- **Coracoid process**

On the **humerus**, identify (Fig. 2.04):

- **Head**
- **Anatomical neck**
- **Greater tubercle**
- **Lesser tubercle**
- **Intertubercular sulcus (bicipital groove)**
- **Surgical neck**
- **Deltoid tuberosity**
- **Radial groove**

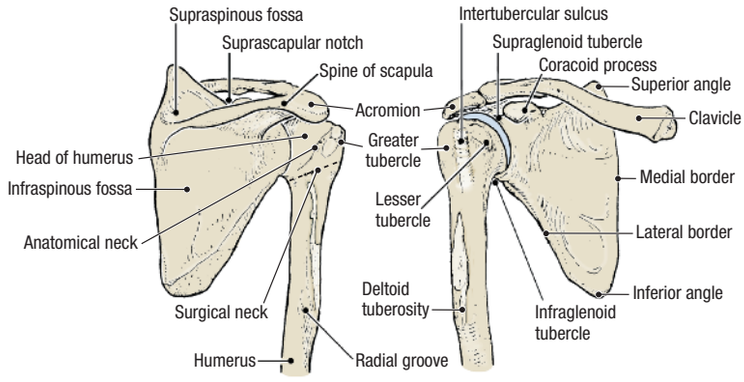

Figure 2.04. Skeleton of the scapular region.

Dissection Instructions

1. Place the cadaver in the prone position (face down). Abduct the upper limb to 45 degrees. If a block is available, place it under the chest.
2. Use blunt dissection to define the borders of the **deltoid muscle**. The proximal attachments of the deltoid muscle are the spine of the scapula, the acromion of the scapula, and the lateral one-third of the clavicle. The distal attachment of the deltoid muscle is the deltoid tuberosity of the humerus. The deltoid muscle abducts the humerus. **[G 497; N 407; R 370; C 407]**
3. Use a scalpel to detach the deltoid muscle from its proximal attachments. Make your cuts close to the bone. Leave the muscle attached to the humerus. Reflect the deltoid muscle laterally, taking care not to tear the vessels and nerve that course along its deep surface.
4. Observe the **axillary nerve** and the **posterior circumflex humeral artery and vein** on the deep surface of the deltoid muscle near its attachment to the humerus. Use a probe to clean the nerve and vessels and trace them around the surgical neck of the humerus (Fig. 2.05). **[G 506; N 409; R 371; C 41]**
5. Note that the axillary nerve innervates the deltoid muscle and the **teres minor muscle**.
6. Follow the axillary nerve and the posterior circumflex humeral artery and vein proximally. Push your finger parallel to the nerve and vessels to open the **quadrangular space** (Fig. 2.05). Define the **borders of the quadrangular space**:
   - **Superior border—**inferior border of the teres minor muscle
   - **Lateral border –** surgical neck of the humerus
   - **Medial border –** long head of the triceps brachii muscle
   - **Inferior border –** superior border of the teres major muscle
7. Identify the **long head of the triceps brachii muscle**. Observe that the long head of the triceps brachii muscle passes anterior to the teres minor muscle and posterior to the teres major muscle.
8. Use a probe to clean and define the borders of the **teres minor muscle**. The proximal attachment of the teres minor muscle is the lateral border of the scapula. The distal attachment of the teres minor muscle is the inferior facet of the greater tubercle of the humerus. The teres minor muscle laterally rotates the humerus.
9. Clean and define the borders of the **teres major muscle**. The proximal attachment of the teres major muscle is the inferior angle of the scapula. The distal attachment of the teres major muscle is the medial lip of the intertubercular sulcus of the humerus. The teres major muscle adducts and medially rotates the humerus.
10. Reflect the trapezius muscle superiorly, leaving it attached along the "hinge" of cervical fascia that was created during the back dissection.
11. Clean and define the borders of the **supraspinatus muscle**. The proximal attachment of the supraspinatus muscle is the supraspinous fossa of the scapula. The distal attachment of the supraspinatus muscle is the highest facet of the greater tubercle of the humerus. The supraspinatus muscle initiates abduction of the humerus.

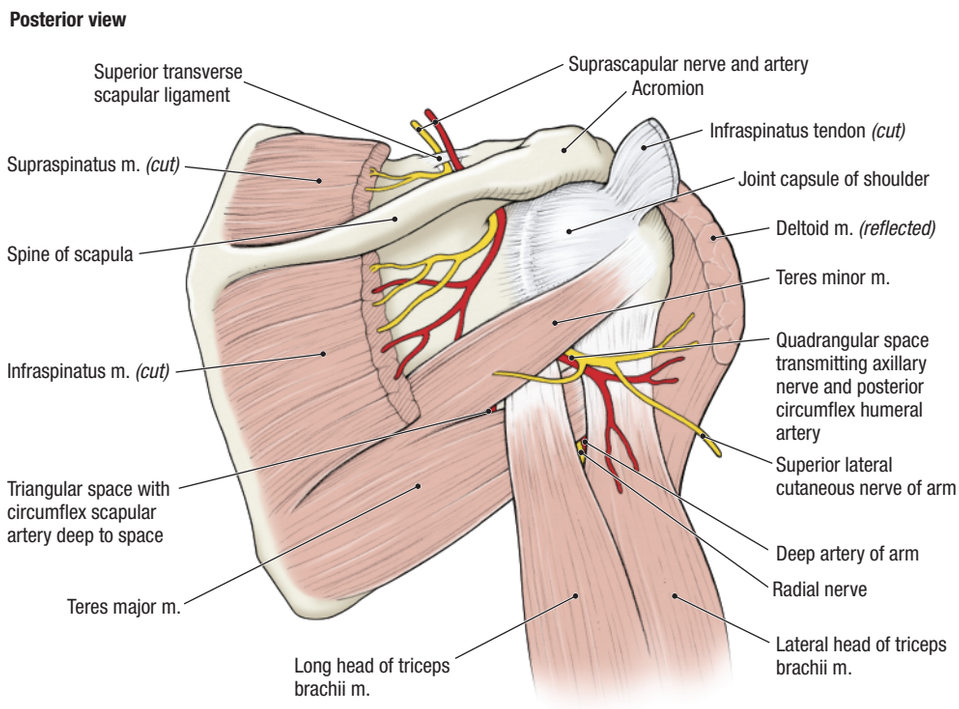

Figure 2.05. Blood and nerve supply to the posterior aspect of the shoulder.

12. Use a probe to define the borders of the **infraspinatus muscle**. The proximal attachment of the infraspinatus muscle is the infraspinous fossa of the scapula. The distal attachment of the infraspinatus muscle is the middle facet of the greater tubercle of the humerus. The infraspinatus muscle laterally rotates the humerus.
13. The **suprascapular artery** and the **suprascapular nerve** are found deep to the supraspinatus muscle (Fig. 2.05). The supraspinatus muscle must be reflected to see them. **[G 506; N 409; R 392; C 23]**
14. Use a scalpel to transect the supraspinatus muscle approximately 5 cm lateral to the superior angle of the scapula but medial to the suprascapular notch. Hold a disarticulated scapula over the scapula of the cadaver to help locate the proper level of the cut.
15. Use blunt dissection to free the distal portion of the supraspinatus muscle from the supraspinous fossa. Reflect the distal part of the supraspinatus muscle laterally. Leave it attached to the humerus.
16. Clean the **suprascapular artery and nerve**. Follow the artery and nerve superiorly. Observe that the suprascapular artery passes superior to the **superior transverse scapular ligament** and the suprascapular nerve passes inferior to it (Fig. 2.05). This relationship can be remembered by use of a mnemonic device: "*A*rmy (*a*rtery) goes over the bridge, *N*avy (*n*erve) goes under the bridge."
17. Transect the **infraspinatus muscle** approximately 5 cm lateral to the vertebral border of the scapula (Fig. 2.05).
18. Use blunt dissection to loosen the distal portion of the infraspinatus muscle from the scapula and reflect it laterally.
19. Follow the **suprascapular artery** and the **suprascapular nerve** inferiorly. Note that they reach the infraspinatus muscle by coursing deep (anterior) to the spine of the scapula (Fig. 2.05).
20. The suprascapular artery contributes to the collateral circulation of the scapular region. Use an illustration to study the **scapular anastomosis**. **[G 471; N 410; R 392]**
21. The four muscles of the **rotator cuff** are: **supraspinatus, infraspinatus, teres minor, and subscapularis**. The subscapularis muscle will be dissected with the axilla. Use an illustration to study the distal attachments of the rotator cuff muscles. **[G 498, 514; N 403, 404; R 371; C 37]**

After you dissect . . .

Replace the muscles of the scapular region in their correct anatomical positions. Use an illustration and the dissected specimen to review the proximal attachment and distal attachment of each muscle of the scapular region. List the action of each muscle and the combined action of the rotator cuff group of muscles. Review the origin, course, and distribution of the transverse cervical artery, dorsal scapular artery, and suprascapular artery. Review the scapular anastomosis. Review the relationship of the suprascapular artery and the suprascapular nerve to the superior transverse scapular ligament. Review the innervation of each muscle dissected today.

PECTORAL REGION

Instructions for dissection of the pectoral region are found in Chapter 3, *The Thorax*. If you are dissecting the upper limb before the thorax, the pectoral region must be dissected now. Turn to pages 43–46, complete that dissection, and return to this page.

AXILLA

Before you dissect . . .

The **axilla** is the region between the pectoral muscles, the scapula, the arm, and the thoracic wall (Fig. 2.06). It is a transitional region through which vessels and nerves pass from the root of the neck into the upper limb. The **contents of the axilla** are: **axillary sheath**, **brachial plexus**, **axillary vessels and their branches**, **lymph nodes and lymphatic vessels**, **portions of three muscles,** and a considerable amount of fat and connective tissue.

Study a diagram and note the following **boundaries of the axilla**: **[G 482; N 411]**

- **Apex of the axilla –** bounded by the clavicle anteriorly, the upper border of the scapula posteriorly and the first rib medially
- **Base of the axilla –** skin and fascia of the armpit
- **Anterior wall –** pectoralis major muscle, pectoralis minor muscle, and the clavipectoral fascia
- **Posterior wall –** posterior axillary fold (teres major and latissimus dorsi muscles) and the subscapularis muscle that covers the anterior surface of the scapula
- **Medial wall –** upper portion of the thoracic wall and the serratus anterior muscle, which overlies this wall
- **Lateral wall –** intertubercular sulcus of the humerus

The order of dissection will be as follows: the pectoralis major and pectoralis minor muscles will be reflected to expose the contents of the axilla. The axillary vein and its tributaries will be removed. The branches of the axillary artery will be dissected. The brachial plexus will be studied.

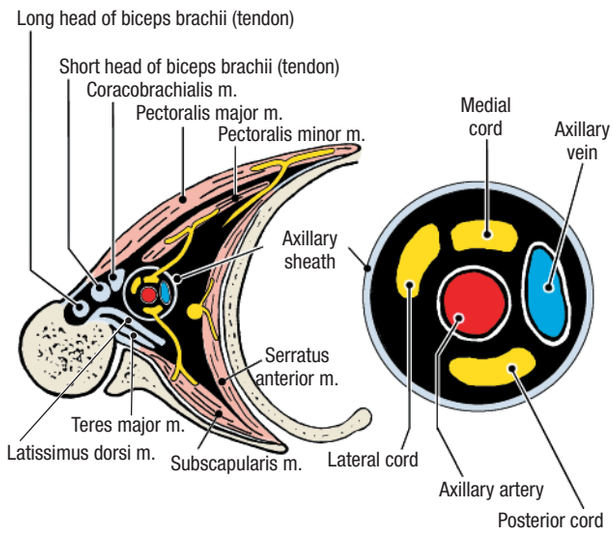

Figure 2.06. Walls and contents of the axilla (transverse section).

Dissection Instructions

1. Review the pectoralis major muscle, the pectoralis minor muscle, and the clavipectoral fascia.
2. Reflect the pectoralis major muscle laterally.
3. Reflect the pectoralis minor muscle superiorly.
4. Abduct the arm to approximately 45 degrees.
5. Identify the **axillary sheath** (Fig. 2.06). The axillary sheath is a connective tissue structure that surrounds the axillary vessels and brachial plexus. The axillary sheath extends from the lateral border of the first rib to the inferior border of the teres major muscle.
6. Use scissors to open the anterior surface of the axillary sheath.
7. Identify the **axillary vein** within the axillary sheath. Cut the cephalic vein where it joins the axillary vein and preserve it. Use a probe to dissect the axillary vein from the structures that lie posterior to it (axillary artery and brachial plexus). Cut the axillary vein at the lateral border of the first rib and bluntly dissect it distally as far as possible. Remove it completely. **[G 481; N 412; R 397; C 15]**
8. As the dissection proceeds, remove veins that are tributary to the axillary vein. Retain the accompanying arteries. Note the presence of lymph nodes that are associated with the veins.

AXILLARY ARTERY [G 488, 489; N 410; R 398; C 14]

The **axillary artery** begins at the lateral border of the first rib, where it is the continuation of the **subclavian artery** (Fig. 2.07). The axillary artery ends at the inferior border of the teres major muscle, where its name changes to **brachial artery**. The axillary artery is surrounded by the brachial plexus (Fig. 2.06, inset). *The brachial plexus must be retracted and preserved during dissection of the axillary artery and its branches.*

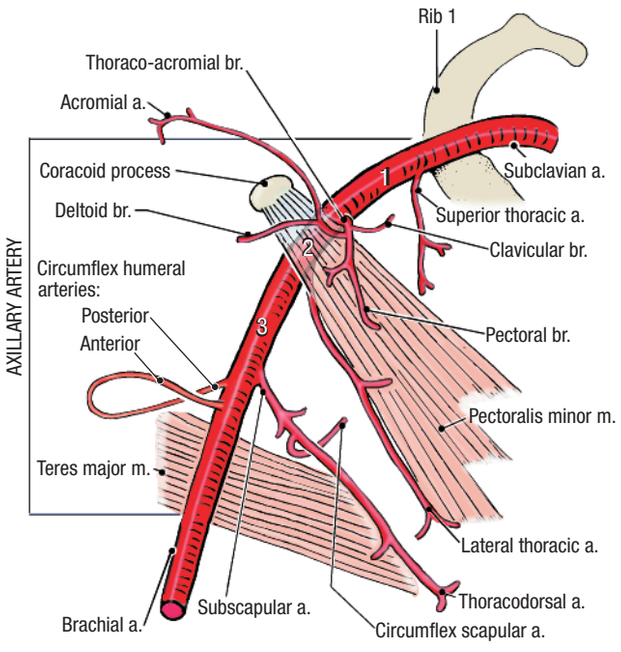

Figure 2.07. Branches arising from the axillary artery.

1. Identify the **three parts of the axillary artery** (Fig. 2.07):
   - **First part** extends from the lateral border of the first rib to the medial border of the pectoralis minor muscle.
   - **Second part** lies posterior to the pectoralis minor muscle.
   - **Third part** extends from the lateral border of the pectoralis minor muscle to the inferior border of the teres major muscle.

Dissection note: The branching pattern of the axillary artery may vary from that which is commonly illustrated. If the pattern is different in your specimen, note that the branches are named according to their distribution rather than by their origin.

2. The first part of the axillary artery has one branch, the **superior thoracic artery**. Follow the superior thoracic artery to its area of distribution in the first and second intercostal spaces.
3. The second part of the axillary artery has two branches (Fig. 2.07): **thoraco-acromial artery** and **lateral thoracic artery**.
4. Use blunt dissection to open the clavipectoral fascia and identify the thoraco-acromial artery on the medial side of the pectoralis minor muscle.
5. Identify the branches of the thoraco-acromial artery:
   - **Acromial branch –** passes laterally across the coracoid process to the acromion.
   - **Deltoid branch –** courses laterally in the deltopectoral groove. It accompanies the cephalic vein.
   - **Pectoral branch –** passes between the pectoralis major and pectoralis minor muscles and supplies both.
   - **Clavicular branch –** courses superior and medial to supply the subclavius muscle.
6. Identify the **lateral thoracic artery** and follow it along the lateral border of the pectoralis minor muscle (Fig. 2.07). The lateral thoracic artery may have an alternate origin from the subscapular artery, but it consistently courses along the lateral border of the pectoralis minor muscle. The lateral thoracic artery supplies the pectoral muscles and the lateral thoracic wall. In females, the lateral thoracic artery also supplies the lateral portion of the mammary gland.
7. The third part of the axillary artery has three branches: **subscapular artery**, **posterior circumflex humeral artery**, and **anterior circumflex humeral artery**.
8. Identify the **subscapular artery**. It is the largest branch of the axillary artery. The subscapular artery courses inferiorly for a short distance before dividing into the **circumflex scapular artery** (to muscles on the posterior surface of the scapula) and the **thoracodorsal artery** (to the latissimus dorsi muscle). The subscapular artery gives off several unnamed muscular branches.
9. Find the **anterior and posterior circumflex humeral arteries**, which arise from the axillary artery distal to the origin of the subscapular artery. Occasionally,

these two arteries may arise from a short common trunk. They supply the deltoid muscle.

10. Observe that the **posterior circumflex humeral artery** is the larger of the two circumflex humeral arteries. Follow it as it passes posterior to the surgical neck of the humerus with the axillary nerve. Demonstrate that the posterior circumflex humeral artery and the axillary nerve pass through the quadrangular space.
11. The **anterior circumflex humeral artery** courses around the anterior surface of the humerus at the surgical neck. It passes deep to the tendon of the long head of the biceps brachii muscle.

BRACHIAL PLEXUS [G 488; N 412; R 399; C 15]

The brachial plexus begins in the root of the neck superior to the clavicle. It passes distally toward the base of the axilla, where its **terminal branches** arise. Only the **infraclavicular part of the brachial plexus** will be dissected at this time. The **supraclavicular part** will be dissected with the neck.

The **three cords of the brachial plexus** (lateral, medial, and posterior) are named according to their relationship to the second part of the axillary artery (posterior to the pectoralis minor muscle) (Fig. 2.08).

1. Identify the **musculocutaneous nerve**. It is the most lateral terminal branch of the brachial plexus and enters the coracobrachialis muscle.
2. To find the **lateral cord**, use your fingers to follow the musculocutaneous nerve proximally.
3. Observe that the lateral cord gives rise to one other large branch, the **lateral root of the median nerve**. Follow the lateral root distally and identify the **median nerve.**
4. To find the **medial cord**, trace the **medial root of the median nerve** proximally.
5. The medial cord continues distally as the **ulnar nerve**.
6. Note that the three **terminal branches** that you have just identified (musculocutaneous nerve, median nerve, and ulnar nerve) form the letter M anterior to the third part of the axillary artery (Fig. 2.08).
7. Trace the **medial** and **lateral pectoral nerves** from the reflected pectoral muscles to their origins from the medial and lateral cords, respectively.
8. Identify two branches of the medial cord. They are the **medial cutaneous nerve of the forearm** and the **medial cutaneous nerve of the arm**. Use your fingers to trace these nerves a short distance (7.5 cm) into the arm.
9. Use a piece of string to retract the axillary artery, the lateral cord, and the medial cord in the superior direction. This procedure exposes the **posterior cord** of the brachial plexus. The branches of the posterior cord are the **axillary nerve**, **radial nerve**, and three **subscapular nerves** (upper, middle and lower).
10. Use blunt dissection to clean the **axillary nerve**. Observe that the axillary nerve passes posterior to the humerus and courses through the quadrangular space with the posterior circumflex humeral artery (Fig. 2.09).
11. Use blunt dissection to clean the **radial nerve** and confirm that it leaves the axilla by passing posterior to the humerus. The radial nerve is the motor and sensory nerve to the posterior portion of the upper limb.
12. Identify the subscapular nerves that arise from the posterior cord (Fig. 2.09). The **upper subscapular nerve** innervates the subscapularis muscle. The **middle subscapular nerve (thoracodorsal nerve**) innervates the latissimus dorsi muscle. The **lower subscapular nerve** innervates the subscapularis muscle and the teres major muscle. Verify that these nerves run in the loose connective tissue on the anterior surface of the subscapularis muscle.

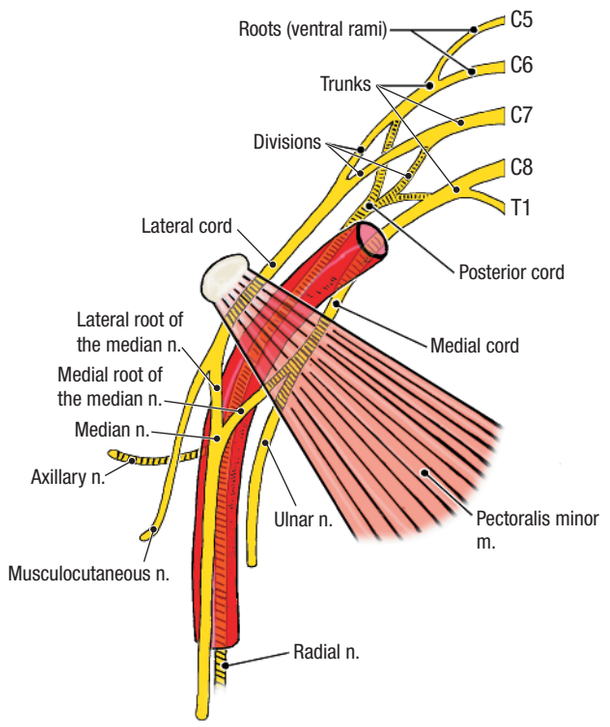

Figure 2.08. Relationship of the brachial plexus to the axillary artery.

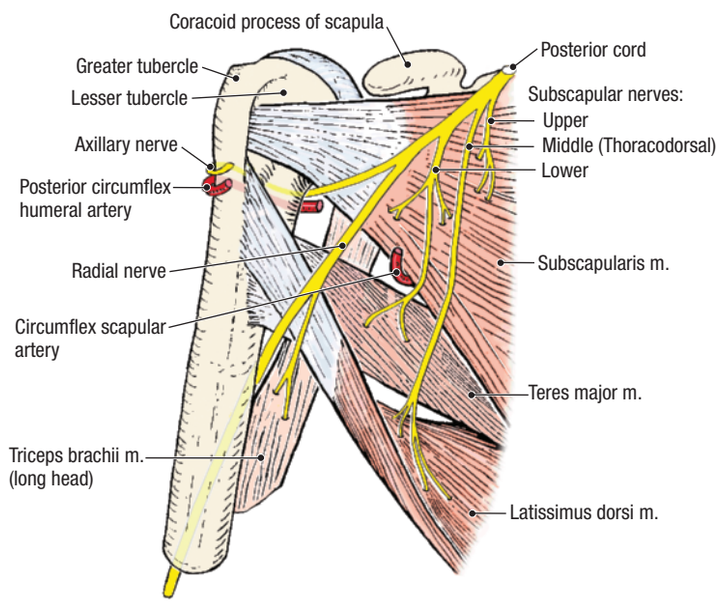

Figure 2.09. Posterior wall of the axilla and posterior cord of the brachial plexus.

13. Identify the three muscles that form the posterior wall of the axilla: **latissimus dorsi**, **teres major,** and **subscapularis** (Fig. 2.09).
14. Examine the **subscapularis muscle**. The proximal attachment of the subscapularis muscle is the subscapular fossa of the scapula. The distal attachment of the subscapularis muscle is the lesser tubercle of the humerus. The subscapularis muscle medially rotates the humerus. The subscapularis muscle is a member of the **rotator cuff group of muscles**.
15. Verify that the medial wall of the axilla is formed by the **serratus anterior muscle** (Fig. 2.06). Use an illustration to study the attachments of the serratus anterior muscle. The proximal attachments of the serratus anterior muscle are the external surfaces of ribs 1 to 8. Its distal attachment is the anterior surface of the medial border of the scapula. The serratus anterior muscle protracts the scapula. The serratus anterior muscle also rotates the scapula, especially when the arm is abducted above the horizontal plane. **[G 491; N 412; R 398; C 12]**
16. Use your fingers to follow the serratus anterior muscle posteriorly toward the medial margin of the scapula. On the superficial surface of this muscle, use a probe to free the **long thoracic nerve**. Note the vertical course of this nerve. Observe its branches to the serratus anterior muscle. Follow the nerve superiorly as far as possible toward the apex of the axilla.

CLINICAL CORRELATION

Nerve Injuries

The **long thoracic nerve** is vulnerable to stab wounds and to surgical injury during radical mastectomy. Injury of the long thoracic nerve affects the serratus anterior muscle. When a patient with paralysis of the serratus anterior muscle is asked to push with both hands against a wall, the medial border of the scapula protrudes on the affected side, a condition known as "winged scapula."

The **thoracodorsal nerve** is vulnerable to compression injuries and surgical trauma during mastectomy. Injury of the thoracodorsal nerve affects the latissimus dorsi muscle, resulting in a weakened ability to extend, adduct, and medially rotate the humerus.

The **axillary nerve** courses around the surgical neck of the humerus and may be injured during a fracture or during an inferior dislocation of the shoulder joint. Injury of the axillary nerve affects the deltoid muscle and teres minor muscle, resulting in a weakened ability to abduct and laterally rotate the humerus.

After you dissect . . .

Replace the pectoralis major muscle and the pectoralis minor muscle into their correct anatomical positions and review their attachments. Review the boundaries of the axilla. Use the dissected specimen to observe the relationship of the three parts of the axillary artery to the pectoralis minor muscle. Name all of the branches of the axillary artery and identify each branch on your dissected specimen. Test your understanding of the brachial plexus by drawing a picture that shows its structure and branches. Extend this exercise to the cadaver by demonstrating the divisions, cords, and terminal branches of the infraclavicular portion of the brachial plexus. Review the motor nerve supply to the muscles of the scapular region. Name each muscle and the nerve that supplies it. Realize that some of these nerves arise from the supraclavicular portion of the brachial plexus and that they have not yet been dissected completely. Review the movements of the scapula. Examine other cadavers to gain an appreciation of variations in the branching patterns of arteries and nerves. Use an illustration to review the lymphatic drainage of the axilla.

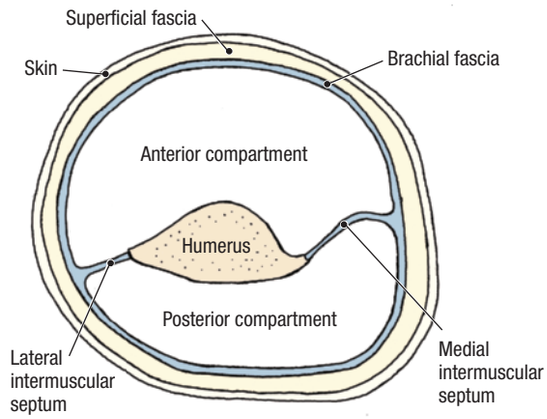

Figure 2.10. Compartments of the right arm.

ARM AND CUBITAL FOSSA

Before you dissect . . .

The **brachial fascia (deep fascia of the arm)** is a sleeve of tough connective tissue that is continuous at its proximal end with the **pectoral fascia**, the **axillary fascia**, and the deep fascia that covers the deltoid and latissimus dorsi muscles. Distally, the brachial fascia is continuous with the **antebrachial fascia (deep fascia of the forearm)**. The brachial fascia is connected to the medial and lateral sides of the humerus by intermuscular septa (Fig. 2.10), creating an **anterior (flexor) compartment** and a **posterior (extensor) compartment** for the muscles of the arm. The anterior compartment contains three muscles (biceps brachii, brachialis, and coracobrachialis) and the musculocutaneous nerve. The posterior compartment contains two muscles (triceps brachii and anconeus), the radial nerve, and the deep artery and vein of the arm.

The order of dissection will be as follows: the anterior compartment of the arm will be opened and its contents will be studied. Nerves and blood vessels will then be traced distally through the arm to the elbow region. The cadaver will be turned to the prone position to complete the dissection of the posterior compartment of the arm.

SKELETON OF THE ARM AND CUBITAL REGION [G 524; N 419; R 361, 362; C 76, 77]

Refer to a skeleton. On the **humerus** identify (Fig. 2.11):

- **Medial epicondyle**
- **Lateral epicondyle**
- **Olecranon fossa**

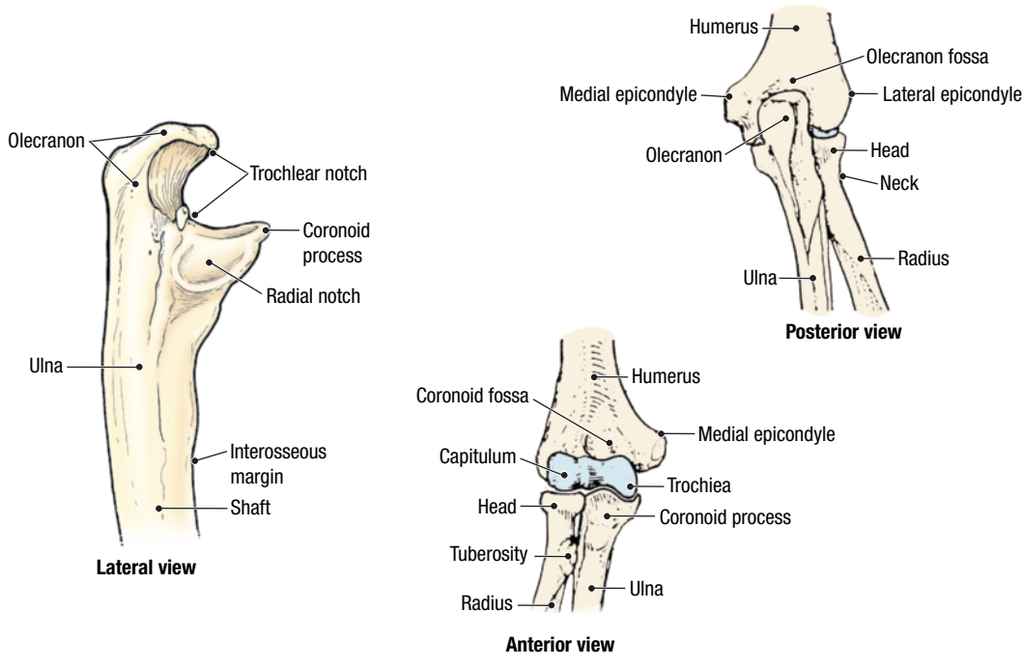

Figure 2.11. Skeleton of the elbow region.

On the **radius** identify:

- **Head**
- **Neck**
- **Tuberosity**

On the **ulna** identify:

- **Olecranon**

Dissection Instructions

ANTERIOR COMPARTMENT OF THE ARM [G 501, 502; N 414; R 401; C 32, 33]

1. Place the cadaver in the supine position.
2. Use scissors to make a longitudinal incision in the anterior surface of the brachial fascia from the level of the pectoralis major tendon to the elbow.
3. Use your fingers to separate the brachial fascia from the underlying muscles. Work laterally and medially from the incision and note the presence of the **lateral intermuscular septum** and the **medial intermuscular septum**.
4. Use your fingers to separate the three muscles in the anterior compartment of the arm: **coracobrachialis**, **brachialis**, and **biceps brachii** (Fig. 2.12).
5. The **biceps brachii muscle** has two proximal attachments on the scapula:
   - **Short head of the biceps brachii muscle** attaches to the coracoid process of the scapula.
   - **Long head of the biceps brachii muscle** attaches to the supraglenoid tubercle of the scapula. The tendon of the **long head of the biceps brachii**

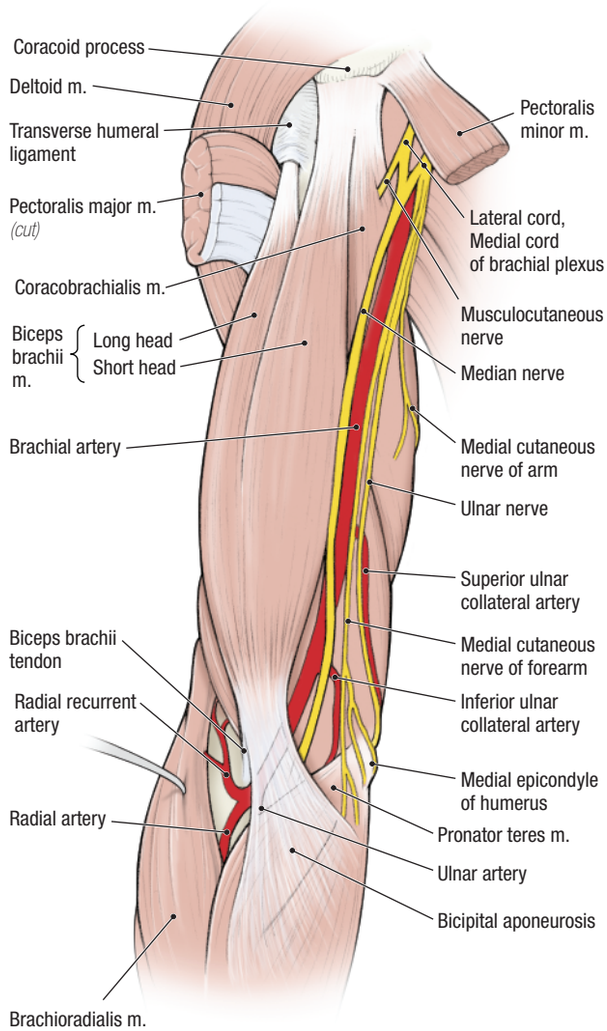

Figure 2.12. Contents of the anterior compartment of the arm.

muscle courses through the intertubercular sulcus of the humerus posterior to the **transverse humeral ligament**, and then enters the shoulder joint. Do not follow the tendon of the long head to its attachment on the scapula.

6. Identify the **biceps brachii tendon** at the level of the elbow. The distal attachment of the biceps brachii muscle is on the tuberosity of the radius. The biceps brachii muscle supinates and flexes the forearm.
7. Identify the **bicipital aponeurosis** (Fig. 2.12). The bicipital aponeurosis is a broad extension of the biceps tendon that attaches to the antebrachial fascia. The bicipital aponeurosis is located on the medial side of the biceps brachii tendon.
8. Find the **musculocutaneous nerve** in the axilla (Fig. 2.12). Follow the musculocutaneous nerve distally until it enters **coracobrachialis muscle**. Note that the musculocutaneous nerve innervates the three muscles of the anterior compartment of the arm.
9. Use your fingers to confirm that the proximal attachment of the coracobrachialis muscle is the coracoid process and that its distal attachment is on the medial side of the shaft of the humerus. The coracobrachialis muscle adducts and flexes the humerus.
10. Use scissors to transect the biceps brachii muscle approximately 5 cm proximal to the elbow. Preserve the musculocutaneous nerve. Reflect the two portions of the biceps brachii muscle proximally and distally, respectively.
11. Observe the **brachialis muscle**, which is deep to the biceps brachii muscle. The proximal attachment of the brachialis muscle is the anterior surface of the distal one-half of the humerus and its distal attachment is on the coronoid process of the ulna. The brachialis muscle flexes the forearm.
12. Follow the **musculocutaneous nerve** through the plane of loose connective tissue between the biceps brachii muscle and brachialis muscle.
13. After the musculocutaneous nerve gives off its muscular branches, it continues distally as the **lateral cutaneous nerve of the forearm**. Follow the lateral cutaneous nerve of the forearm to the cubital fossa, where it emerges near the lateral side of the biceps brachii tendon. Review the relationship of the lateral cutaneous nerve of the forearm to the cephalic vein.
14. Follow the **medial cutaneous nerve of the forearm** from the brachial plexus to the level of the elbow (Fig. 2.12). Note its relationship to the basilic vein at the level of the elbow.
15. Find the **median nerve** where it arises from the brachial plexus (Fig. 2.12). Use blunt dissection to follow the median nerve from the axilla to the cubital fossa. The median nerve courses distally within the **medial intermuscular septum** with the **brachial artery**.
16. Use blunt dissection to follow the **ulnar nerve** from the medial cord of the brachial plexus to the medial epicondyle of the humerus (Fig. 2.12). Note that the ulnar nerve is in contact with the posterior surface of the medial epicondyle of the humerus. Palpate the ulnar nerve on yourself where it passes posterior to the medial epicondyle.
17. Identify the **brachial artery**. The brachial artery is the continuation of the axillary artery. The brachial artery begins at the inferior border of the teres major muscle and ends at the level of the elbow by branching into the **ulnar artery** and **radial artery** (Fig. 2.12). Verify that the brachial artery courses with the median nerve within the medial intermuscular septum, and that the median nerve is the only large structure to cross the brachial artery. **[G 503; N 416; R 401; C 34, 35]**
18. The brachial artery has three named branches in the arm: **deep artery of the arm**, **superior ulnar collateral artery**, and **inferior ulnar collateral artery**. Several unnamed muscular branches also arise along the length of the brachial artery.
19. Remove the brachial veins and their tributaries to clear the dissection field. Preserve the branches of the brachial artery.
20. Find the **deep artery of the arm** (**deep brachial artery**, **profunda brachii artery**) where it arises from the brachial artery. The deep artery of the arm courses around the posterior surface of the humerus, where it accompanies the radial nerve in the radial groove. The course of the deep artery of the arm will be seen when the posterior compartment of the arm is dissected.
21. Identify the **superior ulnar collateral artery** (Fig. 2.12). It arises from the brachial artery near the middle of the arm. It courses distally with the ulnar nerve and passes posterior to the medial epicondyle of the humerus.
22. Find the **inferior ulnar collateral artery** (Fig. 2.12). It arises from the brachial artery approximately 3 cm above the medial epicondyle of the humerus and passes anterior to the medial epicondyle between the **brachialis muscle** and the **pronator teres muscle.**

CLINICAL CORRELATION

Brachial Artery [G 530; N 417; R 385; C 27]

Use an illustration to study the collateral circulation around the elbow joint (Fig. 2.13). The brachial artery may become blocked at any level distal to the deep artery of the arm without completely blocking blood flow to the forearm and hand.

In the arm, the brachial artery lies medial to the biceps brachii muscle and close to the shaft of the humerus. The brachial artery is compressed at this location when taking a blood pressure reading.

CUBITAL FOSSA [G 518-520; N 416; R 405-407; C 44, 48]

The **cubital fossa** (L. *cubitus*, elbow) is the depression on the anterior aspect of the elbow. The cubital fossa is clinically important because it contains superficial veins that are used for venipuncture. Large nerves and vessels pass through this region to enter the forearm.

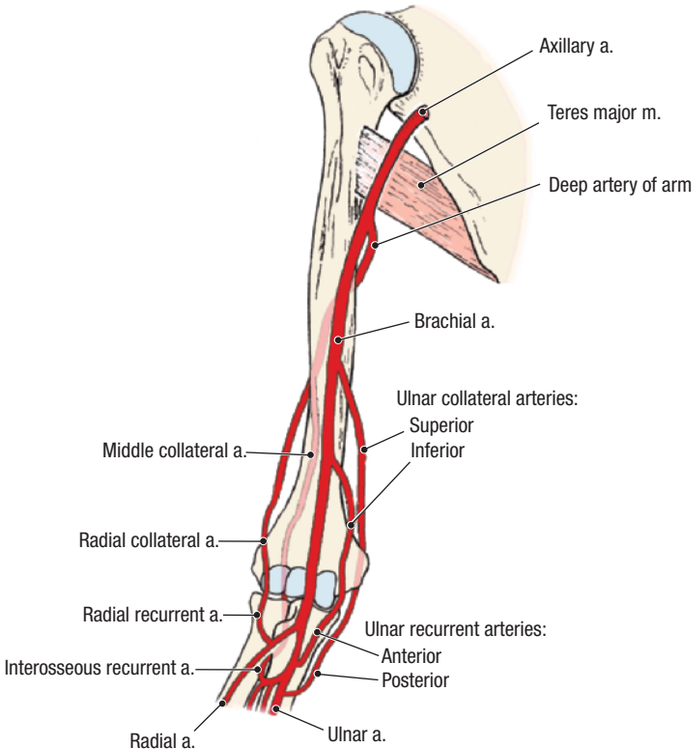

Figure 2.13. Brachial artery and its branches.

1. Note the **boundaries of the cubital fossa**:
   - **Lateral boundary –** brachioradialis muscle
   - **Medial boundary –** pronator teres muscle
   - **Superior boundary –** an imaginary line connecting the medial and lateral epicondyles of the humerus
   - **Superficial boundary (roof of the cubital fossa) –** antebrachial fascia reinforced by the bicipital aponeurosis
   - **Deep boundary (floor of the cubital fossa) –** brachialis and supinator muscles
2. Review the positions of the cephalic vein, basilic vein, and median cubital vein in the cubital fossa. To gain access to deeper structures, it may be necessary to cut the median cubital vein and retract its halves medially and laterally, respectively.
3. Find the **tendon of the biceps brachii muscle** in the cubital fossa.
4. Cut the **bicipital aponeurosis** near the biceps brachii tendon and reflect the aponeurosis medially. Do not cut the brachial artery, which lies deep to the bicipital aponeurosis.
5. Follow the **median nerve** and the **brachial artery** from the arm into the cubital fossa. Remove any fat that may be obstructing your view of these structures.
6. Observe the relative positions of the structures in the cubital fossa (Fig. 2.12): the biceps brachii tendon is lateral, the brachial artery is intermediate, and median nerve is medial. Note that the bicipital aponeurosis passes superficial to the brachial artery and median nerve, but it lies deep to the superficial veins. The bicipital aponeurosis protects the brachial artery and median nerve from injury during venipuncture.

POSTERIOR COMPARTMENT OF THE ARM [G 505, 506; N 415; R389, 390; C 36]

1. Place the cadaver in the prone position.
2. To gain better access to the posterior compartment, rotate the arm medially.
3. Use scissors to open the posterior compartment of the arm by making a longitudinal incision through the brachial fascia from the level of the olecranon of the ulna to the teres minor muscle.
4. Use your fingers to clean and define the borders of the **triceps brachii muscle**. The triceps brachii muscle has three proximal attachments:
   - **Long head of the triceps brachii muscle** attaches to the infraglenoid tubercle of the scapula.
   - **Lateral head of the triceps brachii muscle** attaches to the posterior surface of the humerus superior to the radial groove.
   - **Medial head of the triceps brachii muscle** attaches to the posterior surface of the humerus inferior to the radial groove.
5. Observe the distal attachment of the triceps brachii tendon on the olecranon of the ulna. The triceps brachii muscle extends the forearm.
6. Use your fingers to separate the **long head of the triceps brachii** from the **lateral head**. Observe that the teres major muscle crosses the anterior surface of the long head.
7. Inferior to the teres major muscle is an opening between the long head of the triceps brachii muscle and lateral head of the triceps brachii muscle (Fig. 2.14). Use a probe to widen this opening and identify the **radial nerve** and the **deep artery of the arm.**
8. Push a probe distally along the course of the radial nerve. The probe should be positioned between the lateral head of the triceps brachii muscle and the humerus (Fig. 2.14).
9. Use a scalpel to transect the lateral head of the triceps brachii muscle over the probe. This cut will separate the lateral head of the triceps brachii muscle from the medial head.
10. Use a probe to clean the radial nerve and the deep artery of the arm. Observe that the radial nerve and deep artery of the arm lie directly on the posterior surface of the humerus in the **radial groove**.
11. Confirm the course of the radial nerve through the posterior compartment to the elbow. To do this, return to the cubital fossa. On the lateral aspect of the forearm, identify the **brachioradialis muscle**. Use your fingers to open the connective tissue plane between the brachioradialis muscle and the brachialis muscle. Deep in this plane of connective tissue, find the radial nerve.
12. Follow the radial nerve proximally. Note that the radial nerve passes on the flexor side of the elbow joint and that it is accompanied by the radial recurrent artery (Fig. 2.12).
13. Identify the **anconeus muscle** (Fig. 2.14). The proximal attachment of the anconeus muscle is the lateral epicondyle of the humerus. The distal attachment is the lateral surface of the olecranon and superior part of the posterior surface of the ulna. The anconeus muscle assists the triceps brachii muscle in extension of the forearm.

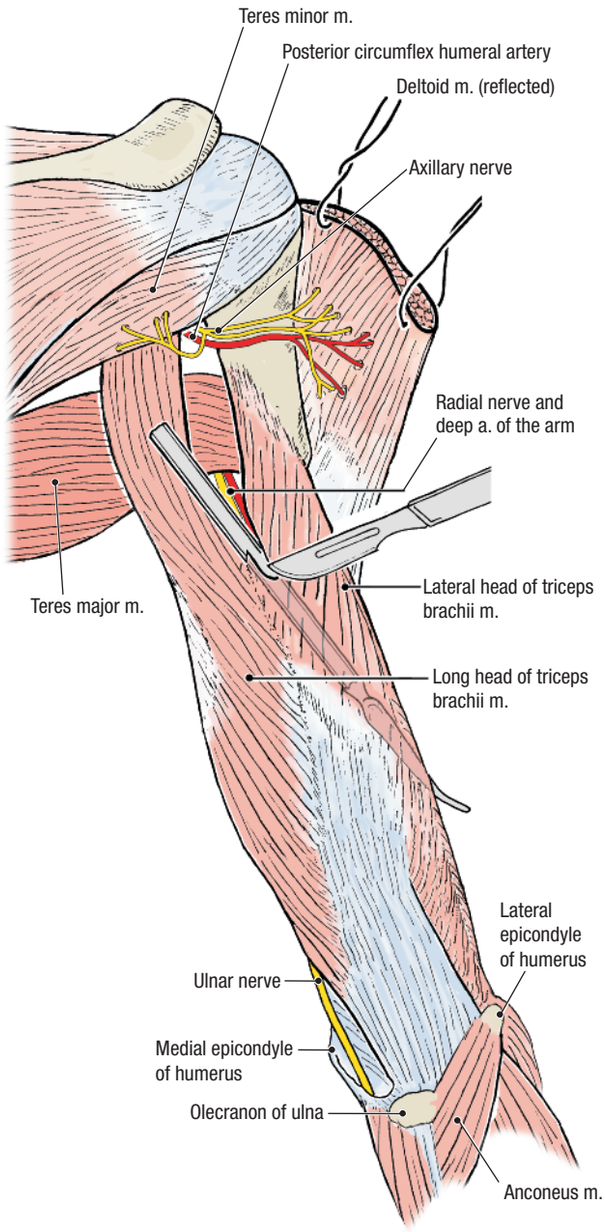

Figure 2.14. How to transect the lateral head of the triceps brachii muscle.

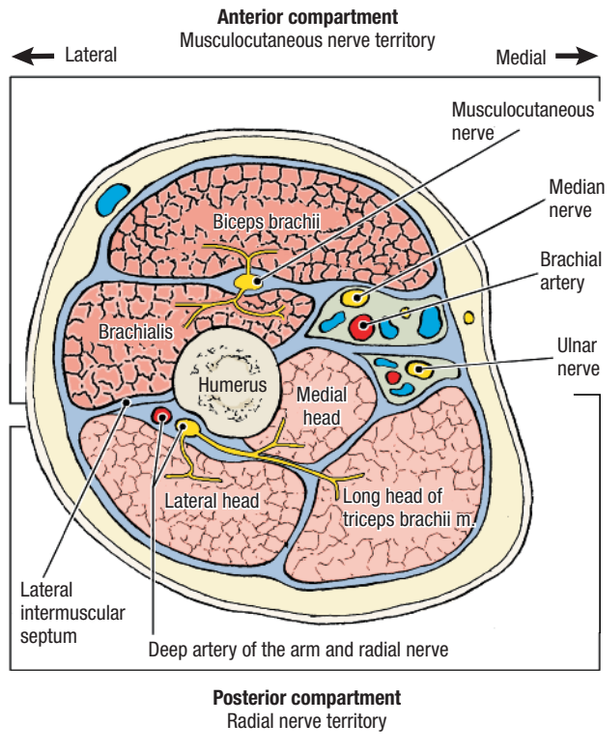

Figure 2.15. Compartments of the right arm with contents.

FLEXOR REGION OF THE FOREARM

Before you dissect . . .

The antebrachial fascia is a sleeve of connective tissue that invests the forearm. Intermuscular septa project inward from it and attach the antebrachial fascia to the radius and ulna (Fig. 2.16). The intermuscular septa, the interosseous membrane, the radius, and the ulna combine to divide the forearm into an **anterior (flexor) compartment** and a **posterior (extensor) compartment**. At the level of the wrist, the antebrachial fascia is thickened posteriorly to create a strong transverse band called the **extensor retinaculum**.

The muscles in the anterior compartment of the forearm can be divided into a **superficial group of flexor muscles** and a

After you dissect . . .

Replace the muscles of the anterior and posterior compartments of the arm in their correct anatomical positions. Review the proximal attachment, distal attachment, nerve, and action of each muscle. Use the dissected specimen to review the origin, course, termination, and branches of the brachial artery. Trace each nerve that you have dissected from the brachial plexus to the elbow, reviewing relationships. Review a drawing of a cross-section of the arm and notice the position of the brachial fascia and the intermuscular septa relative to the structures that you have dissected. Review the nerve territories of the brachial region (Fig. 2.15). Recall the rules of innervation of the muscles of the arm: **all muscles in the anterior compartment of the arm are innervated by the musculocutaneous nerve. All muscles in the posterior compartment of the arm are innervated by the radial nerve.** ***The median nerve and the ulnar nerve do not innervate muscles in the arm.***

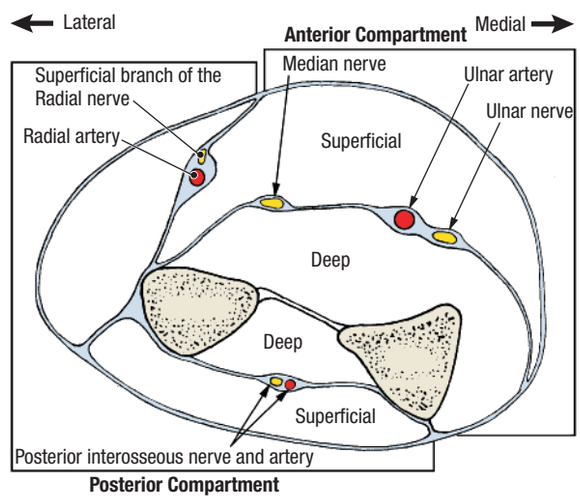

Figure 2.16. Compartments of the right forearm.

deep group of flexor muscles. Muscles of the superficial flexor group arise primarily from the medial epicondyle of the humerus and its supracondylar ridge. Muscles of the deep flexor group arise from the anterior surfaces of the radius, ulna, and interosseous membrane. Study a transverse section through the mid-level of the forearm (Fig. 2.16). Note that the ulnar artery, ulnar nerve, and median nerve are in a connective tissue plane that separates the superficial flexor group from the deep flexor group.

SKELETON OF THE FOREARM [G 524, 532, 554; N 419, 422; R 361, 362; C 76, 77]

Refer to a skeleton. On the **humerus**, identify (Fig. 2.17):

- **Medial epicondyle**
- **Medial supracondylar ridge**
- **Lateral epicondyle**
- **Lateral supracondylar ridge**
- **Capitulum**
- **Trochlea**
- **Olecranon fossa**

On the **radius** identify (Fig. 2.17):

- **Head**
- **Neck**
- **Tuberosity**
- **Anterior oblique line**
- **Ulnar notch**
- **Styloid process**
- **Interosseous border** for attachment of the **interosseous membrane**

On the **ulna** identify (Fig. 2.17):

- **Olecranon**
- **Trochlear notch**
- **Radial notch**
- **Head**
- **Interosseous border** for attachment of the interosseous membrane

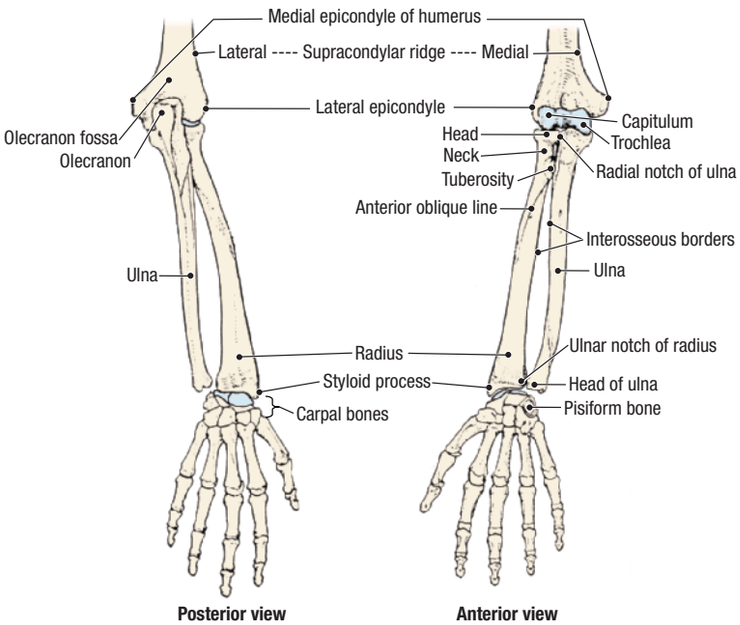

Figure 2.17. Skeleton of the forearm.

On the palmar surface of the articulated hand, identify the **pisiform bone** (Fig. 2.17).

On the skeleton, examine the **elbow joint**. The elbow joint is the articulation between the trochlear notch of the ulna and the trochlea of the humerus, and the articulation between the head of the radius and the capitulum of the humerus. These two articulations account for the hinge action of the elbow joint.

Observe the **proximal radioulnar joint** between the head of the radius and the radial notch of the ulna. Observe the **distal radioulnar joint** between the head of the ulna and the ulnar notch of the radius. Pronate and supinate the hand and notice the rotational movements that occur in the proximal and distal radioulnar joints. In the position of supination (anatomical position), the radius and the ulna are parallel. In the position of pronation, the radius crosses the ulna.

The order of dissection will be as follows: the structures in the superficial fascia will be reviewed and the antebrachial fascia will be removed. At the level of the wrist, the relative positions of tendons, vessels, and nerves will be studied. The superficial group of flexor muscles will be studied and then reflected. Vessels and nerves that lie between the superficial and deep groups of flexor muscles will be studied. The deep group of flexor muscles will be dissected.

Dissection Instructions

SUPERFICIAL GROUP OF FLEXOR MUSCLES [G 534, 535; N 429; R 408; C 44]

1. Place the cadaver in the supine position and abduct the upper limb. Forcefully supinate the hand and have your dissection partner hold it in this position.
2. Use blunt dissection to remove the remnants of the superficial fascia, taking care to preserve the cephalic and basilic veins.
3. Use scissors to incise the anterior surface of the antebrachial fascia from the cubital fossa to the wrist. Use your fingers or a probe to separate the antebrachial fascia from the muscles that lie deep to it. Detach the antebrachial fascia from its attachments to the radius and ulna and place it in the tissue container.
4. Use blunt dissection to clean the **superficial group of flexor muscles**. There are five muscles in this group: **Pronator teres**, **flexor carpi radialis**, **palmaris longus**, **flexor carpi ulnaris**, and **flexor digitorum superficialis**. Note that part of the proximal attachment of these muscles is from a **common flexor tendon**. The common flexor tendon is attached to the medial epicondyle of the humerus.
5. Note the distal attachment and action of each muscle of the superficial group of flexors:
   - **Pronator teres muscle** attaches to the middle of the lateral surface of the radius. The pronator teres muscle pronates the hand and flexes the forearm.
   - **Flexor carpi radialis tendon** attaches to the base of the second metacarpal bone. The flexor carpi radialis muscle flexes and abducts the hand.
   - **Palmaris longus tendon** attaches to the palmar aponeurosis. The palmaris longus muscle flexes the hand.

- **Flexor carpi ulnaris tendon** attaches to the pisiform bone, hamate bone, and the base of the fifth metacarpal bone. The flexor carpi ulnaris muscle flexes and adducts the hand.
- **Flexor digitorum superficialis tendon** attaches to the middle phalanx of digits 2 to 5. The flexor digitorum superficialis muscle flexes the middle phalanx of digits 2 to 5.

6. Use your fingers to separate the tendons of the superficial group of flexor muscles. Note that the muscle bellies cannot be easily separated from each other. From lateral to medial, identify the superficial structures at the wrist (Fig. 2.18): **[G 539; N 429; R 408; C 44]**
   - Tendon of the **abductor pollicis longus muscle**
   - **Radial artery**
   - Tendon of the **flexor carpi radialis muscle**
   - **Median nerve**
   - Tendon of the **palmaris longus muscle** (absent in 13% of limbs)
   - Four tendons of the **flexor digitorum superficialis muscle**
   - **Ulnar artery** and **ulnar nerve**
   - Tendon of the **flexor carpi ulnaris muscle**
7. Palpate the tendons listed above in your own wrist. Feel the pulse of the radial artery between the tendons of the abductor pollicis longus and flexor carpi radialis muscles. The median nerve is superficial at the wrist and can be easily injured. Palpate the distal attachment of the flexor carpi ulnaris tendon on the pisiform bone. Palpate the ulnar nerve and artery, which lie immediately lateral to the pisiform bone.

VESSELS AND NERVES [G 536; N 430; R 408; C 48]

1. On the lateral side of the proximal forearm, identify the **brachioradialis muscle**. At the point where the pronator teres muscle passes deep to the brachioradialis muscle, use your fingers to open the connective tissue plane that is medial to the brachioradialis muscle. In this intermuscular plane, identify the **superficial branch of the radial nerve**, which courses distally on the deep surface of the brachioradialis muscle. Trace the superficial branch of the radial nerve distally and confirm that it becomes subcutaneous near the wrist.
2. Once again, identify the **brachial artery** in the cubital fossa**.** Use blunt dissection to trace the brachial artery distally until it bifurcates into the **radial artery** and the **ulnar artery**.

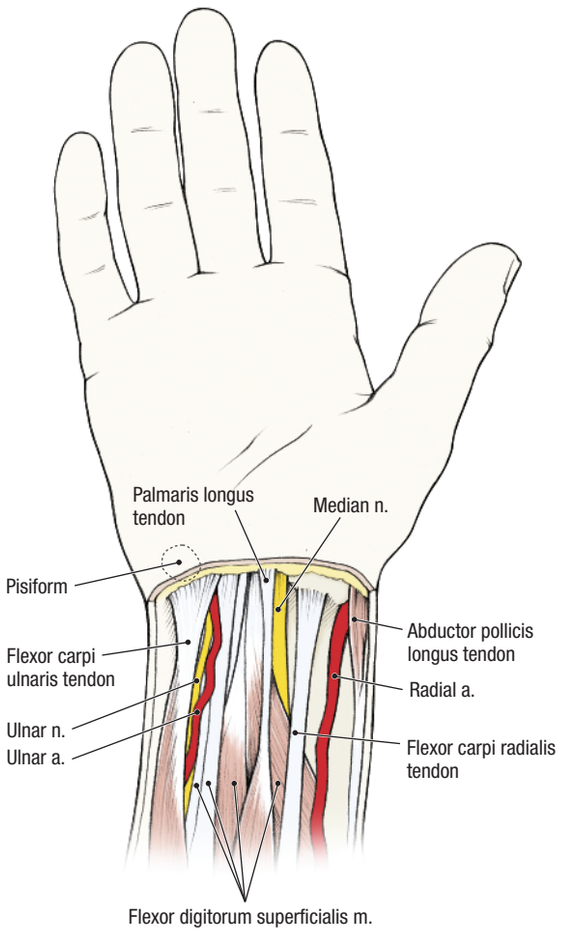

Figure 2.18. Structures of the anterior aspect of the wrist.

CLINICAL CORRELATION

High Bifurcation of the Brachial Artery

In approximately 3% of upper limbs, the brachial artery bifurcates in the arm. When it does, the ulnar artery may course superficial to the superficial group of flexor muscles. When this happens, the ulnar artery may be mistaken for a vein. When certain drugs are injected into an artery, the capillary bed is damaged, followed by gangrene. In the example of the ulnar artery, the hand could be severely injured.

3. Use a probe to clean the radial artery and follow it distally to the level of the wrist. The radial vein and its tributaries may be removed to clear the dissection field. The radial artery gives rise to several unnamed muscular branches in the forearm.
4. Find the **radial recurrent artery**, which arises from the radial artery near its origin from the brachial artery. The radial recurrent artery courses proximally in the connective tissue plane between the brachioradialis muscle and the brachialis muscle. The radial recurrent artery anastomoses with the radial collateral branch of the deep artery of the arm. The radial recurrent artery is part of the anastomotic network around the elbow (Fig. 2.13).
5. Identify the **median nerve** in the cubital fossa. It is medial to the brachial artery. The median nerve innervates most of the muscles of the flexor compartment of the forearm.

6. Follow the median nerve distally. The median nerve courses deep to the superficial group of flexor muscles. To expose the median nerve, use scissors to cut the tendon of the palmaris longus muscle approximately 3 cm proximal to the wrist and reflect the muscle belly proximally. Cut the tendon of the flexor carpi radialis muscle approximately 5 cm proximal to the wrist and reflect it proximally.
7. Insert a probe through the pronator teres muscle along the anterior surface of the median nerve. Use scissors to cut the portion of the pronator teres muscle that lies anterior to the median nerve. Use a probe to release the median nerve and follow it distally.
8. Observe that the median nerve passes deep to the flexor digitorum superficialis muscle. Use scissors to detach the flexor digitorum superficialis muscle from its proximal attachment to the radius. Retract the muscle medially, leaving its ulnar and humeral attachments undisturbed.
9. Use a probe to free the median nerve from the loose connective tissue that lies between the superficial and deep groups of forearm flexor muscles (Fig. 2.16). Observe that the median nerve innervates the palmaris longus, flexor carpi radialis, flexor digitorum superficialis, and pronator teres muscles.
10. Find the **ulnar artery** in the cubital fossa. The ulnar artery passes posterior to the deep part of the pronator teres muscle. To follow the ulnar artery distally, release it from the pronator teres muscle. Insert a probe through the pronator teres muscle along the anterior surface of the ulnar artery (posterior to the deep part of the pronator teres muscle). Use scissors to cut the deep part of the pronator teres muscle. The pronator teres muscle is now completely transected and it may be reflected to broaden the dissection field.
11. Use a probe to clean the ulnar artery and follow it from the cubital fossa to the wrist. The ulnar vein and its tributaries may be removed to clear the dissection field. Observe that the median nerve crosses anterior to the ulnar artery in the cubital fossa. Note that the ulnar artery passes between the flexor digitorum superficialis and the flexor digitorum profundus muscles to reach the ulnar (medial) side of the forearm.
12. Find the **common interosseous artery**. It arises approximately 3 cm distal to the origin of the ulnar artery from the brachial artery. The common interosseous artery is usually quite short. It passes posterolaterally toward the interosseous membrane before dividing into the **anterior interosseous artery** and the **posterior interosseous artery**.
13. Identify the **anterior interosseous artery** on the anterior surface of the interosseous membrane. The anterior interosseous artery supplies the deep group of flexor muscles.
14. The **posterior interosseous artery** passes over the proximal end of the interosseous membrane to reach the posterior compartment of the forearm. The posterior interosseous artery supplies the extensor group of forearm muscles. Identify it, but do not attempt to follow it into the posterior compartment at this time.
15. Two other named vessels arise from the ulnar artery in the proximal forearm: **anterior ulnar recurrent artery** and **posterior ulnar recurrent artery**. They anastomose with the superior and inferior ulnar collateral branches of the brachial artery, respectively (Fig. 2.13). Do not attempt to find these vessels. Note that unnamed muscular branches arise from the ulnar artery in the forearm.
16. Observe that the ulnar artery joins the **ulnar nerve** approximately one-third of the way down the forearm.
17. Follow the ulnar nerve proximally and observe that it passes between the two heads of the flexor carpi ulnaris muscle. The ulnar nerve innervates the flexor carpi ulnaris muscle and the medial one-half of the flexor digitorum profundus muscle.

DEEP GROUP OF FLEXOR MUSCLES [G 537; N 431; R 409; C 50]

1. Three muscles comprise the **deep group of flexor muscles**: **flexor digitorum profundus**, **flexor pollicis longus**, and **pronator quadratus**.
2. The proximal attachment of the **flexor digitorum profundus muscle** is the anterior surface of the ulna and interosseous membrane. Distally, the flexor digitorum profundus tendons attach to the distal phalanx of digits 2 to 5. The flexor digitorum profundus muscle flexes the distal phalanx of digits 2 to 5. The lateral one-half of the flexor digitorum profundus muscle is innervated by the median nerve. The medial one-half of the flexor digitorum profundus muscle is innervated by the ulnar nerve.
3. The proximal attachment of the **flexor pollicis longus muscle** is the anterior surface of the radius and interosseous membrane. The distal attachment of the flexor pollicis longus tendon is the distal phalanx of digit 1 (thumb). The flexor pollicis longus muscle flexes digit 1.
4. The **pronator quadratus muscle** lies posterior to the tendons of the superficial and deep flexor muscles. Its fibers run transversely from the ulna to the radius in the distal one-fourth of the forearm. Retract the tendons of the superficial and deep groups of flexor muscles and find the pronator quadratus muscle. The pronator quadratus muscle pronates the hand.
5. Observe that the **anterior interosseous artery and nerve** pass posterior to the pronator quadratus muscle.

After you dissect . . .

Replace the flexor muscles in their correct anatomical positions. Use the dissected specimen to review the proximal attachment, distal attachment, and action of each muscle dissected. Organize these muscles into a superficial group and a deep group and recall that the nerves and vessels that course through the forearm are found between the two groups. Follow the brachial artery from its origin in the proximal arm to its bifurcation in the cubital fossa. Review all of the branches of the radial and ulnar arteries. Trace the course of these two arteries from the elbow to the wrist. Review the course of the median nerve from the

brachial plexus to the wrist. Review the course of the ulnar nerve from the brachial plexus to the wrist. Recall the rule for innervation of the muscles in the anterior compartment of the forearm: **all muscles of the anterior compartment of the forearm are innervated by the median nerve** ***except the flexor carpi ulnaris muscle and the medial one-half of the flexor digitorum profundus muscle, which are innervated by the ulnar nerve.***

PALM OF THE HAND

Before you dissect . . .

The **intrinsic hand muscles** have their proximal and distal attachments within the hand. There are two superficial groups of intrinsic hand muscles: the **thenar group of muscles** forms the **thenar eminence**, and the **hypothenar group of muscles** forms the **hypothenar eminence**. Deep in the hand is a third group of intrinsic hand muscles: the interosseous muscles and the adductor pollicis muscle.

In the middle of the palm, the palmar fascia is thickened to form the palmar aponeurosis. The palmar fascia over the thenar and hypothenar eminences is much thinner. Deep to the palmar aponeurosis are the tendons of the superficial and deep digital flexor muscles. These tendons reach the palm through the carpal tunnel and are responsible for flexing the digits. In the deepest part of the palm are small muscles that abduct and adduct the digits.

The palm is supplied with blood by two arterial arches. The superficial arch is mainly derived from the ulnar artery and the deep arch from the radial artery. The nerve supply of the palmar aspect of the hand is derived from the median and ulnar nerves.

The order of dissection will be as follows: the palmar aponeurosis will be studied and removed. The superficial palmar arch will be dissected, followed by the tendons of the muscles of the anterior compartment of the forearm. The flexor retinaculum will be cut and the flexor tendons will be released from the palm. The muscles of the thenar group will be dissected, followed by the muscles of the hypothenar group. The deep palmar arch will be dissected along with the deep branch of the ulnar nerve. The interosseous muscles will be studied.

SKELETON OF THE HAND [G 532, 554; N 439; R 364, 365; C 78, 79]

Refer to an articulated skeleton of the hand and identify (Fig. 2.19):

- **Eight carpal bones** (Gr. *karpos*, wrist)
- **Five metacarpal bones**
- **14 phalanges**

Be able to identify the eight carpal bones in an articulated skeleton. Digit 1 (thumb) has two phalanges: proximal and distal. Digits 2 to 5 (fingers) have three phalanges: proximal, middle, and distal.

Identify the **pisiform bone** and the **hook of the hamate** on the medial side of the wrist. On the lateral side of the wrist, identify the **tubercle of the scaphoid** and the **tubercle of the trapezium**. The **flexor retinaculum** bridges these four bones (Fig. 2.20). The space between the carpal bones and the flexor retinaculum is the **carpal tunnel**, which allows passage of the flexor tendons and the median nerve into the hand.

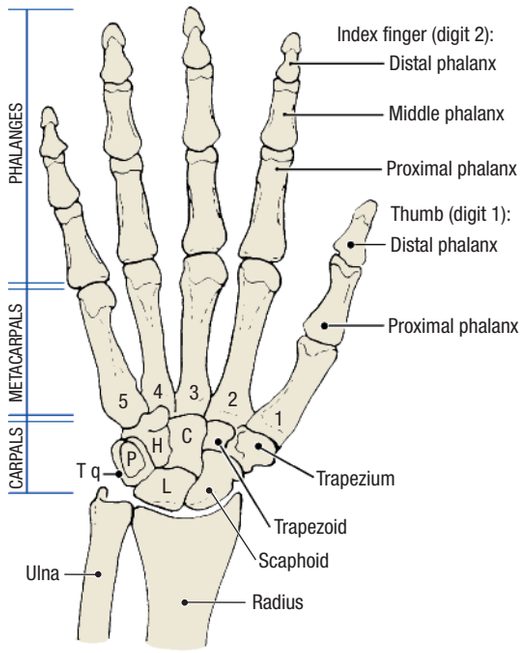

Figure 2.19. Skeleton of the hand. The eight carpal bones include a proximal row of four bones (scaphoid; lunate, *L*; triquetrum, *Tq*; pisiform, *P*) and a distal row of four bones (trapezium; trapezoid; capitate, C; hamate, *H*).

Dissection Instructions

SUPERFICIAL PALM [G 541; N 442, 443; R 412; C 62, 68]

1. Use scraping motions with a dull scalpel blade to clean the fat from the **palmar aponeurosis**. Observe that the palmar aponeurosis has four bands of **longitudinal fibers**, one band to each of digits 2 to 5. These longitudinal fibers end by attaching to the fibrous digital sheath near the base of the proximal phalanx of each digit.
2. Identify the fascia of the **thenar muscles** lateral to the palmar aponeurosis.
3. Identify the fascia of the hypothenar muscles medial to the palmar aponeurosis. The **palmaris brevis muscle** is found superficial to the hypothenar muscles. It is a thin, fragile muscle. The proximal attachment of the

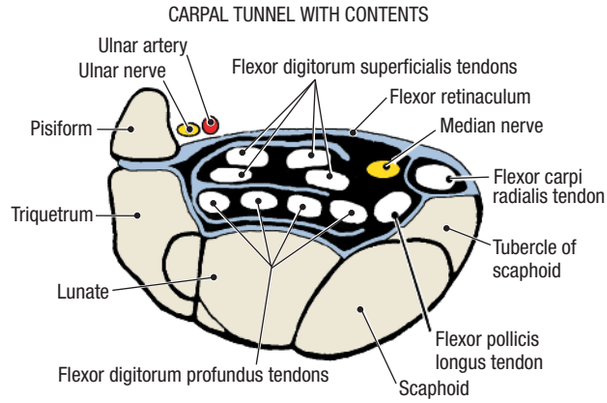

Figure 2.20. Transverse section through the left carpal tunnel.

palmaris brevis muscle is the medial aspect of the palmar aponeurosis. Its distal attachment is the skin over the hypothenar eminence.

4. Detach the palmaris brevis muscle from the palmar aponeurosis and reflect it medially.
5. Find the tendon of the **palmaris longus muscle** where you transected it in the forearm. Follow the palmaris longus tendon distally into the palm, where it is attached to the palmar aponeurosis. Although the palmaris longus muscle may be absent, the palmar aponeurosis is always present.
6. Remove the palmar aponeurosis. Use a scalpel and skinning motions to detach the palmar aponeurosis from the underlying deep structures. Begin at its proximal end and proceed distally. Use the palmaris longus tendon to apply traction to the palmar aponeurosis during its removal. Do not cut too deeply, because the superficial palmar arch is in contact with the deep surface of the palmar aponeurosis.
7. Near the proximal end of digits 2 to 5, remove the band of longitudinal fibers of the palmar aponeurosis. Use blunt dissection to clean the **fibrous digital sheath** on the flexor surface of digit 3 (Fig. 2.21).
8. Find the **ulnar artery** in the forearm. Use a probe to dissect the ulnar artery and follow it into the palm. The ulnar artery passes lateral to the pisiform bone with the ulnar nerve, and then divides into a **superficial branch** and a **deep palmar branch.** The superficial branch of the ulnar artery crosses the palm to form the **superficial palmar arch**. The superficial palmar arch is completed by a smaller contribution from the **superficial palmar branch of the radial artery** (Fig. 2.22). **[G 546; N 443; R 414; C 68]**
9. Use a probe to clean the superficial palmar arch and the three **common palmar digital arteries** arising from it. Trace one common palmar digital artery distally and note that it divides into two **proper palmar digital arteries** that supply the adjacent sides of two digits.
10. Find the **ulnar nerve** lateral to the pisiform bone. Use a probe to dissect the **superficial branch of the ulnar nerve**, which supplies cutaneous innervation to digit 5 and the medial side of digit 4. The **deep branch of the ulnar nerve** disappears into the hypothenar muscles. Identify the initial portion of the deep branch of the ulnar nerve but do not follow it at this time.

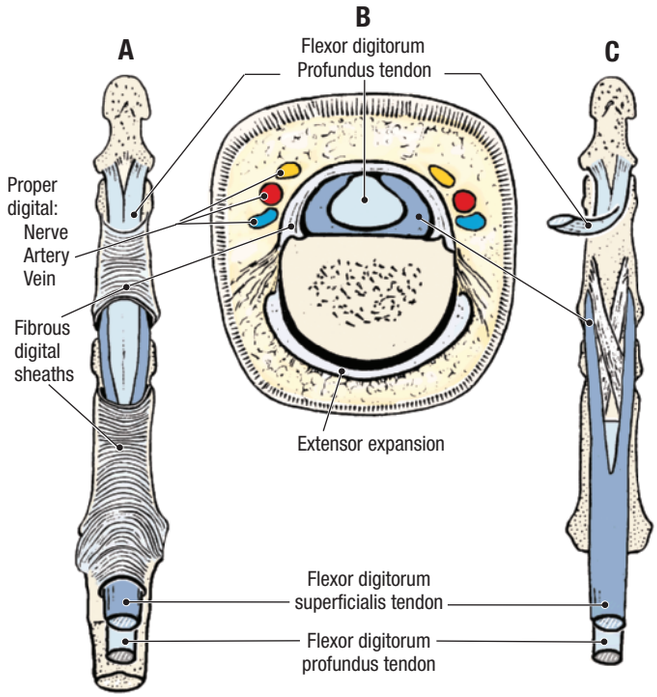

Figure 2.21. Flexor tendons in the finger. **A.** Fibrous digital sheath showing the two osseofibrous tunnels. **B.** Transverse section of a finger showing the fibrous digital sheath surrounding the flexor tendons. **C.** Distal attachment of the flexor tendons.

CARPAL TUNNEL [G 547; N 444; R 415; C 65]

1. Identify the **flexor retinaculum** between the thenar and hypothenar eminences. Use an illustration to review the flexor retinaculum and its role in the formation of the **carpal tunnel** (Fig. 2.21).
2. Insert a probe from proximal to distal, deep to the flexor retinaculum (Fig. 2.23). Use a scalpel to cut through the flexor retinaculum to the probe. Open the carpal tunnel.
3. Examine the **contents of the carpal tunnel**: **median nerve**, **four tendons of the flexor digitorum superficialis muscle**, **four tendons of the flexor digitorum profundus muscle**, and the **tendon of the flexor pollicis longus muscle**.
4. Find the median nerve at the level of the wrist and follow it through the carpal tunnel. Identify the **recurrent branch of the median nerve**, which innervates the three thenar muscles (Fig. 2.23). The median nerve also innervates **lumbrical muscles 1 and 2**.
5. Follow the **common palmar digital branches** of the median nerve to the lateral 3 1/2: digits (Fig. 2.22). Note that the common palmar digital nerves typically divide to give rise to two **proper palmar digital nerves**, which accompany the proper palmar digital arteries. Use an illustration to study the cutaneous distribution of the median nerve in the hand. **[G 559; N 455; R 409; C 24]**
6. Identify the flexor tendons that pass through the carpal tunnel. Observe that these tendons pass through the palm of the hand posterior to the superficial palmar arch and digital nerves. The flexor tendons enter the **fibrous digital sheaths** on the anterior surfaces of the digits (Fig. 2.21).
7. Use an illustration to study the extent of the synovial tendon sheaths deep to the flexor retinaculum and extending into the palm. There are two sets of synovial sheaths: one **common flexor sheath (ulnar bursa)** and three **digital synovial sheaths**. The tendon of the flexor pollicis longus muscle has it own synovial sheath (**radial bursa**). **[G 548; N 445, 446; R 378, 379; C 63]**

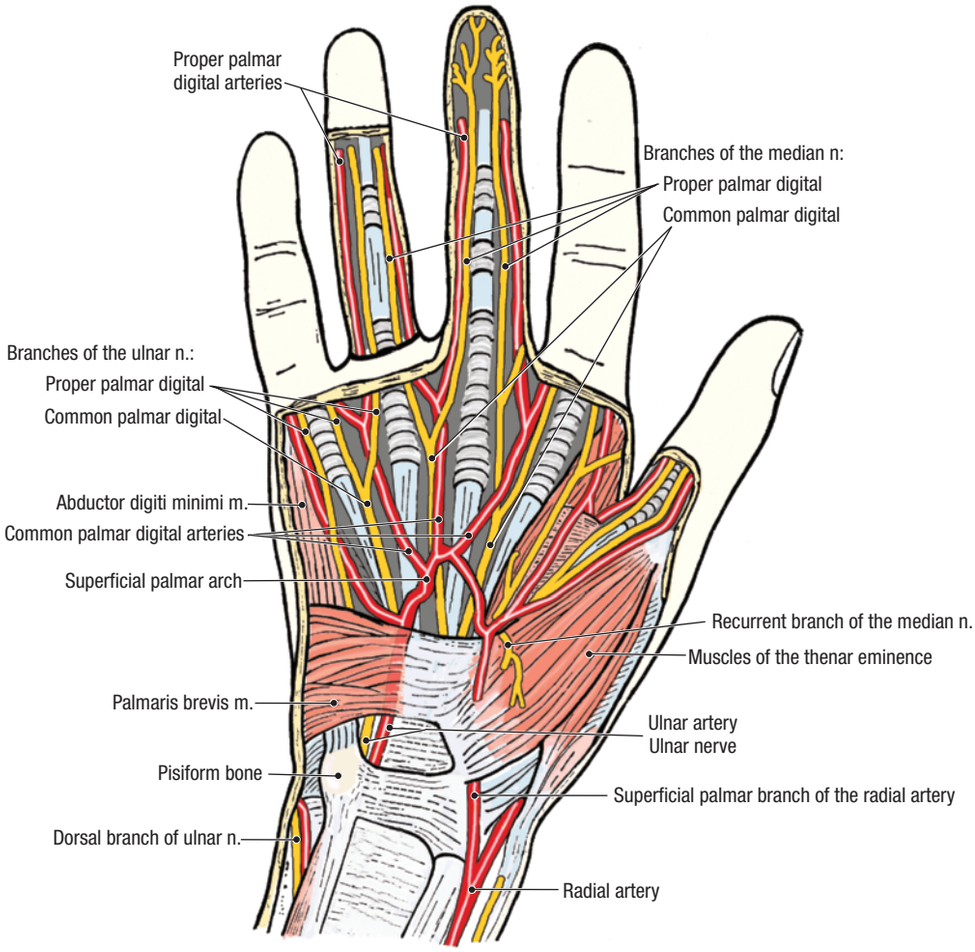

Figure 2.22. Superficial dissection of the palm.

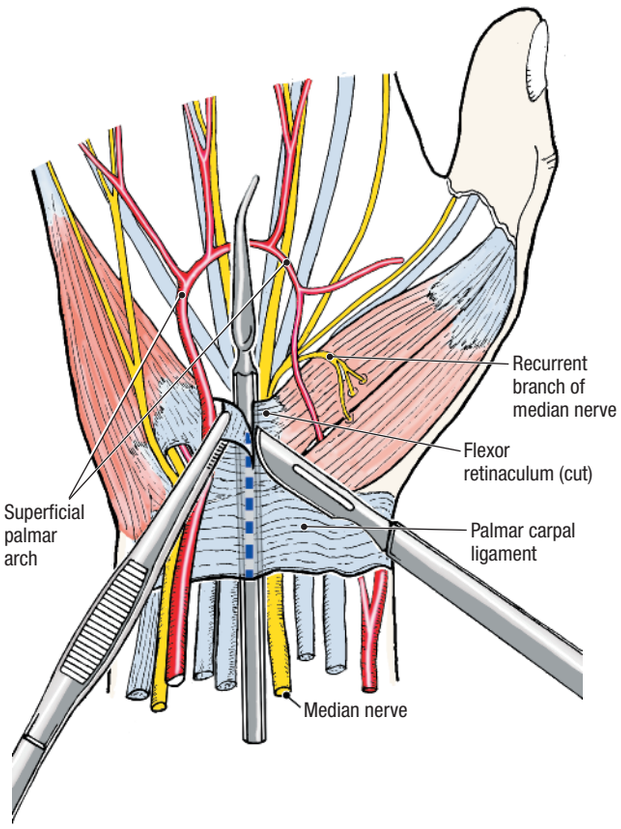

Figure 2.23. How to open the carpal tunnel.

CLINICAL CORRELATION

Carpal Tunnel Syndrome

A swelling of the common flexor sheath may encroach on the available space in the carpal tunnel. As a result, the median nerve may be compressed resulting in pain and paresthesia of the thumb, index finger, and middle finger, and weakness of the thenar muscles.

8. In the distal forearm, use your fingers to separate the tendons of the **flexor digitorum superficialis** muscle from the tendons of the **flexor digitorum profundus muscle**. Approximately 5 cm proximal to the wrist, use scissors to transect the tendons of the flexor digitorum superficialis muscle. Reflect the tendons distally, pulling them through the carpal tunnel. During this procedure, the common flexor sheath will be destroyed. To reflect the tendons even further, cut the superficial palmar arch in the midline of the palm, retract the common digital branches of the median and ulnar nerves, and make a longitudinal slit in the fibrous digital sheaths of digits 2 to 5.

9. In the palm, observe the tendons of the **flexor digitorum profundus muscle**. Identify four **lumbrical muscles** that are attached to the four tendons of the flexor digitorum profundus muscle. The distal attachment of the lumbrical muscles is the radial side of the **extensor expansions** of digits 2 to 5 (Fig. 2.24). The lumbrical muscles flex the metacarpophalangeal joints and extend the interphalangeal joints.
10. In digit 3, study the **relationship of the tendons of the flexor digitorum superficialis** and **flexor digitorum profundus muscles** (Fig. 2.24). Note that the tendon of the flexor digitorum profundus splits the tendon of the flexor digitorum superficialis. Verify that the flexor digitorum superficialis tendon attaches to the middle phalanx, whereas the flexor digitorum profundus tendon attaches to the distal phalanx. This pattern is true of digits 2 to 5.
11. Identify the **flexor pollicis longus muscle** in the forearm. Follow its tendon distally through the carpal tunnel into the palm. Pull on the tendon to confirm that the flexor pollicis longus muscle attaches to the distal phalanx of the thumb.

THENAR MUSCLES [G 548, 550; N 448; R 412; C 64]

1. Use blunt dissection to clean the palmar surface of the thenar muscles.
2. The thenar group contains three muscles: **abductor pollicis brevis**, **flexor pollicis brevis**, and **opponens pollicis** (L. *pollex*, thumb; genitive, *pollicis*). The proximal attachments of the thenar muscles are the scaphoid, trapezium, and flexor retinaculum.
   - **Abductor pollicis brevis muscle** attaches to the lateral side of the proximal phalanx of the thumb and it abducts the thumb.
   - **Flexor pollicis brevis muscle** attaches to the lateral side of the proximal phalanx of the thumb and it flexes the thumb.
   - **Opponens pollicis muscle** attaches to the lateral side of the shaft of the first metacarpal bone and it opposes the thumb.
3. Observe the **recurrent branch of the median nerve**. The recurrent branch of the median nerve crosses the superficial surface of the flexor pollicis brevis muscle, and then disappears deep to the abductor pollicis brevis muscle.
4. Use a probe to separate the abductor pollicis brevis muscle from the flexor pollicis brevis muscle. Use the recurrent branch of the median nerve to help locate the correct plane of separation.
5. Use a probe to elevate the abductor pollicis brevis muscle and transect it with scissors.
6. Observe the **opponens pollicis muscle** deep to the abductor pollicis brevis muscle. Note that the opponens pollicis muscle attaches to the lateral side of the entire length of the shaft of the first metacarpal bone.

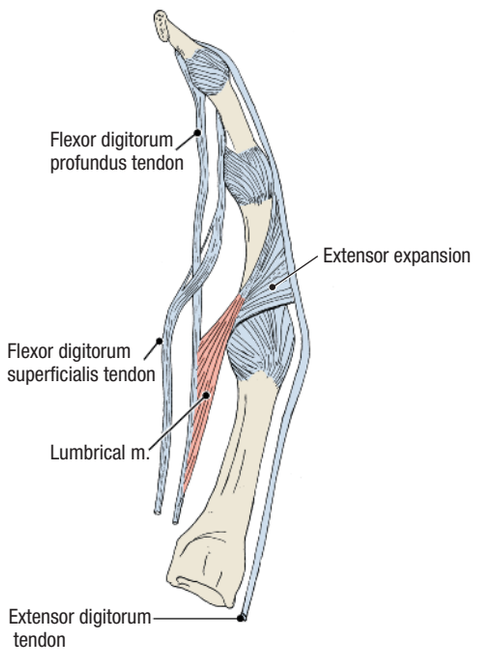

Figure 2.24. Extensor expansion.

CLINICAL CORRELATION

Recurrent Branch of the Median Nerve

The recurrent branch of the median nerve is superficial and it can easily be severed by "minor" cuts over the thenar eminence. If the recurrent branch of the median nerve is injured, the thenar muscles are paralyzed and the thumb cannot be opposed.

HYPOTHENAR MUSCLES [G 548, 550; N 448; R 412; C 64]

1. Use blunt dissection to clean the palmar surface of the hypothenar muscles. The hypothenar group contains three muscles: **abductor digiti minimi**, **flexor digiti minimi brevis**, and **opponens digiti minimi**. The proximal attachments of the hypothenar muscles are the pisiform, hamate, and flexor retinaculum.
   - **Abductor digiti minimi muscle** attaches to the medial side of the base of the proximal phalanx of digit 5 and it abducts digit 5.
   - **Flexor digiti minimi brevis muscle** attaches to the medial side of the base of the proximal phalanx of digit 5and it flexes digit 5.
   - **Opponens digiti minimi muscle** attaches to the medial border of the fifth metacarpal bone and it opposes digit 5.
2. Use a probe to define the borders of the abductor digiti minimi muscle and the flexor digiti minimi brevis muscle. Use the tendons at the distal attachment to aid in this separation.
3. Use a probe to elevate the abductor digiti minimi brevis muscle and detach it from its proximal attachment on the flexor retinaculum. Preserve the deep branches of the ulnar artery and ulnar nerve.

4. Observe the **opponens digiti minimi muscle**. Note that the opponens digiti minimi muscle attaches to the entire length of the shaft of the fifth metacarpal bone.

DEEP PALM [G 550, 551; N 448, 449; R 412; C 69]

1. Transect the flexor digitorum profundus muscle in the distal one-third of the forearm. Reflect its tendons and the associated lumbrical muscles distally as far as possible. The deep palm is now exposed.
2. Find the ulnar nerve and the ulnar artery on the lateral side of the pisiform bone.
3. The **deep branch of the ulnar nerve** and the **deep palmar branch of the ulnar artery** pass between the proximal attachments of the flexor digiti minimi brevis and abductor digiti minimi muscles.
4. Push a probe parallel to the deep branch of the ulnar nerve where it pierces the opponens digiti minimi muscle. Use a scalpel to cut down to the probe. Use blunt dissection to follow the deep branch of the ulnar nerve into the palm.
5. Observe that the deep branch of the ulnar nerve lies on the anterior surface of the interosseous muscles (Fig. 2.25A).
6. Observe the **deep palmar arch.** The deep palmar arch courses with the deep branch of the ulnar nerve. The deep palmar arch arises from the **radial artery**. The deep palmar arch is completed by the deep branch of the ulnar artery. Use an illustration to study the branches of the deep palmar arch.
7. Identify the **adductor pollicis muscle** (Fig. 2.25A). Use blunt dissection to define its borders. The adductor pollicis muscle has two heads: **oblique** and **transverse**. The proximal attachments of the oblique head are the bases of metacarpal bones 2 and 3 and the adjacent carpal bones. The proximal attachment of the transverse head is the anterior surface of the shaft of metacarpal bone 3. Both heads attach to the medial side of the base of the proximal phalanx of the thumb. The adductor pollicis muscle draws the thumb toward digit 3 (adduction).
8. Use an illustration to study the three **palmar interosseous muscles** (Fig. 2.25A). The palmar interosseous muscles are unipennate muscles that attach to the metacarpal bones of digits 2, 4, and 5. Distally, the palmar interosseous muscles attach to the bases of the proximal phalanges and the extensor expansions. Do not dissect these muscles. **[G 545; N 448; R 416; C 66]**
9. Use an illustration to study the four **dorsal interosseous muscles** (Fig. 2.25B). The dorsal interosseous muscles are bipennate muscles that attach to metacarpal bones 1 to 5. Distally, the dorsal interosseous muscles attach to the bases of the proximal phalanges and the extensor expansions of digits 2 to 4. Look at the dorsum of the dissected hand and note that the dorsal interosseous muscles occupy the intervals between the metacarpal bones. Do not dissect these muscles.
10. Study the actions of the interosseous muscles (Fig. 2.25). The three **P**almar interosseous muscles are **AD**ductors (**PAD**). They adduct digits 2, 4, and 5 toward an imaginary axial line drawn through the long axis of digit 3. The four **D**orsal interosseous muscles are **AB**ductors (**DAB**). They move digits 2 to 4 away from the imaginary axial line. The two dorsal interosseous muscles that attach to digit 3 move it to either side of the imaginary axial line. The interosseous muscles are innervated by the deep branch of the ulnar nerve.

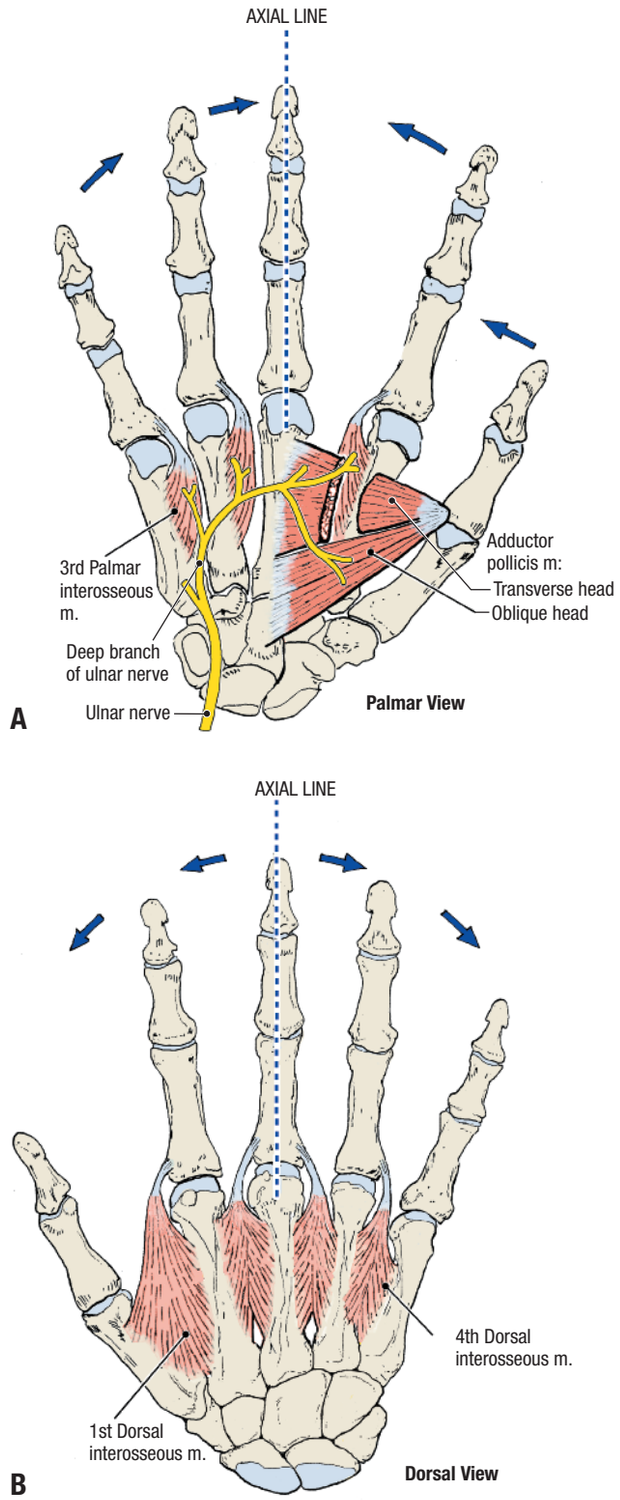

Figure 2.25. A. The three unipennate **P**almar interosseous muscles **AD**duct (**PAD**) the fingers (arrows) in relation to the axial line. **B.** The four bipennate **D**orsal interosseous muscles **AB**duct (**DAB**) the fingers (arrows).

After you dissect . . .

Place the muscles, tendons, and nerves that you have dissected back into their correct anatomical positions. Review the movements of the fingers and thumb. Define flexion, extension, abduction, and adduction. Review the muscles that are responsible for each action. Use the dissected specimen to follow the median nerve from the forearm into the hand. Follow the ulnar artery from the elbow to the hand. In the hand, trace the superficial branch and deep palmar branch of the ulnar artery. Follow the ulnar nerve from the medial epicondyle of the humerus to the hand. In the hand, trace the superficial and deep branches of the ulnar nerve. Review an illustration that demonstrates the cutaneous distribution of the ulnar and median nerves in the hand. Recall the rule for innervation of the muscles in the hand: **all intrinsic muscles of the hand are innervated by the ulnar nerve** ***except the muscles of the thenar group and the first two lumbrical muscles, which are innervated by the median nerve.*** **[G 462; N 455; R 388]**

EXTENSOR REGION OF THE FOREARM AND DORSUM OF THE HAND

Before you dissect . . .

The posterior compartment of the forearm contains the extensor muscles of the forearm. They can be divided into a superficial group and a deep group (Fig. 2.16). The muscles of the superficial group extend the wrist and the proximal phalanges. The muscles of the deep group of extensors cause supination of the hand, extension of digit 2, and abduction and extension of the thumb. The deep branch of the radial nerve innervates the extensor muscles of the forearm. Nerves and vessels of the posterior compartment run in the connective tissue plane that divides the superficial group of extensor muscles from the deep group of extensor muscles.

In the dorsum of the hand, the bones are superficial. There are no intrinsic muscles in the dorsum of the hand, so no motor innervation is required. The radial, ulnar, and median nerves share the cutaneous innervation of the dorsum of the hand.

The order of dissection will be as follows: the antebrachial fascia will be removed from the elbow to the wrist. The muscles of the superficial extensor group will be identified and followed to their distal attachments in the hand. The tendons of the superficial extensor muscles will be released from the extensor retinaculum and retracted to permit the muscles of the deep extensor group to be studied. The contents of the anatomical snuffbox will be identified.

Dissection Instructions

SUPERFICIAL GROUP OF EXTENSOR MUSCLES [G 556; N 427; R 403; C 52]

1. Place the cadaver in the supine position.
2. Use blunt dissection to remove the remnants of the superficial fascia from the posterior forearm and dorsum of the hand, taking care to preserve the dorsal venous arch.
3. Identify the **extensor retinaculum**, which is located on the posterior surface of the distal forearm.
4. Use scissors to incise the posterior surface of the antebrachial fascia from the olecranon to the extensor retinaculum. Preserve the extensor retinaculum. Use your fingers or a probe to separate the antebrachial fascia from the muscles that lie deep to it. Detach the antebrachial fascia from its attachments to the radius and ulna and place it in the tissue container.
5. Six muscles comprise the **superficial extensor group**: **brachioradialis**, **extensor carpi radialis longus**, **extensor carpi radialis brevis**, **extensor digitorum**, **extensor digiti minimi**, and **extensor carpi ulnaris**. Note that four of the muscles in the superficial extensor group (extensor carpi radialis brevis, extensor digitorum, extensor digiti minimi, and extensor carpi ulnaris) attach to the lateral epicondyle of the humerus by way of a **common extensor tendon**.
6. Use tendon patterns at the wrist and distal attachments to positively identify the muscles of the superficial extensor group:
   - **Brachioradialis tendon** attaches to the lateral surface of the distal radius.
   - **Extensor carpi radialis longus tendon** attaches to the base of metacarpal bone 2.
   - **Extensor carpi radialis brevis tendon** attaches to the base of metacarpal bone 3.
   - **Extensor digitorum tendons** attach to the extensor expansions of digits 2 to 5.
   - **Extensor digiti minimi tendon** attaches to the extensor expansion of digit 5.
   - **Extensor carpi ulnaris tendon** attaches to the base of metacarpal bone 5.
7. Note that the tendons of the extensor digitorum longus muscle are tied together by **intertendinous connections** on the posterior surface of the hand. **[G 562; N 453; R 404; C 60]**
8. Observe the **extensor expansion** of digit 3 (Fig. 2.24). The extensor expansion is wrapped around the dorsum and the sides of the proximal phalanx and the distal end of the metacarpal bone. The hood-like expansion retains the extensor tendon in the midline of the digit. The tendons of the lumbrical and interosseous muscles attach to the extensor expansion. **[G 563; N 447; R 404; C 65]**
9. Cut through the **extensor retinaculum** to release the tendons of the extensor digitorum muscle. Retract the tendons medially. Note that the other extensor tendons are also contained within individual osseofibrous tunnels. Synovial sheaths line these tunnels.

DEEP GROUP OF EXTENSOR MUSCLES [G 557; N 428; R 403; C 54]

1. Five muscles comprise the **deep extensor group**: **abductor pollicis longus**, **extensor pollicis brevis**, **extensor pollicis longus**, **extensor indicis**, and **supinator**.
2. The proximal attachments of four muscles of the deep extensor group (abductor pollicis longus, extensor

pollicis brevis, extensor pollicis longus, and extensor indicis) are the posterior surfaces of the radius, ulna, and interosseous membrane. These four muscles emerge from the interval between the extensor digitorum muscle and the extensor carpi radialis brevis muscle.

3. Observe the tendon of each of the following muscles and follow it to its distal attachment:
   - **Abductor pollicis longus tendon** attaches to the base of metacarpal bone 1.
   - **Extensor pollicis brevis tendon** attaches to the base of the proximal phalanx of digit 1.
   - **Extensor pollicis longus tendon** attaches to the base of the distal phalanx of digit 1.
   - **Extensor indicis tendon** attaches to the extensor expansion of digit 2.
4. Identify the **anatomical snuffbox** (Fig. 2.26). The anatomical snuffbox is the depression on the posterior surface of the wrist that is bounded anteriorly by the **abductor pollicis longus tendon** and the **extensor pollicis brevis tendon**. The posterior boundary of the anatomical snuffbox is the **extensor pollicis longus tendon**. [G 564, 565; N 452; R 404; C 59]
5. Within the anatomical snuffbox, find the **radial artery**. Use a probe to clean the radial artery and follow it distally until it disappears between the two heads of the **first dorsal interosseous muscle**. Note that the **dorsal carpal arch** supplies arterial blood to the dorsum of the hand (Fig. 2.26), but do not dissect its branches.
6. Near the elbow, use your fingers to retract the brachioradialis muscle and observe the **supinator muscle**. The proximal attachments of the supinator muscle are the lateral epicondyle of the humerus, the radial collateral ligament, the anular ligament, and the lateral surface of the ulna. The distal attachment of the supinator muscle is the proximal one-third of the radius. The supinator muscle supinates the hand.
7. On the lateral aspect of the elbow, once again find the radial nerve in the connective tissue plane between the brachioradialis muscle and the brachialis muscle. Observe that the radial nerve divides into a superficial branch and a deep branch. The **deep branch of the radial nerve** enters the supinator muscle.
8. Turn the upper limb and look for the deep branch of the radial nerve where it emerges from the distal border of the supinator muscle.
9. When the deep branch of the radial nerve emerges from the supinator muscle, its name changes to **posterior interosseous nerve**. The posterior interosseous nerve provides motor branches to the extensor muscles.
10. Observe that the posterior interosseous nerve is accompanied by the **posterior interosseous artery**, which is a branch of the common interosseous artery.

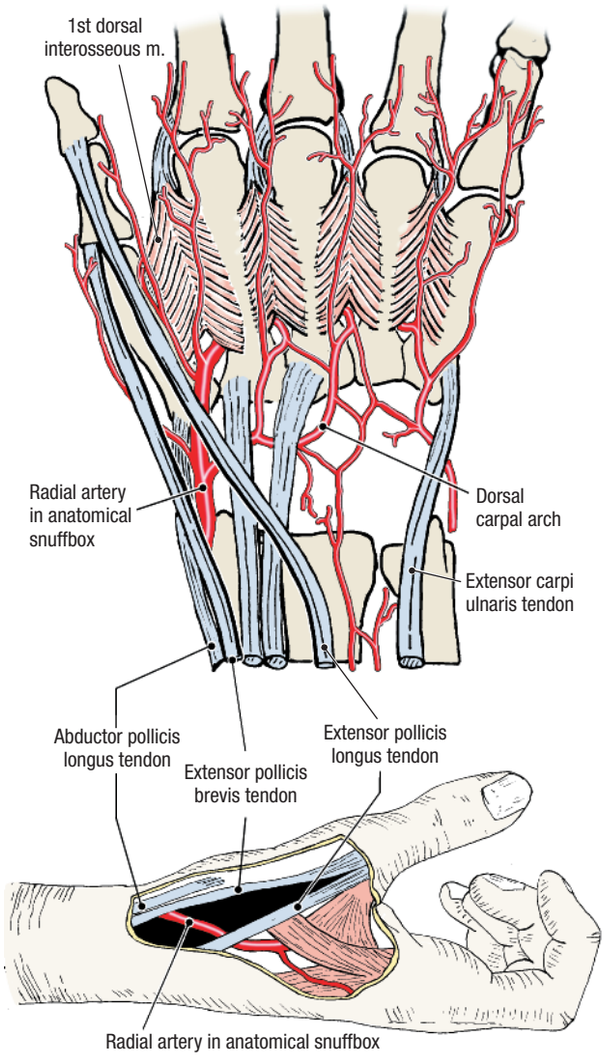

Figure 2.26. Radial artery in the anatomical snuffbox.

After you dissect . . .

Replace the muscles of the posterior compartment of the forearm into their correct anatomical positions. Use the dissected specimen to review the attachments of the extensor tendons. Note that the tendons of three strong extensor muscles (extensor carpi radialis longus, extensor carpi radialis brevis, and extensor carpi ulnaris) attach to the proximal ends of metacarpal bones. These three extensors of the wrist work synergistically with the flexors of the digits: a firm grasp requires an extended wrist. Review the extensor expansion of digit 3. Review the course of the common interosseous branch of the ulnar artery and observe how the posterior interosseous artery enters the posterior compartment of the forearm. Review the course of the radial artery from the cubital fossa to the deep palmar arch. Palpate the anatomical snuffbox on yourself. Feel the pulsations of the radial artery within its boundaries. Recall the rule for innervation of the posterior compartment of the forearm: **The radial nerve innervates all of the muscles in the posterior compartment of the forearm.** ***Note that there are no intrinsic muscles in the dorsum of the hand.***

JOINTS OF THE UPPER LIMB

Before you dissect . . .

Dissect joints in one upper limb. Keep the soft tissue structures of the other limb intact for review purposes.

The order of dissection will be as follows: the sternoclavicular and acromioclavicular joints will be dissected. The glenohumeral joint will be dissected. The elbow joint and radioulnar joints will be studied. The wrist joint will be dissected. Finally, the joints of the digits will be studied. During this dissection, the muscles of one limb will be removed. Take advantage of this opportunity to review the proximal attachment, distal attachment, innervation, and action of each muscle as it is removed.

Dissection Instructions

STERNOCLAVICULAR JOINT [G 486; N 402; C 93]

1. Use an articulated skeleton to observe the relationships between the sternum and clavicle. Identify the **clavicular notch of the manubrium**. The medial end of the clavicle articulates with the clavicular notch and the adjacent part of the first costal cartilage (Fig. 2.27).
2. Place the cadaver in the supine position. The tendon of the sternocleidomastoid muscle is attached to the anterior surface of the sternoclavicular joint. Detach the tendon and reflect the sternocleidomastoid muscle superiorly.
3. Identify the **anterior sternoclavicular ligament**, which connects the sternum to the clavicle.
4. Use blunt dissection to clean the **costoclavicular ligament**, which runs obliquely from the first costal cartilage to the inferior surface of the clavicle near its medial end.
5. Use a scalpel to remove the anterior sternoclavicular ligament. Within the joint cavity, observe the **articular disc**. Inferiorly, the articular disc is attached to the first costal cartilage. Superiorly, the articular disc is attached to the clavicle. Observe that the articular disc is attached in such a manner that it resists medial displacement of the clavicle.
6. Palpate the movements of the sternoclavicular joint on yourself. Place your left hand on your right sternoclavicular joint and circumduct your right upper limb through a large circle. Observe that the sternoclavicular joint allows a limited amount of movement in every direction.

ACROMIOCLAVICULAR JOINT [G 510, 512; N 406; R 366; C 72]

1. Review the bony features that are relevant to the **acromioclavicular joint**: **acromion**, **coracoid process of the scapula**, and **lateral end of the clavicle** (Fig. 2.28).
2. Detach the trapezius muscle from the lateral end of the clavicle. Detach the coracobrachialis and pectoralis minor muscles from the coracoid process. The acromioclavicular joint is now exposed. The acromioclavicular joint is a plane synovial joint between the acromion and the distal end of the clavicle.
3. Identify the **coracoclavicular ligament**, which supports the acromioclavicular joint. Use a probe to clean the ligament. Identify its two parts: **conoid ligament** and **trapezoid ligament**.
4. Open the acromioclavicular joint by completely removing the joint capsule. Separate the acromion from the lateral end of the clavicle.
5. Note the shape of the articulating surfaces. The angle of the articulating surfaces causes the acromion to move inferior to the distal end of the clavicle when the acromion is forced medially. The conoid and trapezoid ligaments prevent the acromion from moving inferiorly relative to the clavicle, strengthening the joint.

GLENOHUMERAL JOINT [G 510, 511; N 406; R 366; C 71-73]

The **glenohumeral joint** (**shoulder joint**) is a ball-and-socket synovial joint with a wide range of motion. The shoulder joint has a greater degree of movement than any other joint in the body. This is because of the small area of contact between the head of the humerus and the glenoid fossa of the scapula and the loose joint capsule. Stability of

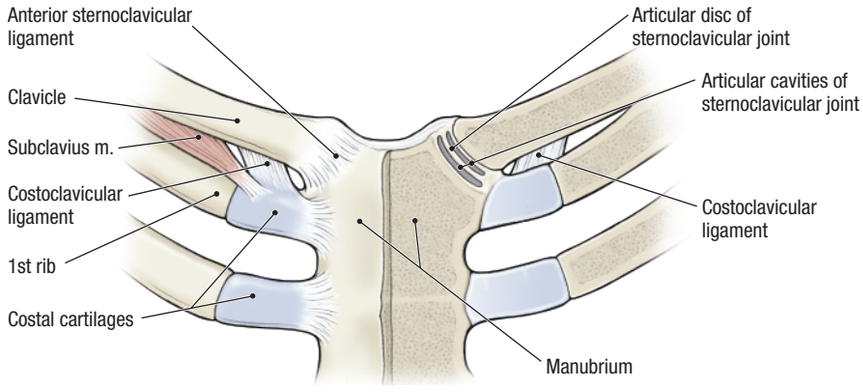

Figure 2.27. Sternoclavicular joint.

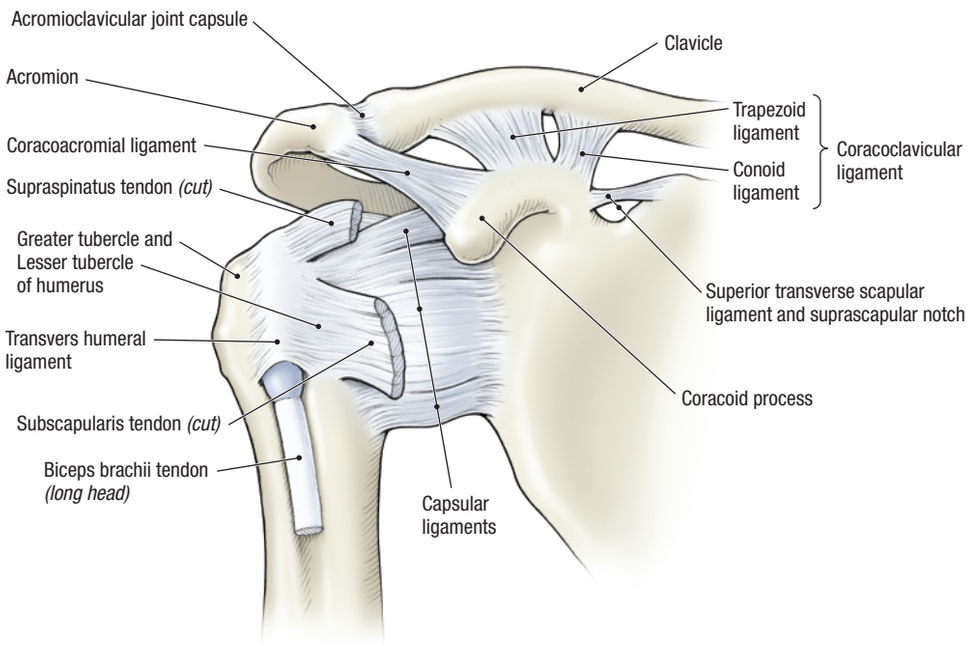

Figure 2.28. Acromioclavicular joint and anterior aspect of glenohumeral joint.

the shoulder joint depends on the function of the muscles of the rotator cuff.

1. Place the cadaver in the supine position.
2. Review the bony features pertinent to dissection of the **glenohumeral joint** (Fig. 2.29):
   - **Glenoid fossa of the scapula**
   - **Head of the humerus**
   - **Anatomical neck of the humerus**
3. To expose the **capsule of the glenohumeral joint**, the muscles and tendons that span the joint must be removed. Review the proximal attachment and distal attachment of each muscle as you remove it.
4. Remove the coracobrachialis muscle and the short head of the biceps brachii muscle. Leave the subscapularis muscle intact.
5. Place the cadaver in the prone position. Observe that the tendons of the supraspinatus, infraspinatus, and teres minor muscles blend with the joint capsule. Remove these tendons.
6. Remove the long head of the triceps brachii muscle
7. The posterior surface of the **joint capsule** is now exposed. Verify that the joint capsule is attached to the anatomical neck of the humerus.
8. Use a scalpel to open the posterior surface of the joint capsule (Fig. 2.29).
9. Use a saw or a chisel to remove the head of the humerus at the anatomical neck.
10. Use a probe to explore the **glenoid cavity**. Identify the **glenoid labrum** and attempt to demonstrate the three **glenohumeral ligaments**, which strengthen the anterior wall of the fibrous capsule (Fig. 2.29).
11. Observe that the **tendon of the long head of the biceps brachii muscle** passes through the glenoid cavity and is attached to the supraglenoid tubercle.
12. Place the cadaver into the supine position. Define and clean the **coracoacromial ligament**, which spans from the coracoid process to the acromion. The coracoacromial ligament, the acromion, and the coracoid process prevent superior displacement of the head of the humerus.

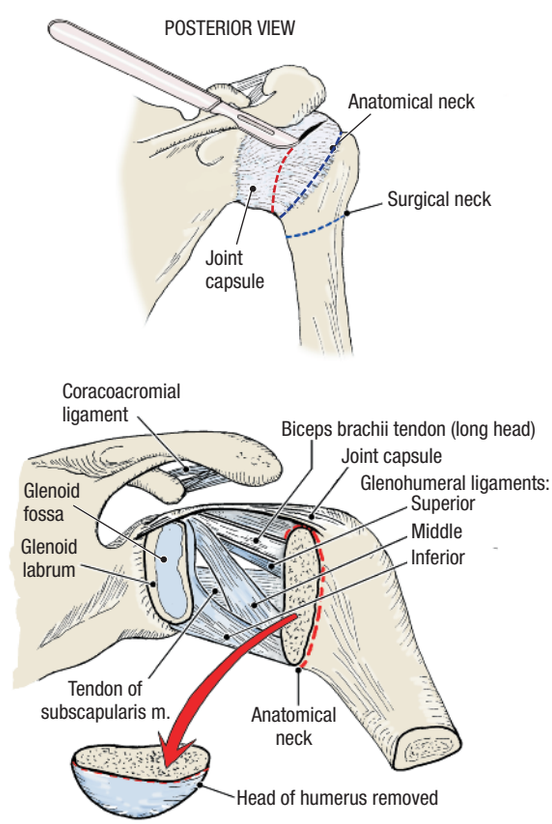

Figure 2.29. How to open the glenohumeral joint capsule and remove the head of the humerus.

13. Use the dissected specimen to perform the movements of the glenohumeral joint: Flexion, extension, abduction, adduction, and circumduction. Note that this freedom of motion is obtained at the loss of joint stability.

ELBOW JOINT AND PROXIMAL RADIOULNAR JOINT [G 526, 527; N 419, 421; R 367; C 80, 81]

1. Review the bony features of the elbow region (Fig. 2.30).
2. Use an articulated skeleton to verify that the elbow joint consists of two parts:
   - A **hinge joint** between the trochlea of the humerus and the trochlear notch of the ulna.
   - A **gliding joint** between the capitulum of the humerus and the head of the radius.
3. Remove the brachialis muscle from the anterior surface of the joint capsule.
4. Detach the triceps brachii tendon from the olecranon and the posterior surface of the joint capsule.
5. Remove the superficial flexor muscles of the forearm from their attachment to the medial epicondyle. Review the common flexor tendon and the five muscles that attach to it.
6. Identify the **ulnar collateral ligament** on the medial side of the elbow joint (Fig. 2.30). Observe that it consists of a strong anterior cord and a fan-like posterior portion.
7. Remove the superficial extensor muscles of the forearm from their attachment to the lateral epicondyle of the humerus. Review the common extensor tendon and the muscles that attach to it.
8. Remove the supinator muscle.
9. Identify the **radial collateral ligament**. It fans out from the lateral epicondyle of the humerus to the radius and anular ligament.
10. The **proximal radioulnar joint** is a pivot joint that occurs between the head of the radius and the radial notch of the ulna. The **anular ligament** and the radial notch of the ulna completely encircle the head of the radius (Fig. 2.30). Note that the radius can freely rotate in the anular ligament. Place the hand of the cadaver specimen into the pronated position. Now, pull on the biceps brachii tendon. Note the strong supinating action of the biceps brachii muscle.
11. Open the elbow joint by making a transverse cut through the anterior surface of the joint capsule between the ulnar collateral ligament and the radial collateral ligament.
12. Use a probe to explore the extent of the **synovial cavity**. Observe the smooth articular surfaces of the humerus, ulna, and radius.
13. Use the dissected specimen to perform the movements of the elbow joint: flexion and extension. Observe the joint surfaces and the collateral ligaments during these movements.

INTERMEDIATE RADIOULNAR JOINT [G 531; N 422; R 368; C 85]

1. The radius and ulna are joined throughout their length by the **interosseous membrane**. Use an illustration to study this joint.

DISTAL RADIOULNAR JOINT [G 570, 571; N 438; C 85]

1. The distal radioulnar joint is the pivot joint that occurs between the head of the ulna and the ulnar notch of the radius (Fig. 2.31).
2. Remove all tendons and soft tissue structures that cross the wrist. Review the distal attachment of each tendon and the action of each muscle.
3. Note that the anterior and posterior surfaces of the wrist joint are reinforced by **radiocarpal ligaments**.

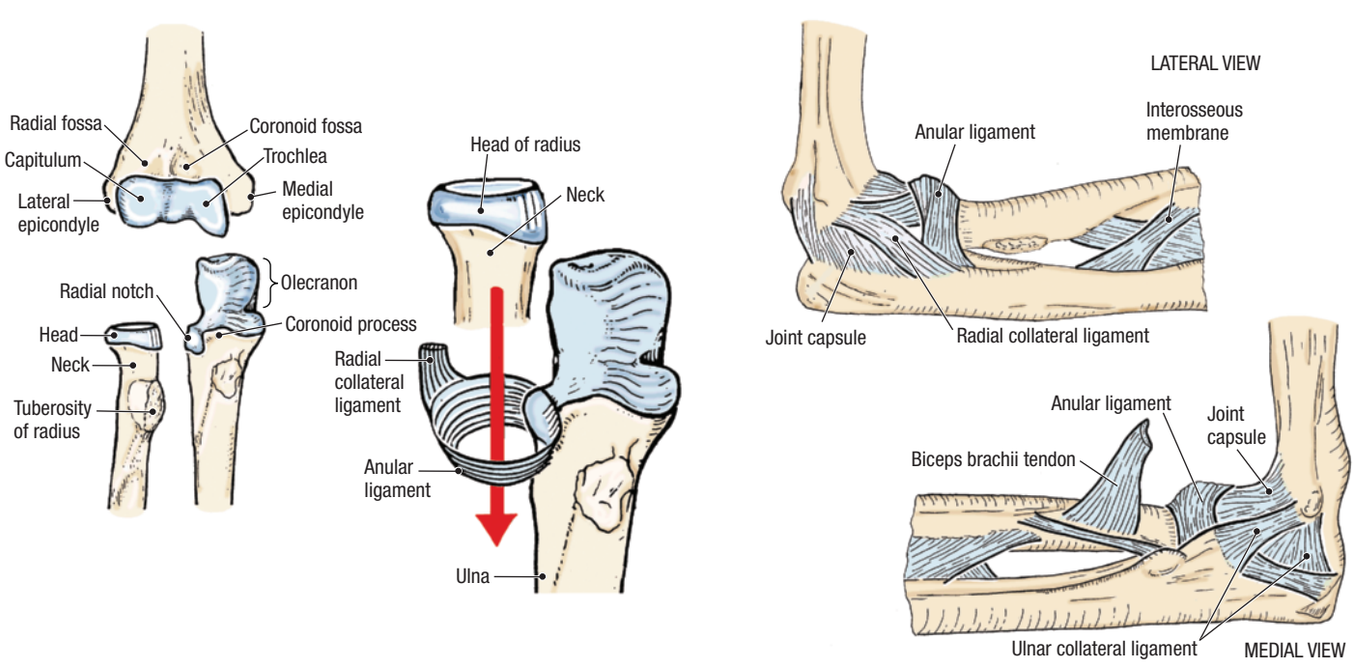

Figure 2.30. Elbow joint.

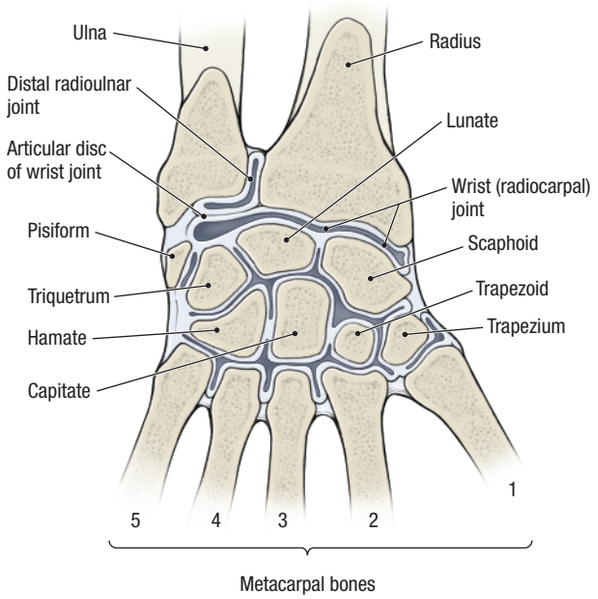

Figure 2.31. Distal radioulnar and wrist joints.

4. To open the distal radioulnar joint, extend the hand. On the anterior surface of the joint capsule, cut transversely through the radiocarpal ligaments. This cut should be made proximal to the flexor retinaculum and carpal tunnel. Leave the hand attached to the forearm by the posterior part of the joint capsule.
5. Use a probe to explore the articulation between the radius and the ulna. Note that the distal radioulnar joint contains an **articular disc**. Verify that the articular disc holds the distal ends of the radius and the ulna together.

WRIST JOINT [G 570, 572; N 437, 438; R 368, 369; C 84]

1. The **wrist joint (radiocarpal joint)** is the articulation between the distal end of the **radius** and the proximal **carpal bones** (Fig. 2.31). Note that the distal end of the radius articulates with only two carpal bones: **scaphoid** and **lunate**.
2. Identify the smooth proximal surfaces of the **scaphoid**, **lunate**, and **triquetrum**. Study the corresponding **articular surface of the radius.** Notice that the **scaphoid** and **lunate** bones must transmit forces from the hand to the forearm. Therefore, these carpal bones are the ones most commonly fractured in a fall on the outstretched hand.
3. Once again, identify the articular disc. The articular disc articulates with the triquetrum when the hand is adducted.
4. Use the dissected specimen to perform the movements of the wrist joint: flexion, extension, adduction, abduction, and circumduction. Observe the articular surfaces during these movements.

METACARPOPHALANGEAL JOINTS [G 575; N 441; R 369; C 85]

1. Dissect digit 3 as a representative example.
2. Remove the tendons of the flexor digitorum superficialis and flexor digitorum profundus muscles. Note their attachments on the phalanges.
3. Remove the interosseous muscles and the extensor expansion to expose the metacarpophalangeal joint capsule.
4. Clean the collateral ligaments (Fig. 2.32). Move the digit to confirm that the ligaments are slack during extension and taut during flexion. Therefore, the digits cannot be spread (abducted) unless they are extended.
5. Use the dissected specimen to perform the movements of the digit at the metacarpophalangeal joint: flexion, extension, abduction, and adduction. Confirm that the metacarpophalangeal joints are condyloid joints.

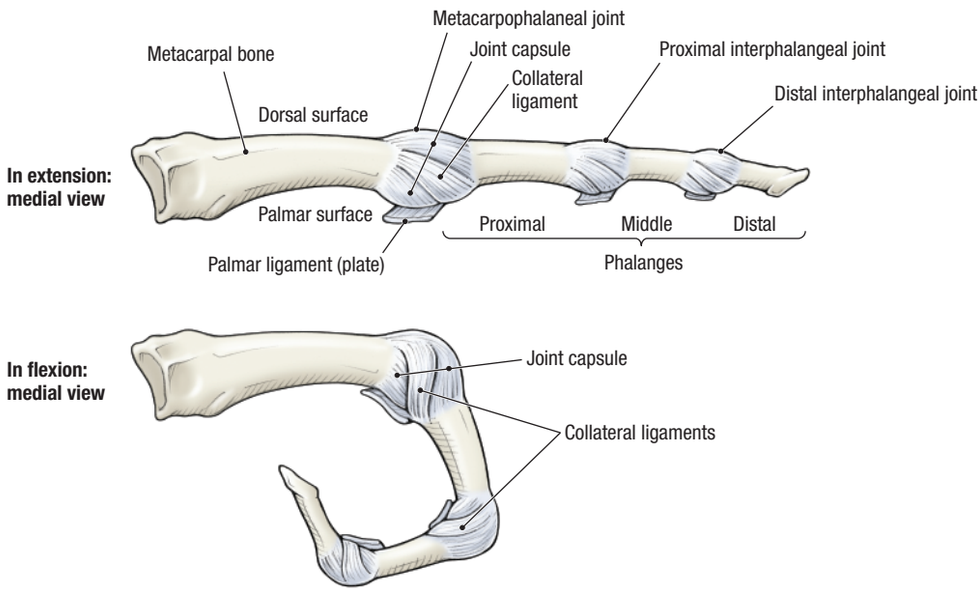

Figure 2.32. Metacarpophalangeal and interphalangeal joints.

INTERPHALANGEAL JOINTS [G 575; N 441; R 369; C 85]

1. Clean the collateral ligaments of the interphalangeal joints of digit 3 (Fig. 2.32).
2. Use a probe to explore the synovial cavity of one interphalangeal joint. Inspect the articular surfaces that are covered with smooth cartilage.
3. Use the dissected specimen to perform flexion and extension of the interphalangeal joint and confirm that the collateral ligaments limit the range of motion. Confirm that the interphalangeal joints are hinge joints.

CHAPTER 3

THE THORAX

The main function of the thorax is to house and protect the heart and lungs. The protective function of the thoracic wall is combined with mobility to accommodate volume changes during respiration. These two dissimilar functions, protection and flexibility, are accomplished by the alternating arrangement of the ribs and intercostal muscles.

The superficial fascia of the thorax contains the usual elements that are common to superficial fascia in all body regions: blood vessels, lymph vessels, cutaneous nerves, and sweat glands. In addition, the superficial fascia of the anterior thoracic wall in the female contains the mammary glands, which are highly specialized organs unique to the superficial fascia of the thorax.

SURFACE ANATOMY [G 2; N 174; C 2]

The surface anatomy of the thorax can be studied on a living subject or on the cadaver. Turn the cadaver to the supine position and palpate the following structures (Fig. 3.01):

- **Clavicle**
- **Acromion of the scapula**
- **Jugular notch (suprasternal notch)**
- **Manubrium**

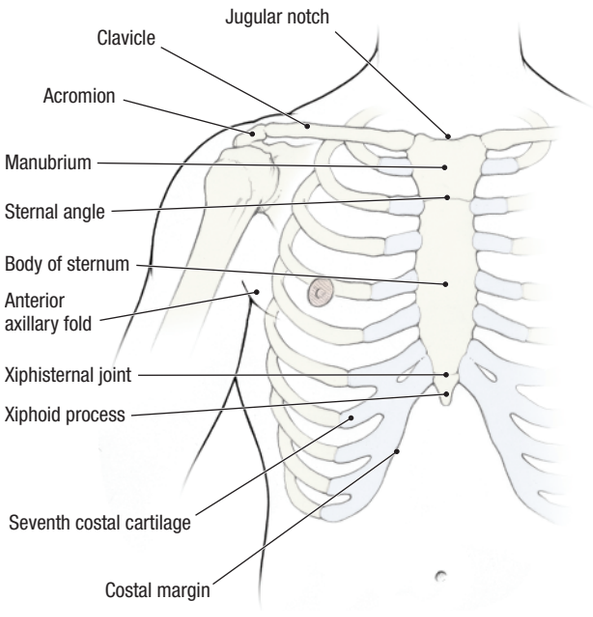

Figure 3.01. Surface anatomy of the anterior thoracic wall.

KEY TO REFERENCES
G = Grant's Atlas, 11th ed., page number
N = Netter's Atlas, 3rd ed., plate number
R = Rohen's Color Atlas of Anatomy, 5th ed., page number
C = Clemente's Atlas, 4th ed., page number

- **Sternal angle**
- **Body of the sternum**
- **Xiphisternal junction**
- **Xiphoid process**
- **Seventh costal cartilage**
- **Costal margin**
- **Anterior axillary fold (lateral border of the pectoralis major muscle)**

SKELETON OF THE THORAX

If you have previously dissected the back, review the parts of a **thoracic vertebra**. If you have not dissected the back, you must study the vertebrae now. Turn to pages 4–6, complete that exercise, and return to this page.

Refer to a skeleton. Examine a **rib** from the mid-thorax level and identify (Fig. 3.02): [G 13; N 179; R 191; C 96]

- **Head**
- **Neck**
- **Tubercle**
- **Angle**
- **Shaft (body)**
- **Costal groove**

On an articulated skeleton, note the following features:

- The **first rib** is the highest, shortest, broadest, and most curved of the ribs.
- The **head** of a rib usually articulates with two vertebral bodies and their intervertebral disc (the 1st, 10th, 11th, and 12th ribs are exceptions to this rule). For example, the head of rib 5 articulates with vertebral bodies T4 and T5 (Fig. 3.03).
- The **tubercle** of a rib articulates with the costal facet on the transverse process of the thoracic vertebra of the same number (Fig. 3.03).
- A **costal cartilage** is attached to the anterior end of each rib. Ribs are classified by the distal articulation of their costal cartilage:

True ribs (ribs 1–7) – costal cartilage is attached directly to the sternum.

False ribs (ribs 8–10) – costal cartilage is attached to the costal cartilage of the rib above.

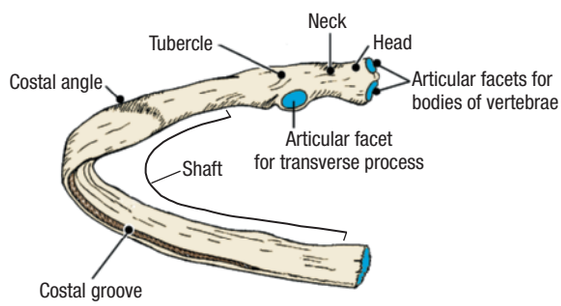

Figure 3.02. Typical left rib, posterior view.

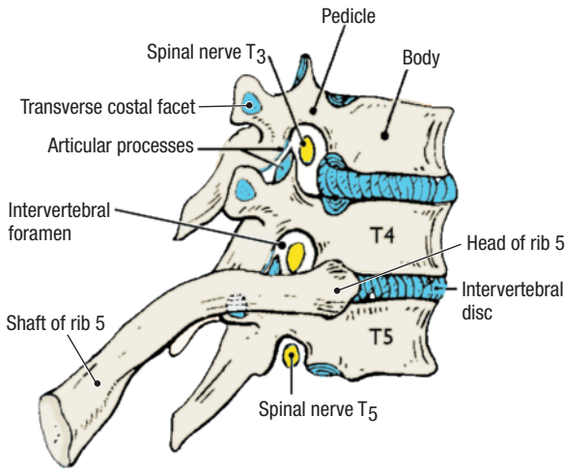

Figure 3.03. Part of the thoracic vertebral column.

Floating ribs (ribs 11 and 12) – costal cartilage is not attached to a skeletal element but ends in the abdominal musculature.

Examine the **sternum** and identify (Fig. 3.04): **[G 12; N 179; R 188; C 95]**

- **Jugular notch** (suprasternal notch)
- **Manubrium** (L. *manubrium*, handle)
- **Sternal angle** (at the level of the T4/T5 intervertebral disc; attachment of the second costal cartilage)
- **Body**
- **Xiphoid process** (Gr. *xiphos*, sword)

Examine a **scapula** and identify (Fig. 3.04): **[G 458; N 178; R 185; C 70]**

- **Acromion**
- **Coracoid process**

Observe that the medial end of the **clavicle** articulates with the manubrium of the sternum (**sternoclavicular joint**) and the lateral end of the clavicle articulates with the acromion of the scapula (**acromioclavicular joint**) (Fig. 3.04).

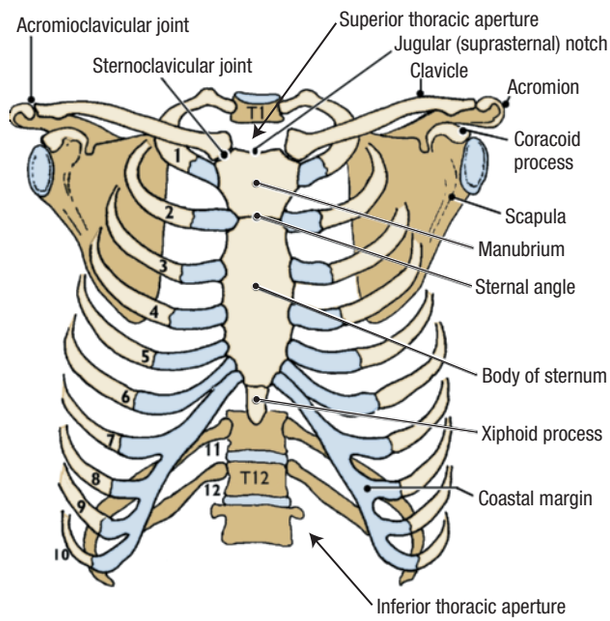

Figure 3.04. Skeleton of the thoracic region.

PECTORAL REGION

Before you dissect . . .

The **pectoral region** (L., *pectus*, chest) covers the anterior thoracic wall and part of the lateral thoracic wall. The order of dissection will be as follows: the skin will be removed from the thoracic wall, and the breast will be dissected in female cadavers. The superficial fascia will be removed.

Dissection Instructions

SKIN INCISIONS

1. Place the cadaver in the supine position.
2. Refer to Figure 3.05. If the back has been dissected previously, some of these incisions have already been made. Before cutting, realize that the skin is thin on the anterior thoracic wall.
3. Make a midline skin incision from the jugular notch (A) to the xiphisternal junction (C).
4. Make a skin incision from the jugular notch (A) along the clavicle to the acromion (B), continuing to a point that is approximately halfway down the arm (F).
5. At point F, make an incision around the anterior and posterior surfaces of the arm, meeting on the medial side (G).
6. Make an incision from the xiphoid process (C) along the costal margin to the midaxillary line (V).
7. Make an incision that begins at G on the medial surface of the arm and extends superiorly to the axilla. Extend this incision inferiorly along the lateral surface of the trunk to V.
8. Make a transverse skin incision from the middle of the manubrium to the midaxillary line, passing around the nipple.
9. Make a transverse skin incision from the xiphisternal junction (C) to the midaxillary line.
10. Remove the skin from medial to lateral. Detach the skin along the midaxillary line and place it in the tissue container.

BREAST [G 4, 5; N 175; R 280; C 5]

The breast is dissected in female cadavers only. Students with male cadavers must observe at another dissection table. Because of the advanced age of some cadavers, it

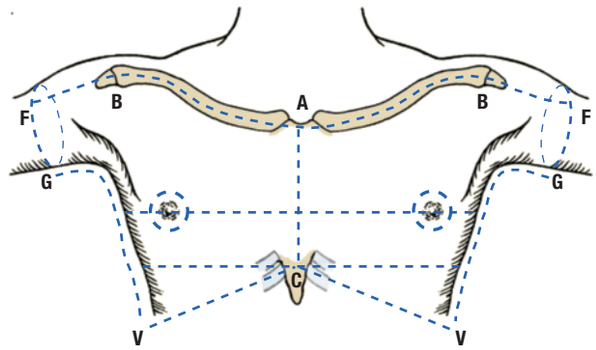

Figure 3.05. Skin incisions.

may be difficult to dissect and identify all of the structures listed. Expect the lobes of the gland to be replaced by fat with advanced age.

The **breast** extends from the lateral border of the sternum to the midaxillary line, and from rib 2 to rib 6. The mammary gland is a modified sweat gland that is contained within the superficial fascia of the breast (Fig. 3.06). The breast is positioned anterior to the **pectoral fascia** (the deep fascia of the pectoralis major muscle). The pectoral fascia is attached to the overlying skin by the **suspensory ligaments of the breast** that pass between the lobes of the mammary gland.

1. Identify the **areola** and the **nipple** (Fig. 3.06).
2. Use the handle of a forceps to scoop the fat out of several compartments between **suspensory ligaments**. These areas between suspensory ligaments once contained lobes of functional glandular tissue.
3. Make a parasagittal (superior to inferior) cut through the nipple that divides the breast into a medial half and a lateral half (Fig. 3.06).
4. On the cut edge of the breast, use a probe to dissect through the fat deep to the nipple. Confine your search area to within 3 cm deep to the areola. Find and clean one of the 15 to 20 **lactiferous ducts** that converge on the nipple. Identify the **lactiferous sinus**, which is an expanded part of the lactiferous duct located deep to the nipple.
5. Trace one lactiferous duct to the nipple and attempt to identify its opening.
6. Use an illustration to study the **lymphatic drainage of the mammary gland**. **[G 9; N 177; R 280; C 6]**
7. Insert your fingers behind the breast and open the **retromammary space**. Note that the normal breast can be easily separated from the underlying deep fascia of the pectoralis major muscle.
8. Remove the breast from the anterior surface of the pectoralis major muscle with the aid of a scalpel.
9. Store the breast in a plastic bag.

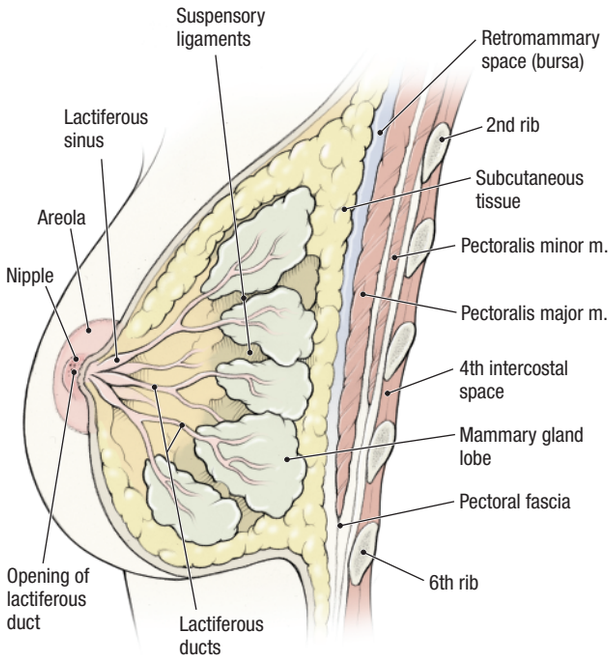

Figure 3.06. Breast in sagittal section.

CLINICAL CORRELATION

Breast

For descriptive purposes, clinicians divide the breast into four quadrants. The superolateral (upper outer) quadrant contains a large amount of glandular tissue and is a common site for breast cancers to develop. From this quadrant, an "axillary tail" often extends into the axilla.

In advanced stages of breast cancer, the tumor may invade the underlying pectoralis major muscle and its fascia. When this happens, the tumor and breast become fused to the chest wall, a condition that can be detected by palpation during a physical examination. As the breast tumor enlarges, it places traction on the suspensory ligaments, resulting in dimpling of the skin overlying the tumor.

SUPERFICIAL FASCIA

1. Dissection of the superficial fascia must be performed on both male and female cadavers.
2. The **platysma muscle** is a muscle of facial expression that may extend into the superficial fascia of the superior thorax. It is very thin, but broad. If the platysma muscle is present in the thorax, dissect it from the superficial fascia that lies deep to it and reflect it superiorly. Do not extend the dissection field superior to the clavicles.
3. Make a vertical cut through the superficial fascia in the midline of the sternum. Make additional cuts through the superficial fascia corresponding to skin incisions A to F, C to V, and G to V (Fig. 3.05).
4. Use blunt dissection to remove the superficial fascia, proceeding from medial to lateral.
5. Study an illustration of the **cutaneous branches of a typical spinal nerve**. The **anterior cutaneous branches** are small and emerge from the intercostal space lateral to the border of the sternum. Do not attempt to find them. **[G 20; N 187; R 204; C 7]**
6. As you peel back the superficial fascia, identify an intercostal space by palpation. Palpate the **lateral cutaneous branches** of the intercostal nerves where they leave the intercostal space and enter the superficial fascia. Identify one lateral cutaneous branch (from intercostal space 4, 5, or 6) while the superficial fascia is being removed. Trace its **anterior and posterior branches** for a short distance and preserve them.
7. Detach the superficial fascia along the midaxillary line and place it in the tissue container.

After you dissect . . .

Review the location and parts of the breast. Use an illustration to review the vascular supply to the breast. Discuss its pattern of lymphatic drainage and identify by name the lymph node groups that are involved. Use an illustration of the branching pattern of a typical spinal nerve to review the innervation of the anterior thoracic wall and breast.

MUSCLES OF THE PECTORAL REGION

Before you dissect . . .

The muscles of the pectoral region attach the upper limb to the thoracic skeleton. Therefore, they are also known as the **anterior thoracoappendicular group of muscles**. The pectoral muscles are positioned immediately deep to the superficial fascia (deep to the breast).

The dissection will proceed as follows: the pectoralis major muscle will be studied and reflected. The pectoralis minor muscle and clavipectoral fascia will be studied. The pectoralis minor muscle will be reflected, and the branches of the thoraco-acromial artery will be dissected.

Dissection Instructions

1. Clean the superficial surface of the **pectoralis major muscle**, using your fingers to define its borders (Fig. 3.07). Study an illustration and note that the deep fascia on the surface of the pectoralis major muscle is called **pectoral fascia** and that it is continuous with the **axillary fascia** that forms the floor of the axilla. **[G 478; N 407; R 394; C 11]**
2. Identify the two heads of the pectoralis major muscle: **clavicular head** and **sternocostal head** (Fig. 3.07). Observe that the juncture of these two heads is at the sternoclavicular joint.
3. Use your fingers to trace the tendon of the pectoralis major muscle to its distal attachment on the humerus. The pectoralis major muscle flexes, adducts, and medially rotates the humerus.
4. Between the clavicular head of the pectoralis major muscle and the adjacent deltoid muscle, use blunt dissection to define the borders of the **deltopectoral triangle** and find the **cephalic vein**. Preserve the cephalic vein in subsequent steps of this dissection.
5. Relax the sternal head of the pectoralis major muscle by flexing and adducting the arm. Gently insert your fingers posterior to the inferior border of the pectoralis major muscle. Create a space between the posterior surface of the pectoralis major and the **clavipectoral fascia**. Push your fingers superiorly to open this space.
6. Use scissors to detach the sternal head of the pectoralis major muscle from its attachment to the sternum (dashed line, Fig. 3.07).
7. Palpate the deep surface of the pectoralis major muscle to locate the **medial and lateral pectoral nerves and vessels**. Preserve these nerves and vessels.
8. Use scissors to cut the clavicular head of the pectoralis major muscle close to the clavicle (Fig. 3.07). Preserve the cephalic vein. Note that the **lateral pectoral nerve** and the **pectoral branch of the thoraco-acromial artery** enter the deep surface of the clavicular head.
9. Reflect the pectoralis major muscle laterally. If the nerves and vessels of the pectoralis major muscle prevent reflection, cut a small piece (1 cm^2) out of the muscle and leave it attached to the nerves and blood vessels.
10. Deep to the pectoralis major muscle are the **clavipectoral fascia** and **pectoralis minor muscle**. **[G 480; N 411; R 395]**
11. Note that the **medial pectoral nerve** pierces the **pectoralis minor muscle**, then enters the sternal head of the pectoralis major muscle.
12. Read a description of the **clavipectoral fascia** and understand that it is attached to the clavicle. It passes both superficial and deep to the subclavius muscle and

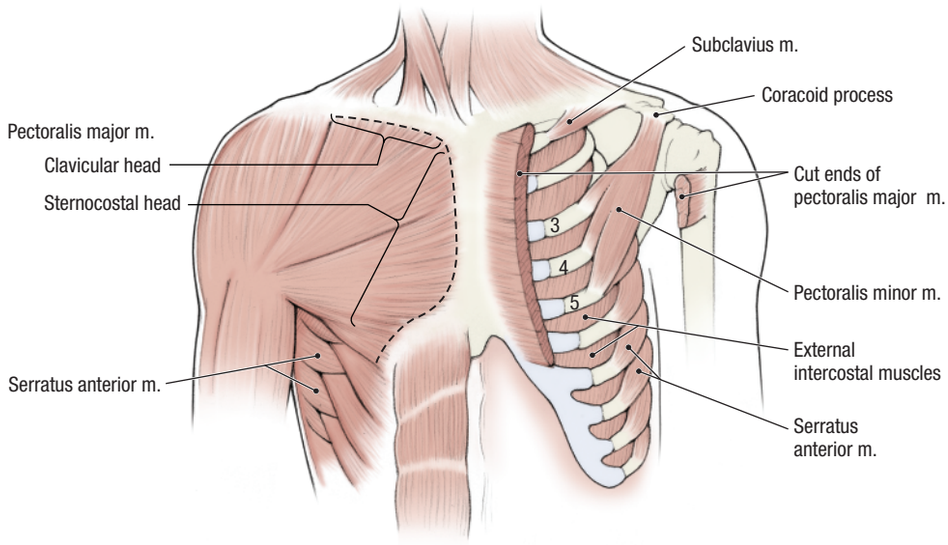

Figure 3.07. Cuts for reflection of the pectoralis major and pectoralis minor muscles.

the pectoralis minor muscle. The clavipectoral fascia is attached to the axillary fascia inferiorly.

13. Identify the **subclavius muscle**, which is located inferior to the clavicle (Fig. 3.07). The subclavius muscle, which is attached to the clavicle and the first rib, depresses the clavicle.
14. Clean the **cephalic vein** as it crosses the anterior surface of the pectoralis minor tendon. The cephalic vein passes through the **costocoracoid membrane** (part of the clavipectoral fascia) medial to the pectoralis minor tendon. The **thoraco-acromial artery** and the **lateral pectoral nerve** also pass through the costocoracoid membrane.
15. Use scissors to detach the pectoralis minor muscle from its proximal attachments on ribs 3-5 (Fig. 3.07).
16. Reflect the pectoralis minor muscle superiorly. Leave the muscle attached to the coracoid process of the scapula. **[G 480; N 410; R 398; C 13]**
17. Clean and define the branches of the thoraco-acromial artery (Fig. 3.08):
    - **Acromial branch –** passes laterally across the coracoid process to the acromion.
    - **Deltoid branch –** courses laterally in the **deltopectoral groove** between the deltoid muscle and pectoralis major muscle. The deltoid branch accompanies the cephalic vein.
    - **Pectoral branch –** passes between and supplies the pectoralis major muscle and the pectoralis minor muscle.
    - **Clavicular branch –** courses superiorly and medially to supply the subclavius muscle.
18. Along the lateral border of the pectoralis minor muscle, identify the origin of the **lateral thoracic artery** (Fig. 3.08). Do not follow the lateral thoracic artery at this time.
19. Identify the **serratus anterior muscle** (Fig. 3.07). Note its extensive proximal attachment on the upper eight ribs. The distal attachment of the serratus anterior muscle is the deep surface of the scapula along the entire length of its medial border. You cannot see the distal attachment at this time.
20. Do not disturb the contents of the axilla.

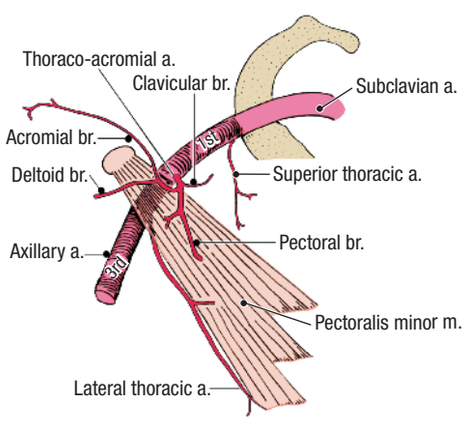

Figure 3.08. Blood supply to the pectoral region.

After you dissect . . .

Replace the pectoral muscles into their correct anatomical positions. Review the attachments of the pectoralis major and pectoralis minor muscles. Review their actions, innervations, and blood supply. Review the relationship of the clavipectoral fascia to the muscles, vessels, and nerves of this region. Name all branches of the thoraco-acromial artery and the structures supplied by each branch. Be sure that you understand the role played by the clavipectoral fascia in supporting the floor of the axilla.

INTERCOSTAL SPACE AND INTERCOSTAL MUSCLES

Before you dissect . . .

The interval between adjacent ribs is called the **intercostal space**. The intercostal space is only a space in a skeleton, because three muscles fill the intercostal space in the living body and the cadaver. From superficial to deep, the three muscles are the **external intercostal muscle**, the **internal intercostal muscle**, and the **innermost intercostal muscle**. There are 11 intercostal spaces on each side of the thorax. They are numbered corresponding to the rib above.

The order of dissection will be as follows: the external intercostal muscle will be studied in one intercostal space and reflected. The internal intercostal muscle will be studied and reflected. Branches of intercostal nerves and blood vessels will be identified. The innermost intercostal muscle will be identified.

Dissection Instructions

1. Detach the **serratus anterior muscle** from its proximal attachments on ribs 1 to 8 and reflect it laterally.
2. Palpate the ribs and the intercostal spaces. Begin at the level of the sternal angle (attachment of the second costal cartilage) and identify each intercostal space by number.
3. Dissect intercostal space 4 (the space between ribs 4 and 5).
4. Identify the **external intercostal muscle** (Fig. 3.09). The external intercostal muscle attaches to the inferior border of the rib above and the superior border of the rib below. The external intercostal muscle elevates the rib below. Note that the fibers of the external intercostal muscles pass diagonally toward the anterior midline as they descend. **[G 19; N 185; R 195; C 93]**
5. Identify the **external intercostal membrane**, which is located at the anterior end of the intercostal space between the **costal cartilages**. Note that the fibers of the external intercostal muscle end at the lateral edge of the external intercostal membrane.
6. Insert a probe deep to the external intercostal membrane just lateral to the border of the sternum in the fourth intercostal space. Push the probe laterally and note that it passes posterior to the external intercostal muscle.

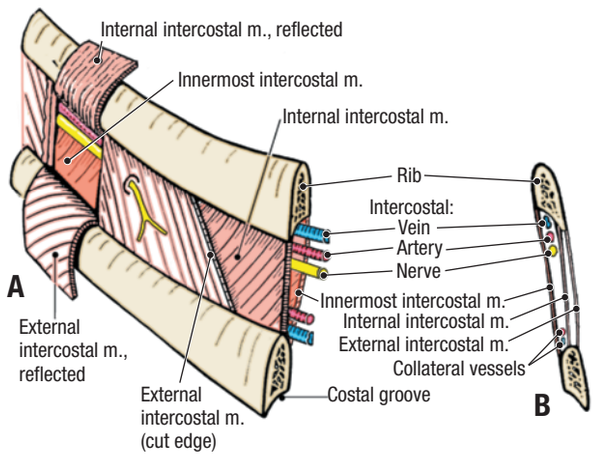

Figure 3.09. Structures in the intercostal space. **A.** Anterior view. **B.** Coronal section at the midaxillary line.

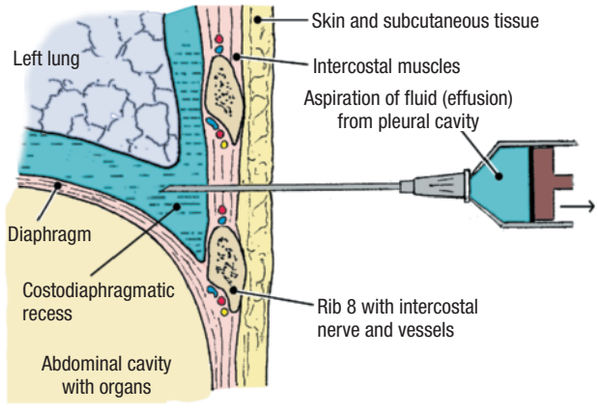

Figure 3.10. Anatomical relationships associated with a pleural tap.

7. With the probe as a guide, use scissors to cut the external intercostal muscle from the rib above and reflect it inferiorly. Continue the cut laterally to the midaxillary line.
8. Identify the **internal intercostal muscle**. The internal intercostal muscle attaches to the superior border of the rib below and the inferior border of the rib above. The internal intercostal muscle depresses the rib above. Note that the fiber direction of the internal intercostal muscle is perpendicular to the fiber direction of the external intercostal muscle (Fig. 3.09).
9. Begin at the midaxillary line and detach the internal intercostal muscle from its inferior attachment on rib 5. Reflect it superiorly. Continue to detach the internal intercostal muscle as far as the lateral border of the sternum.
10. Identify the fourth **intercostal nerve** and the fourth **posterior intercostal artery and vein** inferior to rib 4. The intercostal nerve and vessels run in the plane between the **internal intercostal muscle** and **innermost intercostal muscle** (Fig. 3.09). The **innermost intercostal muscle** has the same fiber direction, attachments, and action as the internal intercostal muscle, but it does not extend as far anteriorly in the intercostal space. **[G 20; N 187; R 204; C 7]**
11. The intercostal nerve and vessels supply the intercostal muscles, the skin of the thoracic wall, and the parietal pleura. Use an illustration to study their course and distribution.
12. The anterior end of the intercostal space is supplied by **anterior intercostal branches** of the **internal thoracic artery**. The internal thoracic artery runs a vertical course just lateral to the border of the sternum and crosses the deep surfaces of the costal cartilages. **[G 22; N 183; R 199; C 92]**

CLINICAL CORRELATION

Pleural Tap (Thoracocentesis)

The aspiration of pathological material from the pleural cavity (serous fluid, fluid mixed with tumor cells, blood, pus, etc.) may be performed through the intercostal space. The pleural tap is performed in the midaxillary line or slightly posterior to it. Usually, intercostal space 6, 7, or 8 is selected for the puncture to avoid penetrating abdominal viscera. A large-bore needle is inserted low in the intercostal space to avoid injury to the intercostal nerve and vessels (Fig. 3.10).

After you dissect . . .

Replace the internal and external intercostal muscles in their correct anatomical positions. Review the muscles that lie in the intercostal space. Review their actions. Understand how they assist respiration by elevating and depressing the ribs. Use an illustration and your dissected specimen to review the origin, course, and branches of the posterior intercostal artery and intercostal nerve. Consult a dermatome chart and compare the dermatome pattern to the distribution of the intercostal nerves. **[G 331; N 157; C 7]**

REMOVAL OF THE ANTERIOR THORACIC WALL

Before you dissect . . .

To open the thoracic cavity, the anterior thoracic wall must be reflected. The goal of this dissection is to reflect the thoracic wall with the underlying **costal parietal pleura**. The area to be reflected includes the anterior and lateral portions of ribs 1 through 5, the contents of the intercostal spaces, and the sternum.

The order of dissection will be as follows: the ribs and contents of the intercostal spaces will be cut at the midaxillary line. The clavicles will be cut. The costal cartilages and sternum will be cut. The anterior thoracic wall will be reflected superiorly, using the muscles of the lower neck as a hinge. The neck muscles will remain intact and will not be detached from their sternal and clavicular attachments. The inner surface of the thoracic wall will be studied.

Dissection Instructions

1. Reflect the serratus anterior muscle laterally.
2. Cut both clavicles at their mid-length using a saw (Fig 3.11, cuts 1 and 2).
3. Make a transverse cut across the sternum and costal cartilages at the level of intercostal space 5 (Fig. 3.11, cut 3). Allow the saw to pass through the bone and cartilage, but not the deeper tissues.
4. Use a saw or bone forceps to cut ribs 1 to 5 in the midaxillary line on both sides of the thorax.
5. With a scalpel, cut intercostal spaces 1 to 5 in the midaxillary line. Make the cut deep enough to cut the parietal pleura.
6. Use scissors to cut the intercostal muscles and underlying parietal pleura from the upper border of rib 6 on both sides of the thorax.
7. Gently, elevate the inferior end of the sternum with the attached portions of the severed ribs, and identify the **right and left internal thoracic vessels** (Fig. 3.11). Cut the internal thoracic vessels at the level of the fifth sternocostal joint and reflect them with the thoracic wall.
8. Reflect the anterior thoracic wall superiorly. Cut the parietal pleura with scissors where it reflects from the inner surface of the thoracic wall to the mediastinum. Leave the anterior thoracic wall attached to the muscles of the neck. **[G 23; N 184; R 196; C 100]**
9. On the internal surface of the anterior thoracic wall, identify the **costal parietal pleura**. Use blunt dissection to remove the parietal pleura from the inner surface of the anterior thoracic wall.
10. Identify the **transversus thoracis muscle**. Observe that the inferior attachment of the transversus thoracis muscle is on the sternum and its superior attachment is on costal cartilages 2 to 6. The transversus thoracis muscle depresses the ribs.
11. The **internal thoracic vessels** are located between the costal cartilages and the transversus thoracis muscle. Observe that the internal thoracic artery divides into the **superior epigastric artery** and the **musculophrenic artery**. Identify at least one of the **anterior intercostal branches** of the internal thoracic artery.

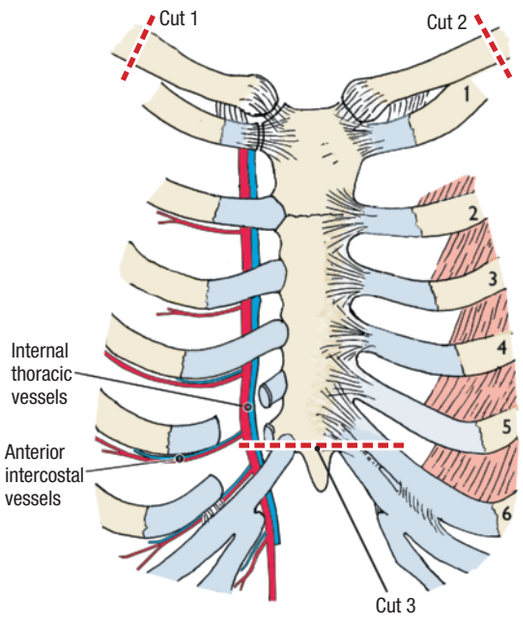

Figure 3.11. How to reflect the anterior thoracic wall.

After you dissect . . .

Replace the anterior thoracic wall in its correct anatomical position. Also replace the pectoralis minor muscle, making sure that its proximal attachments touch ribs 3, 4, and 5. Finally, replace the pectoralis major muscle in its original anatomical position. Review the attachments and the action of the pectoral muscles, the serratus anterior muscle, and the transversus thoracis muscle. Study the course of the internal thoracic artery from its origin to its bifurcation and name its branches.

CLINICAL CORRELATION

Anterior Thoracic Wall

The anterior and lateral approaches are the two most common surgical approaches to the contents of the thorax. In the anterior approach, the sternum is split vertically in the midline. This approach does not cross major vessels and allows good access to the heart. The incision through the sternum is closed with stainless steel wires. In the lateral approach, an intercostal space is incised to provide access to the lungs or to structures posterior to the heart.

PLEURAL CAVITIES

Before you dissect . . .

The thorax has two apertures (Fig. 3.04). The **superior thoracic aperture (thoracic inlet)** is relatively small and bounded by the manubrium of the sternum, the right and left first ribs, and the body of the first thoracic vertebra. Structures pass between the thorax, the neck, and the upper limb through the superior thoracic aperture (e.g., **trachea, esophagus, vagus nerves, thoracic duct, major blood vessels**).

The **inferior thoracic aperture** (**thoracic outlet**) is larger and bounded by the xiphisternal joint, the costal margin, ribs 11 and 12, and the body of vertebra T12. The **diaphragm** attaches to the structures that form the boundaries of the inferior thoracic aperture and separates the thoracic cavity from the abdominal cavity. Several large structures (e.g., **aorta**, **inferior vena cava**, **esophagus**) pass between the thorax and abdomen through openings in the diaphragm.

The thorax contains two **pleural cavities** (right and left) and the **mediastinum**. The two pleural cavities occupy the lateral parts of the thoracic cavity and each contains one **lung**. The mediastinum (L. *quod per medium stat*, that which stands in the middle) is the region between the two pleural cavities. It contains the **heart**, **aorta**, **trachea**, and **esophagus**. **[G 28; N 192; R 233; C 99]**

Each pleural cavity is lined by a serous membrane called the **parietal pleura** (Fig. 3.12). The parietal pleura has subdivisions that are regionally named:

- **Costal pleura—**lines the inner surface of the thoracic wall
- **Mediastinal pleura—**lines the mediastinum
- **Diaphragmatic pleura—**lines the superior surface of the diaphragm
- **Cervical pleura (cupula)—**extends superior to the first rib

The parietal pleura is sharply folded where the costal pleura meets the diaphragmatic pleura, and where the costal pleura meets the mediastinal pleura. The folds are called **lines of pleural reflection**. The lines of pleural reflection are acute, and the inner surfaces of the parietal pleurae are in contact with one another. The areas where parietal pleura contacts parietal pleura are called **pleural recesses**. The two **costomediastinal recesses** (left and right) occur posterior to the sternum where costal pleura meets mediastinal pleura. The two **costodiaphragmatic recesses** (left and right) are located at the most inferior limits of the parietal pleura (Fig. 3.12). During quiet inspiration, the inferior border of the lung does not extend into the costodiaphragmatic recess. **[G 28; N 192; R 255; C 101]**

The **endothoracic fascia** is a small amount of connective tissue between the thoracic wall and the costal parietal pleura. Endothoracic fascia provides a cleavage plane for surgical separation of the pleura from the thoracic wall.

Each lung is completely covered with **visceral pleura (pulmonary pleura)**. At the root of the lung, the visceral pleura becomes continuous with the mediastinal parietal pleura.

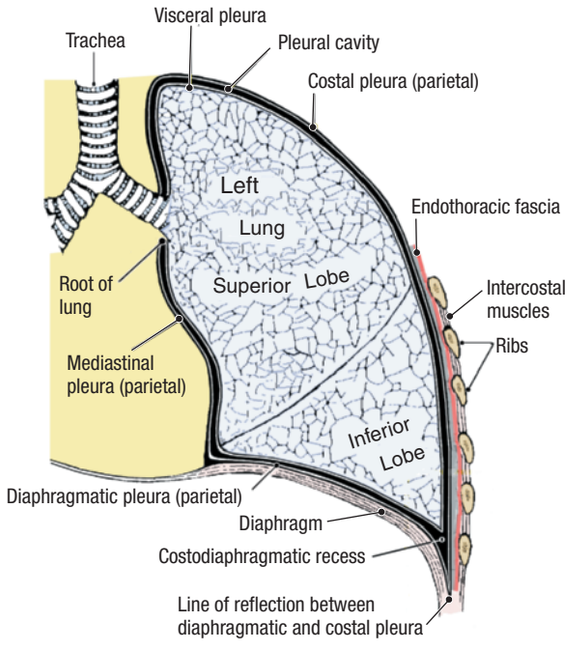

Figure 3.12. The pleurae and pleural cavity

Dissection Instructions

1. The **pleural cavity** is the space between the visceral pleura and the parietal pleura (Fig. 3.12). In the living body, the pleural cavity is a potential space and visceral pleura contacts parietal pleura.
2. Explore the right and left pleural cavities. *Caution: The ends of the ribs are sharp and can cut you.* To reduce the risk of injury, use a mallet or the side of the bone forceps to hit and blunt the ends of ribs 1 to 5. As an additional precaution, place paper towels over the cut ends of the ribs before you begin to palpate the pleural cavities.

CLINICAL CORRELATION

Pleural Cavity

Under pathological conditions, the potential space of the pleural cavity may become a real space. For example, if air enters the pleural cavity (pneumothorax), the lung collapses because of the elasticity of its tissue.

Excess fluid may accumulate in the pleural cavity, compress the lung, and produce breathing difficulties. The fluid could be serous fluid (plural effusion) or blood resulting from trauma (hemothorax).

3. Use paper towels or a large syringe to remove fluid that may have collected in the pleural cavity.
4. Identify the parts of the **parietal pleura**: **costal**, **diaphragmatic**, **mediastinal**, and **cervical**. Part of the costal pleura was removed with the anterior thoracic wall.
5. Place your fingers in the **costodiaphragmatic recess**. Follow it posteriorly and notice the acute angle that the diaphragm makes with the inner surface of the thoracic wall.
6. Place your hand between the lung and the mediastinum and palpate the root of the lung. At the root of the lung the mediastinal parietal pleura is continuous with the visceral pleura. Palpate the **pulmonary ligament**, which extends inferior to the root of the lung.
7. The root of the lung is attached to the mediastinum. All other parts of the lung should slide freely against the parietal pleura. Pleural adhesions may occur between visceral and parietal pleurae. Pleural adhesions are the result of disease processes, and you should use your fingers to break them.

After you dissect . . .

Replace the anterior thoracic wall in is correct anatomical position. Use an illustration and the dissected specimen to project the lines of pleural reflection to the anterior thoracic wall. Review the course of the intercostal nerves and understand that they are the source of somatic innervation (including pain fibers) to the costal parietal pleura.

LUNGS

Before you dissect . . .

The order of dissection will be as follows: the surface features and relationships of the lungs that can be seen from an anterior view will be studied with the lungs in the thorax. Then, the lungs will be removed and the study of surface features and relationships of the lungs will be completed. The hilum of the lung will be studied.

Dissection Instructions

LUNGS IN THE THORAX

1. Observe the lungs *in situ* (Fig. 3.13). **[G 25; N 194; R 258; C 101]**
2. Each lung has three surfaces: **costal, mediastinal**, and **diaphragmatic**. You can see only the costal surface with the lung *in situ*.
3. Observe the **oblique fissure** on both lungs. Replace the anterior thoracic wall and observe that the oblique fissure lies deep to the fifth rib laterally and that it is deep to the sixth costal cartilage anteriorly. Clinicians may refer to the oblique fissure as the **major fissure**.
4. Lift the anterior thoracic wall and identify the **horizontal fissure** on the right lung. Replace the anterior thoracic wall and observe that the horizontal fissure lies deep to the fourth rib and fourth costal cartilage. Clinicians may refer to the horizontal fissure as the **minor fissure** or **transverse fissure**.
5. Note that the right lung has three lobes (**superior**, **middle**, and **inferior**). The left lung has two lobes (**superior** and **inferior**).
6. Observe that the **apex** of the lung rises as high as the neck of the first rib, superior to the body of the first rib. Therefore, the apex of the lung lies superior to the plane of the superior thoracic aperture and is actually in the neck.
7. Identify the **pericardium** that occupies the midline between the lungs. The pericardium contains the heart.

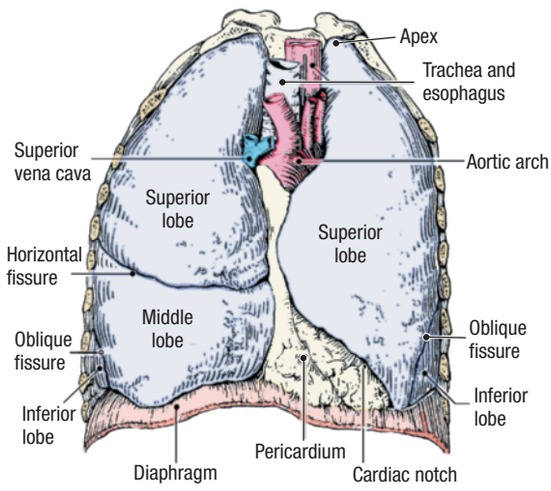

Figure 3.13. The lungs *in situ*.

8. Palpate the **root of the lung**. Feel the hard structures within the root of the lung. These are the pulmonary vessels, filled with clotted blood, and the main (primary) bronchus.
9. Observe that the **phrenic nerve** and **pericardiacophrenic vessels** pass anterior to the root of the lung and medial (deep) to the mediastinal pleura. Use an illustration to observe that the **vagus nerve** passes posterior to the root of the lung. **[G 78, 79; N 226, 227; R 270, 271; C 115, 117]**

REMOVAL OF THE LUNGS

1. Preserve the phrenic nerve, pericardiacophrenic vessels, and the vagus nerve during lung removal.
2. Place your hand into the pleural cavity between the lung and mediastinum. Retract the lung laterally, to stretch the root of the lung.
3. While retracting the lung, use scissors to transect the root of the lung halfway between the lung and the mediastinum. Take care not to cut into the mediastinum or the lung. Remove both lungs.
4. Compare the two lungs (Fig. 3.14). Note that the right lung is shorter but has greater volume than the left lung. **[G 32; R 239; C 106]**
5. Identify the **surfaces of the lung**: **costal**, **mediastinal**, and **diaphragmatic**.
6. Identify the **borders of the lung**: **anterior, posterior**, and **inferior**.
7. Recall that each lung has a **superior lobe** and an **inferior lobe** separated by the **oblique fissure**. Observe the lung from the lateral view, and note that most of the inferior lobe lies posteriorly and that most of the superior lobe lies anteriorly (Fig. 3.14).
8. Recall that the right lung has a **horizontal fissure**, which defines a small **middle lobe** (Fig. 3.14). Identify the middle lobe.
9. Identify the **cardiac notch** on the superior lobe of the left lung (Fig. 3.14). The cardiac notch is located on the anterior border of the left lung, anterior to the heart.
10. Identify the **lingula** of the left lung. The lingula is the inferior, medial portion of the superior lobe of the left lung.
11. Identify **contact impressions** on the mediastinal surface of each lung (Fig. 3.15). These impressions are artifacts of embalming and illustrate the close proximity of the mediastinal structures to the lung.
    - On the mediastinal surface of the **right lung**, identify the **cardiac impression**, the **groove for the esophagus**, the **groove for the arch of the azygos vein**, and the **groove for the superior vena cava**.
    - On the mediastinal surface of the **left lung**, identify the **cardiac impression**, the **groove for the aortic arch,** and the **groove for the thoracic aorta**. **[G 34, 35; N 195; R 239; C 108]**
12. Examine the **hilum of the lung**. Identify the **main bronchus, pulmonary artery,** and **pulmonary veins**. At the hilum, the main bronchus usually lies posterior to the pulmonary vessels, and the pulmonary artery is superior to the pulmonary veins (Fig. 3.15). To help

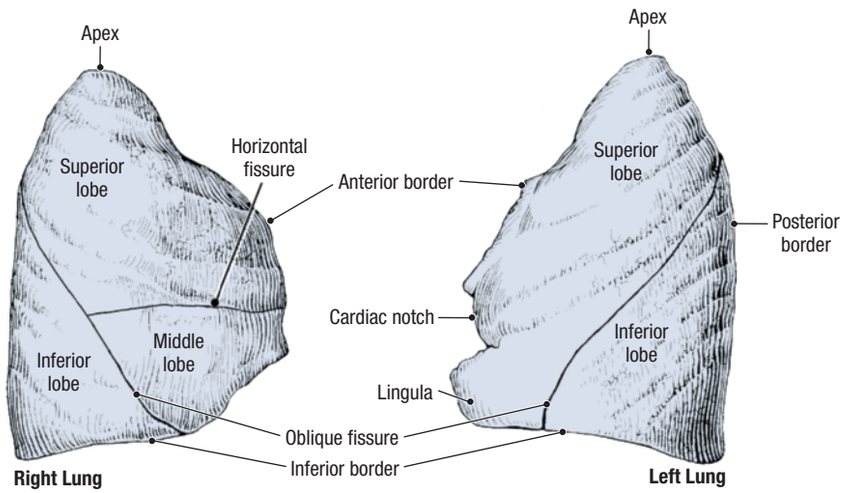

Figure 3.14. Lateral view of the lungs.

distinguish the artery from the veins, compare the relative thickness of the walls of the vessels (arteries have thicker walls).

13. At the hilum of each lung, use blunt dissection to follow the **main bronchus** into the lung.
14. In the left lung, identify the **superior** and **inferior lobar (secondary) bronchi**. **[G 41; N 199; R 237; C 110]**
15. In the right lung, identify the **superior**, **middle**, and **inferior lobar bronchi**. Note that the **right superior lobar bronchus** passes superior to the right pulmonary artery and it is named the "**eparterial bronchus**."
16. Use blunt dissection to follow one lobar bronchus deeper into the lung (approximately 3 cm) until it branches into several **segmental bronchi**. Each lung contains 10 segmental bronchi, and each segmental bronchus supplies one **bronchopulmonary segment** of the lung. In your textbook, find a description of the bronchopulmonary segments and the internal organization of the lung.
17. Identify one of the **bronchial arteries**. The bronchial arteries are branches of the thoracic aorta that course along the surface of the main bronchus. The lumen of the bronchial artery can be seen where the main bronchus was cut during lung removal.
18. The hilum of the lung contains lymph nodes, lymph vessels, and autonomic nerve fibers. Use an illustration to confirm this. **[G 42, 43; N 204, 205; R 265; C 151]**
19. Note that the lungs have a rich nerve supply via the anterior and posterior pulmonary plexuses. Sympathetic contributions are received from the right and left sympathetic trunks, while parasympathetic contributions are received from the right and left vagus nerves.

After you dissect . . .

Review the parts of the lungs. Replace the lungs in their correct anatomical positions within the pleural cavities. Review the relationships of the phrenic and vagus nerves to the root of the lung. Replace the anterior thoracic wall. Project the borders, surfaces, and fissures of the lungs to the surface of the thoracic wall. Review the relationship of the pleural reflections to the thoracic wall. Review the costomediastinal and costodiaphragmatic recesses.

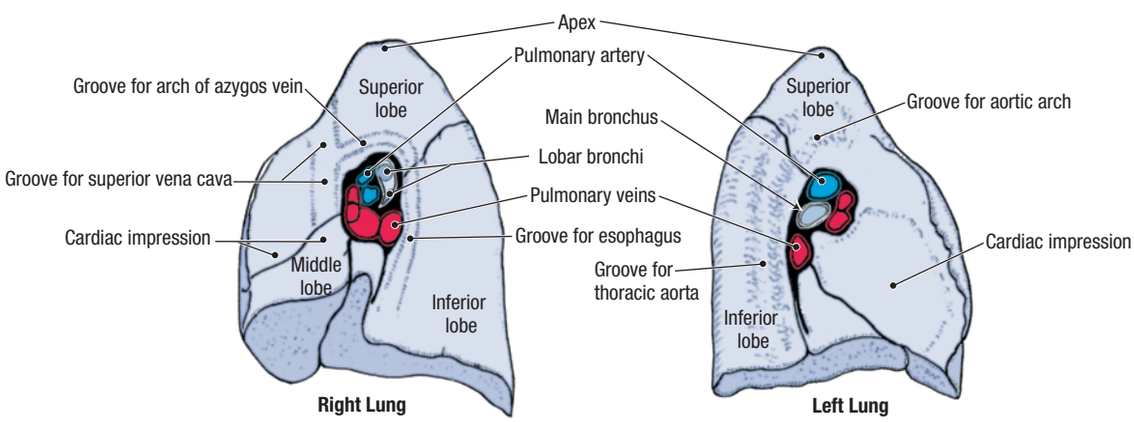

Figure 3.15. Mediastinal surface of the lungs.

MEDIASTINUM

Before you dissect . . .

The region between the two pleural cavities is the mediastinum. The **boundaries of the mediastinum** are:

- **Superior boundary –** superior thoracic aperture
- **Inferior boundary –** diaphragm
- **Anterior boundary –** sternum
- **Posterior boundary –** bodies of vertebrae T1 to T12
- **Lateral boundaries –** mediastinal parietal pleura (left and right)

For descriptive purposes, the mediastinum is divided into four parts (Fig. 3.16). An imaginary horizontal plane at the level of the sternal angle (**plane of the sternal angle**) intersects the intervertebral disk between vertebrae T4 and T5. The plane of the sternal angle separates the **superior mediastinum** from the **inferior mediastinum**. The pericardium divides the inferior mediastinum into three parts: **[G 29; R 233; C 118]**

- **Anterior mediastinum –** the part that lies between the sternum and the pericardium. In children and adolescents, part of the thymus may be found in the anterior mediastinum.
- **Middle mediastinum –** the part that contains the pericardium, the heart, and the roots of the great vessels.
- **Posterior mediastinum –** the part that lies posterior to the pericardium and anterior to the bodies of vertebrae T5 to T12. The posterior mediastinum contains structures that pass between the neck, thorax, and abdomen (esophagus, vagus nerves, azygos system of veins, thoracic duct, thoracic aorta).

Some structures that course through the mediastinum (esophagus, vagus nerve, phrenic nerve, thoracic duct) pass through more than one mediastinal subdivision. The **plane of the sternal angle** marks the level of the **superior border of the pericardium**, **bifurcation of the trachea**, and the **beginning and ending of the arch of the aorta**.

The order of dissection will be as follows: the mediastinal pleura will be examined and mediastinal structures will be palpated. The costal and mediastinal pleurae will then be removed.

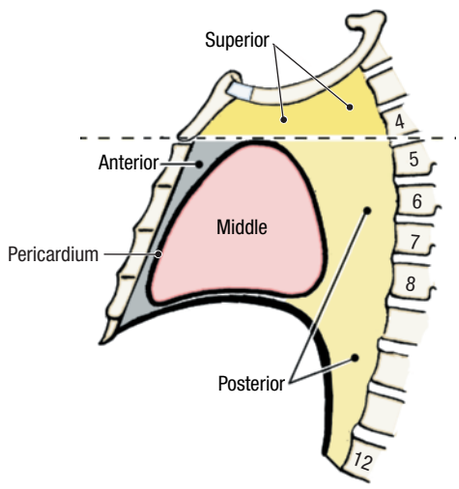

Figure 3.16. Subdivisions of the mediastinum.

Dissection Instructions

1. Observe the **mediastinal pleura**. You may be able to see structures through the mediastinal pleura. **[G 78, 79; N 226, 227; R 270, 271; C 115, 117]**
2. Palpate the **mediastinal pleura** from anterior to posterior. Observe that it is in contact with the **pericardium**, **root of the lung**, **esophagus (right side)**, and **thoracic aorta (left side)**.
3. Follow the mediastinal pleura further posteriorly until it sweeps laterally onto the sides of the vertebral bodies. At this location, the **mediastinal pleura** becomes the **costal pleura**.
4. To examine the mediastinum more closely, the parietal pleura must be removed bilaterally. Note that the **endothoracic fascia** provides a natural cleavage plane for separation of costal pleura from the thoracic wall.
5. Use your fingers to pick up the costal pleura at the cut ends of ribs 1 to 5. Peel the costal pleura off the inner surface of the posterior thoracic wall, moving from lateral to medial.
6. Continue to remove the parietal pleura where it covers the vertebral column, aorta, esophagus, and pericardium.
7. Identify the left and right **phrenic nerves** and the left and right **pericardiacophrenic vessels**. The phrenic nerve and pericardiacophrenic vessels are located between the mediastinal pleura and the pericardium approximately 1.5 cm anterior to the root of the lung. Follow the phrenic nerve and pericardiacophrenic vessels to the diaphragm. Each phrenic nerve is the only motor innervation to that half of the diaphragm.

MIDDLE MEDIASTINUM

Before you dissect . . .

The **middle mediastinum** contains the **pericardium**, the **heart**, and the **roots of the great vessels**. The **pericardium** is a sac that encloses the heart and it is pierced by the great vessels (aorta, pulmonary trunk, superior vena cava, inferior vena cava, and four pulmonary veins). The outer surface of the pericardium is fibrous, whereas the inner surface of the pericardium is serous and smooth. The pericardium is attached to the central tendon of the diaphragm. Thus, the heart moves with the diaphragm during inspiration and expiration.

The order of dissection will be as follows: the pericardium will be opened and its relationship to the heart and great vessels will be explored. The characteristics of the parietal serous pericardium will then be studied. The heart will be removed by cutting the great vessels.

Dissection Instructions

HEART IN THE THORAX [G 49; N 208; R 258; C 120]

1. Open the pericardium in the following manner (Fig. 3.17). Use forceps to elevate the anterior surface of the pericardium. Use scissors to make a longitudinal inci-

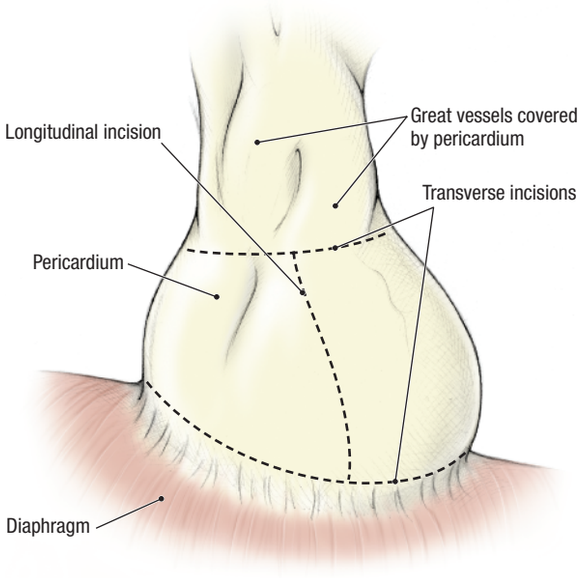

Figure 3.17. How to open the pericardium.

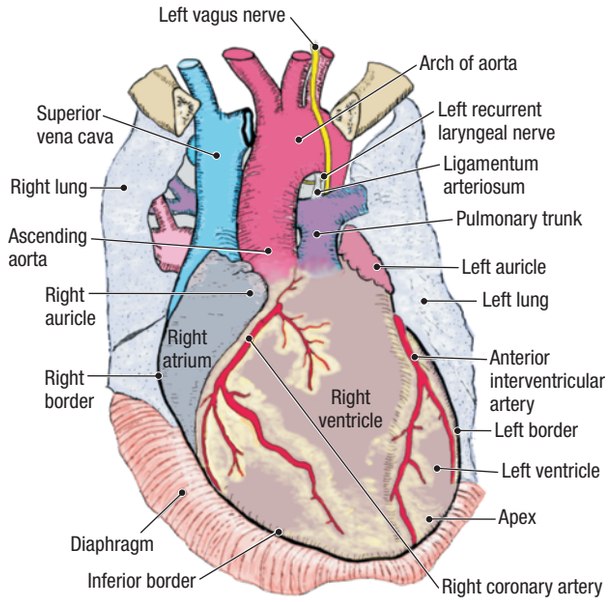

Figure 3.18. Anterior view of the heart *in situ*.

sion from the diaphragm to the aorta. Make the transverse incisions illustrated in Figure 3.17 and open the flaps widely.

2. Identify the following structures (Fig. 3.18): **superior vena cava**, **ascending aorta**, **arch of the aorta**, and **pulmonary trunk**.
3. Use your fingers to gently open the interval between the concavity of the aortic arch and pulmonary trunk, and identify the **ligamentum arteriosum** (Fig. 3.18). The ligamentum arteriosum connects the left pulmonary artery to the arch of the aorta.
4. Use a probe to dissect the **left vagus nerve** where it crosses the left side of the aortic arch (Fig. 3.18). Identify the initial portion of the **left recurrent laryngeal nerve**. The left recurrent laryngeal nerve is located inferior to the aortic arch and adjacent to the ligamentum arteriosum.
5. Examine the heart and identify the chambers that can be seen from the anterior view: **right atrium**, **right ventricle**, and **left ventricle** (Fig. 3.18). Note that the right ventricle forms the anterior part of the heart.
6. Identify the **borders of the heart**:
   - **Right border –** formed by the right atrium
   - **Inferior border –** formed by the right ventricle and a small part of the left ventricle
   - **Left border –** formed by the left ventricle
   - **Superior border –** formed by the right and left atria and auricles
7. Identify the **apex of the heart**. Note that the apex of the heart is part of the left ventricle. The apex of the heart is normally located deep to the left 5th intercostal space, approximately 9 cm from the midline.
8. Identify the **base of the heart**. The left atrium and part of the right atrium form the base of the heart, although clinicians refer to the emergence of the great vessels from the heart as its base.
9. Observe that the inner surface of the pericardium is lined by the smooth, shiny **parietal layer of serous pericardium**.
10. Use the cadaver and an illustration to observe that the parietal layer of serous pericardium is reflected onto the heart as the **visceral layer of serous pericardium (epicardium).** The line of reflection of parietal serous pericardium to visceral serous pericardium occurs at the roots of the great vessels. **[G 49; N 208; R 259; C 120]**
11. The **pericardial cavity** is a potential space between the parietal layer and visceral layers of serous pericardium. Normally it contains only a thin film of serous fluid that lubricates the serous surfaces and allows free movement of the heart within the pericardium.
12. Place your right hand in the pericardial cavity with your fingers posterior to the heart. Lift the heart gently and push your fingers superiorly until they are stopped by the reflection of serous pericardium. Your fingertips are located in the **oblique pericardial sinus** (Fig. 3.19). Remove your hand from the oblique pericardial sinus. **[G 51; N 211; R 262; C 121]**
13. In the transverse plane, push your right index finger posterior to the pulmonary trunk and ascending aorta. Proceed from left to right and make your finger tip emerge between the superior vena cava and the aortic arch. Your finger is in the **transverse pericardial sinus** (Fig. 3.19).
14. Gently insert the tip of a probe between the pericardium and the anterior surface of the ascending aorta. Slowly advance the probe until it stops. This is the superior limit of the pericardial cavity.
15. Use your fingers to explore the lines of reflection of the serous pericardium where the great vessels (aorta, pulmonary trunk, superior vena cava, inferior vena

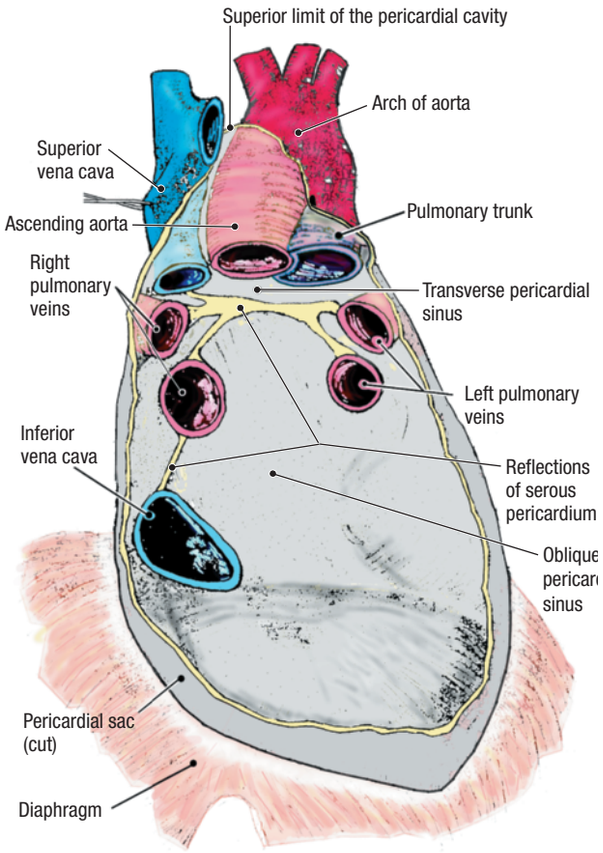

Figure 3.19. Inner surface of the posterior wall of the pericardium showing sinuses and serous reflections.

cava, and four pulmonary veins) enter and exit the heart (Fig. 3.19).

16. Replace the anterior thoracic wall into its correct anatomical position. Use the cadaver and an illustration to project the outline of the heart to the surface of the thoracic wall. **[G 26; N 192; R 242; C 99]**

CLINICAL CORRELATION

Pericardium

Inflammatory diseases can cause fluid to accumulate in the pericardial cavity (pericardial effusion). Bleeding into the pericardial cavity (hemopericardium) may result from penetrating heart wounds or perforation of a weakened heart muscle after myocardial infarction. Because the pericardium is composed of fibrous connective tissue, it cannot stretch, and fluids collected in the pericardial cavity compresses the heart (cardiac tamponade).

REMOVAL OF THE HEART

1. The heart will be detached from the great vessels along the lines of reflection of the serous pericardium (Fig. 3.19).
2. Place a probe through the transverse pericardial sinus.
3. Use scissors to cut the **ascending aorta** and the **pulmonary trunk** anterior to the probe, approximately 1.5 cm superior to the point where the aorta and pulmonary trunk exit the heart.
4. Lift the apex of the heart and cut the **inferior vena cava** close to the surface of the diaphragm.
5. Use scissors to cut the **superior vena cava** approximately 1 cm superior to its junction with the right atrium.
6. Lift the apex of the heart superiorly. Use scissors to cut the **four pulmonary veins** where they form the boundary of the oblique pericardial sinus (Fig. 3.19). Cut the pulmonary veins very close to the parietal pericardium.
7. The heart is now held in place only by reflections of serous pericardium from its posterior surface (Fig. 3.19). Cut these reflections and remove the heart.
8. Refer to Figure 3.19. Examine the posterior aspect of the pericardium and identify the openings of the eight vessels and the lines of the pericardial reflections.

After you dissect . . .

Review the parts of the mediastinum and state their boundaries. Review the attachments of the pericardium to the diaphragm and to the roots of the great vessels. Review the embryonic origin of the transverse and oblique pericardial sinuses. Compare the structural and functional properties of parietal serous pericardium to the properties of parietal pleura.

EXTERNAL FEATURES OF THE HEART

Before you dissect . . .

Dissection of the heart will proceed in two stages. The external features of the heart will be studied, including its vascular supply. The internal features of the chambers of the heart will then be studied.

Dissection Instructions

SURFACE FEATURES

1. Examine the external surface of the heart. Identify the following: **[G 46, 47; N 210; R 242; C 122, 123]**
   - **Coronary (atrioventricular) groove (sulcus)**—it runs obliquely around the heart, separating the atria from the ventricles.
   - **Anterior interventricular groove (sulcus)** and the **posterior interventricular groove (sulcus)**. The interventricular grooves indicate the location of the interventricular septum. The interventricular grooves join the coronary groove at a right angle.

2. Identify the **surfaces of the heart**:
   - **Sternocostal (anterior) surface –** formed mainly by the right ventricle.
   - **Diaphragmatic (inferior) surface –** formed mainly by the left ventricle and a small part of the right ventricle.
   - **Pulmonary (left) surface –** formed mainly by the left ventricle. The pulmonary surface of the heart is in contact with the cardiac impression of the left lung.
3. On the surface of the heart, identify the chambers:
   - **Right atrium** and **right auricle**
   - **Right ventricle**
   - **Left ventricle**
   - **Left atrium** and **left auricle**
4. Examine the heart in superior view. Identify:
   - **Aorta** and **aortic valve**
   - **Pulmonary trunk** and **pulmonary valve**
   - **Superior vena cava**
5. Examine the diaphragmatic surface of the heart and identify the **inferior vena cava**.
6. Observe that the coronary groove and the interventricular grooves mark the boundaries of the four chambers of the heart. The cardiac veins and coronary arteries are located in the grooves.

CARDIAC VEINS [G 53; N 212; R 252; C 122, 123]

1. The **cardiac veins** course superficial to the **coronary arteries**, so they will be dissected first. The coronary groove and the interventricular grooves are filled with fat that must be removed to observe the vessels. Use blunt dissection to remove the fat. Scraping motions with the handle of a forceps usually yield good results.
2. Identify the **coronary sinus** on the diaphragmatic surface of the heart (Fig. 3.20). The coronary sinus is a dilated portion of the venous system of the heart that is located in the coronary groove. The coronary sinus is approximately 2 to 2.5 cm in length and opens into the right atrium. Its opening will be seen when the internal features of the right atrium are dissected.
3. Use a probe to clean the surface of the coronary sinus. Note that most veins of the heart are tributaries to the coronary sinus (Fig. 3.20).
4. Follow the coronary sinus superiorly in the coronary groove to the point where it receives the **great cardiac vein**.
5. Use blunt dissection to follow the great cardiac vein onto the sternocostal surface of the heart. The great cardiac vein courses from the apex of the heart toward the coronary sinus in the anterior interventricular groove.
6. In the posterior interventricular groove, identify the **middle cardiac vein** and trace it to the coronary sinus.
7. Near the inferior end of the coronary sinus, identify the **small cardiac vein**. Use a probe to dissect the small cardiac vein and follow it to the anterior surface of the heart where it courses along the inferior border of the heart.

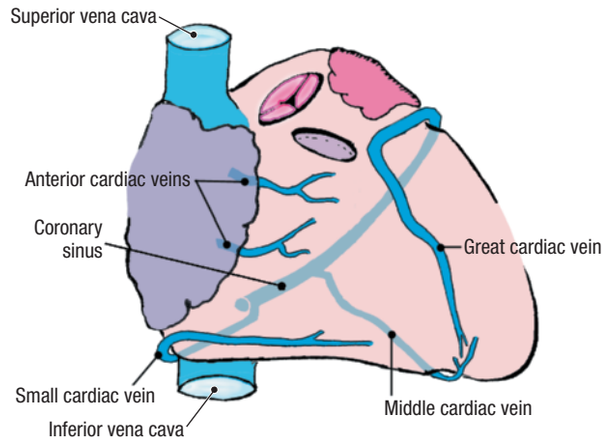

Figure 3.20. Cardiac veins.

8. **Anterior cardiac veins** bridge the atrioventricular groove between the right atrium and right ventricle. The anterior cardiac veins drain the anterior wall of the right ventricle directly into the right atrium. Anterior cardiac veins pass superficial to the right coronary artery.

CORONARY ARTERIES [G 52; N 212; R 252; C 126]

1. Begin the dissection of the coronary arteries by observing the superior surface of the **aortic valve**. Identify the **right**, **left**, and **posterior semilunar cusps** of the aortic valve. Behind each valve cusp is a small pocket called an **aortic sinus** (**right**, **left**, and **posterior**, respectively).
2. In the left aortic sinus, identify the **opening of the left coronary artery**. Place the tip of a probe into the opening. On the surface of the heart, palpate the tip of the probe between the left auricle and the pulmonary trunk. This is the initial portion of the left coronary artery.
3. Use blunt dissection to clean the left coronary artery. In the coronary groove, the left coronary artery divides into the **anterior interventricular branch** and the **circumflex branch** (Fig. 3.21).
4. Trace the **anterior interventricular branch** in the anterior interventricular groove to the apex of the heart. Clinicians call the anterior interventricular branch of

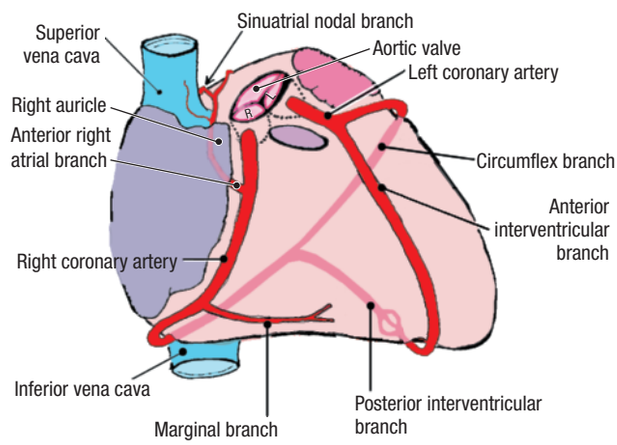

Figure 3.21. Coronary arteries and their branches.

the left coronary artery the **L**eft **A**nterior **D**escending artery (**LAD**). Note that the anterior interventricular artery accompanies the great cardiac vein.

5. Follow the **circumflex branch of the left coronary artery** in the coronary groove and around the left border of the heart. The circumflex branch of the left coronary artery has several unnamed branches that supply the posterior wall of the left ventricle. The circumflex branch of the left coronary artery accompanies the coronary sinus in the coronary groove.
6. To begin the dissection of the **right coronary artery**, identify the **right semilunar cusp of the aortic valve** (Fig. 3.21). Insert a probe into the opening of the right coronary artery in the **right aortic sinus**. On the surface of the heart, palpate the tip of the probe in the coronary groove between the right auricle and the ascending aorta. This is the beginning of the right coronary artery.
7. Use blunt dissection to clean the right coronary artery and identify the **anterior right atrial branch** (Fig. 3.21). The anterior right atrial branch arises close to the origin of the right coronary artery and ascends along the anterior wall of the right atrium toward the superior vena cava. The anterior right atrial branch gives rise to the **sinuatrial nodal branch**, which supplies the sinuatrial node.
8. Follow the right coronary artery in the coronary groove. Preserve the anterior cardiac veins. The **marginal branch** of the right coronary artery usually arises near the inferior border of the heart. The marginal branch accompanies the small cardiac vein along the inferior border of the heart.
9. Continue to follow the right coronary artery in the coronary groove to the diaphragmatic surface of the heart. When the right coronary artery reaches the posterior interventricular groove, it gives rise to the **posterior interventricular branch**. The posterior interventricular branch courses along the posterior interventricular groove to the apex of the heart where it anastomoses with the anterior interventricular branch of the left coronary artery. The posterior interventricular branch accompanies the middle cardiac vein.
10. Note that the **artery to the atrioventricular node** arises from the right coronary artery at the point where the posterior interventricular groove meets the coronary groove.

After you dissect . . .

Review the borders of the heart. On the surface of the heart, review the boundaries of the four chambers. Review the coronary groove and interventricular grooves of the heart and the vessels that course within these grooves. Trace a drop of blood from the right aortic sinus to the coronary sinus. Trace a drop of blood from the left aortic sinus to the apex of the heart and its venous return to the coronary sinus.

INTERNAL FEATURES OF THE HEART

Before you dissect . . .

The atria and ventricles of the heart will be opened and their internal features will be studied. The incisions that will be used are designed to preserve most of the vessels that you have previously dissected. The heart will contain clotted blood, which must be removed. The clots will be hard and may need to be broken before they can be extracted. The chambers will be dissected in the sequence that blood passes through the heart: **right atrium**, **right ventricle**, **left atrium**, and **left ventricle**. All descriptions are based on the heart in anatomical position.

Dissection Instructions

RIGHT ATRIUM [G 56; N 216; R 248; C 130]

1. The cuts used to open the right atrium are illustrated in Figure 3.22.
2. Use scissors to make a cut through the tip of the right auricle. Insert one blade of the scissors through the opening and make a short horizontal cut toward the right.
3. Turn the scissors and cut through the anterior wall of the right atrium in an inferior direction. Stop superior to the inferior vena cava.
4. Make a horizontal cut toward the left, stopping just short of the coronary groove.
5. Turn the flap of the atrial wall toward the left and open the right atrium widely (Fig. 3.23). Remove blood clots and take the heart to the sink to rinse it with water.
6. Observe the inner surface of the **anterior wall of the right atrium**. Identify (Fig. 3.23):
   - **Pectinate muscles –** horizontal ridges of muscle
   - **Crista terminalis –** a vertical ridge of muscle that connects the pectinate muscles

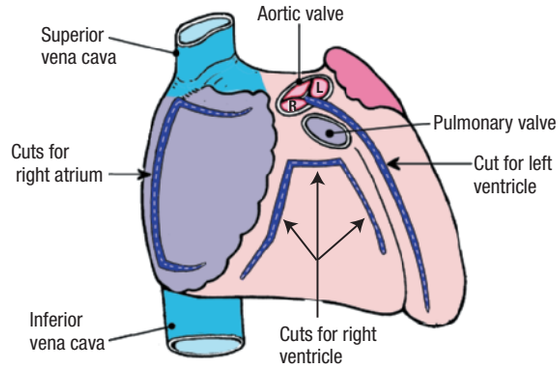

Figure 3.22. Cuts used to open the right atrium, right ventricle, and left ventricle of the heart.

CLINICAL CORRELATION

Coronary Arteries

In approximately 75% of hearts, the right coronary artery gives rise to the posterior interventricular branch and supplies the left ventricular wall and posterior portion of the interventricular septum. In approximately 15% of hearts, the left coronary artery gives rise to the posterior interventricular branch. Other variations account for 10%.

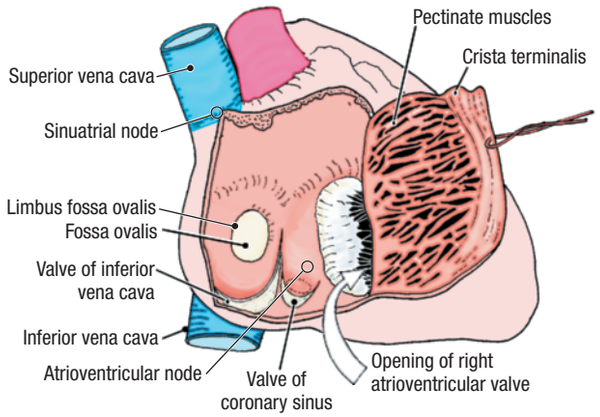

Figure 3.23. Interior of the right atrium. Approximate locations of the nodes of the conducting system are indicated.

7. Observe the **posterior wall of the right atrium**. Identify (Fig. 3.23):
   - **Opening of the superior vena cava**
   - **Opening and valve of the inferior vena cava**
   - **Opening and valve of the coronary sinus**
   - **Fossa ovalis** and the **limbus fossa ovalis** (L. *limbus*, a border)

CLINICAL CORRELATION

Fossa Ovalis

The **fossa ovalis** is the remnant of the **foramen ovale**. In fetal life, blood from the placenta is delivered to the heart by way of the inferior vena cava. This oxygen-rich and nutrient-rich blood is directed toward the foramen ovale, which allows passage into the left atrium and out to the body without entering the lungs.

8. Parts of the **conducting system of the heart** are located in the walls of the right atrium but cannot be seen in dissection. Familiarize yourself with their approximate locations in the dissected specimen (Fig. 3.23). The **sinuatrial node** (SA node) lies at the superior end of the crista terminalis at the junction between the right atrium and the superior vena cava. The **atrioventricular node** (AV node) is located in the lower part of the interatrial septum, near the opening of the coronary sinus.
9. Identify the opening of the **right atrioventricular valve**, which leads into the right ventricle.

RIGHT VENTRICLE [G 57; N 216; R 251; C 130]

1. The cuts used to open the right ventricle are illustrated in Figure 3.22.
2. Insert your finger into the pulmonary trunk and determine the level of the **pulmonary valve**. Inferior to the level of the pulmonary valve, use scissors to make a short horizontal cut through the **anterior wall of the right ventricle**.
3. Insert one blade of the scissors into the right end of the first cut and make a second cut parallel to the coronary groove. The second cut should be approximately 1 cm from the coronary groove and end at the inferior border of the heart. Cut only the ventricular wall, not the atrioventricular valve cusp.
4. Insert your finger through the opening and palpate the **interventricular septum**. From the left end of the first cut, make a third cut toward the inferior border of the heart. The third cut should be approximately 2 cm to the right of the anterior interventricular groove and should parallel the right side of the interventricular septum.
5. Turn the flap of the right ventricular wall inferiorly (Fig. 3.24).

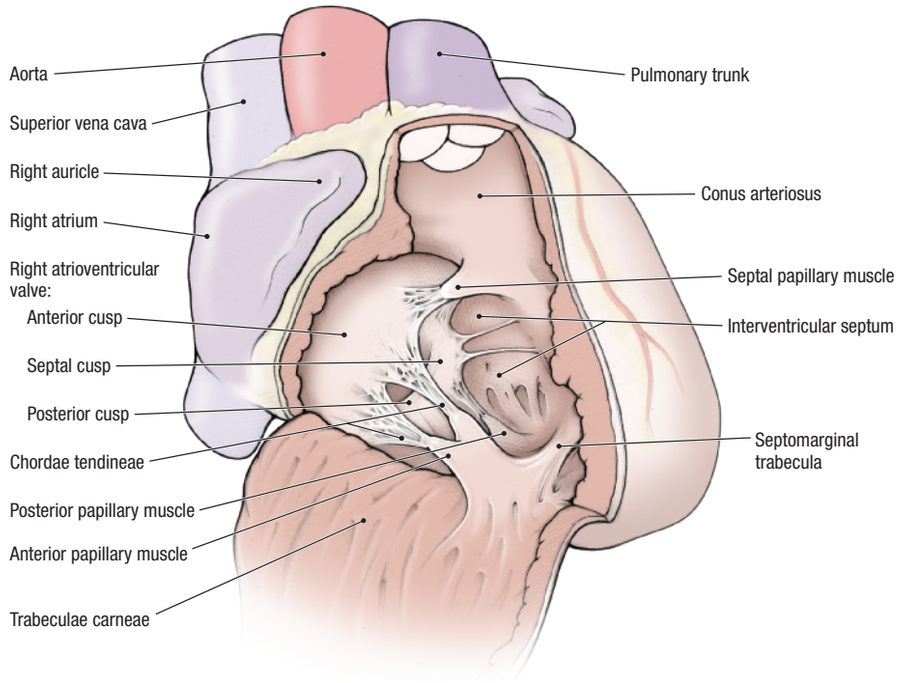

Figure 3.24. Interior of the right ventricle.

6. Remove blood clots. Use care to avoid damaging the **chordae tendineae**. Rinse the right ventricle with water.
7. Identify the **opening of the right atrioventricular valve**. Observe that the right atrioventricular valve has **three cusps**: **anterior**, **septal**, and **posterior** (Fig. 3.24)**.** The right atrioventricular valve is also called the **tricuspid valve**.
8. Identify the **chordae tendineae**. Observe that these delicate tendons pass from the valve cusps to the apices of **papillary muscles**. The papillary muscles arise from the walls of the right atrium.
9. Identify **three papillary muscles**: **anterior**, **septal**, and **posterior**. The anterior papillary muscle is the largest and most prominent. The septal papillary muscle is very small and may be multiple. Note that the chordae tendineae of each papillary muscle attach to the adjacent sides of two valve cusps.
10. Observe that the inner surface of the wall of the right ventricle is roughened by muscular ridges called **trabeculae carneae** (L. *trabs*, wooden beam; *carneus*, fleshy).
11. Identify the **septomarginal trabecula (moderator band**). The septomarginal trabecula extends from the interventricular septum to the base of the anterior papillary muscle. The septomarginal trabecula contains part of the right bundle of the conducting system, the part that stimulates the anterior papillary muscle.
12. Identify the **opening of the pulmonary trunk** (Fig. 3.24). The **conus arteriosus** (**infundibulum)** is the cone-shaped portion of the right ventricle inferior to the opening of the pulmonary trunk. The inner wall of the conus arteriosus is smooth.
13. Observe that the **pulmonary valve** consists of **three semilunar cusps**: **anterior**, **right**, and **left**. **[G 60, 61; N 218; R 149; C 122]**
14. Look into the pulmonary trunk from above and examine the superior surface of the semilunar valve. Observe that each semilunar valve cusp has one fibrous **nodule** and two **lunules**. The nodule and lunules help to seal the valve cusps and prevent backflow of blood during diastole.

LEFT ATRIUM [G 58; N 217; R 248; C 132]

1. Examine the posterior surface of the heart. Observe the openings of the **four pulmonary veins** into the left atrium. The pulmonary veins are usually arranged in pairs, two from the right lung and two from the left lung.
2. The cut used to open the left atrium is illustrated in Figure 3.25A.
3. Use scissors to make an inverted, U-shaped incision through the posterior wall of the left atrium. Do not cut into the openings of the pulmonary veins; cut between them. Turn the flap inferiorly (Fig. 3.25B).
4. Remove blood clots and rinse with water.
5. Note that the inner surface of the wall of the left atrium is smooth except for its auricle, which has a rough inner surface.

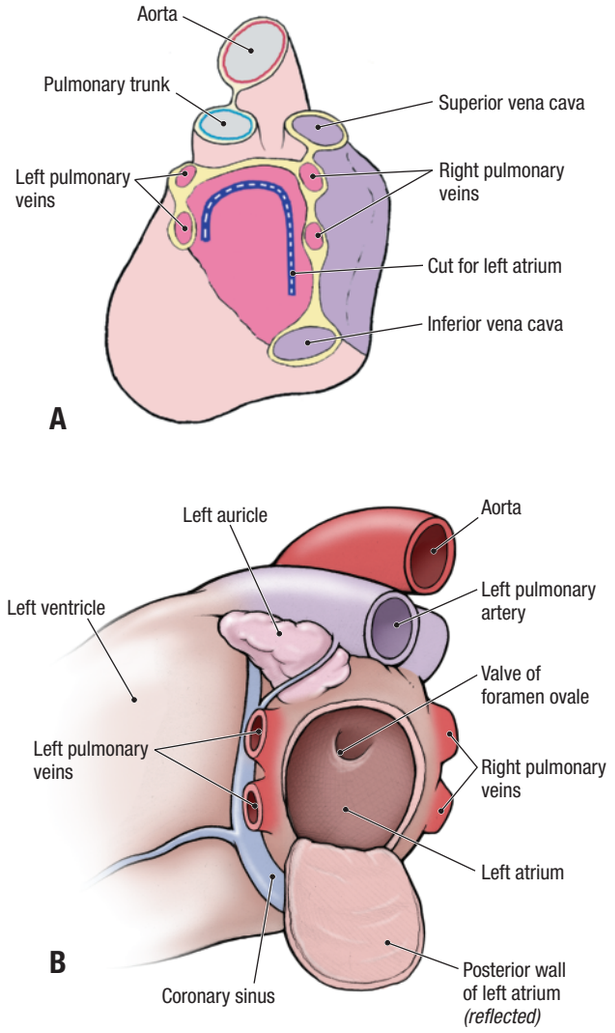

Figure 3.25. The left atrium of the heart. **A.** Cuts used to open the left atrium. **B.** Interior of the left atrium.

6. Observe the following features in the left atrium (Fig 3.25B):
   - **Valve of the foramen ovale** on the **interatrial septum**
   - **Opening into the left auricle**
   - **Opening of the left atrioventricular valve**

LEFT VENTRICLE [G 59; N 217; R 248; C 133]

1. The cut used to open the left ventricle is illustrated in Figure 3.22. Note that the following procedure will cut the anterior interventricular branch of the left coronary artery and the great cardiac vein.
2. Look into the aorta from above and identify the **aortic valve**. Identify **three semilunar valve cusps**: **right**, **left**, and **posterior**. **[G 60, 61; N 218, 219; R 249; C 122]**
3. Insert one blade of a scissors between the left and right semilunar cusps (Fig. 3.22).
4. Make a cut through the anterior wall of the ascending aorta between the left and right semilunar cusps. This cut should be anterior and parallel to the left coronary artery.

5. Continue the cut to the apex of the heart. The cut should be approximately 2 cm to the left of the anterior interventricular groove and should parallel the left side of the interventricular septum. The cut will cross the anterior interventricular branch of the left coronary artery and the great cardiac vein.
6. Open the left ventricle and the ascending aorta widely (Fig. 3.26). Remove blood clots and rinse with water.
7. In the left ventricle, identify the **left atrioventricular valve** (**bicuspid valve**, **mitral valve**). Identify the **anterior cusp** and the **posterior cusp** (Fig. 3.26).
8. Identify the **anterior papillary muscle** and the **posterior papillary muscle**. Observe that the **chordae tendineae** of each papillary muscle attach to both valve cusps.
9. Observe that the inner surface of the wall of the left ventricle is roughened by **trabeculae carneae**.
10. Examine the **aortic valve**. Again identify its **right, left**, and **posterior semilunar cusps**. Observe that each semilunar valve cusp has one nodule and two lunules.
11. Palpate the **muscular part of the interventricular septum**. Place the thumb of your right hand in the right ventricle and your index finger in the left ventricle and palpate the thickness of the muscular part of the interventricular septum.
12. Move your thumb and index finger superiorly along the interventricular septum and identify the thin **membranous part of the interventricular septum**. It is located inferior to the attachment of the right cusp of the aortic valve.
13. In the aorta, observe the openings of the **coronary arteries** and study their relationship to the semilunar valve cusps and the **aortic sinuses**. The posterior cusp is also called the **noncoronary cusp** because there is no coronary artery arising from its sinus.
14. Use an illustration to study the **conducting system of the heart**. Recall that the **sinuatrial (SA) node** is in the wall of the right atrium, at the superior end of the crista terminalis near the superior vena cava. Impulses from the SA node pass through the wall of the right atrium to the **atrioventricular (AV) node**. Impulses that originate in the AV node pass in the **atrioventricular (AV) bundle** through the membranous part of the interventricular septum. Subsequently, the AV bundle divides into **right and left bundles**, which lie on either side of the muscular part of the interventricular septum and stimulate the ventricles to contract. The right bundle is noteworthy because it carries impulses to the anterior papillary muscle through the **septomarginal trabecula**. **[G 62; N 221; R 251; C 136, 137]**

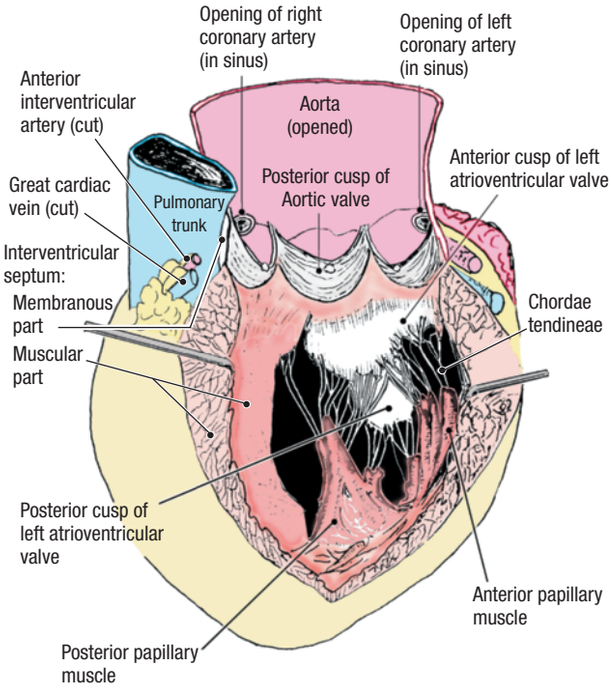

Figure 3.26. Interior of the left ventricle.

After you dissect . . .

Review the internal features of each of the chambers of the heart. Replace the heart into the thorax in its correct anatomical position. Return the thoracic wall to its anatomical position. Use an illustration, a textbook description, and the dissected specimen to project the heart valves to the surface of the anterior thoracic wall. Read a description of the auscultation point used to listen to each heart valve. Review the course of blood as it passes through the heart, beginning in the superior vena cava and ending in the ascending aorta. In the correct sequence, name all of the chambers and valves that the blood passes through. Review the blood supply to the heart. Trace a drop of blood from the left coronary artery and the right coronary artery to the coronary sinus, naming all vessels traversed. Review the connections of the great vessels to the heart. Use an illustration to review the conducting system of the heart and relate the illustration to the dissected specimen.

SUPERIOR MEDIASTINUM

Before you dissect . . .

The superior mediastinum contains structures that pass between the thorax and the neck, or the thorax and the upper limb. These structures include several of the great vessels and their primary branches, the trachea, the esophagus, and the thoracic duct.

The order of dissection will be as follows: the brachiocephalic veins will be studied and reflected. The aortic arch and its branches will be dissected. The trachea and its bifurcation will be studied. The upper part of the esophagus and the vagus nerves will be dissected. Note that only the proximal ends of some of the large vessels will be seen in this dissection. The distal parts of these vessels will be dissected with the neck or the upper limb.

Dissection Instructions

1. Study the **boundaries of the superior mediastinum** (Fig. 3.16).
   - **Superior –** superior thoracic aperture
   - **Posterior –** bodies of vertebrae T1 to T4:
   - **Anterior –** manubrium of the sternum
   - **Lateral –** mediastinal pleurae (left and right)
   - **Inferior –** plane of the sternal angle
2. Reflect the anterior thoracic wall superiorly.
3. Identify the **thymus**. In the adult, the thymus is a fatty remnant that lies immediately posterior to the manubrium of the sternum. **[G 64-67; N 208; R 259; C 119]**

CLINICAL CORRELATION

Thymus

In the newborn, the thymus is an active lymphatic organ that can be visualized on a chest radiograph. The thymus is replaced by connective tissue and fat after puberty. It may be difficult to recognize the thymus in the cadaver.

4. Remove the remnant of the thymus by blunt dissection.
5. Trace the superior vena cava superiorly until it bifurcates. Identify the **left brachiocephalic vein** (Fig. 3.27). Clean the anterior surface of the left brachiocephalic vein and free it from the structures that lie posterior to it.

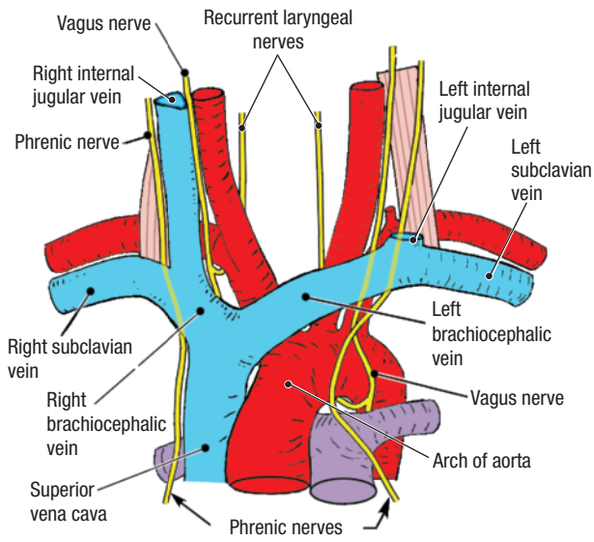

Figure 3.27. Relationships of the phrenic nerves and the vagus nerves to the great vessels.

6. Identify the **right brachiocephalic vein**. The two **brachiocephalic veins** meet to form the **superior vena cava** posterior to the inferior border of the right first costal cartilage.
7. Follow the superior vena cava inferiorly. Note that the superior vena cava passes anterior to the root of the right lung. **[G 78; N 226; R 270; C 115]**
8. Identify the **azygos vein** on the right side of the mediastinum. The **arch of the azygos vein** passes superior to the root of the right lung and drains into the posterior surface of the superior vena cava.
9. Cut the superior vena cava just superior to the entrance of the azygos vein. Reflect the superior vena cava and the brachiocephalic veins superiorly.
10. Identify the **right phrenic nerve** and the **left phrenic nerve** that pass posterior to the brachiocephalic veins. The phrenic nerves were previously dissected in the middle mediastinum. Note that the right and left phrenic nerves pass anterior to the roots of the right and left lungs, respectively. Demonstrate that the phrenic nerves accompany the pericardiacophrenic vessels and that they enter the superior surface of the diaphragm.
11. Identify the **arch of the aorta** (Fig. 3.28). The arch of the aorta begins and ends at the level of the sternal angle. **[G 79; N 227; R 271; C 117]**
12. Identify the three arteries that arise from the arch of the aorta (Fig. 3.28). From anterior to posterior, they are the **brachiocephalic trunk**, the **left common carotid artery**, and the **left subclavian artery**.
13. Identify the **ligamentum arteriosum**. The ligamentum arteriosum is a fibrous cord that connects the concavity of the arch of the aorta to the left pulmonary artery (Fig. 3.28).
14. Identify the **left vagus nerve** and the **left recurrent laryngeal nerve** on the left side of the arch of the aorta (Fig. 3.29). Follow the left vagus nerve inferiorly and note that it passes posterior to the root of the left lung toward the esophagus. Review the relationship of the left recurrent laryngeal nerve to the ligamentum arteriosum.

CLINICAL CORRELATION

Left Recurrent Laryngeal Nerve

The left recurrent laryngeal nerve has a close relationship to the aortic arch and passes through the superior mediastinum. In cases of mediastinal tumors or an aneurysm of the aortic arch, the left recurrent laryngeal nerve may be compromised, resulting in paralysis of the left vocal fold and hoarseness.

15. On the right side, note that the **right vagus nerve** passes posterior to the root of the right lung (Fig. 3.29). The **right recurrent laryngeal nerve** (a branch of the right vagus nerve) loops around the right subclavian artery.

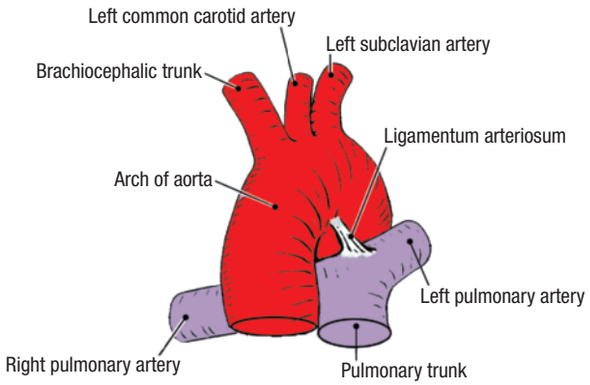

Figure 3.28. Branches of the arch of the aorta.

16. Identify the **trachea**. Observe that **tracheobronchial lymph nodes** are located on both sides of the trachea near its bifurcation.
17. Identify the **bifurcation of the trachea**. The trachea bifurcates at the plane of the sternal angle to form the **right main bronchus** and the **left main bronchus**. Note that the arch of the azygos vein passes superior to the right main bronchus and the arch of the aorta passes superior to the left main bronchus.
18. Palpate the anterior and posterior surfaces of the trachea near its bifurcation. Observe that the **tracheal rings** are "C-shaped" and that the open part of the "C" is located posteriorly.
19. Observe that the esophagus is located posterior to the trachea in close relationship to the open part of the tracheal cartilages.
20. Use scissors to make a longitudinal cut through the anterior surface of the right and left main bronchi. The cuts should meet anterior to the tracheal bifurcation. Make a third cut superiorly through the anterior surface of the trachea for a distance of 2.5 cm. Inside the tracheal bifurcation, identify the **carina** (L. *carina*, keel of a boat). The carina is a specialized piece of tracheal cartilage (Fig. 3.29).
21. Compare the right and left main bronchi. Observe that the right main bronchus is larger in diameter, shorter, and oriented more vertically than the left main bronchus.

CLINICAL CORRELATION

Bifurcation of the Trachea

During bronchoscopy, the carina serves as an important landmark because it lies between the superior ends of the right and left main bronchi. The carina is usually positioned slightly to the left of the median plane of the trachea. When foreign bodies are aspirated, they usually enter the right main bronchus because it is wider and more vertically oriented than the left main bronchus.

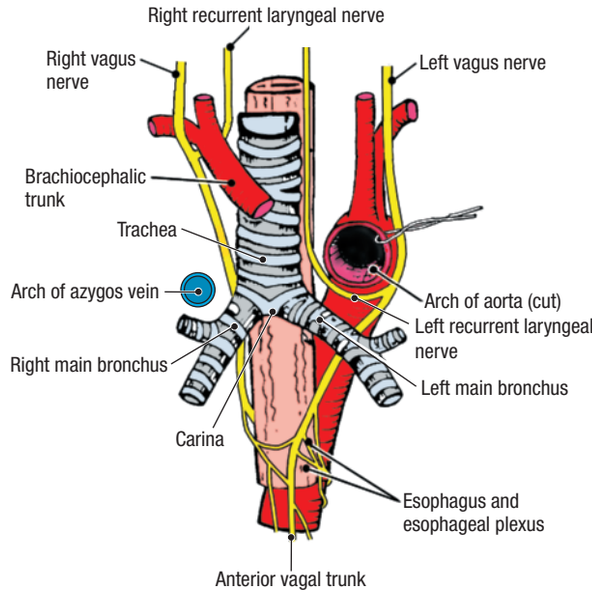

Figure 3.29. Course of the right and left vagus nerves.

After you dissect . . .

Replace the contents of the superior mediastinum into their correct anatomical positions. Return the anterior thoracic wall to its correct anatomical position. Project the structures of the superior mediastinum to the surface of the thoracic wall. Reflect the anterior thoracic wall. Review the formation of the superior vena cava and the position of the arch of the azygos vein. Review the position of the ascending aorta and the position of the arch of the aorta. Review the branches of the arch of the aorta. Compare the relationships of the phrenic and vagus nerves at the root of the lung. Contrast the thoracic course of the left recurrent laryngeal nerve to the thoracic course of the right recurrent laryngeal nerve.

POSTERIOR MEDIASTINUM

Before you dissect . . .

The posterior mediastinum contains structures that course between the thorax and the abdomen. The posterior mediastinum lies posterior to the pericardium. The structures in the posterior mediastinum will be approached through the **posterior wall of the pericardium**.

The order of dissection will be as follows: the pericardium will be reviewed and its posterior wall will be removed. The esophagus will be studied. The azygos vein and its tributaries will be studied. The thoracic duct will be identified. Then, the aorta and its branches will be dissected. Finally, the thoracic portion of the sympathetic trunk and its branches will be dissected.

Dissection Instructions

1. Study the **boundaries of the posterior mediastinum** (Fig. 3.16):
   - **Superior –** plane of the sternal angle
   - **Posterior –** bodies of vertebrae T5 to T12:

- **Anterior –** pericardium
- **Lateral –** mediastinal pleurae (left and right)
- **Inferior –** diaphragm

2. Review the interior of the pericardium (Fig. 3.19).
3. Place the heart back into the pericardium. From the right side of the thorax, examine the relationship of the heart to the esophagus. Note that the esophagus lies immediately posterior to the left atrium and part of the left ventricle. Remove the heart.
4. Remove the posterior wall of the pericardium in the **area of the oblique sinus** (Fig. 3.30). Identify the **esophagus**. The esophagus is a muscular tube that sits just to the right of the midline. To the left and slightly posterior to the esophagus is the **thoracic aorta**.
5. Use blunt dissection to remove the remainder of the posterior wall of the pericardium. Leave the portion adhering to the diaphragm undisturbed. Use scissors to cut the pericardium at its attachments to the great vessels and diaphragm and place the pericardium in the tissue container. **[G 80; N 228; R 264; C 148]**
6. Use blunt dissection to clean the **esophagus**. Note that the surface of the esophagus is covered by the **esophageal plexus of nerves** (Fig. 3.30). The esophageal plexus innervates the inferior portion of the esophagus.
7. Identify the **right vagus nerve** posterior to the root of the right lung (Fig. 3.31). Follow the right vagus nerve inferiorly and verify that its fibers spread out on the surface of the esophagus.
8. Identify the **left vagus nerve** as it crosses the left side of the arch of the aorta. Follow the left vagus nerve posterior to the root of the left lung and confirm that its fibers contribute to the esophageal plexus.

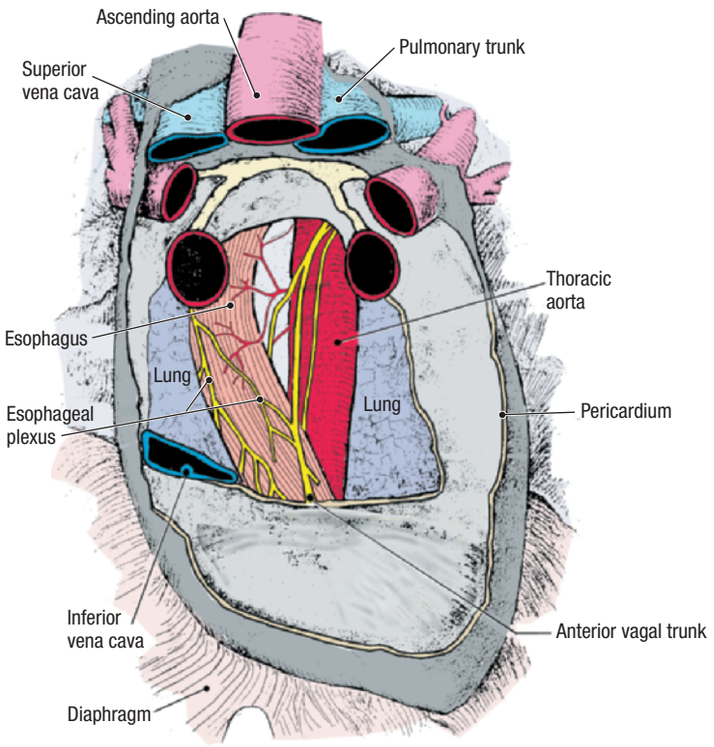

Figure 3.30. The relationship of the posterior mediastinum to the pericardium.

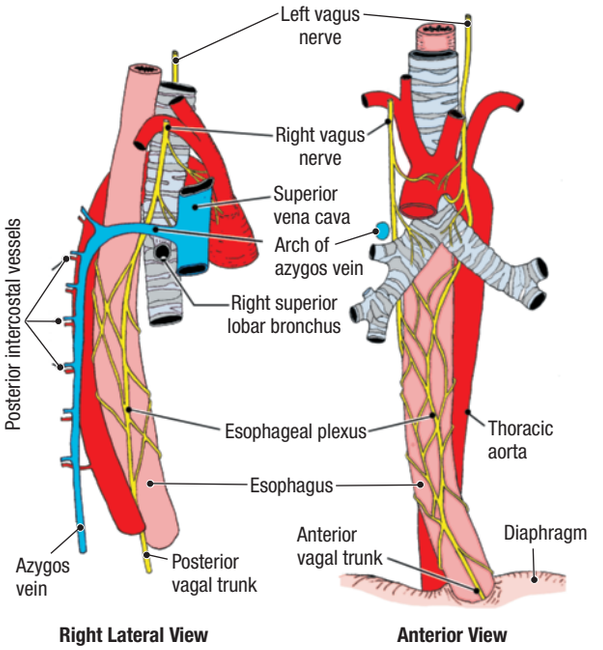

Figure 3.31. Contents of the posterior mediastinum.

9. Identify the **anterior vagal trunk** and the **posterior vagal trunk**. The vagal trunks are found on the inferior part of the esophagus, just before it passes through the diaphragm (Fig. 3.31). The vagal trunks pass through the diaphragm with the esophagus to supply a large part of the gastrointestinal tract.
10. Use an illustration to study the **azygos system of veins**. **[G 76; N 234; R 269; C 149]**
11. Identify the **azygos vein** where it arches superior to the root of the right lung (Fig. 3.31). Clean the azygos vein and follow it inferiorly to the level of the diaphragm. Note that the **posterior intercostal veins** on the right side are tributaries to the azygos vein. **[G 80; N 234; R 269; C 149]**
12. On the left side of the posterior mediastinum, observe that the left posterior intercostal veins drain into the **hemiazygos vein** and **accessory hemiazygos vein**. Note that variations of the azygos system are common.
13. Identify the **thoracic duct**. To find the thoracic duct, retract the esophagus to the left and explore the interval between the **azygos vein** and the **thoracic aorta**. The thoracic duct lies immediately to the left of the azygos vein and is posterior to the esophagus. The thoracic duct is thin-walled and easily torn. It has the appearance of a small vein without blood in it. **[G 74; N 305; R 267; C 149]**
14. Use a probe to free the thoracic duct from the surrounding connective tissue. The thoracic duct may be a network of several small ducts instead of a single duct. The thoracic duct passes through the diaphragm with the thoracic aorta. Superiorly, the thoracic duct drains into the junction of the left internal jugular vein and left subclavian vein. Do not demonstrate its termination at this time.

15. Note that the thoracic duct crosses the anterior surface of the **right posterior intercostal arteries**, the **hemiazygos vein,** and the **accessory hemiazygos vein**. Demonstrate the veins but preserve the thoracic duct.
16. Identify the **thoracic aorta.** Use a probe to clean it from the surrounding connective tissue.
17. Identify **esophageal arteries** and **bronchial arteries.** Both types of arteries are unpaired vessels that arise from the anterior surface of the aorta. They are distinguished by their area of distribution.
18. Dissect one pair of **posterior intercostal arteries** (right and left). Follow them to the intercostal space. Note that the right posterior intercostal arteries cross the midline on the anterior surface of the vertebral bodies. The right posterior intercostal arteries pass posterior to all other contents of the posterior mediastinum.
19. On both sides, identify and clean one **intercostal nerve**. Follow it laterally until it disappears posterior to the **innermost intercostal muscle**.
20. On both sides of the thorax, identify the **sympathetic trunk**. Starting high in the thorax, follow the sympathetic trunk inferiorly and observe that it crosses the heads of ribs 2 to 9. Inferior to rib 9, observe that the sympathetic trunk lies on the sides of the thoracic vertebral bodies. **[G 80; N 236; R 270; C 152]**
21. Observe that the sympathetic trunk has one **sympathetic ganglion** for each thoracic segment.
22. Demonstrate that two **rami communicantes** (**white ramus communicans, gray ramus communicans**) connect each intercostal nerve with its corresponding thoracic sympathetic ganglion. During dissection, it is impossible to distinguish white and gray rami from each other based on color.
23. Use a probe to dissect the **greater splanchnic nerve** on both the right and left sides. Note that the greater splanchnic nerve receives contributions from the fifth through the ninth thoracic sympathetic ganglia and that it is not completely formed until lower thoracic levels. As an aid to identification, observe that the greater splanchnic nerve is found on the sides of vertebral bodies T5 to T9, whereas the sympathetic trunk crosses the heads of ribs 5 to 9 (i.e., the sympathetic trunk is located more posteriorly).
24. The **lesser splanchnic nerve** arises from the tenth and eleventh thoracic sympathetic ganglia. The **least splanchnic nerve** arises from the twelfth thoracic sympathetic ganglion. Because of the curvature of the diaphragm, these two nerves cannot be seen at this time.

After you dissect . . .

Review the boundaries of the anterior, middle, and posterior mediastina. Study a transverse section through the mid-level of the thorax and identify the contents of the posterior mediastinum. Note the relationship of the contents of the posterior mediastinum to the heart and vertebral bodies. Review the course and function of an intercostal nerve, naming all structures that it innervates. Review the parts of the aorta (ascending, arch, thoracic), naming all branches and describing their distribution. Review the origin and course of the right and left posterior intercostal arteries. Name the structures in the posterior mediastinum that course anterior to the right posterior intercostal arteries.

CHAPTER 4

ABDOMEN

The abdomen is the portion of the trunk that lies between the thorax and the pelvis. The abdominal cavity is divided from the thoracic cavity by the diaphragm but it is continuous with the pelvic cavity. Viscera contained within the abdominal cavity are not bilaterally symmetrical. Therefore, it is worth noting that use of the words "right" and "left" in names and instructions refers to the right and left sides of the cadaver in the anatomical position.

SURFACE ANATOMY

Firm fixation of tissues in the cadaver may make it difficult to distinguish between bony landmarks and well-fixed soft tissue structures. Place the cadaver in the supine position and palpate the following structures (Fig. 4.01): **[N 239]**

- **Xiphoid process**
- **Costal margin**
- **Pubic symphysis**
- **Pubic crest**
- **Pubic tubercle**

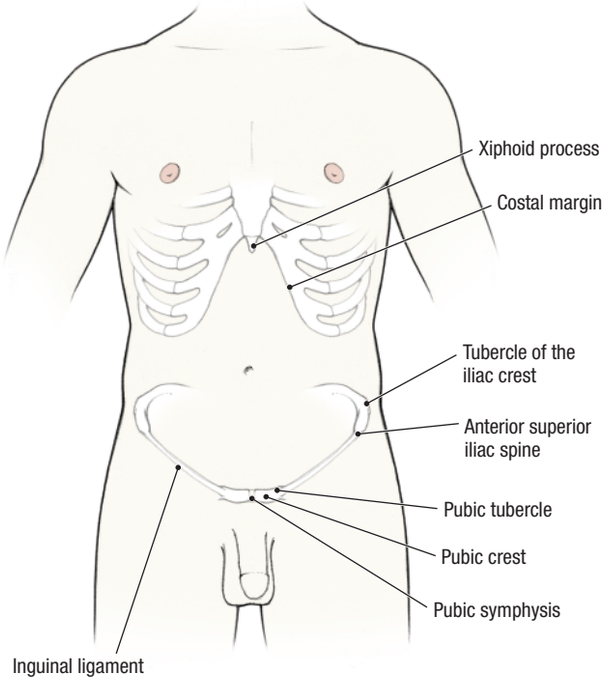

Figure 4.01. Surface anatomy of the abdomen.

KEY TO REFERENCES
G = Grant's Atlas, 11th ed., page number
N = Netter's Atlas, 3rd ed., plate number
R = Rohen's Color Atlas of Anatomy, 5th ed., page number
C = Clemente's Atlas, 4th ed., page number

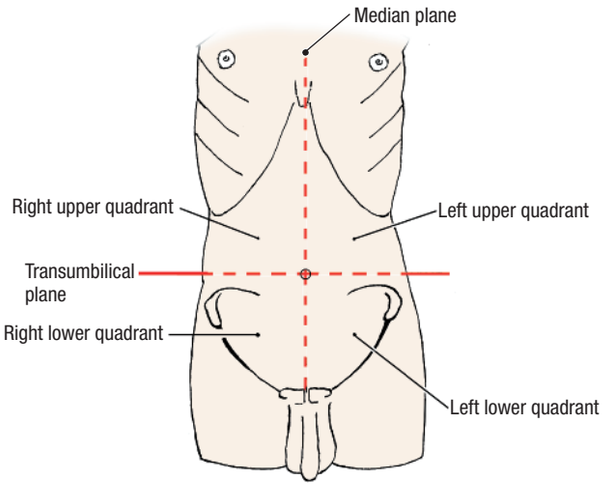

Figure 4.02. The four abdominal quadrants.

- **Inguinal ligament**
- **Anterior superior iliac spine**
- **Tubercle of the iliac crest**

To prepare patient notes, you will need to understand the terminology used to describe the abdomen. The quadrant and regional systems are in common use. The **quadrant system** divides the abdomen by means of the transumbilical plane and the median plane (Fig. 4.02). The quadrant system is suitable for general descriptions and will be used to describe the position of organs in this dissection guide. The **regional system** divides the abdomen based on the right and left midclavicular lines, the subcostal plane and the transtubercular plane (Fig. 4.03). Clinical symptoms may be more specifically described using the regional system.

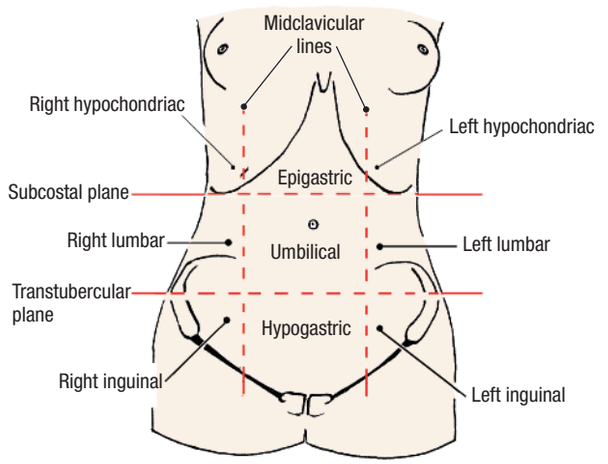

Figure 4.03. The nine abdominal regions.

SUPERFICIAL FASCIA OF THE ANTEROLATERAL ABDOMINAL WALL

Before you dissect . . .

The contents of the abdominal cavity are protected by the anterolateral abdominal wall. The organization of the layers forming the anterolateral abdominal wall is illustrated in Figure 4.04. The superficial fascia is unique in this region in that it has a **fatty (superficial) layer** called **Camper's fascia** and a **membranous (deep) layer** called **Scarpa's fascia**. The membranous layer is noteworthy, because it is continuous with named fascias in the perineum. **[G 99; N 244; R 203; C 168]**

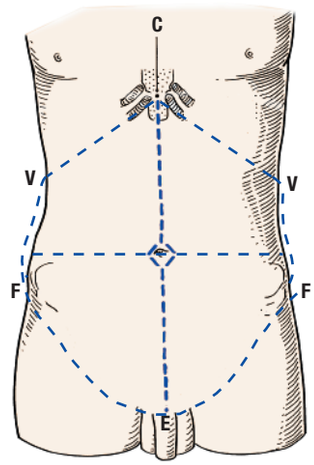

Figure 4.05. Skin incisions.

Dissection Instructions

SKIN INCISIONS

1. Refer to Figure 4.05.
2. Make a midline skin incision from the xiphisternal junction (C) to the pubic symphysis (E), encircling the umbilicus.
3. Make an incision from the xiphoid process (C) along the costal margin to a point on the midaxillary line (V). If the thorax has been dissected previously, this incision has been made.
4. Make a transverse skin incision from the umbilicus to the midaxillary line.
5. Make a skin incision beginning 2 cm below the pubic crest (E). Extend this incision laterally, 2 cm inferior to the inguinal ligament to a point 2 cm below the anterior superior iliac spine. Continue the incision posteriorly, 2 cm below the iliac crest to a point on the midaxillary line (F).
6. Make a vertical skin incision along the midaxillary line from point "V" to point "F."
7. Reflect the skin from medial to lateral, detach it along the midaxillary line, and place it in the tissue container.

SUPERFICIAL FASCIA

1. Use a probe to tear through the superficial fascia approximately 7.5 cm lateral to the midline (Fig. 4.06).

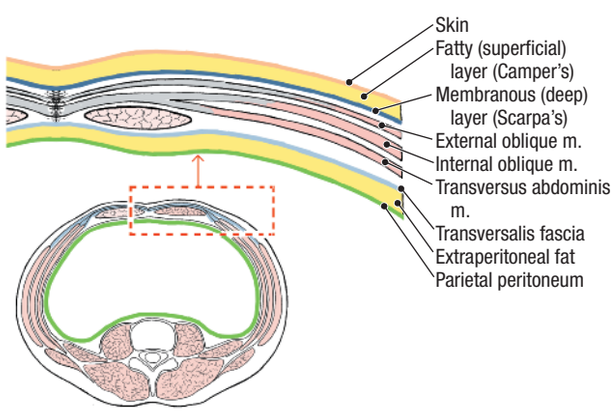

Figure 4.04. Layers of the anterior abdominal wall.

The **superficial epigastric artery and vein** are in the superficial fascia in this area, but do not make a special effort to find them.

2. Dissect through the superficial fascia down to the aponeurosis of the external oblique muscle. On the medial side of the incision, use your fingers to separate the superficial fascia from the aponeurosis of the external oblique muscle (Fig. 4.06, arrow 1).

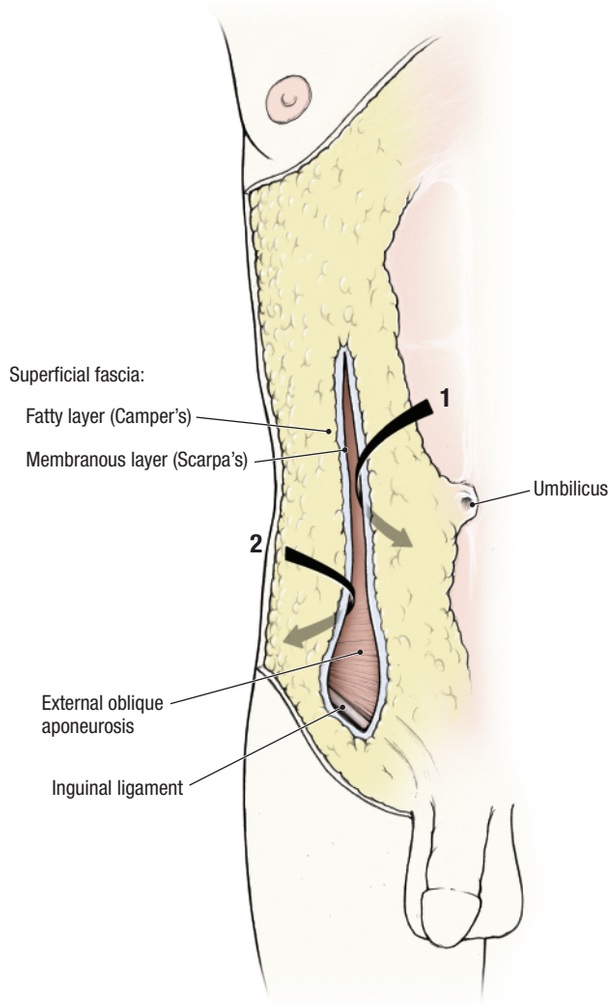

Figure 4.06. Removal of the abdominal superficial fascia.

3. As you approach the midline, palpate the **anterior cutaneous nerves** that enter the superficial fascia approximately 2 to 3 cm lateral to the midline. Clean one anterior cutaneous nerve. Anterior cutaneous nerves are branches of the **thoracoabdominal nerves (T7–T11)**, **the subcostal nerve (T12), and the iliohypogastric and ilioinguinal nerves (L1)**. Consult a dermatome chart and note that: **[G 331; N 157; C 159]**
   - T7 innervates the skin overlying the xiphoid process.
   - T10 innervates the skin of the umbilicus.
   - T12 innervates the skin superior to the pubic symphysis.
   - L1 innervates the skin overlying the pubic symphysis. **[G 97; N 249; R 204; C 161]**
4. Lateral to the incision, use your fingers to separate the superficial fascia from the external oblique muscle (Fig. 4.06, arrow 2). As you near the midaxillary line, palpate the **lateral cutaneous nerves** entering the superficial fascia. The lateral cutaneous nerves are branches of thoracoabdominal nerves. Clean the branches of one lateral cutaneous nerve.
5. Remove the superficial fascia in an inferior direction until the lower border of the external oblique muscle is exposed (approximately 2.5 cm into the proximal thigh).
6. Detach the superficial fascia from the midline, midaxillary line, and proximal thigh and place it in the tissue container.

After you dissect . . .

Use an illustration to review the distribution of the superficial epigastric vessels. Review the abdominal distribution of the ventral primary rami of spinal nerves T7 to L1.

CLINICAL CORRELATION

Superficial Veins of the Abdominal Wall

The superficial epigastric vein anastomoses with the lateral thoracic vein in the superficial fascia. This is an important collateral venous channel from the femoral vein to the axillary vein. In patients who have an obstruction of the inferior vena cava or hepatic portal vein, the superficial veins of the abdominal wall are engorged and become visible around the umbilicus (**caput medusae**).

MUSCLES OF THE ANTEROLATERAL ABDOMINAL WALL

Before you dissect . . .

Three flat muscles (external oblique, internal oblique, and transversus abdominis) form most of the anterolateral abdominal wall. The rectus abdominis muscle completes the anterior abdominal wall near the midline. The three flat muscles have fleshy proximal attachments (to the ribs, vertebrae, and the pelvis) and broad, aponeurotic distal attachments (to the ribs, linea alba, and pubis). Each of the three flat muscles contributes to the formation of the rectus sheath and the inguinal canal.

In the male, the testes are housed in the scrotum, which is an outpouching of the anterior abdominal wall. Each testis passes through the abdominal wall during development, dragging its ductus deferens behind it. This passage occurs through the **inguinal canal**. The inguinal canal is located superior to the medial half of the inguinal ligament and extends from the **superficial (external) inguinal ring** to the **deep (internal) inguinal ring**. In the female, the inguinal canal is smaller in diameter.

It must be noted that the structures forming the inguinal canal are identical in the two sexes, but the *contents* of the inguinal canal differ. In the male, the inguinal canal contains the **spermatic cord**, whereas in the female the inguinal canal contains the **round ligament of the uterus**. Dissection instructions are provided for male cadavers, but these instructions are applicable to female cadavers

The order of dissection will be as follows. The three flat muscles of the abdominal wall will be studied, particularly in the inguinal region. The composition and contents of the rectus sheath will be explored. The anterior abdominal wall will be reflected.

SKELETON OF THE ABDOMINAL WALL

Use a skeleton to identify the following structures (Fig. 4.07): **[G 10, 185; N 240; R 185; C 95, 253]**

- **Xiphisternal junction**
- **Xiphoid process**
- **Costal margin**
- **Pubic symphysis**
- **Pubic crest**
- **Pubic tubercle**
- **Anterior superior iliac spine**
- **Iliac crest**
- **Tubercle of the iliac crest**

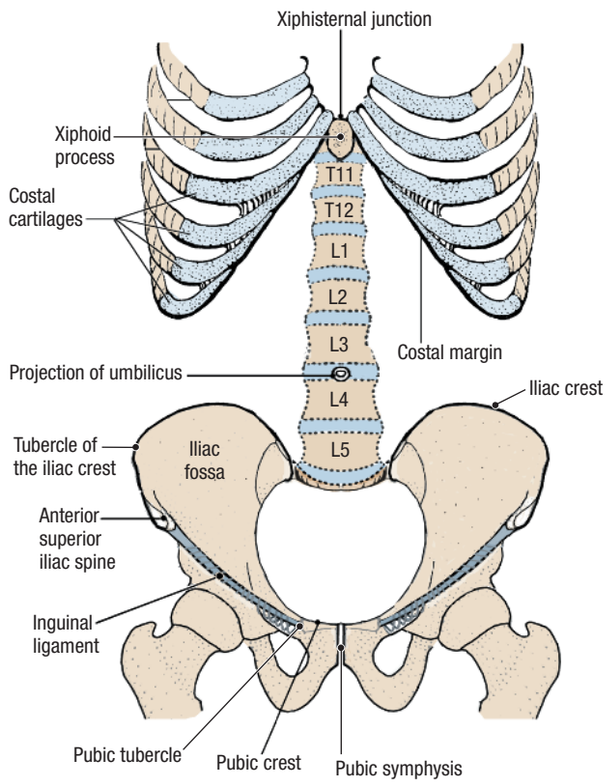

Figure 4.07. Skeleton of the anterior abdominal wall.

Dissection Instructions

EXTERNAL OBLIQUE MUSCLE [G 97; N 241; R 200; C 162]

The external oblique muscle forms the most superficial layer (first arch) of the inguinal canal (Fig. 4.08A, B).

1. Observe the **external oblique muscle**. The proximal attachments of the external oblique muscle are the external surfaces of ribs 5 to 12. The distal attachments of the external oblique muscle are the linea alba, pubic tubercle, and anterior half of the iliac crest. Observe that the fibers of the external oblique muscle course from superolateral to inferomedial.

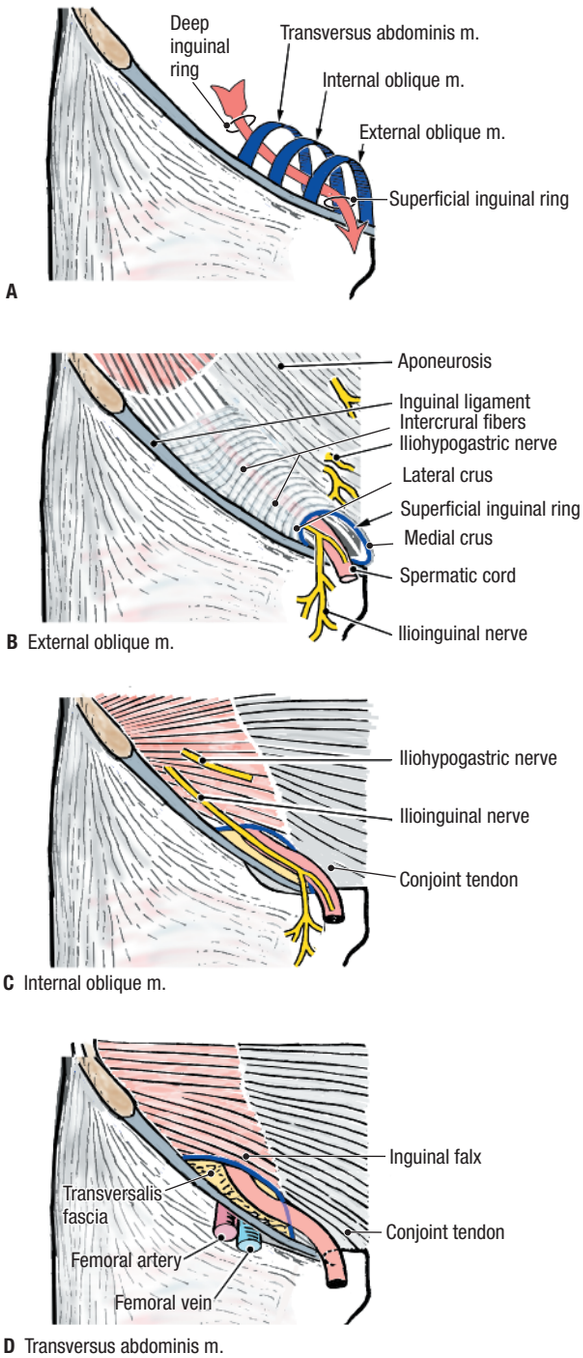

Figure 4.08. Contributions of the flat abdominal muscles to the inguinal canal.

2. In the inguinal region, use blunt dissection to clean the aponeurosis of the external oblique muscle. Gentle scraping motions with a dull scalpel blade yield good results. Be careful not to damage the **spermatic cord** (or **round ligament of the uterus**) where it emerges from the superficial inguinal ring. [G 100, 104; N 241; R 207, 210; C 163]
3. Identify the **superficial inguinal ring** (Fig. 4.08B), which is an opening in the external oblique aponeurosis.
4. Identify the **lateral (inferior) crus**. The lateral crus is the portion of the external oblique aponeurosis that forms the lateral margin of the superficial inguinal ring.
5. Identify the **medial (superior) crus**. The medial crus is the portion of the external oblique aponeurosis that forms the medial margin of the superficial inguinal ring.
6. Identify the **intercrural fibers**. Intercrural fibers span across the crura superolateral to the superficial inguinal ring. They prevent the crura from spreading apart.
7. Note that the **ilioinguinal nerve** emerges from the inguinal canal at the superficial inguinal ring, anterior to the spermatic cord (or round ligament of the uterus). The ilioinguinal nerve supplies sensory fibers to the skin of the external genitalia and the medial aspect of the thigh.
8. Identify the **inguinal ligament**. It is the inferior border of the aponeurosis of the external oblique muscle. Palpate the attachments of the inguinal ligament to the anterior superior iliac spine and to the pubic tubercle. Vessels and nerves exit the abdominal cavity and enter the lower limb by passing deep to the inguinal ligament.

INTERNAL OBLIQUE MUSCLE [G 98; N 242; R 202; C 164]

The internal oblique muscle lies deep to the external oblique muscle. The internal oblique muscle forms the intermediate layer (second arch) of the inguinal canal (Fig. 4.08A, C). To expose the internal oblique muscle, the external oblique muscle must be transected and reflected (Fig. 4.09). Perform this transection bilaterally.

1. In the midaxillary line at the level of the umbilicus, insert closed scissors between the fibers of the external oblique muscle. Open the scissors parallel to the fiber direction to split the external oblique muscle (Fig. 4.09A, cut 1). Make an opening that extends inferiorly as far as the anterior superior iliac spine.
2. Insert your fingers into cut 1 and use blunt dissection to separate the fibers of the external oblique muscle from the underlying internal oblique muscle.
3. Direct your fingers medially in the transumbilical plane and create a tunnel between the external oblique and internal oblique muscles. Note that your fingers cannot pass medial to the semilunar line because the external oblique aponeurosis is fused to the internal oblique aponeurosis.

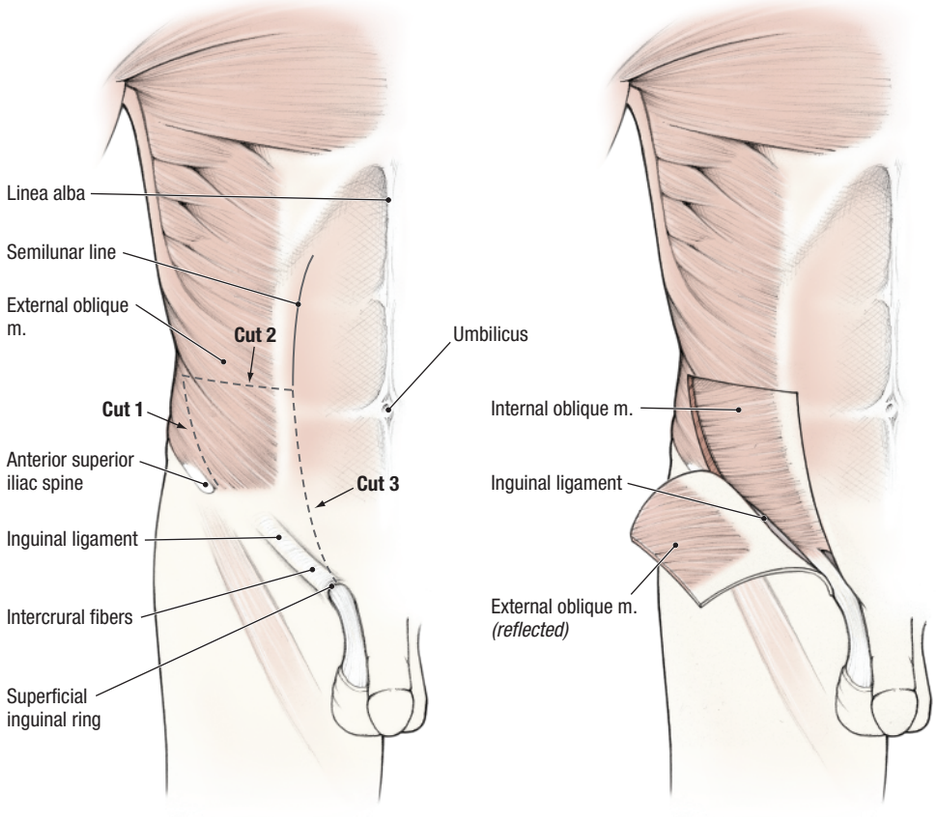

Figure 4.09. Cuts used to reflect the external oblique muscle.

4. Use scissors to cut the external oblique muscle in the transumbilical plane. Extend the cut as far medially as the semilunar line (Fig. 4.09A, cut 2).
5. Inferior to cut 2, use your fingers to separate the external oblique muscle from the internal oblique muscle. Be gentle as you approach the superficial inguinal ring.
6. Using scissors, make an incision from the medial end of cut 2 to the superior margin of the superficial inguinal ring (Fig. 4.09A, cut 3). Cut 3 should follow the lateral side of the semilunar line and cut only the external oblique aponeurosis.
7. Reflect the external oblique muscle in an inferior and lateral direction to reveal the lower half of the internal oblique muscle (Fig. 4.09B).
8. Identify the **internal oblique muscle**. The proximal attachments of the internal oblique muscle are the thoracolumbar fascia, the iliac crest, and the lateral half of the inguinal ligament. The distal attachments of the internal oblique muscle are the inferior border of ribs 10 to 12, the linea alba, the pubic crest, and the pecten pubis.
9. Observe the portion of the internal oblique muscle that arises from the lateral part of the inguinal ligament (Fig. 4.10). Note that this portion of the muscle arches medially to its distal attachment on the pecten pubis and contributes to the roof of the inguinal canal. **[G 101, 105; N 242; R 207, 210; C 165]**
10. Lateral to the spermatic cord (or round ligament of the uterus), observe muscle fibers connecting the internal oblique muscle with the spermatic cord (Fig. 4.10). This is the layer of **cremaster muscle and fas-**

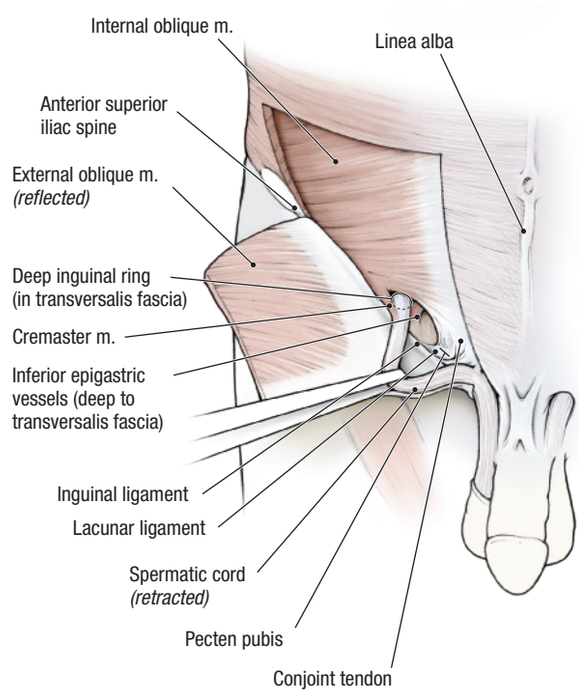

Figure 4.10. The internal oblique muscle in the inguinal region.

cia, which is the contribution of the internal oblique muscle to the coverings of the spermatic cord. In the female, the cremaster muscle and fascia surround the round ligament of the uterus.

11. Once again, find the **ilioinguinal nerve**, which courses through the inguinal canal to emerge at the superficial inguinal ring (Fig. 4.08C). Also, identify the **iliohypogastric nerve**, which runs parallel and superior to the ilioinguinal nerve.
12. Just medial to the superficial inguinal ring the aponeurosis of the internal oblique becomes fused with the aponeurosis of the transversus abdominis muscle to form the **conjoint tendon** (Fig. 4.08C).

TRANSVERSUS ABDOMINIS MUSCLE [G 98; N 243; R 205; C 167]

The **transversus abdominis muscle** lies deep to the internal oblique muscle. The transversus abdominis muscle forms the deepest layer (third arch) of the inguinal canal (Fig. 4.08A, D). In the inguinal region, the transversus abdominis muscle has attachments and fiber directions that are similar to the internal oblique muscle.

1. Use an illustration to study the proximal attachments, distal attachments, and fiber direction of the transversus abdominis muscle. The proximal attachments of the transversus abdominis muscle are the internal surfaces of the costal cartilages of ribs 7 to 12, the thoracolumbar fascia, the iliac crest, and the lateral third of the inguinal ligament. The distal attachments of the transversus abdominis muscle are the linea alba, the pubic crest, and the pecten pubis. **[G 102; N 243; R 208; C 181]**

Dissection note: The transversus abdominis muscle is often difficult to separate from the internal oblique muscle because their tendons are fused near their distal attachments (conjoint tendon), and the muscle bellies adhere to each other laterally. If you are not required to separate the internal oblique muscle from the transversus abdominis muscle, go to the section entitled "Deep Inguinal Ring." If you are required to separate the internal oblique muscle from the transversus abdominis muscle, proceed with the next dissection step.

2. Use a probe to follow the ilioinguinal nerve superolaterally until it enters the internal oblique muscle (Fig. 4.08C).
3. Insert a pair of closed scissors into the internal oblique muscle superficial to the course of the ilioinguinal nerve and open the scissors parallel to the fiber direction to split the muscle. Follow the ilioinguinal nerve proximally and use it as a guide to find the plane between the internal oblique and transversus abdominis muscles.
4. Insert your finger through the split and into the plane between the internal oblique and transversus abdominis muscles. Push your finger inferiorly and medially to separate the muscles. Proceed until you reach the inferior borders of the two muscles. Observe that the aponeuroses of the two muscles are inseparable near their attachment to the pecten pubis (conjoint tendon).
5. Note that the inferior free edge of the transversus abdominis muscle is slightly superior to the inferior free edge of the internal oblique muscle. Below the arch formed by these two muscles, the abdominal wall is unsupported by muscle. This weak point occurs directly posterior to the superficial inguinal ring.

DEEP INGUINAL RING [G 103; N 251; R 208; C 181]

Transversalis fascia lines the inner surface of the abdominal muscles (Fig. 4.04). The **deep inguinal ring** is the point at which the testis passed through the transversalis fascia during development. The deep inguinal ring is located superior to the midpoint of the inguinal ligament and it marks the deep extent of the inguinal canal. In the male, the ductus deferens passes through the deep inguinal ring. In the female, the round ligament of the uterus passes through the deep inguinal ring.

1. Use a probe to lift the inferior margin of the fused internal oblique and transversus abdominis muscles.
2. Use blunt dissection to separate the transversus abdominis muscle from the transversalis fascia.
3. Retract the spermatic cord (or round ligament of the uterus) laterally and observe the **inferior epigastric vessels** through the transversalis fascia (Fig. 4.10). The inferior epigastric vessels are located within the layer of extraperitoneal (endoabdominal) fat.
4. The location of the deep inguinal ring is lateral to the inferior epigastric vessels and is identified by the presence of the ductus deferens (or round ligament of the uterus).
5. To review, the **boundaries of the inguinal canal** are (Fig. 4.08):
   - **Deep –** deep inguinal ring
   - **Superficial –** superficial inguinal ring
   - **Anterior –** aponeurosis of the external oblique muscle
   - **Inferior** (floor) **–** inguinal ligament
   - **Superior** (roof) **–** the arching fibers of the internal oblique and the transversus abdominis muscles
   - **Posterior –** transversalis fascia, reinforced medially by the conjoint tendon

CLINICAL CORRELATION

Inguinal Hernias

The inguinal canal is a weak area of the abdominal wall through which abdominal viscera may protrude (inguinal hernia). The identifying characteristic of an inguinal hernia is its position relative to the inferior epigastric vessels. An **indirect inguinal hernia** exits the abdominal cavity through the deep inguinal ring *lateral* to the inferior epigastric vessels, and it follows the inguinal canal (an indirect course through the abdominal wall) (Fig. 4.11B). In contrast, a **direct inguinal hernia** exits the abdominal cavity *medial* to the inferior epigastric vessels and takes a direct course through the abdominal wall (Fig. 4.11C).

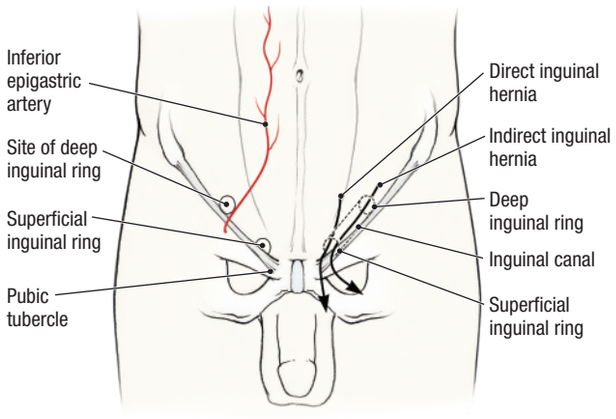

A Inguinal hernias

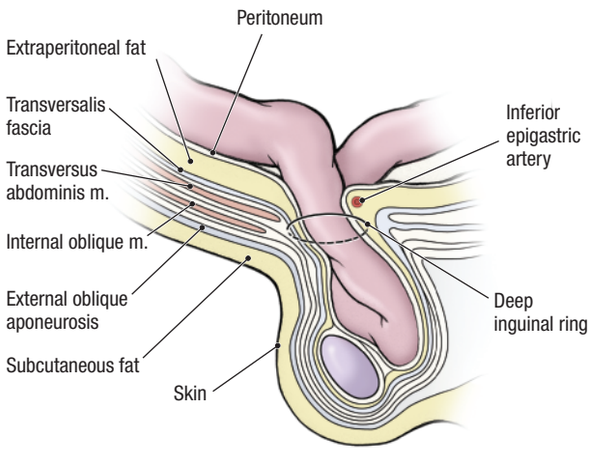

B Indirect inguinal hernia

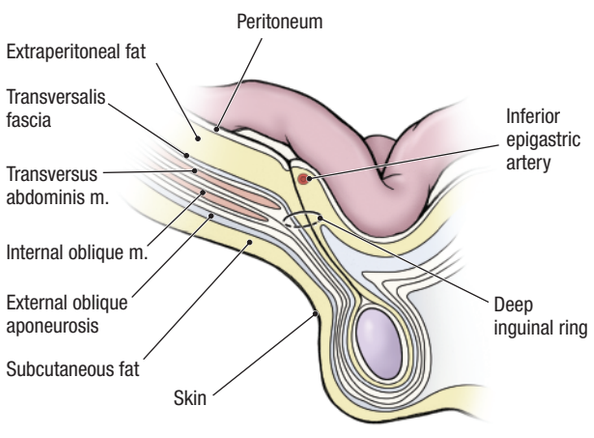

C Direct inguinal hernia

Figure 4.11. Inguinal hernias. **A.** Anatomical relationships and course through the abdominal wall. **B.** An indirect inguinal hernia leaves the abdominal cavity lateral to the inferior epigastric vessels and passes down the inguinal canal. **C.** A direct inguinal hernia leaves the abdominal cavity medial to the inferior epigastric vessels.

RECTUS ABDOMINIS MUSCLE [G 97; N 242; R 201; C 167]

The **rectus sheath** is formed by the aponeuroses of the three flat abdominal muscles. The rectus sheath contains the **rectus abdominis muscle**, the **superior** and **inferior epigastric vessels**, the terminal ends of the ventral primary rami of spinal nerves T7 to T12, and the **pyramidalis muscle**.

1. Reposition the internal oblique and external oblique muscles. The following cuts should be made bilaterally.
2. Use scissors to make a transverse incision across the anterior surface of the rectus sheath at the level of the umbilicus (Fig. 4.12, cut 1). Begin the cut approximately 2.5 cm lateral to the umbilicus and continue laterally as far as the semilunar line.
3. Use scissors to cut the rectus sheath along the medial border of the **rectus abdominis muscle** (Fig. 4.12, cut 2). This incision should extend in a superior direction, approximately 2.5 cm from the midline. Stop at the costal margin.
4. Extend the vertical incision inferiorly along the medial border of the rectus abdominis muscle (Fig. 4.12, cut 3). Cut 3 should be approximately 1.2 cm from the midline and stop at the pubic crest.
5. Insert your fingers into the vertical incision and bluntly dissect the anterior wall of the rectus sheath from the anterior surface of the rectus abdominis muscle. Observe that the anterior wall of the rectus sheath is firmly attached to the anterior surface of the rectus muscle by several **tendinous intersections** (Fig. 4.13). Use scissors to cut the tendinous intersections and free the rectus sheath from the rectus abdominis muscle.
6. Observe the **rectus abdominis muscle** (Fig. 4.13). The inferior attachment of the rectus abdominis muscle is the symphysis and body of the pubis. The superior attachment of the rectus abdominis muscle is onto the costal cartilages of ribs 5 to 7. The rectus abdominis muscle flexes the trunk.

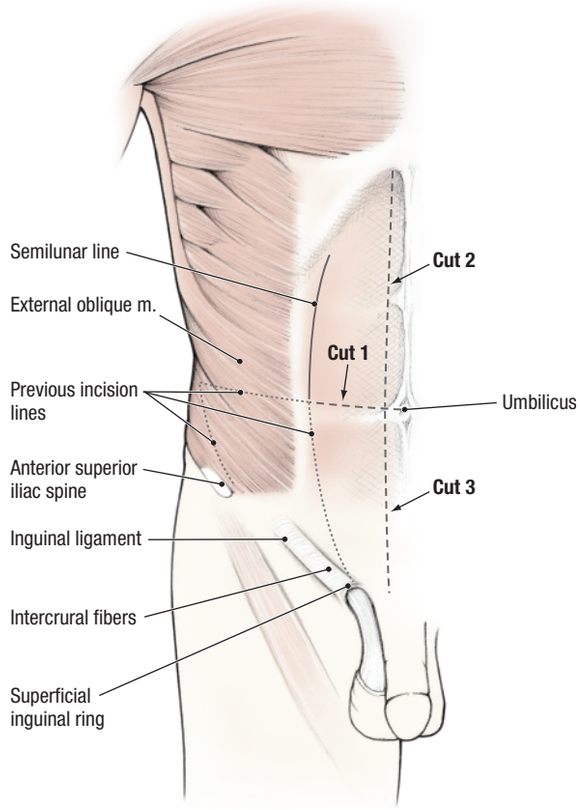

Figure 4.12. Cuts used to open the rectus sheath.

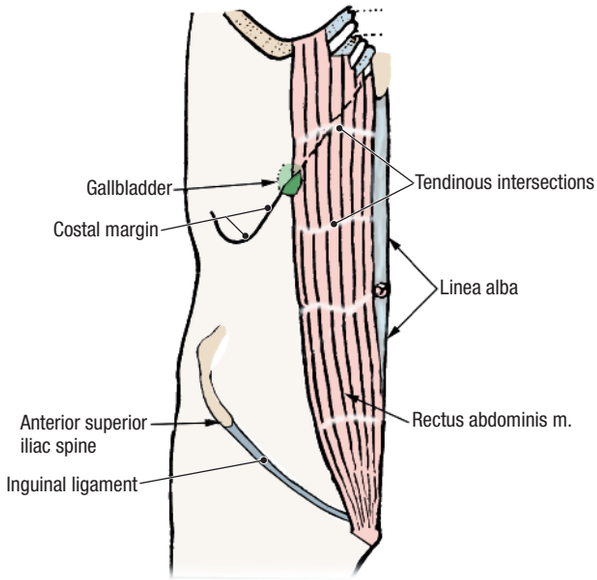

Figure 4.13. Rectus abdominis muscle.

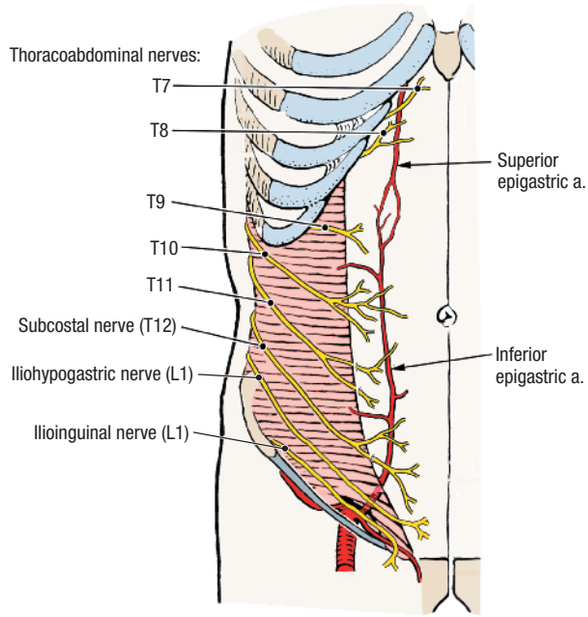

Figure 4.14. Nerves and arteries within the rectus sheath. The rectus abdominis muscle has been removed.

7. Observe that the branches of six thoracoabdominal nerves (T7–T12) enter the lateral side of the rectus sheath (Fig. 4.14). These nerves innervate the rectus abdominis muscle then continue toward the midline as **anterior cutaneous nerves**. **[G 98; N 249; R 206; C 170]**
8. Use your fingers to mobilize the medial border of the rectus abdominis muscle. At the level of the umbilicus, transect the rectus abdominis muscle with scissors. Reflect the two halves superiorly and inferiorly, respectively. If the thoracoabdominal nerves prevent full reflection of the rectus abdominis muscle, cut them along the lateral border of the muscle.
9. Observe the **superior epigastric artery and vein** on the posterior (deep) surface of the superior half of the rectus abdominis muscle. **[G 98; N 247; R 206; C 170]**
10. Observe the **inferior epigastric artery and vein** on the posterior surface of the inferior half of the rectus abdominis muscle.

CLINICAL CORRELATION

Epigastric Anastomoses

The superior epigastric vessels anastomose with the inferior epigastric vessels within the rectus sheath (Fig. 4.14). If the inferior vena cava becomes obstructed, the anastomosis between the inferior epigastric and superior epigastric veins provides a collateral venous channel that drains into the superior vena cava. If the aorta is occluded, collateral arterial circulation to the lower part of the body occurs through the superior and inferior epigastric arteries.

11. Examine the posterior wall of the rectus sheath (Fig. 4.15). Identify the **arcuate line,** which is located midway between the pubic symphysis and the umbilicus. The arcuate line is the inferior limit of the posterior wall of the rectus sheath, and it may be indistinct. At the level of the arcuate line, the inferior epigastric vessels enter the rectus sheath.
12. Inferior to the arcuate line, observe the **transversalis fascia** and, deep to it, the **parietal peritoneum** (Fig. 4.15).
13. In the midline, observe the **linea alba**. The linea alba is formed by the fusion of the aponeuroses of the right and left flat abdominal muscles (external oblique, internal oblique, and transversus abdominis).
14. Anterior to the inferior end of the rectus abdominis muscle, look for the **pyramidalis muscle**. It is frequently absent. When present, the pyramidalis muscle attaches to the anterior surface of the pubis and the linea alba and it draws down on the linea alba.

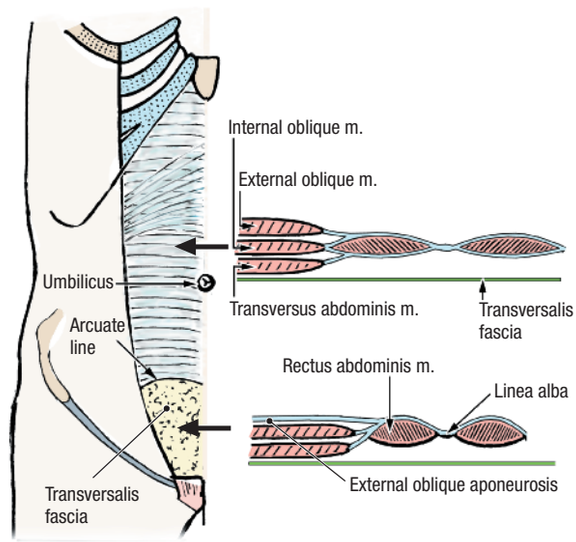

Figure 4.15. Posterior wall of the rectus sheath (left) and transverse sections of the rectus sheath at the two levels indicated by the arrows.

After you dissect . . .

Replace the muscles of the anterior abdominal wall in their correct anatomical positions. Review the proximal attachment, distal attachment, and action of each muscle. Review the structures that form the nine layers of the abdominal wall (Fig. 4.04). Use the dissected specimen to review the rectus sheath at the level of the umbilicus and just superior to the pubic symphysis (Fig. 4.15). Review the nerve supply to the anterior abdominal wall. Review the blood supply to the anterior abdominal wall.

LABIUM MAJUS IN THE FEMALE; SCROTUM, SPERMATIC CORD, AND TESTIS IN THE MALE

Before you dissect . . .

The **scrotum** is an outpouching of the anterior abdominal wall, and most layers of the abdominal wall are represented in its structure (Fig. 4.16). The superficial fascia of the scrotum contains no fat. Instead, the superficial fascia is represented by **dartos fascia**, which contains smooth muscle fibers (**dartos muscle**).

The order of dissection will be as follows. The scrotum (labium majus) will be opened by an anterior incision. The spermatic cord (round ligament of the uterus in the female) will be followed into the scrotum (labium majus in the female). The testis will be removed from the scrotum. The spermatic cord will be dissected. The testis will be studied.

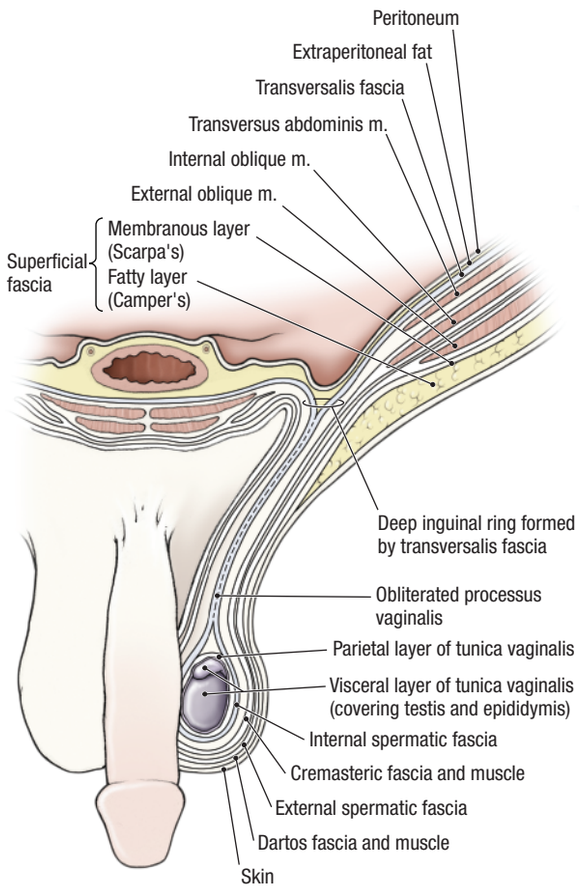

Figure 4.16. Contributions of the anterior abdominal wall to the coverings of the spermatic cord and testis.

Dissection Instructions

MALE AND FEMALE CADAVERS [G 104; R 210; C 176]

1. Partner with a dissection team that has a cadaver of the opposite sex for the following dissection.
2. Inferior to the superficial inguinal ring, insert your finger deep to the subcutaneous tissue of the lower anterior abdominal wall and push your finger into the scrotum. If you are dissecting a female cadaver, your finger will pass into the labium majus.
3. Use scissors to make an incision down the anterior surface of the scrotum (labium) through the skin, dartos, and superficial fascia.
4. Use your fingers to free the testis and spermatic cord from the scrotum. In the female cadaver, demonstrate that the round ligament of the uterus ends in the fatty tissue of the labium majus. This step completes the dissection of the female anatomy.

MALE CADAVER [G 107; N 370; R 329; C 182]

1. Observe a band of tissue that anchors the inferior pole of the testis to the scrotum. This is the **scrotal ligament** (the remnant of the gubernaculum testis).
2. Use scissors to cut the scrotal ligament. Use your fingers to remove the testis from the scrotum, but leave the testis attached to the spermatic cord.
3. Observe that the **scrotal septum** divides the scrotum into two compartments.

Spermatic Cord [G 108; N 370; R 329; C 182]

The spermatic cord contains the ductus deferens, testicular vessels, lymphatics, and nerves. The contents of the spermatic cord are surrounded by three fascial layers, the **coverings of the spermatic cord**, that are derived from layers of the anterior abdominal wall (Fig. 4.16). These coverings are added to the spermatic cord as it passes through the inguinal canal.

1. Study an illustration of a transverse section through the spermatic cord (Fig. 4.17).
2. Palpate the **ductus deferens (vas deferens)** within the spermatic cord. It is hard and cord-like.
3. Use a probe to longitudinally incise the **coverings of the spermatic cord**. The three coverings are fixed to each other at the time of embalming and cannot be

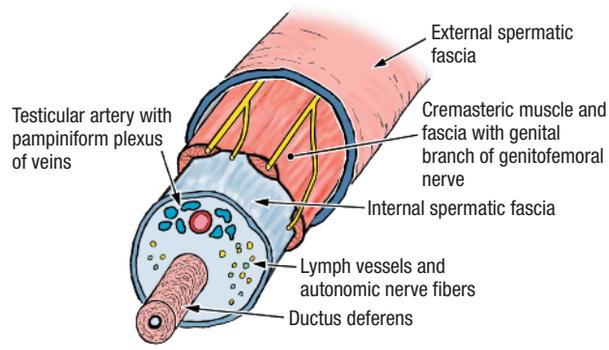

Figure 4.17. Transverse section through the spermatic cord.

separated. The coverings of the spermatic cord are (Fig. 4.16):

- **External spermatic fascia –** derived from the external oblique muscle
- **Cremasteric muscle and fascia –** derived from the internal oblique muscle
- **Internal spermatic fascia –** derived from the transversalis fascia

4. Use a probe to separate the ductus deferens from the **pampiniform plexus of veins**.
5. Follow the ductus deferens superiorly into the inguinal canal and toward the deep inguinal ring. Note that the ductus deferens passes through the deep inguinal ring lateral to the inferior epigastric vessels.
6. Use a probe to separate the **testicular artery** from the pampiniform plexus of veins. The testicular artery can be distinguished from the veins by its slightly thicker wall.
7. Note that sensory nerve fibers, autonomic nerve fibers, and lymphatic vessels accompany the blood vessels in the spermatic cord (Fig. 4.17), but they are too small to dissect.

CLINICAL CORRELATION

Vasectomy

The ductus deferens can be surgically interrupted in the superior part of the scrotum (vasectomy). As a precaution against reconnection, a small segment is removed. Sperm production in the testes continues but the spermatozoa cannot reach the urethra.

Testis [G 110; N 371; R 329; C 183, 184]

1. The testis is covered by the **tunica vaginalis**, a serous sac that is derived from the parietal peritoneum (Fig. 4.16). The tunica vaginalis has a visceral layer and a parietal layer (Fig. 4.18).
2. Use scissors to incise the parietal layer of the tunica vaginalis along its anterior surface and open it widely. Observe that the visceral layer of the tunica vaginalis covers the anterior, medial, and lateral surfaces of the testis, but not its posterior surface.
3. Use a probe to trace the ductus deferens inferiorly until it joins the epididymis. Identify the **tail**, **body**, and **head of the epididymis** (Fig. 4.18).
4. Use a scalpel to section the testis longitudinally from its superior pole to its inferior pole. Make the cut along its anterior surface. Use the epididymis as a hinge, and open the halves of the testis like a book.
5. Note the thickness of the **tunica albuginea**, which is the fibrous capsule of the testis. Observe the **septa** that divide the interior of the testis into **lobules** (Fig. 4.18).
6. Use a needle forceps to tease some of the **seminiferous tubules** out of one lobule.

CLINICAL CORRELATION

Lymphatic Drainage of the Testis

Lymphatics from the scrotum drain to the superficial inguinal lymph nodes. Inflammation of the scrotum may cause tender, enlarged superficial inguinal lymph nodes. In contrast, lymphatics from the testis follow the testicular vessels through the inguinal canal and into the abdominal cavity where they drain into lumbar (lateral aortic) nodes and preaortic lymph nodes. Testicular tumors may metastasize to lumbar and preaortic lymph nodes, not to superficial inguinal lymph nodes.

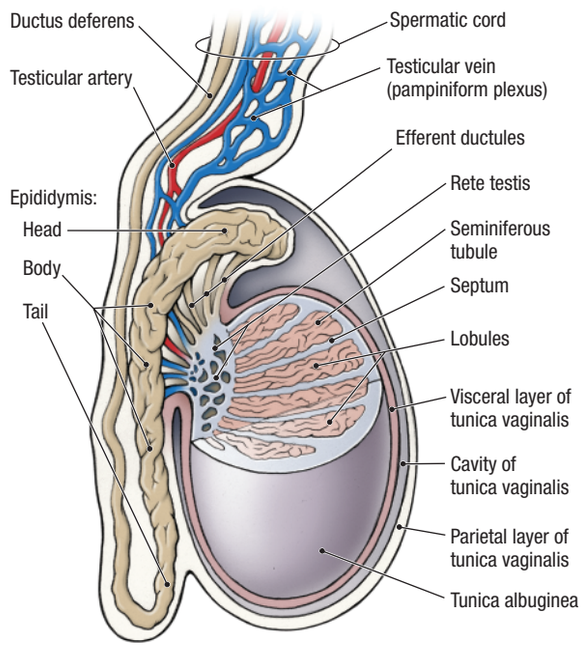

Figure 4.18. Parts of the testis and epididymis.

After you dissect . . .

Review the course of the ductus deferens from the abdominal wall to the testis. Review the coverings of the spermatic cord and recall the layers of the abdominal wall from which they are derived. Use an illustration to trace the route of spermatozoa from their origin in the seminiferous tubule to the ejaculatory duct.

REFLECTION OF THE ABDOMINAL WALL

Before you dissect . . .

The anterior abdominal wall will be reflected in such a way that the contents of the abdominopelvic cavity can be accessed, but the abdominal wall can be repositioned for review. The incision lines will be similar to the quadrant lines illustrated in Figure 4.02. The incisions are designed to give direct reference to the position of the abdominal organs within the abdominal quadrants.

The order of dissection is as follows. The anterior abdominal wall will be incised and opened. The inner surface of the anterior abdominal wall will be studied.

Dissection Instructions

1. Reflect the halves of the rectus abdominis muscles superiorly and inferiorly.
2. Refer to Figure 4.19. On the left side of the umbilicus, use scissors to create a small hole (2 cm) through the posterior wall of the rectus sheath, extraperitoneal fat, and parietal peritoneum.
3. Insert your finger through the hole into the abdominal cavity. Pull the posterior wall of the rectus sheath anteriorly to create a space between the abdominal wall and the abdominal viscera.
4. Use scissors to make a vertical incision through the linea alba to the xiphoid process (Fig. 4.19, cut 1). Stay 1 cm to the left of the midline to preserve the falciform ligament.
5. Extend the incision inferiorly as far as the pubic symphysis (Fig. 4.19, cut 2). Stay 1 cm to the left of the midline to preserve the median umbilical fold.
6. Return the rectus abdominis muscle and the external oblique muscle to their correct anatomical positions.
7. At the level of the umbilicus, place one hand through the vertical incision and raise the abdominal wall from the abdominal contents.
8. On the right side, use scissors to incise the posterior wall of the rectus sheath, extraperitoneal fat, and peritoneum in the transumbilical plane (Fig. 4.19, cut 3). The scissors should pass through the previous transverse cut that was made in the rectus abdominis muscle and the external oblique muscle. Extend the cut through all three flat abdominal muscles as far laterally as the midaxillary line. Duplicate the transverse cut on the left side.
9. Open the flaps of the abdominal wall.
10. Identify the **falciform ligament**, which is superior to the umbilicus. It is attached to the right upper quadrant flap. The falciform ligament connects the anterior abdominal wall to the surface of the liver. **[G 112; N 245; R 283; C 173]**
11. Identify the **median umbilical fold**, which is inferior to the umbilicus. It is attached to the right lower quadrant flap, but may have been cut longitudinally. The median umbilical fold contains the urachus (obliterated allantoic duct).
12. Identify the **medial umbilical fold**. There are two medial umbilical folds, one on each side of the median umbilical fold. The medial umbilical fold contains the obliterated umbilical artery.
13. Find a **lateral umbilical fold** just lateral to each medial umbilical fold. The lateral umbilical fold overlies the inferior epigastric artery and vein.
14. Lateral to the lateral umbilical fold, observe a small depression that marks the location of the **deep inguinal ring**.

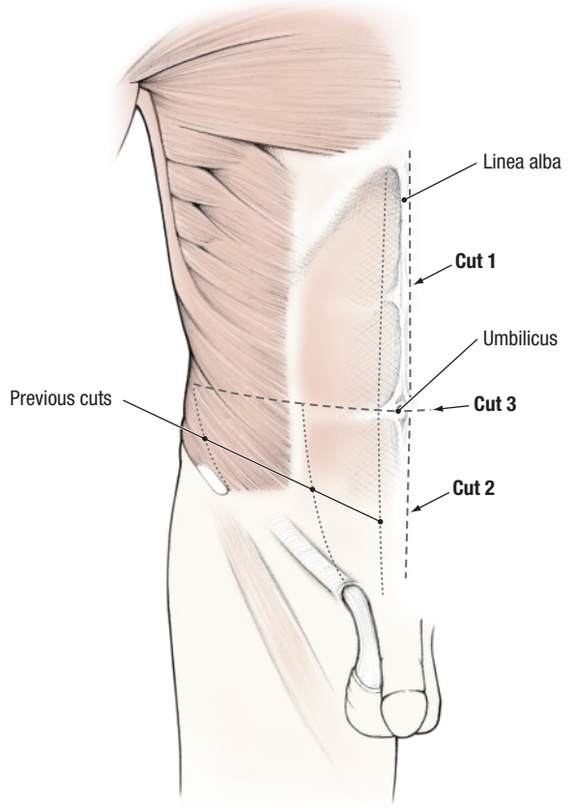

Figure 4.19. Cuts used to open the abdominal cavity.

PERITONEUM AND PERITONEAL CAVITY

Before you dissect . . .

All body cavities (thoracic cavity, pericardium, and abdominopelvic cavity) are lined by a serous membrane, which secretes a small amount of fluid to lubricate the movements of organs. In the abdominal cavity and pelvic cavity this membrane is called the **peritoneum**. There are two types (Fig. 4.20). **Parietal peritoneum** lines the inner surfaces of the abdominal and pelvic walls, and **visceral peritoneum** covers the surfaces of the abdominal and pelvic organs. Between these two types of peritoneum is a potential space called the **peritoneal cavity**.

During development, some organs grow into the peritoneal cavity and become **intraperitoneal** (invested in peritoneum). Examples of intraperitoneal organs include the stomach, small intestine, liver, and spleen. Some organs develop behind the peritoneum and are called **retroperitoneal organs.** The ureters and kidneys are examples. Some parts of the gastrointestinal tract begin as intraperitoneal organs then become attached to the abdominal wall during development. These organs are **secondarily retroperitoneal**. Examples of secondarily retroperitoneal organs include the duodenum, pancreas, ascending colon, and descending colon.

The order of dissection will be as follows. The abdominal viscera will be identified and localized by abdominal quadrant. The named specializations of the peritoneum will be studied. For a more complete understanding, review the development of the gastrointestinal tract before examining the peritoneal specializations.

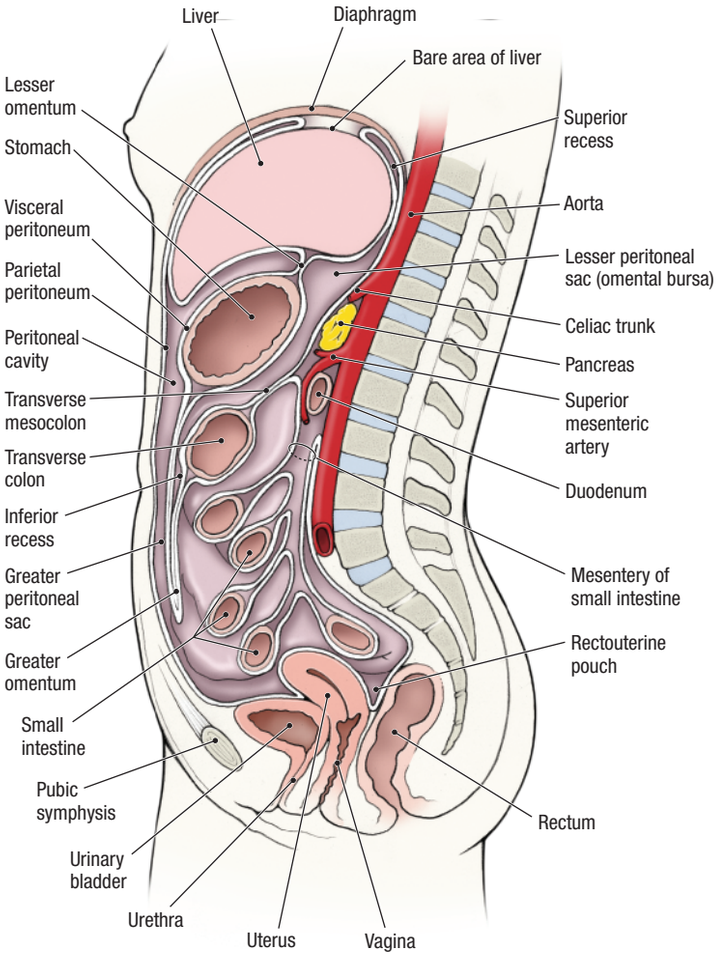

Figure 4.20. Peritoneum and peritoneal cavity, median section.

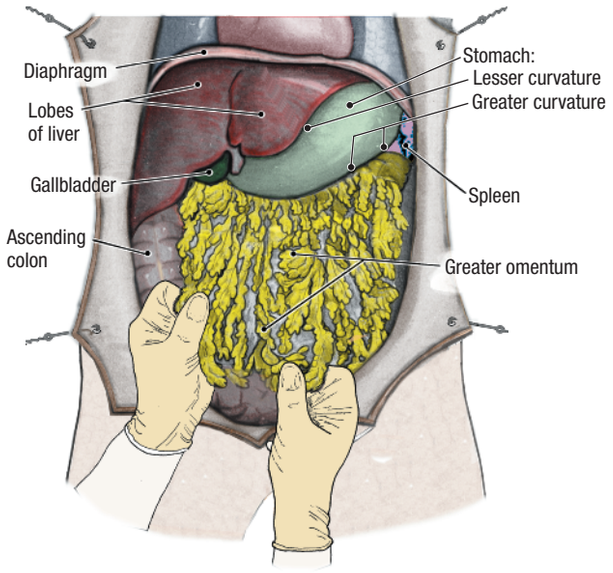

Figure 4.21. The relationship of the greater omentum to the abdominal viscera.

Dissection Instructions

ABDOMINAL VISCERA [G 113, 120; N 261; R 281, 282; C 188]

1. Use your hands to inspect the abdominal cavity. As you perform the inspection, you may encounter adhesions. If adhesions are present, tear them with your fingers.
2. Open the flaps of the abdominal wall. The incision lines correlate to the abdominal quadrant lines. As you examine the organs, you should close and open the flaps to help you relate the organs to the abdominal quadrants. Most of the organs to be identified are parts of the **gastrointestinal tract**.
3. Identify the **liver** (Fig. 4.21). It is an intraperitoneal organ. The liver occupies the right upper quadrant and extends across the midline into the left upper quadrant. The liver lies against the inferior surface of the diaphragm. The attachment of the falciform ligament divides the liver into **right** and **left lobes**.
4. The **gallbladder**, an intraperitoneal organ, is also in the right upper quadrant. The gallbladder extends below the inferior border of the liver. It is usually found at the tip of the right ninth costal cartilage in the midclavicular line. Confirm this relationship.
5. Identify the **stomach**. It is an intraperitoneal organ and lies in the left upper quadrant. It is continuous with the esophagus proximally and the duodenum distally. The liver partially covers the anterior surface of the stomach.
6. Find the **spleen**. It is an intraperitoneal organ, which lies in the left upper quadrant. It is found posterior to the stomach and may be difficult to find unless it is enlarged. Reach around the left side of the stomach with your right hand and palpate the spleen.
7. Identify the **greater omentum** (Fig. 4.21). The greater omentum is attached to the greater curvature of the stomach. Reflect the greater omentum superiorly over the costal margin (Fig. 4.22).
8. Identify the **small intestine** (Figs. 4.22, 4.23). The small intestine begins at the pyloric end of the stomach. It has three parts:
   - **Duodenum**
   - **Jejunum**
   - **Ileum**
9. Most of the duodenum is secondarily retroperitoneal. It will be studied with the pancreas.
10. The **jejunum** and **ileum** are intraperitoneal organs that extend from the left upper quadrant to the right lower quadrant, but because of their length and mobility, they occupy all four quadrants. Beginning in the left upper quadrant, pass the jejunum and ilium between your hands and appreciate its length, position, and termination.
11. Identify the **large intestine**. The large intestine begins in the right lower quadrant at the ileocecal junction (Fig. 4.23). It has six parts:
    - **Cecum** is in the right lower quadrant. The **appendix** is attached to the inferior end of the cecum.
    - **Ascending colon** extends from the right lower quadrant to the right upper quadrant. It ends at the **right colic (hepatic) flexure**. The ascending colon is secondarily retroperitoneal.

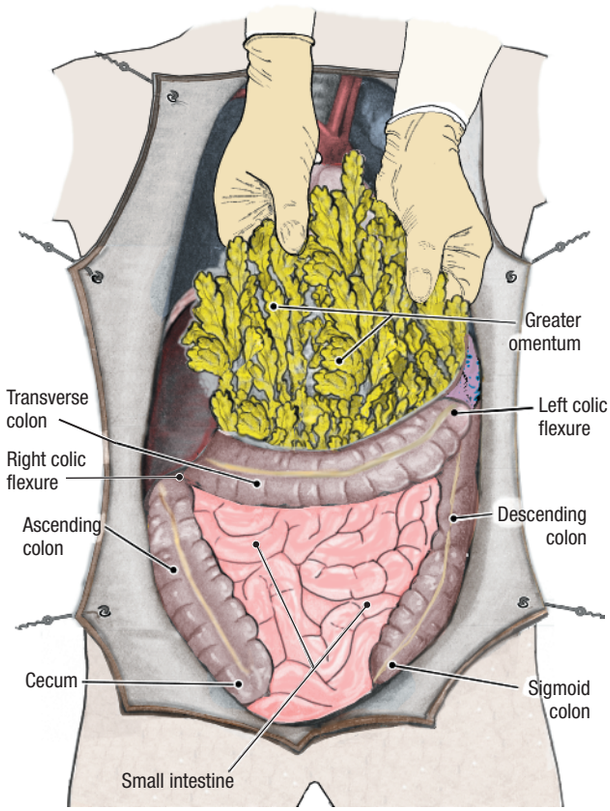

Figure 4.22. Reflect the greater omentum superiorly to expose the small intestine and large intestine.

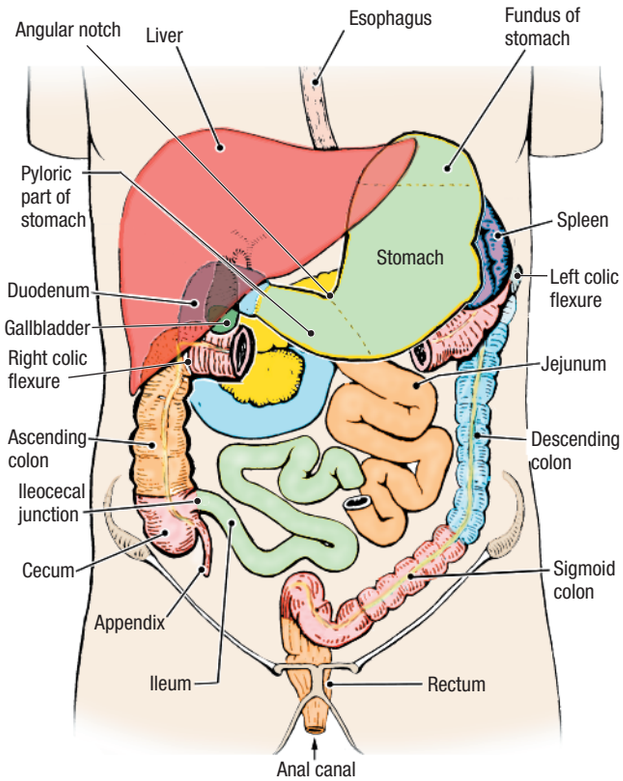

Figure 4.23. Schematic drawing of the abdominal organs. Part of the transverse colon has been removed.

- **Transverse colon** extends from the right upper quadrant to the left upper quadrant. The transverse colon ends at the **left colic (splenic) flexure**. The transverse colon is intraperitoneal.
- **Descending colon** extends from the left upper quadrant to the left lower quadrant. The descending colon is secondarily retroperitoneal.
- **Sigmoid colon** is in the left lower quadrant. The sigmoid colon ends in the pelvic cavity at the level of the third sacral vertebral level. The sigmoid colon is an intraperitoneal organ.
- **Rectum** is the pelvic portion of the gastrointestinal tract. It will be studied with the pelvic viscera.

12. Use your hands to trace the large intestine from the right lower quadrant to the left lower quadrant. Note the position and mobility of each of its parts.

PERITONEUM [G 113; N 261; R 294; C 192]

1. Observe the **visceral peritoneum** on the surface of the stomach or small intestine (Fig. 4.20). Note that visceral peritoneum is smooth and slippery.
2. Observe the **parietal peritoneum** on the inner surface of the abdominal wall (Fig. 4.20). Note that parietal peritoneum is also smooth and slippery.
3. Observe the **greater omentum** (Fig. 4.21). Spread this apron-like structure to appreciate its size. The greater omentum normally lies between the intestines and the anterior abdominal wall (Fig. 4.20). **[G 114; N 267; R 299; C 202]**
4. Elevate the inferior border of the liver and identify the **lesser omentum** (Fig. 4.20). The lesser omentum passes from the lesser curvature of the stomach and first part of the duodenum to the inferior surface of the liver. The lesser omentum has two parts:
   - **Hepatogastric ligament**
   - **Hepatoduodenal ligament**
5. Return the right upper quadrant flap to its anatomical position and review the **falciform ligament**. The falciform ligament passes from the parietal peritoneum on the anterior abdominal wall to the visceral peritoneum on the surface of the liver. The **round ligament of the liver (ligamentum teres hepatis)** is the obliterated umbilical vein, and it is found in the inferior free margin of the falciform ligament.
6. Follow the falciform ligament superiorly to find the **coronary ligament** that attaches the liver to the diaphragm. Two peritoneal ligaments are parts of the coronary ligament:
   - **Left triangular ligament** is between the left lobe of the liver and the diaphragm.
   - **Right triangular ligament** is between the right lobe of the liver and the diaphragm.
7. The **gastrophrenic ligament** connects the superior part of the greater curvature of the stomach to the diaphragm. Slide your hand superiorly to the left of the stomach to feel this ligament.
8. The **gastrosplenic (gastrolienal) ligament** passes from the greater curvature of the stomach to the spleen, and the **splenorenal (lienorenal) ligament**

connects the spleen to the posterior abdominal wall over the left kidney (Fig. 4.24).

9. Reflect the greater omentum superiorly over the costal margin and identify the **transverse mesocolon** (Fig. 4.20). The transverse mesocolon attaches the transverse colon to the posterior abdominal wall. At the left end of the transverse mesocolon is the **phrenicocolic ligament**, which attaches the left colic flexure to the diaphragm. **[N 263; R 294; C 212]**
10. Identify the **mesentery** (Fig. 4.20). The mesentery suspends the jejunum and ileum from the posterior abdominal wall. The root of the mesentery attaches to the posterior abdominal wall from the left upper quadrant to the right lower quadrant.
11. Observe the **mesoappendix**. The mesoappendix attaches the appendix to the posterior abdominal wall and it contains the appendicular artery.
12. Identify the **sigmoid mesocolon** in the lower left quadrant. The sigmoid mesocolon suspends the sigmoid colon from the posterior abdominal wall.
13. Note that these peritoneal structures all are found within a subdivision of the peritoneal cavity called the **greater peritoneal sac** (Fig. 4.20). Posterior to the stomach and lesser omentum is a smaller subdivision of the peritoneal cavity called the **lesser peritoneal sac (omental bursa)** (Fig. 4.24).
14. The **omental foramen (epiploic foramen, foramen of Winslow)** connects the greater and lesser peritoneal sacs. The omental foramen lies posterior to the hepatoduodenal ligament (Fig. 4.24). **[G 114; N 267; R 299; C 220]**
15. Insert your finger into the omental foramen and review its **four boundaries**:
    - **Anterior**—hepatic portal vein, hepatic artery proper, and bile duct contained within the hepatoduodenal ligament (Fig. 4.24)
    - **Posterior**—inferior vena cava and right crus of the diaphragm covered with parietal peritoneum
    - **Superior**—caudate lobe of the liver covered with visceral peritoneum
    - **Inferior**—first part of the duodenum covered with visceral peritoneum
16. Study a diagram of the **lesser peritoneal sac** (Fig. 4.20). The lowest part of the lesser peritoneal sac is called the **inferior recess** and it extends inferiorly as far as the greater omentum. During development, the inferior recess extended between the layers of the greater omentum (review an embryology text). The highest part of the lesser peritoneal sac is the **superior recess**. The diaphragm lies posterior to the superior recess and the caudate lobe of the liver is anterior to the superior recess. **[G 116; N 165; R 301; C 195]**
17. Posterior to the main part of the lesser peritoneal sac is the pancreas (Fig. 4.20). The peritoneum that covers the pancreas forms part of the posterior wall of the lesser peritoneal sac.

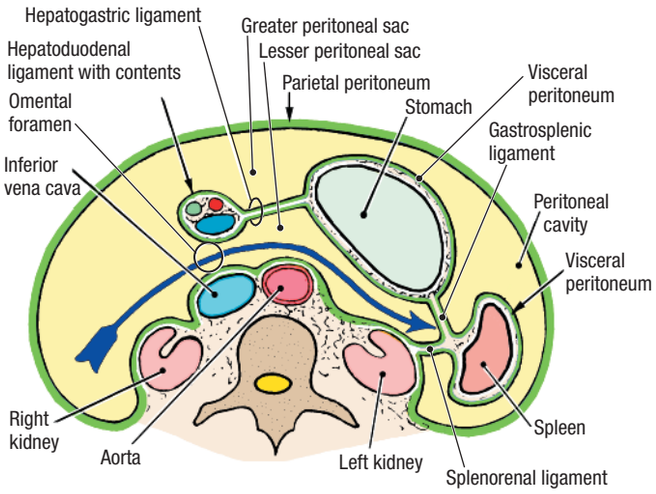

Figure 4.24. Schematic drawing of the peritoneal cavity in transverse section—inferior view. The arrow passes through the omental foramen.

After you dissect . . .

Use the cadaver specimen to review all parts of the gastrointestinal tract in proximal to distal order. State the quadrant(s) in which each abdominal organ normally is found. Review all parts and specializations of the peritoneum listed on the preceding pages. Review the development of the gut tube and mesenteries.

CELIAC TRUNK, STOMACH, SPLEEN, LIVER, AND GALLBLADDER

Before you dissect . . .

The order of dissection will be as follows. The surface features of the stomach will be studied. The vessels and ducts in the hepatoduodenal ligament will be demonstrated. The branches of the celiac trunk that supply the stomach, spleen, liver, and gallbladder will be dissected. The remainder of the field of supply of the celiac trunk (to the duodenum and pancreas) will be dissected later. The hepatic portal vein will be studied. The spleen, liver, and gallbladder will be studied.

Dissection Instructions

1. Place the greater omentum in its correct anatomical position.
2. Identify the parts of the stomach (Fig. 4.25): **[G 121; N 267; R 284; C 198]**
    - **Anterior surface**
    - **Greater curvature**
    - **Lesser curvature**
    - **Cardia**
    - **Cardial notch**
    - **Fundus**
    - **Body**
    - **Angular incisure (notch)**
    - **Pyloric part**
    - **Pylorus**

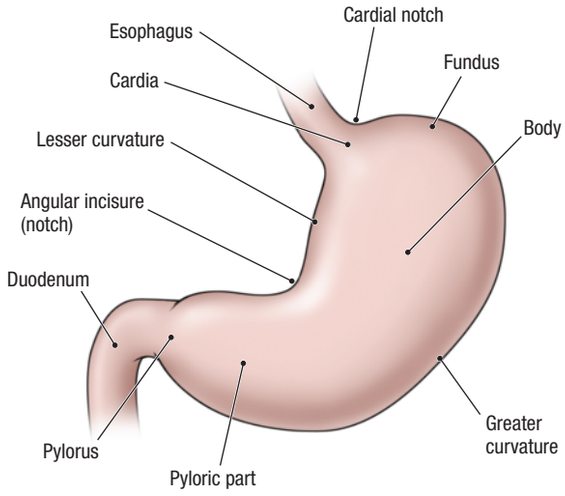

Figure 4.25. Parts of the stomach.

3. Identify the following features of the liver (Fig. 4.26A,B): **[G 142; N 279 ; R 288; C 207]**
   Right lobe
   Left lobe
   Diaphragmatic surface
   Inferior border
4. Use your hand to raise the inferior border of the liver. Identify the **visceral surface of the liver** (Fig. 4.26B). The visceral surface is in contact with the gallbladder and the peritoneum covering the stomach, duodenum, colon, right kidney, and right suprarenal gland.
5. Identify the **porta hepatis** on the visceral surface of the liver. It is the fissure through which vessels, ducts, lymphatics, and nerves enter the liver (Fig. 4.26B). **[G 143; N 279; R 289; C 207]**
6. Identify the **gallbladder** (Fig.4.26B). The gallbladder may have been surgically removed.

CELIAC TRUNK [G 128; N 292; R 303; C 196]

As you dissect the branches of the celiac trunk, realize that *arteries are named by their region of distribution, not by their origin or branching pattern*.

1. Insert your finger into the omental foramen. Anterior to your finger is the **hepatoduodenal ligament** and its contents: **bile ducts**, **hepatic artery proper**, **hepatic portal vein**, **autonomic nerves**, and **lymphatics**.
2. To aid dissection, place a strip of white paper into the omental foramen (Fig. 4.27).
3. Use blunt dissection to remove the peritoneum from the anterior surface of the hepatoduodenal ligament (anterior to the vessels and ducts).
4. Identify the three large structures that are contained within the hepatoduodenal ligament: **(common) bile duct**, **hepatic artery proper**, and **hepatic portal vein** (Fig. 4.27). The bile duct is the most lateral of the three.
5. Use a probe to trace the bile duct superiorly. Identify the **cystic duct** and the **common hepatic duct** (Fig. 4.28).

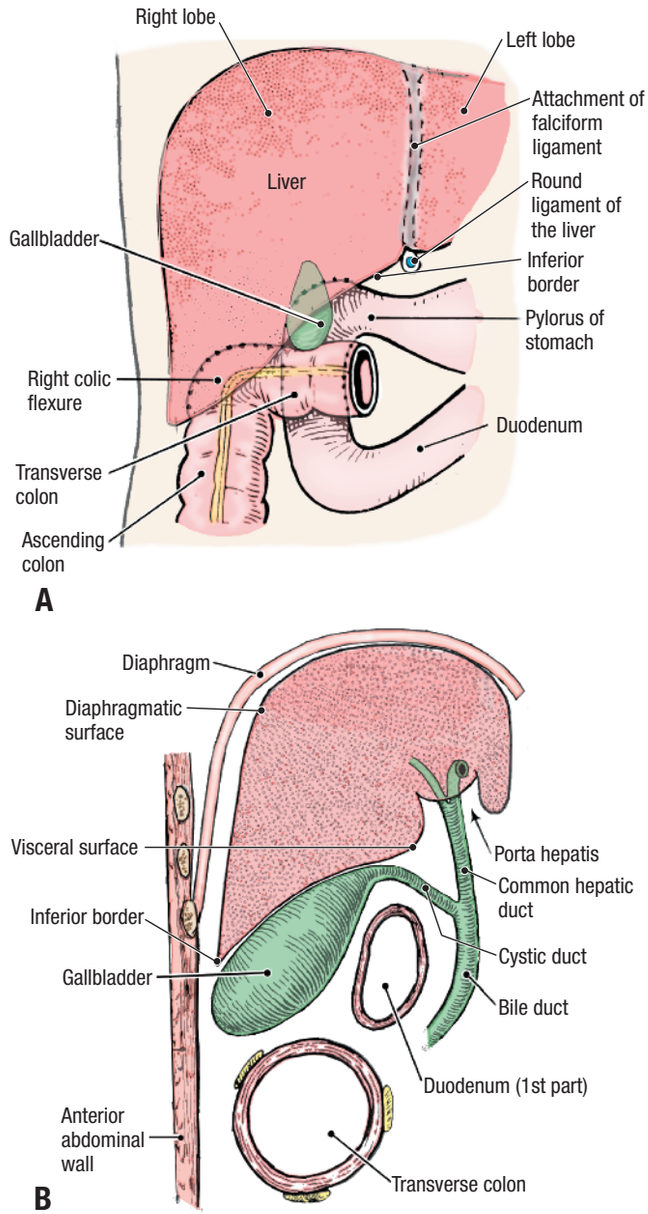

Figure 4.26. Relationships of the gallbladder. **A.** Anterior view. **B.** Sagittal view.

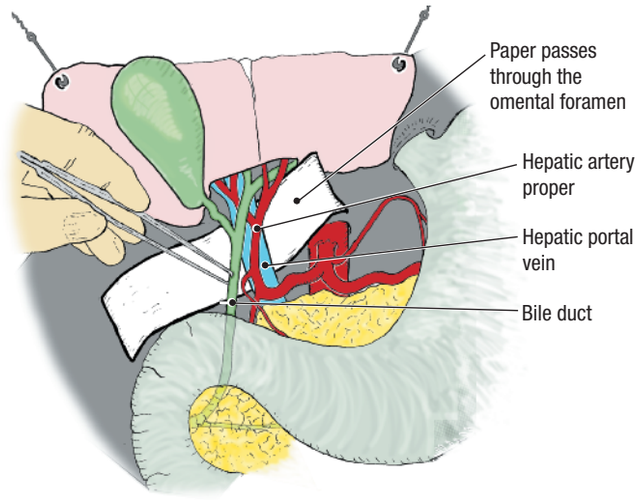

Figure 4.27. Structures contained within the hepatoduodenal ligament.

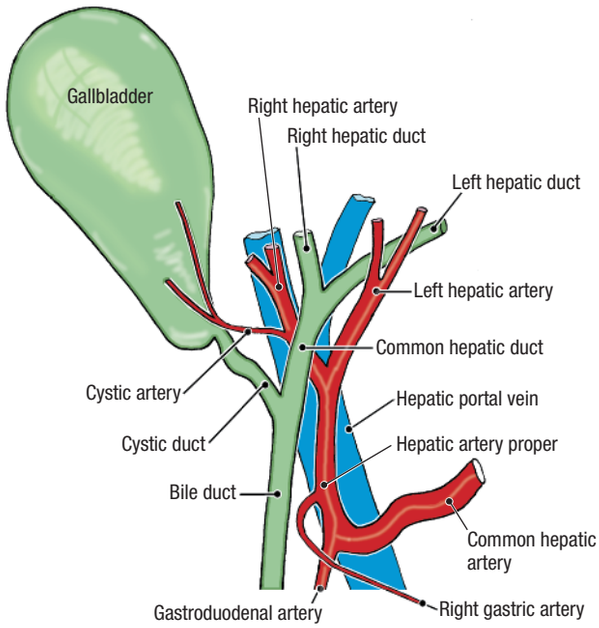

Figure 4.28. Structures contained within the hepatoduodenal ligament. Tributaries of the (common) bile duct and branches of the common hepatic artery.

6. Follow the common hepatic duct superiorly until it receives its tributaries, the **right hepatic duct** and the **left hepatic duct**. The right and left hepatic ducts exit the **porta hepatis**.
7. Clean the **hepatic artery proper**. The tough "connective tissue" around these vessels contains an **autonomic nerve plexus**. To clear the dissection field, remove the autonomic nerves. **[G 122; N 290; R 303; C 196]**
8. Follow the hepatic artery proper through the hepatoduodenal ligament to the porta hepatis where it branches into the **left hepatic artery** and the **right hepatic artery** (Fig. 4.28).
9. Two other arteries arise in the hepatoduodenal ligament (Fig. 4.28):
   - **Cystic artery**—arises from the right hepatic artery. Follow it to the gallbladder.
   - **Right gastric artery**—arises from the hepatic artery proper. Follow it to the lesser curvature of the stomach.
10. **Lymphatics** are also contained within the hepatoduodenal ligament. The lymphatic vessels are too small to dissect but **hepatic lymph nodes** can be seen. The lymph nodes may be removed to clear the dissection field.
11. Follow the hepatic artery proper inferiorly and confirm that it is the continuation of the **common hepatic artery** (Fig. 4.28).
12. Observe that the common hepatic artery gives rise to the **gastroduodenal artery**. The gastroduodenal artery passes posterior to the first part of the duodenum (Fig. 4.29). Follow the gastroduodenal artery until it divides to give rise to the **right gastro-omental (gastroepiploic) artery** and the **superior pancreaticoduodenal artery**.

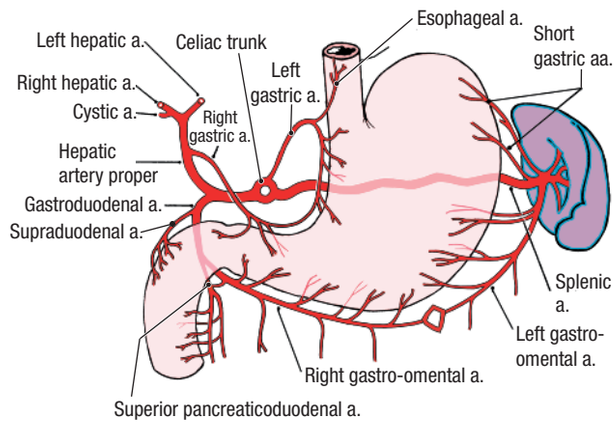

Figure 4.29. Schematic drawing of the branches of the celiac trunk.

CLINICAL CORRELATION

Anatomical Variation in Arteries

In approximately 12% of cases, the right hepatic artery arises from the superior mesenteric artery. An aberrant left hepatic artery may arise from the left gastric artery. During gastrectomy (surgical removal of the stomach), blood flow to an aberrant left hepatic artery could be interrupted, endangering the left lobe of the liver. The cystic artery usually arises from the right hepatic artery, but other origins are possible. The cystic artery may pass posterior (75%) or anterior (24%) to the common hepatic duct (Fig. 4.30).

13. Follow the common hepatic artery to the left toward the **celiac trunk** (Fig. 4.29). Note that the celiac trunk arises from the anterior surface of the abdominal aorta at the level of the twelfth thoracic vertebra. The celiac trunk is very short (less than 2 cm in most cases) and divides into three branches:
    - **Common hepatic artery** (already dissected)
    - **Left gastric artery**
    - **Splenic artery**
14. Use blunt dissection to follow the **left gastric artery** (Fig. 4.29). The left gastric artery reaches the stomach near the esophagus and then follows the lesser curva-

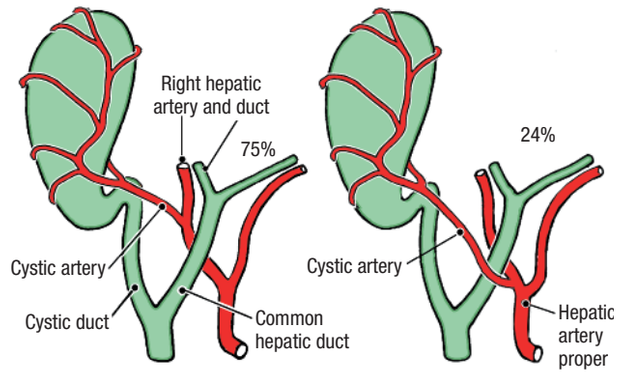

Figure 4.30. The two most common branching patterns of the cystic artery.

ture of the stomach within the lesser omentum. The left gastric artery forms an anastomosis with the right gastric artery along the lesser curvature of the stomach. Branches of the gastric arteries distribute to the anterior and posterior surfaces of the stomach.

15. Follow the **splenic artery** to the left for approximately 5 cm and verify that it lies against the posterior abdominal wall. The splenic artery courses along the superior border of the pancreas and may be partially imbedded in it. Do not dissect the splenic artery from the pancreas at this time. Note that **short gastric arteries** arise from the splenic artery to supply the fundus of the stomach (Fig. 4.29).
16. Find the **left gastro-omental (gastroepiploic) artery** in the greater omentum approximately 2 cm from the greater curvature of the stomach (Fig. 4.29). The left gastro-omental artery is a branch of the splenic artery.
17. Find the **right gastro-omental artery** in the greater omentum near the right end of the greater curvature of the stomach. The right gastro-omental artery anastomoses with the left gastro-omental artery. Follow the right gastro-omental artery to the right to find its origin from the gastroduodenal branch of the common hepatic artery. **[G 128; N 292; R 302; C 196]**
18. Return to the hepatoduodenal ligament and identify the **hepatic portal vein**. The hepatic portal vein lies posterior to both the hepatic artery proper and the bile duct (Fig. 4.27). Follow the hepatic portal vein superiorly and observe that it passes into the porta hepatis where it divides into **right and left portal veins**. The hepatic portal vein usually receives the **left and right gastric veins** as tributaries. Inferiorly, the hepatic portal vein passes posterior to the first part of the duodenum.

SPLEEN [G 123; N 289; R 305; C 202]

The spleen is the largest hematopoietic organ in the body. Its size and weight may vary considerably depending upon the blood volume that it contains. The spleen is covered by visceral peritoneum except at the hilum where the splenic vessels enter and leave.

1. Use your left hand to pull the fundus of the stomach to the right. Use your right hand to gently pull the spleen anteriorly.
2. Observe that the spleen has a smooth diaphragmatic surface. The spleen has sharp anterior, inferior, and superior borders. The superior border of the spleen is often notched.
3. The **visceral surface of the spleen** is related to four organs:
   - **Stomach**
   - **Left kidney**
   - **Transverse colon (left colic flexure)**
   - **Pancreas**
4. The **diaphragmatic surface of the spleen** is related (through the diaphragm) to ribs 9, 10, and 11 (Fig. 4.31).

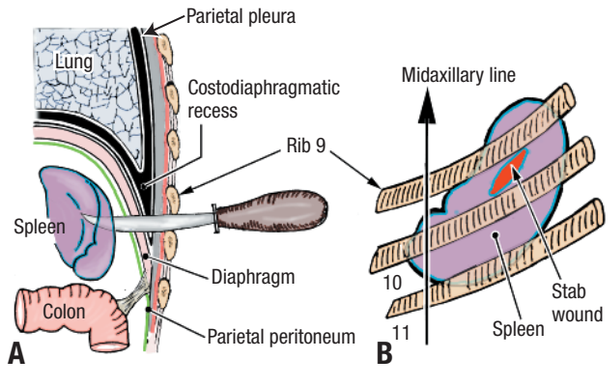

Figure 4.31. Relationships of the spleen to the thoracic wall. **A.** Frontal section. **B.** Lateral view. A penetrating wound through the ninth intercostal space, just posterior to the midaxillary line, will penetrate the pleural cavity, diaphragm, peritoneal cavity, and spleen.

CLINICAL CORRELATION

Spleen

The relationship of the spleen to ribs 9, 10, and 11 is of clinical importance in evaluating rib fractures and penetrating wounds. A lacerated spleen bleeds profusely into the abdominal cavity and may have to be removed surgically (splenectomy). It must be emphasized that there is a risk of puncturing the spleen during thoracocentesis (pleural tap).

An enlarged spleen (splenomegaly) may be encountered during physical examination. The spleen is considered enlarged when it can be palpated inferior to the costal margin.

LIVER [G 142; N 279; R 288; C 206]

The **liver** is the largest gland in the body, comprising approximately 2.5% of the body weight of an adult. To study the surface features of the liver, it must be detached from the diaphragm.

1. Review the falciform ligament and the coronary ligament of the liver.
2. Use scissors to cut the falciform ligament along its attachment to the anterior abdominal wall. Extend the cut superiorly and cut the right and left triangular ligaments along the inferior surface of the diaphragm.
3. Insert your fingers between the liver and the diaphragm and free the connective tissue attachment of the liver to the diaphragm. Cut the posterior layer of the coronary ligament.
4. Use scissors to cut the inferior vena cava between the liver and the diaphragm. Elevate the inferior border of the liver and cut the inferior vena cava again, as close to the inferior surface of the liver as possible. These two cuts will leave a short segment of the inferior vena cava within the liver (Fig. 4.32B).
5. The liver should now be freely mobile but attached to the other abdominal viscera by the bile duct, hepatic artery proper, and hepatic portal vein. Move the liver carefully to avoid tearing these structures.

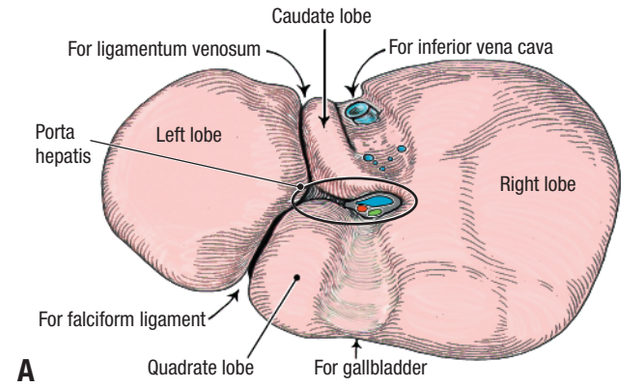

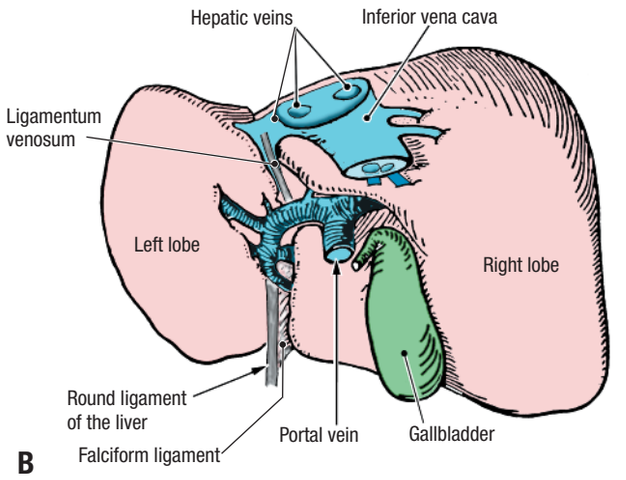

Figure 4.32. Posterior views of the liver. **A.** Fissures and sulci define the four lobes of the liver (right, left, quadrate, and caudate). **B.** Structures located in the H-shaped fissures.

6. Examine the **liver** and note that the **right lobe** is six times larger than the **left lobe**. The sharp **inferior border** of the liver separates the **visceral surface** from the **diaphragmatic surface**.
7. Identify the **bare area** on the posterior aspect of the diaphragmatic surface. Here, the liver was adjacent to the diaphragm and not covered by peritoneum. Around the bare area, note the cut edges of the **coronary ligament**.
8. Examine the **visceral surface** of the liver (Fig. 4.32A). An H-shaped set of fissures and fossae defines four lobes. Identify the **right lobe**, **left lobe**, **caudate lobe**, and **quadrate lobe**. **[G 143, 148; N 279; R 289; C 207]**
9. Observe that the **ligamentum venosum** and **falciform ligament** occupy the left fissure of the "H" (Fig. 4.32B). The **gallbladder** and **inferior vena cava** occupy the fossae that form the right side of the "H."
10. Identify the **porta hepatis**. It forms the horizontal bar of the "H." The structures passing through the hepatoduodenal ligament (bile ducts, hepatic arteries, hepatic portal vein, lymphatics, and autonomic nerves) enter or leave the liver at the porta hepatis.
11. Examine the small segment of the **inferior vena cava** that is attached to the liver. Note that several **hepatic veins** drain directly into the inferior vena cava (Fig. 4.32B).
12. Use a textbook to study the two conventions by which the liver may be divided into lobes. The falciform ligament divides the liver into **right and left anatomical lobes**. The pattern of its bile drainage and vascular supply are used to divide the liver into **right and left functional lobes**. **[G 146; N 281; R 289]**
13. The liver has a substantial lymphatic drainage. At the porta hepatis, small lymph vessels drain into **hepatic lymph nodes**. From the hepatic lymph nodes, lymphatic vessels follow the hepatic arteries to **celiac lymph nodes** located around the celiac trunk.

CLINICAL CORRELATION

Liver

The liver may undergo pathologic changes that could be encountered during dissection. The liver may be enlarged. This happens in liver congestion because of cardiac insufficiency (cardiac liver). In contrast, the liver may be small and have fibrous nodules. Such a finding may indicate cirrhosis of the liver. Because the liver is essentially a capillary bed downstream from the gastrointestinal tract, metastatic tumor cells are often trapped within it, resulting in secondary tumors.

GALLBLADDER [G 148; N 285; R 287; C 208]

The gallbladder is a reservoir for the storage and concentration of bile. The gallbladder occupies a shallow fossa on the visceral surface of the liver (Fig. 4.32B). The gallbladder is usually stained dark green by bile, which leaks through the wall of the gallbladder after death.

1. Replace the liver into its correct anatomical position.
2. Confirm that the gallbladder is located near the tip of the ninth costal cartilage in the midclavicular line.
3. Reposition the liver to expose the visceral surface. Use blunt dissection to remove the gallbladder from its fossa.
4. Identify the parts of the gallbladder (Fig. 4.33):
   - **Fundus**
   - **Body**
   - **Neck**
5. Review the course of the **cystic artery**. The cystic artery is stained green by bile and is often fragile and difficult to dissect.
6. Use scissors to make a longitudinal incision through the wall of the gallbladder, beginning at the fundus and continuing through the neck. If gallstones are present, remove them. Look for the **spiral fold**, which is present in the mucosal lining of the neck, continuing into the **cystic duct**.

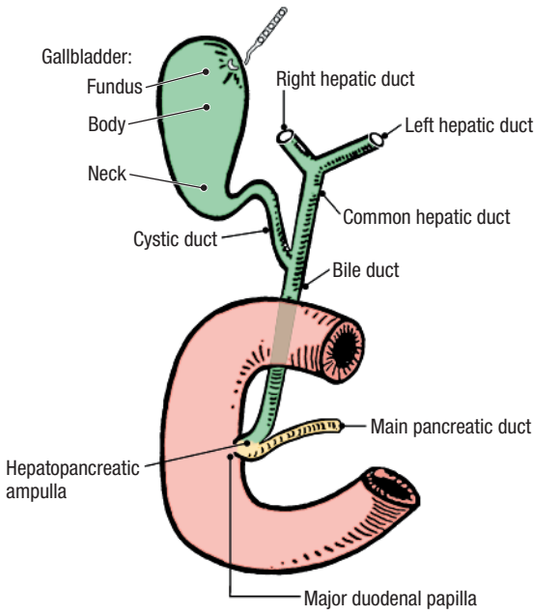

Figure 4.33. Extrahepatic bile ducts.

After you dissect . . .

Replace the organs in their correct anatomical positions. Close and open the flaps of the abdominal wall and review the location of each organ relative to the abdominal quadrant system. Use an illustration and the dissected specimen to trace the branches of the celiac trunk. Review the relationships of the structures in the hepatoduodenal ligament. Review the boundaries of the omental foramen. Review the parts of the organs dissected and their relationships to surrounding structures. Use an embryology textbook to review the development of the liver and the ventral mesogastrium. Review the derivatives of the embryonic foregut.

SUPERIOR MESENTERIC ARTERY AND SMALL INTESTINE

Before you dissect . . .

The order of dissection will be as follows. The mesentery will be examined. The branches of the superior mesenteric artery that supply the jejunum, ileum, cecum, ascending colon, and transverse colon will be dissected. The remainder of the field of supply of the superior mesenteric artery (to the duodenum and pancreas) will be dissected later, because these structures lie behind the attachment of the transverse mesocolon. The external features of the jejunum and ileum will be studied. The inferior mesenteric vessels will be dissected.

Dissection Instructions

SUPERIOR MESENTERIC ARTERY [G 136; N 295, 296; R 291; C 216]

The superior mesenteric artery arises from the anterior surface of the abdominal aorta approximately 1 cm inferior to the celiac trunk. At its origin, the superior mesenteric artery lies posterior to the neck of the pancreas. When the superior mesenteric artery emerges from posterior to the neck of the pancreas, it passes anterior to the uncinate process, third part of the duodenum, and left renal vein. The superior mesenteric artery then enters the mesentery. Within the mesentery the superior mesenteric artery courses toward the terminal end of the ileum.

1. Return the liver to its correct anatomical position.
2. Turn the transverse colon and greater omentum superiorly over the costal margin. The posterior surface of the transverse mesocolon should face anteriorly.
3. Move the coils of the **jejunum** and **ileum** to the left side of the abdomen so that the right side of the mesentery faces anteriorly (Fig. 4.34). Observe that the root of the mesentery is attached to the posterior abdominal wall along a line from the left upper quadrant to the right lower quadrant.
4. Remove the peritoneum on the right side of the mesentery to expose the branches of the superior mesenteric artery. To do this, use a probe to tear the peritoneum, then grasp it between your thumb and index finger (Fig. 4.35). Peel it slowly, using the handle of a forceps to scrape the peritoneum free from deeper structures.
5. Remove the parietal peritoneum from the posterior abdominal wall on the right side of the mesentery. Remove the peritoneum as far laterally as the ascending colon.
6. Identify the **superior mesenteric artery**. Use blunt dissection to trace the superior mesenteric artery proximally and observe that it crosses anterior to the third part of the duodenum. Note that the third part of the duodenum and the left renal vein can become compressed between the superior mesenteric vessels and the abdominal aorta.
7. Use blunt dissection to clean the branches of the superior mesenteric artery. As you dissect, note the dense autonomic nerve network surrounding the vessels. This is the **superior mesenteric plexus of nerves**. Remove the nerves as necessary to clear the dissection field.

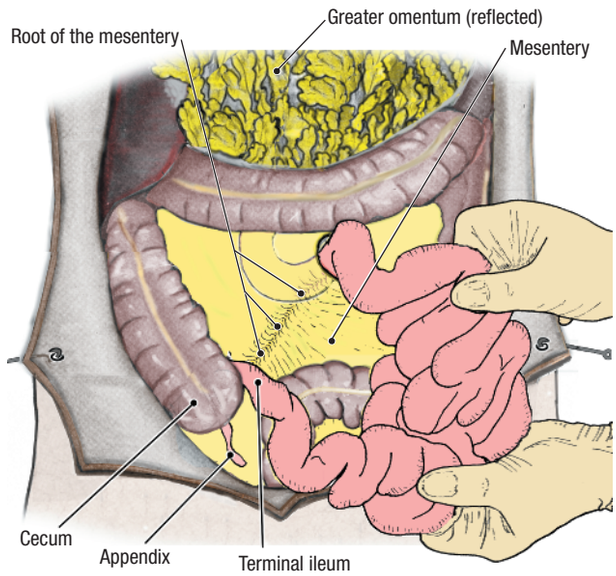

Figure 4.34. Move the small intestine to the left for dissection of the superior mesenteric artery.

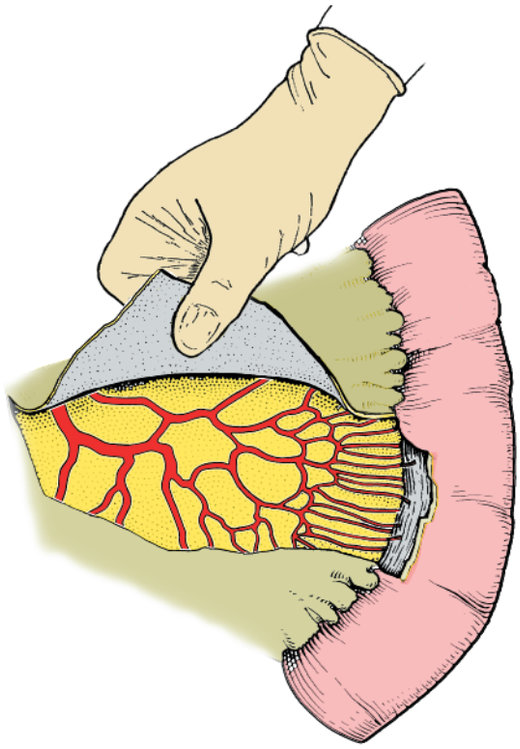

Figure 4.35. How to remove the peritoneum from the mesentery to expose the blood vessels.

8. Identify the **branches of the superior mesenteric artery**:
   - **Inferior pancreaticoduodenal artery –** the first branch of the superior mesenteric artery. The inferior pancreaticoduodenal artery will be dissected later.
   - **Intestinal arteries –** 15 to 18 arteries to the jejunum and the ileum. Intestinal arteries end in straight terminal branches called **vasa recta** (Fig. 4.36). **Arcades** connect the intestinal arteries. Observe the blood supply to the proximal jejunum and note that only one or two arcades are found between adjacent intestinal arteries, resulting in relatively long vasa recta (Fig. 4.36A). Examine the distal ileum and note that four or five arcades occur between adjacent intestinal arteries, resulting in relatively short vasa recta (Fig. 4.36B).
   - **Ileocolic artery –** supplies the cecum. The ileocolic artery gives rise to the **appendicular artery** (Fig. 4.37). The ileocolic artery anastomoses with intestinal branches and with the right colic artery.
   - **Right colic artery –** supplies the ascending colon. The right colic artery arises from the right side of the superior mesenteric artery and passes to the right in a retroperitoneal position. It divides into a superior branch and an inferior branch.
   - **Middle colic artery –** supplies the transverse colon. The middle colic artery arises from the anterior surface of the superior mesenteric artery and courses through the transverse mesocolon. It divides into a right branch and a left branch.
9. Identify the **superior mesenteric vein**. The superior mesenteric vein is formed by branches that correspond in name and position to the branches of the superior mesenteric artery. The superior mesenteric vein courses along the right side of the superior mesenteric artery. Posterior to the pancreas, the superior mesenteric vein joins the splenic vein to form the **hepatic portal vein**.
10. The mesentery may contain up to 200 **mesenteric lymph nodes**. Identify one or two of these lymph nodes along the branches of the superior mesenteric vessels. The **superior mesenteric lymph nodes** are located near the origin of the superior mesenteric artery from the abdominal aorta. Lymph nodes may be removed to clear the dissection field.

SMALL INTESTINE [G 132, 133; N 262; R 298; C 218]

The small intestine consists of the duodenum, jejunum, and ileum. The function of the small intestine is to absorb nutrients from food. It has elaborate folds of mucosa that increase surface area and a rich blood supply to transport the absorbed nutrients. The **jejunum** (proximal two-

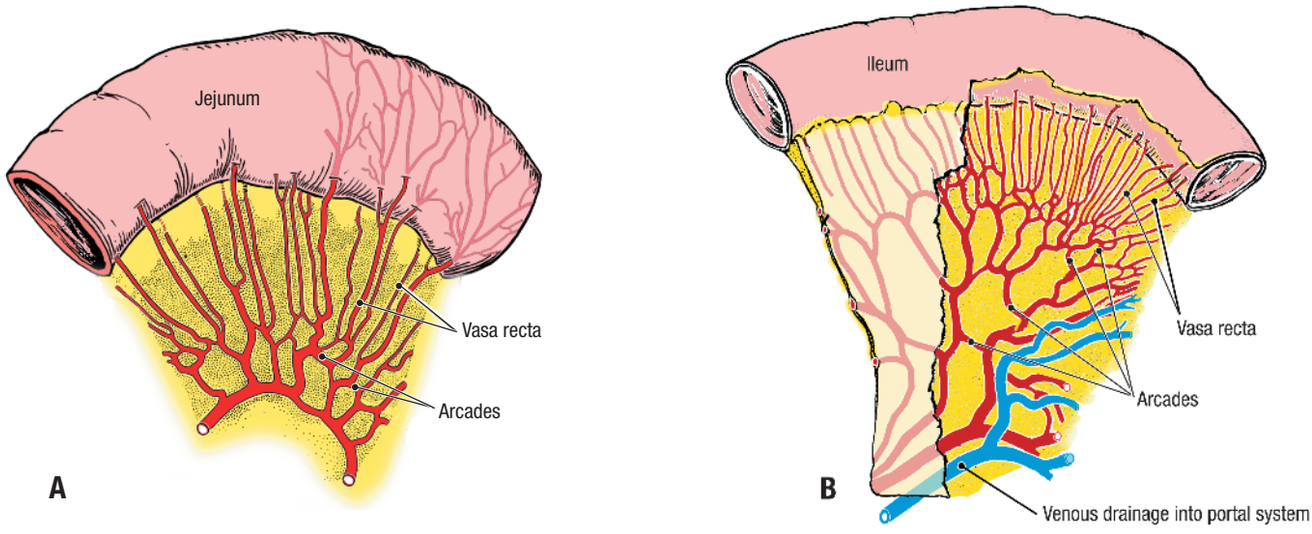

Figure 4.36. Comparison of intestinal arteries. **A.** Arteries of the jejunum. **B.** Arteries of the ileum.

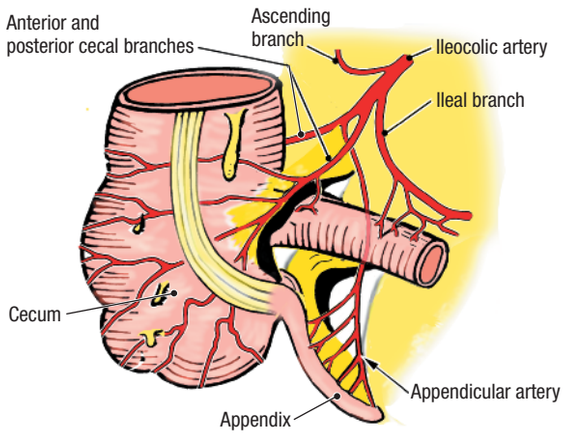

Figure 4.37. Branches of the ileocolic artery.

fifths) and **ileum** (distal three-fifths) are studied together because their transition is not obvious.

1. Move the small intestine to the left side of the abdominal cavity and follow the jejunum proximally (Fig. 4.38). Find the **duodenojejunal junction**.
2. Note that the **suspensory ligament of the duodenum** is a fibromuscular ligament that arises from the right crus of the diaphragm and anchors the intestine at the duodenojejunal junction (Fig. 4.38, inset).
3. Palpate the small intestine and note that the wall of the jejunum is thicker than the wall of the ileum.
4. Identify the termination of the ileum where it empties into the **cecum** at the **ileocecal junction** (Fig. 4.38).
5. Verify that the **root of the mesentery** crosses the posterior abdominal wall from the duodenojejunal junction to the ileocecal junction (Fig. 4.38). The root of the mesentery is approximately 15 cm long. The **intestinal attachment of the mesentery** is nearly 6 m long.

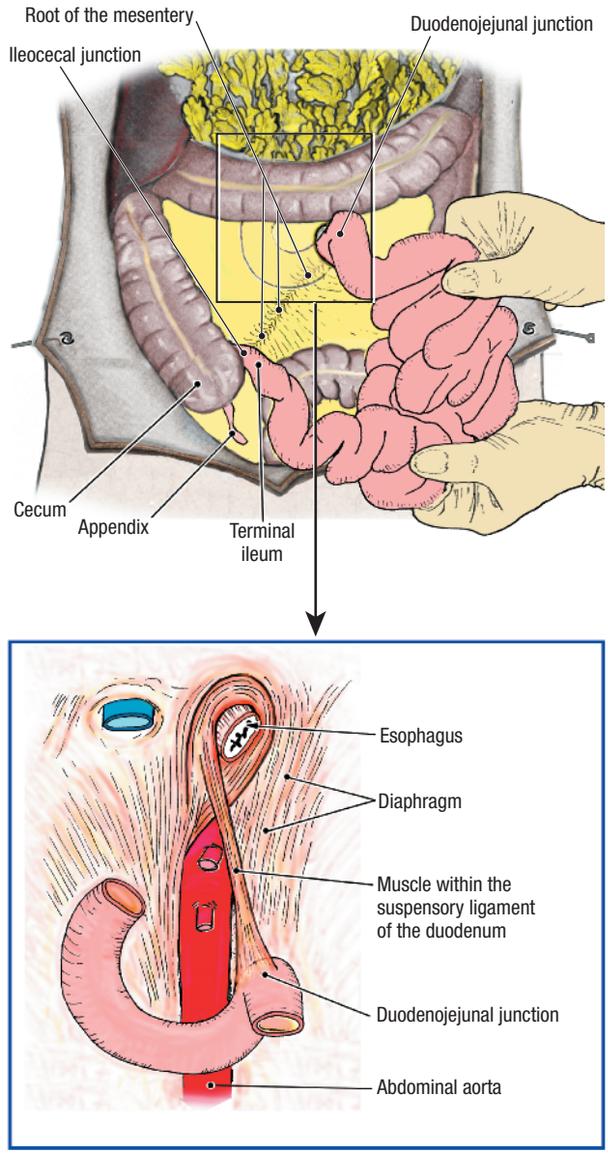

Figure 4.38. Move the small intestine to the left side to find the duodenojejunal junction. Inset: The duodenojejunal junction is suspended by the suspensory muscle (ligament) of the duodenum.

After you dissect . . .

Replace the small intestine in its correct anatomical position. Close and open the flaps of the abdominal wall and review the location of the jejunum and ileum relative to the abdominal quadrant system. Review the relationships of the jejunum and ileum to surrounding structures. Use an illustration and the dissected specimen to review the branches of the superior mesenteric artery. Use an embryology textbook to review the derivatives of the embryonic midgut.

INFERIOR MESENTERIC ARTERY AND LARGE INTESTINE

Before you dissect . . .

The **inferior mesenteric artery** arises from the anterior surface of the abdominal aorta at the level of the intervertebral disk between vertebrae L2 and L3. The objective is to demonstrate the field of supply of the inferior mesenteric artery (left half of the transverse colon, descending colon, sigmoid colon, and most of the rectum). Except for the branches that pass through the sigmoid mesocolon to supply the sigmoid colon, the inferior mesenteric artery and its branches lie retroperitoneally.

The order of dissection will be as follows. The inferior mesenteric artery and its branches will be dissected. The external features of the large intestine will be studied.

Dissection Instructions

INFERIOR MESENTERIC ARTERY [G 138; N 296; R 293; C 218]

1. Turn the transverse colon and greater omentum superiorly over the costal margin to expose the posterior surface of the transverse mesocolon.
2. Move the small intestine to the right so that the descending colon is visible from the left colic flexure to the sigmoid colon (Fig. 4.39).

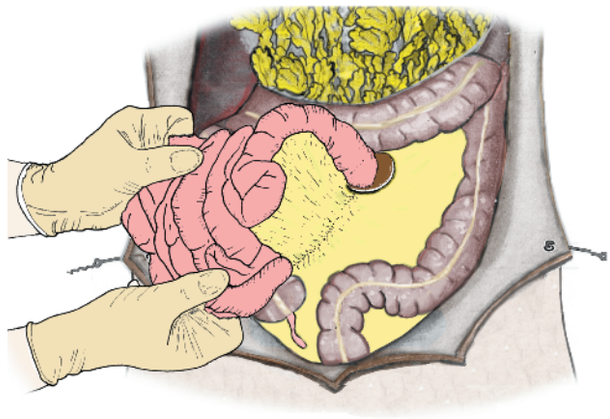

Figure 4.39. Move the small intestine to the right for dissection of the inferior mesenteric artery.

3. The origin of the inferior mesenteric artery lies posterior to the third part of the duodenum. If you have trouble finding it, find one of its branches in the sigmoid mesocolon and trace the branch back to the main vessel. Then proceed with the dissection of the peripheral branches.

Dissection note: The left ureter could be mistaken for the inferior mesenteric artery or one of its branches. The inferior mesenteric artery and vein and the ureter all lie in the retroperitoneal space, but the vessels pass anterior to the ureter.

4. Use a probe to clean the **branches of the inferior mesenteric artery** (Fig. 4.40):
   - **Left colic artery –** supplies the descending colon and the left half of the transverse colon. The left colic artery anastomoses with the middle colic branch of the superior mesenteric artery.
   - **Sigmoid arteries –** supply the sigmoid colon. Sigmoid arteries pass through the sigmoid mesocolon. Note that they form arcades similar to those of the intestinal arteries.
   - **Superior rectal artery –** supplies the proximal part of the rectum. The superior rectal artery divides into a **right branch** and a **left branch**. The right and left branches of the superior rectal artery descend into the pelvis on either side of the rectum. Do not follow them into the pelvis.
5. Observe the tributaries of the **inferior mesenteric vein**. The tributaries of the inferior mesenteric vein correspond to the branches of the inferior mesenteric artery. The inferior mesenteric vein ascends on the left side of the inferior mesenteric artery, passes posterior to the pancreas, and joins either the **splenic vein** or (less frequently) the **superior mesenteric vein**.
6. The inferior mesenteric artery and vein are accompanied by lymph vessels that drain into the **inferior mesenteric nodes** around the origin of the inferior mesenteric artery.

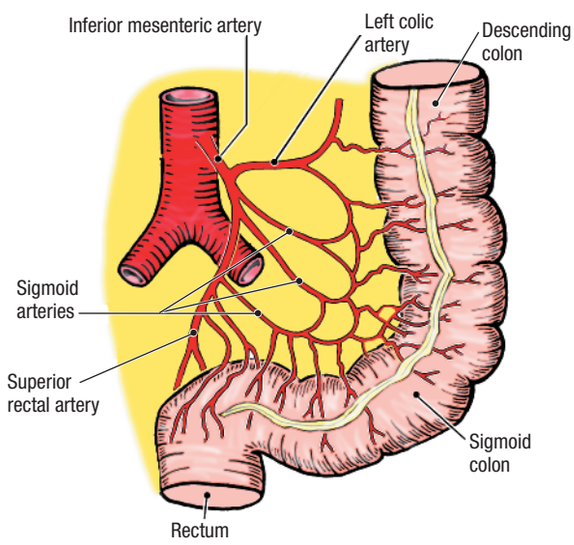

Figure 4.40. Branches of the inferior mesenteric artery.

LARGE INTESTINE [G 132, 133; N 276; R 295; C 212, 214]

The large intestine consists of the **cecum** (with attached **appendix)**, **colon** (ascending, transverse, descending and sigmoid), **rectum**, and **anal canal**. Absorption of water from fecal material is a major function of the large intestine. The relatively smooth mucosal surface of the large intestine is well-suited for this function, because a smooth surface is less likely to impede the movement of progressively more solid fecal matter.

1. Return the small intestine and transverse colon to their correct anatomical positions.
2. In the right lower quadrant, identify the **cecum** (L. *caecus*, blind). The length of its mesentery and the degree of its mobility vary considerably from individual to individual.
3. The **appendix (vermiform appendix)** (L. *appendere*, to hang on) is attached to the end of the cecum. The appendix may be found in one of several positions (Fig. 4.41). Recall that the appendix is suspended on a mesentery called the **mesoappendix**. The **appendicular artery** is found within the mesoappendix (Fig. 4.37).
4. Identify the **ascending colon**. It is a secondarily retroperitoneal organ. The ascending colon extends from the cecum to the **right colic flexure** (Fig. 4.23).

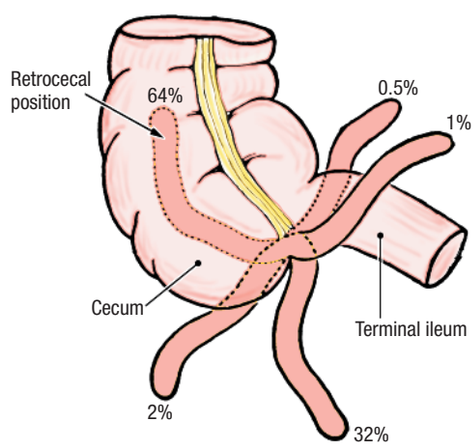

Figure 4.41. Variations in the position of the appendix.

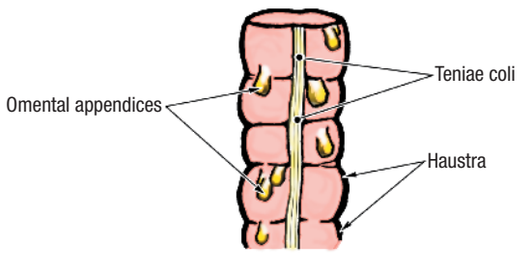

Figure 4.42. Surface features of the large intestine.

5. Identify the **transverse colon**. The transverse colon extends from the **right colic flexure** to the **left colic flexure**. Observe that the left colic flexure is at a more superior level than the right colic flexure. Between the two flexures, the transverse colon is freely movable.
6. Observe the **descending colon.** It is a secondarily retroperitoneal organ. The descending colon descends from the left colic flexure to the left lower quadrant (Fig. 4.23).
7. In the left lower quadrant, find the **sigmoid colon**. Observe that the sigmoid colon has a mesentery (**sigmoid mesocolon**) and is mobile. The sigmoid colon ends in the pelvis at the level of the 3rd sacral segment, where it becomes continuous with the rectum.
8. The **rectum** is contained entirely within the pelvic cavity and will be dissected at a later time.
9. Observe the external surface of the large intestine and note three features that distinguish it from the small intestine (Fig. 4.42):
   - **Teniae coli –** three narrow bands of longitudinal muscle
   - **Haustra –** outpouchings of the wall of the colon
   - **Omental appendices (epiploic appendages) –** small accumulations of fat covered by visceral peritoneum
10. Review the branches of the superior mesenteric artery and inferior mesenteric artery that supply the large intestine. **[G 141; N 296; R 296; C 216, 218]**

After you dissect . . .

Close and open the flaps of the abdominal wall to review the location of each part of the large intestine relative to the abdominal quadrant system. Review the relationship of each part of the large intestine to the surrounding structures. Use an illustration and the dissected specimen to trace the branches of the inferior mesenteric artery. Use an embryology textbook to review the derivatives of the embryonic hindgut.

DUODENUM, PANCREAS, AND HEPATIC PORTAL VEIN

Before you dissect . . .

The duodenum is the part of the small intestine between the stomach and the jejunum. The duodenum is the drainage point for the ducts of the liver and pancreas. The pancreas lies within the bend of the duodenum. The pancreas is both an endocrine and an exocrine organ and has a rich blood supply arising from the celiac trunk and the superior mesenteric artery.

The order of dissection will be as follows. The parts of the duodenum will be studied. The pancreas will be dissected. The formation of the hepatic portal vein will be demonstrated.

Dissection Instructions

DUODENUM [G 125, 126; N 270; R 304; C 210]

1. Turn the transverse colon and greater omentum superiorly over the costal margin.
2. Use blunt dissection to remove the remaining connective tissue and peritoneum from the anterior surface of the duodenum and pancreas.
3. Observe the **four parts of the duodenum** (Fig. 4.43):
   - **Superior (first) part –** at the level of vertebra L1. The superior part of the duodenum lies in the transverse plane and the hepatoduodenal ligament is attached to it. It is mostly intraperitoneal.
   - **Descending (second) part –** at the level of vertebra L2. The descending part of the duodenum is positioned to the right of the midline and anterior to the right kidney, right renal vessels, and inferior vena cava. It is retroperitoneal. The bile duct and the pancreatic duct drain into the descending part of the duodenum.
   - **Horizontal (third) part –** at the level of vertebra L3. The horizontal part of the duodenum lies anterior to the inferior vena cava and the abdominal aorta. It is retroperitoneal. The horizontal part of the duodenum is crossed anteriorly by the superior mesenteric vessels and posteriorly by the inferior mesenteric vessels.
   - **Ascending (fourth) part –** ascends to the level of vertebra L2. The ascending part of the duodenum is retroperitoneal throughout most of its length. The ascending part of the duodenum turns anteriorly to join the jejunum at the duodenojejunal junction.

PANCREAS [G 125, 130; N 288; R 305; C 211]

1. Identify the **pancreas** within the bend of the duodenum. Note that it is a secondarily retroperitoneal organ that lies across the midline and that it is positioned against the vertebral bodies.

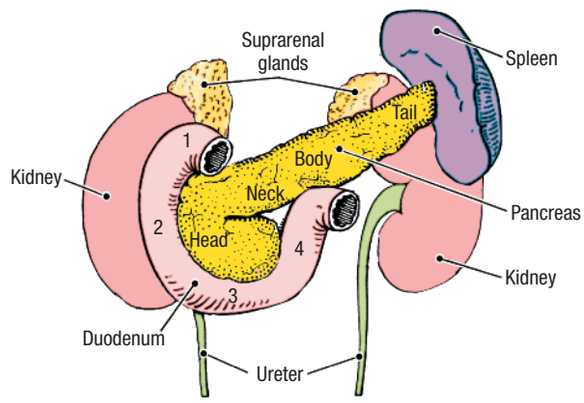

Figure 4.43. Relationships of the spleen, pancreas, duodenum, and kidneys.

2. Identify the parts of the pancreas (Fig. 4.43):
   - **Head –** lies within the curve of the duodenum. The head of the pancreas lies anterior to the origin of the superior mesenteric artery. The **uncinate process** is a small projection from the inferior margin of the head that passes posterior to the superior mesenteric vessels. The inferior vena cava lies posterior to the head of the pancreas.
   - **Neck –** a short portion that lies anterior to the superior mesenteric vessels and connects the head of the pancreas to the body.
   - **Body –** extends from right to left and slightly superiorly as it crosses the posterior abdominal wall. The abdominal aorta lies posterior to the body of the pancreas.
   - **Tail –** the narrow left end of the gland. The tip of the tail lies in the splenorenal ligament and contacts the hilum of the spleen.
3. Use a probe to dissect into the anterior surface of the head of the pancreas and find the **main pancreatic duct**. Trace the main pancreatic duct through the neck and into the body. The **accessory pancreatic duct** joins the main pancreatic duct from the superior side.
4. Follow the main pancreatic duct toward the descending part of the duodenum. Observe that the main pancreatic duct is joined by the bile duct.
5. Identify the **superior pancreaticoduodenal artery** (Fig. 4.44), a branch of the gastroduodenal artery. **[G 127; N 291; R 304; C 213]**
6. The **inferior pancreaticoduodenal artery** is usually the most proximal branch of the superior mesenteric artery, although its origin is variable (Fig. 4.44). The inferior pancreaticoduodenal artery enters the inferior portion of the head of the pancreas.
7. Return to the celiac trunk and follow the splenic artery as it passes to the left along the superior margin of the pancreas (Fig. 4.44). The splenic artery will supply up to 10 small arteries to the body and tail of the pancreas. Identify only two:
   - **Dorsal pancreatic artery –** enters the neck of the pancreas.
   - **Greater pancreatic (pancreatica magna) artery –** enters the pancreas at the junction of the medial two-thirds and lateral one-third of the gland.
8. Follow the splenic artery to the hilum of the spleen and identify the **left gastro-omental artery**. Complete the dissection of the left gastro-omental artery by following it through the greater omentum to its anastomosis with the right gastro-omental artery.
9. The veins of the pancreas correspond to the arteries. They drain into the superior mesenteric and splenic veins and ultimately are tributary to the hepatic portal vein.

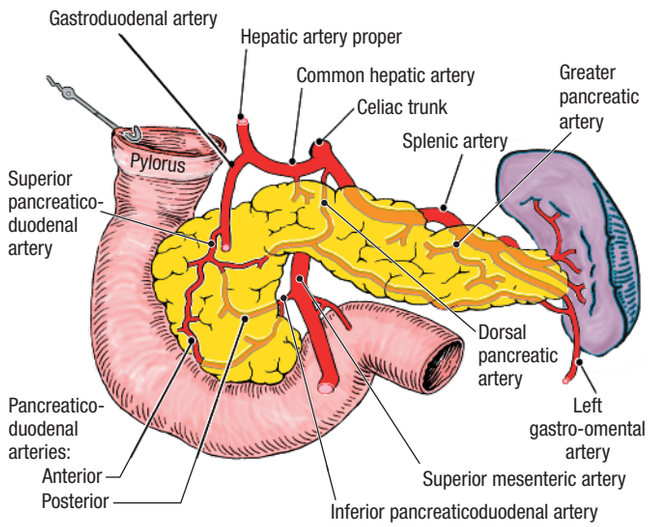

Figure 4.44. Blood supply of the duodenum and pancreas.

HEPATIC PORTAL VEIN [G 152; N 301; R 290; C 201]

Use an illustration to review the hepatic portal venous system. The **superior mesenteric vein** and the **splenic vein** join to form the hepatic portal vein posterior to the neck of the pancreas. The **hepatic portal vein** carries venous blood to the liver from the abdominal portion of the gastrointestinal tract, the spleen, and the pancreas.

1. The **splenic vein** courses posterior to the pancreas, inferior to the splenic artery. Use a probe to dissect posterior to the body of the pancreas and find the splenic vein.
2. Follow the splenic vein to the right, where it is joined by the superior mesenteric vein. This is the origin of the **hepatic portal vein**. Recall that the hepatic portal vein ascends in the hepatoduodenal ligament to the porta hepatis.
3. Return to the field of distribution of the inferior mesenteric vein. Find it and follow it superiorly. The inferior mesenteric vein usually joins the splenic vein, but it may join the superior mesenteric vein, or the junction of the superior mesenteric and splenic veins.
4. Use a textbook or atlas to review the portal–systemic (portal–caval) anastomoses:
   - **Gastroesophageal –** left gastric vein/esophageal veins/azygos vein
   - **Anorectal –** superior rectal vein/middle and inferior rectal veins
   - **Paraumbilical –** paraumbilical veins/superficial epigastric veins
   - **Retroperitoneal –** colic veins/retroperitoneal veins

CLINICAL CORRELATION

Portal Hypertension

The hepatic portal system of veins has no valves. When the hepatic portal vein becomes blocked, blood pressure increases in the hepatic portal system (portal hypertension) and its tributaries become engorged. Portal hypertension causes hemorrhoids, and varicose gastric and esophageal veins. Bleeding from ruptured **gastroesophageal varices** is a dangerous complication of portal hypertension.

After you dissect . . .

Review the relationship of each part of the duodenum to surrounding structures. Review the branches of the celiac trunk and superior mesenteric artery. Use an illustration and the dissected specimen to reconstruct the blood supply to the pancreas and duodenum. Review the formation and field of drainage of the hepatic portal vein. Trace a drop of blood from the small intestine to the inferior vena cava. Use an embryology textbook to review the development of the liver, pancreas, and duodenum.

REMOVAL OF THE GASTROINTESTINAL TRACT

Before you dissect . . .

The order of dissection will be as follows. The arteries to the gastrointestinal tract (celiac trunk, superior mesenteric artery, and inferior mesenteric artery) will be cut close to the aorta. The esophagus and rectum will be cut, using ligatures to prevent spillage of their contents. The gastrointestinal tract will then be removed and reviewed outside of the body. The gastrointestinal tract will be taken to a sink and selected areas will be opened and rinsed to study specializations of the mucosa.

Dissection Instructions

1. Tie two strings 4 cm apart around the superior end of the rectum. Use scissors to cut the rectum *between the strings*. Cut the superior rectal artery.
2. Inferior to the diaphragm, tie one string around the esophagus and cut the esophagus superior to the string. Cut the vagus nerve trunks at the same level.
3. Use scissors to cut the celiac trunk close to the aorta, leaving no stump.
4. Use scissors to cut the superior and inferior mesenteric arteries near the aorta, leaving a 1 cm stump of each.
5. Free the stomach from any peritoneal attachments it may still have to the posterior abdominal wall.
6. Grasp the spleen and gently pull medially. Insert your fingers posterior to the spleen and carefully free the splenic vessels, tail of the pancreas, and body of the pancreas from the posterior abdominal wall.
7. Use scissors to cut the suspensory ligament of the duodenum close to the duodenojejunal junction.
8. Insert your fingers posterior to the duodenum and free it from the posterior abdominal wall.
9. Use scissors to cut the parietal peritoneum lateral to the ascending colon and use your fingers to free the ascending colon from the posterior abdominal wall. Roll the ascending colon toward the midline and use your fingers to loosen its blood vessels from the posterior abdominal wall.
10. Cut the parietal peritoneum lateral to the descending colon and use your fingers to free the descending colon from the posterior abdominal wall. Roll the descending colon toward the midline and use your fingers to loosen its blood vessels from the posterior abdominal wall.
11. The gastrointestinal tract, liver, pancreas, and spleen should now be free of attachments. Remove them from the abdominal cavity. Be careful not to twist or tear the structures in the hepatoduodenal ligament.
12. Arrange the abdominal viscera on the dissecting table in anatomical position and study the parts from the anterior view. Trace the branches of the celiac trunk, superior mesenteric artery, and inferior mesenteric artery to their areas of distribution. Note the differences between the branching pattern of the arteries and the veins. Turn the viscera and repeat the exercise from a posterior view.
13. Carry the viscera to a sink to examine their internal features.
14. Use scissors to open the stomach along its anterior surface. Extend the cut into the first portion of the duodenum. Rinse the mucosa and observe the following features (Fig. 4.45): **[G 121; N 268; R 284; C 199]**
    - **Gastric canal**
    - **Gastric folds (rugae)**
    - **Pyloric antrum**
    - **Pyloric canal**
    - **Pyloric sphincter**
    - **Pyloric orifice**
15. Use scissors to make a longitudinal incision in the anterior wall of the duodenum. In the second part of the duodenum, identify the following (Fig. 4.46): **[G 125; N 271; R 287; C 211]**
    - **Circular folds** (**plicae circulares**)
    - **Major (greater) duodenal papilla** – an elevation of mucosa on the medial wall of the second part of the duodenum. The major duodenal papilla is the shared opening of the main pancreatic duct and bile duct.
    - **Minor (lesser) duodenal papilla** – the site of drainage of the accessory pancreatic duct. If present, it will be approximately 2 cm superior to the major duodenal papilla.

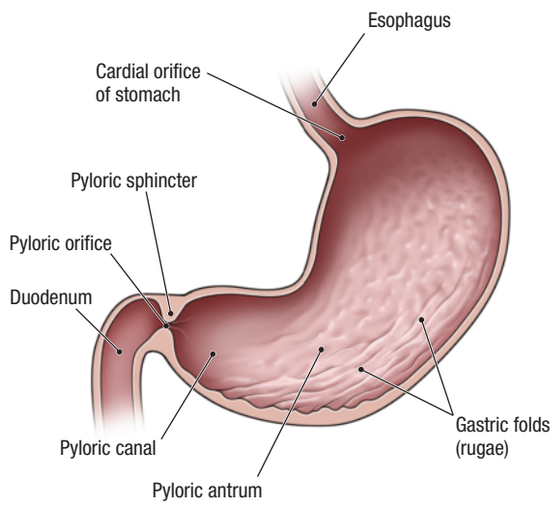

Figure 4.45. Internal features of the stomach.

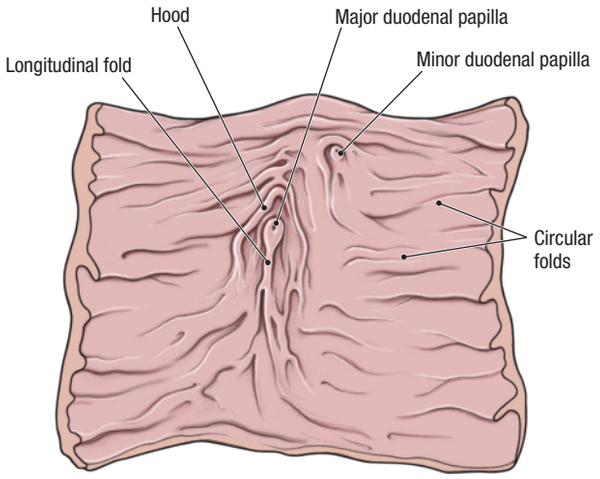

Figure 4.46. Mucosal features in the descending (second) part of the duodenum.

16. Use scissors to make one 5-cm longitudinal incision in the **proximal jejunum** and another in the **distal ileum**. Rinse the mucosa and compare features. Note that the circular folds are larger and closer together in the jejunum (Fig. 4.47). **[G 132; N 272]**
17. Use scissors to make an incision approximately 7.5 cm long in the anterior wall of the **cecum**. Rinse the mucosa and identify the following (Fig. 4.48): **[G 135; N 274; R 298; C 222]**
    - **Ileocecal orifice**
    - **Superior and inferior lips of the ileocecal valve**
    - **Opening of the appendix**

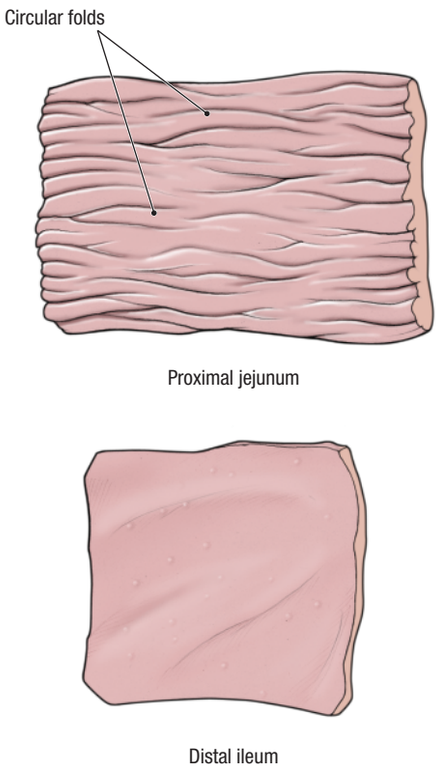

Figure 4.47. Comparison of mucosal features in the proximal jejunum and distal ileum.

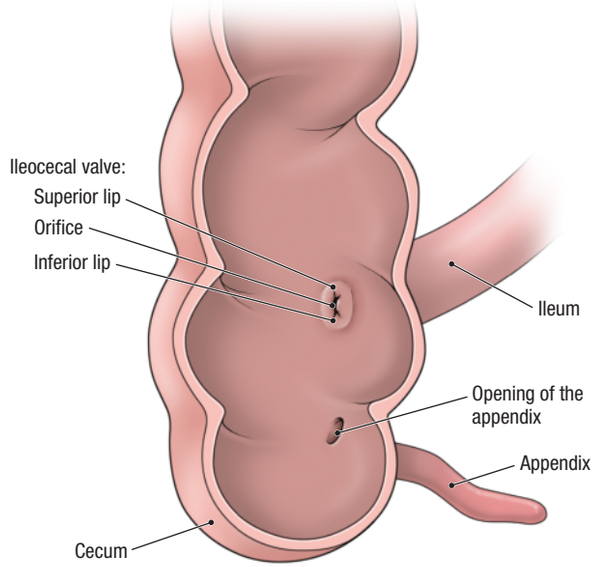

Figure 4.48. Interior of the cecum, from an anterior view.

18. Make an incision approximately 5 cm long in the anterior surface of the transverse colon. Note the **semilunar folds (plicae semilunares)** between adjacent **haustra**. Observe the relative smoothness of the mucosa. **[G 133; N 276; C 224]**
19. The viscera may be stored in a large plastic bag or in the abdominal cavity. Wet these specimens frequently with mold-inhibiting solution.

After you dissect . . .

Review the features of the gastrointestinal mucosa. Compare the quantity and complexity of circular folds in the proximal and distal parts of the small intestine. Compare this arrangement to the mucosal features seen in the stomach and large intestine. Correlate your findings to the function of the organs dissected. Recall the locations of valves in the gastrointestinal tract.

POSTERIOR ABDOMINAL VISCERA

Before you dissect . . .

The posterior abdominal viscera are located in an area that is referred to as the **retroperitoneal space**. The retroperitoneal space is not a real space. It is that part of the body between the parietal peritoneum and the muscles and bones of the posterior abdominal wall (Fig. 4.49). The retroperitoneal space contains the kidneys, ureters, suprarenal glands, aorta, inferior vena cava, and the abdominal portions of the sympathetic trunks. **[G 163; N 332; R 312; C 247]**

The order of dissection will be as follows. The posterior abdominal viscera will be palpated. The kidneys and suprarenal glands will be removed from the renal fascia and studied. The abdominal aorta and the inferior vena cava will be studied. The muscles of the posterior abdominal wall will be studied. The lumbar plexus of nerves will be examined. Finally, the diaphragm will be studied.

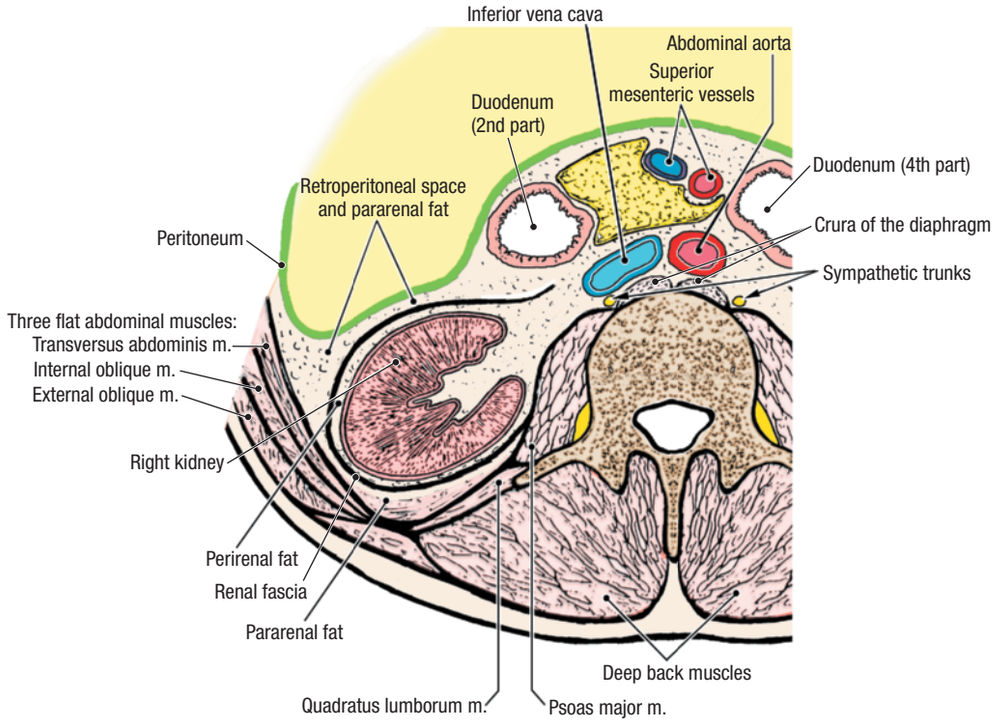

Figure 4.49. Transverse section through the posterior abdominal wall at the level of the kidneys.

Dissection Instructions

1. Use a sponge or paper towels to clean the posterior abdominal wall.
2. Palpate the **kidneys** and the **suprarenal (adrenal) glands**. They lie lateral to the vertebral column at vertebral levels T12 to L3. **[G 155; N 319; R 319; C 228]**
3. Palpate the abdominal aorta.
4. To the right of the abdominal aorta, palpate the inferior vena cava.
5. Remove any remaining parietal peritoneum from the posterior abdominal wall.
6. If you are dissecting a female cadaver, go to step 10.
7. Identify the **testicular artery and vein** at the deep inguinal ring. The testicular artery is quite small and delicate. Follow the testicular vessels superiorly and note that they cross anterior to the ureter. Do not damage the ureter.
8. Observe that the left testicular vein drains into the left renal vein. The right testicular vein drains directly into the inferior vena cava.
9. The **right** and **left testicular arteries** branch directly from the aorta at about vertebral level L2. This origin is inferior to the origin of the renal arteries.

CLINICAL CORRELATION

Testicular Varicocele

Varicocele is a varicose condition of the pampiniform plexus of veins. Varicocele is more common on the left side because the left testicular vein drains into the left renal vein, and the left renal vein is subject to compression where it passes inferior to the superior mesenteric artery.

10. In the **female cadaver**, identify the **ovarian vessels**. Their origin is comparable to that of the testicular vessels in the male. Note that the ovarian vessels cross anterior to the ureter.
11. Inferiorly, the ovarian vessels end in the pelvic cavity. Follow the ovarian vessels inferiorly until they cross the external iliac vessels. Do not follow them into the pelvis at this time.

KIDNEYS [G 155; N 319; R 319; C 228]

The position of the kidneys is well-illustrated on transverse section (Fig. 4.49). The kidneys are well-protected by their position within the body as well as by a cushioning layer of fat.

1. Note that the kidneys lie against the posterior abdominal wall. The anterior aspect of the kidney faces anterolaterally (Fig. 4.49).
2. Use your fingers to separate the **kidney** from the **perirenal fat** and **renal fascia** (Fig. 4.49).
3. Observe that the **superior pole** of the kidney is separated from the suprarenal gland by a thin layer of renal fascia. Carefully insert your fingers between the kidney and the suprarenal gland and separate the two organs. Be careful not to remove the suprarenal gland with the fat.
4. Note the size and shape of the kidney.
5. Identify the **left renal vein**. Use a probe to trace the left renal vein from the left kidney to the inferior vena cava. Observe that it crosses anterior to the renal arteries and aorta.
6. Identify and clean the tributaries of the left renal vein:
   - **Left testicular** (or **ovarian**) **vein**
   - **Left suprarenal vein**

7. Use scissors to cut the left renal vein close to the inferior vena cava. Reflect the left renal vein toward the left. Do not detach the testicular (or ovarian) vein or the left suprarenal vein from the left renal vein.
8. Identify the **left renal artery**, which lies posterior to the left renal vein. Follow the left renal artery to the hilum of the kidney. The renal artery usually divides before it enters the kidney, and accessory renal arteries are common.
9. Observe small branches of the left renal artery to the ureter and left suprarenal gland.
10. Using the left renal artery as a hinge, turn the left kidney toward the right. At the most posterior part of the hilum, identify the **renal pelvis** and its inferior continuation, the **ureter**.
11. Use blunt dissection to follow the ureter inferiorly. Observe that the abdominal part of the ureter passes posterior to the testicular (or ovarian) vessels and crosses the anterior surface of the psoas major muscle. The pelvic part of the ureter will be seen later.
12. Return the left kidney to its correct anatomical position.
13. Clean the relatively short right renal vein. Note that it has no tributaries.
14. Reflect the inferior vena cava inferiorly and slightly toward the right. Identify the **right renal artery**, which lies posterior to the right renal vein and inferior vena cava. Note that the right renal artery is longer than the left renal artery. The right renal pelvis lies posterior to the right renal artery.
15. Follow the right ureter inferiorly and observe its relationship to the right testicular (ovarian) vessels.
16. Use an illustration to review the relationships of the kidneys: **[G 154; N 319; R 306; C 229]**
    - The suprarenal gland is superior to the kidney.
    - Through the peritoneum, the right kidney is in contact with the right colic flexure, the visceral surface of the liver and the second part of the duodenum.
    - Through the peritoneum, the left kidney is in contact with the tail of the pancreas, the left colic flexure, the stomach, and the spleen.
17. Divide the left kidney into anterior and posterior halves by splitting it longitudinally along its lateral border. Open the two halves of the kidney like a book.
18. Identify (Fig. 4.50): **[G 158; N 321; R 314; C 233]**
    - **Renal capsule –** a fibrous capsule which can be stripped off of the surface of the kidney
    - **Renal cortex –** the outer zone of the kidney (approximately one-third of its depth)
    - **Renal medulla –** the inner zone of the kidney consisting of **renal pyramids** and **renal columns** (approximately two-thirds of its depth)
    - **Renal sinus –** the space within the kidney that is occupied by the renal pelvis, calices, vessels, nerves, and fat.
    - **Renal papilla –** the apex of the renal pyramid that projects into a minor calyx
    - **Minor calyx –** a cup-like chamber that is the beginning of the extrarenal duct system. Several minor calyces combine to form a major calyx.

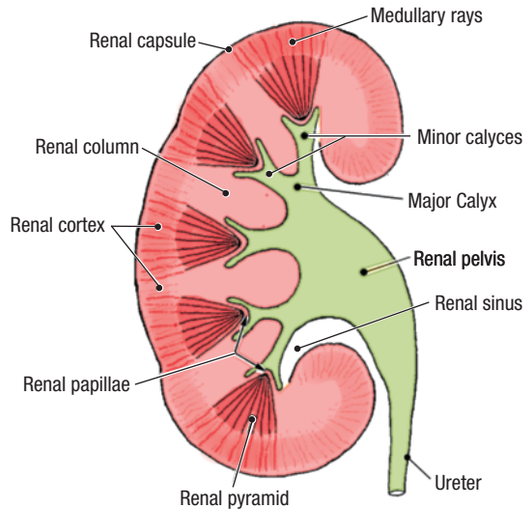

Figure 4.50. Internal features of the kidney in longitudinal section.

- **Major calyx –** two or three per kidney that combine to form the renal pelvis
- **Renal pelvis –** the funnel-like end of the ureter that lies within the renal sinus
- **Ureter –** the muscular duct that carries urine from the kidney to the urinary bladder

CLINICAL CORRELATION

Kidney Stones

Kidney stones (renal calculi) may form in the calyces and renal pelvis. Small kidney stones may spontaneously pass through the ureter into the bladder. Larger kidney stones may lodge at one of three natural constrictions of the ureter: (1) where the renal pelvis joins the ureter; (2) where the ureter crosses the pelvic brim; and (3) at the entrance of the ureter into the urinary bladder.

SUPRARENAL GLANDS [G 155; N 322, 333; R 314; C 230]

The **suprarenal (adrenal) glands** are fragile and easily torn. They are closely related to the superior poles of the kidneys (Fig. 4.51). The suprarenal glands are highly vascularized endocrine glands.

1. Observe that the **right suprarenal gland** is triangular in shape. Part of the right suprarenal gland lies posterior to the inferior vena cava.
2. Observe that the **left suprarenal gland** is semilunar in shape.
3. The suprarenal glands receive multiple arteries (Fig. 4.51). Identify **superior suprarenal arteries** arising

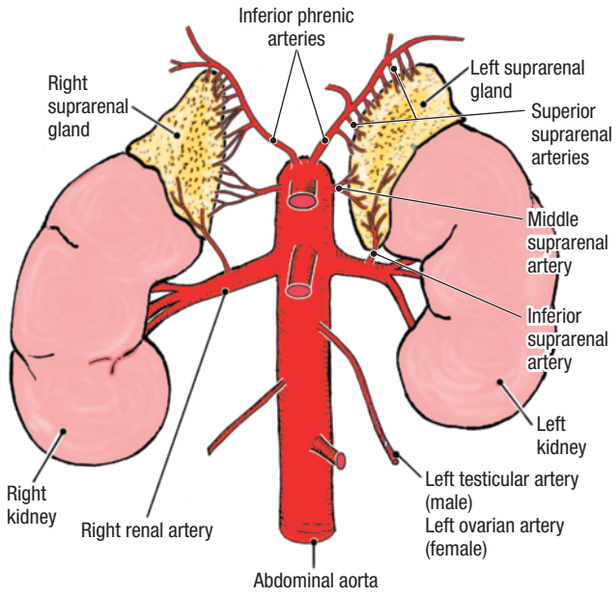

Figure 4.51. Blood supply of the suprarenal glands.

from the **inferior phrenic arteries**. **Middle suprarenal arteries** arise from the aorta near the celiac trunk. **Inferior suprarenal branches** arise from the renal arteries.

4. Note that the left suprarenal vein empties into the left renal vein. The right suprarenal vein drains directly into the inferior vena cava.
5. The suprarenal glands receive numerous sympathetic nerve fibers.

CLINICAL CORRELATION

Suprarenal Glands

The kidneys and suprarenal glands have different embryonic origins. If the kidney fails to ascend to its normal position during development, the suprarenal gland develops in its normal position lateral to the celiac trunk.

ABDOMINAL AORTA AND INFERIOR VENA CAVA [G 167; N 319; R 319; C 238]

1. Use an illustration to study the abdominal aorta. Observe that the abdominal aorta has three types of branches:
   - **Unpaired arteries to the gastrointestinal tract** (celiac trunk, superior mesenteric and inferior mesenteric arteries)
   - **Paired arteries to the three paired abdominal organs** (suprarenal, renal, and testicular or ovarian arteries)
   - **Paired arteries to the abdominal wall** (inferior phrenic and lumbar arteries)
2. Identify at least one **lumbar artery** (Fig. 4.52). Four pairs of lumbar arteries supply the posterior abdominal wall. Trace one lumbar artery to its origin from the posterior aspect of the abdominal aorta. Note that the lumbar arteries pass deep to the psoas major muscles positioned on either side of the vertebral column.
3. Observe the **bifurcation of the abdominal aorta** at vertebral level L4 (Fig. 4.52). In a thin person, the umbilicus projects superior to the bifurcation of the aorta.
4. Identify the **common iliac arteries**, which arise at the bifurcation of the aorta. The common iliac artery supplies blood to the pelvis and lower limb.
5. Review the **inferior vena cava** and its tributaries. Recall that a segment of the inferior vena cava was removed with the liver. Note that the inferior vena cava has no unpaired visceral tributaries because the hepatic portal system collects blood from the gastrointestinal tract. Review the hepatic portal vein. Recall that the hepatic portal vein drains into the liver, and that the hepatic veins drain into the inferior vena cava.

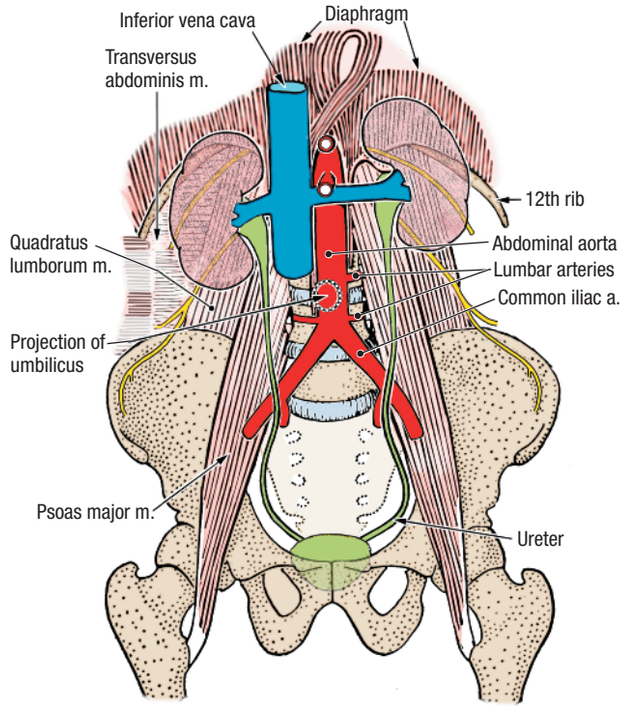

Figure 4.52. Posterior relationships of the kidneys.

After you dissect . . .

Replace the kidneys in their correct anatomical positions. Use an illustration and the dissected specimen to review the relationships of each kidney to surrounding structures. Trace the path taken by a drop of urine from the renal papilla to the ureter. Review the position, relationships, and blood supply of each suprarenal gland. Review the branches of the abdominal aorta.

POSTERIOR ABDOMINAL WALL

Before you dissect . . .

The posterior abdominal wall is composed of the vertebral column, muscles that move the vertebral column, muscles that move the lower limb, and the diaphragm. The nerves that supply the abdominal wall and the lumbar plexus of nerves that supply the lower limb will be dissected with the posterior abdominal wall.

The order of dissection will be as follows. The branches of the lumbar plexus will be studied. Muscles that form the posterior abdominal wall will be dissected. The sympathetic trunk will be studied.

Dissection Instructions

1. Move the kidneys and suprarenal glands toward the midline (do not cut their vessels) and use your hands to remove the remaining fat and the renal fascia from the posterior abdominal wall.
2. Identify the **psoas major muscle** (Fig. 4.53). The proximal attachments of the psoas major muscle are the lumbar vertebrae (bodies, intervertebral discs, and transverse processes). Its distal attachment is the lesser trochanter of the femur. The psoas major muscle is a strong flexor of the thigh and vertebral column. **[G 164; N 255; R 323; C 235]**
3. Look for the **psoas minor muscle**. The psoas minor muscle is absent in approximately 40% of cases and may be present on only one side of the cadaver. The psoas minor muscle has a long flat tendon that passes down the anterior surface of the psoas major muscle to its distal attachment on the pubis.
4. Identify the **iliacus muscle** (Fig. 4.53). The proximal attachment of the iliacus muscle is the iliac fossa. Its distal attachment is on the lesser trochanter of the femur. The iliacus muscle flexes the thigh. The iliacus and psoas major muscles form a functional unit, and together they are called the **iliopsoas muscle**.
5. Identify the **quadratus lumborum muscle** (Fig. 4.53). The proximal attachments of the quadratus lumborum muscle are the twelfth rib and lumbar transverse processes. Its distal attachments are the iliolumbar ligament and iliac crest. The quadratus lumborum muscle flexes the vertebral column laterally and anchors the inferior end of the rib cage during respiration.
6. Review the **transversus abdominis muscle**. The transversus abdominis muscle forms the lateral part of the posterior abdominal wall. The transversus abdominis muscle lies posterior to the quadratus lumborum muscle.
7. Use an illustration and the dissected specimen to study the relationships between the kidneys and the posterior abdominal wall (Fig. 4.52). Verify that the dorsal surface of each kidney is related, through the renal fat and fascia, to the diaphragm, psoas major muscle, quadratus lumborum muscle, and the transversus abdominis muscle. The superior pole of the right kidney is at the level of the twelfth rib. The superior pole of the left kidney is at the level of the eleventh rib.

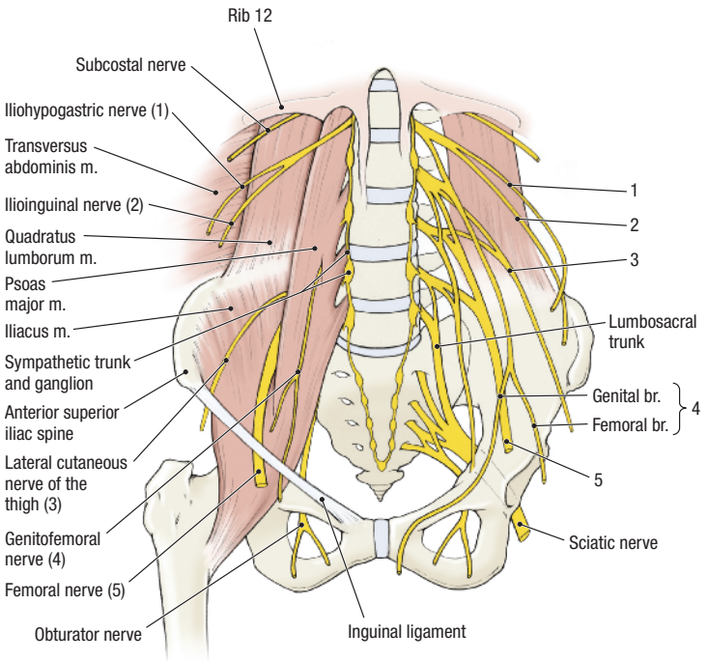

Figure 4.53. Lumbar plexus of nerves.

LUMBAR PLEXUS [G 164, 165; N 259; R 321; C 238]

The nerves of the posterior abdominal wall arise from the ventral primary rami of spinal nerves T12 to L4. The **lumbar plexus** (L1–L4) is formed within the psoas major muscle and its branches can be seen as they emerge from the lateral border of this muscle. The lumbar plexus can be seen only after removal of the psoas major muscle.

Dissect the lumbar plexus on the left side only. Because each branch of the lumbar plexus passes through the psoas major muscle at a different depth, it is necessary to follow each nerve proximally into the psoas major muscle, removing the muscle piece by piece. The nerves of the lumbar plexus are variable in their branching. Use the peripheral relationships of the nerves (their region of distribution or a point of exit from the abdominal cavity) for positive identification.

1. Identify the **genitofemoral nerve**. It is found on the anterior surface of the psoas major muscle (Fig. 4.53). It is the motor nerve to the cremaster muscle (genital part) and supplies a small area of skin inferior and medial to the inguinal ligament (femoral part). The two parts of the genitofemoral nerve divide on the anterior surface of the psoas major muscle superior to the inguinal ligament.
2. Use blunt dissection to remove the fascia from the posterior abdominal wall lateral to the psoas major muscle. The branches of the lumbar plexus are in the extraperitoneal fat and care must be taken to move the dissection instrument parallel to the course of the nerves (Fig. 4.53).
3. To find the **subcostal nerve**, palpate rib 12 and look for the subcostal nerve approximately 1 cm inferior to it.

4. Find the **iliohypogastric** and **ilioinguinal nerves**. They descend steeply across the anterior surface of the quadratus lumborum muscle. Frequently, these two nerves arise from a common trunk and do not separate until they reach the transversus abdominis muscle. To positively identify the ilioinguinal nerve, follow it to the superficial inguinal ring.
5. Identify the **lateral cutaneous nerve of the thigh**. The lateral cutaneous nerve of the thigh passes deep to the inguinal ligament near the anterior superior iliac spine. The lateral cutaneous nerve of the thigh supplies the skin on the lateral aspect of the thigh.
6. Identify the **femoral nerve**. The femoral nerve lies on the lateral side of the psoas major muscle in the groove between the psoas major and iliacus muscles. The femoral nerve innervates these two muscles. The femoral nerve passes deep to the inguinal ligament and provides motor and sensory branches to the anterior thigh.
7. To find the **obturator nerve**, insert your finger on the medial side of the psoas major muscle and move your finger parallel to the muscle, creating a gap between the psoas major muscle and the common iliac vessels. The obturator nerve supplies motor and sensory innervation to the medial thigh.
8. Identify the **lumbosacral trunk**. The lumbosacral trunk is a large nerve that is formed by a contribution from the ventral primary ramus of L4 and all of the ventral primary ramus of L5. The lumbosacral trunk passes into the pelvis to join the sacral plexus.

SYMPATHETIC TRUNK [G 168; N 308; R 322; C 329]

1. Study the location of the **sympathetic trunk** on a transverse section of the abdomen (Fig. 4.49). Note that each sympathetic trunk is found on the vertebral body between the crus of the diaphragm and the psoas major muscle.
2. Identify **lumbar splanchnic nerves** that pass anteriorly from the sympathetic trunk to the aortic autonomic nerve plexus.
3. Identify **rami communicantes** that pass posteriorly from the sympathetic ganglia to lumbar ventral primary rami. Note that each ramus communicans passes between the psoas major muscle and the vertebral body. The gray rami of the lower lumbar region are the longest in the body because the sympathetic trunk crosses the anterolateral surface of the lumbar vertebral bodies.
4. Use an illustration to review the autonomic nerve supply of the abdominal viscera.

After you dissect . . .

Use the dissected specimen to review the proximal and distal attachments, as well as the action of each of the muscles of the posterior abdominal wall. Review the three muscles that form the anterolateral abdominal wall (external oblique, internal oblique, and transversus abdominis). Follow each branch of the lumbar plexus peripherally. Review the region of innervation of each of these nerves. Use an atlas drawing to review the sympathetic trunk.

DIAPHRAGM

Before you dissect . . .

The **diaphragm** forms the roof of the abdominal cavity and the floor of the thoracic cavity (Fig. 4.54). It is the principal muscle of respiration. The diaphragm has a right half and a left half (the **hemidiaphragms**).

The order of dissection will be as follows. The parts of the diaphragm will be identified. The phrenic nerve will be reviewed. The greater splanchnic nerves that pass through the diaphragm will be studied.

Dissection Instructions

1. Use blunt dissection to strip the parietal peritoneum and connective tissue off of the abdominal surface of the diaphragm. [G 166; N 255; R 273; C 237]
2. Identify the parts of the diaphragm (Fig. 4.54):
   - **Central tendon –** the aponeurotic center of the diaphragm, which is the distal attachment of all of its muscular parts.
   - **Sternal part –** two small bundles of muscle fibers that attach to the posterior surface of the xiphoid process.
   - **Costal part –** the muscle fibers that attach to the inferior six ribs and their costal cartilages.
   - **Lumbar part –** formed by two crura (right and left).
3. Identify the **right crus**. The proximal attachments of the right crus of the diaphragm are the bodies of vertebrae L1 to L3. The **esophageal hiatus** is an opening in the right crus.
4. Observe the **left crus** (Fig. 4.54). The proximal attachments of the left crus of the diaphragm are the bodies of vertebrae L1 to L2.
5. Identify the **arcuate ligaments (lumbocostal arches)**. The arcuate ligaments are thickenings of fascia that serve as proximal attachments for some of the muscle fibers of the diaphragm. There are two arcuate ligaments on each side of the body:

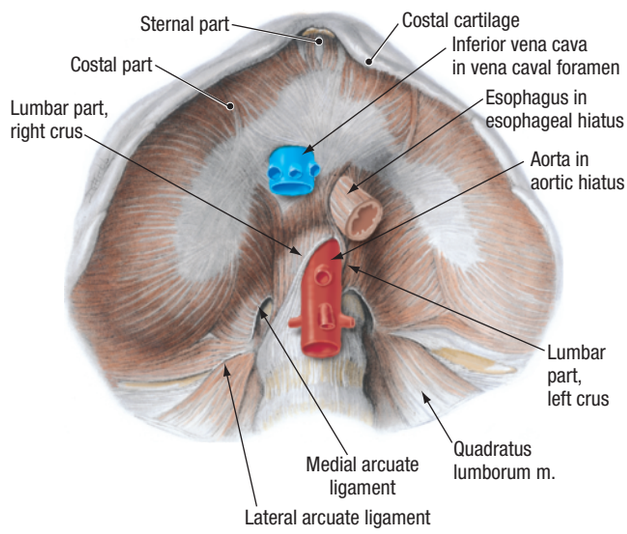

Figure 4.54. Diaphragm.

- **Medial arcuate ligament –** bridges the anterior surface of the psoas major muscle.
- **Lateral arcuate ligament –** bridges the anterior surface of the quadratus lumborum muscle.

6. There are three large openings in the diaphragm (Fig. 4.54). Identify the **vena caval foramen**, which passes through the central tendon (vertebral level T8) and the **esophageal hiatus**, which passes through the right crus (vertebral level T10). The aorta passes through the **aortic hiatus** (vertebral level T12).
7. The **right** and **left phrenic nerves** innervate the diaphragm. Each phrenic nerve provides motor innervation to one half of the diaphragm (one hemidiaphragm). The phrenic nerves supply most of the sensory innervation to the abdominal (parietal peritoneum) and thoracic (parietal pleura) surfaces of the diaphragm. The pleural and peritoneal coverings of the peripheral part of the diaphragm receive sensory fibers from the lower intercostal nerves (T5–T11) and the subcostal nerve.
8. Identify the **greater splanchnic nerve** in the thorax and follow it to the superior surface of the diaphragm. **[G 168; N 259; C 238]**
9. Push a probe through the diaphragm parallel to the greater splanchnic nerve. Note that the greater splanchnic nerve penetrates the crus to enter the abdominal cavity.
10. Observe that the main portion of the greater splanchnic nerve distributes to the celiac ganglion where its sympathetic axons will synapse. The greater splanchnic nerve also innervates the suprarenal gland.
11. Find the **celiac ganglia**. The celiac ganglia are found on the left and right sides of the celiac trunk near its origin from the aorta. The celiac ganglia are the largest of the sympathetic ganglia that are located on the surface of the aorta.
12. Use an illustration or textbook description to review the autonomic nerve supply of the abdomen.

CLINICAL CORRELATION

Diaphragm

The phrenic nerves arise from cervical spinal cord segments (C3–C5). Therefore, pain from the diaphragm is referred to the shoulder region (supraclavicular nerve territory). The diaphragm is paralyzed in cases of high cervical spinal cord injuries, but is spared in low cervical spinal cord injuries. A paralyzed hemidiaphragm cannot contract (descend), so it will appear high in the thorax on a chest X-ray.

After you dissect . . .

Review the attachments of the diaphragm to the skeleton of the thoracic wall. Trace the course of the thoracic aorta as it passes through the aortic hiatus to become the abdominal aorta. Review the course of the esophagus and the vagus nerve trunks through the esophageal hiatus. Recall the position of the heart on the superior surface of the diaphragm and review the course of the inferior vena cava. Study an illustration and observe that the thoracic duct passes through the aortic hiatus and that the splanchnic nerves (greater, lesser, and least) penetrate the crura.

CHAPTER 5

THE PELVIS AND PERINEUM

The pelvis is the area of transition between the trunk and the lower limbs. The bony pelvis serves as the foundation for the pelvic region and it provides strong support for the vertebral column upon the lower limbs. The pelvic cavity is continuous with the abdominal cavity, the transition occurring at the plane of the **pelvic inlet** (Fig. 5.01). The pelvic cavity contains the rectum, the urinary bladder, and the internal genitalia. **[G 185]**

The perineum is the region of the trunk that is located between the thighs. The **pelvic diaphragm** separates the pelvic cavity from the perineum (Fig. 5.01). The perineum contains the anal canal, the urethra, and the external genitalia (penis and scrotum in the male, vulva in the female).

This chapter begins with the dissection of structures in the anal triangle that are common to both sexes. Dissection of internal and external genitalia is divided into two sections, one for male cadavers and one for female cadavers. Students will be expected to demonstrate knowledge of both male and female anatomy in the pelvis and perineum. Each dissection team should partner with another dissection team that is working on a cadaver of the opposite sex.

SKELETON OF THE PELVIS

Refer to an articulated bony pelvis. The **pelvis** (L. *pelvis*, basin) is formed by two **hip bones (os coxae)** joined posteriorly by the **sacrum** (Fig. 5.02A). Each hip bone is formed by three fused bones: **pubis**, **ischium**, and **ilium**. The point of fusion of these three bones is the **acetabulum**. The **coccyx** is attached to the sacrum. **[G 185; N 341; R 422; C 253]**

On the hip bone, identify: **[G 184; N 340; R 419; C 250]**

- **Iliac fossa**
- **Iliopubic eminence**
- **Arcuate line**
- **Pecten pubis**
- **Superior pubic ramus**
- **Pubic symphysis**
- **Pubic arch**
- **Ischiopubic ramus**—formed by the ischial ramus and the inferior pubic ramus
- **Obturator foramen**
- **Ischial tuberosity**
- **Ischial spine**

On the sacrum identify: **[G 185; N 341; R 420; C 428]**

- **Sacral promontory**
- **Anterior sacral foramina**
- **Coccyx**

The hip bone and sacrum are connected by strong ligaments. On a model with pelvic ligaments, identify (Fig. 5.02A,B): **[G 186, 188; N 340; R 430; C 255, 257]**

- **Sacrotuberous ligament**
- **Sacrospinous ligament**
- **Obturator membrane**
- **Greater sciatic foramen**
- **Lesser sciatic foramen**

Note that the sacrotuberous ligament and sacrospinous ligament convert the **greater and lesser sciatic notches** into the **greater and lesser sciatic foramina**.

The sacroiliac articulation is a synovial joint between the auricular surfaces of the sacrum and the ilium. It is strengthened by an **anterior sacroiliac ligament** and a **posterior sacroiliac ligament** (Fig. 5.02A, B).

Identify the **pubic arch**. Note that the **subpubic angle** (angle of the pubic arch) is wider in females than males. **[G 190, 191; N 342; R 422; C 254, 255]**

Identify the **pelvic inlet (superior pelvic aperture)**. The bony rim of the pelvic inlet is called the **pelvic brim**. From anterior to posterior, identify the structures that form the pelvic brim: **[G 191; N 341; R 421; C 253]**

- **Superior margin of the pubic symphysis**
- **Posterior border of the pubic crest**
- **Pecten pubis**
- **Arcuate line of the ilium**

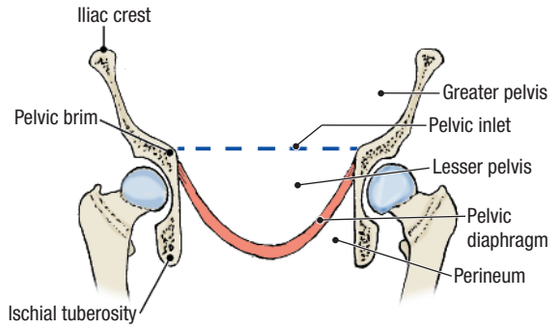

Figure 5.01. The pelvis on coronal section.

KEY TO REFERENCES
G = Grant's Atlas, 11th ed., page number
N = Netter's Atlas, 3rd ed., plate number
R = Rohen's Color Atlas of Anatomy, 5th ed., page number
C = Clemente's Atlas, 4th ed., page number

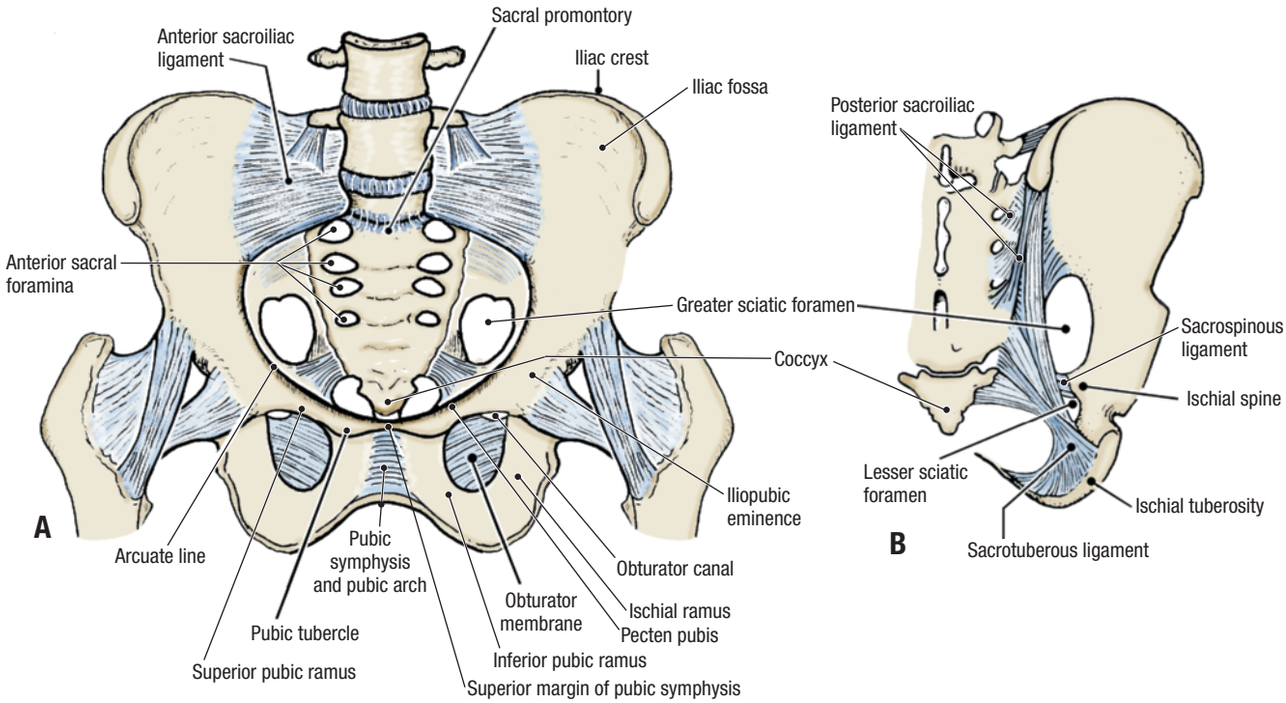

Figure 5.02. Bones and ligaments of the pelvis. **A.** Anterior view. **B.** Posterior view.

- **Anterior border of the ala (wing) of the sacrum**
- **Sacral promontory**

Identify the **pelvic outlet**. The pelvic outlet is bounded on each side by: **[G 192; N 340; R 430; C 256]**

- **Inferior margin of the pubic symphysis**
- **Ischiopubic ramus**
- **Ischial tuberosity**
- **Sacrotuberous ligament**
- **Tip of the coccyx**

The pelvic inlet divides the pelvis into the **greater (false) pelvis** and **lesser (true) pelvis** (Fig. 5.01). The greater pelvis is situated superior to the pelvic brim and is bounded bilaterally by the ala of the ilium. The lesser pelvis is located inferior to the pelvic brim. The inferior border of the lesser pelvis is the pelvic diaphragm. **[G 185]**

In the **erect posture** (anatomical position), the anterior superior iliac spines and the anterior aspect of the pubis are in the same vertical plane. In this position, the plane of the pelvic inlet forms an angle of approximately 55 degrees to the horizontal. A line connecting the superior aspect of the pubis with the tip of the coccyx lies in the horizontal plane. **[G 184; N 340; R 424]**

ANAL TRIANGLE

Before you dissect . . .

The **perineum** is a diamond-shaped area between the thighs that is divided for descriptive purposes into two triangles (Fig. 5.03). The **anal triangle** is the posterior part of the perineum and it contains the anal canal and anus. The **urogenital triangle** is the anterior part of the perineum and contains the urethra

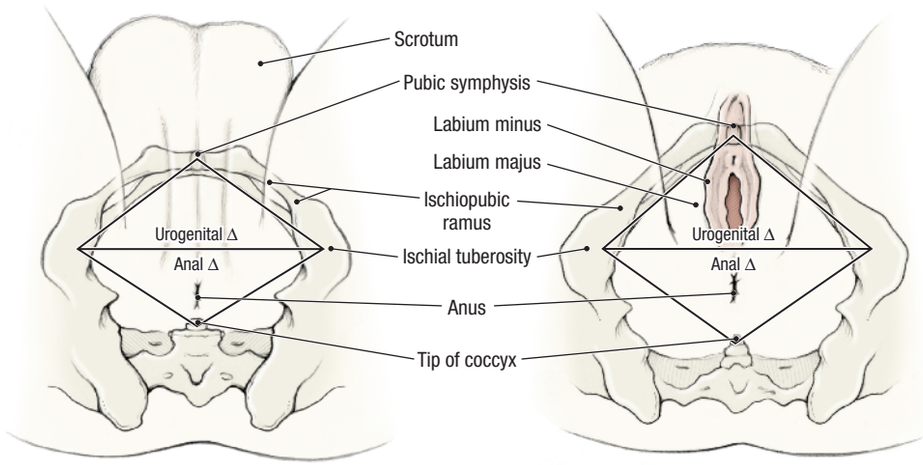

Figure 5.03. Boundaries of the urogenital and anal triangles in the male and female.

and the external genitalia. At the outset of dissection, it is important to understand that the *pelvic diaphragm separates the pelvic cavity from the perineum* (Fig. 5.01). [G 185]

The order of dissection will be as follows. Dissection of the anal triangle will begin with removal of skin from the gluteal region and partial reflection of the gluteus maximus muscle. The nerves and vessels of the ischioanal fossa will be dissected. The fat will be removed from the ischioanal fossa to reveal the inferior surface of the pelvic diaphragm.

Dissection Instructions

SKIN INCISIONS

1. If the lower limb has been dissected previously, reflect the gluteus maximus muscle laterally and move ahead to the dissection of the *ischioanal fossa*. If the lower limb has not been dissected, continue with step 2.
2. Place the cadaver in the prone position.
3. Refer to Figure 5.04.
4. Make an incision that follows the lateral border of the sacrum and the iliac crest from the tip of the coccyx (S) to the midaxillary line (T). If the back has been skinned, this incision has been made previously.
5. Make a midline skin incision from "S" to the posterior edge of the anus.
6. Make an incision that encircles the anus.
7. Make an incision from the anterior edge of the anus down the medial surface of the thigh to point "D" (approximately 7.5 cm down the medial thigh).
8. Make an oblique skin incision from "D" across the posterior surface of the thigh to point "E" on the lateral surface of the thigh. Point E should be approximately 30 cm inferior to the iliac crest.
9. Make a skin incision along the lateral side of the thigh from "T" to "E."
10. Remove the skin from medial to lateral and place it in the tissue container.
11. Remove the superficial fascia from the surface of the gluteus maximus muscle and place it in the tissue container.
12. Clean the posterior surface of the **gluteus maximus muscle** (Fig. 5.05). Do not save the **inferior cluneal nerves**, but take care not to cut the deep fascia of the posterior thigh**.**
13. Use your hands to define the superior margin of the gluteus maximus muscle and separate it from the gluteal aponeurosis, which overlies the gluteus medius muscle (Fig. 5.05). The plane between the gluteus maximus muscle and the gluteus medius muscle can be found by observing the different directions of their muscle fibers.
14. Use scissors to cut the proximal attachment of the gluteus maximus muscle very close the posterior surface of the sacrum and coccyx (dotted line in Fig. 5.05). Start superiorly and work inferiorly. Insert your fingers under the superior margin of the gluteus maximus muscle and loosen it from deeper structures as you cut.
15. Inferiorly, the gluteus maximus muscle is attached to the **sacrotuberous ligament**. Use scissors to detach the gluteus maximus from the sacrotuberous ligament but do not cut the ligament.
16. Reflect the gluteus maximus muscle laterally until the inferior gluteal nerve and vessels prevent further reflection. The entire length of the sacrotuberous ligament should be visible.

ISCHIOANAL FOSSA

The **ischioanal (ischiorectal) fossa** is a wedge-shaped area on either side of the anus. The apex of the wedge is directed superiorly and the base is beneath the skin. The ischioanal fossa is filled with fat that helps accommodate the fetus during childbirth or the distended anal canal during the passage of feces. The ischioanal fat is part of the su-

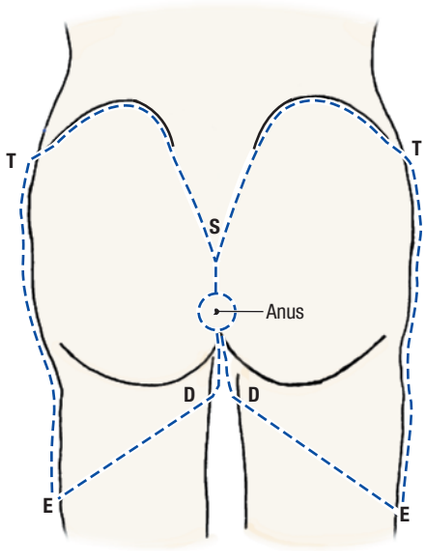

Figure 5.04. Skin incisions.

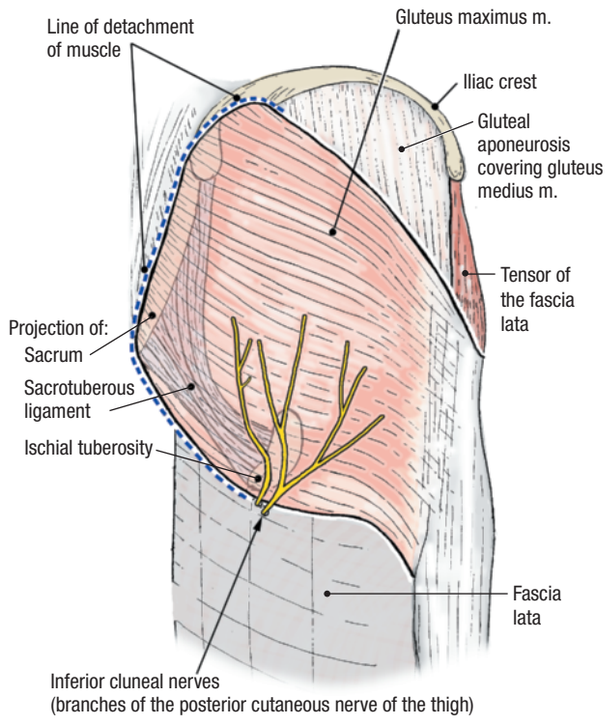

Figure 5.05. The cut used to reflect the gluteus maximus muscle.

perficial fascia of this region. The goal of this dissection is to remove the fat and identify the nerves and vessels that pass through the ischioanal fossa. **[G 245; N 391; R 339; C 301]**

1. Lateral to the anus, insert closed scissors 4 cm deep into the ischioanal fat. Open the scissors in the transverse direction to tear the fat (Incision, Fig. 5.06).
2. Insert your finger into the incision and move it back and forth (medial to lateral) to enlarge the opening.
3. Palpate the **inferior rectal (anal) nerve** and **vessels** (Fig. 5.06). Preserve the branches of the inferior rectal nerve and vessels but use blunt dissection to remove the fat that surrounds them. Dry the area with paper towels if necessary.
4. Use blunt dissection to clean the **external anal sphincter muscle** (Fig. 5.06). The external anal sphincter muscle has three parts:
   - **Subcutaneous** – encircling the anus (not visible in dissection)
   - **Superficial** – anchoring the anus to the perineal body and coccyx
   - **Deep** – a circular band that is fused with the pelvic diaphragm
5. Use blunt dissection to clean the **inferior surface of the pelvic diaphragm** (medial boundary of the ischioanal fossa).
6. Use blunt dissection to clean the **fascia of the obturator internus muscle** (the lateral boundary of the ischioanal fossa).

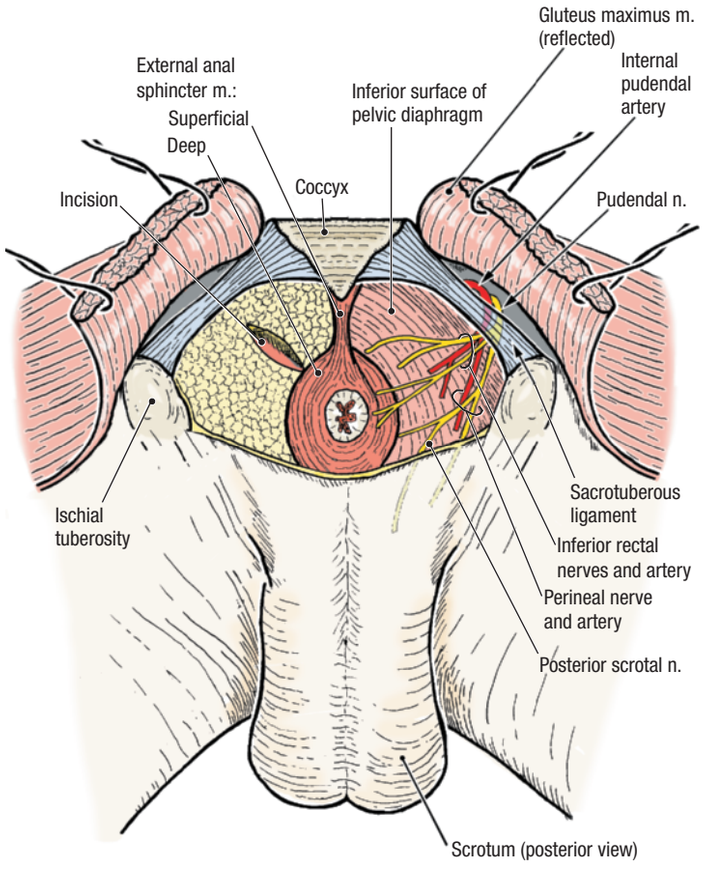

Figure 5.06. Initial incision used to begin the dissection of the ischioanal fossa.

7. Observe that the inferior rectal nerve and vessels penetrate the fascia of the obturator internus muscle. The inferior rectal vessels and nerve exit the **pudendal canal** to enter the ischioanal fossa.
8. Place gentle traction on the inferior rectal vessels and nerve and observe that a ridge is raised in the obturator internus fascia. Carefully incise the obturator fascia along this ridge to open the pudendal canal.
9. Use a probe to elevate the contents of the pudendal canal. The pudendal canal contains the **pudendal nerve** and the **internal pudendal artery and vein**.

After you dissect . . .

Review the boundaries of the true pelvis and the concept that the pelvic diaphragm separates the pelvic cavity from the perineum. In the dissected specimen, review the inferior surface of the pelvic diaphragm and understand that this is the "roof" of the perineum. Use the dissected specimen to review the lateral and medial walls of the ischioanal fossa. Review the external anal sphincter muscle and its blood and nerve supply. Understand that the external anal sphincter muscle is skeletal muscle under voluntary control.

MALE UROGENITAL TRIANGLE

If you are dissecting a female cadaver, go to the dissection of the *Female Urogenital Triangle* (page 110).

Before you dissect . . .

The order of dissection of the male urogenital triangle will be as follows. The skin will be removed from the urogenital triangle. The superficial perineal fascia will be removed and the contents of the superficial perineal pouch will be identified. The skin will be removed from the penis and its parts will be studied. The contents of the deep perineal pouch will be described, but not dissected.

Dissection Instructions

SKIN REMOVAL

1. The scrotum, testis, and spermatic cord were dissected with the anterior abdominal wall (Chapter 4). Review this material.
2. Place the cadaver in the supine position. Stretch the thighs widely apart and brace them. Usually, only one student can work on the urogenital triangle at a time. The dissector should be positioned between the thighs.
3. Make a skin incision that encircles the proximal end of the penis. The skin is very thin.
4. Make a midline skin incision posterior to the proximal end of the penis that splits the scrotum along the scrotal septum. Carry the cut posteriorly as far as the anus.
5. Make an incision in the midline superior to the penis. Stop where the skin of the abdomen was removed previously.

6. Reflect the skin flaps from medial to lateral. Detach the scrotum and skin flaps along the medial thigh and place them in the tissue container.
7. If the cadaver has a large amount of fat in the superficial fascia of the medial thighs, remove a portion of the superficial fascia starting at the ischiopubic ramus and extending down the medial thigh approximately 7 cm. Stay superficial to the deep fascia when removing the superficial fascia.
8. Note that the **posterior scrotal nerve and vessels** enter the urogenital triangle by passing lateral to the external anal sphincter muscle. The posterior scrotal nerve and vessels supply the posterior part of the scrotum.

SUPERFICIAL PERINEAL POUCH [G 245, 246; N 364; R 338; C 300]

The superficial perineal fascia has a superficial fatty layer and a deep membranous layer. The superficial fatty layer is continuous with the superficial fatty layer of the lower abdominal wall, ischioanal fossa, and thigh. The **membranous layer of the superficial perineal fascia (Colles' fascia)** is continuous with the membranous layer of the superficial fascia of the anterior abdominal wall, and the **dartos fascia** of the penis and scrotum (Fig. 5.07A). The membranous layer of the superficial perineal fascia is attached to the ischiopubic ramus as far posteriorly as the ischial tuberosity and to the posterior edge of the **perineal membrane**. The membranous layer of the superficial perineal fascia forms the superficial boundary of the **superficial perineal pouch (space)**.

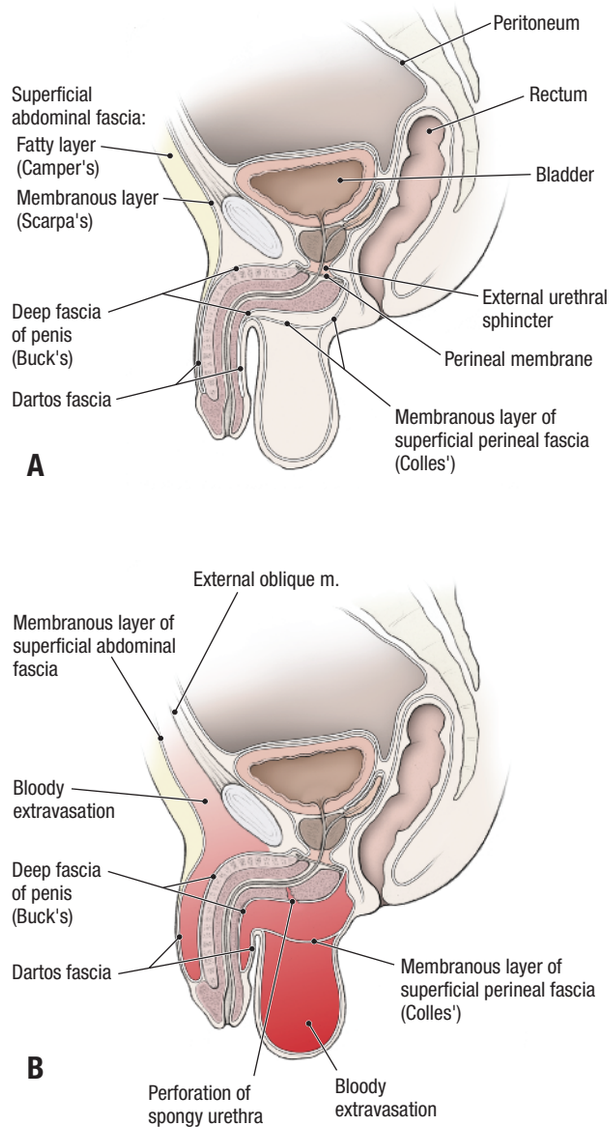

Figure 5.07. Fasciae of the perineum. **A.** The membranous layer of the superficial perineal fascia (Colles' fascia) is continuous with the superficial fascia (dartos fascia) of the scrotum and the penis. It is also continuous with the membranous layer of superficial fascia of the lower abdominal wall (Scarpa's fascia) and is attached to the posterior border of the perineal membrane. **B.** After injury to the urethra in the perineum, extravasated urine is contained in the superficial perineal pouch and spreads into the lower abdominal wall.

CLINICAL CORRELATION

Superficial Perineal Pouch

If the urethra is injured in the perineum, urine may escape into the superficial perineal pouch. The urine may spread into the scrotum and penis, and upward into the lower abdominal wall between the membranous layer of the abdominal superficial fascia (Scarpa's fascia) and the aponeurosis of the external oblique muscle (Fig. 5.07B). The urine does not enter the thigh because the membranous layer of the superficial fascia attaches to the fascia lata, ischiopubic ramus, and posterior edge of the perineal membrane.

1. The **contents of the superficial perineal pouch in the male** are **three paired muscles (superficial transverse perineal**, **bulbospongiosus**, and **ischiocavernosus)**, the **crura of the penis**, and the **bulb of the penis** (Fig. 5.08A). The superficial perineal pouch also contains the arteries, veins, and nerves that supply these structures.
2. It is not necessary to identify the membranous layer of the superficial perineal fascia to complete the dissection. Use a probe to dissect through the superficial perineal fascia approximately 2 cm lateral to the midline.
3. Use blunt dissection to find the **superficial transverse perineal muscle** at the posterior border of the urogenital triangle (Fig. 5.08A). The superficial transverse perineal muscle may be delicate and difficult to find; limit the time spent looking for it. The lateral attachments of the superficial transverse perineal muscle are the ischial tuberosity and the ischiopubic ramus. The medial attachment of the superficial transverse perineal muscle is the **perineal body**. The perineal body is a fibromuscular mass located between the anal canal and the posterior edge of the perineal membrane. It serves as an attachment for several muscles.

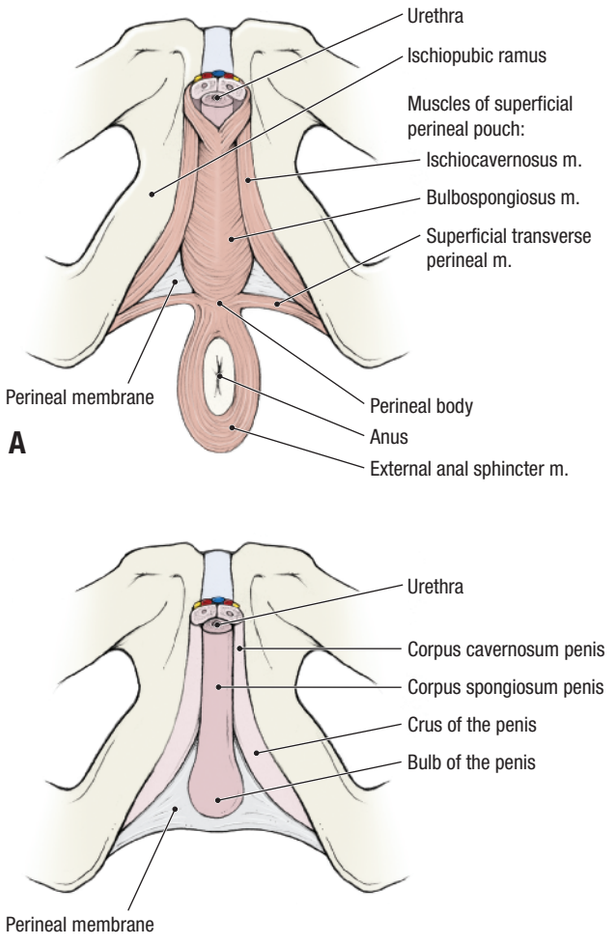

Figure 5.08. Contents of the superficial perineal pouch in the male. **A.** Muscles. **B.** Erectile bodies.

The superficial transverse perineal muscle helps to support the perineal body.

4. Use a probe to clean the surface of the **ischiocavernosus muscle**. The ischiocavernosus muscle covers the superficial surface of the **crus of the penis**. The proximal attachment of the ischiocavernosus muscle is the ischial tuberosity and the ischiopubic ramus. The distal attachment of the ischiocavernosus muscle is the crus of the penis. The ischiocavernosus muscle forces blood from the crus of the penis into the corpus cavernosum penis.
5. Identify the **bulbospongiosus muscle** in the midline of the urogenital triangle. The bulbospongiosus muscle covers the superficial surface of the **bulb of the penis**. The posterior attachments of the bulbospongiosus muscle are the bulbospongiosus muscle of the opposite side (a midline raphe) and the perineal body. The anterior attachment of the bulbospongiosus muscle is the corpus cavernosum penis. The bulbospongiosus muscle compresses the bulb of the penis to expel urine or semen.
6. Use a probe to dissect between the three muscles of the superficial perineal pouch until a small triangular opening is created (Fig. 5.08A). The membrane that becomes visible through this opening is the **perineal membrane**. The perineal membrane is the deep boundary of the superficial perineal pouch and the erectile bodies are attached to it.
7. Use scissors to divide the bulbospongiosus muscles along their midline raphe. On the right side of the cadaver, remove the bulbospongiosus muscle.
8. Identify the **bulb of the penis** (Fig. 5.08B). The bulb of the penis is continuous with the corpus spongiosum penis and contains a portion of the spongy urethra.
9. On the right side of the cadaver, use blunt dissection to remove the ischiocavernosus muscle from the **crus of the penis** (Fig. 5.08B). The crus of the penis is continuous with the corpus cavernosum penis.

PENIS [G 250; N 364, 365; R 324, 327; C 182, 302]

In the anatomical position, the penis is erect. The surface of the penis that is closest to the anterior abdominal wall is the **dorsal surface of the penis**.

Study a drawing of a transverse section of the **penis** (L. *penis*, tail) (Fig. 5.09). The **superficial fascia of the penis (dartos fascia)** has no fat and contains the **superficial dorsal vein of the penis.** The **deep fascia of the penis (Buck's fascia)** is an investing fascia. Contained within the deep fascia of the penis are the **corpus spongiosum**, **corpus cavernosum (paired)**, **deep dorsal vein of the penis (unpaired)**, **dorsal artery of the penis (paired)**, **and dorsal nerve of the penis (paired)**.

1. Identify the parts of the penis:
   - **Root**
   - **Body (shaft)**
   - **Glans penis**
   - **Corona of the glans**
   - **Prepuce**
   - **Frenulum**
   - **External urethral orifice**
2. Use a scalpel to make a midline incision down the ventral surface of the penis. Remove the skin from the body of the penis, detaching it around the corona of the glans. Do not skin the glans.
3. Use a probe to dissect the **superficial dorsal vein** of the penis. The superficial dorsal vein of the penis drains into the **superficial external pudendal vein** of the inguinal region.

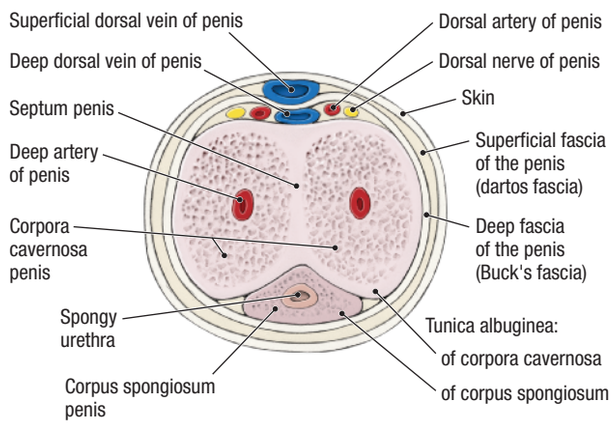

Figure 5.09. Transverse section through the body of the penis.

4. On the dorsum of the penis, use a probe to dissect through the **deep fascia of the penis** and identify (Fig. 5.10): **[G 250; R 337; C 302]**
   - **Deep dorsal vein of the penis** – a single vein in the midline. Most of the blood from the penis drains through the deep dorsal vein into the **prostatic venous plexus**.
   - **Dorsal artery of the penis (2)** – one artery on each side of the deep dorsal vein. The dorsal artery of the penis is a terminal branch of the internal pudendal artery.
   - **Dorsal nerve of the penis (2)** – one nerve on each side of the midline, lateral to the deep dorsal artery. The dorsal nerve of the penis is a branch of the pudendal nerve.
5. Use a probe to trace the vessels and nerves of the penis proximally. Use an illustration to study the course of the pudendal nerve and the internal pudendal artery (Fig. 5.10). Observe that the dorsal artery and nerve of the penis course deep to the perineal membrane before they emerge onto the dorsum of the penis. The deep dorsal vein passes between the inferior pubic ligament and the anterior edge of the perineal membrane to enter the pelvis, and does not accompany the deep dorsal artery and dorsal nerve proximal to the body of the penis. **[G 250, 254; N 383, 390; R 336; C 287, 304]**

SPONGY URETHRA [G 255; N 368; R 326, 327; C 290]

The male urethra consists of three portions: **prostatic urethra, membranous urethra**, and **spongy urethra** (Fig. 5.11). The spongy urethra is the portion that is located within the corpus spongiosum penis. The next objective is to longitudinally open the spongy urethra.

1. Examine the **external urethral orifice** at the tip of the glans penis. Push a probe into the external urethral orifice, and then use a scalpel to cut down to the probe from both the dorsal and ventral surfaces of the penis.

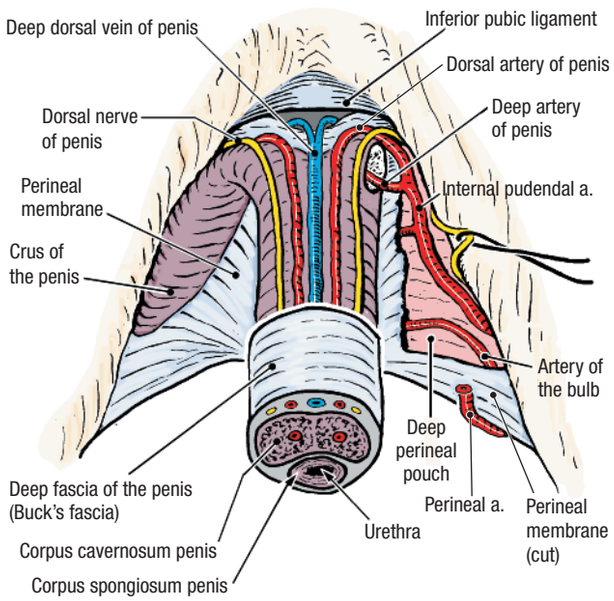

Figure 5.10. Arteries and nerves of the penis.

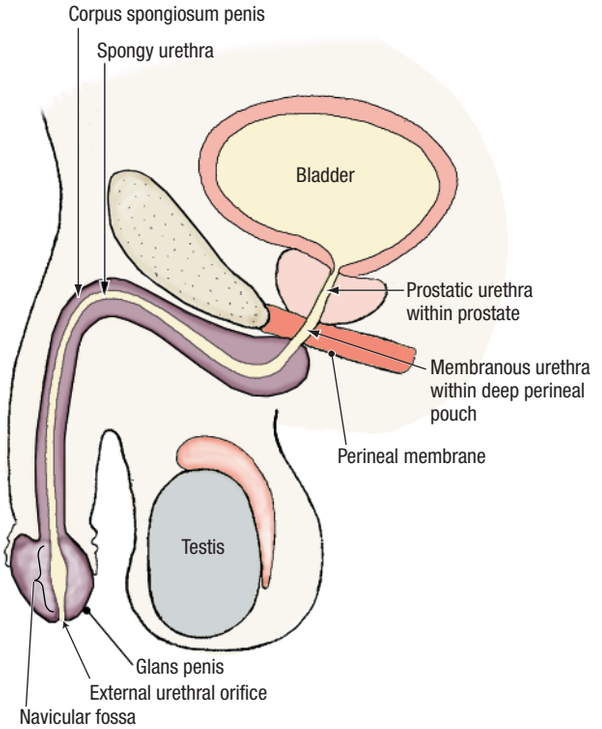

Figure 5.11. Parts of the male urethra.

Cut in the median plane *of the penis* (it may not be a straight line).

2. Advance the probe proximally, and continue to divide the penis. Dorsal to the probe, the cut should pass between the corpora cavernosa and may split the deep dorsal vein longitudinally. Stop inferior to the pubic symphysis where the two corpora cavernosa separate. Ventral to the probe the cut should divide the corpus spongiosum into equal halves. Stop at the bulb of the penis.
3. In the bulb of the penis, the urethra bends at a sharp angle and passes through the perineal membrane (Fig. 5.11). Carefully complete the cut through the bulb posterior to the urethra but do not cut through the perineal membrane.
4. Examine the interior of the spongy urethra. Identify the **navicular fossa**, a widening of the urethra in the glans penis. The openings of the ducts of the **bulbourethral glands** are in the proximal part of the spongy urethra, but may be too small to see.
5. Note that the **glans penis** (L. *glans*, acorn) is the distal expansion of the corpus spongiosum and that it caps the two corpora cavernosa penis. The spongy urethra terminates by passing through the glans.
6. On the right side of the penis, make a transverse cut through the body of the penis about midway down its length.
7. On the cut surface of the transverse section of the penis, study the relationship of the **corpus cavernosum penis** and **corpus spongiosum penis**. Identify (Fig. 5.09): **[G 254; N 364; R 327; C 182]**
   - **Tunica albuginea of the corpora cavernosa penis**

- **Tunica albuginea of the corpus spongiosum penis**
- **Septum penis** (cut)

8. Study the erectile tissue within the corpus spongiosum penis. Observe that the corpus spongiosum penis surrounds the spongy urethra.
9. Study the erectile tissue within the corpus cavernosum penis (Fig. 5.09). Identify the **deep artery of the penis** near the center of the erectile tissue. Review the origin of the deep artery of the penis from the internal pudendal artery.

DEEP PERINEAL POUCH

The deep perineal pouch (space) will not be dissected. The deep perineal pouch lies superior (deep) to the perineal membrane (Fig. 5.11). The **contents of the deep perineal pouch in the male** are the **membranous urethra**, **external urethral sphincter muscle**, **bulbourethral glands**, **branches of the internal pudendal vessels**, and **branches of the pudendal nerve** (Fig. 5.12).

1. Use an illustration to study the following: **[G 247; N 366; C 299]**
   - **Membranous urethra** – extends from the perineal membrane to the prostate gland (Fig. 5.11). This is the shortest (approximately 1 cm), thinnest, narrowest, and least distensible part of the urethra.
   - **External urethral sphincter** (**sphincter urethrae**) **muscle** – a voluntary muscle that surrounds the membranous urethra (Fig. 5.12). When the external urethral sphincter muscle contracts, it compresses the membranous urethra and stops the flow of urine.
   - **Deep transverse perineal muscle** – has a lateral attachment to the ischial tuberosity and the ischiopubic ramus and a medial attachment to the perineal body (Fig. 5.12). Its fiber direction and function are identical to those of the superficial transverse perineal muscle, which is a content of the superficial perineal pouch.

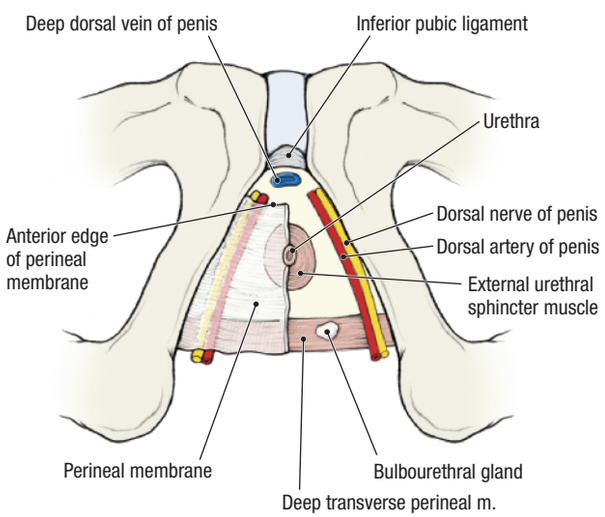

Figure 5.12. Contents of the deep perineal pouch in the male.

2. The **bulbourethral glands** are located in the deep perineal pouch. The duct of the bulbourethral gland passes through the perineal membrane and drains into the proximal portion of the spongy urethra.
3. The deep perineal pouch contains branches of the **pudendal nerve** and **internal pudendal artery** that supply the external urethral sphincter muscle, the deep transverse perineal muscle, and the penis (Fig. 5.12).
4. Collectively, the muscles within the deep perineal pouch plus the perineal membrane are known as the **urogenital diaphragm**. This older anatomical nomenclature is still in clinical use.

After you dissect . . .

Return the muscles of the urogenital triangle to their correct anatomical positions. Review the contents of the superficial perineal pouch. Use an illustration to review the course of the internal pudendal artery from its origin in the pelvis to the dorsum of the penis. Use an illustration to review the course and branches of the pudendal nerve. Study an illustration showing the course of the deep dorsal vein of the penis into the pelvis to join the prostatic venous plexus. Draw a cross-section of the penis showing the erectile bodies, superficial fascia, deep fascia, vessels, and nerves. Review an illustration that shows the entire male urethra and identify its parts by name.

MALE PELVIC CAVITY

Before you dissect . . .

The male pelvic cavity contains the urinary bladder anteriorly, male internal genitalia, and the rectum posteriorly (Fig. 5.13). The order of dissection will be as follows. The peritoneum will be studied in the male pelvic cavity. The pelvis will be sectioned in the midline and the cut surface of the sectioned pelvis will be studied. The ductus deferens will be traced from the anterior abdominal wall to the region between the urinary bladder and rectum. The seminal vesicles and prostate gland will be studied.

CLINICAL CORRELATION

Pelvic Peritoneum

As the urinary bladder fills, the peritoneal reflection is elevated above the level of the pubis and is raised from the anterior abdominal wall. A filled urinary bladder can be approached with a needle just superior to the pubis without entering the peritoneal cavity.

Dissection Instructions

PERITONEUM [G 197, 198; N 348; R 324; C 286]

Examine the **peritoneum** in the male pelvis (Fig. 5.13). The peritoneum passes from the anterior abdominal wall (1) superior to the pubis (2), then onto the superior surface of the urinary bladder (3). The peritoneum then passes inferiorly along the posterior surface of the urinary bladder (4) to the superior ends of the seminal vesicles (5). The peritoneum passes inferiorly between the urinary bladder and the rectum to form the **rectovesical pouch** (6). The peritoneum contacts the anterior surface of the second part of the rectum. At more superior levels, the peritoneum envelops the sides of the rectum (7). At the level of the third sacral vertebra, the peritoneum becomes the sigmoid mesocolon (8). Laterally, a **paravesical fossa** is apparent on each side of the urinary bladder. Further posteriorly, a **pararectal fossa** is apparent on each side of the rectum.

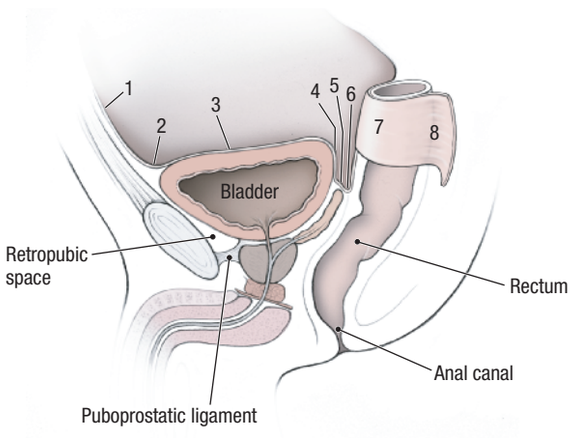

Figure 5.13. Peritoneum in the male pelvis. The numbered features of the peritoneum are explained in the text.

SECTION OF THE PELVIS

The pelvis will be divided in the midline. First, the pelvic viscera and the soft tissues of the perineum will be cut in the midline with a scalpel. The pubic symphysis and vertebral column (up to vertebral level L3) will be cut in the midline with a saw. Subsequently, the right side of the body will be transected at vertebral level L3. The left lower limb and left side of the pelvis will remain attached to the trunk.

Both halves of the pelvis will be used to dissect the pelvic viscera, pelvic vasculature, and nerves of the pelvis. One half of the pelvis will be used to demonstrate the muscles of the pelvic diaphragm.

1. Begin this dissection with a new scalpel blade.
2. In the pelvic cavity make a midline cut, beginning posterior to the pubic symphysis. Carry this midline cut through the superior surface of the urinary bladder. Open the bladder and sponge the interior, if necessary.
3. Identify the internal urethral orifice and insert a probe. Use the probe as a guide and continue the midline cut inferior to the urinary bladder. Divide the prostate gland.
4. Extend the midline cut in the posterior direction. Cut through the anterior and posterior walls of the rectum and the distal part of the sigmoid colon. Sponge them clean.
5. In the perineum, insert the scalpel blade inferior to the pubic symphysis with the cutting edge directed inferiorly. Cut between the halves of the bulb of the penis (sectioned earlier). Cut in the midline through the perineal membrane, perineal body, and anal canal (from pubic symphysis to coccyx).
6. Use a saw to make two cuts in the midline:
   - Pubic symphysis – cut through the pubic symphysis from anterior to posterior.
   - Sacrum – turn the cadaver to the prone position. Cut through the sacrum from posterior to anterior. Do not allow the saw to pass between the soft tissue structures that were cut with the scalpel. Spread the opening and extend the midline cut as far superiorly as the body of the third lumbar vertebra.
7. Return the cadaver to the supine position. To mobilize the right lower limb, use a scalpel to cut the right common iliac vein, right common iliac artery, and right testicular vessels. Cut the right ureter and the branches of the right lumbar plexus.
8. In the transverse plane, cut the psoas major muscle and the quadratus lumborum muscle at vertebral level L3. Use the saw to cut horizontally through the right half of the intervertebral disc between L3 and L4. Now, the right lower limb can be removed.
9. Clean the rectum and anal canal.

MALE INTERNAL GENITALIA [G 197; N 348; R 324; C 289]

1. Study the cut surface of the sectioned specimen. Use an illustration to guide you.
2. Identify the **perineal membrane**. It is located deep to the bulb of the penis and can be identified where the bulb ends (Fig. 5.11). Superior (deep) to the perineal membrane, the **external urethral sphincter muscle** surrounds the **membranous urethra**. The external urethral sphincter muscle may be difficult to see in the sectioned specimen.
3. On the sectioned pelvis, identify the three parts of the urethra: **prostatic urethra**, **membranous urethra**, and **spongy urethra** (Fig. 5.11).
4. Examine the **interior of the prostatic urethra**. The prostatic urethra is approximately 3 cm in length and is the part that passes through the prostate. On the posterior wall of the prostatic urethra identify (Fig. 5.14): **[G 209; N 368; R 326; C 289]**
   - **Urethral crest** – a longitudinal ridge
   - **Seminal colliculus** – an enlargement of the urethral crest
   - **Prostatic sinus** – the groove on either side of the seminal colliculus
   - **Prostatic utricle** – a small opening on the midline of the seminal colliculus
   - **Opening of the ejaculatory duct** – one on either side of the prostatic utricle
5. Find the **ductus deferens** where it enters the **deep inguinal ring** lateral to the inferior epigastric vessels. Use a probe to break through the peritoneum at the deep inguinal ring. Use blunt dissection to peel the

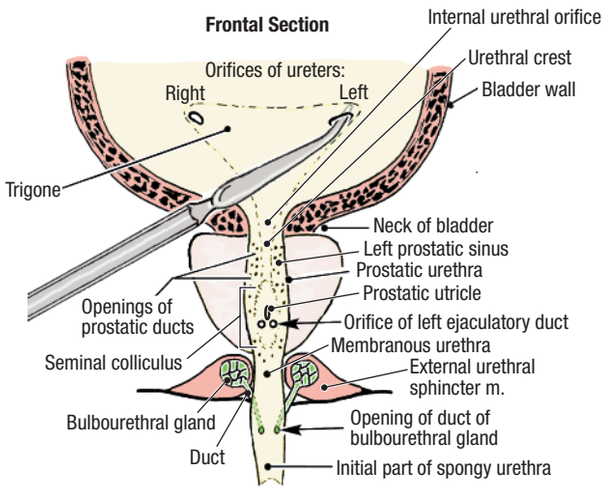

Figure 5.14. Urinary bladder and proximal portion of the male urethra seen in frontal section. The tip of the probe is located in the orifice of the left ureter.

peritoneum off the lateral wall of the pelvis. Strip the peritoneum from lateral to medial, stopping where it comes in contact with the rectum and urinary bladder. Detach the peritoneum and place it in the tissue container.

6. Use blunt dissection to trace the ductus deferens from the deep inguinal ring toward the midline. Observe that the ductus deferens passes superior and then medial to the branches of the internal iliac artery. Note that the ductus deferens crosses superior to the ureter. **[G 214; N 350; R 324; C 287]**
7. Trace the ductus deferens into the **rectovesical septum**, which is the fascia between the rectum and the urinary bladder. Observe that the ductus deferens is in contact with the fundus (posterior surface) of the urinary bladder.
8. Identify the **ampulla of the ductus deferens**, which is the enlarged portion just before its termination (Fig. 5.15). **[G 208; N 367; R 327; C 288]**
9. Identify the **seminal vesicle**. The seminal vesicle is located lateral to the ampulla of the ductus deferens in the rectovesical septum. Use blunt dissection to release the seminal vesicle from the connective tissue of the rectovesical septum.
10. Identify the point where the duct of the seminal vesicle joins the ductus deferens to form the **ejaculatory duct** (Fig. 5.15). The ejaculatory duct is delicate and easily torn where it enters the prostate. The ejaculatory duct empties into the prostatic urethra on the seminal colliculus.
11. Observe the **prostate**. The **apex** of the prostate is directed inferiorly and the **base** of the prostate is located superiorly against the neck of the urinary bladder. Use a textbook to study the **lobes of the prostate**.

After you dissect . . .

Review the position of the male pelvic viscera within the lesser pelvis. Review the peritoneum in the pelvic cavity. Trace the ductus deferens from the epididymis to the ejaculatory duct, recalling its relationships to vessels, nerves, the ureter, and the seminal vesicle.

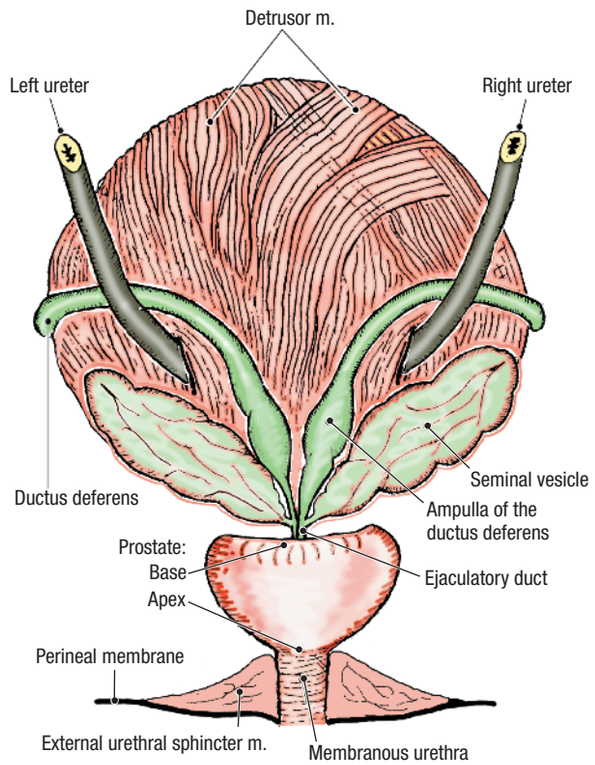

Figure 5.15. Posterior view of the urinary bladder and the male internal genitalia.

URINARY BLADDER, RECTUM, AND ANAL CANAL

Before you dissect . . .

The urinary bladder is a reservoir for urine. When empty, it is located within the pelvic cavity. When filled, it extends into the abdominal cavity. The urinary bladder is a retroperitoneal organ that is surrounded by **endopelvic fascia**. Between the pubic symphysis and the urinary bladder is a potential space called the **retropubic space (prevesical space)** (Fig. 5.13). The retropubic space is filled with fat and loose connective tissue that accommodates the expansion of the urinary bladder. The **puboprostatic ligament** is a condensation of fascia that ties the prostate to the pubis across the retropubic space (Fig. 5.13). The lower one-third of the rectum is surrounded by endopelvic fascia. The middle and upper thirds of the rectum are partially covered by peritoneum (Fig. 5.13).

The order of dissection will be as follows. The parts of the urinary bladder will be studied. The interior of the urinary bladder will be studied. The interior of the rectum and anal canal will be studied.

Dissection Instructions

URINARY BLADDER [G 209; N 353; R 324; C 289]

1. Identify the **parts of the urinary bladder** (Fig. 5.16):
   - **Apex** – the pointed part directed toward the anterior abdominal wall. The apex of the urinary blad-

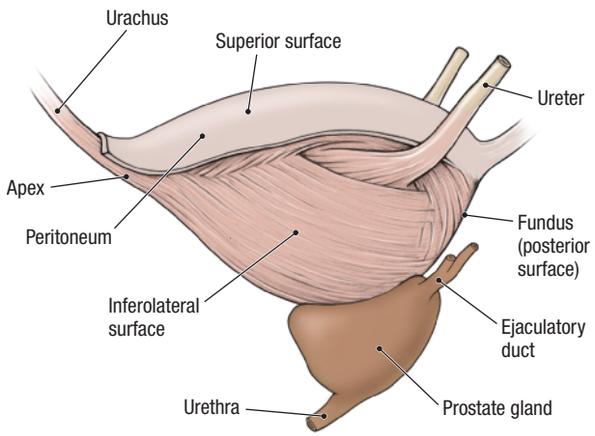

Figure 5.16. Parts of the urinary bladder in the male.

der can be identified by the attachment of the urachus.
- **Body** – between the apex and fundus
- **Fundus** – the posterior wall, also called the **base of the urinary bladder**. In the male the fundus is related to the ductus deferens, seminal vesicles, and rectum.
- **Neck** – where the urethra exits the urinary bladder. In the neck of the urinary bladder, the wall thickens to form the involuntary **internal urethral sphincter muscle**.

2. Identify the four **surfaces of the urinary bladder** (Fig. 5.16):
   - **Superior** – covered by peritoneum
   - **Posterior** – covered by the endopelvic fascia of the rectovesical septum
   - **Inferolateral (2)** – covered by endopelvic fascia
3. Examine the **wall of the urinary bladder** and note its thickness. The wall of the urinary bladder consists of bundles of smooth muscle called the **detrusor muscle** (L. *detrudere*, to thrust out).
4. Identify the **trigone** on the inner surface of the fundus (Fig. 5.14). The angles of the trigone are the **internal urethral orifice** and the two **orifices of the ureters**. The internal urethral orifice is located at the most inferior point in the urinary bladder. **[G 209; N 353; R 326; C 288]**
5. Observe that the mucous membrane over the trigone is smooth. The mucous membrane lining the other parts of the urinary bladder lies in folds when the bladder is empty but will accommodate expansion.
6. Insert the tip of a probe into the orifice of the ureter and observe that the ureter passes through the muscular wall of the urinary bladder in an oblique fashion. When the urinary bladder is full (distended), the pressure of the accumulated urine flattens the part of the ureter that is within the wall of the bladder and prevents reflux of urine.

CLINICAL CORRELATION

Kidney Stones

Kidney stones pass through the ureter to the urinary bladder and may become lodged in the ureter. The point where the ureter passes through the wall of the urinary bladder is a relatively narrow passage. If a kidney stone becomes lodged, severe colicky pain results. The pain stops suddenly once the stone passes into the bladder.

7. Find the ureter where it crosses the external iliac artery or the bifurcation of the common iliac artery. Use blunt dissection to follow the ureter to the fundus of the urinary bladder.

RECTUM AND ANAL CANAL [G 197, 199; N 348, 374; R 325; C 289, 292]

1. The rectum begins at the level of the third sacral vertebra. Observe the sectioned pelvis and note that the rectum follows the curvature of the sacrum.
2. Identify the **ampulla of the rectum** (Fig. 5.17). At the ampulla, the rectum turns approximately 80 degrees posteriorly (**anorectal flexure**) and is continuous with the anal canal. Observe that the prostate and seminal vesicles are located close to the anterior wall of the rectum (Fig. 5.13).

CLINICAL CORRELATION

Rectal Examination

Digital rectal examination is part of the physical examination. The size and consistency of the prostate gland can be assessed by palpation through the anterior wall of the rectum.

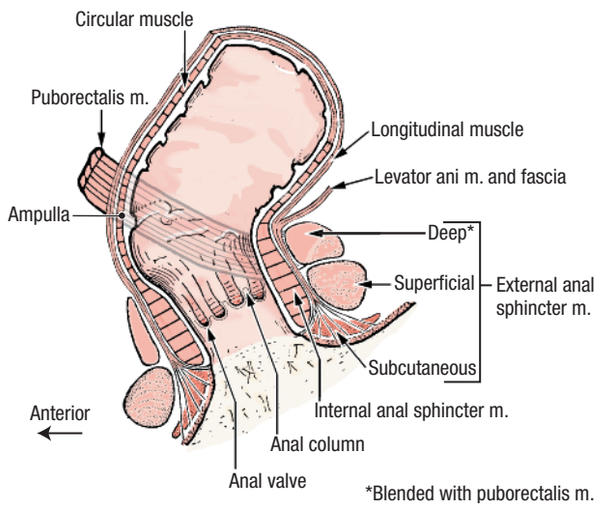

Figure 5.17. Rectum, anal canal, and anal sphincter muscles.

3. Examine the inner surface of the rectum. Note that the mucous membrane is smooth except for the presence of **transverse rectal folds**. There is usually one transverse rectal fold on the right side and two on the left side. The transverse rectal folds may be difficult to identify in some cadavers.
4. Observe that the **anal canal** is only 2.5 to 3.5 cm in length. The anal canal passes out of the pelvic cavity and enters the anal triangle of the perineum.
5. Examine the inner surface of the anal canal (Fig. 5.17). The mucosal features of the anal canal may be difficult to identify in older individuals. Attempt to identify the following:
   - **Anal columns** – five to 10 longitudinal ridges of mucosa in the proximal part of the anal canal. The anal columns contain branches of the **superior rectal artery** and **vein**.
   - **Anal valves** – semilunar folds of mucosa that unite the distal ends of the anal columns. Between the anal valve and the wall of the anal canal is a small pocket called an **anal sinus**.
   - **Pectinate line** – the irregular line formed by all of the anal valves.

CLINICAL CORRELATION

Hemorrhoids

In the anal columns, the superior rectal veins of the hepatic portal system anastomose with middle and inferior rectal veins of the inferior vena caval system. An abnormal increase in blood pressure in the hepatic portal system causes engorgement of the veins contained in the anal columns, resulting in **internal hemorrhoids**. Internal hemorrhoids are covered by mucous membrane and are relatively insensitive to painful stimuli because the mucous membrane is innervated by autonomic nerves.

External hemorrhoids are enlargements of the tributaries of the inferior rectal veins. External hemorrhoids are covered by skin and are very sensitive to painful stimuli because they are innervated by somatic nerves (inferior rectal nerves).

6. The anal sphincter muscles surround the anal canal. Identify the **external anal sphincter muscle** and the **internal anal sphincter muscle** in the sectioned specimen (Fig. 5.17). The longitudinal muscle of the anal canal separates the two sphincter muscles. If you have difficulty identifying them, use a new scalpel blade to cut another section through the wall of the anal canal to improve the clarity of the dissection.

After you dissect . . .

Use the dissected specimen to review the features of the urinary bladder, rectum, and anal canal. Review the relationships of the seminal vesicles, ampulla of the ductus deferens, and ureters to the rectum and fundus of the urinary bladder. Review the kidney, the abdominal course of the ureter, the pelvic course of the ureter, and the function of the urinary bladder as a storage organ. Review the parts of the male urethra. Review all parts of the large intestine and recall its function in absorption of water, compaction, and elimination of fecal material. Recall that the external anal sphincter muscle is composed of skeletal muscle and is under voluntary control, whereas the internal anal sphincter muscle is composed of smooth muscle and is involuntary.

INTERNAL ILIAC ARTERY AND SACRAL PLEXUS

Before you dissect . . .

Anterior to the sacroiliac articulation, the **common iliac artery** divides to form the **external** and **internal iliac arteries** (Fig. 5.18). The external iliac artery distributes to the lower limb and the internal iliac artery to the pelvis. The internal iliac artery commonly divides into an anterior division and a posterior division. Branches arising from the anterior division are mainly visceral (branches to the urinary bladder, internal genitalia, external genitalia, rectum, and gluteal region). Branches arising from the posterior division are parietal (branches to the pelvic walls and gluteal region). The branching pattern of the internal iliac artery is variable, so it is important to identify the arteries by their distribution. The internal iliac vein is typically plexiform. To clear the dissection field, remove all tributaries to the internal iliac vein.

The order of dissection will be as follows. The branches of the anterior division of the internal iliac artery will be identified. The branches of the posterior division of the internal iliac artery will be identified. The nerves of the sacral plexus will be dissected. Subsequently, the pelvic portion of the sympathetic trunk will be dissected.

Dissection Instructions

BLOOD VESSELS [G 212; N 382, 383; R 333; C 266]

1. Identify the **common iliac artery** and follow it to its bifurcation.
2. Identify the **internal iliac artery**. Use blunt dissection to follow the internal iliac artery into the lesser pelvis.

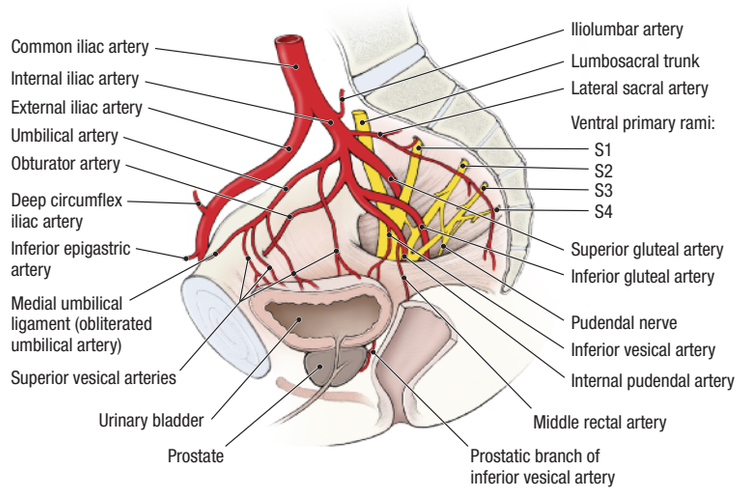

Figure 5.18. Branches of the internal iliac artery in the male.

3. Identify the branches of the anterior division of the internal iliac artery (Fig. 5.18):
   - **Umbilical artery** – in the medial umbilical fold, find the **umbilical ligament** (the obliterated portion of the umbilical artery) and use blunt dissection to trace it posteriorly to the umbilical artery. Note that several **superior vesical arteries** arise from the inferior surface of the umbilical artery and descend to the superolateral part of the urinary bladder.
   - **Obturator artery** – passes through the obturator canal. Find the obturator artery where it enters the obturator canal in the lateral wall of the lesser pelvis, and follow the artery posteriorly to its origin. In approximately 20% of cases, the obturator artery arises from the inferior epigastric artery (**aberrant obturator artery**). An aberrant obturator artery crosses the pelvic brim and is at risk for injury during surgical repair of a femoral hernia.
   - **Inferior vesical artery** – courses toward the fundus of the urinary bladder to supply the bladder, seminal vesicle, and prostate. The inferior vesical artery is a named branch only in the male; in the female, it is an unnamed branch of the vaginal artery.
   - **Middle rectal artery** – courses medially toward the rectum. It often arises in common with the inferior vesical artery, making positive identification difficult. Identify the middle rectal artery by tracing it to the rectum. The middle rectal artery, like the inferior vesical artery, sends branches to the seminal vesicle and prostate.
   - **Internal pudendal artery** – exits the pelvic cavity by passing through the greater sciatic foramen inferior to the piriformis muscle. The internal pudendal artery often arises from a common trunk with the inferior gluteal artery.
   - **Inferior gluteal artery** – passes out of the pelvic cavity between ventral primary rami S2 and S3. The inferior gluteal artery exits the pelvis by passing through the greater sciatic foramen inferior to the piriformis muscle. The inferior gluteal artery may share a common trunk with the internal pudendal artery.
4. Identify the branches of the posterior division of the internal iliac artery (Fig. 5.18):
   - **Iliolumbar artery** – passes posteriorly between the lumbosacral trunk and the obturator nerve. It may arise from a common trunk with the lateral sacral artery.
   - **Lateral sacral artery** – gives rise to a superior branch and an inferior branch. Observe the inferior branch that passes anterior to the sacral ventral primary rami.
   - **Superior gluteal artery** – exits the pelvic cavity by passing between the lumbosacral trunk and the ventral primary ramus of S1.
5. Use an illustration to study the **prostatic venous plexus**, **vesical venous plexus**, and **rectal venous plexus**. All of these plexuses drain into the internal iliac vein.
6. On the dissected specimen, observe the **deep dorsal vein of the penis** just inferior to the pubic symphysis. Verify that the deep dorsal vein of the penis empties into the prostatic venous plexus.
7. Identify the **internal iliac vein**. Follow the internal iliac vein to its junction with the **external iliac vein**. At this junction, the **common iliac vein** is formed.

NERVES [G 220, 221; N 390, 481; R 456; C 296]

The somatic plexuses of the pelvic cavity are the **sacral plexus** and **coccygeal plexus**. They are located between the pelvic viscera and the lateral pelvic wall. These somatic nerve plexuses are formed by contributions from ventral primary rami of spinal nerves L4 to S4. The primary visceral nerve plexus of the pelvic cavity is the **inferior hypogastric plexus**. It is formed by contributions from the hypogastric nerves, sympathetic trunks, and pelvic splanchnic nerves.

1. Use your fingers to dissect the rectum from the anterior surface of the sacrum and coccyx.
2. Retract the rectum medially. Identify the **sacral plexus** of nerves. The sacral plexus is closely related to the anterior surface of the piriformis muscle. Verify the following (Fig. 5.19):
   - The **lumbosacral trunk** (ventral primary rami of L4, L5) joins the sacral plexus.
   - The ventral primary rami of S2 and S3 emerge between the proximal attachments of the piriformis muscle.
   - The **sciatic nerve** is formed by the ventral primary rami of spinal nerves L4 through S3. The sciatic nerve exits the pelvis by passing through the greater sciatic foramen, usually inferior to the piriformis muscle.
   - The **superior gluteal artery** usually passes between the **lumbosacral trunk** and the **ventral primary ramus of spinal nerve S1**, and exits the pelvis by passing superior to the piriformis muscle.

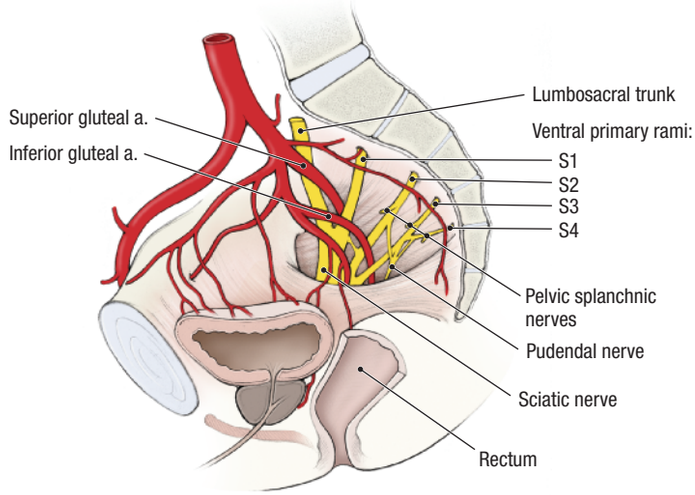

Figure 5.19. Sacral plexus of nerves in the male.

- The **inferior gluteal artery** usually passes between the **ventral primary rami of spinal nerves S2 and S3**. The inferior gluteal artery exits the pelvis by passing inferior to the piriformis muscle.
- The **pudendal nerve** receives a contribution from the ventral primary rami of spinal nerves S2, S3, and S4. The pudendal nerve exits the pelvis by passing inferior to the piriformis muscle.

3. Identify the **pelvic splanchnic nerves (nervi erigentes)**. Pelvic splanchnic nerves are branches of the ventral primary rami of spinal nerves S2 to S4 (Fig. 5.19). Pelvic splanchnic nerves carry preganglionic parasympathetic axons for the innervation of pelvic organs and the distal gastrointestinal tract (from the left colic flexure through the anal canal). **[G 220; N 390; R 334; C 296]**
4. The **sacral portion of the sympathetic trunk** is located on the anterior surface of the sacrum, medial to the ventral sacral foramina. Identify the following:

- **Sympathetic trunk** – continues from the abdominal region into the pelvis. The sympathetic trunks of the two sides join in the midline near the level of the coccyx to form the **ganglion impar**.
- **Gray rami communicantes** – connect the sympathetic ganglia to the sacral ventral primary rami. Each gray ramus communicans carries postganglionic sympathetic fibers to a ventral primary ramus for distribution to the lower extremity and perineum.
- **Sacral splanchnic nerves** – arise from two or three of the sacral sympathetic ganglia and pass directly to the **inferior hypogastric plexus**. Sacral splanchnic nerves carry sympathetic fibers that distribute to the pelvic viscera.

CLINICAL CORRELATION

Pelvic Nerve Plexuses

The pelvic splanchnic nerves (parasympathetic outflow of S2, S3, S4) are closely related to the lateral aspects of the rectum. The inferior hypogastric plexus is located in the connective tissue lateral to the prostate. These autonomic nerve plexuses can be injured during surgery, causing loss of bladder control and erectile dysfunction.

After you dissect . . .

Review the abdominal aorta and its terminal branches. Use the dissected specimen to review the branches of the internal iliac artery. Review the region supplied by each branch. Review the formation of the sacral plexus and the branches that were dissected in the pelvis. Use the dissected specimen and an illustration to review the course of the pudendal nerve from the pelvis to the urogenital triangle.

PELVIC DIAPHRAGM

Before you dissect . . .

The **pelvic diaphragm** is the muscular floor of the pelvic cavity. The pelvic diaphragm is formed by the levator ani muscle and coccygeus muscle plus the fasciae covering their superior and inferior surfaces (Fig. 5.20A,B). The pelvic diaphragm extends from the pubic symphysis to the coccyx. Laterally, the pelvic diaphragm is attached to the fascia covering the obturator internus muscle. The urethra and anal canal pass through a midline opening in the pelvic diaphragm called the **urogenital hiatus**.

Dissection Instructions

1. Perform the dissection of the pelvic diaphragm on one side of the cadaver. Save the side with the best dissection of arteries and nerves for review. **[G 193, 194; N 343-345; C 299]**
2. Retract the rectum, urinary bladder, prostate, and seminal vesicles medially.

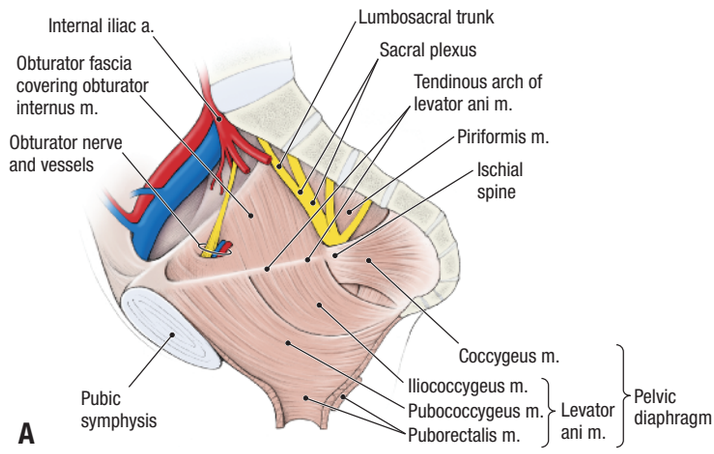

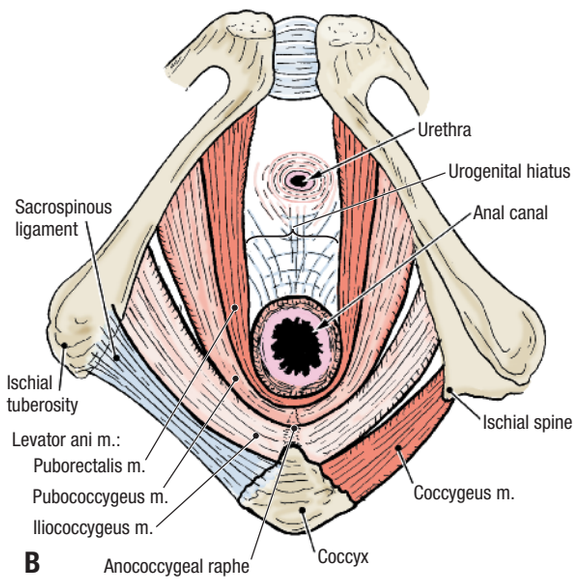

Figure 5.20. Pelvic diaphragm in the male. **A.** Left lateral view. **B.** Inferior view.

3. Use blunt dissection to remove any remaining fat and connective tissue from the superior surface of the pelvic diaphragm.
4. Find the **tendinous arch of the levator ani muscle** (Fig. 5.20A). Palpate the medial surface of the ischial spine. Locate the obturator canal. The tendinous arch lies just inferior to a line connecting these two structures. Note that the tendinous arch is the superior edge of the pelvic diaphragm.
5. Identify the three muscles that form the **levator ani muscle**. The muscles are identified by their proximal attachments. Learn, but do not dissect, their distal attachments. Identify the following:
   - **Puborectalis muscle** – its proximal attachment is the body of the pubis. Its distal attachment is the puborectalis muscle of the opposite side (midline raphe). The pubococcygeus muscle forms the lateral boundary of the urogenital hiatus. The two puborectalis muscles form a "puborectal sling," which causes the **anorectal flexure** at the ampulla of the rectum (Fig. 5.17). During defecation, the puborectalis muscles relax, the anorectal flexure straightens, and the elimination of fecal matter is facilitated.
   - **Pubococcygeus muscle** – its proximal attachment is the body of the pubis. Its distal attachment is the coccyx and the **anococcygeal raphe**.
   - **Iliococcygeus muscle** – its proximal attachment is the tendinous arch. Its distal attachment is the coccyx and the anococcygeal raphe.
6. The levator ani muscle supports the pelvic viscera and resists increases in intra-abdominal pressure.
7. Identify the **coccygeus muscle**. The coccygeus muscle completes the pelvic diaphragm posteriorly. The proximal attachment of the coccygeus muscle is the ischial spine and its distal attachment is the lateral border of the coccyx and the lowest part of the sacrum.
8. Place one hand in the ischioanal fossa and the other on the superior surface of the pelvic diaphragm. Palpate the thinness of the pelvic diaphragm.
9. Observe that the **obturator internus muscle** forms the lateral wall of the ischioanal fossa. The proximal attachment of the obturator internus muscle is the margin of the obturator foramen and inner surface of the obturator membrane. The distal attachment of the obturator internus muscle will be studied when the gluteal region is dissected. Superior to the tendinous arch of the levator ani muscle, the obturator internus muscle forms the lateral wall of the pelvic cavity. Inferior to the tendinous arch, the obturator internus muscle forms the lateral wall of the perineum.
10. Use your textbook to learn the general pattern of lymphatic drainage of the pelvis, and the location of each of the following groups of lymph nodes: **[G 203, 218, 219; N 388]**
    - **Internal iliac nodes**
    - **External iliac nodes**
    - **Common iliac nodes**
    - **Sacral nodes**
    - **Lumbar nodes**

After you dissect . . .

Use the dissected specimen to review the proximal attachment and action of each muscle of the pelvic diaphragm. Review the relationship of the branches of the internal iliac artery to the pelvic diaphragm. Review the relationship of the sacral plexus to the pelvic diaphragm. Use an illustration to review the role of the pelvic diaphragm in dividing the pelvic cavity from the perineum. Review the function of the pelvic diaphragm and perineal body in supporting the pelvic and abdominal viscera. Use an illustration to review the lymphatic drainage from the pelvis and perineum. Realize that structures in the perineum (including the scrotum and the lower part of the anal canal) drain into superficial inguinal lymph nodes. The lymphatic drainage of the testis follows the testicular vessels to the lumbar chain of nodes, bypassing the perineal and pelvic drainage systems. Review the formation of the thoracic duct to complete your understanding of the lymph drainage from this region.

FEMALE UROGENITAL TRIANGLE

Before you dissect . . .

The order of dissection of the female urogenital triangle will be as follows. The external genitalia will be examined. The skin will be removed from the labia majora. The superficial perineal fascia will be removed and the contents of the superficial perineal pouch will be identified. The contents of the deep perineal pouch will be described, but not dissected.

Dissection Instructions

EXTERNAL GENITALIA **[G 256; N 359; R 350; C 274]**

1. Place the cadaver in the supine position. Stretch the thighs widely apart and brace them. Usually, only one student can work on the urogenital triangle at a time. The dissector should be positioned between the thighs.
2. Examine the **vulva** (female external genitalia) (Fig. 5.21). Identify the following structures:
   - **Mons pubis**
   - **Anterior labial commissure**
   - **Labium majus**
   - **Clitoris and prepuce of clitoris**
   - **Labium minus**
   - **Vestibule of the vagina** – the area between the labia minora
   - **External urethral orifice**
   - **Vaginal orifice**
   - **Openings of the paraurethral ducts** – on each side of the external urethral orifice
   - **Posterior labial commissure**

SKIN REMOVAL

1. Refer to Figure 5.22.
2. Make a skin incision in the midline from the anterior margin of the anus to the posterior labial commissure.
3. Make a skin incision that follows the medial surface of the labium majus on each side. Each incision should

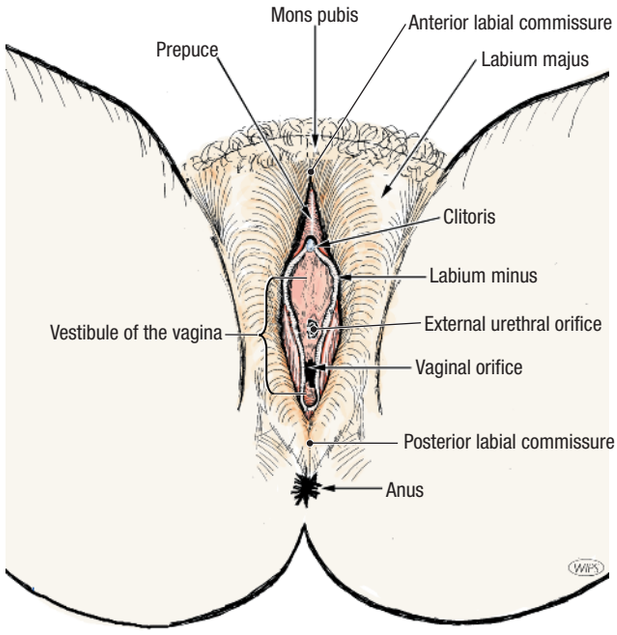

Figure 5.21. Female external genitalia.

begin at the posterior labial commissure, pass lateral to the labium minus, and end at the anterior labial commissure. Extend the incision in the midline to the mons pubis.

4. Make a transverse incision across the mons pubis that extends from the right thigh to the left thigh.
5. Remove the skin from the labium majus (lateral to the incisions). Detach each skin flap along the medial surface of the thigh and place the skin in the tissue container (Fig. 5.22, dashed lines).
6. If the cadaver has a large amount of fat in the superficial fascia of the medial thighs, remove a portion of the superficial fascia that corresponds to the skin that was removed.

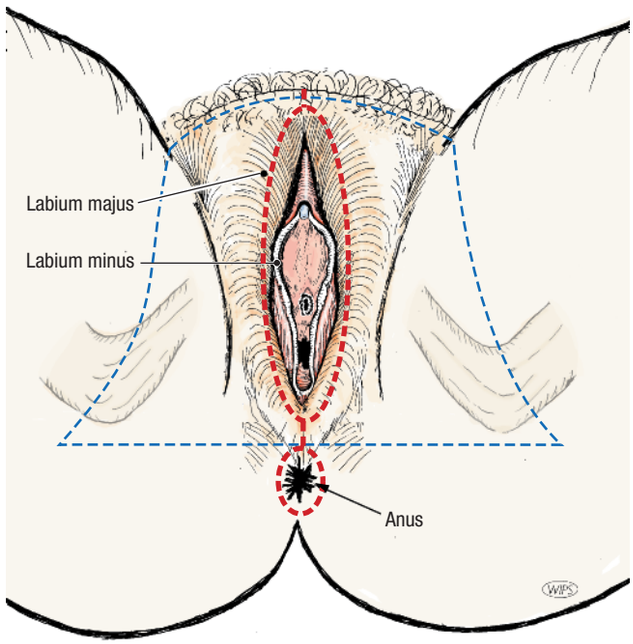

Figure 5.22. Skin incisions.

7. Note that the posterior labial nerve and vessels enter the urogenital triangle by passing lateral to the external anal sphincter muscle. The posterior labial nerve and vessels supply the posterior part of the labium majus.

SUPERFICIAL PERINEAL POUCH AND CLITORIS [G 256-258; N 360, 361; R 352, 353; C 276, 277]

The superficial perineal fascia has a superficial fatty layer and a deep membranous layer. In the female, the superficial fatty layer provides the shape of the labium majus and is continuous with the fat of the lower abdominal wall, ischioanal fossa, and thigh. The **membranous layer of the superficial perineal fascia (Colles' fascia)** is attached to the ischiopubic ramus as far posteriorly as the ischial tuberosity, and to the posterior edge of the **perineal membrane** (Fig. 5.23). The membranous layer of the superficial perineal fascia forms the superficial boundary the **superficial perineal pouch (space)**.

1. The **contents of the superficial perineal pouch in the female** include **three muscles** (**ischiocavernosus, bulbospongiosus**, and **superficial transverse perineal**), the **crus of the clitoris**, the **bulb of the vestibule**, and the **greater vestibular gland** (Fig. 5.24). These structures are paired. The superficial perineal pouch also contains the blood vessels and nerves for these structures.
2. It is not necessary to identify the membranous layer of the superficial perineal fascia to complete the dissection. Use a probe to dissect through the superficial perineal fascia approximately 2 cm lateral to the labium minus. Remove the fat that forms the labium majus and place it in the tissue container.
3. Use blunt dissection to find the **superficial transverse perineal muscle** at the posterior border of the urogenital triangle (Fig. 5.24A). The superficial transverse perineal muscle may be delicate and difficult to find; limit the time spent looking for it. The lateral attachment of the superficial transverse perineal muscle

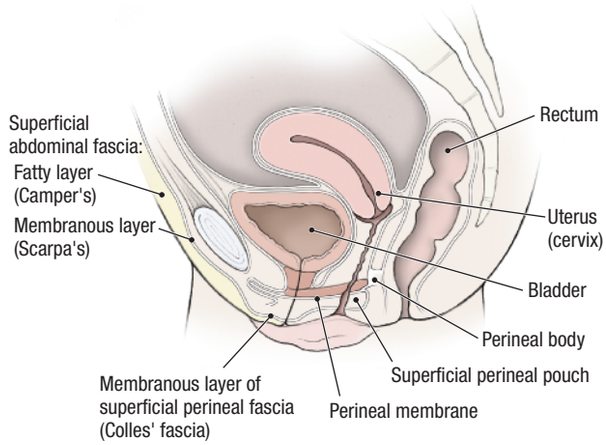

Figure 5.23. Perineal fasciae in the female. The membranous layer of superficial perineal fascia (Colles' fascia) is continuous with the membranous layer of superficial fascia of the lower abdominal wall (Scarpa's fascia). The membranous layer of the superficial perineal fascia is attached along the posterior border of the perineal membrane.

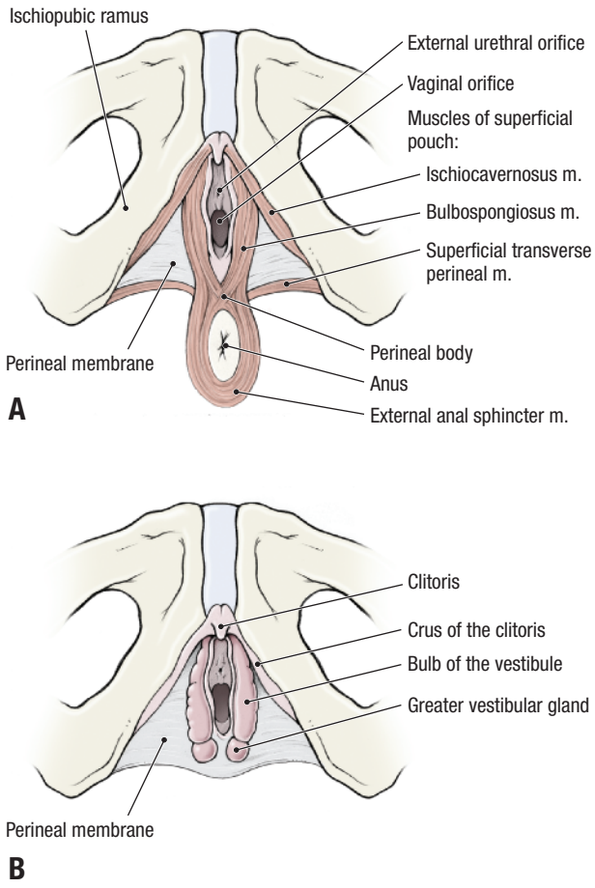

Figure 5.24. Contents of the superficial perineal pouch in the female. **A.** Muscles. **B.** Erectile bodies.

is the ischial tuberosity and the ischiopubic ramus. The medial attachment of the superficial transverse perineal muscle is the **perineal body**. The perineal body is a fibromuscular mass located between the anal canal and the posterior edge of the perineal membrane that serves as an attachment for several muscles. The superficial transverse perineal muscle helps to support the perineal body.

4. Use blunt dissection to clean the surface of the **ischiocavernosus muscle.** The ischiocavernosus muscle covers the superficial surface of the **crus of the clitoris**. The proximal attachments of the ischiocavernosus muscle are the ischial tuberosity and the ischiopubic ramus. The distal attachment of the ischiocavernosus muscle is the crus of the clitoris. The ischiocavernosus muscle forces blood from the crus of the clitoris into the corpus cavernosum clitoris.
5. Identify the **bulbospongiosus muscle**, which is lateral to the labium minus. The bulbospongiosus muscle covers the superficial surface of the **bulb of the vestibule**. The posterior attachment of the bulbospongiosus muscle is the perineal body. The anterior attachment of the bulbospongiosus muscle is the corpus cavernosum clitoris. The bulbospongiosus muscle in the female does not join the bulbospongiosus muscle of the opposite side across the midline as it does in the male.
6. Note that the **greater vestibular gland** is found in the superficial perineal pouch immediately posterior to the bulb of the vestibule (Fig. 5.24B).
7. Use a probe to dissect between the three muscles of the superficial perineal pouch until a small triangular opening is created. The membrane that becomes visible through this opening is the **perineal membrane** (Fig. 5.24A). The perineal membrane is the deep boundary of the superficial perineal pouch, and the erectile bodies are attached to it.
8. On the right side of the cadaver, use blunt dissection to remove the bulbospongiosus muscle and identify the **bulb of the vestibule** (Fig. 5.24B). The bulb of the vestibule is an elongated mass of erectile tissue that lies lateral to the vaginal orifice. Anteriorly, the bulbs of the two sides are joined at the **commissure of the bulbs** and the commissure is continuous with the **glans of the clitoris**.
9. On the right side of the cadaver, use blunt dissection to remove the ischiocavernosus muscle from the **crus of the clitoris** (Fig. 5.24B). The crus of the clitoris is continuous with the corpus cavernosum clitoris. The two corpora cavernosa form the **body of the clitoris**.
10. Use an illustration to study the erectile bodies of the clitoris. Note that the glans of the clitoris caps the two corpora cavernosa.

DEEP PERINEAL POUCH

The deep perineal pouch (space) will not be dissected. The deep perineal pouch lies superior (deep) to the perineal membrane (Fig. 5.25). The **contents of the deep perineal pouch in the female** are the **urethra**, a portion of the **vagina**, **external urethral sphincter muscle**, **branches of the internal pudendal vessels**, and **branches of the pudendal nerve**.

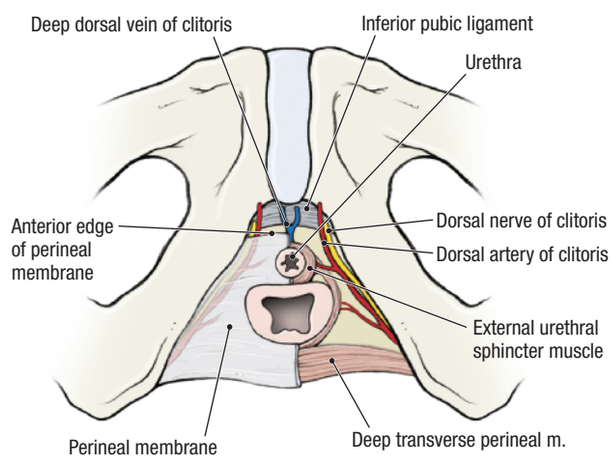

Figure 5.25. Contents of the deep perineal pouch in the female.

1. Use an illustration to study the following: [G 242; N 361; C 278]
   - **Urethra** – extends from the internal urethral orifice in the urinary bladder to the external urethral orifice in the vestibule of the vagina (approximately 4 cm).
   - **External urethral sphincter (sphincter urethrae) muscle** – a voluntary muscle that surrounds the urethra. When the external urethral sphincter muscle contracts, it compresses the urethra and stops the flow of urine.
   - **Deep transverse perineal muscle** – has a lateral attachment to the ischial tuberosity and the ischiopubic ramus and a medial attachment to the perineal body. Its fiber direction and function are identical to those of the superficial transverse perineal muscle, which is a content of the superficial perineal pouch.
2. Other contents of the deep perineal pouch include **branches of the internal pudendal artery** and **branches of the pudendal nerve** that supply the external urethral sphincter muscle, the deep transverse perineal muscle, and the clitoris (Fig. 5.25).
3. Collectively, the muscles within the deep perineal pouch plus the perineal membrane are known as the **urogenital diaphragm**. This older anatomical nomenclature is still in clinical use.

CLINICAL CORRELATION

Obstetrical Considerations

As the head of the baby pushes through the vagina during childbirth, the anus and the levator ani muscle are forced posteriorly toward the sacrum and coccyx. The urethra is forced anteriorly toward the pubic symphysis. Perineal lacerations during childbirth are common, and it may be necessary to surgically widen the vaginal orifice (episiotomy). If the perineal body is lacerated, it must be repaired to prevent weakness of the pelvic floor, which could result in prolapse of the urinary bladder, uterus, or rectum.

To alleviate the pain of childbirth, a **pudendal nerve block** is performed by injecting a local anesthetic around the pudendal nerve where it passes near the ischial spine. To perform the injection, the ischial spine is palpated through the vagina, and the needle is inserted through the skin and directed toward ischial spine.

After you dissect . . .

Replace the muscles of the urogenital triangle in their correct anatomical positions. Review the contents of the superficial perineal pouch. Use an illustration to review the course of the internal pudendal artery from its origin in the pelvis. Use an illustration to review the course and branches of the pudendal nerve. Review an illustration showing the urethra and note its course from the urinary bladder to the perineum.

FEMALE PELVIC CAVITY

Before you dissect . . .

The female pelvic cavity contains the urinary bladder anteriorly, the female internal genitalia, and the rectum posteriorly (Fig. 5.26). The term **adnexa** (L. *adnexa*, adjacent parts) refers to the ovaries, uterine tubes, and ligaments of the uterus. Removal of the uterus (hysterectomy), with or without the ovaries, is a common surgical procedure. If the uterus has been surgically removed from your cadaver, examine it in other cadavers.

The order of dissection will be as follows. The peritoneum will be studied in the female pelvic cavity. The pelvis will be sectioned in the midline and the cut surface of the sectioned pelvis will be studied. The uterus and vagina will be studied. The uterine tube will be traced from the uterus to the ovary. The ovary will be studied.

Dissection Instructions

PERITONEUM [G 224, 225; N 347; R 345; C 258]

1. Examine the **peritoneum** in the female pelvis (Fig. 5.26). The peritoneum passes from the anterior abdominal wall (1) superior to the pubis (2), then onto the superior surface of the urinary bladder (3). The peritoneum then passes from the superior surface of the urinary bladder to the uterus where it forms the **vesicouterine pouch** (4). The peritoneum covers the fundus and body of the uterus (5). It extends over the posterior wall of the vagina near the posterior part of the vaginal fornix. Between the uterus and the rectum, the peritoneum forms the **rectouterine pouch** (6). From the rectouterine pouch, the peritoneum passes onto the anterior surface and sides of the rectum (7). At the level of the third sacral vertebra, the peritoneum forms the sigmoid mesocolon (8). Laterally, a **paravesical fossa** is apparent on each side of the urinary bladder. Further posteriorly, a **pararectal fossa** is apparent on each side of the rectum.

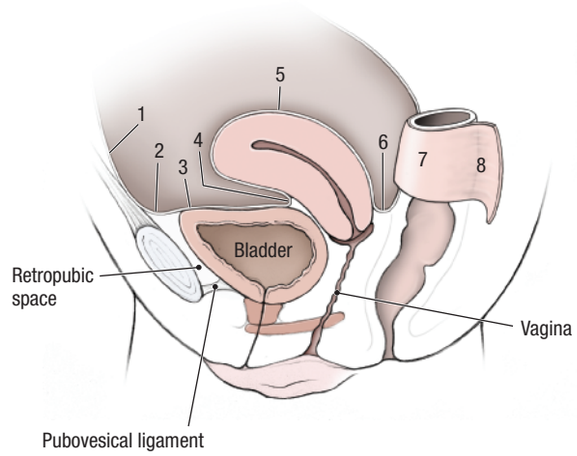

Figure 5.26. Peritoneum in the female pelvis. The numbered features of the peritoneum are explained in the text.

CLINICAL CORRELATION

Pelvic Peritoneum

As the urinary bladder fills, the peritoneal reflection from the anterior abdominal wall to the bladder is elevated above the level of the pubis. A filled urinary bladder can be approached with a needle superior to the pubis without entering the peritoneal cavity.

2. Identify the **broad ligament of the uterus**. The broad ligament of the uterus is formed by two layers of peritoneum that extend from the lateral side of the uterus to the lateral pelvic wall. The **uterine tube** is contained within the superior margin of the broad ligament. The broad ligament has three parts (Fig. 5.27): **[G 229; N 355; R 347; C 262]**
   - **Mesosalpinx** (Gr. *salpinx*, tube) – supports the uterine tube
   - **Mesovarium** – attaches the ovary to the posterior aspect of the broad ligament
   - **Mesometrium** – the part of the broad ligament that is below the attachment of the mesovarium
3. The tissue enclosed between the two layers of the broad ligament is called **parametrium** (Gr. *para*, beside; *metra*, womb, uterus) (Fig. 5.27).
4. Identify the **round ligament of the uterus**, which is visible through the anterior layer of the broad ligament. Observe that the round ligament of the uterus passes over the pelvic brim and exits the abdominal cavity by passing through the deep inguinal ring, lateral to the inferior epigastric vessels. The round ligament of the uterus passes through the inguinal canal and ends in the labium majus.
5. Identify the **ligament of the ovary**, which is a fibrous cord within the broad ligament that connects the ovary to the uterus.
6. Identify the **suspensory ligament of the ovary**, which is a peritoneal fold that covers the ovarian vessels. The suspensory ligament of the ovary extends into the greater pelvis from the superior aspect of the ovary.
7. The **endopelvic fascia** contains condensations of connective tissue that passively support the uterus. Study an illustration and note the following (Fig. 5.28):
   - **Uterosacral (sacrogenital) ligament**—extends from the cervix to the sacrum. The uterosacral ligament underlies the **uterosacral fold**.
   - **Transverse cervical ligament (cardinal ligament)**—extends from the cervix to the lateral wall of the pelvis
   - **Pubocervical (pubovesical) ligament**—extends from the pubis to the cervix

SECTION OF THE PELVIS

The pelvis will be divided in the midline. First, the pelvic viscera and the soft tissues of the perineum will be cut in the midline with a scalpel. The pubic symphysis and vertebral column (up to vertebral level L3) will be cut in the midline with a saw. Subsequently, the right side of the body will be transected at vertebral level L3. The left

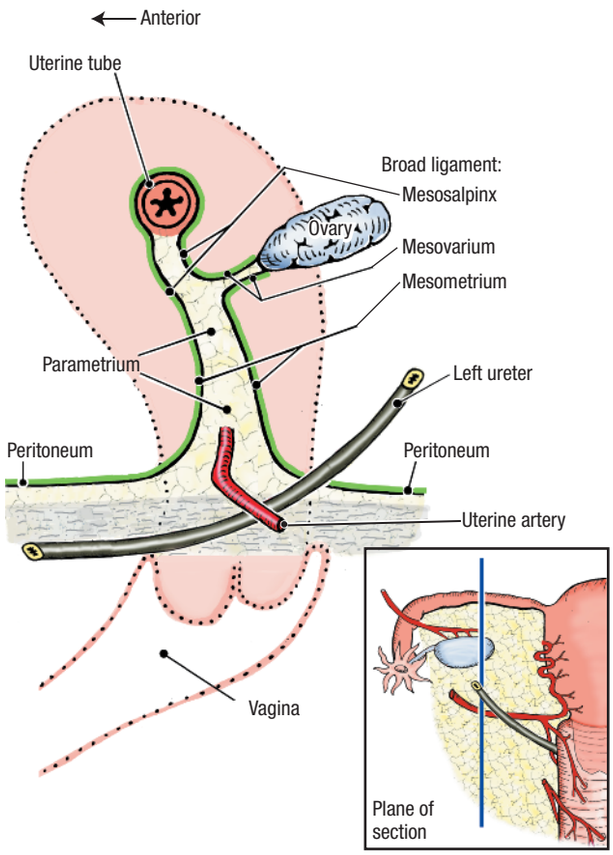

Figure 5.27. Parts of the broad ligament of the uterus.

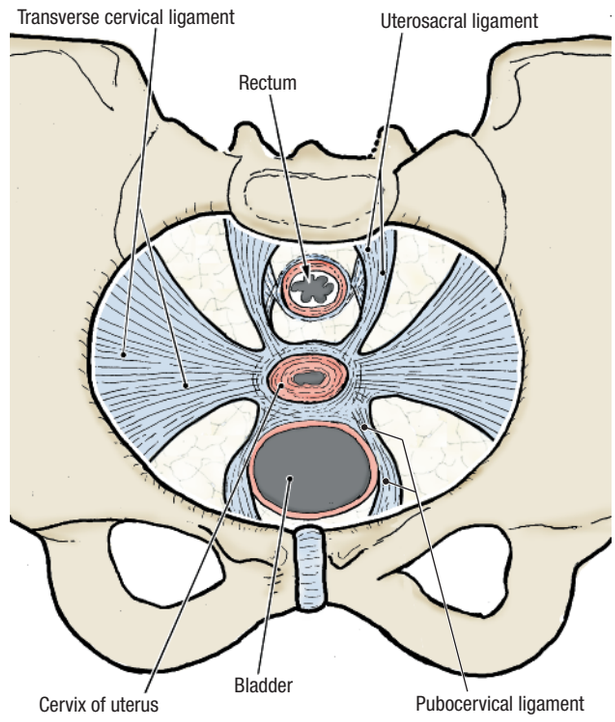

Figure 5.28. Ligaments of the endopelvic fascia that support the uterus.

lower limb and left side of the pelvis will remain attached to the trunk.

Both halves of the pelvis will be used to dissect the pelvic viscera, pelvic vasculature, and nerves of the pelvis. One half of the pelvis will be used to demonstrate the muscles of the pelvic diaphragm.

1. Begin this dissection with a new scalpel blade.
2. Use your hand to position the uterus in the midline. Use a scalpel to divide the uterus in its median plane. Extend the cut through the cervix and into the fornix of the vagina.
3. Beginning posterior to the pubic symphysis, make a midline cut through the superior surface of the urinary bladder. Open the bladder and sponge the interior, if necessary.
4. Identify the internal urethral orifice and insert a probe. Use the probe as a guide and cut through the inferior part of the bladder.
5. Extend the midline cut in the posterior direction. Cut through the anterior and posterior walls of the rectum and the distal part of sigmoid colon. Sponge them clean.
6. In the perineum, insert the tip of a probe into the external urethral orifice. Use the probe as a guide to make a midline cut through the clitoris, dividing it into right and left sides. Extend this cut posteriorly, dividing the urethra and vagina into right and left sides.
7. In the midline, cut through the perineal membrane, perineal body, and anal canal. Extend the cut to the tip of the coccyx.
8. Use a saw to make two cuts in the midline:
   - Pubic symphysis – cut through the pubic symphysis from anterior to posterior.
   - Sacrum – turn the cadaver to the prone position. Cut through the sacrum from posterior to anterior. Do not allow the saw to pass between the soft tissue structures that were cut with the scalpel. Spread the opening and extend the midline cut as far superiorly as the body of the third lumbar vertebra.
9. Return the cadaver to the supine position. To mobilize the right lower limb, use a scalpel to cut the right common iliac vein, right common iliac artery, and right ovarian vessels. Cut the right ureter and the branches of the right lumbar plexus.
10. In the transverse plane, cut the psoas major muscle and the quadratus lumborum muscle at vertebral level L3. Use the saw to cut horizontally through the right half of the intervertebral disc between L3 and L4. Now, the right lower limb can be removed.
11. Clean the rectum and anal canal.

FEMALE INTERNAL GENITALIA [G 224; N 347, 352; R 345; C 258]

1. Study the cut surface of the sectioned specimen. Use an illustration to guide you.
2. Trace the sectioned urethra anteroinferiorly from the urinary bladder to the **external urethral orifice**. Identify the **external urethral sphincter muscle** that surrounds the urethra. The external urethral sphincter muscle may be difficult to see.
3. In the sectioned specimen, observe the **vagina**. Identify the **vaginal fornix**. The vaginal fornix has four parts: **anterior**, **lateral (2)**, and **posterior** (Fig. 5.29). Observe that the anterior vaginal wall is shorter than the posterior vaginal wall.
4. Observe that the posterior wall of the vagina (near the posterior part of the vaginal fornix) is in contact with the peritoneum that lines the rectouterine pouch.
5. Study the **uterus** (Fig. 5.29). Observe that the uterus is tilted approximately 90 degrees anterior to the axis of the vagina (anteverted). The position of the uterus changes during pregnancy and as the urinary bladder fills. [G 227, 230; N 356; R 346, 347; C 262, 263]
6. Identify the following features of the uterus:
   - **Fundus** – the rounded part of the body that lies superior to the attachments of the uterine tubes
   - **Body** – the part of the uterus between the fundus and the cervix. The **vesical surface** of the body of the uterus faces the vesicouterine pouch and the **intestinal surface** faces the rectouterine pouch. Note that the broad ligament is attached to the lateral surface of the body of the uterus.

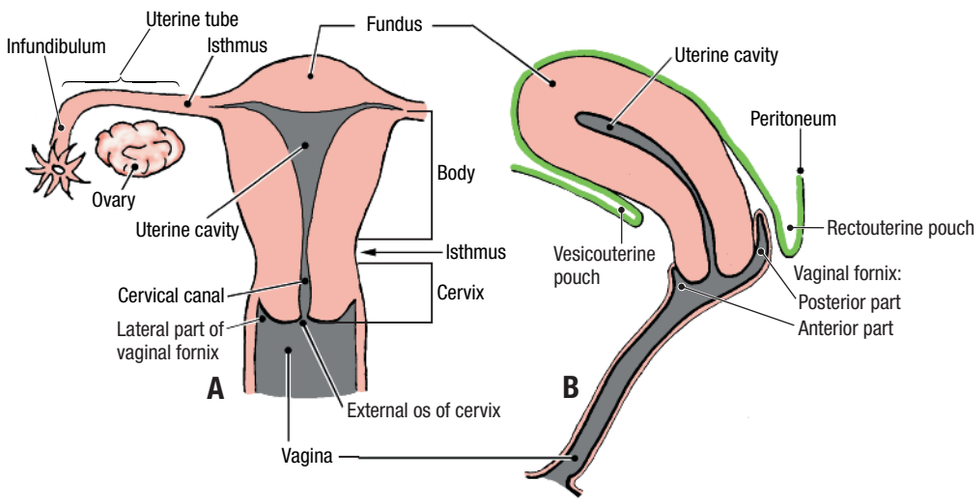

Figure 5.29. The uterus. **A.** Coronal section. **B.** Midsagittal section.

- **Isthmus** – the narrowed portion of the body that is superior to the cervix
- **Cervix** – the thick walled portion of the uterus that protrudes into the vaginal canal

8. Identify the **uterine cavity**. In a coronal section, it is triangular (Fig. 5.29A). In a sagittal section, it is a slit (Fig. 5.29B).
9. Note that the uterine mucosa is called **endometrium**. The thick muscular wall of the uterus is called **myometrium**. The peritoneal covering on the surface of the uterus is called **perimetrium** (Gr. *pari*, around). The tissues within the broad ligament are called **parametrium** (Gr. *para*, beyond).
10. Identify the **uterine (fallopian) tube** (Fig. 5.29). Use your fingers to follow the uterine tube laterally within the mesosalpinx. Observe the **isthmus**, which is the narrow, medial one-third of the uterine tube. Note that the distal end of the uterine tube is expanded to form the **infundibulum.** Identify the **fimbriae** around the margin of the infundibulum.
11. Observe the **ovary**. The ovary is ovoid, with a **tubal (distal) extremity** and a **uterine (proximal) extremity**. The ovarian vessels enter the tubal extremity, and the ovarian ligament is attached to the uterine extremity.
12. The ovary sits in the **ovarian fossa**. The ovarian fossa is a shallow depression in the lateral pelvic wall bounded by the ureter, external iliac vein, and uterine tube.
13. Review the abdominal origin and course of the ovarian vessels. Note that they pass through the **suspensory ligament of the ovary**.

After you dissect . . .

Review the relationships of the female internal genitalia. Use the dissected specimen to review the peritoneum in the pelvic cavity. Trace the round ligament of the uterus from the labium majus to the uterus. Review the parts of the broad ligament and review the function of the endopelvic fascia in passive support of the uterus.

URINARY BLADDER, RECTUM, AND ANAL CANAL

Before you dissect . . .

The urinary bladder is a reservoir for urine. When empty, it is located within the pelvic cavity. When filled, it extends into the abdominal cavity. The urinary bladder is a retroperitoneal organ that is surrounded by **endopelvic fascia**. Between the pubic symphysis and the urinary bladder is a potential space called the **retropubic space (prevesical space)** (Fig. 5.26). The retropubic space is filled with fat and loose connective tissue that accommodates the expansion of the urinary bladder. The **pubovesical ligament** is a condensation of fascia that ties the neck of the urinary bladder to the pubis across the retropubic space.

The lower one-third of the rectum is surrounded by endopelvic fascia. The middle and upper thirds of the rectum are partially covered by peritoneum (Fig. 5.26).

The order of dissection will be as follows. The parts of the urinary bladder will be studied. The interior of the urinary bladder will be studied. The interior of the rectum and anal canal will be studied.

Dissection Instructions

URINARY BLADDER [N 353; C 262]

1. Identify the **parts of the urinary bladder** (Fig. 5.30):
   - **Apex** – the pointed part directed toward the anterior abdominal wall. The apex of the urinary bladder can be identified by the attachment of the urachus.
   - **Body** – between the apex and fundus
   - **Fundus** – the posterior wall, also called the **base of the bladder**. In the female the fundus is related to the vagina and cervix.
   - **Neck** – where the urethra exits the urinary bladder. In the neck of the urinary bladder, the wall thickens to form the involuntary **internal urethral sphincter muscle**.
2. Identify the four **surfaces of the urinary bladder** (Fig. 5.30):
   - **Superior** – covered by peritoneum
   - **Posterior** – covered by endopelvic fascia
   - **Inferolateral (2)** – covered by endopelvic fascia
3. Examine the **wall of the urinary bladder** and note its thickness. The wall of the urinary bladder consists of bundles of smooth muscle called the **detrusor muscle** (L. *detrudere*, to thrust out).
4. Identify the **trigone** on the inner surface of the fundus (Fig. 5.31). The angles of the trigone are the **internal urethral orifice** and the two **orifices of the ureters**. The internal urethral orifice is located at the most inferior point in the urinary bladder. **[N 353]**
5. Observe that the mucous membrane over the trigone is smooth. The mucous membrane lining the other parts of the urinary bladder lies in folds when the bladder is empty but will accommodate expansion.

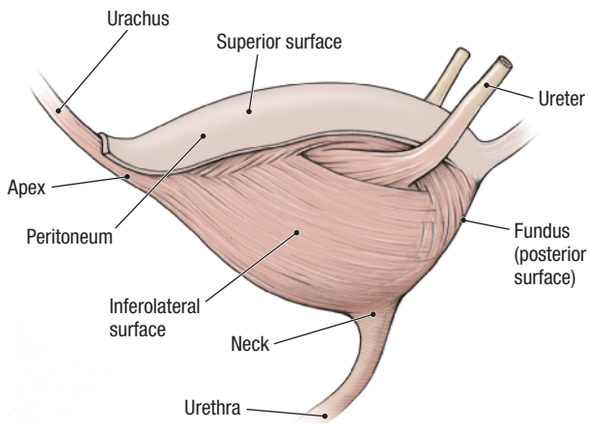

Figure 5.30. Parts of the urinary bladder in the female.

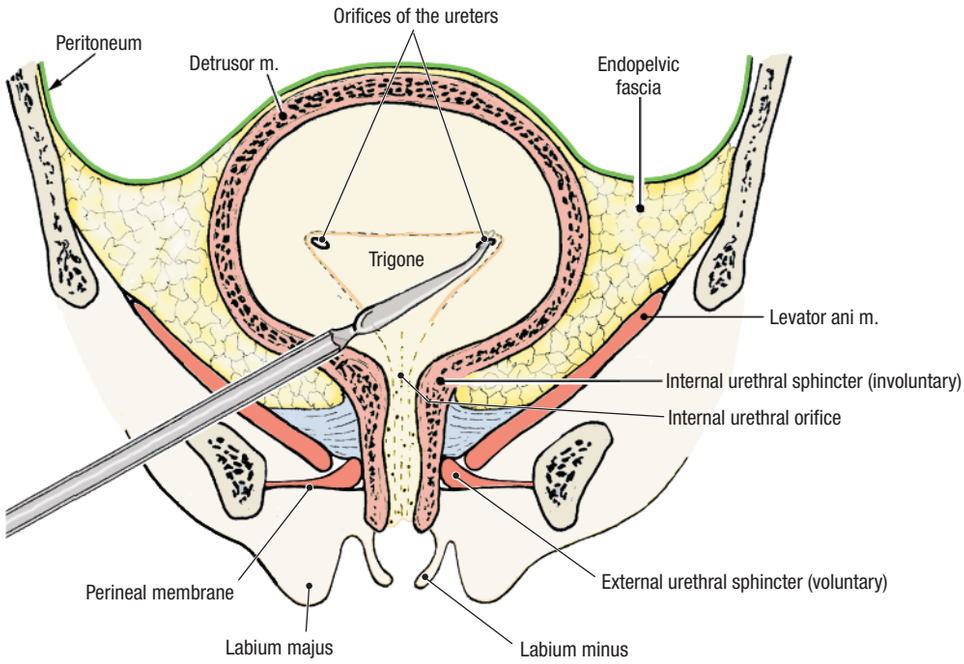

Figure 5.31. Urinary bladder and urethra in the female seen in frontal section. The tip of the probe is located in the orifice of the left ureter.

6. Insert the tip of a probe into the orifice of the ureter and observe that the ureter passes through the wall of the urinary bladder in an oblique fashion. When the urinary bladder is full (distended), the pressure of the accumulated urine flattens the part of the ureter that is within the wall of the bladder and prevents reflux of urine.

CLINICAL CORRELATION

Kidney Stones

Kidney stones pass through the ureter to the urinary bladder and may become lodged in the ureter. The point where the ureter passes through the wall of the urinary bladder is a relatively narrow passage. If a kidney stone becomes lodged, severe colicky pain results. The pain stops suddenly once the stone passes into the bladder.

7. Find the ureter where it crosses the external iliac artery or the bifurcation of the common iliac artery. Use a probe to follow the ureter to the fundus of the urinary bladder. Observe that the ureter crosses inferior to the **uterine artery** and superior to the **vaginal artery**. **[G 228; N 380; R 344; C 269]**

RECTUM AND ANAL CANAL [G 199, 224; N 347, 374; R 345; C 258, 292]

1. Recall that the rectum begins at the level of the third sacral vertebra. Observe the sectioned pelvis and note that the rectum follows the curvature of the sacrum.
2. Identify the **ampulla of the rectum** (Fig. 5.32). At the ampulla, the rectum turns approximately 80 degrees posteriorly (**anorectal flexure**) and is continuous with the anal canal.
3. Examine the inner surface of the rectum. Note that the mucous membrane is smooth except for the presence of **transverse rectal folds**. There is usually one transverse rectal fold on the right side and two on the left side. The transverse rectal folds may be difficult to identify in some cadavers.
4. Observe that the **anal canal** is only 2.5 to 3.5 cm in length. The anal canal passes out of the pelvic cavity and enters the anal triangle of the perineum.
5. Examine the inner surface of the anal canal (Fig. 5.32). Note that the mucosal features of the anal canal may

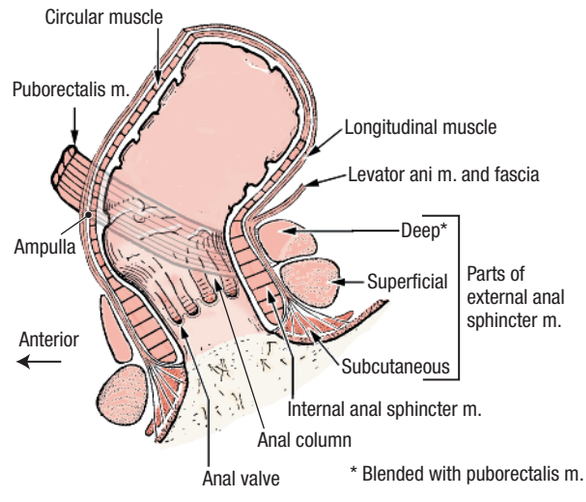

Figure 5.32. Rectum, anal canal, and anal sphincter muscles.

be difficult to identify in older individuals. Attempt to identify the following:

- **Anal columns** – five to 10 longitudinal ridges of mucosa in the proximal part of the anal canal. The anal columns contain branches of the **superior rectal artery** and **vein**.
- **Anal valves** – semilunar folds of mucosa that unite the distal ends of the anal columns. External to each anal valve is a small pocket called an **anal sinus**.
- **Pectinate line** – the irregular line formed by all of the anal valves.

CLINICAL CORRELATION

Hemorrhoids

In the anal columns, the superior rectal veins of the hepatic portal system anastomose with middle and inferior rectal veins of the inferior vena caval system. An abnormal increase in blood pressure in the hepatic portal system causes engorgement of the veins contained in the anal columns, resulting in **internal hemorrhoids**. Internal hemorrhoids are covered by mucous membrane and are relatively insensitive to painful stimuli because the mucous membrane is innervated by autonomic nerves.

External hemorrhoids are enlargements of the tributaries of the inferior rectal veins. External hemorrhoids are covered by skin and are very sensitive to painful stimuli because they are innervated by somatic nerves (inferior rectal nerves).

6. The anal sphincter muscles surround the anal canal. Identify the **external anal sphincter muscle** and the **internal anal sphincter muscle** in the sectioned specimen (Fig. 5.32). The longitudinal muscle of the anal canal separates the two sphincter muscles. If you have difficulty identifying them, use a new scalpel blade to cut another section through the wall of the anal canal to improve the clarity of the dissection.

After you dissect . . .

Use the dissected specimen to review the features of the urinary bladder, rectum, and anal canal. Review the relationships of the uterus, vagina, and ureters to the rectum and fundus of the urinary bladder. Review the kidney, the abdominal course of the ureter, the pelvic course of the ureter, and the function of the urinary bladder as a storage organ. Review the female urethra. Review all parts of the large intestine and recall its function in absorption of water, compaction, and elimination of fecal material. Recall that the external anal sphincter muscle is composed of skeletal muscle and is under voluntary control, whereas the internal anal sphincter muscle is composed of smooth muscle and is involuntary.

INTERNAL ILIAC ARTERY AND SACRAL PLEXUS

Before you dissect . . .

Anterior to the sacroiliac articulation, the **common iliac artery** divides to form the **external** and **internal iliac arteries** (Fig. 5.33). The external iliac artery distributes to the lower limb and the internal iliac artery to the pelvis. The internal iliac artery commonly divides into an anterior division and a posterior division. Branches arising from the anterior division are mainly visceral (branches to the urinary bladder, internal genitalia, external genitalia, rectum, and gluteal region). Branches arising from the posterior division are parietal (branches to the pelvic walls and gluteal region). The branching pattern of the internal iliac artery is variable, so it is important to identify the arteries by their distribution. The internal iliac vein is typically plexiform. To clear the dissection field, remove all tributaries to the internal iliac vein.

The order of dissection will be as follows. The branches of the anterior division of the internal iliac artery will be identified. The branches of the posterior division of the internal iliac artery will be identified. The nerves of the sacral plexus will be dissected. Finally, the pelvic portion of the sympathetic trunk will be dissected.

Dissection Instructions

BLOOD VESSELS [G 234; N 380, 382; C 269]

1. Identify the **common iliac artery** and follow it to its bifurcation.
2. Identify the **internal iliac artery**. Use blunt dissection to follow the **internal iliac artery** into the lesser pelvis.
3. Identify the branches of the anterior division of the internal iliac artery (Fig. 5.33):
   - **Umbilical artery** – in the medial umbilical fold, find the **umbilical ligament** (the obliterated portion of the umbilical artery) and use blunt dissection to trace it posteriorly to the umbilical artery. Note that several **superior vesical arteries** arise from the inferior surface of the umbilical artery and descend to the superolateral aspect of the urinary bladder.
   - **Obturator artery** – passes through the obturator canal. Find the obturator artery where it enters the obturator canal in the lateral wall of the lesser pelvis, and follow the artery posteriorly to its origin. In approximately 20% of cases, the obturator artery arises from the inferior epigastric artery (**aberrant obturator artery**). An aberrant obturator artery crosses the pelvic brim and is at risk of injury during surgical repair of a femoral hernia.
   - **Uterine artery** – courses along the inferior margin of the broad ligament. Use blunt dissection to trace it to the lateral aspect of the uterus and note that it passes superior to the ureter. The uterine artery divides into a large superior branch to the body and fundus of the uterus and a smaller branch to the

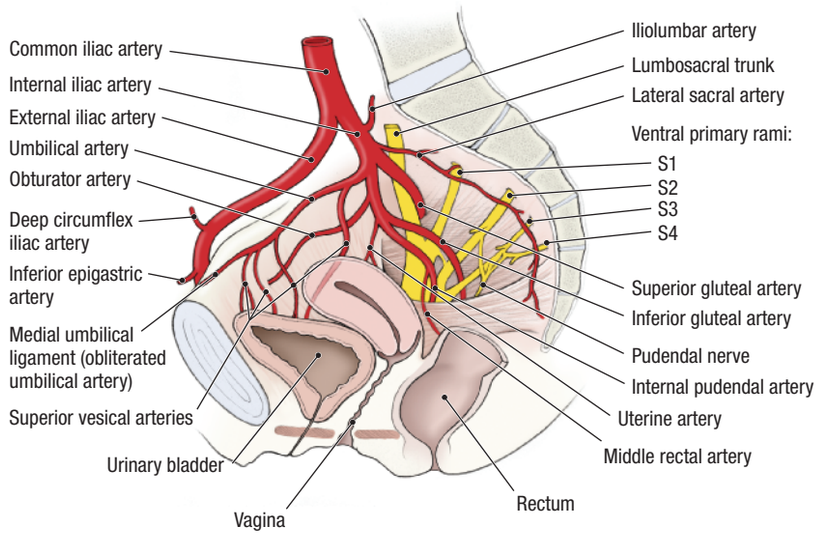

Figure 5.33. Branches of the internal iliac artery in the female.

cervix and vagina. Observe the close relationship of the lateral part of the vaginal fornix to the uterine artery. In the living body, the pulsations of the uterine artery may be felt through the lateral part of the vaginal fornix.

CLINICAL CORRELATION

Uterine Artery

The close proximity of the ureter and the uterine artery near the lateral fornix of the vagina is of clinical importance. During hysterectomy, the uterine artery is tied off and cut. The ureter may be unintentionally clamped, tied off, and severed where it crosses the uterine artery. This would have serious consequences for the corresponding kidney. To recall this relationship, use the mnemonic device "water under the bridge."

- **Vaginal artery** – passes across the floor of the pelvis, inferior to the ureter. The vaginal artery supplies the vagina and the urinary bladder. Note that the ureter passes between the vaginal artery and the uterine artery.
- **Middle rectal artery** – courses medially toward the rectum. To confirm the identity of the middle rectal artery, follow it to the rectum.
- **Internal pudendal artery** – exits the pelvic cavity by passing through the greater sciatic foramen inferior to the piriformis muscle. The internal pudendal artery often arises from a common trunk with the inferior gluteal artery.
- **Inferior gluteal artery** – passes out of the pelvic cavity between ventral primary rami S2 and S3. The inferior gluteal artery exits the pelvis by passing through the greater sciatic foramen inferior to the piriformis muscle. The inferior gluteal artery may share a common trunk with the internal pudendal artery.

4. Identify the branches of the posterior division of the internal iliac artery (Fig. 5.33):
   - **Iliolumbar artery** – passes posteriorly between the lumbosacral trunk and the obturator nerve. It may arise from a common trunk with the lateral sacral artery.
   - **Lateral sacral artery** – gives rise to a superior branch and an inferior branch. Observe the inferior branch that passes anterior to the sacral ventral primary rami.
   - **Superior gluteal artery** – exits the pelvic cavity by passing between the lumbosacral trunk and the ventral primary ramus of spinal nerve S1.
5. Use an illustration to study the **vesical venous plexus, uterine venous plexus, vaginal venous plexus**, and **rectal venous plexus**. All of these plexuses drain into the internal iliac vein.
6. In the cadaver, identify the **internal iliac vein**. Follow the internal iliac vein to its junction with the **external iliac vein**. At this junction, the **common iliac vein** is formed.

NERVES [G 220, 234; N 392, 481; R 456; C 296]

The somatic plexuses of the pelvic cavity are the **sacral plexus** and **coccygeal plexus**. They are located between the pelvic viscera and the lateral pelvic wall. These somatic nerve plexuses are formed by contributions from ventral primary rami of spinal nerves L4 to S4. The primary visceral nerve plexus of the pelvic cavity is the **inferior hypogastric plexus**. It is formed by contributions from the hypogastric nerves, sympathetic trunks, and pelvic splanchnic nerves.

1. Use your fingers to dissect the rectum from the anterior surface of the sacrum and coccyx.

2. Retract the rectum medially. Identify the **sacral plexus** of nerves. The sacral plexus is closely related to the anterior surface of the piriformis muscle. Verify the following (Fig. 5.34):
   - The **lumbosacral trunk** (ventral primary rami of L4, L5) joins the sacral plexus.
   - The ventral primary rami of S2 and S3 emerge between the proximal attachments of the piriformis muscle.
   - The **sciatic nerve** is formed by the ventral primary rami of spinal nerves L4 through S3. The sciatic nerve exits the pelvis by passing through the greater sciatic foramen, usually inferior to the piriformis muscle.
   - The **superior gluteal artery** usually passes between the **lumbosacral trunk** and the **ventral primary ramus of spinal nerve S1**, and exits the pelvis by passing superior to the piriformis muscle.
   - The **inferior gluteal artery** usually passes between the **ventral primary rami of spinal nerves S2 and S3**. The inferior gluteal artery exits the pelvis by passing inferior to the piriformis muscle.
   - The **pudendal nerve** receives a contribution from the ventral primary rami of spinal nerves S2, S3, and S4. The pudendal nerve exits the pelvis by passing inferior to the piriformis muscle.
3. Identify the **pelvic splanchnic nerves (nervi erigentes)**. Pelvic splanchnic nerves are branches of the ventral primary rami of spinal nerves S2 to S4 (Fig. 5.34). Pelvic splanchnic nerves carry preganglionic parasympathetic axons for the innervation of pelvic organs and the distal gastrointestinal tract (from the left colic flexure through the anal canal). **[G 236, 237, 239; N 392; C 296]**
4. The **sacral portion of the sympathetic trunk** is located on the anterior surface of the sacrum, medial to the ventral sacral foramina. Identify the following:
   - **Sympathetic trunk** – continues from the abdominal region into the pelvis. The sympathetic trunks of the two sides join in the midline near the level of the coccyx to form the **ganglion impar**.
   - **Gray rami communicantes** – connect the sympathetic ganglia to the sacral ventral primary rami. Each gray ramus communicans carries postganglionic sympathetic fibers to a ventral primary ramus for distribution to the lower extremity and the perineum.
   - **Sacral splanchnic nerves** – arise from two or three of the sacral sympathetic ganglia and pass directly to the **inferior hypogastric plexus**. Sacral splanchnic nerves carry sympathetic fibers that distribute to the pelvic viscera.

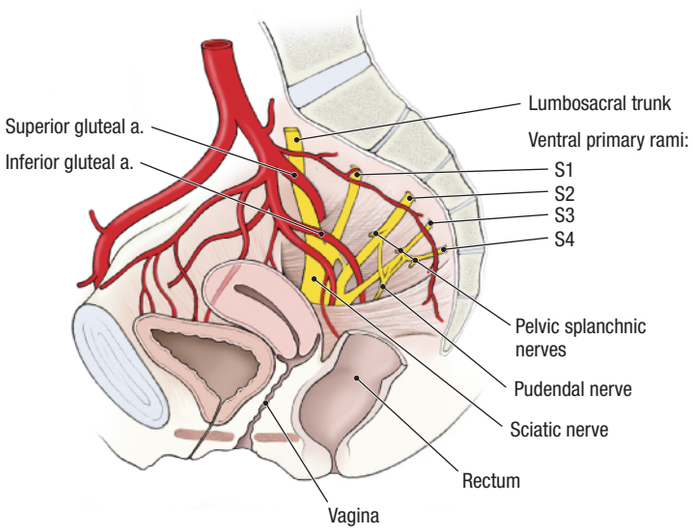

Figure 5.34. Sacral plexus of nerves in the female.

CLINICAL CORRELATION

Pelvic Nerve Plexuses

The pelvic splanchnic nerves (parasympathetic outflow of S2, S3, S4) are closely related to the lateral aspects of the rectum. The inferior hypogastric plexus is located in the connective tissue lateral to the uterus. These autonomic nerve plexuses can be injured during surgery, causing loss of bladder control.

After you dissect . . .

Review the abdominal aorta and its terminal branches. Use the dissected specimen to review the branches of the internal iliac artery. Review the region supplied by each branch. Review the formation of the sacral plexus and the branches that were dissected in the pelvis. Use the dissected specimen and an illustration to review the course of the pudendal nerve from the pelvis to the urogenital triangle.

PELVIC DIAPHRAGM

Before you dissect . . .

The **pelvic diaphragm** is the muscular floor of the pelvic cavity. The pelvic diaphragm is formed by the levator ani muscle and coccygeus muscle plus the fasciae covering their superior and inferior surfaces (Fig. 5.35A,B). The pelvic diaphragm extends from the pubic symphysis to the coccyx. Laterally, the pelvic diaphragm is attached to the fascia covering the obturator internus muscle. The urethra, vagina, and anal canal pass through a midline opening in the pelvic diaphragm called the **urogenital hiatus**.

Dissection Instructions

1. Perform the dissection of the pelvic diaphragm on one side of the cadaver. Save the side with the best dissection of arteries and nerves for review. **[G 193, 195; N 343, 344; C 271, 272]**

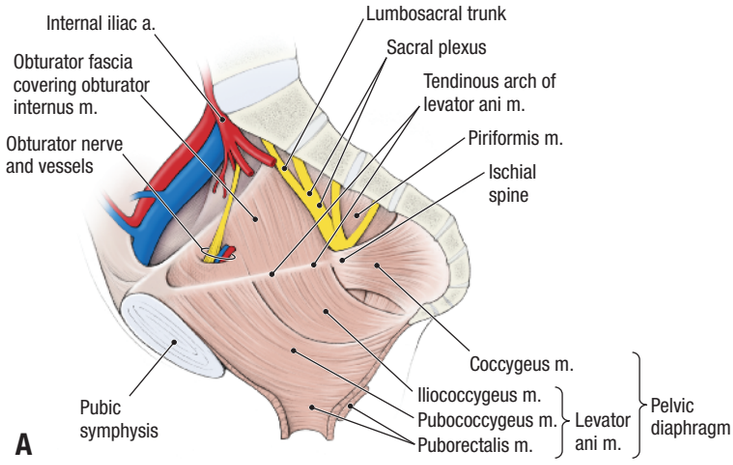

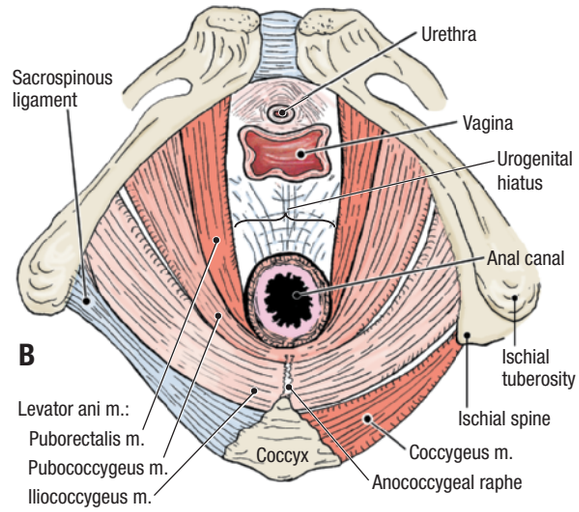

Figure 5.35. Pelvic diaphragm in the female. **A.** Left lateral view. **B.** Inferior view.

2. Retract the urinary bladder, uterus, and rectum toward the midline.
3. Use blunt dissection to remove any remaining fat and connective tissue from the superior surface of the pelvic diaphragm.
4. Find the **tendinous arch of the levator ani muscle** (Fig. 5.35A). Palpate the medial surface of the ischial spine. Locate the obturator canal. The tendinous arch lies just inferior to a line connecting these two structures. Note that the tendinous arch is the superior edge of the pelvic diaphragm.
5. Identify the three muscles that form the **levator ani muscle**. The muscles are identified by their proximal attachments. Learn, but do not dissect, their distal attachments. Identify the following:
   - **Puborectalis muscle** – its proximal attachment is the body of the pubis. Its distal attachment is the puborectalis muscle of the opposite side (midline raphe). The pubococcygeus muscle forms the lateral boundary of the urogenital hiatus. The two puborectalis muscles form a "puborectal sling," which causes the **anorectal flexure** at the ampulla of the rectum (Fig. 5.32). During defecation, the puborectalis muscles relax, the anorectal flexure straightens, and the elimination of fecal matter is facilitated.
   - **Pubococcygeus muscle** – its proximal attachment is the body of the pubis. Its distal attachment is the coccyx and the **anococcygeal** raphe.
   - **Iliococcygeus muscle** – its proximal attachment is the tendinous arch. Its distal attachment is the coccyx and the anococcygeal raphe.
6. The levator ani muscle supports the pelvic viscera and resists increases in intra-abdominal pressure.
7. Identify the **coccygeus muscle**. The coccygeus muscle completes the pelvic diaphragm posteriorly. The proximal attachment of the coccygeus muscle is the ischial spine and its distal attachment is the lateral border of the coccyx and the lowest part of the sacrum.
8. Place one hand in the ischioanal fossa and the other on the superior surface of the pelvic diaphragm. Palpate the thinness of the pelvic diaphragm.
9. Observe that the **obturator internus muscle** forms the lateral wall of the ischioanal fossa. The proximal attachment of the obturator internus muscle is the margin of the obturator foramen and inner surface of the obturator membrane. The distal attachment of the obturator internus muscle will be studied when the gluteal region is dissected. Superior to the tendinous arch of the levator ani muscle, the obturator internus muscle forms the lateral wall of the pelvic cavity. Inferior to the tendinous arch, the obturator internus muscle forms the lateral wall of the perineum.
10. Use your textbook to learn the general pattern of lymphatic drainage of the pelvis, and the location of each of the following groups of lymph nodes: **[G 203, 236, 237; N 386; R 349; C 269]**
    - **Internal iliac nodes**
    - **External iliac nodes**
    - **Common iliac nodes**
    - **Sacral nodes**
    - **Lumbar nodes**

After you dissect . . .

Use the dissected specimen to review the proximal attachment and action of each muscle of the pelvic diaphragm. Review the relationship of the branches of the internal iliac artery to the pelvic diaphragm. Review the relationship of the sacral plexus to the pelvic diaphragm. Use an illustration to review the role of the pelvic diaphragm in dividing the pelvic cavity from the perineum. Review the function of the pelvic diaphragm and perineal body in supporting the pelvic and abdominal viscera. Use an illustration to review the lymphatic drainage from the pelvis and perineum. Realize that structures in the perineum (including the labia majora and the lower part of the anal canal) drain into superficial inguinal lymph nodes. The lymphatic drainage of the ovary follows the ovarian vessels to the lumbar chain of nodes, bypassing the pelvic drainage systems. Review the formation of the thoracic duct to complete your understanding of the lymph drainage from this region.

CHAPTER 6

THE LOWER LIMB

The functional requirements of the lower limb are weight bearing, locomotion, and maintenance of equilibrium. As such, it is constructed for strength at the cost of mobility. The lower limb is divided into four parts: **hip**, **thigh**, **leg**, and **foot** (Fig. 6.01). It is worth noting that the term *leg* refers only to the portion of the lower limb between the knee and ankle, not to the entire lower limb.

SURFACE ANATOMY [G 343; N 467; C 310]

The surface anatomy of the lower limb can be studied on a living subject or the cadaver. Place the cadaver in the supine position and palpate the following structures (Fig. 6.01):

- **Iliac crest**
- **Anterior superior iliac spine**
- **Inguinal ligament**
- **Pubic tubercle**
- **Patella**
- **Medial femoral epicondyle**
- **Lateral femoral epicondyle**
- **Medial malleolus**
- **Lateral malleolus**

SUPERFICIAL VEINS AND CUTANEOUS NERVES

Before you dissect . . .

The order of dissection will be as follows: The entire lower limb will be skinned. The superficial veins and cutaneous nerves will be dissected. The subcutaneous connective tissue and fat will be removed leaving selected superficial veins and nerves intact. The deep fascia of the thigh will be studied.

Dissection Instructions

SKIN INCISIONS

1. Refer to Figure 6.02A. The objective is to remove the skin from the lower limb, leaving the superficial veins and cutaneous nerves undisturbed.
2. Make a cut from the anterior superior iliac spine (D) along the inguinal ligament to the pubic tubercle. Extend this cut around the medial side of the thigh to the posterior surface of the thigh (E). If the abdomen and perineum have been dissected, this cut has been made previously.
3. Make a cut from the midpoint of the inguinal ligament (F) to the dorsum of the foot (G) passing over the patella.
4. Make a cut across the dorsum of the foot at the webs of the toes (H to H). The skin is very thin on the dorsum of the foot. Do not cut too deep.

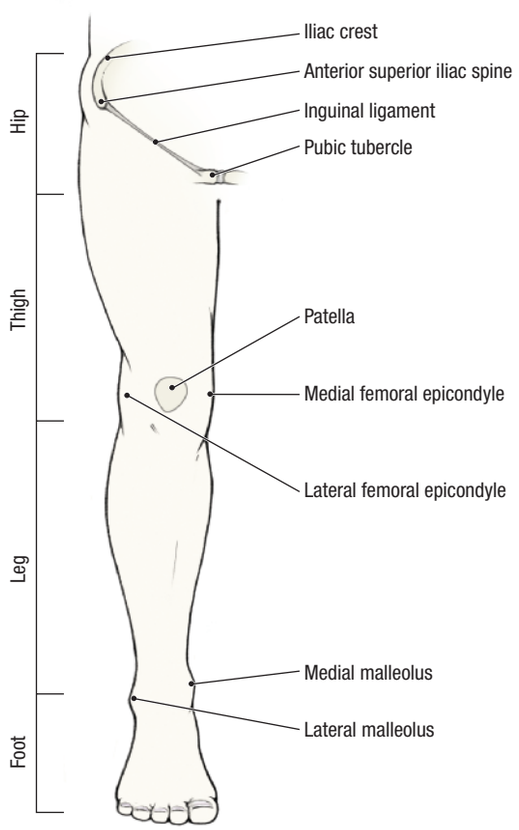

Figure 6.01. Surface anatomy of the lower limb.

KEY TO REFERENCES
G = Grant's Atlas, 11th ed., page number
N = Netter's Atlas, 3rd ed., plate number
R = Rohen's Color Atlas of Anatomy, 5th ed., page number
C = Clemente's Atlas, 4th ed., page number

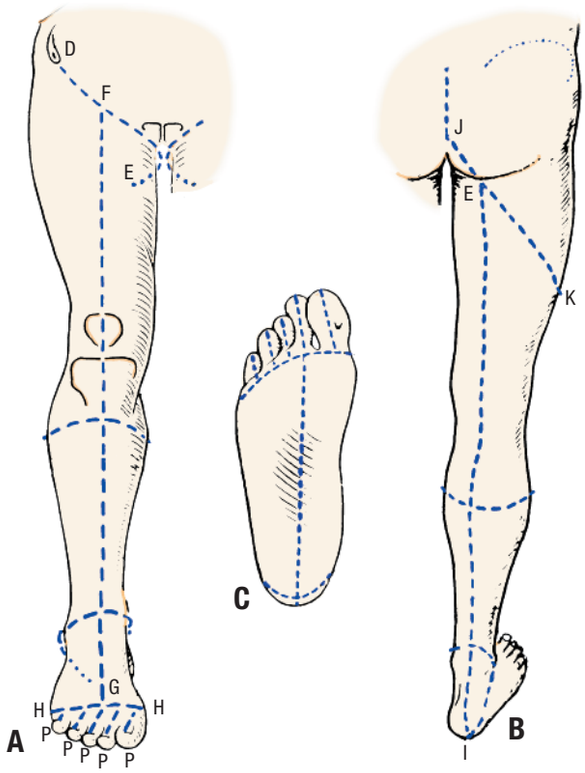

Figure 6.02. Skin incisions.

5. Make one cut along the dorsal midline of each toe to the proximal end of the nail (H to P).
6. Remove the skin from the thigh, leg and dorsum of the foot as far laterally and medially as possible. Make as many transverse skin incisions as are needed to speed up the skinning process.
7. Turn the cadaver into the prone position and refer to Figure 6.02B.
8. If not already done during the dissection of the pelvis, begin at the midline over the sacrum and remove all of the skin from the gluteal region. Detach this skin along line J-K and place it in the tissue container.
9. Make a cut along the midline of the thigh and leg from the gluteal fold to the heel (E to I).
10. Extend the previous transverse skin incisions around the limb to join incision E-I. Remove the skin completely from the lower limb and place it in the tissue container.
11. Remove the skin from the sole of the foot using the cuts indicated in Figure 6.02C. The skin is thick over the heel and over the heads of the metatarsal bones, but it is thinner on the toes and the instep.

SUPERFICIAL FASCIA OF THE POSTERIOR LOWER LIMB
[G 340, 342; N 527; R 468, 473; C 505, 538]

1. With the cadaver still in the prone position, examine the structures contained in the superficial fascia of the posterior aspect of the lower limb (Fig. 6.03B).
2. The skin of the gluteal region is innervated by **cluneal nerves** (L. *clunis*, buttock).
   - **Superior cluneal nerves** and **middle cluneal nerves**—are branches of dorsal primary rami. Do not attempt to find these nerves.
   - **Inferior cluneal nerves** are branches of the posterior cutaneous nerve of the thigh (Fig. 6.03B). The inferior cluneal nerves wrap around the inferior border of the gluteus maximus muscle and they have been removed if the perineum has been dissected previously.
3. The **posterior cutaneous nerve of the thigh** runs deep to the deep fascia (Fig. 6.03, *dotted lines*). Branches of the posterior cutaneous nerve pierce the deep fascia to supply the skin on the posterior surface of the thigh and popliteal fossa.

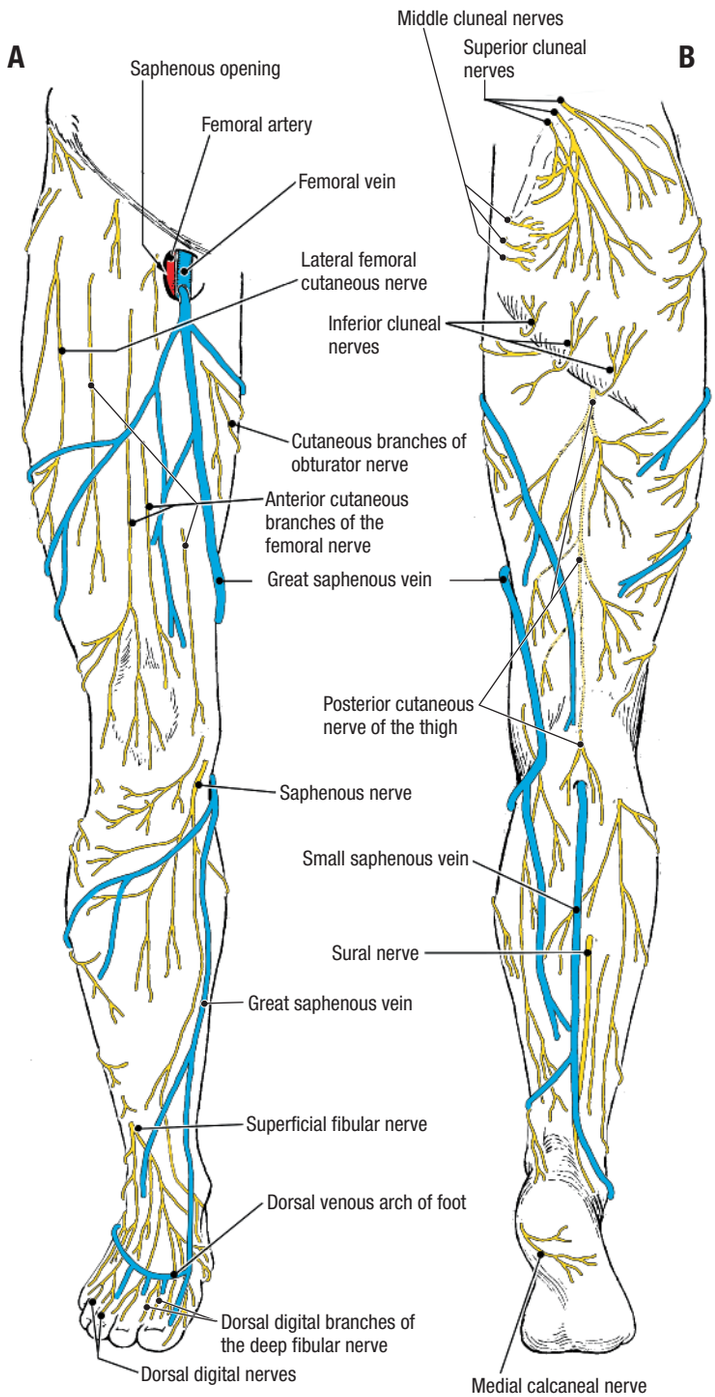

Figure 6.03. Cutaneous nerves and superficial veins of the lower limb. **A.** Anterior view. **B.** Posterior view.

4. Find the **small saphenous vein** where it passes posterior to the lateral malleolus at the ankle (Fig. 6.03B). The small saphenous vein arises from the lateral end of the **dorsal venous arch**. Clean the small saphenous vein and follow it superiorly until it pierces the deep fascia in the popliteal fossa to join the popliteal vein.
5. Identify the **sural nerve** (L. *sura*, calf of the leg). The sural nerve pierces the deep fascia half way down the posterior aspect of the leg and courses parallel to the small saphenous vein. The sural nerve innervates the skin of the lateral aspect of the ankle and foot.
6. Remove all **superficial fascia** from the posterior aspect of the gluteal region, thigh, and leg. Preserve the deep fascia, nerves, and veins that you have dissected.

SUPERFICIAL FASCIA OF THE ANTERIOR LOWER LIMB
[G 340, 342; N 526; R 462, 476; C 314, 342, 350]

1. Turn the cadaver to the supine position and refer to Figure 6.03A.
2. Find the **great saphenous vein** (Gr., *saphenous*, manifest; obvious) where it arises from the medial end of the **dorsal venous arch of the foot** (Fig. 6.03A). Use blunt dissection to follow it proximally. At the ankle, the great saphenous vein passes anterior to the medial malleolus. At the knee, it passes over the posterior border of the medial epicondyle of the femur. The great saphenous vein then courses anterolaterally to lie on the anterior surface of the thigh.
3. Inferior to the inguinal ligament, the great saphenous vein passes deeply through the **saphenous opening** in the deep fascia and drains into the femoral vein. The saphenous opening will be dissected later.
4. Note the following characteristics of the great saphenous vein:
   - The **saphenous nerve** accompanies the great saphenous vein in the leg.
   - **Perforating veins** connect the great saphenous vein to the deep venous system.
   - Unnamed superficial veins join the great saphenous vein, and some of these are quite large.
   - Three named superficial veins (**superficial external pudendal**, **superficial epigastric**, and **superficial circumflex iliac**) join the great saphenous vein near its proximal end.
5. Use an illustration to study the cutaneous innervation of the anterior surface of the lower limb and note the following (Fig. 6.03A):
   - **Lateral femoral cutaneous nerve** – passes deep to the inguinal ligament and innervates the skin of the lateral thigh.
   - **Anterior cutaneous branches of the femoral nerve** – innervate the skin of the anterior thigh. These branches enter the superficial fascia lateral to the great saphenous vein.
   - **Cutaneous branches of the obturator nerve** – innervate the skin of the medial thigh.
   - **Saphenous nerve** – pierces the deep fascia on the medial aspect of the knee and accompanies the great saphenous vein into the leg. The saphenous nerve is a branch of the femoral nerve. The saphenous nerve innervates the anterior and medial aspects of the leg and the medial side of the ankle and foot.
6. In the distal third of the leg, identify the **superficial fibular (peroneal) nerve**. The superficial fibular nerve pierces the deep fascia proximal to the lateral malleolus. Follow the superficial fibular nerve distally and note that it innervates the dorsum of the foot and sends **dorsal digital nerves** to the skin of the toes. The skin between the 1st toe and the 2nd toe is innervated by the **dorsal digital branches of the deep fibular nerve**. This innervation pattern is used for the assessment of nerve injuries in the leg.
7. Identify the **superficial inguinal lymph nodes**. Two subgroups can be identified (Fig. 6.04):
   - **Horizontal group**—about 2 cm below the inguinal ligament
   - **Vertical group**—around the proximal end of the great saphenous vein
8. Note that the superficial inguinal lymph nodes collect lymph from the lower limb, lower anterior abdominal wall, gluteal region, perineum, and external genitalia. The superficial inguinal lymph nodes drain into the **deep inguinal lymph nodes**. Do not attempt to dissect the deep inguinal lymph nodes.

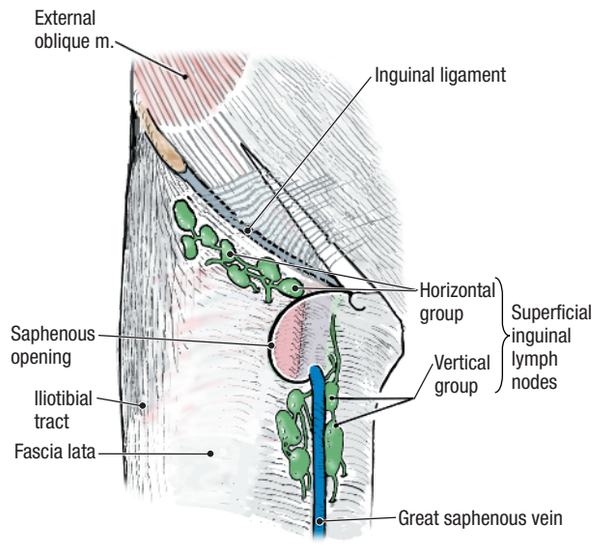

Figure 6.04. Saphenous opening and superficial inguinal lymph nodes.

CLINICAL CORRELATION

Great Saphenous Vein

Superficial veins and perforating veins have valves that prevent the back flow of blood. If these valves become insufficient, then the veins become distended, a condition known as varicose veins.

Portions of the great saphenous vein may be removed and used as graft vessels in coronary bypass surgery. The distal end of the vein is attached to the aorta, reversing the direction of blood flow through the vessel so that the valves do not impede the flow of blood.

9. Remove the superficial fascia from the anterior thigh, leg, and foot. Preserve the superficial veins, the cutaneous nerves, and the deep fascia.
10. Examine the deep fascia of the lower limb. It is named regionally: **fascia lata** (L., *latus*, broad) in the thigh, **crural fascia** in the leg and **pedal fascia** in the foot. The lateral portion of the fascia lata is particularly strong and is called the **iliotibial tract**.

After you dissect . . .

Review the superficial fascia of the lower limb. Review the course of the superficial veins from distal to proximal. Review the locations and distributions of the cutaneous nerves that you have dissected. Review the deep fascia and name its parts.

ANTERIOR COMPARTMENT OF THE THIGH

Before you dissect . . .

The fascia lata is connected to the femur by intermuscular septa to form three fascial compartments of the thigh: **anterior (extensor)**, **medial (adductor)**, and **posterior (flexor)** (Fig. 6.05). The anterior compartment of the thigh contains five muscles: sartorius, rectus femoris, vastus lateralis, vastus intermedius, and vastus medialis. The shared action of these muscles is extension of the leg. The major blood supply to the lower limb (femoral artery and deep femoral artery) passes through the anterior compartment of the thigh. **[G 345; N 487; R 441; C 400]**

The order of dissection will be as follows: The fascia lata of the thigh will be reviewed and its saphenous opening will be studied. The anterior surface of the fascia lata will be opened to expose the femoral triangle. The femoral triangle will be dissected and its contents traced distally. The adductor canal will be dissected and the anterior thigh muscles will be studied.

SKELETON OF THE THIGH

Refer to a skeleton and Figure 6.06.

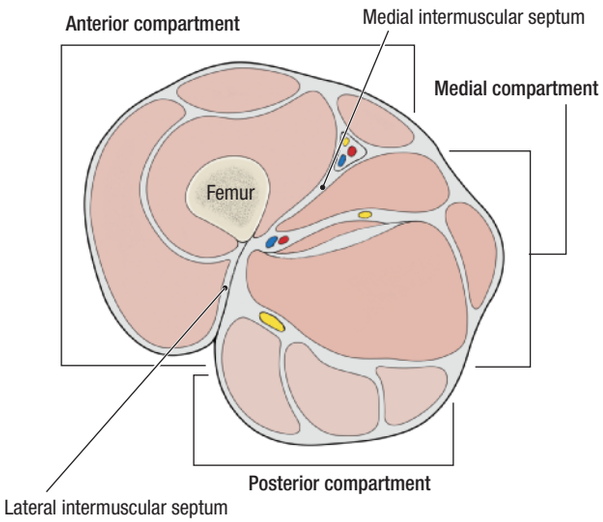

Figure 6.05. Compartments of the right thigh from an inferior view

On the pelvis, identify: **[G 362; N 468; R 422; C 250]**

- **Anterior superior iliac spine**
- **Anterior inferior iliac spine**
- **Pubic tubercle**

On the femur, identify: **[G 362; N 471; R 425; C 374, 375]**

- **Greater trochanter**
- **Lesser trochanter**
- **Lateral condyle** and **lateral epicondyle**
- **Medial condyle** and **medial epicondyle**
- **Medial supracondylar line**
- **Adductor tubercle**
- **Linea aspera**
- **Pectineal line**

On the tibia, identify: **[G 362; N 495; R 426; C 388]**

- **Tuberosity**

On the patella, identify:

- **Anterior surface**
- **Articular surface**

Dissection Instructions

SAPHENOUS OPENING [G 350, 352; N 526; R 454; C 314]

1. Clean the fascia lata in the region of the **saphenous opening** (Fig. 6.07). Observe that the great saphenous vein passes through the saphenous opening to enter the deeper part of the anterior thigh.
2. Use scissors to make a vertical incision through the fascia lata from the saphenous opening to the sartorius muscle.
3. Use your fingers to separate the fascia lata from deeper structures. Make a second incision that extends laterally from the lateral margin of the saphenous opening, parallel to the inguinal ligament. Open the fascia lata widely.
4. Identify the **femoral sheath** (Fig. 6.07). The femoral sheath envelops the femoral artery, femoral vein, and some deep inguinal lymph nodes. Note that the femoral sheath is shaped like a short cone. The femoral sheath is subdivided into **three compartments** (Fig. 6.07):
   - **Lateral** – containing the femoral artery
   - **Intermediate** – containing the femoral vein
   - **Medial** – containing lymphatics. The medial compartment of the femoral sheath is called the **femoral canal** and its proximal opening is called the **femoral ring**.

CLINICAL CORRELATION

Femoral Hernia

The femoral ring is a site of potential herniation. A femoral hernia is a protrusion of abdominal viscera through the femoral ring into the femoral canal. A femoral hernia may become strangulated due to the inflexibility of the inguinal ligament.

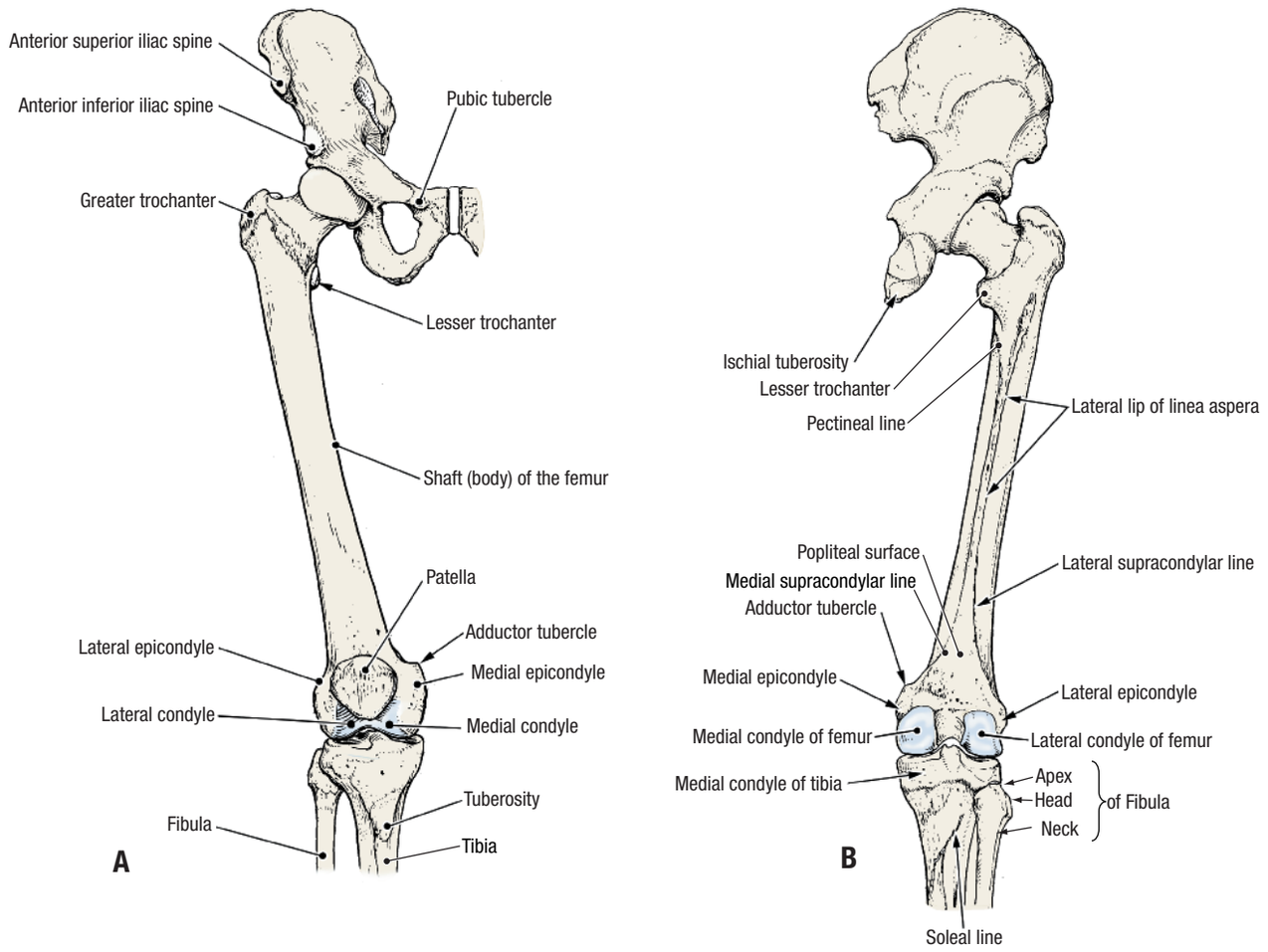

Figure 6.06. Bones of the thigh. **A.** Anterior view. **B.** Posterior view.

FEMORAL TRIANGLE [G 354, 355; N 482; R 463-465; C 318, 321]

1. Identify the **femoral triangle** (Fig. 6.08). The femoral triangle is bounded superiorly by the **inguinal ligament,** laterally by the medial border of the **sartorius muscle** and medially by the lateral border of the **adductor longus muscle**. The base of the femoral triangle is the inguinal ligament and the apex is located inferiorly. The **contents of the femoral triangle** are the:
   - **Femoral nerve** and its branches
   - **Femoral artery** and some of its branches
   - **Femoral vein** and some of its tributaries (notably, the great saphenous vein)
   - **Femoral sheath**

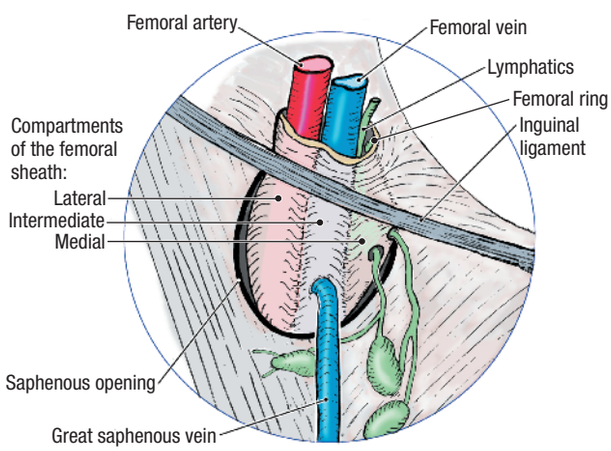

Figure 6.07. The femoral sheath.

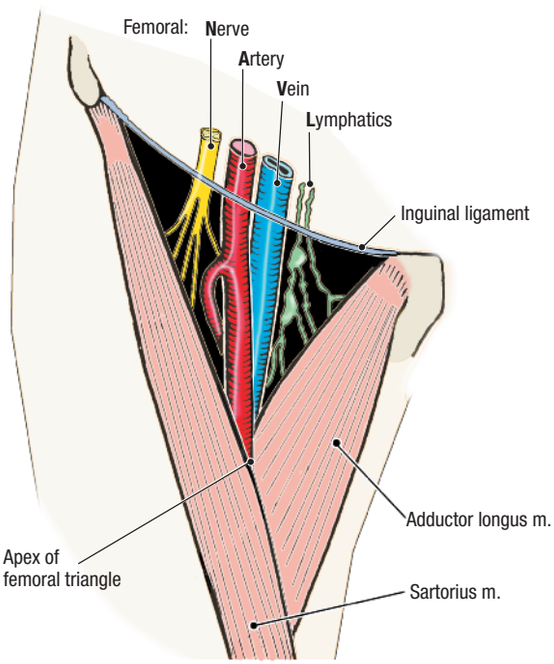

Figure 6.08. Boundaries and contents of the femoral triangle.

CLINICAL CORRELATION

Femoral Triangle

The pulse of the femoral artery can be palpated about 3 cm inferior to the midpoint of the inguinal ligament. Within the femoral triangle, the femoral vessels are accessed for diagnostic purposes. A catheter introduced into the femoral artery can be advanced proximally into the aorta and its branches. A catheter introduced into the femoral vein can be advanced through the inferior vena cava into the right atrium of the heart.

2. Use blunt dissection to clean the **femoral artery** and **femoral vein** within the femoral triangle. Three small arteries arise from the femoral artery just distal to the inguinal ligament: **superficial external pudendal artery**, **superficial epigastric artery**, and **superficial circumflex iliac artery**. Respectively, these arteries pass medially, superiorly and laterally from their origin and they supply the superficial fascia of the abdominal wall, proximal thigh and part of the perineum. Do not attempt to follow these vessels.
3. Three large arteries arise within the femoral triangle: **deep artery of the thigh (deep femoral artery, profunda femoris artery)**, **lateral circumflex femoral artery**, and **medial circumflex femoral artery** (Fig. 6.09B). The medial and lateral circumflex femoral arteries usually arise from the deep artery of the thigh, but each may arise from the femoral artery.
4. Preserve the major veins (femoral vein, deep vein of the thigh, great saphenous vein) but remove their tributaries to clear the dissection field.
5. The **femoral artery** courses distally between the sartorius muscle and the adductor longus muscle (Fig. 6.09A).
6. Retract the femoral artery laterally or medially and identify the **deep artery of the thigh**. The deep artery of the thigh courses parallel to the femoral artery but posterior to the adductor longus muscle (Fig. 6.09C). The deep artery of the thigh supplies the medial and posterior compartments of the thigh.
7. Identify the **lateral circumflex femoral artery**. The lateral circumflex femoral artery usually arises from the deep artery of the thigh very close to its origin from the femoral artery. The lateral circumflex femoral artery passes laterally, deep to the proximal end of the rectus femoris muscle, and supplies the lateral part of the thigh.
8. Identify the **medial circumflex femoral artery**. The medial circumflex femoral artery typically arises from the deep artery of the thigh close to the origin of the lateral circumflex femoral artery. The medial circumflex femoral artery passes posteriorly, between the pectineus and iliopsoas muscles.
9. The floor of the femoral triangle is formed by the iliopsoas muscle and the pectineus muscle. Use blunt dissection to clean the floor of the femoral triangle.
10. The iliacus and psoas major muscles collectively are named the **iliopsoas muscle**. The proximal attachment of the iliacus muscle is the iliac fossa and the proximal attachments of the psoas major muscle are the transverse processes and bodies of vertebra T12-L5. The distal attachment of the iliopsoas muscle is the lesser trochanter of the femur and it is a strong flexor of the thigh.
11. The proximal attachment of the **pectineus muscle** is the superior ramus of the pubis and its distal attach-

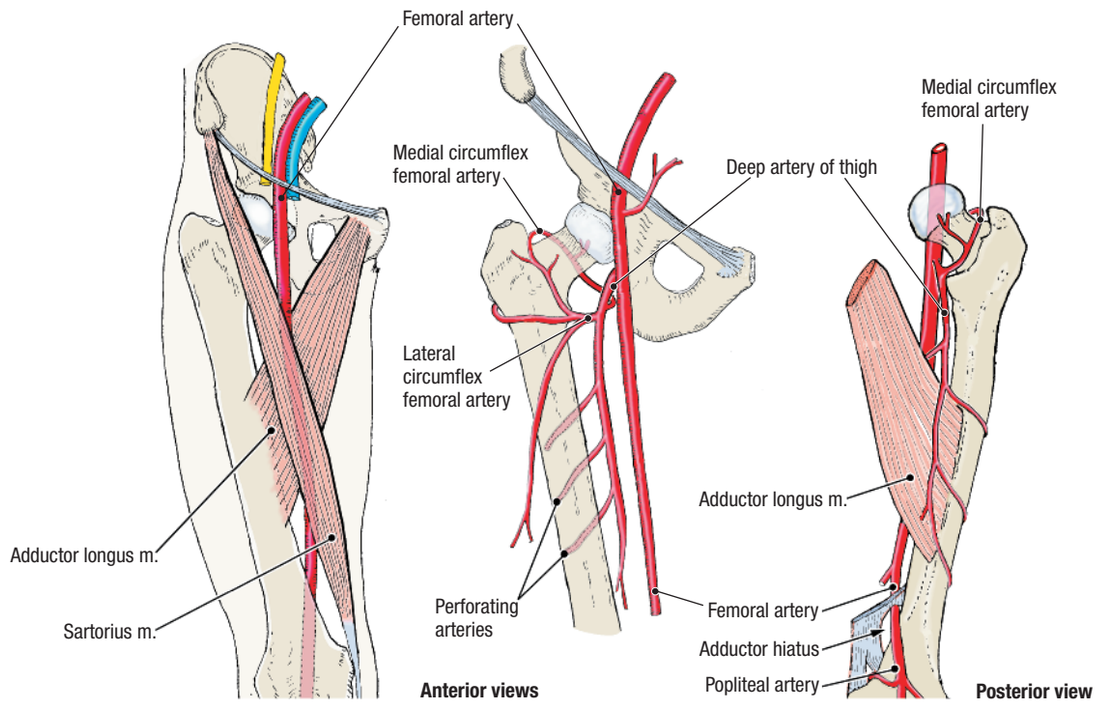

Figure 6.09. Arteries of the thigh.

ment is the pectineal line of the femur. The pectineus muscle adducts and flexes the thigh.

12. Use blunt dissection to expose the **femoral nerve**, which lies on the lateral side of the femoral artery (Fig. 6.08). Follow the femoral nerve inferiorly and observe that it divides into numerous branches. The femoral nerve innervates the anterior thigh muscles and the skin of the anterior thigh. Its motor branches will be identified later.
13. Verify that the **anterior cutaneous branches of the femoral nerve** enter the superficial fascia by penetrating the fascia lata along the anterior surface of the sartorius muscle (Fig. 6.03).

ADDUCTOR CANAL [G 364; N 482; R 464; C 321]

1. The **adductor canal** begins at the **apex of the femoral triangle** and ends at the **adductor hiatus**, which is an opening in the tendon of the adductor magnus muscle located just above the knee (Fig. 6.09C). The femoral vessels pass through the adductor canal to reach the popliteal fossa.
2. Use scissors to cut the fascia lata along the superficial surface of the sartorius muscle. The cut should extend from the anterior superior iliac spine to the medial epicondyle of the femur.
3. Use your fingers to separate the **sartorius muscle** from the deep fascia that is posterior to it. The proximal attachment of the sartorius muscle is the anterior superior iliac spine and its distal attachment is the medial surface of the proximal tibia. Observe that the sartorius muscle crosses both the hip joint and the knee joint. It flexes and laterally rotates the thigh, and flexes the leg.
4. Transect the sartorius muscle near the apex of the femoral triangle. Reflect the distal part of the sartorius muscle inferiorly. The adductor canal is now exposed deep to the inferior part of the sartorius muscle.
5. Examine the femoral vessels within the adductor canal. Observe that the **femoral vein** lies posterior to the **femoral artery**. Follow the femoral artery distally through the adductor hiatus, where its name changes to **popliteal artery** (Fig. 6.09C).
6. The **nerve to vastus medialis** and the **saphenous nerve** accompany the femoral vessels in the adductor canal. The saphenous nerve innervates the skin of the medial side of the leg, ankle, and foot.

QUADRICEPS FEMORIS MUSCLE [G 358, 364; N 483; R 465; C 322]

1. Use scissors to make a vertical cut through the fascia lata between the apex of the femoral triangle and the patella. Make a transverse incision in the fascia lata above the patella. Open the fascia lata widely.
2. Use your fingers to follow the inner surface of the fascia lata laterally. Here, the fascia lata is continuous with the **lateral intermuscular septum** (Fig. 6.10). The lateral intermuscular septum is attached to the **linea aspera** on the posterior aspect of the femur.

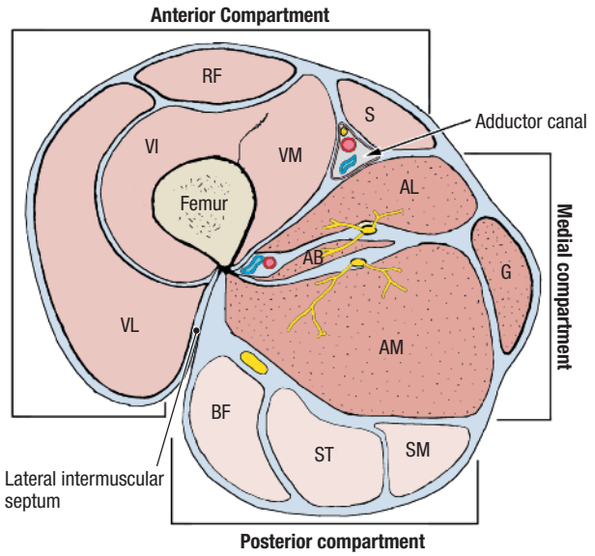

Figure 6.10. Transverse section through the right thigh, inferior view. Anterior compartment: **VI**, vastus intermedius; **VL**, vastus lateralis; **VM**, vastus medialis; **RF**, rectus femoris; **S**, sartorius; Medial compartment: **AB**, adductor brevis; **AL**, adductor longus; **AM**, adductor magnus; **G**, gracilis; Posterior compartment: **BF**, biceps femoris; **ST**, semitendinosus; **SM**, semimembranosus.

3. The **quadriceps femoris muscle** occupies most of the anterior compartment of the thigh (Fig. 6.10). The four parts of the quadriceps femoris muscle are the rectus femoris, vastus lateralis, vastus intermedius, and vastus medialis. The tendons of all four muscles unite to form the **quadriceps femoris tendon**. The quadriceps femoris tendon is attached to the patella. The **patellar ligament** attaches the patella to the tibial tuberosity, so the ultimate attachment of the quadriceps femoris muscle is the tibial tuberosity (Fig. 6.11).

CLINICAL CORRELATION

Patellar Tendon (Quadriceps) Reflex

Tapping the patellar ligament stimulates the patellar reflex (quadriceps reflex; knee jerk). Tapping activates muscle spindles in the quadriceps femoris muscle, and afferent impulses travel in the femoral nerve to spinal segments L2, L3, and L4. Efferent impulses are then carried by the femoral nerve to the quadriceps femoris muscle, resulting in a brief contraction. The patellar tendon reflex tests the function of the femoral nerve, and spinal cord segments L2-L4.

4. Identify the **rectus femoris muscle** in the midline of the anterior thigh. The proximal attachment of the rectus femoris muscle is the anterior inferior iliac spine and its distal attachment is the tibial tuberosity. The rectus femoris muscle crosses both the hip joint and the knee joint. It flexes the thigh and extends the leg.
5. Identify the **vastus lateralis muscle** on the lateral side of the anterior thigh (Fig. 6.11). The proximal attachments of the vastus lateralis muscle are the lateral lip

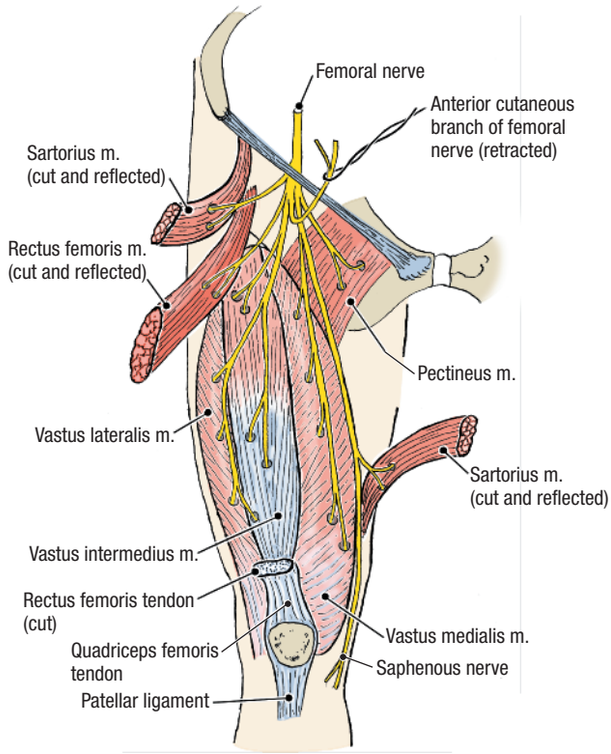

Figure 6.11. Branches of the femoral nerve.

of the linea aspera and greater trochanter of the femur. The distal attachment of the vastus lateralis muscle is the tibial tuberosity, and it extends the leg.

6. Identify the **vastus medialis muscle** on the medial side of the anterior thigh. The proximal attachments of the vastus medialis muscle are the medial lip of the linea aspera of the femur and the intertrochanteric line. The distal attachment of the vastus medialis muscle is the tibial tuberosity and it extends the leg.
7. Expose the **vastus intermedius muscle** by retracting the rectus femoris muscle to one side. The proximal attachments of the vastus intermedius muscle are the anterior and lateral surfaces of the femur (Fig. 6.10). The distal attachment of the vastus intermedius muscle is the tibial tuberosity and it extends the leg.
8. Identify the **motor branches of the femoral nerve** to the anterior thigh muscles (Fig. 6.11). The motor branches of the femoral nerve are located between the rectus femoris muscle and the vastus muscles. Note that the femoral nerve innervates the sartorius muscle and the pectineus muscle in addition to innervating the quadriceps femoris muscle.

After you dissect . . .

Replace the anterior thigh muscles in their correct anatomical positions. Use the dissected specimen to review the boundaries and contents of the femoral triangle. Review the origin and course of the femoral artery and its branches in the thigh. Use the dissected specimen to review the attachments and actions of the muscles of the anterior compartment of the thigh. Recall the rule of innervation of the anterior compartment of the thigh: **All muscles in the anterior compartment of the thigh are innervated by the femoral nerve.**

MEDIAL COMPARTMENT OF THE THIGH [G 360; N 483; R 465; C 324]

Before you dissect . . .

The medial compartment of the thigh contains five muscles: adductor magnus, adductor longus, adductor brevis, gracilis, and obturator externus. The shared function of this group of muscles is to adduct the thigh. Therefore, they are also known as the adductor group of thigh muscles.

The order of dissection will be as follows: The fascia lata will be removed from the medial thigh. The gracilis muscle will be studied. The adductor muscles will be dissected by following the medial circumflex femoral artery, the deep artery of the thigh, and the branches of the obturator nerve.

Dissection Instructions

1. On the medial aspect of the thigh, use your hands to separate the fascia lata from the muscles of the medial compartment. Begin at the medial border of the femoral triangle and work medially. Be careful not to remove the gracilis muscle. Use scissors to cut the fascia lata and remove it.
2. Identify the **gracilis muscle**. With your fingers, follow the gracilis muscle to its inferior attachment on the medial condyle of the tibia. The gracilis muscle crosses both the hip and knee joints. It adducts the thigh and assists in flexion of the leg.
3. Use an illustration to observe the proximal attachments of the **pectineus muscle**, **adductor longus muscle**, and **gracilis muscle** along a curved line on the pubic bone. [G 362; N 472; R 439; C 374]
4. Observe the anterior surface of the **pectineus** and **adductor longus muscles**. They fan out to their distal attach on the linea aspera of the femur. Both muscles are adductors of the thigh.
5. Note that the **deep artery of the thigh** passes between the pectineus and adductor longus muscles. Follow the deep artery of the thigh between the pectineus and adductor longus muscles and use blunt dissection to define the muscle borders.
6. Follow the deep artery of the thigh posterior to the adductor longus muscle to separate the adductor longus muscle from the adductor brevis muscle. Transect the adductor longus muscle 5 cm inferior to its proximal attachment and reflect it (Fig. 6.12).
7. Clean the deep artery of the thigh and identify one or two **perforating arteries**. Perforating arteries penetrate the adductor brevis muscle, encircle the femur, and supply the muscles of the medial and posterior compartments of the thigh.
8. The **adductor brevis muscle** can now be seen at a deeper plane. The proximal attachments of the adductor brevis muscle are the body and inferior ramus of the pubis and its distal attachments are the pectineal line and linea aspera of the femur. The adductor brevis muscle adducts the thigh.

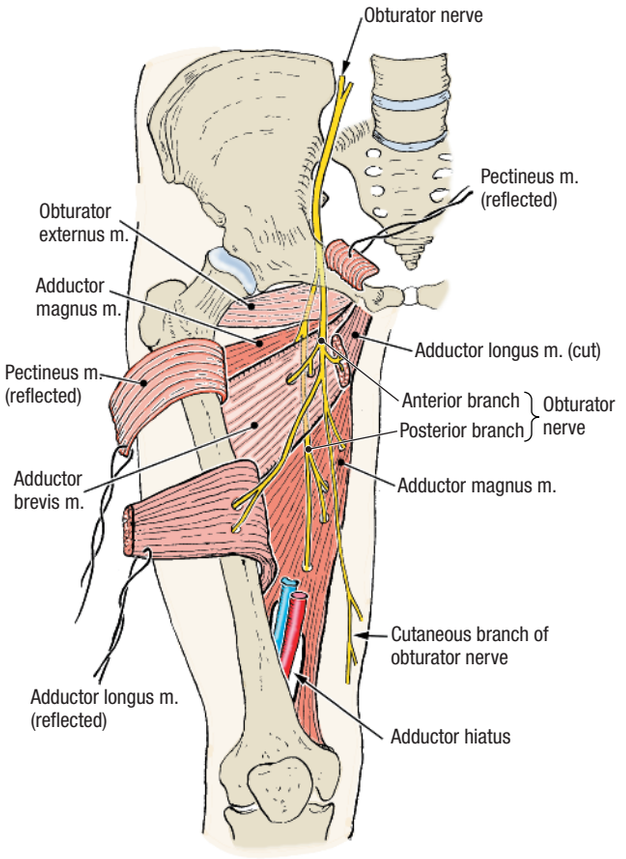

Figure 6.12. How to dissect the adductor brevis muscle using the branches of the obturator nerve.

9. Refer to Figure 6.12 and note that the **anterior branches of the obturator nerve** cross the anterior surface of the adductor brevis muscle and the **posterior branches of the obturator nerve** cross its posterior surface.
10. Follow the anterior branch of the obturator nerve proximally to separate the pectineus muscle from the adductor brevis muscle. Transect the pectineus muscle about 5 cm inferior to its proximal attachment and reflect it (Fig. 6.12). Note that the superior border of the adductor brevis muscle is deep to the pectineus muscle. Use blunt dissection to clean the adductor brevis. Do not damage the anterior branches of the obturator nerve.
11. The posterior branches of the obturator nerve pass between the adductor brevis muscle and **adductor magnus muscle**. Use blunt dissection to follow the posterior branch of the obturator nerve proximally to separate the adductor brevis muscle from the adductor magnus muscle.
12. Raise the adductor brevis muscle and observe the **adductor magnus muscle**. The proximal attachments of the adductor magnus muscle are the ischiopubic ramus and the ischial tuberosity, and its distal attachments are the gluteal tuberosity, linea aspera, medial supracondylar line, and adductor tubercle of the femur. The adductor magnus muscle adducts and extends the thigh.
13. Trace the adductor magnus tendon to the **adductor tubercle** on the medial epicondyle of the femur. Observe the **adductor hiatus** in the adductor magnus tendon. Note that femoral artery and vein pass from the anterior compartment of the thigh to the posterior compartment of the thigh through the adductor hiatus.
14. Study an illustration of the **obturator externus muscle**. Do not attempt to dissect this muscle, as it lies deep to the pectineus muscle and iliopsoas tendon. The obturator externus muscle is a lateral rotator of the thigh. **[G 376; N 483; C 323]**

After you dissect . . .

Replace the medial thigh muscles in their correct anatomical positions. Use the dissected specimen to review the attachments and action of each muscle dissected. Trace the deep artery of the thigh from its origin to its termination as the 4th perforating artery. Trace the medial femoral circumflex artery from its origin to where it disappears between the iliopsoas and pectineus muscles. Trace the course of the anterior and posterior branches of the obturator nerve. Recall the rule for innervation of the medial thigh muscles: **The obturator nerve innervates the muscles of the medial compartment of the thigh**. Note that the pectineus muscle may receive a motor contribution from the obturator nerve in addition to its innervation by the femoral nerve.

GLUTEAL REGION

Before you dissect . . .

The gluteal region (Gr. *gloutos*, buttock) lies on the posterior aspect of the pelvis. It is the most superior part of the lower limb. If you have already dissected the pelvis and perineum, the gluteus maximus has been reflected so that the blood supply to the perineal region could be traced.

The order of dissection will be as follows: The borders of the gluteus maximus muscle will be defined and it will be reflected to expose the muscles that lie deep to it. Arteries and nerves in the region will be studied. The greater and lesser sciatic foramina and the piriformis muscle will be key structures in understanding the relationships of this region.

SKELETON OF THE GLUTEAL REGION

Refer to a skeleton and a drawing of an articulated pelvis with intact ligaments. On the pelvis, identify (Fig. 6.13): **[G 363; N 468; R 423; C 249]**

- **Gluteal lines (posterior, anterior, inferior)**
- **Greater sciatic notch**
- **Greater sciatic foramen**
- **Ischial spine**
- **Lesser sciatic notch**
- **Lesser sciatic foramen**
- **Ischial tuberosity**
- **Sacrotuberous ligament**
- **Sacrospinous ligament**

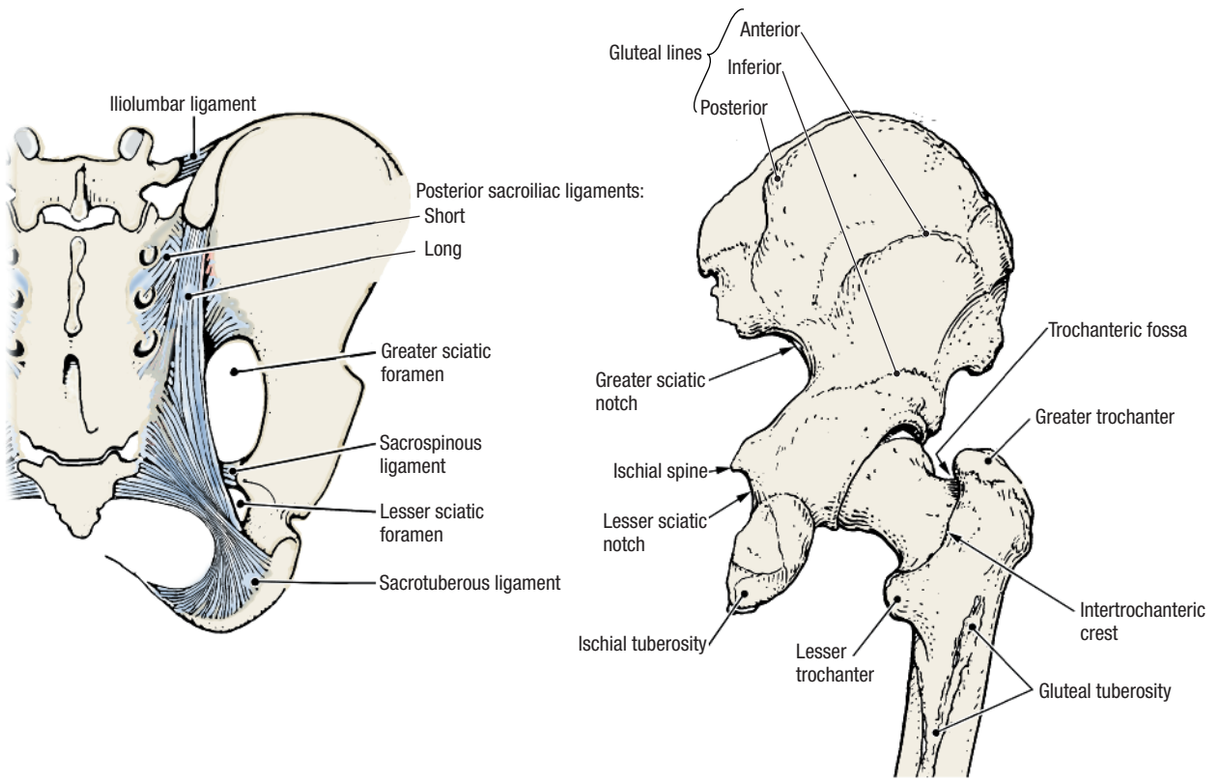

Figure 6.13. Skeleton of the gluteal region.

On the femur, identify (Fig. 6.13): **[G 363; N 471; R 425; C 375]**

- **Greater trochanter**
- **Intertrochanteric crest**
- **Trochanteric fossa**
- **Gluteal tuberosity**

Dissection Instructions

1. Place the cadaver in the prone position. If the pelvis and perineum have been dissected previously, go to step 8.
2. Remove the superficial fascia from the surface of the gluteal region.
3. Identify the **gluteus maximus muscle** (Fig. 6.14). The proximal attachment of the gluteus maximus muscle is the ilium, sacrum, coccyx, and sacrotuberous ligament. The distal attachment of the gluteus maximus muscle is the iliotibial tract, and through it, the lateral condyle of the tibia. A small part of the gluteus maximus muscle attaches the gluteal tuberosity of the femur. The gluteus maximus muscle is a powerful extensor of the thigh. **[G 366; N 477; R 440; C 329]**
4. Remove the fascia lata from the surface of the gluteus maximus muscle. The fascia lata is relatively thin at this location.
5. The **gluteal aponeurosis** is a thickening of the fascia lata that spans from the iliac crest to the superior border of the gluteus maximus muscle. Use your fingers to define the superior border of the gluteus maximus muscle and separate it from the gluteal aponeurosis.
6. Use blunt dissection to define the inferior border of the gluteus maximus muscle.
7. Use scissors to detach the gluteus maximus from its proximal attachment. Start at the superior border of the muscle and cut the gluteus maximus close to the ilium, sacrum, and sacrotuberous ligament.

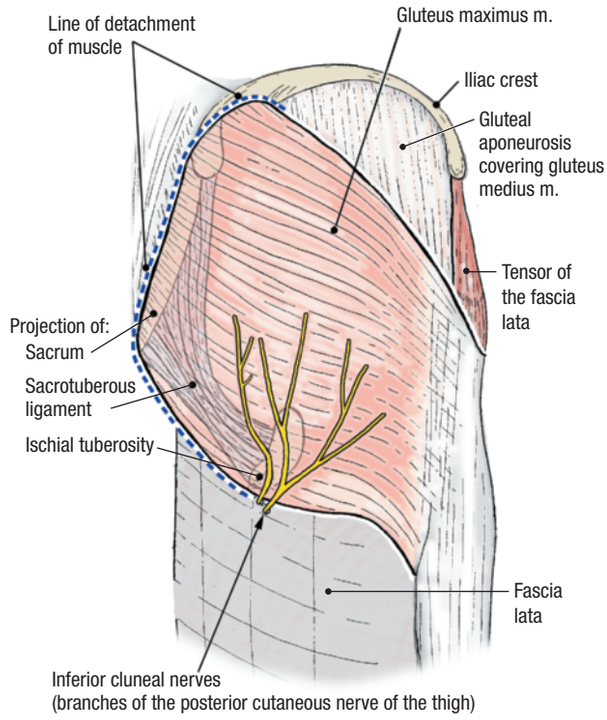

Figure 6.14. Muscles of the gluteal region, superficial dissection.

8. Insert your fingers deep to the gluteus maximus muscle and palpate the **inferior gluteal artery**, **vein**, and **nerve**. The inferior gluteal nerve is the only nerve supply to the gluteus maximus muscle.
9. Use scissors to cut the inferior gluteal vessels and nerve and reflect the gluteus maximus muscle laterally. Leave the distal attachment of the gluteus maximus muscle intact. The deeper structures of the gluteal region are now exposed (Fig. 6.15). **[G 368, 371; N 477; R 440; C 330]**
10. Use a scalpel to incise the gluteal aponeurosis along the iliac crest. Use skinning motions to remove the gluteal aponeurosis from the gluteus medius muscle.
11. The proximal attachment of the **gluteus medius muscle** is the deep surface of the gluteal aponeurosis and the lateral surface of the ilium between the **posterior gluteal line** and the **anterior gluteal line**. The distal attachment of the gluteus medius muscle is the greater trochanter of the femur and it is an abductor of the thigh.
12. The **piriformis muscle** is located inferior to the gluteus medius muscle. The proximal attachment of the piriformis muscle is the anterior surface of the sacrum and its distal attachment is the greater trochanter of the femur. The piriformis muscle is a lateral rotator of the thigh. Verify that the piriformis muscle passes through the greater sciatic foramen.
13. Use a probe to define the superior border of the piriformis muscle. Note that the **superior gluteal artery**, **vein**, and **nerve** pass between the piriformis muscle and the gluteus medius muscle.
14. Clean the inferior border of the piriformis muscle. Note that the **sciatic nerve, posterior cutaneous nerve of the thigh**, **inferior gluteal vessels**, **inferior gluteal nerve**, **pudendal nerve**, and **internal pudendal vessels** all appear at the inferior border of the piriformis muscle.
15. Identify the **sciatic nerve** (Fig. 6.15). The sciatic nerve is the largest nerve in the body and it has a **tibial division** and a **common fibular division**. The divisions may emerge separately through the piriformis muscle. Use scissors to make a vertical cut (6 or 7 cm in length) through the posterior surface of the fascia lata and use your fingers to trace the sciatic nerve into the thigh.
16. Identify the **posterior cutaneous nerve of the thigh**, which lies on the medial side of the sciatic nerve (Fig. 6.15).
17. Identify the cut ends of the **inferior gluteal vessels** and **nerve** (Fig. 6.15).
18. Identify the **pudendal nerve** and **the internal pudendal artery** and **vein** near the medial end of the inferior border of the piriformis muscle (Fig. 6.15). The pudendal nerve and internal pudendal vessels enter

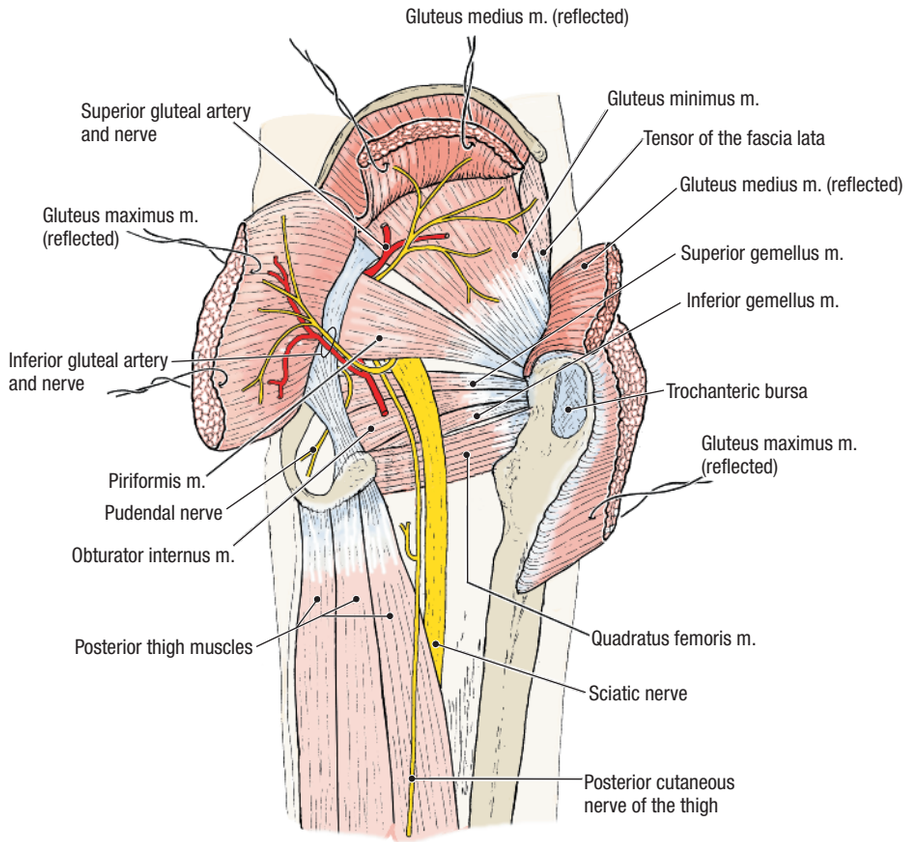

Figure 6.15. Muscles of the gluteal region, deep dissection. The gluteus maximus and gluteus medius muscles have been reflected.

the gluteal region by passing through the greater sciatic foramen and enter the perineum by passing through lesser sciatic foramen. The pudendal nerve and internal pudendal vessels supply the anal and urogenital triangles.

19. Identify the tendon of the **obturator internus muscle** (Fig. 6.15). The obturator internus muscle is inferior to the piriformis muscle. The proximal attachment of the obturator internus muscle is the margin of the obturator foramen and the inner surface of the obturator membrane. The distal attachment of the obturator internus muscle is the trochanteric fossa on the medial side of the greater trochanter of the femur. The obturator internus muscle is a lateral rotator of the thigh. The obturator internus muscle exits the lesser pelvis by passing through the lesser sciatic foramen.
20. Identify the two **gemellus muscles** (L. *gemellus*; twin) (Fig. 6.15). The proximal attachment of the **superior gemellus muscle** is the ischial spine superior to the obturator internus muscle. The proximal attachment of the **inferior gemellus muscle** is the ischial tuberosity inferior to the obturator internus muscle. Both gemellus muscles attach with the obturator internus muscle on the greater trochanter of the femur and both are lateral rotators of the thigh.
21. Identify the **quadratus femoris muscle** (Fig. 6.15), which is inferior to the inferior gemellus muscle. The proximal attachment of the quadratus femoris muscle is the ischial tuberosity and its distal attachment is the intertrochanteric crest of the femur. The quadratus femoris muscle is a lateral rotator of the thigh.
22. Locate the branches of the **superior gluteal vessels** superior to the piriformis muscle (Fig. 6.15). Use your fingers to follow these vessels deep to the gluteus medius muscle. Your fingers are in the plane between the gluteus medius muscle and the **gluteus minimus muscle**.
23. Use scissors to transect the gluteus medius muscle, following the course of the superior gluteal vessels. Gently reflect the proximal portion of the muscle superiorly and observe the **superior gluteal nerve**.
24. Reflect the distal part of the gluteus medius muscle and identify the **gluteus minimus muscle** (Fig. 6.15). The proximal attachment of the gluteus minimus muscle is the lateral surface of the ilium between the anterior gluteal line and the inferior gluteal line. The distal attachment of the gluteus minimus muscle is on the greater trochanter of the femur and it abducts the thigh.
25. Identify the **tensor of the fascia lata (tensor fasciae latae muscle)**. It is within the fascia lata inferior to the anterior superior iliac spine (Fig. 6.15). The proximal attachment of the tensor of the fascia lata is the anterior superior iliac spine and its distal attachment is the **iliotibial tract**. The tensor of the fascia lata is an abductor and medial rotator of the thigh.

CLINICAL CORRELATION

Intragluteal Injections

The gluteal region is commonly used for intramuscular injections. These injections are made in the **superior lateral quadrant of the gluteal region**. Injections into the two inferior quadrants of the gluteal region would endanger the sciatic nerve, or the nerves and vessels that pass inferior to the piriformis muscle. Injections into the superior medial quadrant may injure the superior gluteal nerve and vessels. Intragluteal injections into the superior lateral quadrant are relatively safe since the superior gluteal nerve and vessels are well ramified in this region.

After you dissect . . .

Replace the muscles of the gluteal region in their correct anatomical positions. Review the attachments, action, and innervation of each muscle. Study the functions of muscles in the gluteal region. Extend your thigh. This movement is accomplished by the gluteus maximus muscle. Abduct your thigh. This movement is accomplished by the gluteus medius muscle, gluteus minimus muscle, and tensor of the fascia lata. Laterally rotate your thigh. This motion is accomplished by the piriformis muscle, obturator internus muscle, superior gemellus muscle, inferior gemellus muscle, and quadratus femoris muscle. Review the anatomy of the safe intragluteal injection site.

If you have completed the dissection of the pelvis and perineum prior to dissection of the lower limb, study the continuity of muscles, vessels, and nerves observed in the gluteal and pelvic regions. Within the lesser pelvis identify the obturator internus muscle and follow the muscle posteriorly into the gluteal region. Within the pelvis, identify the piriformis muscle then follow this muscle laterally to the greater trochanter of the femur. Within the pelvis, study the gluteal vessels and their relationship to the piriformis muscle and the sacral plexus. Review the sacral plexus and its contribution to the sciatic nerve. Note that the muscles of the gluteal region are innervated by branches of the sacral nerve plexus.

POSTERIOR COMPARTMENT OF THE THIGH

Before you dissect . . .

The posterior compartment of the thigh contains the posterior thigh muscles: biceps femoris, semimembranosus, and semitendinosus. The muscles of the posterior group extend the thigh and flex the leg. The posterior thigh muscles are commonly known as the “hamstring” muscles.

The order of dissection will be as follows: The muscles of the posterior compartment of the thigh will be studied. The course and branches of the sciatic nerve will be studied. The dissection will be extended into the popliteal fossa. The muscular boundaries of the popliteal fossa will be identified and the contents of the popliteal fossa will be studied.

SKELETON OF THE POSTERIOR THIGH

Refer to a skeleton. On the pelvis, identify (Fig. 6.06B): **[G 363; N 468; R 424; C 249]**

- **Ischial tuberosity**

On the femur, identify: **[G 363; N 471; R 425; C 375]**

- **Lateral lip of linea aspera**
- **Lateral supracondylar line**
- **Medial condyle**
- **Lateral condyle**
- **Popliteal surface**

On the fibula, identify: **[G 363; N 495; R 426; C 389]**

- **Apex**
- **Head**
- **Neck**

On the tibia, identify:

- **Medial condyle**
- **Soleal line**

Dissection Instructions

POSTERIOR THIGH [G 367, 369; N 477; R 469; C 334-337]

1. Place the cadaver in the prone position. Incise the fascia lata from the superior thigh to the knee and open it widely.
2. Use blunt dissection to clean the **sciatic nerve** and follow it inferiorly. The sciatic nerve passes deep to the long head of the biceps femoris muscle (Fig. 6.16).
3. Identify the **long head of the biceps femoris muscle**. The proximal attachment of the long head of the biceps femoris muscle is the ischial tuberosity and its distal attachment is the head of the fibula.
4. Retract the long head of the biceps femoris muscle laterally to observe the **short head of the biceps femoris muscle** (Fig. 6.16). The proximal attachment of the short head of the biceps femoris muscle is the lateral lip of the linea aspera of the femur. The tendon of the short head of the biceps femoris muscle joins the tendon of the long head. The biceps femoris muscle extends the thigh and flexes the leg.
5. On the medial side of the thigh, identify the **semitendinosus muscle** ("half tendon") (Fig. 6.16). The proximal attachment of the semitendinosus muscle is the ischial tuberosity and its distal attachment is the medial surface of the superior part of the tibia. The semitendinosus muscle extends the thigh and flexes the leg.
6. Use your fingers to separate the semitendinosus muscle from the **semimembranosus muscle** ("half membrane"). The proximal attachment of the semimembranosus muscle is the ischial tuberosity and its distal attachment is the posterior part of the medial condyle of the tibia. The semimembranosus muscle extends the thigh and flexes the leg.
7. Verify that the **hamstring part of the adductor magnus muscle** arises from the ischial tuberosity deep to the proximal attachment of the posterior thigh muscles. Confirm that the adductor magnus muscle forms the deep boundary of the posterior compartment of the thigh (Fig. 6.16). The hamstring part of the adductor magnus muscle is innervated by the sciatic nerve.
8. Follow the sciatic nerve through the posterior compartment of the thigh to the area behind the knee. The sciatic nerve gives off unnamed muscular branches to the posterior thigh muscles. The sciatic nerve typically divides at the level of the knee, but this division may occur more superiorly in the thigh, or in the gluteal region (Fig. 6.16).

CLINICAL CORRELATION

Sciatic Nerve

The sciatic nerve and its branches innervate the posterior muscles of the thigh and the muscles of the leg (which act on the foot). The cutaneous branches of the sciatic nerve innervate a large area of the lower limb. Thus, when the sciatic nerve is injured, significant peripheral neurological deficits may occur: Paralysis of the flexors of the knee and all muscles below the knee, and widespread numbness of the skin of the posterior aspect of the lower limb.

POPLITEAL FOSSA [G 384-386; N 484; R 471, 472; C 338-340]

1. Define the **borders of the popliteal fossa**:
   - **Superolateral** – biceps femoris muscle
   - **Superomedial** – semitendinosus and semimembranosus muscles
   - **Inferolateral and inferomedial** – the two heads of the gastrocnemius muscle
   - **Posterior** – skin and deep fascia
   - **Anterior** – popliteal surface of the femur and the popliteus muscle
2. At the superior border of the popliteal fossa, the sciatic nerve divides into the **tibial** and **common fibular (peroneal) nerves** (Fig. 6.16).
3. Use a probe to follow the **common fibular nerve** along the superolateral border of the popliteal fossa. Note that the common fibular nerve parallels the biceps femoris tendon and passes superficial to the lateral head of the gastrocnemius muscle.
4. Remove the remnants of the deep fascia (popliteal fascia) to expose the medial and lateral heads of the gastrocnemius muscle. Use your fingers to follow the **tibial nerve** inferiorly. The tibial nerve bisects the popliteal fossa and passes deep to the gastrocnemius muscle at the inferior border of the popliteal fossa (Fig. 6.16).

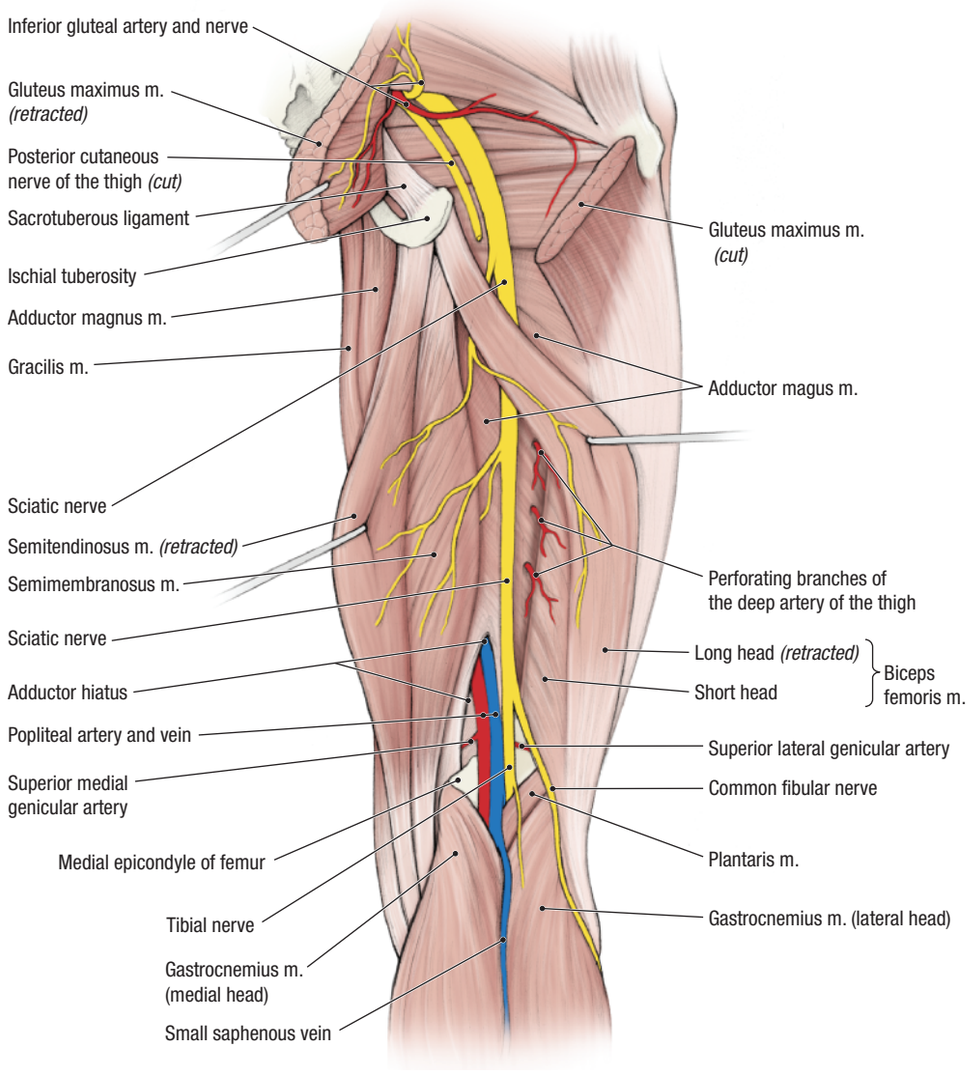

Figure 6.16. Contents of the posterior compartment of the thigh and popliteal fossa.

5. At the inferior border of the popliteal fossa, insert your index fingers between the two bellies of the gastrocnemius muscle. Pull the muscle bellies apart for a distance of 5 to 10 cm. This will expose the structures that pass from the popliteal fossa into the leg.
6. The **popliteal artery** and **vein** are located deep to the tibial division of the sciatic nerve. Note that the popliteal artery and vein are enclosed by a common connective tissue sheath. Use scissors to open the sheath. Extend the incision superiorly and inferiorly.
7. Use a probe to separate the popliteal artery from the popliteal vein. Preserve the popliteal vein but remove its tributaries to clear the dissection field.
8. Use an illustration to study the arterial anastomoses around the knee joint (Fig. 6.17). Identify the **superior lateral genicular artery** and the **superior medial genicular artery**. These arteries are located deep in the popliteal fossa, proximal to the attachments of the gastrocnemius muscle. **[G 398; N 500; R 453; C 340]**
9. Distally, the popliteal artery passes deep to the gastrocnemius muscle (Fig. 6.16). Retract the popliteal artery posteriorly and identify the **inferior lateral genicular artery** and the **inferior medial genicular artery**. The inferior genicular arteries pass between the proximal attachments of the gastrocnemius muscle and the tibia.
10. Part of the floor of the popliteal fossa is formed by the **popliteus muscle** (Fig. 6.17). Retract the inferior end of the popliteal artery and vein and find the popliteus muscle. It will be seen better when the posterior muscles of the leg are dissected.
11. At the medial side of the knee, observe that the **sartorius**, **gracilis**, and **semitendinosus tendons** converge on the proximal end of the tibia in an arrangement that is named the **pes anserinus** (L., goose's foot).

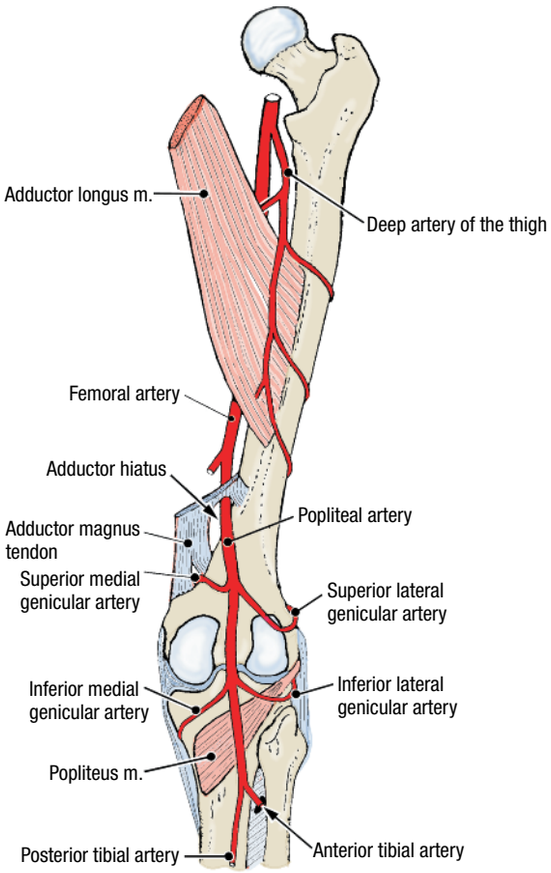

Figure 6.17. Popliteal artery and genicular arteries in the popliteal fossa.

After you dissect . . .

Replace the muscles of the posterior compartment of the thigh into their correct anatomical positions. Using the dissected specimen, review the attachments and actions of the posterior thigh muscles. Trace the course of the sciatic nerve from the pelvis to the knee. Review its terminal branches. Trace the femoral artery and vein from the level of the inguinal ligament to the popliteal fossa, naming its branches. Review the course of the deep artery of the thigh through the medial compartment of the thigh. Review the course of its perforating vessels through the adductor magnus muscle into the posterior compartment of the thigh. Review the anastomotic blood supply around the knee.

Review the principal muscle groups of the thigh and the innervation of each muscle group (Fig. 6.18). Recall the rules for innervation of the thigh muscles: **The anterior thigh muscles are innervated by the femoral nerve. The medial thigh muscles are innervated by the obturator nerve. The posterior thigh muscles are innervated by the sciatic nerve.**

LEG AND DORSUM OF THE FOOT

The two bones of the leg are unequal in size. The larger **tibia** is the weight-bearing bone of the leg. The **fibula** is surrounded by muscles except at its proximal and distal ends. The tibia and fibula are joined by an **interosseous membrane** (Fig. 6.19). The **deep fascia of the leg (crural fascia)** is attached to the fibula by two **intermuscular septa**: **anterior** and **posterior**. The tibia, fibula, interosseous membrane, and the intermuscular septa divide the leg into **three compartments: anterior**, **lateral (fibular)**, and **posterior** (Fig. 6.19). **[G 345; N 504; C 344]**

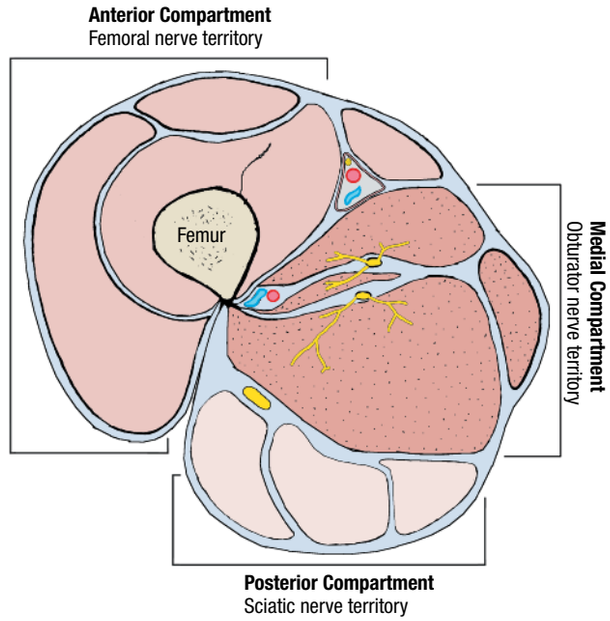

Figure 6.18. Motor nerve territories of the thigh.

Skeleton of the Leg

Refer to a skeleton. On the tibia, identify (Fig. 6.20): **[G 405; N 495; R 426; C 389]**

- **Medial condyle**
- **Lateral condyle**
- **Shaft (body)**
- **Anterior border**
- **Medial malleolus**
- **Soleal line**

On the fibula, identify (Fig. 6.20):

- **Head**
- **Neck**
- **Shaft (body)**
- **Lateral malleolus**

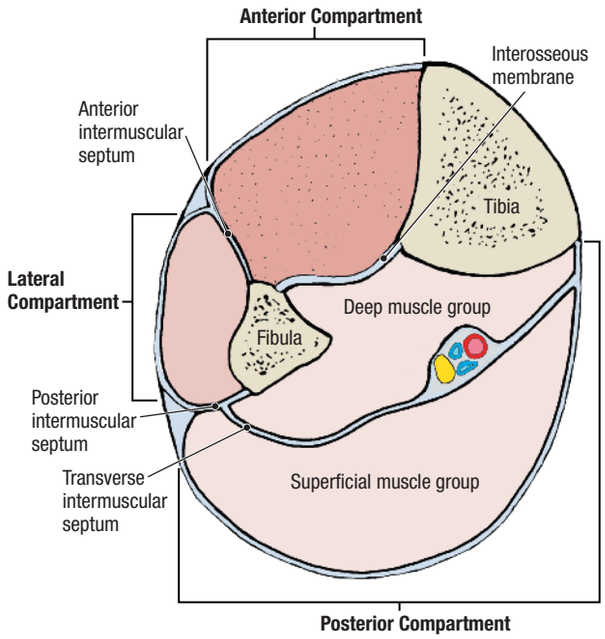

Figure 6.19. Compartments of the right leg, inferior view.

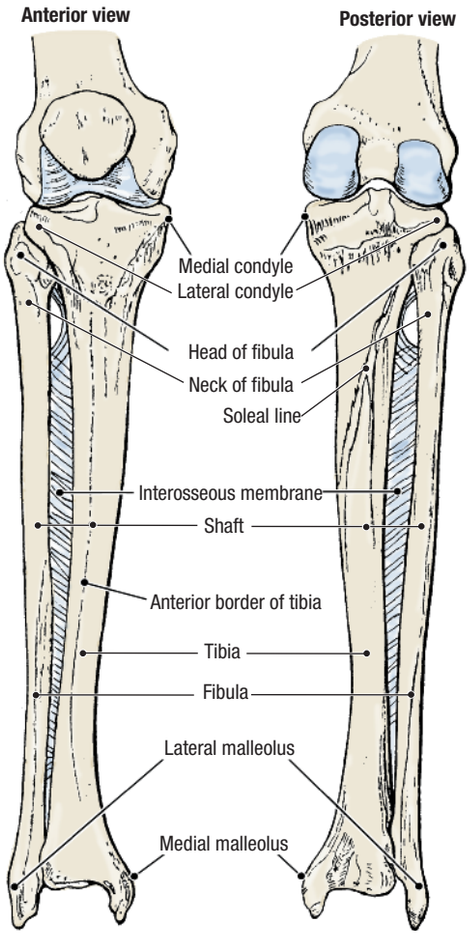

Figure 6.20. Skeleton of the leg.

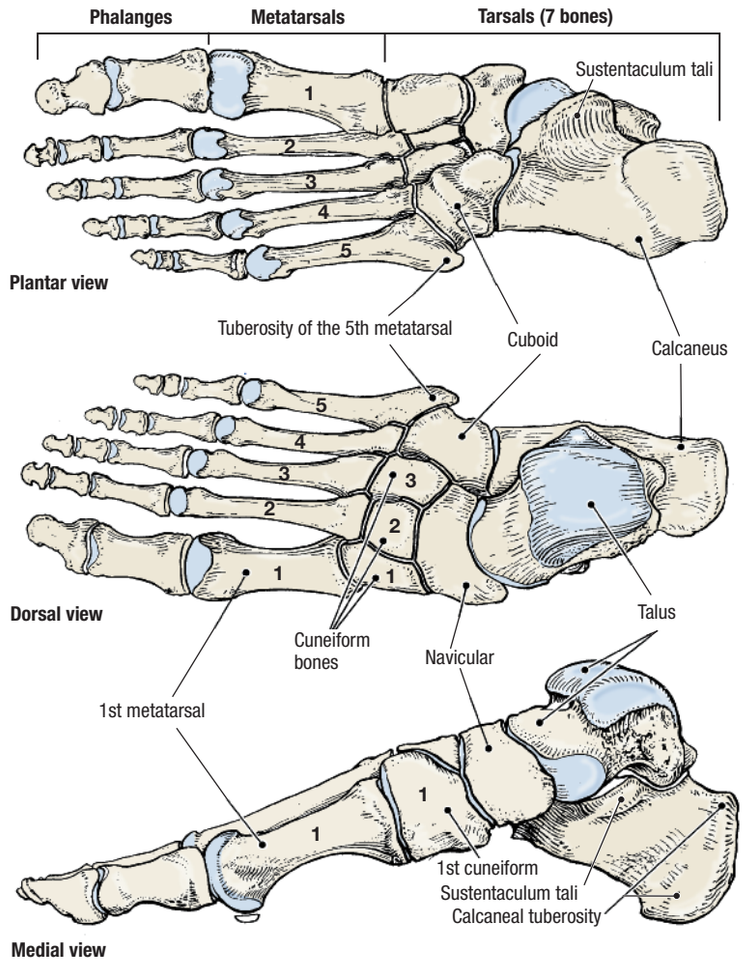

Figure 6.21. Skeleton of the foot.

In the articulated foot, identify the seven tarsal bones (Fig. 6.21): **[G 426; N 505; R 428; C 390, 391]**

- **Talus**
- **Calcaneus**
- **Navicular**
- **Cuboid**
- **Three cuneiform bones**—1st (medial), 2nd (intermediate, middle), and 3rd (lateral)

On the **calcaneus**, identify (Fig. 6.21):

- **Calcaneal tuberosity**
- **Sustentaculum tali**

Identify the **five metatarsal bones** and the **tuberosity of the 5th metatarsal bone**.

Identify **14 phalanges**. Note that the first toe has only two phalanges, whereas the other toes each have three phalanges.

ANTERIOR COMPARTMENT OF THE LEG AND DORSUM OF THE FOOT **[G 404, 405; N 501, 502; R 448; C 343, 346]**

Before you dissect . . .

The **anterior compartment** of the leg contains four muscles: tibialis anterior, extensor hallucis longus, extensor digitorum longus, and fibularis (peroneus) tertius. The deep fibular (peroneal) nerve innervates the muscles of the anterior compartment. The group actions of the muscles in the anterior compartment are dorsiflexion of the foot, inversion of the foot, and extension of the toes.

Dissection Instructions

1. Place the cadaver in the supine position.
2. Observe that the deep fascia of the leg is firmly attached to the anterior border of the tibia.
3. Identify the **superior and inferior extensor retinacula** on the anterior surface of the ankle (Fig. 6.22). The retinacula are transverse thickenings of the deep fascia of the leg that hold tendons in place. The superior extensor retinaculum extends across the tendons superior to the ankle joint. The inferior extensor retinaculum is at the level of the ankle joint and it is Y-shaped. The stem of this Y is attached to the calcaneus.
4. Use a scalpel to make a vertical cut through the deep fascia of the leg just below the lateral condyle of the tibia. Use forceps to lift the edges of the deep fascia and observe that the muscles of the anterior compartment are attached to its deep surface. Open the deep fascia of the leg in the distal direction as far as the inferior extensor retinaculum.

5. The proximal attachments of the anterior muscles of the leg are on the proximal tibia, fibula, and interosseous membrane. Do not attempt to dissect the proximal attachments.
6. Observe that vessels, nerves, and the tendons of the anterior muscles of the leg cross the anterior surface of the ankle joint. From medial to lateral, identify (Fig. 6.22):
   - **Tibialis anterior tendon**
   - **Extensor hallucis longus tendon**
   - **Deep fibular (peroneal) nerve**
   - **Anterior tibial vessels**
   - **Extensor digitorum longus tendon**
   - **Fibularis tertius tendon**
7. Follow the tendon of the **tibialis anterior muscle** into the foot. Observe that the distal attachment of the tibialis anterior tendon is the first cuneiform bone and the base of the first metatarsal bone. The tibialis anterior muscle dorsiflexes and inverts the foot.
8. Follow the tendon of the **extensor hallucis longus muscle** into the foot. Observe that the distal attachment of the extensor hallucis longus tendon is the base of the distal phalanx of the great toe (L., *hallux*, great toe). The extensor hallucis longus muscle extends the great toe and dorsiflexes the foot.
9. Observe that the tendons of the **extensor digitorum longus muscle** attach to the middle and distal phalanges of the lateral four toes. The extensor digitorum longus muscle extends the toes and dorsiflexes the foot. Note that each of these tendons forms an **extensor expansion**.
10. Follow the tendon of the **fibularis tertius muscle** to its distal attachment on the tuberosity of the 5th metatarsal bone. The fibularis tertius muscle dorsiflexes the foot and assists in eversion of the foot. The fibularis tertius muscle may be absent.
11. At the level of the superior extensor retinaculum, identify the **anterior tibial artery** (Fig. 6.22). Trace the anterior tibial artery proximally. Use your fingers to forcibly separate the extensor digitorum longus muscle and the tibialis anterior muscle. Follow the anterior tibial artery between the two muscle bellies. **[G 406; N 501; R 448; C 343]**
12. Use a probe to clean the anterior tibial artery. Note that it passes over the superior border of the interosseous membrane (Fig. 6.22). Note that the anterior tibial artery lies directly on the anterior surface of the interosseous membrane and that it gives rise to unnamed muscular branches.
13. Observe that the deep fibular nerve joins the anterior tibial artery just below the knee (Fig. 6.22). The deep fibular nerve is the motor nerve of the anterior compartment of the leg and the dorsum of the foot. Trace the deep fibular nerve proximally and confirm that it is a branch of the **common fibular nerve**.
14. Return to the ankle region and trace the distal end of the anterior tibial artery deep to the inferior extensor retinaculum. As the anterior tibial artery crosses the ankle joint, its name changes to **dorsalis pedis artery** (L., *pes*, *pedis*, foot). **[G 408; N 502; R 481; C 346]**
15. Use scissors to cut the inferior extensor retinaculum over the extensor digitorum longus tendons. Retract the tendons of the extensor digitorum longus muscle in the lateral direction.
16. In the dorsum of the foot deep to the tendons of the extensor digitorum longus muscle, identify the **extensor digitorum brevis muscle** and the **extensor hallucis brevis muscle**. The extensor digitorum brevis and extensor hallucis brevis muscles share a common muscle belly that attaches to the calcaneus. Four tendons arise from this muscle belly and attach to the extensor expansions of toes 1-4. The portion of this muscle that attaches on the great toe is called the extensor hallucis brevis muscle. These muscles extend the toes and they are innervated by the deep fibular nerve.

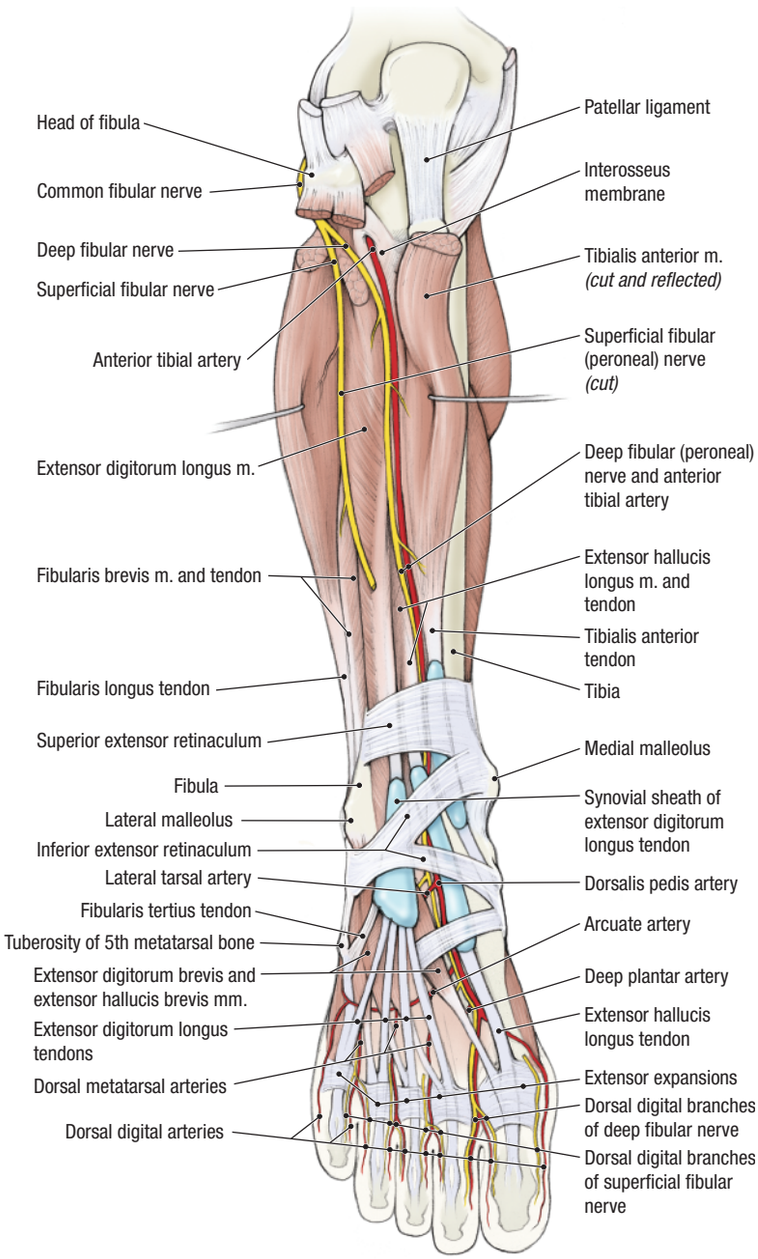

Figure 6.22. Contents of the anterior compartment of the leg.

17. Follow the dorsalis pedis artery onto the dorsum of the foot. It passes deep to the tendon of the extensor hallucis brevis muscle. In the living person, the pulse of the dorsalis pedis artery can be palpated between the tendons of the extensor hallucis longus muscle and the extensor digitorum longus muscle.
18. Identify the **arcuate artery**. The arcuate artery is a branch of the dorsalis pedis artery that crosses the proximal ends of the metatarsal bones. The **dorsal metatarsal arteries** originate from the arcuate artery. **[G 409; N 502; R 481; C 355]**
19. Identify the **lateral tarsal artery**. The lateral tarsal artery arises from the dorsalis pedis artery near the ankle joint and passes deep to the extensor digitorum brevis and extensor hallucis brevis muscles. The lateral tarsal artery joins the lateral end of the arcuate artery to complete an arterial arch.
20. Identify the **deep plantar artery**. The deep plantar artery arises from the dorsalis pedis artery near the origin of the arcuate artery. The deep plantar artery passes between the first and second metatarsal bones to enter the sole of the foot. In the sole of the foot, the deep plantar artery anastomoses with the deep plantar arch.
21. At the level of the ankle, identify the **deep fibular nerve** (Fig. 6.22). Use blunt dissection to follow the deep fibular nerve into the dorsum of the foot. Note that the deep fibular nerve innervates the extensor digitorum brevis muscle and the extensor hallucis brevis muscle. The deep fibular nerve then continues toward the great toe to give rise to two **dorsal digital branches of the deep fibular nerve**.
22. Use an illustration and your cadaver specimen to trace the cutaneous branch of the deep fibular nerve to the region of skin between the great toe and the second toe (Fig. 6.03). Understand that this is the only skin on the dorsum of the foot that is innervated by the deep fibular nerve. The **superficial fibular nerve** innervates all other skin on the dorsum of the foot.

After you dissect . . .

Use the dissected specimen to review the attachments and actions of the muscles in the anterior compartment of the leg. Trace the anterior tibial artery through the anterior compartment to the foot, where its name changes to dorsalis pedis artery. Name the branches of this arterial system. Recall the rule of innervation for the anterior compartment of the leg and the dorsum of the foot: **All muscles in the anterior compartment of the leg and the dorsum of the foot are innervated by the deep fibular nerve.**

LATERAL COMPARTMENT OF THE LEG **[G 410, 411; N 503; R 445; C 348]**

Before you dissect . . .

The lateral compartment of the leg contains two muscles: fibularis (peroneus) brevis and fibularis (peroneus) longus. The nerve of the lateral compartment is the superficial fibular (peroneal) nerve. The group action of the muscles in the lateral compartment of the leg is to evert and plantar flex the foot.

Dissection Instructions

1. Examine the **deep fascia** on the lateral side of the leg. Identify the **superior fibular (peroneal) retinaculum**. It is found on the lateral side of the ankle posterior to the lateral malleolus.
2. At the mid-level of the leg, identify the **superficial fibular (peroneal) nerve** where it penetrates the deep fascia (Fig. 6.03). Follow the superficial fibular nerve distally. It is the primary cutaneous nerve to the dorsum of the foot, and gives rise to several **dorsal digital branches** (Fig. 6.22). The superficial fibular nerve is a branch of the common fibular nerve.
3. Use scissors to incise the deep fascia overlying the lateral compartment of the leg. Carry the incision as far inferiorly as the superior fibular retinaculum. Open the deep fascia and observe that the fibularis longus muscle is attached to its inner surface.
4. Follow the tendons of the fibularis brevis and fibularis longus muscles distally and observe that their tendons pass deep to the superior and inferior fibular retinacula.
5. Follow the tendon of the fibularis brevis muscle to its distal attachment on the tuberosity of the 5th metatarsal bone.
6. Follow the tendon of the fibularis longus muscle and observe that it hooks around the cuboid bone and enters the sole of the foot. The tendon of the fibularis longus muscle attaches to the inferior surface of the first metatarsal bone and it will be dissected later.

CLINICAL CORRELATION

Common Fibular Nerve

The common fibular nerve is the most frequently injured nerve in the body because of its superficial position and relationship to the head and neck of the fibula. When the common fibular nerve is injured, there is impairment of eversion, dorsiflexion of the foot, and extension of the toes. The result is a condition called "foot drop," resulting in steppage gait (the advancing foot hangs with the toes pointed toward the ground, the knee being lifted high so that the toes may clear the ground). There will also be sensory loss on the dorsum of the foot and toes.

After you dissect . . .

Use the dissected specimen to review the attachments and actions of the muscles in the lateral compartment of the leg. Understand that the fibular artery supplies the muscles of the lateral compartment of the leg by small branches that penetrate the posterior intermuscular septum. Recall the rule of innervation for the lateral compartment of the leg: **All of the muscles in the lateral compartment of the leg are innervated by the superficial fibular nerve.**

POSTERIOR COMPARTMENT OF THE LEG

Before you dissect . . .

The **posterior compartment of the leg** lies posterior to the interosseous membrane, tibia, and fibula (Fig. 6.19). A **transverse intermuscular septum** divides the muscles of the posterior compartment into superficial and deep groups. The superficial posterior group contains three muscles: gastrocnemius, soleus, and plantaris. The group action of the superficial posterior muscle group is plantar flexion of the foot. The deep posterior group contains four muscles: popliteus, tibialis posterior, flexor digitorum longus, and flexor hallucis longus. The shared actions of the deep posterior muscle group are inversion of the foot, plantar flexion of the foot, and flexion of the toes. The tibial nerve innervates both the superficial and deep posterior muscle groups.

Dissection Instructions

1. Turn the cadaver to the prone position.
2. Incise the deep fascia of the leg from the popliteal fossa to the calcaneus and open the posterior compartment.
3. Identify the **gastrocnemius muscle**. The gastrocnemius muscle is the most superficial muscle in the posterior compartment of the leg. The proximal attachments of the **two heads of the gastrocnemius muscle** are the femoral condyles. The distal attachment of the gastrocnemius muscle is on the calcaneal tuberosity by way of the **calcaneal tendon (tendo calcaneus, Achilles' tendon)**. The gastrocnemius muscle plantar flexes the foot. **[G 416; N 498; R 343; C 357]**
4. Use scissors to transect the two heads of the gastrocnemius muscle about half way between their proximal attachments and the point where they join. Reflect the proximal and distal portions of the muscle.
5. Identify the **soleus muscle**, which is located deep to the gastrocnemius muscle. The proximal attachments of the soleus muscle are the soleal line of the tibia and the head of the fibula. The distal attachment of the soleus muscle is the calcaneal tendon. The soleus muscle plantar flexes the foot. **[G 417; N 499; R 443; C 359]**
6. Identify the tendon of the **plantaris muscle**. The belly of the plantaris muscle lies in the popliteal fossa and its proximal attachment is the lateral supracondylar line of the femur. The popliteus tendon courses between the gastrocnemius and soleus muscles to its distal attachment on the calcaneal tendon. The plantaris muscle is a plantar flexor of the foot and a weak flexor of the knee. The plantaris muscle may be absent.
7. The **tibial nerve** and **posterior tibial vessels** exit the popliteal fossa by passing deep to the tendinous arch of the soleus muscle (Fig. 6.23). They course distally in the **transverse intermuscular septum** that separates the superficial posterior muscle group from the deep posterior muscle group (Fig. 6.19).
8. Use scissors to transect the calcaneal tendon about 5 cm superior to the tuberosity of the calcaneus. Use your fingers to separate the calcaneal tendon from the muscles that lie deep to it.
9. Use scissors to detach the soleus muscle from its tibial attachment but leave it attached to the fibula. Retract the soleus muscle and the gastrocnemius muscle laterally to expose the transverse intermuscular septum.
10. Identify the **posterior tibial vessels** and the **tibial nerve** in the transverse intermuscular septum (Fig. 6.23). The posterior tibial artery is usually accompanied by two veins. Remove the veins to clear the dissection field. **[G 418; N 500; R 474; C 361]**
11. Use a probe to follow the posterior tibial artery and the tibial nerve proximally. Observe that the popliteal artery bifurcates at the inferior border of the popliteus muscle to form the **posterior tibial artery** and the **anterior tibial artery**.
12. Retract the contents of the popliteal fossa laterally and identify the **popliteus muscle** (Fig. 6.23). The proximal attachment of the popliteus muscle is the lateral condyle of the femur and its distal attachment is the posterior surface of the proximal tibia. The popliteus muscle unlocks the knee and is a weak flexor of the leg. **[G 419; N 500; R 446; C 362]**
13. Identify the **tibialis posterior muscle**. The proximal attachments of the tibialis posterior muscle are the tibia, fibula, and the interosseous membrane. The distal attachments of the tibialis posterior muscle are the inferior surfaces of several tarsal bones. The tibialis posterior muscle is an inverter and plantar flexor of the foot.
14. The proximal attachment of the **flexor digitorum longus muscle** is the tibia. Distally, its tendons attach to the bases of the distal phalanges of the lateral four toes. The flexor digitorum longus muscle flexes toes 2-5 and plantar flexes the foot.
15. The proximal attachment of the **flexor hallucis longus muscle** is the inferior two-thirds of the fibula and interosseous membrane, and its distal attachment is the base of the distal phalanx of the great toe. The flexor hallucis longus muscle flexes the great toe and plantar flexes the foot.
16. Posterior to the medial malleolus, observe that the **posterior tibial artery** and the **tibial nerve** lie between the tendons of the flexor digitorum longus and flexor hallucis longus muscles, deep to the flexor retinaculum. Posterior to the medial malleolus the following mnemonic device may be used to identify the tendons and vessels: **T**om, **D**ick **AN**d **H**arry (**T**ibialis posterior, flexor **D**igitorum longus, posterior tibial **A**rtery, tibial **N**erve, flexor **H**allucis longus). **[G 420; N 498; C 360]**
17. Once again, observe the vascular distribution in the posterior compartment of the leg (Fig. 6.23). Identify the **fibular (peroneal) artery**. The fibular artery arises from the posterior tibial artery about 2 or 3 centimeters distal to the inferior border of the popliteus muscle. The fibular artery courses between the tibialis posterior muscle and the flexor hallucis longus muscle.

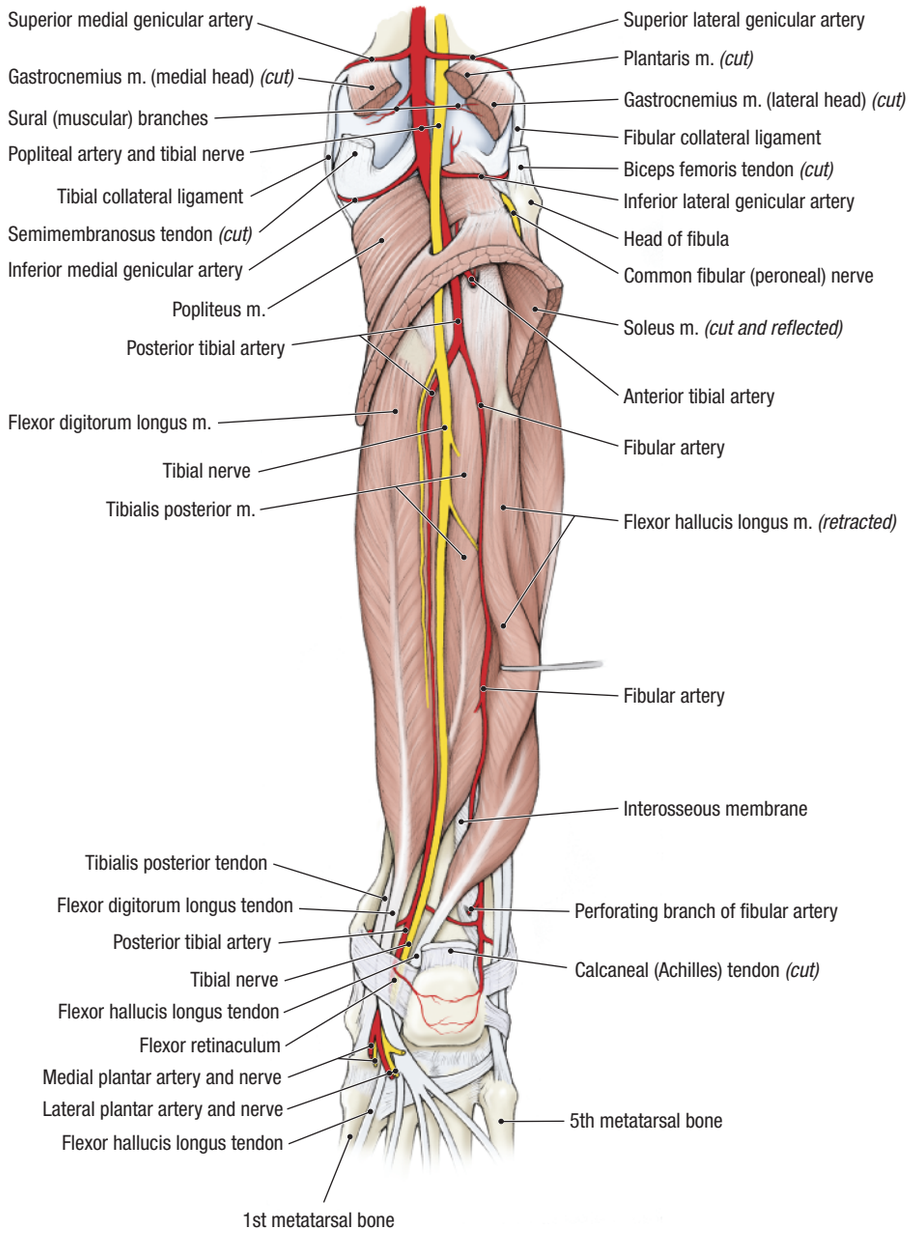

Figure 6.23. Contents of the deep posterior compartment of the leg.

It supplies blood to the muscles of the lateral compartment of the leg and lateral side of the posterior compartment of the leg.

18. The **perforating branch of the fibular artery** usually arises just above the ankle joint (Fig. 6.23). It perforates the interosseous membrane and anastomoses with a branch of the anterior tibial artery. Occasionally, the perforating branch of the fibular artery will give rise to the dorsalis pedis artery.

After you dissect . . .

Replace the muscles of the posterior compartment of the leg into their correct anatomical positions. Using the dissected specimen, review the attachments and action of each muscle dissected. Follow the popliteal artery into the posterior compartment of the leg and identify its branches. Follow the posterior tibial artery distally and identify the origin of the fibular artery. Review the distribution of the arteries of the posterior compartment of the leg. Follow the tibial nerve through the popliteal fossa and posterior compartment of the leg, observing that it gives off numerous muscular branches. Review the relationships of the nerve, tendons, and vessels posterior to the medial malleolus and use this pattern to organize the contents of the deep posterior compartment of the leg. Recall the rule of innervation of the posterior compartment of the leg: **All muscles in the posterior compartment of the leg are innervated by the tibial nerve.**

Review the muscles of all three compartments of the leg and the nerves that innervate the compartments (Fig. 6.24). The **muscles in the anterior compartment** (tibialis anterior, extensor hallucis longus, extensor digitorum longus, and fibularis tertius) are innervated by the **deep fibular nerve**. The **muscles in the lateral compartment** (fibularis brevis and fibularis longus) are innervated by the **superficial fibular nerve**. The **muscles in the posterior compartment** (superficial—gastrocnemius, soleus, plantaris; deep—popliteus, tibialis posterior, flexor digi-

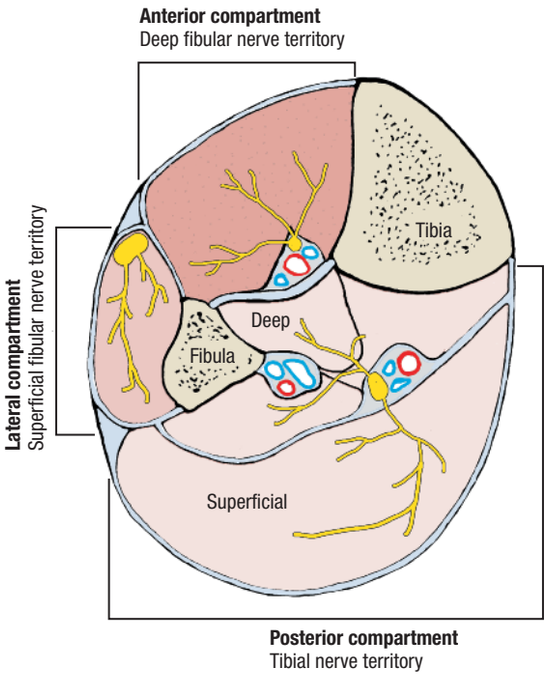

Figure 6.24. Motor nerve territories of the leg.

torum longus, flexor hallucis longus) are innervated by the **tibial nerve.**

SOLE OF THE FOOT

Before you dissect . . .

The **foot is arched longitudinally** (Fig. 6.21). The **weight bearing points** of the foot are the calcaneus posteriorly and the heads of the five metatarsal bones anteriorly. The **plantar aponeurosis** supports the longitudinal arch. Deep to the plantar aponeurosis are four layers of intrinsic foot muscles.

The order of dissection will be as follows: The plantar aponeurosis will be cleaned of superficial fascia and studied. It will then be reflected to expose the first layer of muscles. The dissection will proceed from superficial (inferior) to deep (superior) and each of the four layers of muscles will be dissected. Note that abduction and adduction movements of the toes are described around an axis of reference that passes through the second digit (second toe). This convention differs from the hand, in which the axis of reference passes through the third digit.

Dissection Instructions

PLANTAR APONEUROSIS AND CUTANEOUS NERVES [G 424; N 514; R 449; C 366]

1. If the skin has not been removed from the sole of the foot, refer to Figure 6.02C and complete the skin removal.
2. Use a dull scalpel blade to scrape the superficial fascia off the plantar aponeurosis. Note that the plantar aponeurosis is attached to the calcaneus posteriorly and that it divides distally into five bands, one to each toe.
3. Use a scalpel to cut the plantar aponeurosis longitudinally (Fig. 6.25A). The plantar aponeurosis is approximately 4 mm thick. Do not cut too deeply.
4. Make two transverse cuts through the plantar aponeurosis; one cut close to the calcaneus and one in the anterior one-third of the foot (Fig. 6.25A). Tough bands of connective tissue attach the plantar aponeurosis to the metatarsal bones. Use a scalpel to cut these bands and release the plantar aponeurosis from the underlying structures. Reflect the flaps medially and laterally (Fig. 6.25B).

FIRST LAYER OF PLANTAR MUSCLES [G 428; N 515; R 449; C 367]

1. Identify the **flexor digitorum brevis muscle** (Fig. 6.25B). The proximal attachments of the flexor digitorum brevis muscle are the calcaneal tuberosity and the plantar aponeurosis. The distal attachments of the

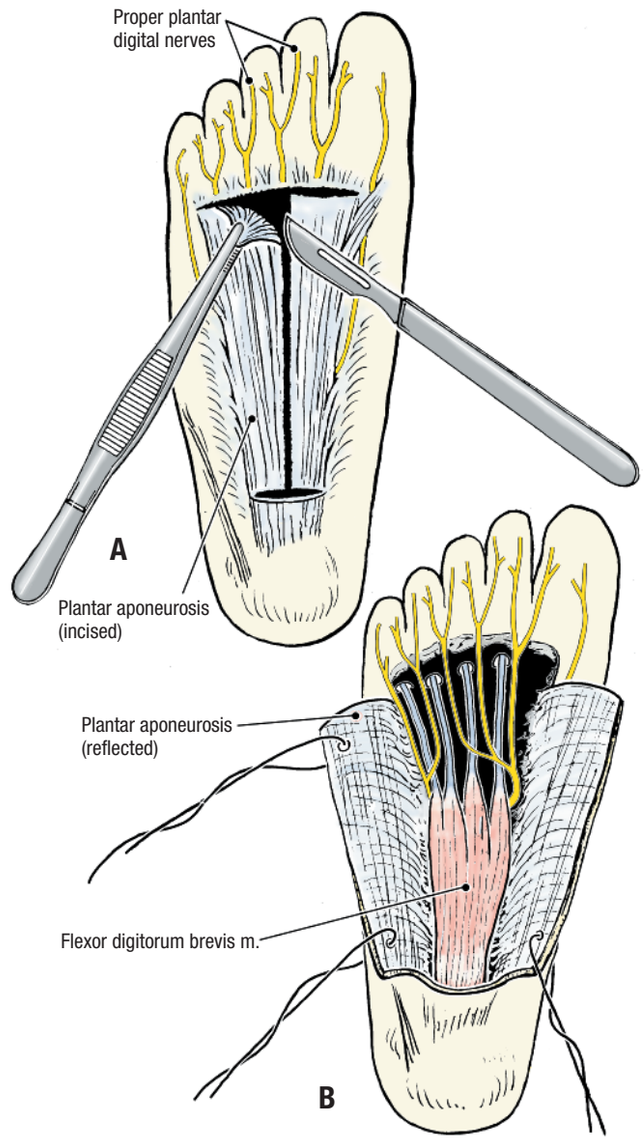

Figure 6.25. How to open the plantar aponeurosis.

flexor digitorum brevis muscle are the middle phalanges of the lateral four toes. The flexor digitorum brevis muscle flexes the lateral four toes. Trace the flexor digitorum brevis tendons to their distal attachments. Remove the plantar aponeurosis piece by piece as necessary.

2. Identify the **abductor hallucis muscle** (Fig. 6.26). The abductor hallucis muscle is located on the medial side of the flexor digitorum brevis muscle. The proximal attachments of the abductor hallucis muscle are the medial side of the calcaneal tuberosity and the plantar aponeurosis. The distal attachment of the abductor hallucis muscle is the medial side of the base of the proximal phalanx of the great toe and it abducts the great toe. Use blunt dissection to follow the tendon to its distal attachment.
3. Identify the **abductor digiti minimi muscle** (Fig. 6.26). The proximal attachments of the abductor digiti minimi muscle are the lateral side of the calcaneal tuberosity and the plantar aponeurosis and its distal attachment is the lateral side of the base of the proximal phalanx of the 5th (small) toe. The abductor digiti minimi muscle abducts the 5th toe. Follow the tendon to its distal attachment.
4. In the distal one-third of the sole of the foot look for **common** and **proper plantar digital nerves**, which are branches of the **medial** and **lateral plantar nerves** (Fig. 6.26). The common and proper digital nerves lie between the tendons just identified.

SECOND LAYER OF PLANTAR MUSCLES [G 429; N 516; R 450; C 368]

1. Use scissors to transect the flexor digitorum brevis muscle close to the calcaneus (Fig. 6.26). Reflect the muscle distally. To make reflection easier, cut the common plantar digital nerves and vessels.
2. Identify the **quadratus plantae (flexor accessorius) muscle**, which is deep to the flexor digitorum brevis muscle (Fig. 6.27). The proximal attachment of the quadratus plantae muscle is the calcaneus and its distal attachment is the tendon of the flexor digitorum longus muscle. The quadratus plantae muscle assists the flexor digitorum longus muscle in flexing the lateral four toes.
3. Use a probe to dissect the **flexor digitorum longus tendons** in the sole of the foot. Observe that its four tendons pass through the tendons of the flexor digitorum brevis muscle (Fig. 6.27).
4. Observe that four **lumbrical muscles** arise from the tendons of the flexor digitorum longus muscle. The distal attachments of the lumbrical muscles are the extensor expansions of the lateral four toes.

THIRD LAYER OF PLANTAR MUSCLES [G 430; N 517; R 451; C 371]

1. Use scissors to transect the flexor digitorum longus tendon where it is joined by the quadratus plantae muscle (Fig. 6.27). Reflect the tendons distally, along with the lumbrical muscles.
2. Identify the **flexor hallucis brevis muscle** (Fig. 6.28). The proximal attachments of the flexor hallucis brevis muscle are the first metatarsal bone, the cuboid bone,

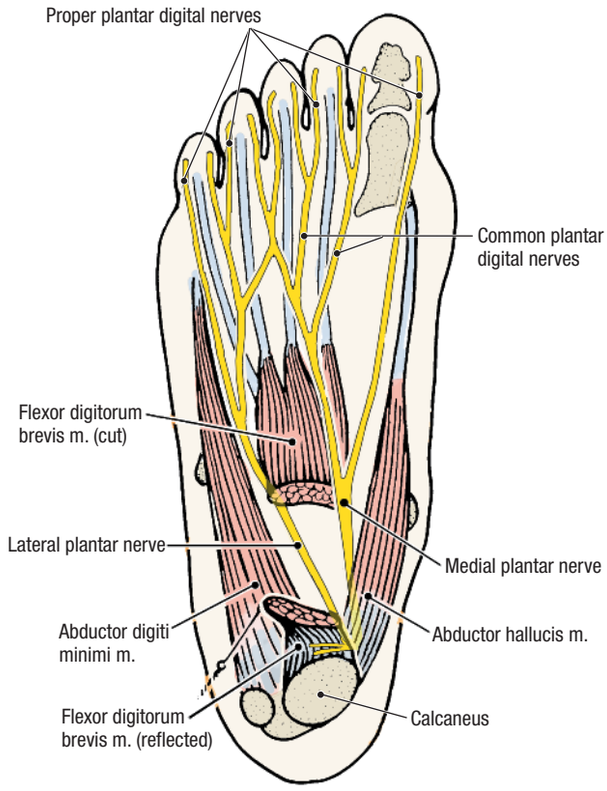

Figure 6.26. Sole of the foot. First layer of muscles and the plantar nerves.

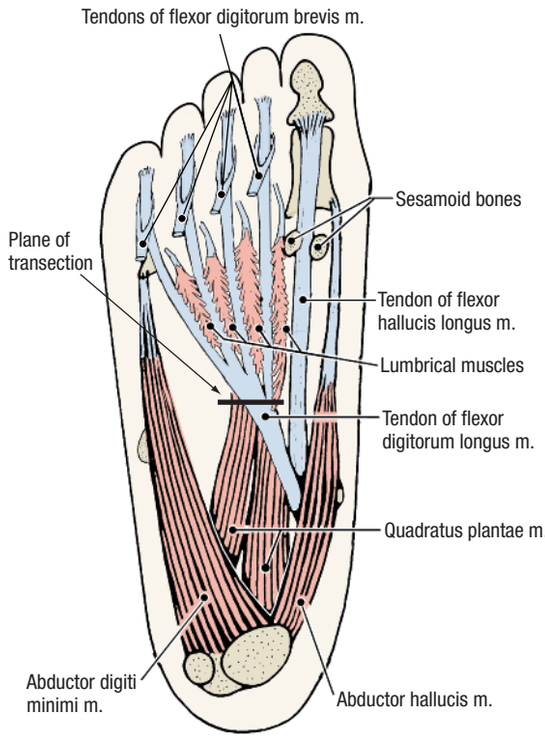

Figure 6.27. Sole of the foot. Second layer of muscles.

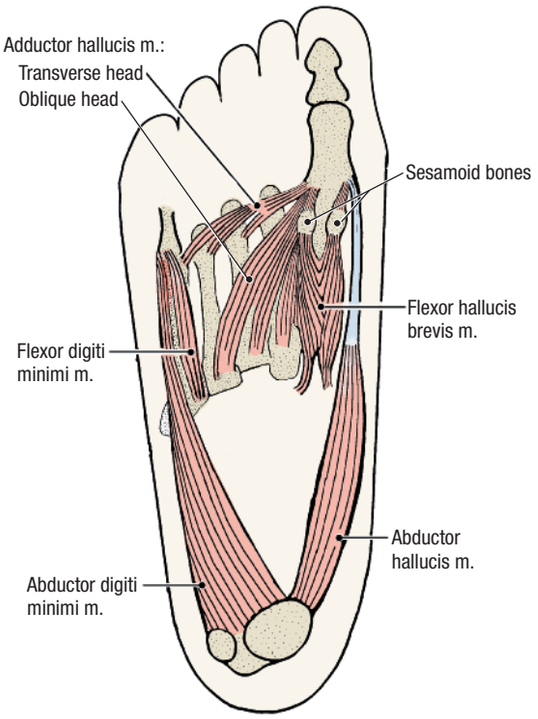

Figure 6.28. Sole of the foot. Third layer of muscles.

and the 3rd cuneiform bone. The flexor hallucis brevis muscle has two heads (medial and lateral) and two tendons. A **sesamoid bone** is found in each of the tendons. The distal attachment of the flexor hallucis brevis muscle is the base of the proximal phalanx of the great toe and it flexes the great toe.

3. Observe that the **tendon of the flexor hallucis longus muscle** runs between the two sesamoid bones of the flexor hallucis brevis muscle. Verify that the tendon of the flexor hallucis longus is attached to the base of the distal phalanx of the great toe (Fig. 6.27).
4. Identify the **adductor hallucis muscle**. The adductor hallucis muscle has a transverse head and an oblique head (Fig. 6.28). Both heads attach to the lateral side of the base of the proximal phalanx of the great toe. The adductor hallucis muscle adducts the great toe (i.e., moves it toward the second toe).
5. Identify the **flexor digiti minimi muscle**. The proximal attachment of the flexor digiti minimi muscle is the base of the 5th metatarsal bone and its distal attachment is the base of the proximal phalanx of the 5th toe. The flexor digiti minimi muscle flexes the 5th toe.
6. Push a probe deep to the abductor hallucis muscle along the course of the posterior tibial artery. Cut the muscle overlying the probe and use blunt dissection to follow the posterior tibial artery and tibial nerve into the sole. Identify the **medial** and **lateral plantar nerves** and **arteries**.

FOURTH LAYER OF PLANTAR MUSCLES [G 431; N 518; R 451; C 372]

1. Use an illustration to study the **interosseous muscles**. The four **D**orsal interosseous muscles are **AB**ductors (**DAB**) and the three **P**lantar interosseous muscles are **AD**ductors (**PAD**) of the toes. Recall that the reference axis for abduction and adduction passes through the 2nd toe.
2. Trace the **fibularis longus tendon** from the level of the lateral malleolus to its distal attachment on the base of the 1st metatarsal bone and the 1st cuneiform bone. Note that the fibularis longus tendon occupies the deepest plane of the sole of the foot.
3. Follow the **tibialis posterior tendon** distally and verify that it has a broad distal attachment on the navicular bone, all three cuneiform bones, and the bases of the 2nd, 3rd, and 4th metatarsal bones.
4. Use blunt dissection to trace the lateral plantar artery to the deep **plantar arch**. Follow the deep plantar arch medially and demonstrate its connection to the **deep plantar branch of the dorsalis pedis artery**. The deep plantar branch of the dorsalis pedis artery passes between the first and second metatarsal bones.
5. Once again, identify the **flexor hallucis longus muscle** in the posterior compartment of the leg. Follow its tendon distally until it disappears into an osseofibrous tunnel at the medial side of the ankle. Push a probe into the tunnel, then open it with a scalpel. Lift the tendon of the flexor hallucis longus muscle with a probe and verify that it crosses the inferior surface of the **sustentaculum tali**. The sustentaculum tali acts as a pulley to change the direction of force of the flexor hallucis longus muscle.

After you dissect . . .

Replace the structures of the four layers of the sole of the foot into their correct anatomical positions. Using the dissected specimen, review the attachments and action of each muscle. Organize the muscles from superficial (inferior) to deep (superior). Follow the posterior tibial artery from its origin in the leg to its bifurcation in the sole of the foot. Use an illustration and the dissected specimen to review the distribution of the medial and lateral plantar arteries. Review the connection between the deep plantar arch and the deep plantar branch of the dorsalis pedis artery. Retrace the course of the tibial nerve from the popliteal fossa to the medial side of the ankle. Follow its two branches (medial and lateral plantar nerves) in the sole of the foot. Use a textbook description to help you relate the motor and sensory function of the lateral and medial plantar nerves to your dissected specimen. Typically, the medial plantar nerve innervates the abductor hallucis muscle, flexor digitorum brevis muscle, flexor hallucis brevis muscle, and the medial lumbrical muscle. The medial plantar nerve will provide cutaneous innervation to the plantar surfaces of the medial 3 1/2 toes. The motor and cutaneous distribution of the medial plantar nerve is similar to the distribution of the median nerve in the hand. The lateral plantar nerve innervates all other muscles in the sole of the foot and provides cutaneous innervation to the plantar surfaces of the lateral 1 1/2 toes. The distribution of the lateral plantar nerve compares favorably to the distribution of the ulnar nerve in the hand.

JOINTS OF THE LOWER LIMB

Before you dissect . . .

Dissect the joints of one lower limb. Keep the soft tissue structures of the other limb intact for review purposes. If the pelvis and perineum have been dissected previously, the right side of the pelvis and the right lower limb have been separated from the trunk. If that is the case, perform joint dissections on the right lower limb.

The order of dissection will be as follows: The hip will be dissected, then the knee joint. The ankle joint will be dissected. The intermetatarsal joints, which are responsible for inversion and eversion, will be studied. During this dissection, the muscles of one limb will be removed. Take advantage of this opportunity to review the attachments, innervation, and action of each muscle as it is removed.

Dissection Instructions

HIP JOINT

1. Review the bony features of the hip joint. Three bones form the acetabulum: **ilium**, **ischium**, and **pubis**. Review the proximal end of the femur and identify the following: **head**, **fovea for the ligament of the head**, **neck**, and **intertrochanteric line**.
2. Remove the sartorius muscle, rectus femoris muscle, and pectineus muscle.
3. Identify the **iliopsoas muscle**. Trace its tendon to the lesser trochanter. Sever the tendon of the iliopsoas muscle close to the lesser trochanter and reflect the muscle superiorly.
4. Use an illustration to identify the ligaments that contribute to the formation of the **fibrous joint capsule**: **iliofemoral ligament**, **ischiofemoral ligament**, and **pubofemoral ligament** (Figs. 6.29, 6.30). **[G 376, 377; N 469; R 430, 431; C 376]**
5. Examine the **iliofemoral ligament**. Verify that the distal end of the iliofemoral ligament is attached to the intertrochanteric line of the femur. The proximal end is attached to the anterior inferior iliac spine and the margin of the acetabulum.
6. Flex and extend the femur. Observe that the iliofemoral ligament becomes lax in flexion and taut in extension. The iliofemoral ligament prevents overextension of the hip joint.
7. Use a scalpel to open the anterior aspect of the **joint capsule** as illustrated in Figure 6.29.
8. Inside the joint capsule, observe the **cartilage on the articular surface of the head of the femur**. Rotate the femur laterally and note that you can see more of the articular surface of the head. Rotate the femur medially and observe that the articular surface disappears into the acetabulum. **[G 376; N 469; R 431; C 377]**
9. Abduct and laterally rotate the femur. Identify the **ligament of the head of the femur** (Fig. 6.29).
10. Identify the **obturator externus muscle**. Note that the obturator externus muscle passes inferior to the neck of the femur.

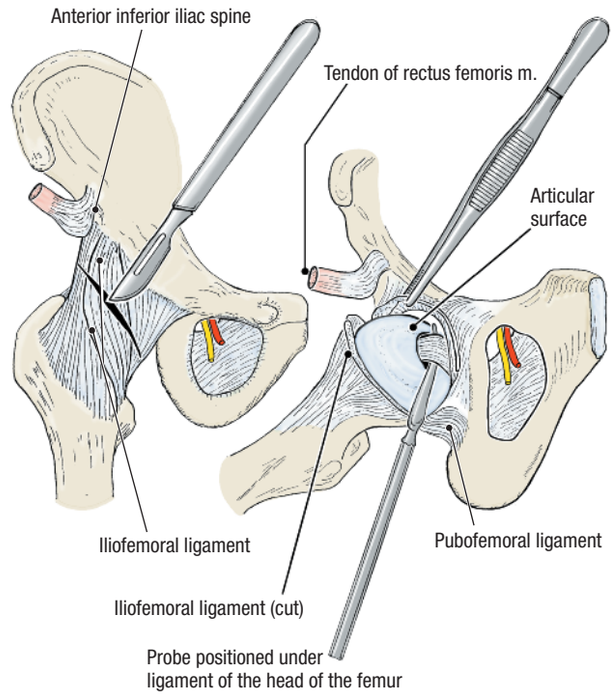

Figure 6.29. How to open the anterior aspect of the hip joint capsule.

11. Remove the obturator externus muscle to expose the **pubofemoral ligament**.
12. Turn the specimen to the prone position.
13. Remove the piriformis, superior gemellus, obturator internus, inferior gemellus, quadratus femoris, gluteus medius, and gluteus minimus muscles.
14. Use a scalpel and scraping motions to clean the posterior surface of the **joint capsule** (Fig. 6.30).
15. Identify the **ischiofemoral ligament**, which runs from the acetabular margin to the neck of the femur. Note that the ischiofemoral ligament does not attach to the intertrochanteric crest but leaves an area where the synovial membrane of the hip joint is exposed.

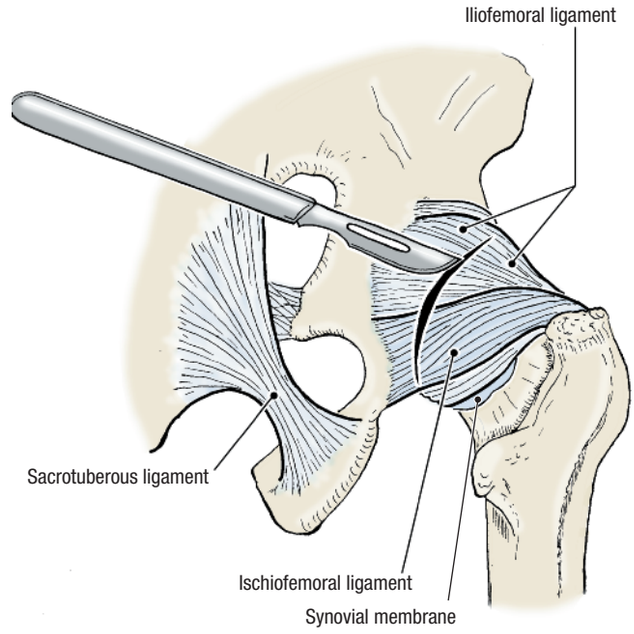

Figure 6.30. How to open the posterior aspect of the hip joint capsule.

16. Extend the femur. Observe that the ischiofemoral ligament becomes taut and limits extension of the hip joint.
17. Open the posterior wall of the joint cavity by incising the capsule as shown in Figure 6.30. Observe the thickness of the joint capsule.
18. The next objective is to disarticulate the hip joint. Return the specimen to the supine position. Insert a probe under the ligament of the head of the femur (Fig. 6.29) and cut it with a scalpel. Rotate the femur laterally and the head of the femur will come out of the acetabulum.
19. Examine the head and neck of the femur (Fig. 6.31). Identify the **articular surface** of the head of the femur. Observe the cut end of the **ligament of the head of the femur** and identify the **artery of the ligament of the head of the femur** in its center. Use an illustration to review the blood supply to the head and neck of the femur.
20. Identify the **lunate surface** in the acetabulum (Fig. 6.31). Note that the **ligament of the head of the femur** lies in the **acetabular notch**. **[G 378; N 469; R 431; C 377]**
21. Identify the **transverse acetabular ligament** that bridges the acetabular notch and the **acetabular labrum** that surrounds the rim of the acetabulum.

CLINICAL CORRELATION

Neck of the Femur

A fracture of the neck of the femur disrupts the blood supply to the head of the femur. If the blood supply (via the artery of the ligament of the head) is insufficient, the head will become necrotic. Necrosis of the femoral head is a common complication in femoral neck fractures of the elderly.

KNEE JOINT

1. Review the skeleton of the knee. On the distal end of the femur identify: **medial condyle, lateral condyle**, and **intercondylar fossa**. On the proximal end of the tibia identify: **superior articular surface**, **medial condyle**, **lateral condyle**, and **intercondylar eminence**. On the patella identify: **articular surface** and **anterior surface**.
2. On the medial side of the knee, use a scalpel to detach the tendons of the sartorius, gracilis, and semitendinosus muscles from their distal attachments (pes anserinus). **[G 390; N 488; R 432; C 381]**
3. Reflect the muscles and identify the **tibial collateral ligament** of the knee (Fig. 6.32B). Note that the tibial collateral ligament is attached to the medial meniscus through the joint capsule.
4. On the lateral side of the knee, cut the tendon of the biceps femoris muscle close to its distal attachment on the head of the fibula.
5. Reflect the biceps femoris muscle and identify the **fibular collateral ligament** of the knee. Note that the fibular collateral ligament is not attached to the external surface of the joint capsule (Fig. 6.32B). Observe that the popliteus tendon passes between the fibular collateral ligament and the joint capsule. **[G 391; N 488; R 432; C 381]**
6. On the posterior surface of the knee, remove the popliteal vessels, the tibial nerve, and the common fibular nerve.
7. Detach the semimembranosus and semitendinosus tendons and reflect the muscles. Free the plantaris muscle and both heads of the gastrocnemius muscle from the joint capsule. Detach the proximal attachments of these muscles close to the bone.
8. Remove the popliteus muscle. During this procedure, the posterior wall of the joint capsule will be opened. Clear away the remnants of the posterior wall of the joint capsule.
9. From the posterior view, identify the **posterior cruciate ligament** (Fig. 6.32A). Verify that the cruciate ligaments are located *outside* of the synovial cavity but are *inside* the joint capsule. **[G 394; N 491; R 432; C 383]**
10. On the anterior surface of the knee, identify the tendon of the quadriceps femoris muscle. Observe that the tendon has **patellar retinacula** that help to keep the patella centered. Inferior to the patella, identify the **patellar ligament**.
11. Make a transverse incision superior to the patella through the quadriceps femoris tendon. Carry the incision around the sides of the knee stopping short of the collateral ligaments.
12. Reflect the patella and patellar ligament inferiorly (Fig. 6.32B). Confirm that the femur and the tibia remain attached to each other by **two collateral ligaments** and **two cruciate ligaments**. **[G 393; N 489; R 433; C 381]**
13. Verify that the cruciate ligaments cross each other (Fig. 6.32C). The **anterior cruciate ligament** attaches to the tibia anteriorly. The **posterior cruciate ligament** attaches to the tibia posteriorly.
14. Extend the leg. With the leg in this position, observe:
    - The articular surfaces of the femur and tibia are in maximum contact.
    - The joint is "locked" in its most stable position.
    - The anterior cruciate ligament is taut and prohibits further extension.

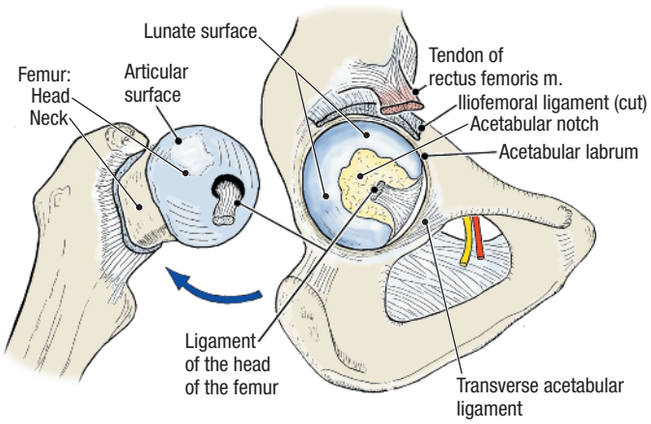

Figure 6.31. Disarticulated hip joint.

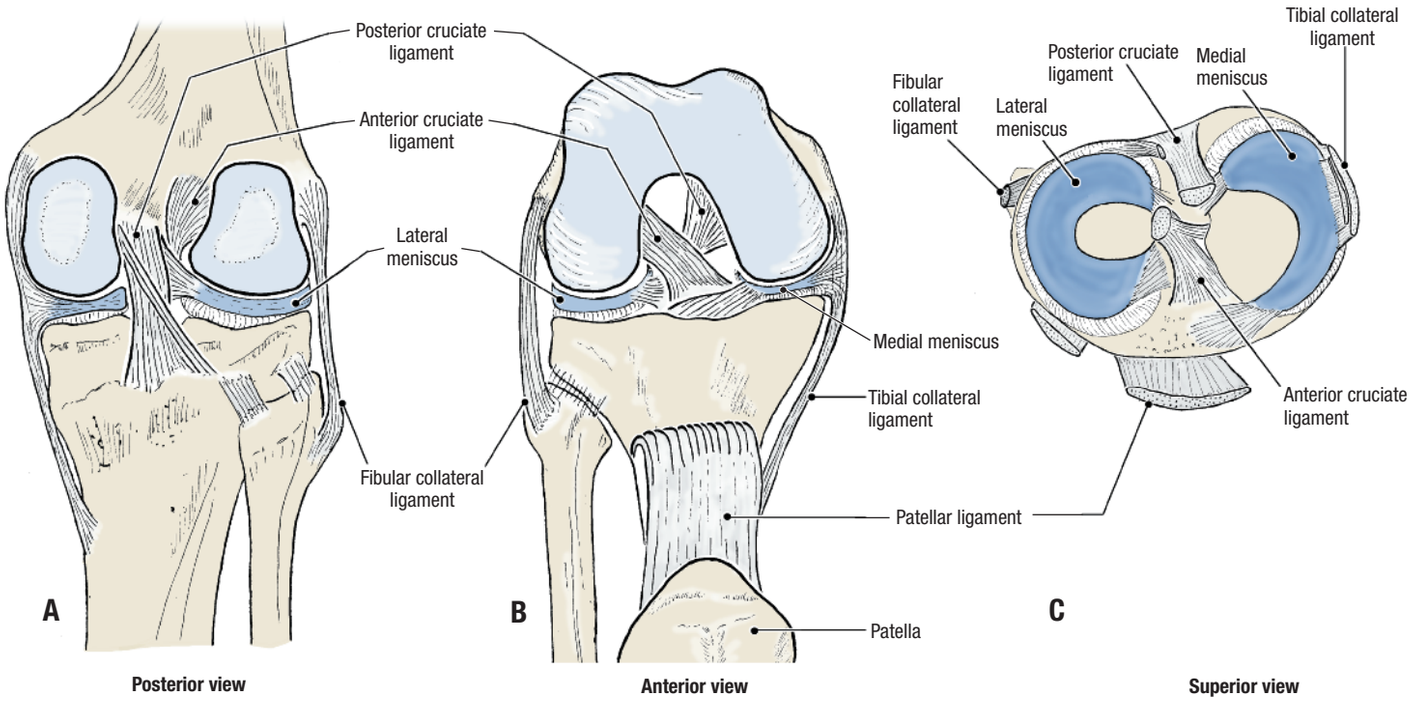

Figure 6.32. Right knee joint.

15. Flex the leg. With the leg in this position, observe:
    - There is less contact between the articular surfaces of the femur and tibia.
    - Some rotation occurs in the knee joint.
    - The posterior cruciate ligament prevents the tibia from being pushed posteriorly.
    - The anterior cruciate ligament prevents the tibia from being pulled anteriorly.
16. Flex the leg and pull the tibia anteriorly. Note the tightness of the joint. Cut the anterior cruciate ligament. Now flex the leg and pull the tibia anteriorly. Feel the forward movement of the tibia. This forward movement indicates a ruptured anterior cruciate ligament and is an important clinical sign (anterior drawer sign).
17. Observe the **menisci** (Fig. 6.32C). Note that the **medial meniscus** is firmly attached to the tibial collateral ligament. In contrast, the **lateral meniscus** is not attached to the fibular collateral ligament.

CLINICAL CORRELATION

Knee Injuries

The medial meniscus is injured 6 to 7 times more often than the lateral meniscus because the medial meniscus is firmly attached to the tibial collateral ligament.

Forced abduction and lateral rotation of the leg may result in the simultaneous injury of three structures: tibial collateral ligament, medial meniscus, and anterior cruciate ligament. The injury has been named the "unhappy triad." This injury is caused by a blow to the lateral side of the knee and is a common injury in contact sports.

ANKLE JOINT [G 435; N 509; R 436; C 394, 395]

1. Review the bony landmarks related to the ankle joint. On the distal end of the fibula identify the **lateral malleolus**. On the distal end of the tibia, identify the **medial malleolus**. On the talus, identify the **trochlea**. Review the tarsal bones.
2. Cut and reflect the tendons, vessels, and nerves that cross the anterior aspect of the ankle joint. Leave a long portion of the tibialis anterior tendon attached to the tarsal bones.
3. On the medial aspect of the ankle joint, cut and reflect the flexor digitorum longus muscle. Retract the tendon of the tibialis posterior muscle anteriorly. Do not cut it.
4. Clean and define the **medial (deltoid) ligament of the ankle** (Fig. 6.33A). It has four parts: **posterior tibiotalar ligament**, **tibiocalcaneal ligament**, **tibionavicular ligament**, and **anterior tibiotalar ligament**.
5. On the lateral side of the ankle, identify the tendons of the fibularis longus and fibularis brevis muscles. Open the superior and inferior fibular retinacula. Retract the tendons of the fibularis longus and fibularis brevis muscles anteriorly.
6. Clean and define the **lateral ligament of the ankle** (Fig. 6.33B). It has three parts: **posterior talofibular ligament**, **calcaneofibular ligament**, and **anterior talofibular ligament**.
7. Dorsiflex and plantar flex the ankle joint. Observe that these are the only actions of the ankle joint.

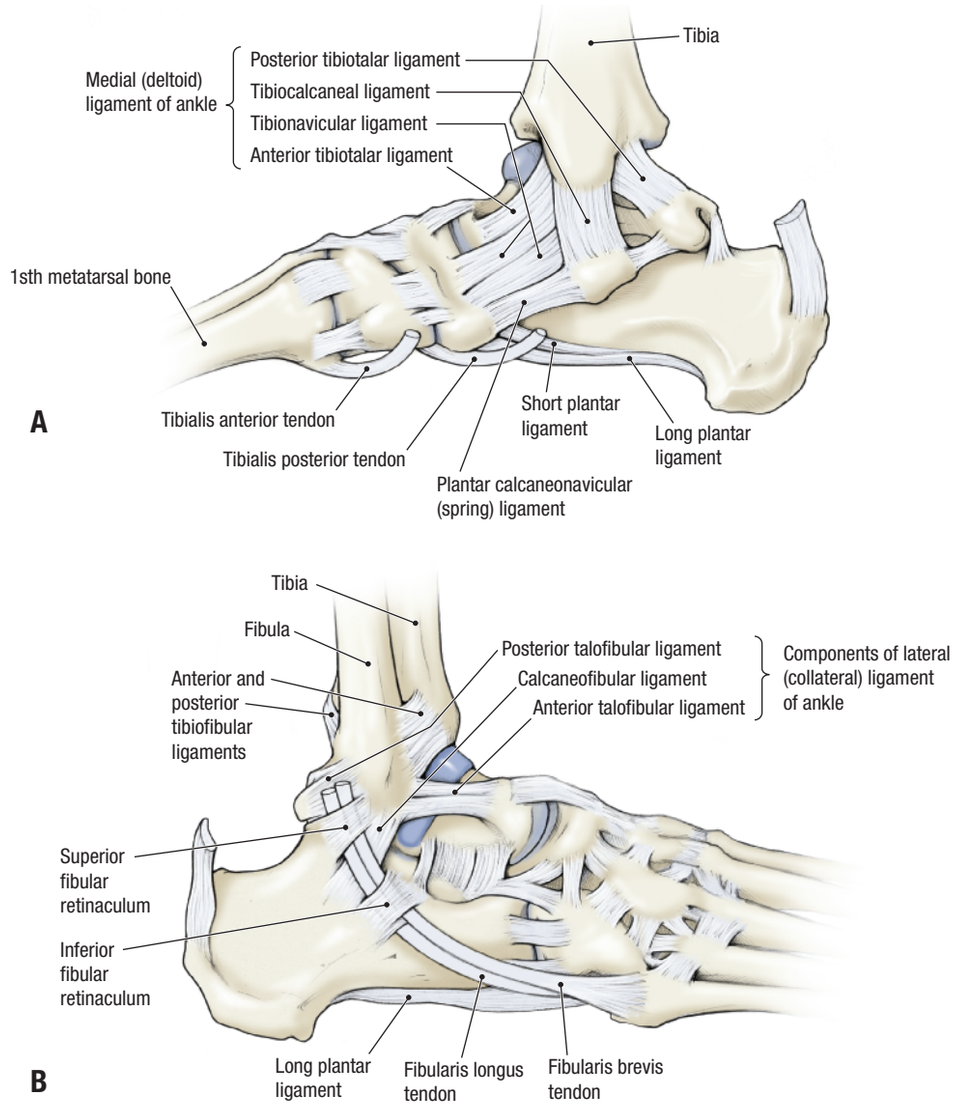

Figure 6.33. Right ankle joint. **A.** Medial view. **B.** Lateral view.

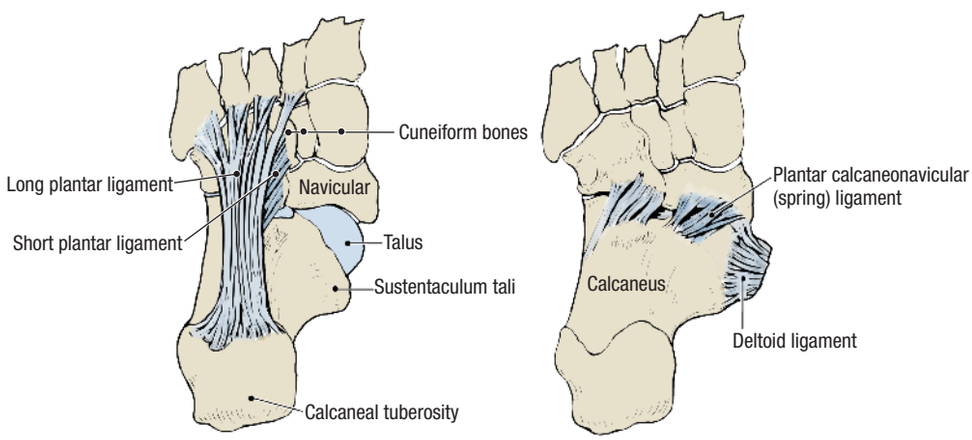

Figure 6.34. Plantar ligaments.

CLINICAL CORRELATION

Ankle Injuries

Ankle injuries are very common. Frequently, the lateral ligament of the ankle is injured when the foot is forcefully inverted. The result is an ankle sprain with swelling around the lateral malleolus. In severe cases, the calcaneofibular and talofibular ligaments are torn, and the inferior tip of the lateral malleolus may be avulsed (pulled off).

JOINTS OF INVERSION AND EVERSION

1. Study the movements of inversion and eversion of the foot in a suitable skeletal specimen (caution—wired laboratory skeletons can be damaged). With one hand, immobilize the ankle joint by holding the talus stationary between the tibia and fibula. With the other hand, invert and evert the foot. Observe:
   - The talus remains fixed in the ankle joint.
   - The entire foot rotates about the inferior and anterior surfaces of the talus (subtalar joint).
2. In the cadaver specimen, produce **eversion** by pulling on the tendons of the fibularis longus and fibularis brevis muscles. Produce **inversion** by pulling on the tendons of the tibialis anterior and tibialis posterior muscles simultaneously.
3. Observe that these movements occur in the **transverse tarsal joint** (calcaneocuboid and talonavicular joints) and the **subtalar joint**.
4. The longitudinal arch of the foot is supported by ligaments that span the tarsal bones. In the sole of the foot, remove the flexor digitorum brevis and quadratus plantae muscles. Observe the **long plantar ligament** and the **short plantar ligament** (Fig. 6.34). **[G 446; N 510; R 435; C 398]**
5. Remove the tendon of the tibialis posterior muscle where it crosses inferior to the talus. Identify the **plantar calcaneonavicular (spring) ligament** (Fig. 6.34). This ligament and the tibialis posterior tendon support the head of the talus and the longitudinal arch.

CHAPTER 7

THE HEAD AND NECK

The study of head and neck anatomy provides a considerable intellectual challenge because the region is packed with small, important structures. These structures are associated with the proximal ends of the respiratory and gastrointestinal systems, the cranial nerves, and the organs of special sense, all of which are found within the region. Dissection of the head and neck provides a special problem in that peripheral structures must be dissected long before their parent structure can be identified. A complete understanding of the region cannot be gained until the final dissection is completed.

SURFACE ANATOMY

Palpate the following structures on the cadaver (Fig. 7.01):

- **Vertex**
- **Supraorbital margin**
- **Nasal bones**
- **Alveolar process of the maxilla**
- **Mental protuberance of the mandible**
- **Zygomatic arch**
- **Zygomatic bone**
- **Angle of the mandible**

SKULL

All of the cranial nerves and many blood vessels pass through openings in the skull. Therefore, the skull is an important tool with which to organize the study of the soft tissues of the head and neck. Parts of the skull will be studied as needed and details will be added as the dissection proceeds.

All parts of the skull are fragile, but the bones of the orbit are exceptionally delicate. The medial wall of the orbit is very easily broken. Never hold a skull by placing your fingers into the orbits.

Anterior View of the Skull [G 588; N 2; R 26; C 480]

Examine the skull from an anterior view and identify (Fig. 7.02):

- **Frontal bone**
  - **Glabella**
  - **Superciliary arch**
  - **Supraorbital notch (foramen)**
- **Nasal bone**
- **Zygomatic bone**
- **Maxilla**
  - **Frontal process**
    - **Infraorbital foramen**
    - **Anterior nasal spine**
    - **Alveolar process**
- **Nasal septum**
- **Mandible**
  - **Alveolar process**
  - **Mental foramen**
  - **Mental protuberance**

Parts of several bones combine to form the following (Fig. 7.02):

- **Nasion** – the junction between the frontal and nasal bones
- **Orbital margin** – formed by three bones (frontal, maxillary, and zygomatic)
- **Anterior nasal aperture** – bounded by the nasal bones and maxillae

Lateral View of the Skull [G 591; N 4; R 25; C 481]

Examine the skull from a lateral view and identify (Fig. 7.03):

- **Parietal bone**
  - **Superior temporal line**
  - **Inferior temporal line**

KEY TO REFERENCES
G = Grant's Atlas, 11th ed., page number
N = Netter's Atlas, 3rd ed., plate number
R = Rohen's Color Atlas of Anatomy, 5th ed., page number
C = Clemente's Atlas, 4th ed., page number

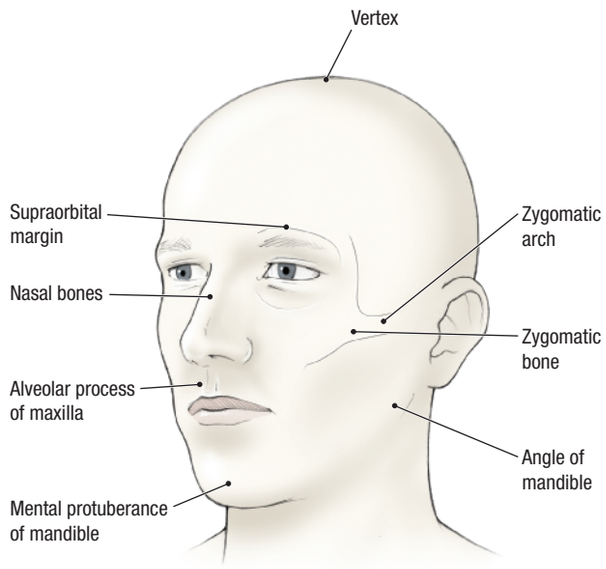

Figure 7.01. Surface anatomy of the face.

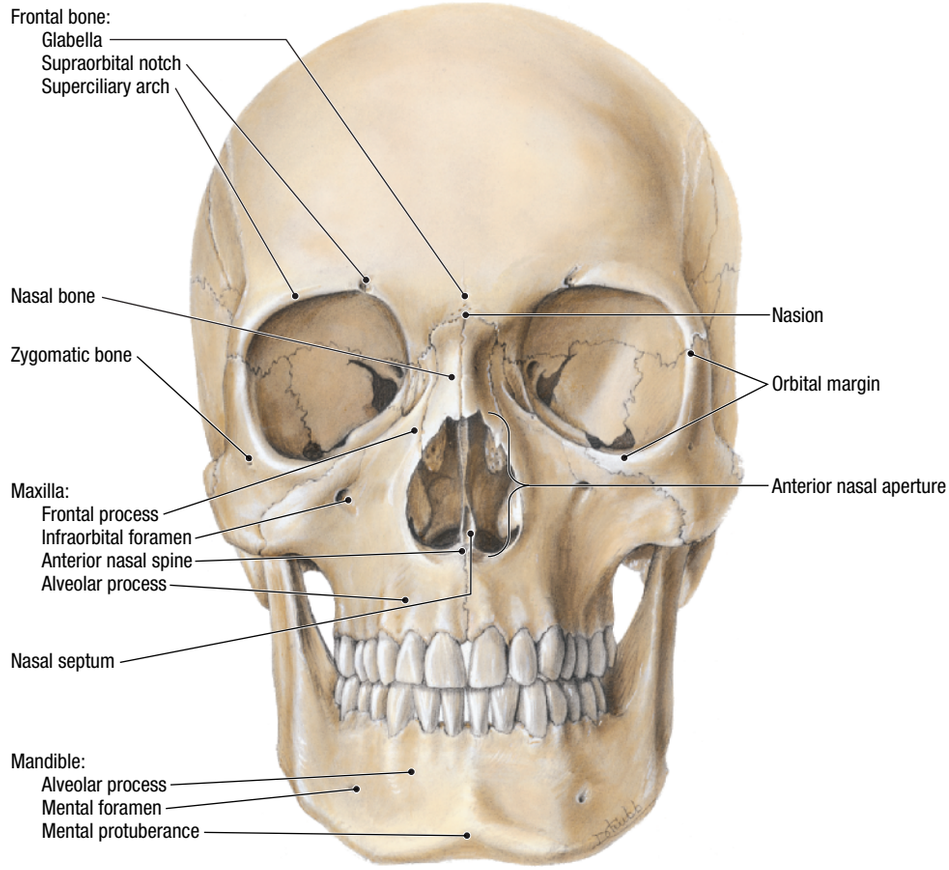

Figure 7.02. The skull, anterior view.

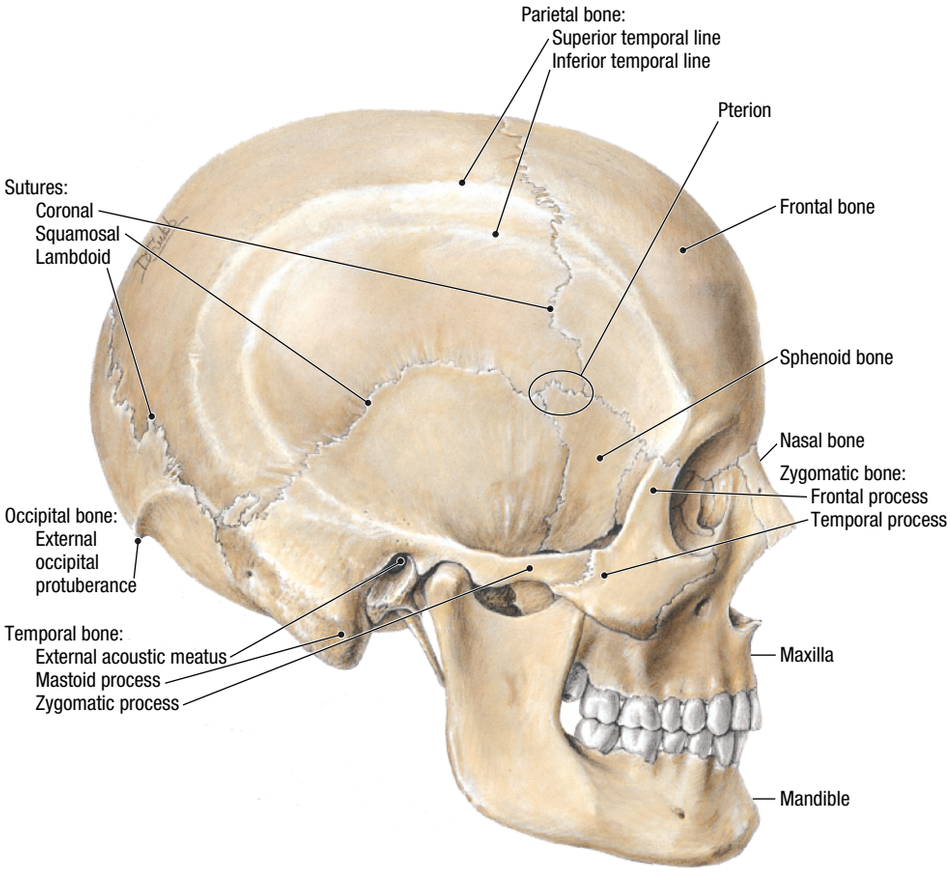

Figure 7.03. The skull, lateral view.

- **Frontal bone**
- **Sphenoid bone**
- **Zygomatic bone**
  - **Frontal process**
  - **Temporal process**
- **Temporal bone**
  - **External acoustic meatus**
  - **Mastoid process**

  Zygomatic process
- **Occipital bone**
  - **External occipital protuberance**
- **Sutures**
  - **Lambdoid**
  - **Squamosal**
  - **Coronal**

In the temporal region, identify the **pterion**. The pterion is the junction of the frontal, parietal, sphenoid, and temporal bones.

- **Mandible** (Fig. 7.04) **[G 654; N 13; R 55; C 543]**
  - **Ramus**
    - **Coronoid process**
    - **Mandibular notch**
    - **Condylar process**
      - **Head (condyle)**
      - **Neck**
  - **Angle**
  - **Body**
    - **Mental foramen**
  - **Inferior border**

Superior View of the Skull [G 592; N 7; R 33; C 482]

The **calvaria** is the skull cap formed by parts of the frontal, parietal, and occipital bones. Examine the external surface of the calvaria and identify (Fig. 7.05):

- **Frontal (metopic) suture** – usually closed in the adult
- **Coronal suture** – separating the large unpaired frontal bone from the two parietal bones
- **Sagittal suture** – separating the two parietal bones
- **Bregma** – the point where sagittal and coronal sutures meet
- **Lambdoid suture** – separating the unpaired occipital bone from the two parietal bones
- **Lambda** – the point where sagittal and lambdoid sutures meet

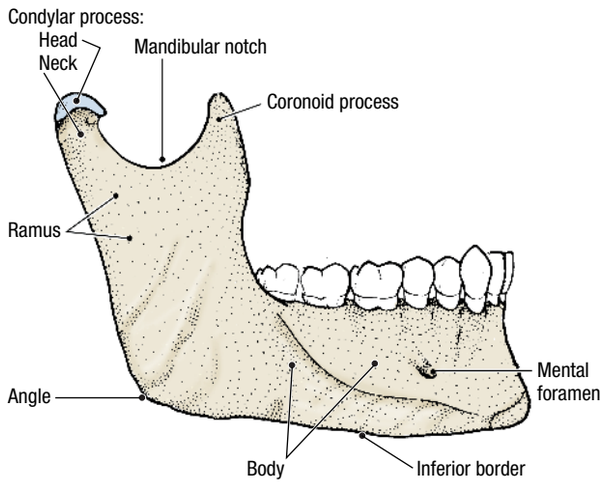

Figure 7.04. The external surface of the mandible.

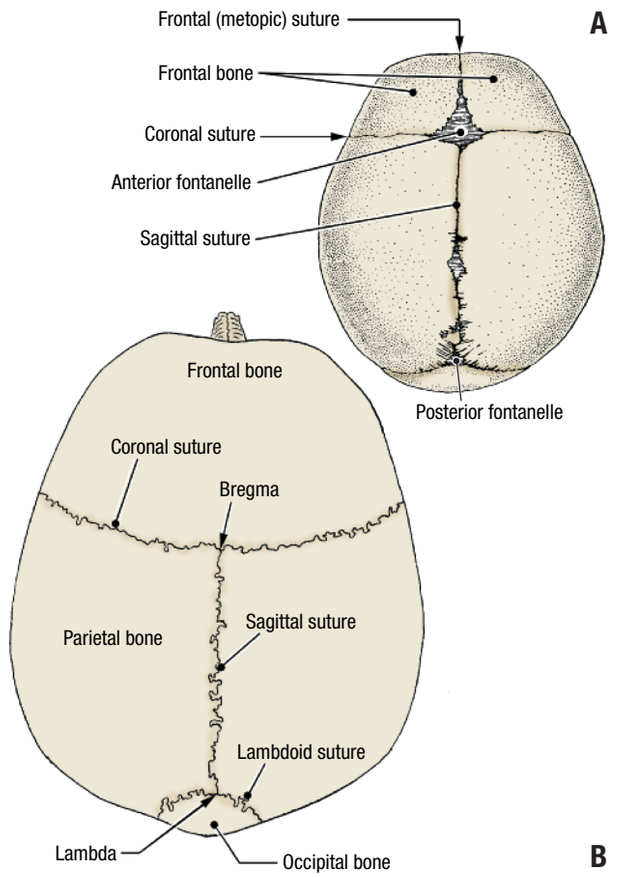

Figure 7.05. Superior view of the calvaria of the skull. **A.** Infant skull. **B.** Adult

FACE

Before you dissect . . .

The skin of the face receives sensory innervation from the trigeminal nerve (V). Three branches (divisions) of the trigeminal nerve share this innervation (Fig. 7.06). The forehead, upper eyelids, and nose are innervated by the **ophthalmic nerve (V_1)**. The lower eyelid, cheek, and upper lip are innervated by the **maxillary nerve (V_2)**. The lower face and part of the side of the head are innervated by the **mandibular nerve (V_3)**. The back of the head and the area around the ear receive sensory innervation from **cervical spinal nerves 2 and 3**. All of the muscles of

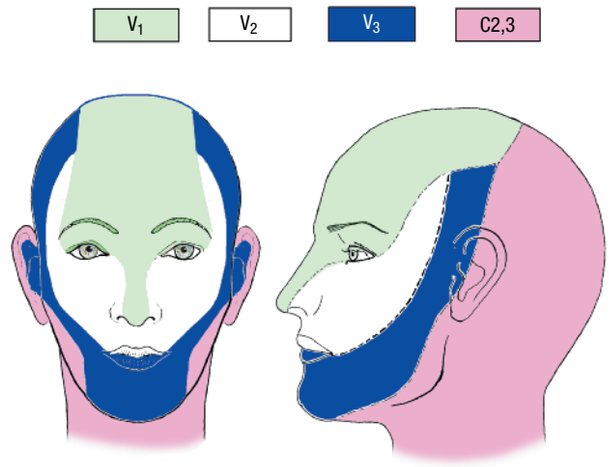

Figure 7.06. Cutaneous nerve distribution of the head and neck.

facial expression receive motor innervation from the **facial nerve (VII)**. [G 605; N 20; C 467]

The order of dissection will be as follows: The skin of the face will be reflected to expose the muscles of facial expression. The parotid duct and gland will be identified. Branches of the facial nerve will be identified as they emerge from the anterior border of the parotid gland. Several facial muscles will be dissected. Two important sphincter muscles will receive particular attention: the orbicularis oris (mouth), and the orbicularis oculi (eye). The terminal branches of the trigeminal nerve will be exposed where they emerge from openings in the skull.

Dissection Instructions

SKIN INCISIONS

The skin of the face is very thin and is firmly attached to the nose and ears but is mobile over other parts of the face. The muscles of facial expression are attached to the skin and act as sphincters and dilators for the openings of the eyes, mouth, and nostrils.

1. Place the cadaver in the supine position and refer to Figure 7.07.
2. In the midline, make a cut from the vertex (A) to the mental protuberance (B). Encircle the mouth at the margin of the lips.
3. On the lateral surface of the head, make a cut from the vertex (A) to the angle of the mandible (D), passing just anterior to the ear.
4. Starting at the nasion (C), make a cut that encircles the orbital margin. Extend the incision from the lateral angle of the eye to the ear.
5. Make a cut from the mental protuberance (B) along the inferior border of the mandible. Stop at the angle of the mandible (D).
6. Remove the skin from the forehead and anterior half of the scalp. Note that the skin adheres to tough subcutaneous connective tissue. Leave this connective tissue intact and do not remove the frontalis muscle. If the skin is raised without difficulty, the plane of separation is deep to the frontalis muscle and its aponeurosis.
7. Remove the skin of the lower face, beginning at the midline and proceeding laterally. The superficial fascia of the face is thick and contains the muscles of facial expression.

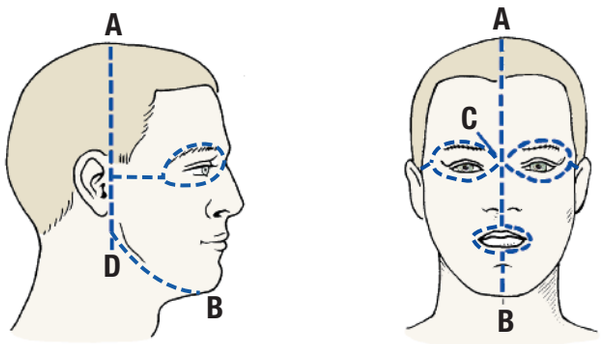

Figure 7.07. Skin incisions.

8. Detach the skin along the line from the vertex to the angle of the mandible (A to D) and place it in the tissue container.

SUPERFICIAL FASCIA OF THE FACE [G 600; N 19; R 76; C 462]

The superficial fascia of the face contains the parotid gland, part of the submandibular gland, muscles of facial expression, branches of the facial nerve, branches of the trigeminal nerve, and the facial artery and vein. The muscles of facial expression are attached to the skin, and these attachments have been severed during skin removal. The goal of this stage of the dissection is to identify a subgroup of the muscles of facial expression and follow branches of the facial nerve posteriorly into the parotid gland.

1. A small part of the **platysma muscle** extends into the face along the inferior border of the mandible (Fig. 7.08). The inferior attachment of the platysma muscle is the superficial fascia of the upper pectoral region and it forms a sheet of muscle that covers the anterior neck. Use blunt dissection to define the superior attachment of the muscle on the inferior border of the mandible, skin of the cheek, and angle of the mouth.
2. Identify the **masseter muscle**. It is a muscle of mastication, which will be dissected later.
3. Identify the **parotid duct** (Fig. 7.08). The parotid duct is approximately the diameter of a probe handle and it crosses the lateral surface of the masseter muscle about 2 cm inferior to the zygomatic arch. Use blunt dissection to follow the parotid duct anteriorly as far as the anterior border of the masseter muscle where the duct turns medially, pierces the buccinator muscle of the cheek, and drains into the oral cavity.
4. Superior to the parotid duct, use blunt dissection to find the **transverse facial artery** (Fig. 7.08). The transverse facial artery is small and it may be difficult to identify.

FACIAL NERVE [G 601; N 21; R 76, 78; C 468]

1. Use a probe to follow the parotid duct posteriorly and identify the anterior margin of the **parotid gland**.
2. Study the branches of the facial nerve in an illustration (Fig. 7.08). Use a probe to dissect along the anterior margin of the parotid gland and find branches of the facial nerve. Move the probe parallel to the branches as you dissect through the superficial fascia. Identify the following:
   - **Temporal branch** – crosses the zygomatic arch
   - **Zygomatic branch** – crosses the zygomatic bone
   - **Buccal branches** – cross the superficial surface of the masseter muscle
   - **Mandibular branch** – parallels the inferior margin of the mandible
   - **Cervical branch** – crosses the angle of the mandible to enter the neck
3. The parotid gland has very tough connective tissue that will not yield to a probe. To follow the branches of the facial nerve into the parotid gland, use the point of a scalpel blade as a probe.

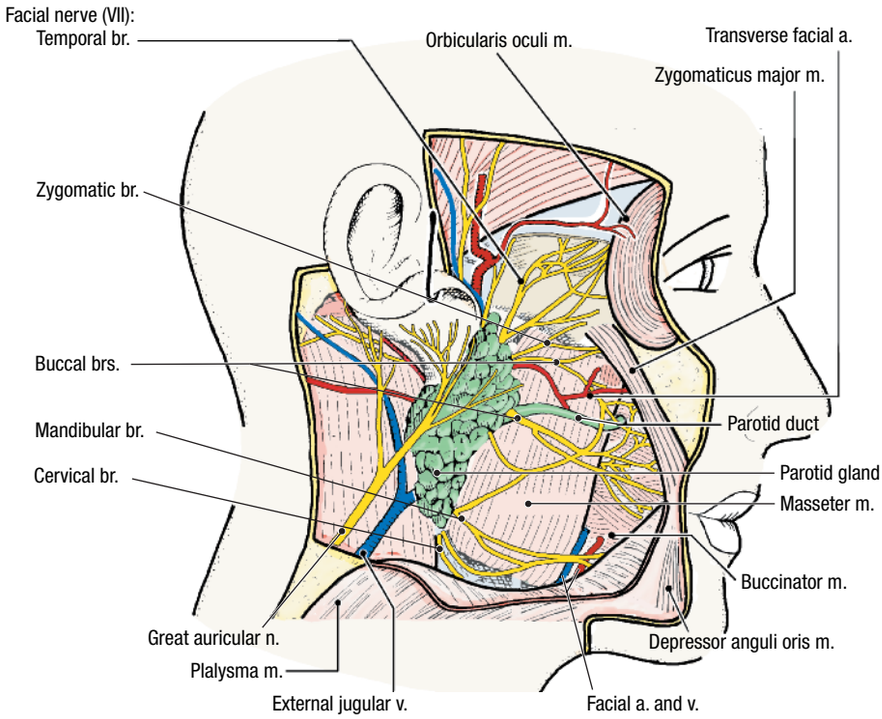

Figure 7.08. Dissection of the lateral aspect of the face.

4. Follow the branches of the facial nerve into the parotid gland. Superficial to the nerves, remove the parotid gland piece by piece. Within the parotid gland the nerve branches join to form the **parotid plexus**. Follow the nerve branches proximally until they combine into one or two nerves, just anterior to the ear lobe.
5. Use a probe to define the anterior border of the **masseter muscle**. Anterior to the masseter is the **buccal fatpad**. Use the probe to remove the buccal fat pad and expose the **buccinator muscle**. Verify that the **parotid duct** pierces the buccinator muscle.
6. Observe that two nerves enter the buccinator muscle:
   - **Buccal branch of the facial nerve** – crosses the superficial surface of the masseter muscle to provide motor innervation to the buccinator muscle.
   - **Buccal nerve**, a branch of the mandibular nerve (V_3) – emerges from deep to the masseter muscle. The buccal nerve does not supply motor innervation to the buccinator muscle. It pierces the buccinator muscle to provide sensory innervation to the mucosa of the cheek. The buccal nerve also innervates the skin of the cheek.

FACIAL ARTERY AND VEIN [G 600; N 19; R 79; C 469]

The facial artery and vein run a winding course across the face and they may pass either superficial or deep to the muscles of facial expression.

1. Starting at its posterior margin, use a probe to lift the platysma muscle. Cut the platysma muscle along the inferior border of the mandible and detach it from the angle of the mouth. Reflect the platysma muscle inferiorly to expose the entire length of the margin of the mandible (Fig. 7.08).
2. Find the **facial artery** where it crosses the mandible at the anterior border of the masseter muscle. At this location the facial artery is covered only by skin and the platysma muscle (Fig. 7.08). Note that the facial artery passes deep to the submandibular gland in the neck, then becomes superficial where it crosses the inferior border of the mandible.
3. Use a probe to trace the facial artery toward the angle of the mouth and observe that the facial artery has several loops or bends in this part of its course. Near the angle of the mouth, the facial artery gives off the **inferior labial** and **superior labial arteries**.
4. Continue to trace the facial artery as far as the lateral side of the nose, where its name changes to **angular artery**.
5. The **facial vein** crosses the mandible posterior to the facial artery and it receives tributaries that correspond to the branches of the facial artery.

MUSCLES AROUND THE ORBITAL OPENING [G 600; N 22; R 60; C 462]

1. At only 1-2 mm in thickness, the skin of the eyelids is the thinnest skin in the body. Carefully skin the upper and lower eyelids.
2. Identify the **orbicularis oculi muscle**, which encircles the **palpebral fissure** (opening of the eyelid) (Fig. 7.09). The orbicularis oculi muscle has three parts:
   - **Orbital part** – surrounds the orbital margin and is responsible for the tight closure of the eyelid.
   - **Palpebral part** – a thinner portion, which is contained in the eyelids and is involved in blinking of the eyelid.
   - **Lacrimal part** – lies deep to the palpebral part and will not be seen in dissection.

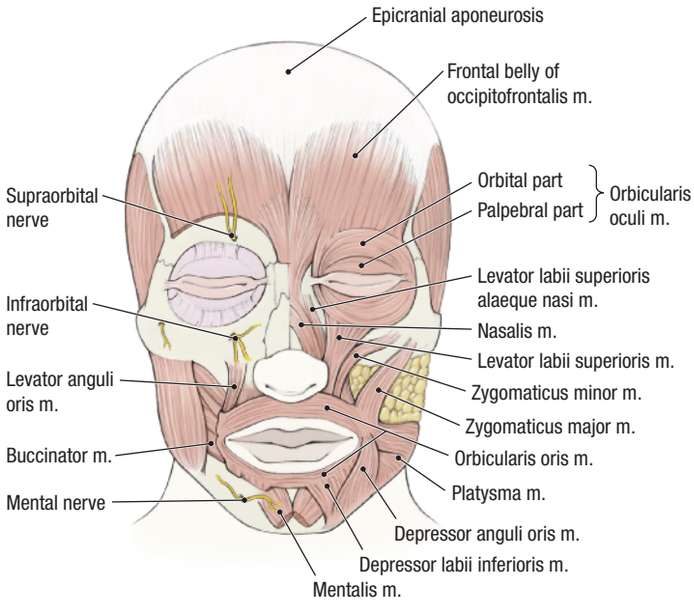

Figure 7.09. Muscles of the face.

3. Note that the medial attachment of the orbicularis oculi muscle is the medial orbital margin, the medial palpebral ligament, and the lacrimal bone. The lateral attachment of the orbicularis oculi muscle is the skin around the orbital margin.

MUSCLES AROUND THE ORAL OPENING [G 600, 604; N 22; R 60; C 463]

1. Several muscles alter the shape of the mouth and lips. Use a probe to define some of these muscles (Fig. 7.09):
   - **Levator labii superioris muscle** – has a superior attachment to the maxilla just below the orbital margin and an inferior attachment to the upper lip. It elevates the upper lip.
   - **Zygomaticus major muscle** – has a lateral attachment to the zygomatic bone and a medial attachment to the angle of the mouth. It draws the angle of the mouth superiorly and posteriorly.
   - **Orbicularis oris muscle** – has medial attachments to the maxilla, mandible, and skin in the median plane and a lateral attachment to the angle of the mouth. The orbicularis oris muscle is the sphincter of the mouth.
   - **Buccinator muscle** – has proximal attachments to the pterygomandibular raphe and the lateral surfaces of the alveolar processes of the maxilla and mandible. The distal attachment of the buccinator muscle is the angle of the mouth. It compresses the cheek against the molar teeth, keeping food on the occlusal surfaces during chewing.
   - **Depressor anguli oris muscle** – has an inferior attachment to the mandible and a superior attachment to the angle of the mouth. It depresses the corner of the mouth.

CLINICAL CORRELATION

Facial Nerve

Bell's Palsy is a sudden loss of control of the muscles of facial expression on one side of the face. The patient presents with drooping of the mouth and inability to close the eyelid on the affected side.

2. On the right side, use blunt dissection to define the borders of the levator labii superioris muscle. Transect the muscle close to the infraorbital margin and reflect it inferiorly to expose the **infraorbital nerve (V_2)**. The infraorbital nerve supplies sensory innervation to the inferior eyelid, side of the nose, and upper lip.

CLINICAL CORRELATION

Study the infraorbital foramen and infraorbital canal in the skull. For purposes of dental anesthesia, the infraorbital nerve may be infiltrated where it emerges from the infraorbital foramen.

LOWER LIP [G 604; C 469]

1. Make a midline incision through the entire thickness of the lower lip, extending as far inferiorly as the mental protuberance. On the right side, make a second incision parallel to the first. The second incision should begin at the angle of the mouth and end at the margin of the mandible. Reflect the flap of lip inferiorly.
2. Cut through the mucous membrane where it reflects from the lip to the gums. Use blunt dissection to peel the flap of lip from the bone and locate the **mental foramen** (L., *mentum*, chin). The mental foramen is located approximately 3 cm from the median plane.
3. Observe that the **mental nerve, artery, and vein** emerge from the mental foramen. The mental nerve supplies sensory innervation to the lower lip and chin.

SENSORY NERVES OF THE FACE [G 604; N 20; R 73; C 469]

1. Use an illustration to summarize the sensory nerves of the face (Fig. 7.10):
   - **Supraorbital nerve** – a branch of the ophthalmic nerve (V_1) that passes through the supraorbital notch (foramen). It will be dissected later.
   - **Infraorbital nerve** – a branch of the maxillary nerve (V_2) that passes through the infraorbital foramen.
   - **Mental nerve** – a branch of the mandibular nerve (V_3) that passes through the mental foramen.
2. There are several smaller branches of the trigeminal nerve that innervate the facial region (lacrimal, infratrochlear, zygomaticofacial, zygomaticotemporal, etc.). Do not dissect these branches. The auriculotemporal nerve (a branch of V_3) will be dissected later.

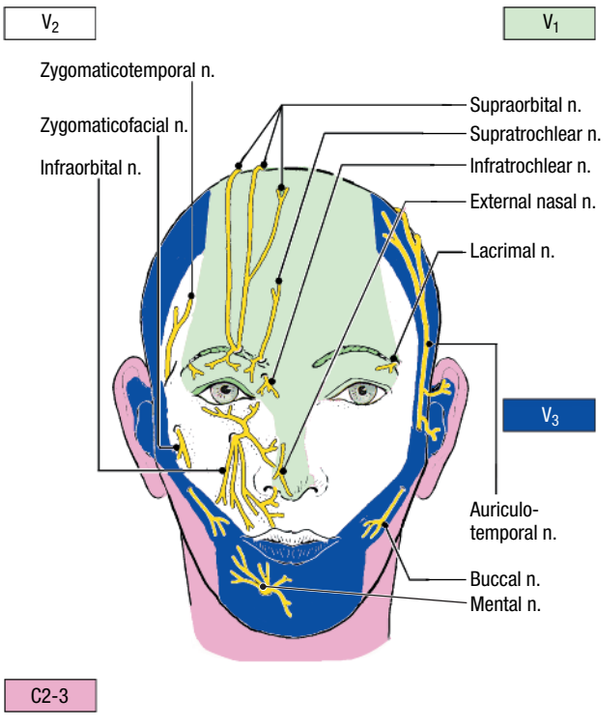

Figure 7.10. Sensory nerves of the face.

After you dissect . . .

Use the dissected specimen to trace the branches of the facial nerve from the parotid plexus to the muscles of facial expression. Review the attachments, action, and innervation of each muscle that was identified in this dissection. Use a skull and the dissected specimen to review the branches of the trigeminal nerve that were dissected and the openings in the bones that they pass through. Use an illustration and the dissected specimen to review the origin and course of the facial artery and vein.

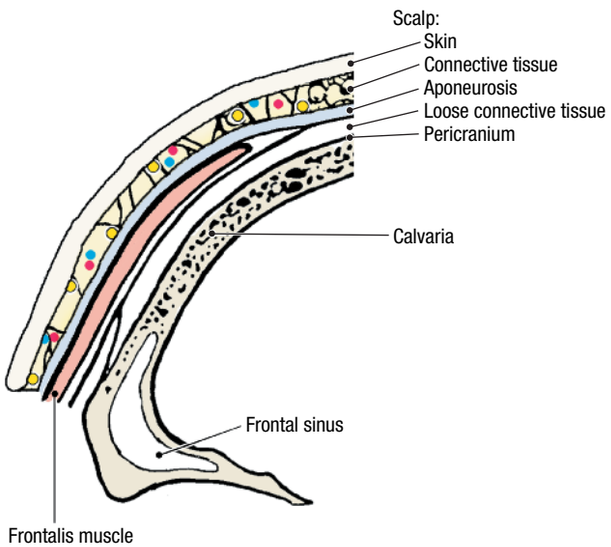

Figure 7.11. Layers of the scalp.

SCALP [G 610; R 85; C 486]

Before you dissect . . .

The scalp consists of five layers that are firmly bound together (Fig. 7.11):

- **Skin**
- **Connective tissue** – dense subcutaneous tissue containing the vessels and nerves of the scalp
- **Aponeurosis** (epicranial aponeurosis) – connecting the frontalis muscle to the occipitalis muscle
- **Loose connective tissue** – permits the scalp to move over the calvaria
- **Pericranium** – the periosteum of the cranial bones

Note that the first letters of the names of the five layers spell the word "scalp."

CLINICAL CORRELATION

Scalp

The connective tissue layer of the scalp contains collagen fibers that attach to the external surface of the blood vessels. When a blood vessel of the scalp is cut, the connective tissue holds the lumen open, resulting in profuse bleeding.

If an infection occurs in the scalp, it can spread within the connective tissue layer. Therefore, this layer has been called the "dangerous area." From the "dangerous area," the infection may pass into the cranial cavity through emissary veins.

The order of dissection will be as follows: The five layers of the scalp will be reflected as one. The muscles of the scalp will be examined on the cut surface of the scalp. Nerves and vessels that supply the scalp will be dissected in other regions, but they will not be dissected in the scalp.

Dissection Instructions

1. The cuts should be made through the entire scalp and the scalpel should contact the bones of the calvaria.
2. Refer to Figure 7.12 and make a midline cut from the nasion (C) to the vertex (A). Extend this cut to the external occipital protuberance (G).
3. Make a cut in the coronal plane from the vertex (A) to the ear (D). Duplicate this cut on the opposite side of the head.
4. Beginning at the vertex, use forceps to grasp one corner of the cut scalp and insert a chisel between the scalp and the calvaria. Use the chisel to loosen the scalp from the calvaria.
5. Once the flap of scalp is raised, grasp the flap with both hands and pull it inferiorly. Do not detach the flaps.
6. Reflect all four flaps of scalp down to the level that a hatband would occupy (Fig. 7.13).

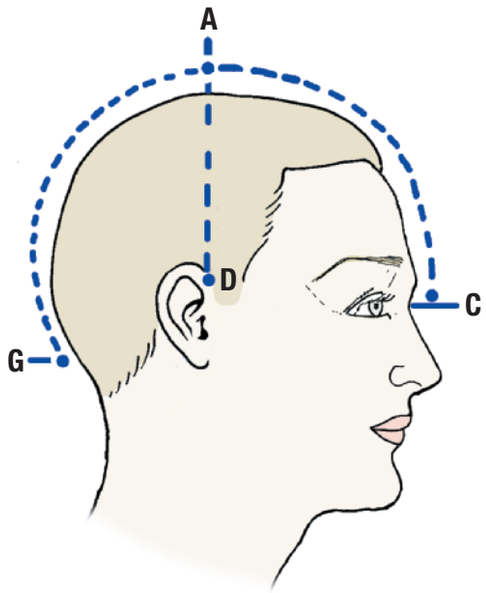

Figure 7.12. Scalp incisions.

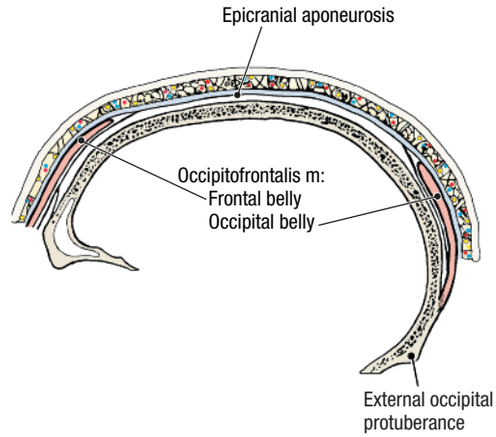

Figure 7.14. The occipitofrontalis muscle in sagittal section.

7. Examine the cut edge of the scalp and identify the **occipitofrontalis muscle** (Fig. 7.14). The inferior attachment of the occipital belly is the occipital bone and its superior attachment is the epicranial aponeurosis. The superior attachment of the frontal belly is the epicranial aponeurosis and its inferior attachment is the skin of the forehead and eyebrows. Both muscles are innervated by the facial nerve (VII). **[G 603, 608; N 19, 22; R 61, 65; C 466, 468]**
8. Pull the anterior scalp flap inferiorly to expose the supraorbital margin. Identify the **supraorbital nerve and vessels** where they exit the supraorbital notch and enter the deep surface of the scalp.
9. Use an illustration to observe that nerves and vessels are contained within the flaps of the scalp (Fig. 7.15). Note that the nerves and vessels enter the scalp from more inferior regions.

After you dissect . . .

Replace the flaps of scalp in their correct anatomical positions. Use an illustration to review the course of nerves and vessels that supply the scalp. Use a skull and the dissected specimen to review the course of the supraorbital nerve through the supraorbital notch. Use an illustration to study the course of the greater occipital nerve from the cervical region to the posterior surface of the head. The auriculotemporal nerve and lesser occipital nerves will be dissected later. Recall the attachments of the occipitofrontalis muscle and review its two bellies in the sagittal scalp cut.

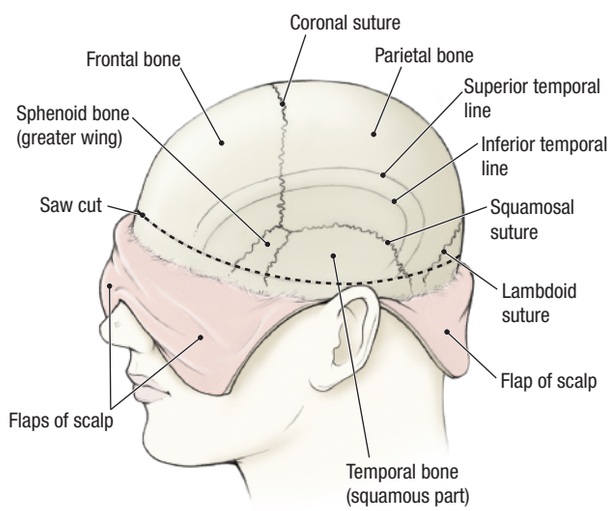

Figure 7.13. How to reflect the scalp and mark the calvaria for sawing.

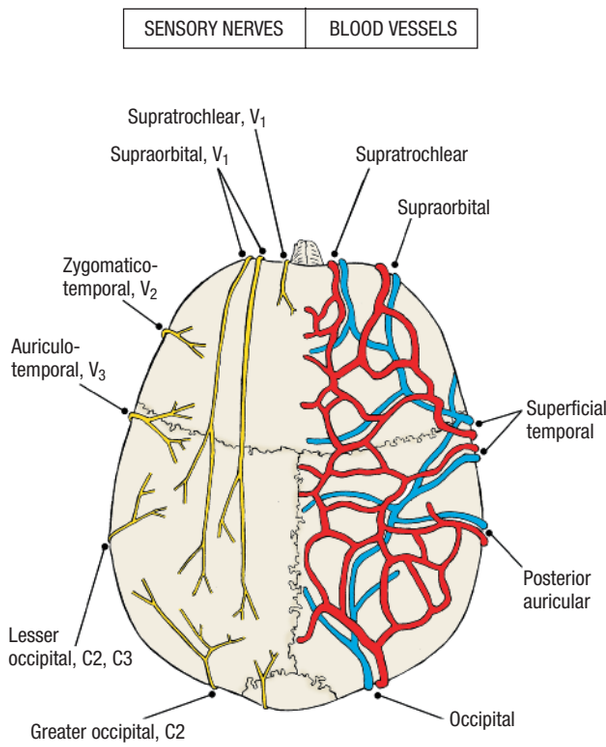

Figure 7.15. Sensory nerves and blood vessels of the scalp.

INTERIOR OF THE SKULL

Before you dissect . . .

The bones of the calvaria provide a protective covering for the cerebral hemispheres. To view the internal features of the cranial cavity, the calvaria must be removed. In addition, a wedge of occipital bone will be removed to open the dissection field and make removal of the brain easier.

The order of dissection will be as follows: The scalp and temporalis muscle will be reflected inferiorly. The calvaria will be cut with a saw and removed. A wedge of occipital bone will be removed. The dura mater will be examined and then opened to reveal the arachnoid mater and pia mater.

Dissection Instructions

REMOVAL OF THE CALVARIA

1. The cadaver should be in the supine position. Fold the flaps of the scalp inferiorly as shown in Figure 7.13.
2. On the lateral surface of the calvaria, note that the scalp has been separated from the fascia that covers the **temporalis muscle (temporal muscle)**. Beginning at the superior temporal line, use a scalpel to detach the temporalis muscle from the calvaria. Reflect the temporalis muscle inferiorly over the reflected scalp but do not transect it. The temporalis muscle will be studied later.
3. Observe the **pericranium** that covers the calvaria. Note that the sutures of the skull are clearly visible. Identify the sagittal, coronal, squamosal, and lambdoid sutures (Fig. 7.13).
4. Use a scalpel or chisel to scrape the bones of the calvaria clean of periosteum and muscle fibers.
5. Place a rubber band around the circumference of the skull (dashed line, Fig. 7.13). Anteriorly, the rubber band should be about 2 cm superior to the supraorbital margin. Posteriorly, the rubber band should be about 2 cm superior to the external occipital protuberance. Use the rubber band as a guide to mark the circumference of the calvaria with a pencil line.
6. Refer to a skull. Remove the calvaria and note that the bones of the calvaria have three layers:
   - **Outer lamina** – compact bone
   - **Diploe** – spongy bone between the outer and inner laminae
   - **Inner lamina** – compact bone
7. Use a saw to cut along the pencil line. The saw cut should pass through the outer lamina of the calvaria but not completely through the bone. Moist red bone indicates that the saw is within the diploe. Be particularly careful when cutting the squamous part of the temporal bone, which is very thin. If you saw through the inner lamina, you may damage the underlying dura mater or the brain.
8. While sawing, turn the body alternately from supine to prone and back to supine as you work your way around the skull. After making a complete circumferential cut, break the inner lamina of the calvaria by repeatedly inserting a chisel into the saw cut and striking the chisel gently with a mallet. Continue with this procedure until the calvaria can be pried loose.
9. Remove the calvaria by detaching it from the dura mater with your fingers or the handle of a forceps. Work from anterior to posterior and do not use more force than is necessary. Violent pulling may result in tearing of the dura and damage to the brain.

REMOVAL OF A WEDGE OF OCCIPITAL BONE

1. Place the cadaver in the prone position and refer to Figure 7.16.
2. Use a scalpel to detach the semispinalis capitis muscle, splenius capitis muscle, obliquus capitis superior muscle, and the rectus capitis posterior major and minor muscles from the occipital bone.
3. Identify the **posterior atlanto-occipital membrane**, which spans the interval between the **atlas** (C1) and the **occipital bone**. Use scissors to incise the posterior atlanto-occipital membrane transversely from the left vertebral artery to the right vertebral artery. Preserve the **vertebral arteries**.
4. Use a scalpel or chisel to scrape the occipital bone clean of remaining muscle fibers and pericranium.
5. Review the following landmarks on a skull (Fig. 7.16): **[G 592; N 4; R 25; C 481]**
   - **Mastoid process**
   - **External occipital protuberance**
   - **Lambdoid suture**
6. On the skull, note the point where the lambdoid suture meets the saw cut where the calvaria was removed. Transfer this point to the cadaver specimen and mark the location with a pencil (Point A, Fig. 7.17).
7. On the skull, examine the internal surface of the **occipital bone** and identify (Fig. 7.18): **[G 615; N 9; R 34; C 497]**
   - **Foramen magnum**
   - **Groove for the superior sagittal sinus**
   - **Grooves for the transverse sinuses**
   - **Fossae for the cerebellum (2)** – inferior to the grooves for the transverse sinuses
   - **Fossae for the occipital poles of the cerebral hemispheres (2)** – superior to the grooves for the transverse sinuses
8. On the external surface of the skull, identify the lateral margin of the foramen magnum and transfer this point to the cadaver specimen (Point B, Fig. 7.17). On the right and left sides of the cadaver, connect points A and B with a pencil line to define the wedge of occipital bone that will be removed in the cadaver.
9. Use a saw to cut along the pencil lines. As in the removal of the calvaria, do not cut through the inner lamina of compact bone. Extend the saw cut into the foramen magnum but preserve the vertebral arteries. Loosen the wedge of bone with chisel and mallet and remove it, leaving the dura mater intact (Fig. 7.19).

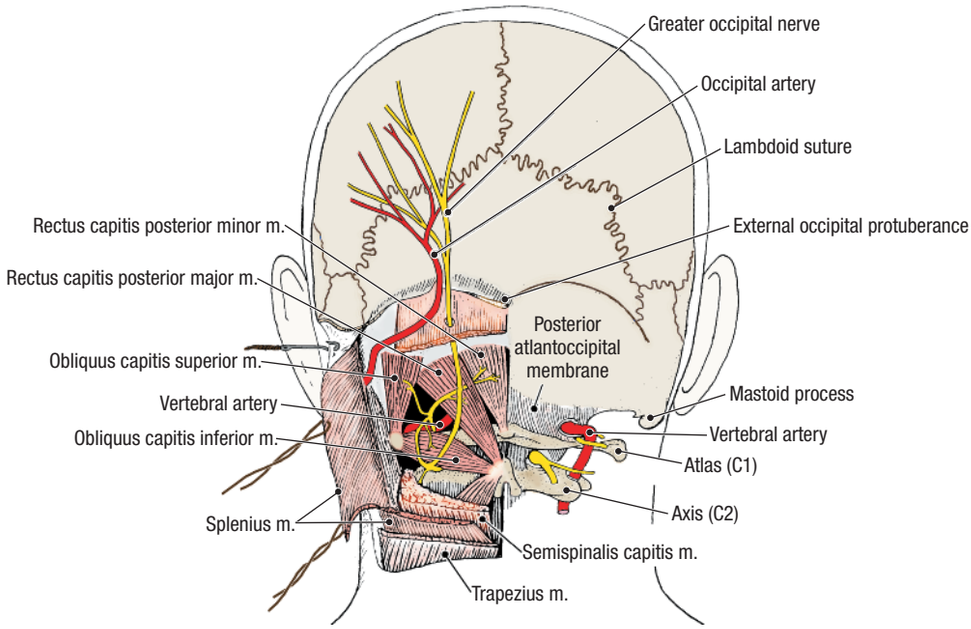

Figure 7.16. Muscles that must be removed to cut an occipital wedge.

CRANIAL MENINGES [G 610; N 96; R 85; C 486]

1. The brain is covered with three membranes called meninges (Gr., *meninx*, membrane). From outside to inside they are (Fig. 7.20):
   - **Dura mater** – the outer tough membrane
   - **Arachnoid mater** – the intermediate membrane
   - **Pia mater** – a delicate membrane that is closely applied to the surface of the brain
2. The **dura mater** (L., *dura mater*, hard mother) consists of two layers, an external **periosteal layer** and an internal **meningeal layer** (Fig. 7.20). The two dural layers are indistinguishable except where they separate to enclose the dural venous sinuses.
3. Identify the **superior sagittal sinus** and the right and left **transverse sinuses** (Fig. 7.19). **[G 611; N 95; C 487]**
4. Use scissors to make a longitudinal incision in the superior sagittal sinus (Fig. 7.21) and verify that:
   - Its inner surface is smooth because it is lined by endothelium.
   - Its caliber increases from anterior to posterior (direction of venous blood flow).
   - It has lateral expansions called **lateral venous lacunae.**
   - **Arachnoid granulations** may be seen in the lateral venous lacunae (Fig. 7.20). The arachnoid granulations return cerebrospinal fluid (CSF) to the venous system.

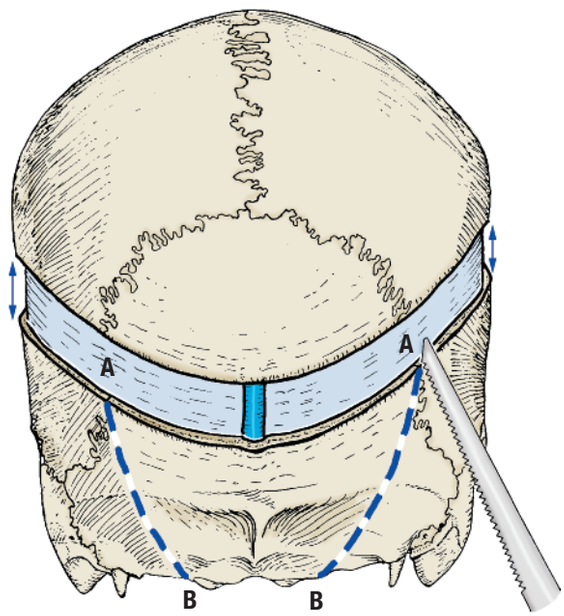

Figure 7.17. How to remove the wedge of occipital bone. Make one saw cut on each side from **A** to **B**.

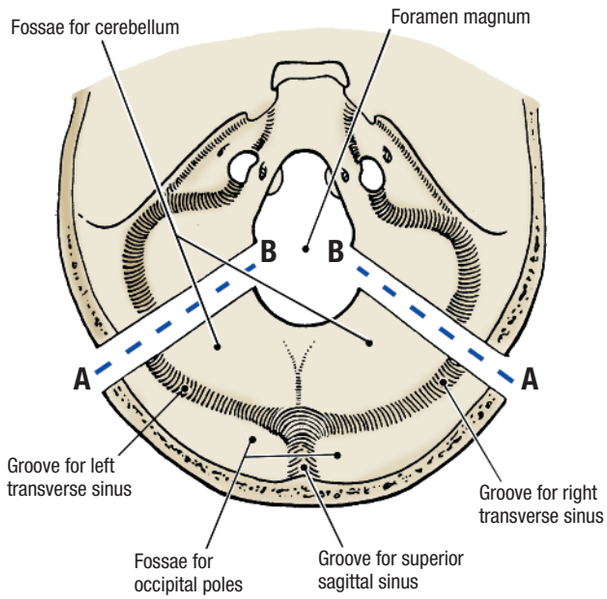

Figure 7.18. Internal surface of the occipital bone. Demarcation of the wedge-shaped area that is to be removed from the occipital bone.

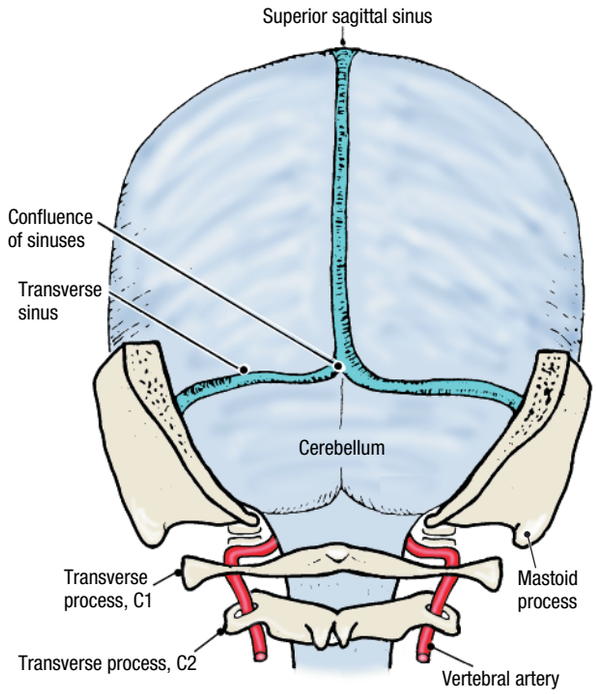

Figure 7.19. Posterior aspect of the dura mater.

5. Examine the dura mater that covers the cerebral hemispheres and observe the branches of the **middle meningeal artery**. The middle meningeal artery supplies the dura mater and adjacent calvaria. Note that the **anterior branch** of the middle meningeal artery crosses the inner surface of the **pterion**, where it may tunnel through the bone. Fractures through this area of the skull may result in tearing of the middle meningeal artery.

CLINICAL CORRELATION

Middle Meningeal Artery

When the middle meningeal artery is torn in a head injury, blood accumulates between the skull and the dura mater (epidural hematoma).

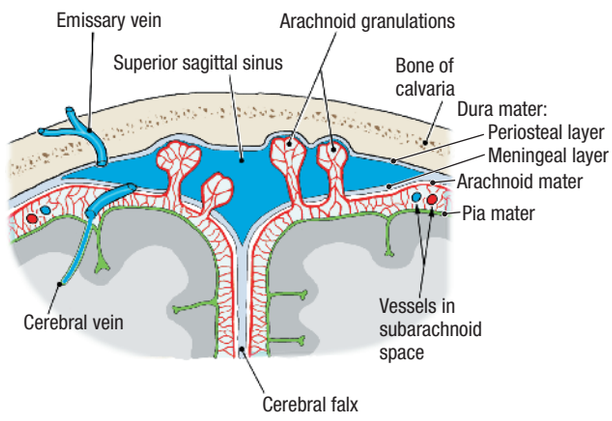

Figure 7.20. Coronal section through the superior sagittal sinus.

6. Examine the inner surface of the removed calvaria. Identify the following features: **[N 7; C 483]**
   - **Groove for the superior sagittal sinus**
   - **Granular foveolae** – shallow depressions caused by the arachnoid granulations
   - **Grooves for the branches of the middle meningeal artery**
7. Use scissors to make a parasagittal cut through the dura mater about 2 cm lateral to the midline (Fig. 7.21). Cut only the dura mater, not the arachnoid mater. This cut should be lateral and parallel to the lateral edge of the superior sagittal sinus. Extend the cut to the frontal bone anteriorly and to the transverse sinus posteriorly. Duplicate the parasagittal cut on the opposite side of the cadaver.
8. Make a coronal cut through the dura mater from the midpoint of the parasagittal cut (near the vertex) to just above the ear (Fig. 7.21). Repeat on the opposite side of the cadaver.
9. The result is a median strip of dura mater containing the superior sagittal sinus and four flaps of dura mater that are similar to the scalp flaps (Fig. 7.21). Fold the dural flaps inferiorly over the cut edge of the skull. Use scissors to detach any small adhesions or blood vessels that constrain the flaps.
10. Observe the **arachnoid mater** (Gr., *arachnoeides*, like a cobweb—in reference to the spider web-like connective tissue strands in the subarachnoid space). The arachnoid mater loosely covers the brain and spans across the fissures and sulci. In the living person, the arachnoid mater is closely applied to the internal meningeal layer of the dura mater with no space between (Fig. 7.20). **[G 611; N 96; R 85]**
11. Observe the **cerebral veins** that are visible through the arachnoid mater. The cerebral veins empty into the superior sagittal sinus. At the point where the cerebral veins enter the sinus they may be torn in cases of head trauma.

CLINICAL CORRELATION

Subdural Hematoma

As a complication of head injury, cerebral veins may bleed into the potential space between the dura mater and the arachnoid mater. When this happens, the blood accumulates between the dura mater and arachnoid mater (a "subdural space" is created), and this condition is called a subdural hematoma.

12. Use scissors to make a small cut (2.5 cm) through the arachnoid mater over the lateral surface of the brain. Use a probe to elevate the arachnoid mater and observe the **subarachnoid space**. In the living, the subarachnoid space is a real space that contains cerebrospinal fluid.

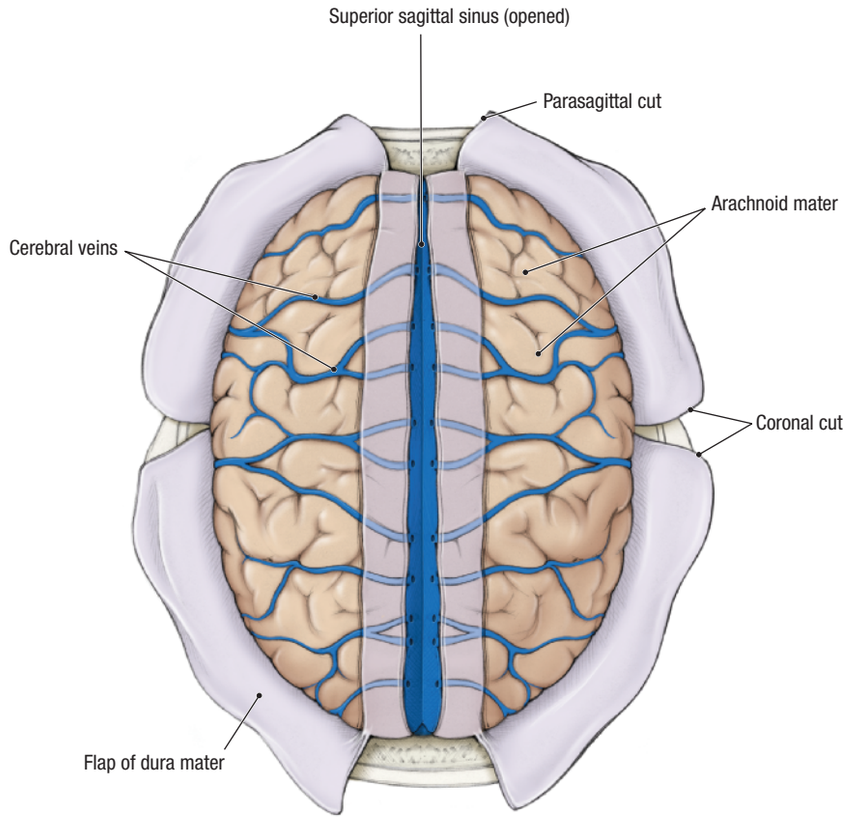

Figure 7.21. Dura mater reflected to show a superior view of the arachnoid mater.

13. Through the opening in the arachnoid mater, observe the **pia mater** (L., *pia mater*, tender mother) on the surface of the brain. The pia mater faithfully follows the contours of the brain, passing into all sulci and fissures. The pia mater cannot be removed from the surface of the brain.

After you dissect . . .

Review the bones that form the calvaria. Review the external features of the cranial dura mater and note that the external periosteal layer is attached to the skull. Review the features of the spinal dura mater and compare it to the cranial dura mater. Review the extradural (epidural) space in the vertebral canal and recall that it contains fat and the internal vertebral venous plexus. Under normal conditions there is no extradural space in the cranial cavity. Compare and contrast the features of an epidural hematoma and a subdural hematoma.

REMOVAL OF THE BRAIN

Before you dissect . . .

The internal meningeal layer of the dura mater forms inwardly projecting folds (dural infoldings) that serve as incomplete partitions of the cranial cavity. Three of these folds (cerebral falx, cerebellar tentorium, and cerebellar falx) extend inward between parts of the brain. These infoldings must be cut to remove the brain.

The order of dissection will be as follows: The brain will be removed intact, along with the arachnoid mater and pia mater. The dura mater will be left in the cranial cavity, where the dural infoldings will be studied.

Dissection Instructions

1. Use a skull to identify the following features (Fig. 7.22): **[G 615; N 9; R 34; C 497]**
   - **Crista galli**
   - **Cribriform plate**
   - **Anterior clinoid process**
   - **Posterior clinoid process**
   - **Superior border of the petrous part of the temporal bone**
   - **Internal acoustic meatus**
   - **Jugular foramen**
   - **Hypoglossal canal**
   - **Foramen magnum**
   - **Groove for the sigmoid sinus**
   - **Groove for the transverse sinus**
2. In the midline, use your fingers to gently retract one cerebral hemisphere 1 or 2 cm laterally and observe the **cerebral falx** (L., *falx*, sickle) between the cerebral hemispheres (Fig. 7.23). The cerebral falx is attached to the **crista galli** at its anterior end and the **cerebellar tentorium** at its posterior end. **[G 612; N 97; R 87; C 489]**

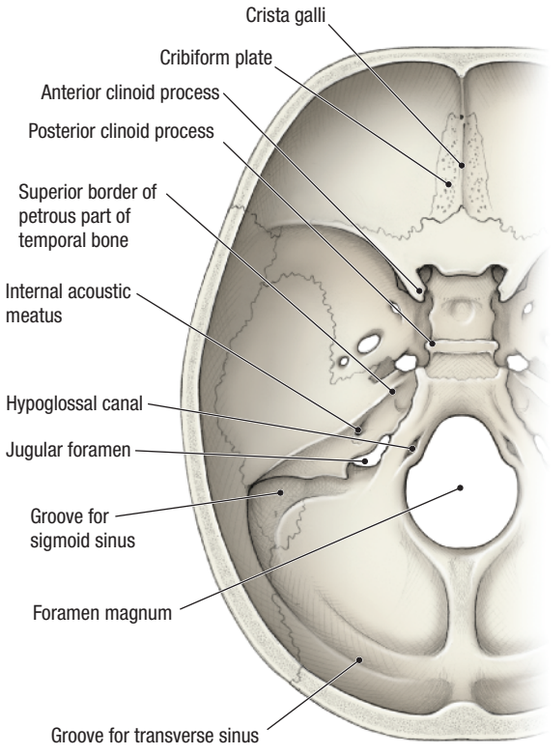

Figure 7.22. Floor of the cranial cavity from the superior view.

3. Use your hand to gently lift the frontal lobes (anterior part of the brain) and use scissors to cut the cerebral falx where it is attached to the crista galli. This cut should connect the anterior ends of the two parasagittal cuts illustrated in Figure 7.21.
4. Use scissors to cut the cerebral veins where they enter the superior sagittal sinus so that the veins will remain on the surface of the brain (Fig. 7.21). Grasp the cerebral falx near the crista galli and pull it superiorly and posteriorly from between the cerebral hemispheres. Posteriorly, the cerebral falx will remain attached to the cerebellar tentorium.
5. On the right side, gently lift the occipital lobe (posterior part of brain) and observe the **cerebellar tentorium**. Beginning anteriorly, use a scalpel to cut the cerebellar tentorium as close to bone as possible. Sever the cerebellar tentorium from the posterior clinoid process and then from the superior border of the petrous part of the temporal bone. The cut should continue to the posterolateral end of the superior border of the petrous part of the temporal bone, near the groove for the sigmoid sinus. Repeat the cut on the left side of the cadaver.
6. Pull the cerebral falx and cerebellar tentorium posteriorly from between the cerebral hemispheres and cerebellum. This procedure will tear the **great cerebral vein** (Fig. 7.24).
7. With the dural infoldings detached, the brain may be gently moved to expose the cranial nerves and vessels that are located on its inferior surface.
8. Use your fingers to gently elevate the frontal lobes. Use a probe to lift the olfactory bulb from the cribriform plate on each side of the crista galli.
9. Use a scalpel to cut the following structures bilaterally: optic nerve, internal carotid artery, and oculomotor nerve. Cut the stalk of the pituitary gland in the midline.
10. Raise the brain slightly higher and cut the following structures bilaterally: trochlear nerve, trigeminal nerve, and abducent nerve.
11. Elevate the cerebrum and brainstem still further and cut the following structures bilaterally: facial and vestibulocochlear nerves near the internal acoustic meatus; glossopharyngeal, vagus and accessory nerves near the jugular foramen; hypoglossal nerve near the hypoglossal canal.
12. Sever the two vertebral arteries where they enter the skull through the foramen magnum and use a scalpel to cut the cervical spinal cord as low in the foramen magnum (or cervical vertebral canal) as you can reach.

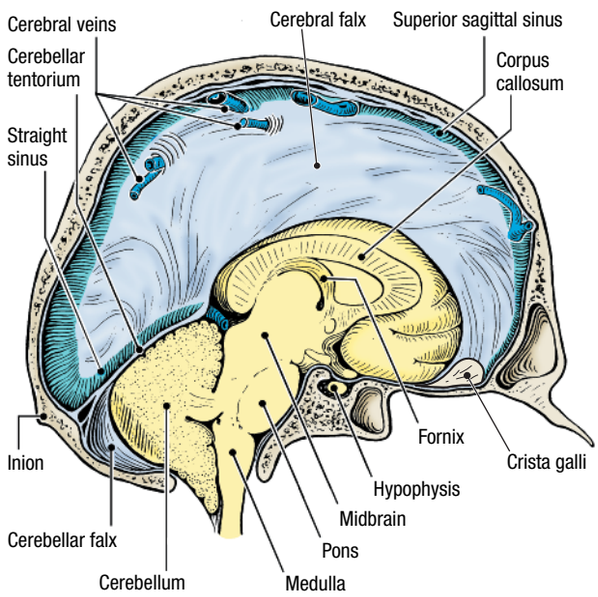

Figure 7.23. Infoldings of dura mater.

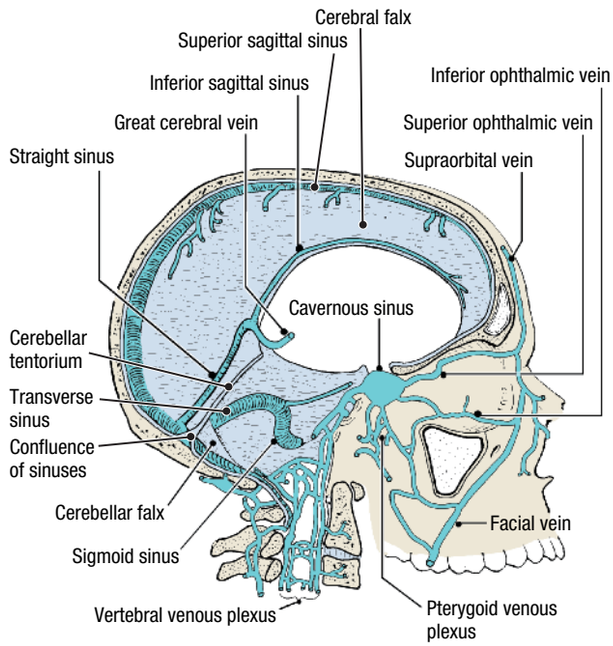

Figure 7.24. Dural venous sinuses.

13. Support the brain with the palm of one hand under the frontal lobes and your fingers extending down the ventral surface of the brainstem. Insert the tip of your middle finger into the cut that was made across the cervical spinal cord to support the brainstem and cerebellum. Roll the brain, brainstem, and cerebellum posteriorly and out of the cranial cavity in one piece.
14. The brain should be stored in a bath of preservative fluid.

DURAL INFOLDINGS AND DURAL VENOUS SINUSES

Before you dissect . . .

The two layers of the dura mater are separated in several locations to form dural venous sinuses. The dural venous sinuses collect venous drainage from the brain and conduct it out of the cranial cavity.

The order of dissection will be as follows: The dura mater will be repositioned to recreate its morphology during life. The infoldings of the dura mater and the associated dural venous sinuses will be identified.

Dissection Instructions

DURAL INFOLDINGS [G 612; N 97; R 87; C 489]

1. Return the dura mater to its correct anatomical position.
2. On the right side of the head, open the two flaps of dura mater and identify the **cerebral falx (falx cerebri)** (Fig. 7.24). In the living person, the cerebral falx lies between the cerebral hemispheres. The cerebral falx is attached to the crista galli, the calvaria on both sides of the groove for the superior sagittal sinus, and the cerebellar tentorium.
3. Identify the **cerebellar tentorium** (**tentorium cerebelli**; L., *tentorium*, tent) (Fig. 7.24). The cerebellar tentorium is attached to the clinoid processes of the sphenoid bone, the superior border of the petrous portion of the temporal bone, and the occipital bone on both sides of the groove for the transverse sinus. The opening in the cerebellar tentorium is called the **tentorial notch (tentorial incisure)**, and the brainstem passes through it. In the living person, the cerebellar tentorium is between the cerebral hemispheres and the cerebellum.
4. Identify the **cerebellar falx (falx cerebelli),** which is located inferior to the cerebellar tentorium in the midline (Fig. 7.24). Note that the cerebellar falx is attached to the inner surface of the occipital bone and that it is located between the cerebellar hemispheres.

DURAL VENOUS SINUSES [G 613; N 98; R 87; C 488]

1. Review the position of the **superior sagittal sinus** (Fig. 7.24). Note that the superior sagittal sinus begins near the crista galli and ends near the cerebellar tentorium by draining into the **confluence of sinuses**.
2. Identify the **inferior sagittal sinus**, which is in the inferior margin of the cerebral falx (Fig. 7.24). The inferior sagittal sinus begins anteriorly and ends near the cerebellar tentorium by draining into the straight sinus. Note that the inferior sagittal sinus is much smaller in diameter than the superior sagittal sinus.
3. The **straight sinus** is located in the line of junction of the cerebral falx and the cerebellar tentorium. At its anterior end, the straight sinus receives the inferior sagittal sinus and the **great cerebral vein**. The straight sinus drains into the confluence of sinuses.
4. Review the position of the **transverse sinuses** (right and left). Each transverse sinus carries venous blood from the confluence of sinuses to the sigmoid sinus. Use a scalpel to open the lumen of the transverse sinus.
5. Identify the **sigmoid sinus**. The sigmoid sinus begins at the lateral end of the transverse sinus and ends at the jugular foramen. Use a scalpel to open the lumen of the sigmoid sinus and trace it to the jugular foramen. The **internal jugular vein** is formed at the external surface of the jugular foramen.
6. Observe the floor of the cranial cavity. Note that the dura mater covers all of the bones and provides openings through which the cranial nerves pass. There are small dural venous sinuses located between the layers of the dura mater in the floor of the cranial cavity. Use an atlas illustration to study the following dural venous sinuses: **[G 613; N 98; R 87; C 494]**
   - **Sphenoparietal sinus**
   - **Cavernous sinus**
   - **Superior petrosal sinus**
   - **Inferior petrosal sinus**
   - **Basilar plexus**

After you dissect . . .

Review the infoldings of the dura mater and obtain a three-dimensional understanding of their arrangements. Trace the route of a drop of blood from a cerebral vein to the internal jugular vein, naming all venous structures encountered along the way. Trace the route of a drop of blood from the sphenoparietal sinus to the sigmoid sinus. Trace the route of a drop of blood from the great cerebral vein to the internal jugular vein.

GROSS ANATOMY OF THE BRAIN

Before you dissect . . .

The study of brain anatomy is highly specialized and is usually reserved for a neuroscience course. The description that is provided here is intended to relate the major features of the external surface of the brain to the parts of the skull that will be studied in subsequent dissections. An additional goal of this study is to establish a mental picture of the continuity of the arteries and nerves of the brain with those same structures that are left behind in the cranial fossae after brain removal.

Dissection Instructions

1. Examine the **lateral surface of the brain** and identify (Fig. 7.25): **[G 626; N 99; R 92]**
   - **Frontal lobe**
   - **Central sulcus**
   - **Parietal lobe**
   - **Occipital lobe**
   - **Lateral sulcus**
   - **Temporal lobe**
2. Identify the **cerebellum** and the **brainstem**.
3. Refer to a skull and identify the **three cranial fossae: anterior**, **middle**, and **posterior** (Fig. 7.25). Use the cadaver specimen and the brain to verify the following: **[N 9; C 496]**
   - The **frontal lobe** is located in the **anterior cranial fossa**.
   - The **temporal lobe** is located in the **middle cranial fossa**.
   - The **cerebellum** is located in the **posterior cranial fossa**.
   - The **occipital lobe** is located superior to the cerebellar tentorium.
   - The **brainstem** becomes continuous with the cervical spinal cord at the **foramen magnum**.
4. Examine the inferior surface of the brain and note that it is covered by arachnoid mater. Use a probe to peel back the arachnoid mater and expose the arteries. Observe the arteries and note the following (Fig. 7.26): **[G 622; N 132; R 93; C 493]**
   - Two vertebral arteries and two internal carotid arteries supply the brain.
   - Each **vertebral artery** gives rise to one **posterior inferior cerebellar artery (PICA)**.
   - The two vertebral arteries combine to form the **basilar artery.**
   - The **basilar artery** gives off the **anterior inferior cerebellar artery**, the **superior cerebellar artery**, and several **pontine branches**.
   - The basilar artery terminates by branching into two **posterior cerebral arteries**.
   - Each posterior cerebral artery gives off a **posterior communicating artery** that anastomoses with the **internal carotid artery**.
   - After giving off the **ophthalmic artery**, each internal carotid artery terminates by dividing into a **middle cerebral artery** and an **anterior cerebral artery**.
   - The anterior cerebral arteries are joined across the midline by the **anterior communicating artery**.
   - The **cerebral arterial circle** is formed by the posterior cerebral, posterior communicating, internal carotid, anterior cerebral, and anterior communicating arteries.
5. On the inferior surface of the brain, identify the **12 cranial nerves** by name and by number (Fig. 7.26).
   - **Olfactory bulb and tract (I)**
   - **Optic (II)**
   - **Oculomotor (III)**
   - **Trochlear (IV)**
   - **Trigeminal (V)**
   - **Abducent (VI)**
   - **Facial (VII)**
   - **Vestibulocochlear (VIII)**
   - **Glossopharyngeal (IX)**
   - **Vagus (X)**
   - **Accessory (XI)**
   - **Hypoglossal (XII)**

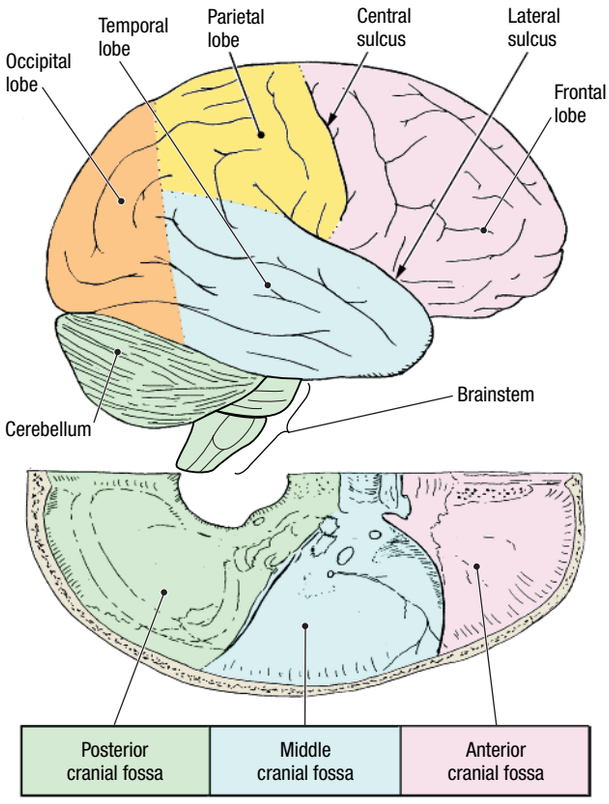

Figure 7.25. The brain and its relationship to the three cranial fossae.

After you dissect . . .

Review the parts of the brain and the cranial fossae in which they are found. Review the infoldings of the dura mater and their relationship to the cerebral hemispheres and cerebellum.

CRANIAL FOSSAE

Before you dissect . . .

The order of dissection will be as follows: The bones of the floor of the cranial cavity will be studied and the boundaries of the cranial fossae will be identified. The vessels and the nerves of each cranial fossa will be studied. Because the floor of the cranial cavity is covered by dura mater, the dissection is much easier if a skull is held beside the cadaver specimen during dissection to permit direct observation of the foramina.

SKELETON OF THE CRANIAL BASE

Use a skull to identify (Fig. 7.27): **[G 614, 615; N 9; R 34; C 497]**

- **Ethmoid bone**
  - **Crista galli**
  - **Cribriform plate**

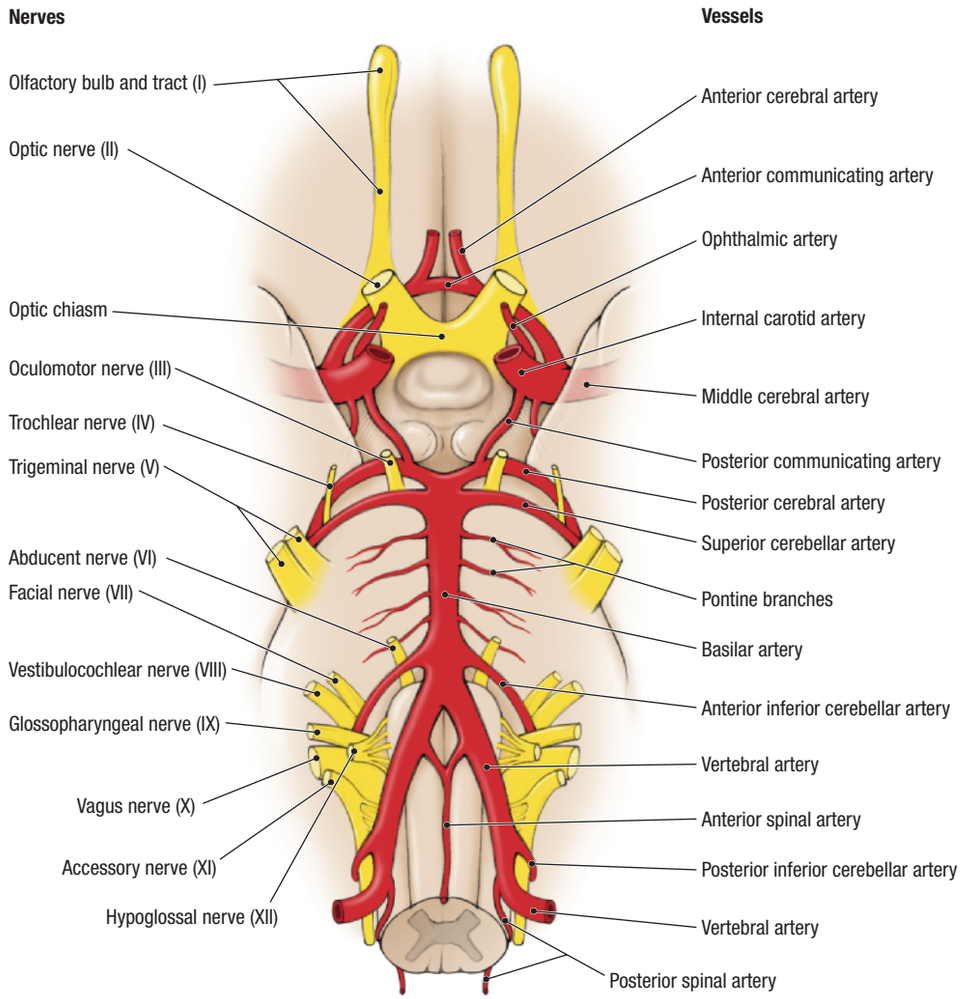

Figure 7.26. Blood vessels and cranial nerves at the base of the brain.

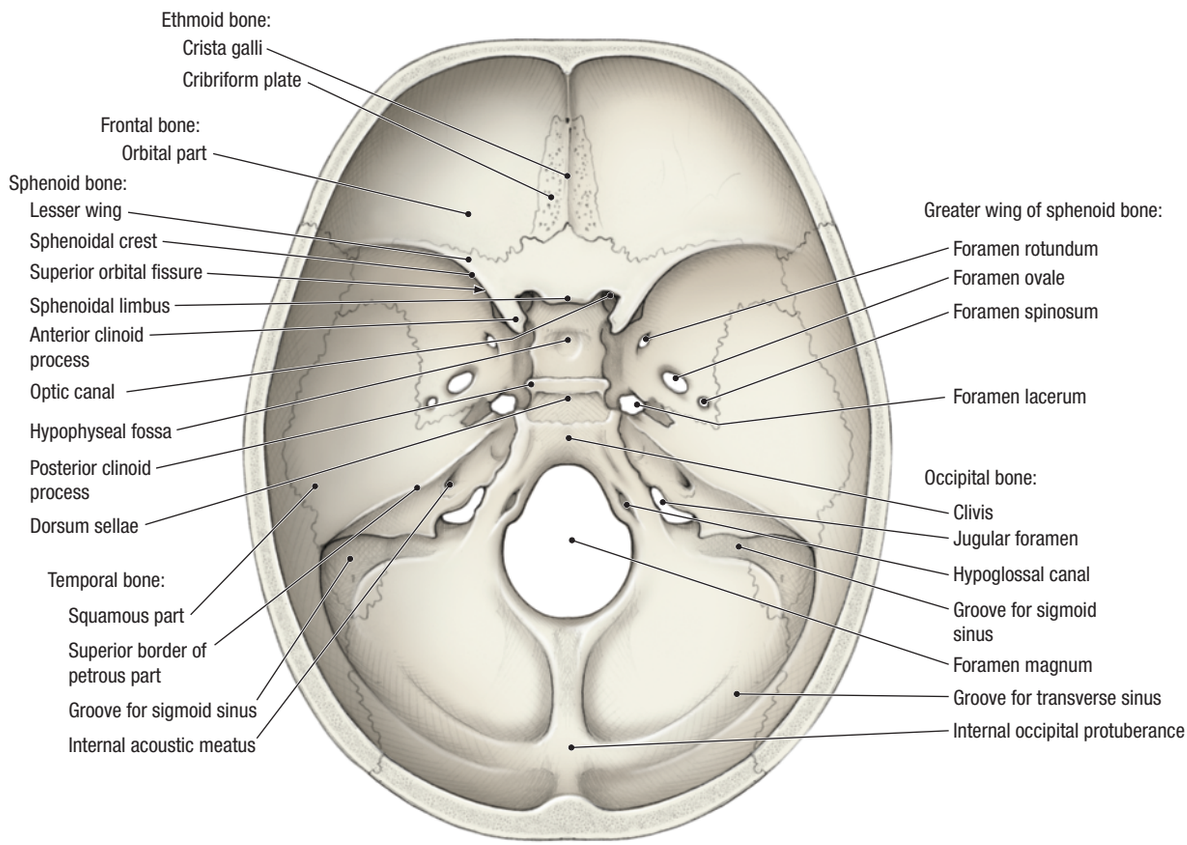

Figure 7.27. Features of the three cranial fossae.

- **Frontal bone**
  - **Orbital part**
- **Sphenoid bone**
  - **Lesser wing**
  - **Sphenoidal crest**
  - **Superior orbital fissure**
  - **Anterior clinoid process**
  - **Sphenoidal limbus**
  - **Optic canal**
  - **Hypophyseal fossa**
  - **Posterior clinoid process**
  - **Greater wing**
    - **Foramen rotundum**
    - **Foramen ovale**
    - **Foramen spinosum**
- **Temporal bone**
  - **Squamous part**
  - **Petrous part**
    - **Superior border (petrous ridge)**
  - **Groove for the sigmoid sinus**
  - **Internal acoustic meatus**
- **Occipital bone**
  - **Clivus**
  - **Jugular foramen**
  - **Hypoglossal canal**
  - **Groove for the sigmoid sinus**
  - **Foramen magnum**
  - **Groove for the transverse sinus**
  - **Internal occipital protuberance**

Identify the **foramen lacerum,** which is formed by portions of the greater wing of the sphenoid bone and the temporal bone.

The **anterior cranial fossa** is separated from the **middle cranial fossa** by the right and left sphenoidal crests and the sphenoidal limbus. The middle cranial fossa is separated from the **posterior cranial fossa** by the superior border of the petrous part of the right and left temporal bones and the dorsum sellae. The cerebellar tentorium is attached to the superior border of the petrous part of the temporal bone and it forms the roof of the posterior cranial fossa.

Dissection Instructions

ANTERIOR CRANIAL FOSSA [G 616; N 98; R 66; C 494]

1. On the right side of the cadaver only, use a probe to loosen the dura mater along the cut edge of the frontal bone. Grasp the dura mater with your fingers and pull it posteriorly as far as the lesser wing of the sphenoid bone. The dura mater will strip from the bone more easily if it is moistened. Use scissors to detach the dura mater along the sphenoidal crest and along the midline and place it in the tissue container.
2. Note that the sphenoparietal venous sinus is located along the sphenoidal crest and that its lumen may now be visible where you detached the dura mater.
3. Identify the three bones that participate in the formation of the **anterior cranial fossa**: sphenoid bone, ethmoid bone, and orbital part of the frontal bone (Fig. 7.27). Note that the orbital part forms the roof of the orbit.
4. Before the brain was removed, the cerebral falx was attached to the crista galli and the frontal lobe of the brain rested on the orbital part of the frontal bone. The olfactory bulb rested on the cribriform plate and the fibers of the **olfactory nerve (I)** passed through the openings of the cribriform plate to enter the nasal cavity (Fig. 7.28).

MIDDLE CRANIAL FOSSA [G 616, 620; N 98; R 71; C 494]

1. Recall that the **middle cranial fossa** contains the temporal lobe of the brain.
2. Observe the dura mater that covers the floor of the middle cranial fossa. The dura mater hides all of the openings in the skull and the nerves and vessels that pass through them (Fig. 7.28).
3. Identify the **middle meningeal artery** that can be seen through the dura mater (Fig. 7.28). It appears as a dark line extending laterally from the deepest point of the middle cranial fossa. The middle meningeal artery enters the middle cranial fossa by passing through the **foramen spinosum**.
4. Grasp the dura mater along the sphenoidal crest and peel it posteriorly as far as the superior border of the petrous part of the temporal bone. Note that the middle meningeal artery adheres to the external surface of the dura mater. Use a probe to tease the proximal part of middle meningeal artery away from the dura mater and leave it in the skull.
5. Use scissors to detach the dura mater along the superior border of the petrous part of the temporal bone and place it in the tissue container. Do not cut the cranial nerves that cross the anterior end of the superior border of the petrous part of the temporal bone (oculomotor, trigeminal, trochlear and abducent). Note that the lumen of the **superior petrosal sinus** can be seen along the line of the cut (Fig. 7.28).
6. Observe that the floor of the middle cranial fossa is formed by two bones: sphenoid and temporal (Fig. 7.27).
7. Identify the **optic nerve (II)** (Fig. 7.28). The optic nerve passes through the **optic canal** to enter the orbit. The optic nerve is surrounded by a sleeve of dura mater as it exits the middle cranial fossa.
8. Use a probe to identify the **superior orbital fissure** that is located inferior to the lesser wing of the sphenoid bone (Fig. 7.27). Three cranial nerves and part of a fourth exit the middle cranial fossa by passing through the superior orbital fissure:
   - **Oculomotor nerve (III)** – passes over the superior border of the petrous part of the temporal bone and passes anteriorly within the wall of the cavernous sinus.
   - **Trochlear nerve (IV)** – courses anteriorly within the wall of the cavernous sinus immediately inferior to the oculomotor nerve (Fig. 7.28). The trochlear nerve is a very small nerve that enters the dura mater at the anterior end of the tentorial notch. It may have been cut during brain removal but should be intact further anteriorly.
   - **Ophthalmic nerve (V_1)** – arises from the trigemi-

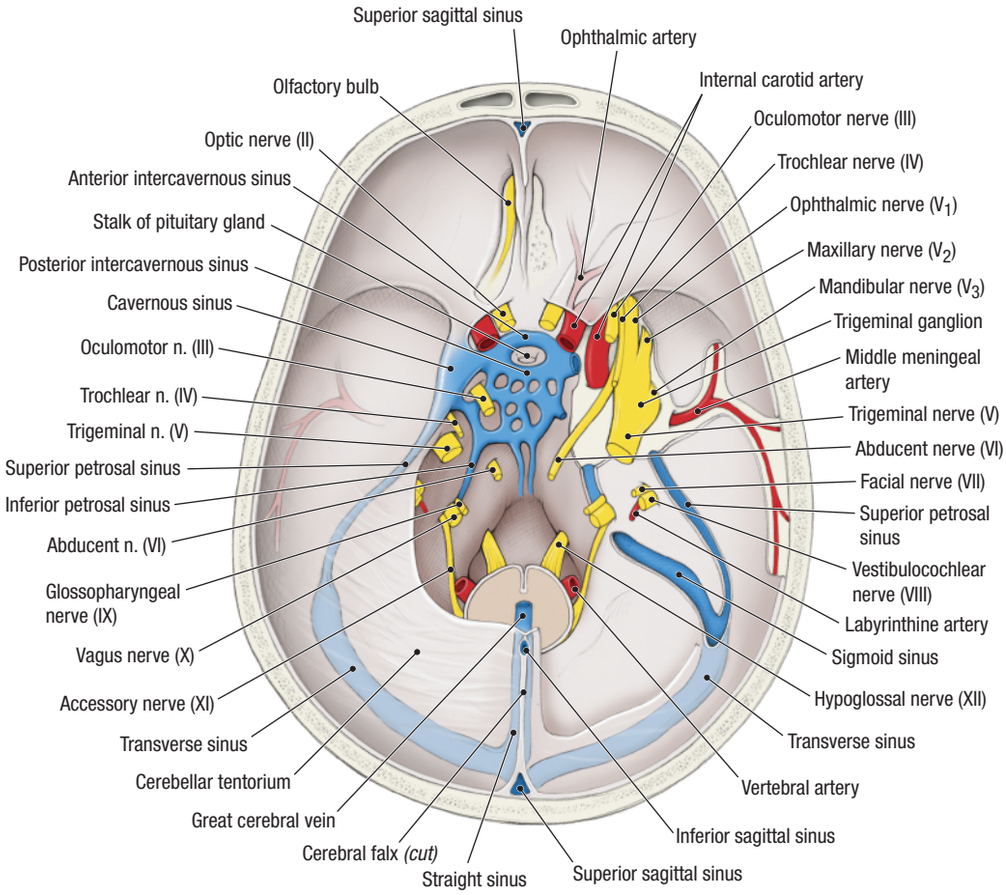

Figure 7.28. Nerves and vessels in the cranial fossae.

nal ganglion and passes anteriorly within the wall of the cavernous sinus inferior to the trochlear nerve (Fig. 7.28).

- **Abducent nerve (VI)** – enters the dura mater over the body of the occipital bone (Fig. 7.28). The abducent nerve passes anteriorly within the cavernous sinus. It is medial to (deep to) the other nerves listed above, and lateral to the internal carotid artery.

9. Use a probe to clean the nerves that pass through the superior orbital fissure. Note that three of these nerves are located within the lateral wall of the cavernous sinus (III, IV, V_1) and one is within the cavernous sinus (VI) (Fig. 7.29).
10. Identify the **trigeminal nerve (V)** (Fig. 7.28). It is the largest cranial nerve and is easily found where it crosses the superior border of the petrous part of the temporal bone.
11. Follow the trigeminal nerve anteriorly to the **trigeminal ganglion**. Use a probe to define the three nerves (divisions) that arise from the anterior border of the trigeminal ganglion [ophthalmic (V_1), mandibular (V_2), and maxillary (V_3)]. Note that these three nerves are named according to their region of distribution and are numbered from superior to inferior as they arise from the trigeminal ganglion.
12. Identify the **maxillary nerve (V_2)** and follow it anteriorly to the **foramen rotundum**, where it exits the middle cranial fossa (Fig. 7.28). The maxillary nerve courses within the lateral wall of the cavernous sinus just inferior to the ophthalmic nerve (V_1) (Fig. 7.29).

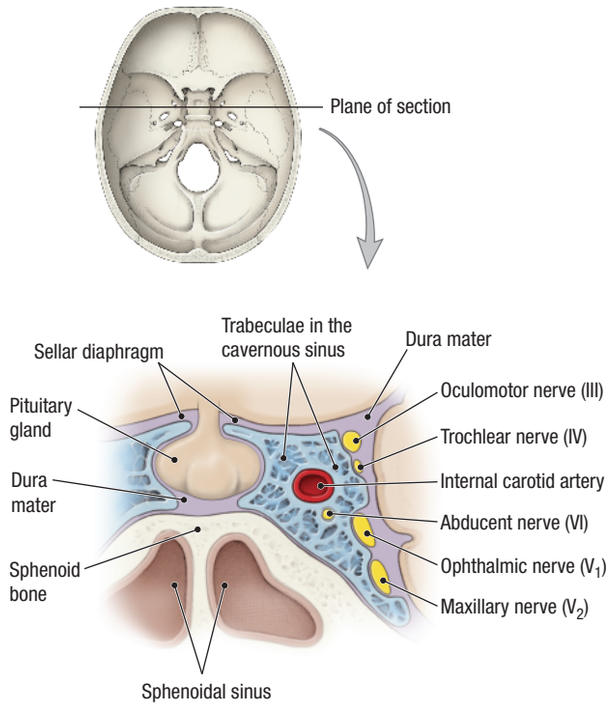

Figure 7.29. Coronal section through the cavernous sinus.

13. Identify the **mandibular nerve (V_3)** and follow it inferiorly to the **foramen ovale**, where it exits the middle cranial fossa (Fig. 7.28).
14. Return to the area of the cavernous sinus and use a probe to retract the cranial nerves. Identify **the internal carotid artery** (Fig. 7.28). The internal carotid artery enters the cranial cavity by passing through the **carotid canal**. It makes an S-shaped bend in the cavernous sinus and emerges near the optic nerve. Cranial nerves III, IV, V_1, V_2, and VI cross the lateral side of the internal carotid artery. Among this group of nerves the abducent nerve (VI) is most closely related to the internal carotid artery (Fig. 7.29).
15. Identify the region of the **hypophyseal fossa**. The hypophyseal fossa is covered by the **sellar diaphragm (diaphragma sellae)** which is a dural infolding (Fig. 7.29). The stalk of the pituitary gland passes through an opening in the sellar diaphragm. The pituitary gland is still contained within the hypophyseal fossa.
16. Anterior and posterior to the stalk of the pituitary gland are two small dural venous sinuses called the **anterior and posterior intercavernous sinuses** (Fig. 7.28). The intercavernous sinuses connect the right and left cavernous sinuses across the midline. Do not attempt to dissect the intercavernous sinuses.
17. Use an atlas illustration to identify all of the veins and venous sinuses that drain into or out of the cavernous sinus. **[G 613; N 98; R 87; C 494]**

CLINICAL CORRELATION

Cavernous Sinus

In fractures of the base of the skull, the internal carotid artery may rupture within the cavernous sinus. The release of arterial blood into the cavernous sinus creates an abnormal reflux of blood from the cavernous sinus into the ophthalmic veins. As a result, the eye is protruded, engorged, and is pulsating in synchrony with the radial pulse (pulsating exophthalmos).

POSTERIOR CRANIAL FOSSA [G 616, 618; N 98; R 69; C 494]

1. Recall that the posterior cranial fossa contains the cerebellum and the brainstem. At the foramen magnum, the brainstem becomes continuous with the cervical spinal cord. The features of the posterior cranial fossa will be studied with the dura mater intact.
2. Identify the **facial nerve (VII)** and the **vestibulocochlear nerve (VIII)** where they enter the internal acoustic meatus (Fig. 7.28). Do not follow them into the bone at this time.
3. The jugular foramen is inferior to the internal acoustic meatus (Fig. 7.27). Identify the rootlets of the **glossopharyngeal nerve (IX)**, the **vagus nerve (X)**, and the **accessory nerve (XI)** where they enter the jugular foramen. During dissection it is not possible to tell where one nerve ends and the next begins, but the **cervical root of the accessory nerve** can be positively identified because it enters the posterior cranial fossa through the foramen magnum and crosses the inner surface of the occipital bone (Fig. 7.28).
4. Identify the **hypoglossal nerve (XII)** where it enters the **hypoglossal canal** (Fig. 7.28).
5. Review the course of the transverse sinus and sigmoid sinus. Observe that the sigmoid sinus ends at the jugular foramen posterior to the exit point of cranial nerves IX, X, and XI.
6. On the left (undissected) side of the cranial cavity, identify the cranial nerves in order from anterior to posterior (Fig. 7.28).

After you dissect . . .

Review the bones that form the floor of the cranial cavity. Read an account of the dural venous sinuses and review them in the cadaver. Summarize the cranial nerves, review the course of each cranial nerve and name the opening through with each passes to exit the cranial cavity. In the skull, review the openings (foramina and fissures) through which the cranial nerves pass. If the brain is still available, hold it beside the cranial cavity so that you can see its ventral surface, and review the cranial nerves and severed vessels on both specimens.

ORBIT

Before you dissect . . .

The orbit contains the eyeball and extraocular muscles. The eyeball is about 2.5 cm in diameter and occupies the anterior half of the orbit. The posterior half of the orbit contains fat, extraocular muscles, branches of cranial nerves, and blood vessels. Vessels and nerves pass through the orbit to reach the scalp and face.

The order of dissection will be as follows: The bones of the orbit will be studied. On the right side only, the floor of the anterior cranial fossa will be removed and the right orbit will be dissected from a superior approach. Cranial nerves III, IV, V_1, and VI will be followed through the superior orbital fissure into the orbit and the extraocular muscles will be identified. The left orbit will be dissected from an anterior approach. On the left side only, the features of the eyelid will be studied and then the eyeball will be removed. The attachments of the extraocular muscles will be studied.

SKELETON OF THE ORBIT

The bones of the orbit form a four-sided pyramid. The base of the pyramid is the orbital margin and the apex of the pyramid is the optic canal. Viewed from above, the medial walls of the two orbits are parallel to each other and about 2.5 cm apart. The lateral walls of the two orbits form a right angle to each other.

Refer to a skull and identify the bones that participate in the formation of the walls of the orbit (Fig. 7.30): **[G 640; N 2; R 46; C 502]**

- **Frontal bone**
  - **Supraorbital notch**
  - **Orbital surface**
  - **Lacrimal fossa**

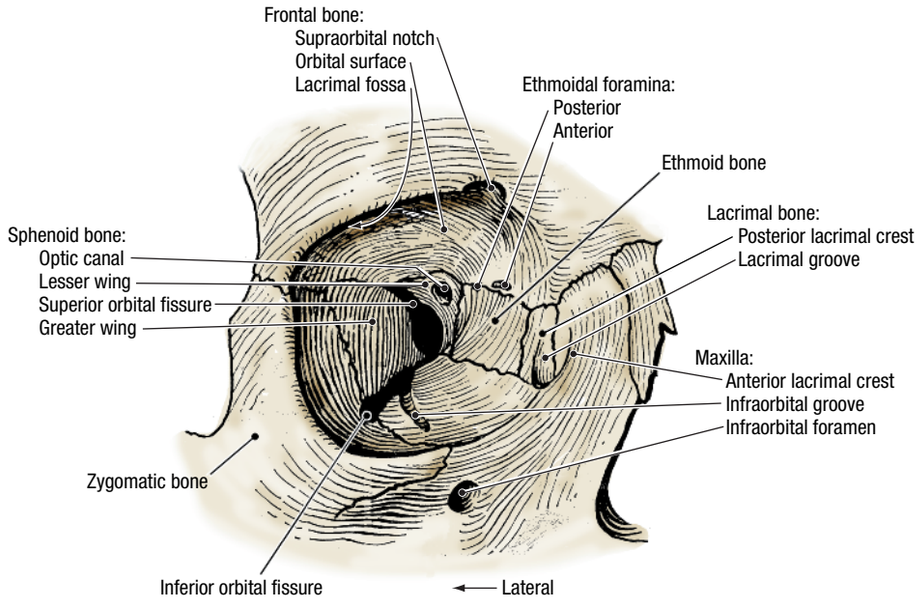

Figure 7.30. Walls of the orbit.

- **Ethmoid bone**
- **Lacrimal bone**
  - **Posterior lacrimal crest**
  - **Lacrimal groove**
- **Maxilla**
  - **Anterior lacrimal crest**
  - **Infraorbital groove**
  - **Infraorbital foramen**
- **Zygomatic bone**
- **Sphenoid bone**
  - **Optic canal**
  - **Lesser wing**
  - **Superior orbital fissure**
  - **Greater wing**

In the suture between the ethmoid and frontal bones, identify the **anterior** and **posterior ethmoidal foramina**.

Identify the **inferior orbital fissure**, which is a gap between the maxilla and the greater wing of the sphenoid bone. Note that the lateral wall of the orbit is stout and strong but the part of the ethmoid bone that forms the medial wall is paper-thin and for this reason it is called the **lamina papyracea**. Examine the topographic relations of the orbit and understand the following (Fig. 7.31):

- **Roof of the orbit** – is related to the anterior cranial fossa.
- **Floor of the orbit** – is related to the maxillary sinus.
- **Medial wall of the orbit** – is related to the ethmoidal cells.

The bones of the orbit are lined with periosteum called **periorbita**. At the optic canal and the superior orbital fissure, the periorbita is continuous with the dura mater of the middle cranial fossa.

SURFACE ANATOMY OF THE EYEBALL, EYELIDS, AND LACRIMAL APPARATUS

Use a mirror or your lab partner to inspect the living eye. Identify: **[G 640, 641; N 77; C 500]**

- **Eyelashes (cilia)**
- **Palpebral fissure (rima)** – the opening between the eyelids
- **Medial and lateral palpebral commissures** – where the upper and lower eyelids join
- **Medial and lateral angles (canthi)** – the medial and lateral corners of the eye
- **Sclera** – the whitish posterior 5/6 of the exterior coat of the eyeball
- **Cornea** – the transparent anterior 1/6 of the exterior coat of the eyeball
- **Iris** – the colored diaphragm seen through the cornea
- **Pupil** – the aperture in the center of the iris

In the medial angle of the eye, observe:

- **Lacrimal caruncle** – a pink fleshy bump
- **Lacrimal lake** – the area surrounding the lacrimal caruncle

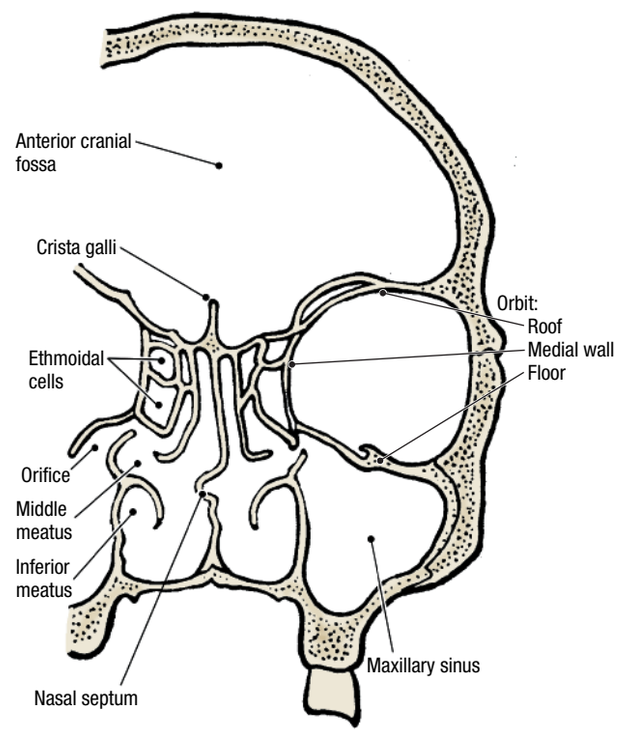

Figure 7.31. Coronal section of the skull to show the relationships of the orbit.

- **Lacrimal papilla** – a small bump on the medial end of each eyelid
- **Lacrimal puncta** – a small opening at the apex of each lacrimal papilla

Evert the lower lid slightly and observe:

- **Margin of the eyelid** – flat and thick
- **Eyelashes (cilia)** – arranged in two or three irregular rows

Use an illustration to study the following features and relate them to the living eye: **[G 645; N 77; R 130; C 509]**

- **Bulbar conjunctiva** – the membrane that lines the surface of the eyeball
- **Palpebral conjunctiva** – the membrane that lines the inner surface of the eyelid
- **Superior and inferior conjunctival fornices** – (L., *fornix*, arch) the regions where the bulbar conjunctiva becomes continuous with the palpebral conjunctiva
- **Conjunctival sac** – the potential space between the bulbar conjunctiva and the palpebral conjunctiva

Dissection Instructions

EYELID AND LACRIMAL APPARATUS [G 641, 645; N 77, 78; R 140; C 506, 507]

1. Dissect the eyelid and lacrimal gland only in the left eye.
2. Review the attachments of the **orbicularis oculi muscle**. Use a probe to raise the lateral part of the **orbital portion of the orbicularis oculi muscle** and reflect the muscle medially.
3. Raise the thin **palpebral portion of the orbicularis oculi muscle** off the underlying **tarsal plate** and reflect the muscle medially.
4. The **orbital septum** is a sheet of connective tissue that is attached to the periosteum at the margin of the orbit and to the tarsal plates (Figs. 7.32, 7.33). The orbital septum separates the superficial fascia of the face from the contents of the orbit.
5. Identify the **tarsal plates**, which give shape to the eyelids (Fig. 7.32). **Tarsal glands** are embedded in the posterior surface of each tarsal plate. Tarsal glands drain by small orifices that are located posterior to the eyelashes. Tarsal glands secrete an oily substance onto the margin of the eyelid that prevents the overflow of lacrimal fluid (tears).

CLINICAL CORRELATION

Tarsal Glands

If the duct of a tarsal gland becomes obstructed, a chalazion (cyst) will develop. A chalazion will be located between the tarsal plate and the conjunctiva. In contrast, a hordeolum (stye) is the inflammation of a sebaceous gland associated with the follicle of an eyelash.

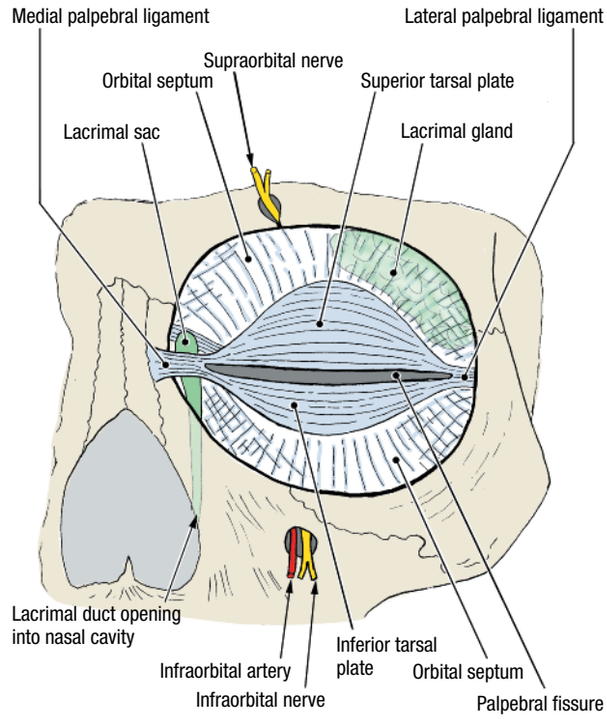

Figure 7.32. Orbital septum and tarsal plates.

6. The **lacrimal gland** occupies the lacrimal fossa in the frontal bone (Fig. 7.32). To find the lacrimal gland, use a scalpel to cut through the orbital septum adjacent to the orbital margin in the superolateral quadrant of the left orbit. Pass a probe through the incision and free the lacrimal gland from the lacrimal fossa. Note that the lacrimal gland drains into the superior conjunctival fornix by 6 to 10 ducts (Fig. 7.34).
7. Use a skull to identify the **lacrimal groove** at the medial side of the orbital margin. Observe that the **anterior lacrimal crest** of the maxilla forms the anterior border of the lacrimal groove. The **medial palpebral ligament** is attached to the anterior lacrimal crest and

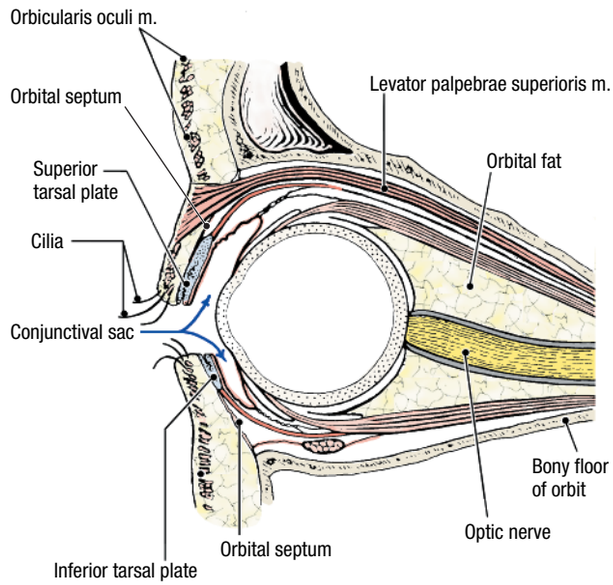

Figure 7.33. Parasagittal section through the orbit.

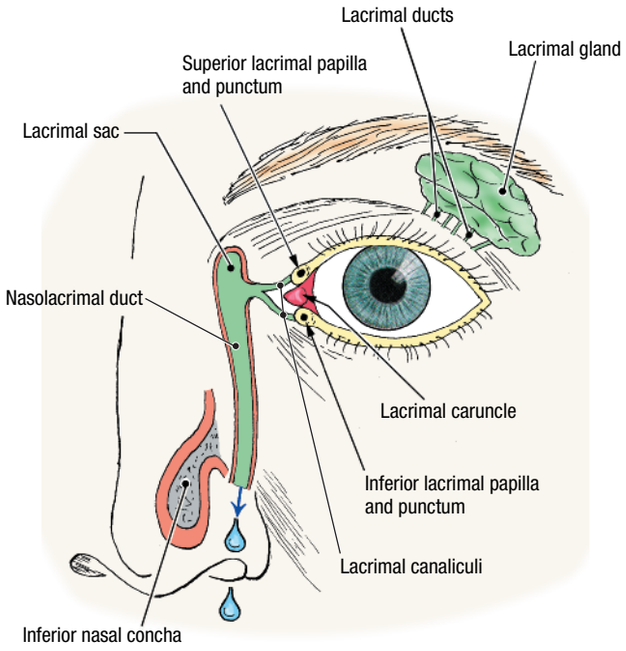

Figure 7.34. Parts of the lacrimal apparatus.

the **lacrimal sac** lies posterior to the medial palpebral ligament (Fig. 7.32).

8. Two **lacrimal canaliculi** drain lacrimal fluid from the medial angle of the eye into the lacrimal sac. The **nasolacrimal duct** extends inferiorly from the nasolacrimal sac and enters the inferior meatus of the nasal cavity (Fig. 7.34).
9. Lacrimal fluid flows from the lacrimal gland across the eyeball to the medial angle of the eye. During crying, excessive lacrimal fluid cannot be emptied through the lacrimal canaliculi and tears overflow the lower eyelids. Increased drainage of tears into the nasal cavity results in sniffling, which is characteristic of crying.

RIGHT ORBIT FROM THE SUPERIOR APPROACH [G 642; N 82; R 138; C 510]

1. Dissect only the right orbit from the superior approach. *Wear eye protection for all steps that require the use of bone cutters.*
2. In the floor of the anterior cranial fossa, use the handle of a chisel to tap the orbital part of the frontal bone until it cracks. Use bone cutters to pick out the bone fragments and enlarge the opening in the **roof of the orbit**. Remove the roof of the orbit as far anteriorly as the superior orbital margin.
3. The frontal bone contains the **frontal sinus** that may extend into the roof of the orbit. Medially, the **ethmoidal cells** may extend into the roof of the orbit. If either situation occurs in your cadaver you must remove the mucous membrane that lines the sinus and remove a second layer of thin bone to open the orbit.
4. Identify the membrane just inferior to the roof of the orbit. This is the **periorbita**, which lines the bones of the orbit.
5. Push a probe posteriorly between the roof of the orbit and the periorbita. The probe should pass inferior to the lesser wing of the sphenoid bone, through the superior orbital fissure, and into the middle cranial fossa. Use the probe to break the lesser wing of the sphenoid bone.
6. Use bone cutters to remove the fragments of the lesser wing of the sphenoid bone. Chip away the roof of the optic canal and remove the anterior clinoid process (Fig. 7.35).
7. Examine the periorbita and note that the frontal nerve may be visible through it. Use scissors to incise the periorbita from the apex of the orbit to the midpoint of the superior orbital margin. Use forceps to lift the periorbita off deeper structures and make a transverse incision through the periorbita, close to the superior orbital margin. Use a probe to tease open the flaps of periorbita and remove them.
8. The use of a fine probe and fine forceps is recommended from this point onward in the dissection.
9. Three nerves enter the apex of the orbit by passing superior to the extraocular muscles:
   - **Frontal nerve** (a branch of V_1) – courses from the apex of the orbit toward the superior orbital margin (Fig. 7.35). Trace the frontal nerve anteriorly and observe that it divides into the **supratrochlear nerve** and the **supraorbital nerve**.
   - **Lacrimal nerve** (a branch of V_1) – passes through the superior orbital fissure lateral to the frontal nerve and courses along the lateral wall of the orbit. The lacrimal nerve is much smaller than the frontal nerve.
   - **Trochlear nerve** – passes through the superior orbital fissure medial to the frontal nerve (Fig. 7.35). Follow the trochlear nerve to the superior border of the **superior oblique muscle**, which it innervates.

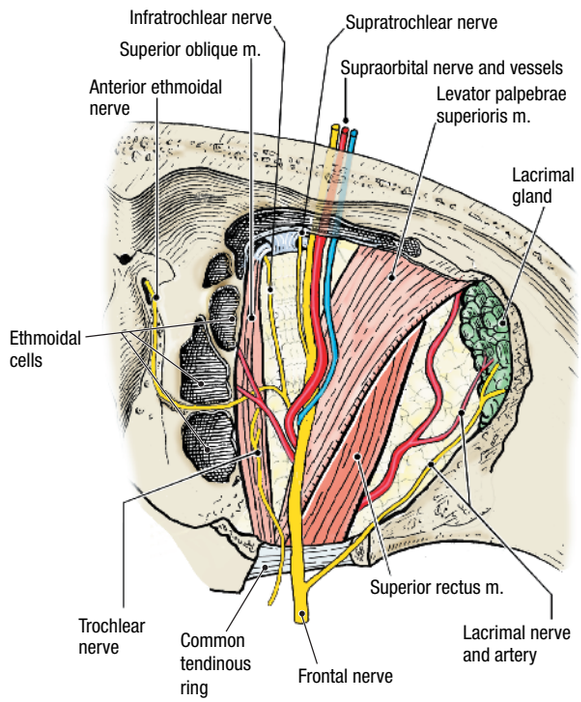

Figure 7.35. Right orbit in superior view.

10. While preserving the nerves, use forceps to pick out lobules of fat and expose the superior surface of the **levator palpebrae superioris muscle** (Figs. 7.33, 7.35). The levator palpebrae superioris muscle attaches to the upper eyelid, which it elevates.
11. Transect the levator palpebrae superioris muscle as far anteriorly as possible and reflect it posteriorly.
12. Identify the **superior rectus muscle** that lies immediately inferior to the levator palpebrae superioris muscle (Figs. 7.33, 7.35). Clean the superior rectus muscle and observe that it is attached to the eyeball by a thin, broad tendon.
13. Transect the superior rectus muscle close to the eyeball and reflect it posteriorly (Fig. 7.36). Note that a branch of the superior division of the **oculomotor nerve (III)** reaches the inferior surface of the superior rectus muscle. A second branch of the superior division passes around the medial side of the superior rectus muscle to innervate the levator palpebrae superioris muscle. **[G 642; N 82; R 139; C 512]**
14. On the medial side of the orbit, identify the **superior oblique muscle** and trace it anteriorly (Fig. 7.36). Observe that the tendon of the superior oblique muscle passes through the trochlea (L., *trochlea*, pulley), bends at an acute angle, and attaches to the posterolateral portion of the eyeball.
15. On the lateral side of the orbit, identify the **lateral rectus muscle** (Fig. 7.36). The lateral rectus muscle arises by two heads from the **common tendinous ring**. The common tendinous ring surrounds the optic canal and part of the superior orbital fissure, and is the proximal attachment of the four rectus muscles. The optic nerve (II), nasociliary nerve, oculomotor nerve (III), abducent nerve (IV), and ophthalmic vein pass through the common tendinous ring.
16. Use scissors to cut the common tendinous ring between the attachments of the superior rectus and lateral rectus muscles. All structures passing through the common tendinous ring are now exposed.
17. Identify the **abducent nerve (VI)**. The abducent nerve passes between the two heads of the lateral rectus muscle, turns laterally, and enters the medial surface of the lateral rectus muscle. Find the abducent nerve on the medial surface of the lateral rectus muscle near the apex of the orbit (Fig. 7.36).
18. Identify the **nasociliary nerve**, which is a branch of V_1 (Fig. 7.36). Trace the nasociliary nerve through the orbit and note that it is much smaller than the frontal nerve. The nasociliary nerve crosses superior to the optic nerve and gives off several **long ciliary nerves** to the posterior part of the eyeball.
19. Follow the nasociliary nerve toward the medial wall of the orbit. Use forceps to pick out the fat that fills the intervals between muscles, nerves, and vessels.
20. Identify the **anterior ethmoidal nerve**, which is a small branch of the nasociliary nerve that passes through the anterior ethmoidal foramen. The anterior ethmoidal nerve enters the cranial cavity, runs lateral to the cribriform plate, and passes through the ethmoid bone to reach the nasal cavity. The anterior ethmoidal nerve supplies part of the mucous membrane in the nasal cavity. Its terminal branch is the **external nasal nerve** that innervates the skin at the tip of the nose.
21. In the middle cranial fossa, identify the **oculomotor nerve** within the lateral wall of the cavernous sinus. Follow the oculomotor nerve to the superior orbital fissure where it branches into two divisions:
    - **Superior division** – innervates the levator palpebrae superioris and the superior rectus muscles
    - **Inferior division** – innervates the medial rectus, inferior rectus, and inferior oblique muscles
22. The **ciliary ganglion** is a parasympathetic ganglion located between the optic nerve and the lateral rectus muscle. It is approximately 2 mm in diameter and is located about 1 cm anterior to the apex of the orbit (Fig. 7.36). Note that short ciliary nerves connect the ciliary ganglion to the posterior surface of the eyeball. Study the autonomic function of the ciliary ganglion.
23. Use an atlas illustration to study the course of the **superior ophthalmic vein** in the orbit. At the medial angle of the eye, the superior ophthalmic vein anastomoses with the angular vein, which is a tributary of the facial vein. **[G 646; N 81; C 475]**

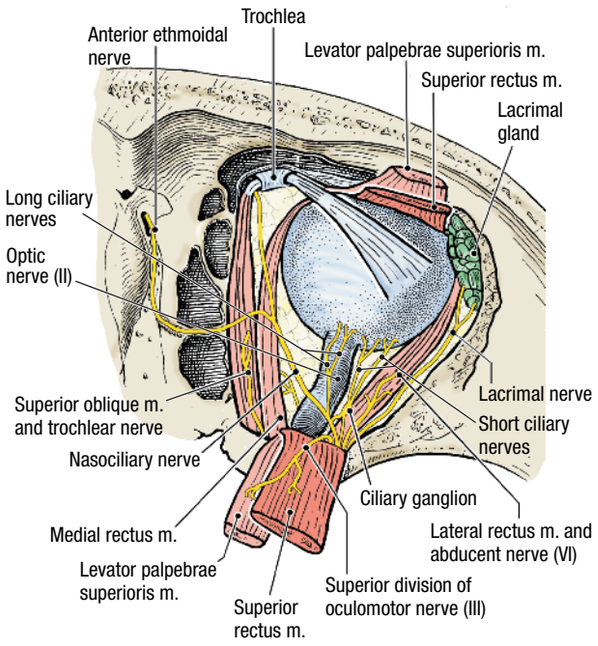

Figure 7.36. Deeper dissection of right orbit in superior view.

CLINICAL CORRELATION

Ophthalmic Veins

Anastomoses between the angular vein and the superior and inferior ophthalmic veins are of clinical importance. Infections of the nasal cavity, upper lip, cheeks, and forehead may spread through the facial and angular veins into the ophthalmic veins and then into the cavernous sinus. Thrombosis of the cavernous sinus may result, leading to involvement of the abducent nerve and dysfunction of the lateral rectus muscle.

24. Identify the **optic nerve (II)** (Fig. 7.36). The optic "nerve" is actually a brain tract and it is surrounded by the three meningeal layers: dura mater, arachnoid mater, and pia mater.
25. Identify the **ophthalmic artery** where it branches from the internal carotid artery (Fig. 7.37). In its course through the orbit, note that the ophthalmic artery courses superior to the optic nerve and reaches the medial wall of the orbit. Use a probe to gently tease out the posterior ciliary arteries that supply the eyeball.
26. The **medial rectus**, **inferior rectus** and **inferior oblique muscles** are not easily seen from the superior approach. They will be identified from the anterior approach.

LEFT ORBIT FROM THE ANTERIOR APPROACH [G 641; N 79; R 133; C 514]

1. Use a probe to explore the **conjunctival sac**. Verify that the conjunctiva is loosely attached to the sclera.
2. To facilitate the dissection, remove both eyelids and the orbital septum. Examine the orbit from the anterior view and note:
   - The **lacrimal gland** is located superolaterally
   - The **trochlea** is located superomedially
   - The attachment of the **inferior oblique muscle** is located inferomedially
3. Review the attachments of the extraocular muscles on the eyeball. The four rectus muscles attach to the sclera near the cornea (Fig. 7.38). The two oblique muscles attach to the sclera on the posterior half of the eyeball.
4. Use a probe to pick up the tendon of each rectus muscle and transect it with scissors (Fig. 7.38).
5. Adduct the eyeball (turn it medially) and pull it anteriorly. Insert scissors into the orbit on the lateral side of the eyeball and cut the optic nerve.

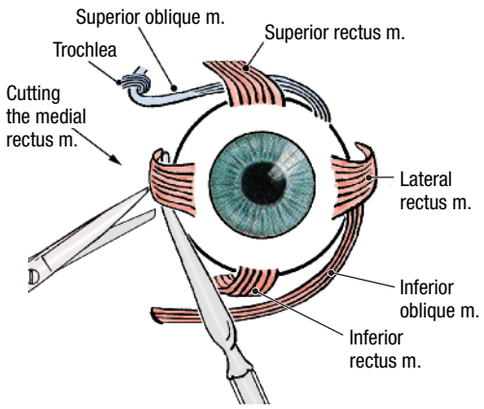

Figure 7.38. How to transect the muscles of the left eye.

6. Pull the eyeball further anteriorly and transect the superior and inferior oblique tendons near the surface of the eyeball and remove the eyeball.
7. Study the orbit (Fig. 7.39). Use forceps to pick out lobules of fat from the posterior portion of the orbit. Find the nerve to the inferior oblique muscle and follow it posteriorly to the **inferior division of the oculomotor nerve (III)**. [G 646; N 79; R 134; C 517]
8. Trace the four rectus muscles to their attachments on the **common tendinous ring**.
9. Identify the structures that pass through the common tendinous ring: **optic nerve (II) and central artery of the retina, superior and inferior divisions of the oculomotor nerve (III)**, **abducent nerve (VI)**, and the **nasociliary nerve** (Fig. 7.39).
10. Examine the cut surface of the optic nerve and try to identify the central artery of the retina, which may be seen as a dark spot on the cut surface.
11. In most cases, the eyeball that is removed from the cadaver is poorly preserved. However, if the eyeball is in dissectible condition, use a new scalpel blade to cut it in half in the coronal plane. Remove the vitreous body.

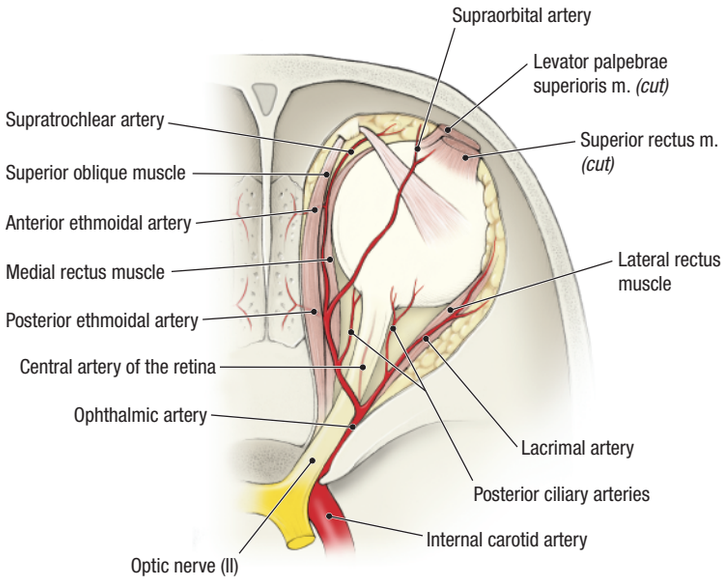

Figure 7.37. Branches of the ophthalmic artery in the right orbit.

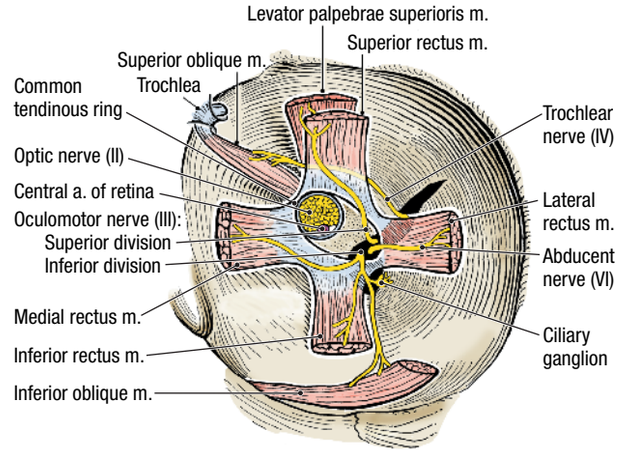

Figure 7.39. The left orbit in anterior view. The common tendinous ring and its relationship to the four rectus muscles and cranial nerves II, III, IV, and VI.

12. Note the following features of the eyeball: [G 650; N 83; R 131; C 519]
    - **Fibrous (outer) layer** – sclera (posterior 5/6) and cornea (anterior 1/6)
    - **Vascular (middle) layer** – choroid, ciliary body and iris
    - **Inner layer** – retina, partially detached in the cadaver
    - **Macula** – only seen in well preserved specimens
    - **Optic disc** – where the optic nerve and retinal vessels enter or leave
    - **Lens** – may be replaced by a prosthetic implant

After you dissect . . .

Use a skull to review the bones that form the margin of the orbit, the walls of the orbit and the openings at the apex of the orbit. Examine the middle cranial fossa and review the optic canal and superior orbital fissure. Use the dissected specimen to review the nerves that pass through the lateral wall of the cavernous sinus and superior orbital fissure to reach the apex of the orbit. Review the orbital course and function of each of these cranial nerves. Review the course of the internal carotid artery through the cavernous sinus and note its relationship to the optic nerve near the optic canal. Note the origin of the ophthalmic artery and its course through the optic canal. Review the course of the optic nerve through the optic canal to the eyeball. Review the attachments of each of the six extraocular muscles. Use the cadaver specimen to find each of the extraocular muscles. Use an illustration to review the movements of the eyeball and relate each movement to the extraocular muscles that are responsible. Review the ciliary ganglion and note the origin of its preganglionic parasympathetic axons and the course of its postganglionic axons to the eyeball. State the function of the muscles that are innervated by the ciliary ganglion.

POSTERIOR TRIANGLE OF THE NECK

Before you dissect . . .

Study a transverse section through the neck (Fig. 7.40). The posterior part of the neck contains the cervical vertebral column and the muscles that move it. The anterior part of the neck houses the cervical viscera. The cervical viscera include: [G 723; N 31; R 152; C 446]

- **Pharynx and esophagus** – the superior parts of the digestive tract
- **Larynx and trachea** – the superior parts of the respiratory tract
- **Thyroid gland and parathyroid glands**

The visceral part of the neck has the following boundaries:

- **Posterior** – the cervical vertebrae
- **Posterolateral** – the scalene muscles
- **Lateral** – the sternocleidomastoid muscle
- **Anterior** – the infrahyoid muscles

Large vessels and nerves lie lateral to the cervical viscera (Fig. 7.40). The **carotid artery** (**internal carotid artery** at more superior levels), **internal jugular vein**, and **vagus nerve** are contained within the **carotid sheath**.

For descriptive purposes the neck is divided into an anterior triangle and a posterior triangle (Fig. 7.41). The **boundaries of the posterior triangle** of the neck are:

- **Anterior** – the posterior border of the sternocleidomastoid muscle
- **Posterior** – the anterior border of the trapezius muscle
- **Inferior** – the middle 1/3 of the clavicle
- **Superficial (roof)** – investing layer of the deep cervical fascia
- **Deep (floor)** – muscles of the neck covered by prevertebral fascia

The order of dissection will be as follows: The skin will be removed from the anterior and lateral neck. The platysma muscle will be studied and reflected. The external jugular vein will be identified. Several cutaneous branches of the cervical plexus (great auricular nerve, lesser occipital nerve, transverse cervical nerve, and supraclavicular nerves) will be dissected. The accessory nerve (XI) will be identified and traced from the sternocleidomastoid muscle to the trapezius muscle.

Dissection Instructions

SKIN INCISIONS

1. The skin is thin on the neck. Be careful when removing it.
2. Refer to Figure 7.42 and make a skin incision from the mastoid process (E) to the medial end of the clavicle (F).
3. If the upper limb has not been dissected previously, make a second skin incision along the clavicle from its medial end to a point 3 cm lateral to the acromion.
4. Posterior to the first skin incision, reflect the skin as far as the anterior border of the trapezius muscle and detach it.
5. Anterior to the first incision, reflect the skin as far as the midline and detach it.

STRUCTURES IN THE POSTERIOR TRIANGLE [G 722; N 22; R 172; C 440]

1. Examine the **platysma muscle**, which is in the superficial fascia (Fig. 7.43). The platysma muscle covers the lower part of the posterior triangle. At its inferior end, the platysma muscle passes superficial to the clavicle and attaches to the superficial fascia of the deltoid and pectoral regions. Superiorly, the platysma muscle is attached to the mandible, skin of the cheek, angle of the mouth, and orbicularis oris muscle. It is innervated by the facial nerve.
2. Note that the supraclavicular nerves, the transverse cervical nerve and the external jugular vein are in contact with the deep surface of the platysma muscle. Preserve them in the next dissection step.
3. Use a probe to raise the posterior border of the platysma muscle. Use blunt dissection to free the platysma muscle from the deeper structures and re-

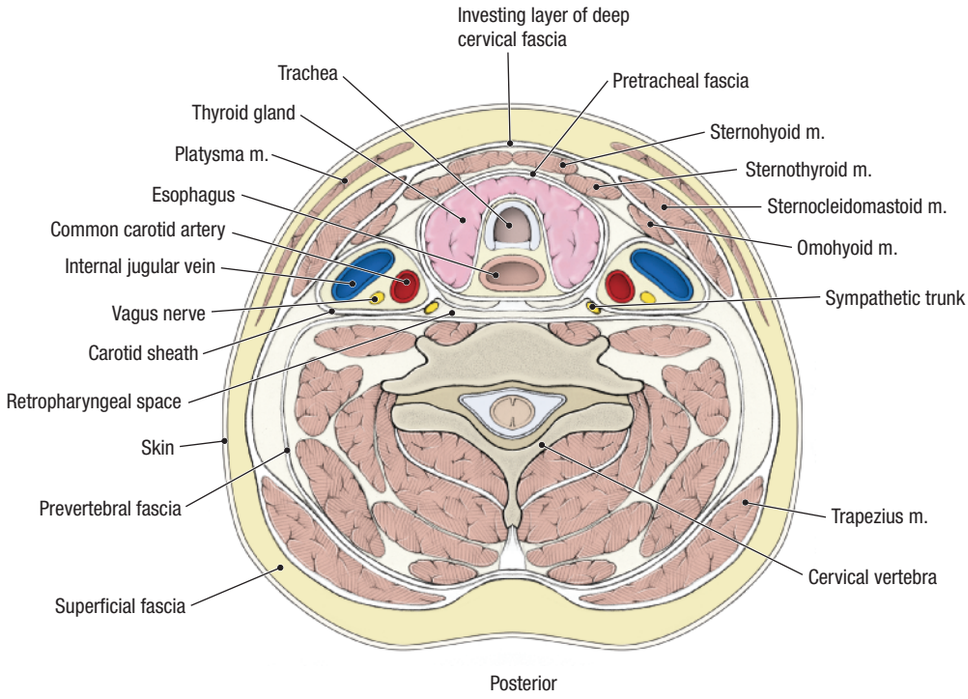

Figure 7.40. Transverse section through the neck.

flect it superiorly. Detach the platysma muscle from its superior attachments and place it in the tissue container.

4. Identify the **external jugular vein** (Fig. 7.44). The external jugular vein begins posterior to the angle of the mandible and crosses the superficial surface of the sternocleidomastoid muscle. About 3 cm superior to the clavicle, the external jugular vein pierces the investing layer of the deep cervical fascia (roof of the posterior triangle) to drain into the subclavian vein. Follow the external jugular vein until it passes through the investing layer of deep cervical fascia. **[G 730; N 27; R 174; C 441]**

5. The skin of the neck and posterior head is innervated by **cutaneous nerves** that are branches of the **cervical plexus** (Fig. 7.44). The cutaneous nerves enter the superficial fascia at the midpoint of the posterior border of the sternocleidomastoid muscle. Identify:
   - **Lesser occipital nerve** – passes superiorly along the posterior border of the sternocleidomastoid muscle. The lesser occipital nerve supplies the scalp.
   - **Great auricular nerve** – crosses the superficial surface of the sternocleidomastoid muscle parallel to the external jugular vein. The great auricular nerve supplies the skin of the lower part of the ear and an area of skin extending from the angle of the mandible to the mastoid process.
   - **Transverse cervical nerve** – passes transversely across the sternocleidomastoid muscle and neck. It supplies the skin of the anterior triangle of the neck.
   - **Supraclavicular nerves** – pass inferiorly to the region of the shoulder. Observe medial, intermediate, and lateral branches.

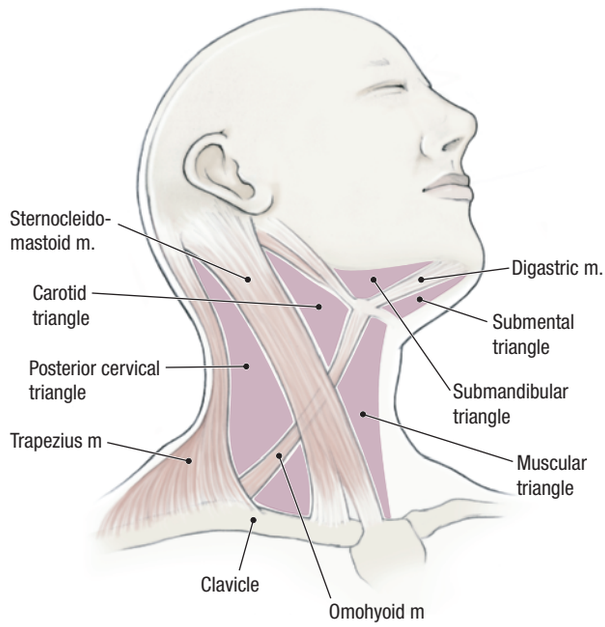

Figure 7.41. Boundaries of the cervical triangles.

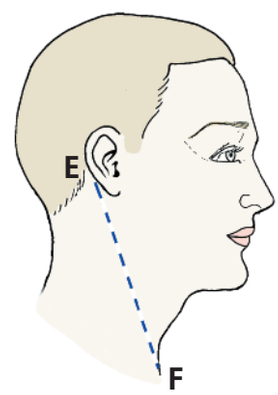

Figure 7.42. Skin incision.

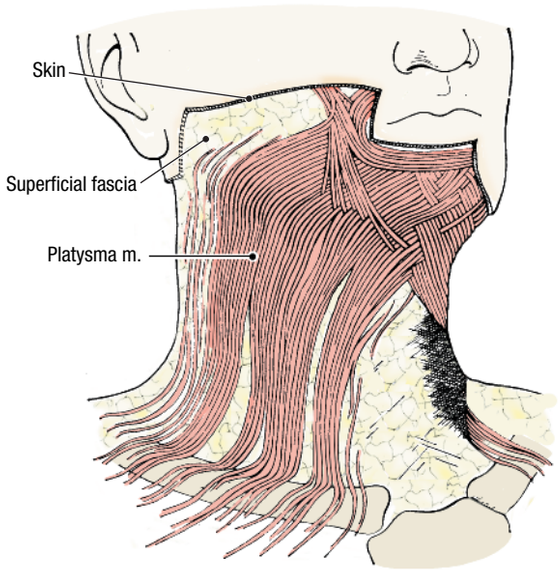

Figure 7.43. The platysma muscle.

6. The **accessory nerve (XI)** courses from slightly superior to the midpoint of the posterior border of the sternocleidomastoid muscle to the anterior border of the trapezius muscle (Fig. 7.44). The accessory nerve lies deep to the investing layer of the deep cervical fascia. Use blunt dissection to free the accessory nerve from the surrounding connective tissue. Note that branches of spinal nerves C3 and C4 join the accessory nerve in the posterior cervical triangle. The accessory nerve innervates the sternocleidomastoid muscle and the trapezius muscle. If the back has been dissected, confirm that the accessory nerve may be found on the deep surface of the trapezius muscle.
7. The inferior portion of the posterior triangle will be dissected with the root of the neck.

CLINICAL CORRELATION

Diaphragmatic Pain Referred to the Shoulder

The supraclavicular nerves and the phrenic nerve arise from spinal cord segments C3 and C4. Irritation of the diaphragmatic pleura or peritoneum produces pain that is carried by the phrenic nerve and referred to the area supplied by the supraclavicular nerves (shoulder and clavicular region).

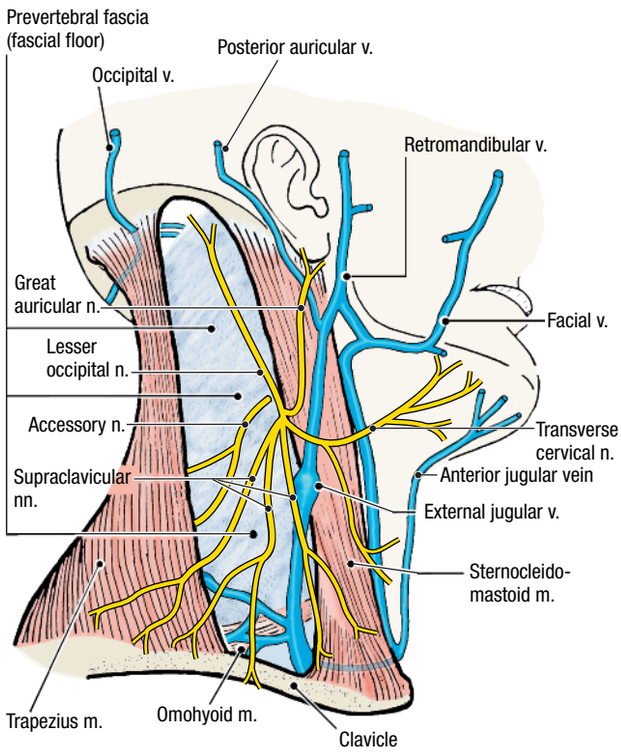

Figure 7.44. Posterior triangle of the neck. The external jugular vein lies superficial to the investing layer of deep cervical fascia.

After you dissect . . .

Use an illustration to review the relationship of the platysma muscle to the cutaneous branches of the cervical plexus. Note that the transverse cervical nerve crosses the neck deep to the platysma muscle but that its branches pass through the muscle to reach the skin of the anterior neck. Review the area of distribution of the other cutaneous branches of the cervical plexus. Review the course of the accessory nerve. Note that the accessory nerve is superficial in the neck where it is vulnerable to injury by laceration or blunt trauma. Review the course of the occipital artery at the apex of the posterior triangle.

ANTERIOR TRIANGLE OF THE NECK [G 739; N 24; R 173; C 447]

Before you dissect . . .

The boundaries of the **anterior triangle of the neck** are (Fig. 7.41):

- **Anterior** – the median line of the neck
- **Posterior** – the anterior border of the sternocleidomastoid muscle
- **Superior** – the inferior border of the mandible
- **Superficial (roof)** – investing layer of the deep cervical fascia
- **Deep (floor)** – larynx and pharynx

For descriptive purposes, the anterior triangle is divided by the digastric and omohyoid muscles into smaller triangles: **muscular**, **carotid**, **submandibular**, and **submental** (Fig. 7.41).

BONES AND CARTILAGES

Use an illustration to identify bony and cartilaginous landmarks that will be used as reference structures (Fig. 7.45): **[G 740; N 25; R 173; C 447]**

- **Hyoid bone** – at the angle between floor of the mouth and the superior end of the neck.
- **Thyrohyoid membrane** – stretching between the thyroid cartilage and hyoid bone.
- **Thyroid cartilage** – in the anterior midline of the neck.

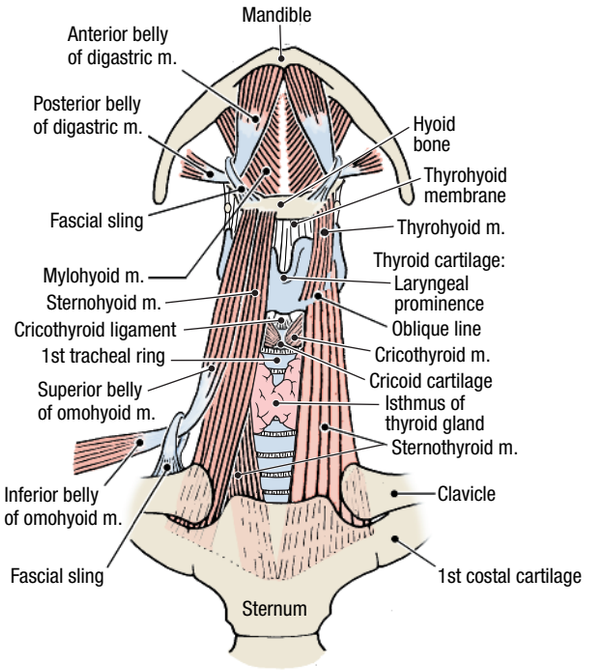

Figure 7.45. The muscular triangle of the neck.

The order of dissection will be as follows: The superficial veins of the anterior triangle will be studied. The contents of each subdivision of the anterior triangle will be dissected in the following order: muscular triangle, carotid triangle, submandibular triangle and submental triangle.

Dissection Instructions

SUPERFICIAL FASCIA [G 739; N 27; R 172; C 450]

1. The platysma muscle has been removed, revealing the **external jugular vein**. Follow the external jugular vein superiorly and observe that it is formed by the joining of the **retromandibular vein** and the **posterior auricular vein** (Fig. 7.44).
2. In the superficial fascia near the anterior midline, note the **anterior jugular vein** (Fig. 7.44). It courses inferiorly near the midline to the suprasternal region where it penetrates the investing layer of the deep cervical fascia. The anterior jugular vein passes deep to the sternocleidomastoid muscle to join the external jugular vein in the root of the neck.

MUSCULAR TRIANGLE [G 739; N 25; R 173; C 447]

1. The contents of the **muscular triangle** of the neck are the infrahyoid muscles, the thyroid gland, and the parathyroid glands. The **boundaries of the muscular triangle** are (Fig. 7.41):
   - **Superolateral** – superior belly of the omohyoid muscle
   - **Inferolateral** – anterior border of the sternocleidomastoid muscle
   - **Medial** – median plane of the neck
2. In the midline of the neck, use a probe to break through the investing layer of the deep cervical fascia and identify the **sternohyoid muscle** (Fig. 7.45). The inferior attachment of the sternohyoid muscle is the sternum and its superior attachment is the body of the hyoid bone. The sternohyoid muscle depresses the hyoid bone.
3. Lateral to the sternohyoid muscle, identify the **superior belly of the omohyoid muscle**. The inferior attachment of the omohyoid muscle is the superior border of the scapula near the suprascapular notch and its superior attachment is the inferior border of the hyoid bone. The omohyoid muscle depresses the hyoid bone.
4. Use blunt dissection to loosen the medial border of the sternohyoid muscle from the structures that lie deep to it. Use scissors to transect the sternohyoid muscle close to the hyoid bone and reflect the muscle inferiorly.
5. Use a probe to raise the medial border of the superior belly of the omohyoid muscle and loosen it from deeper structures. Use scissors to transect the superior belly of the omohyoid muscle close to the hyoid bone and reflect it inferiorly.
6. Identify the **sternothyroid muscle** (Fig. 7.45). The inferior attachment of the sternothyroid muscle is the sternum and its superior attachment is the oblique line of the thyroid cartilage. The sternothyroid muscle depresses the larynx.
7. Identify the **thyrohyoid muscle**. The inferior attachment of the thyrohyoid muscle is the oblique line of the thyroid cartilage and its superior attachment is the hyoid bone. The thyrohyoid muscle elevates the larynx.
8. The **ansa cervicalis** innervates the infrahyoid muscles. It will be identified later.
9. Gently retract the right and left sternothyroid muscles to widen the gap in the midline. Identify (Fig. 7.45): [G 749; N 27; R 173; C 452]
   - **Laryngeal prominence**
   - **Cricothyroid ligament**
   - **Cricoid cartilage**
   - **1st tracheal ring**
   - **Isthmus of the thyroid gland**

CLINICAL CORRELATION

Tracheotomy

Tracheotomy (tracheostomy) is the creation of an opening into the trachea. As an emergency operation, it must be rapidly performed in cases with sudden obstruction of the airway (for example: aspiration of a foreign body, edema of the larynx or paralysis of the vocal folds). The opening is made in the midline between the infrahyoid muscles of the neck.

CAROTID TRIANGLE [G 739; N 28; R 178; C 442]

1. The contents of the **carotid triangle** are the carotid arteries (common, internal, and external), the branches of the external carotid artery, the hypoglossal nerve, and branches of the vagus nerve (X). The **boundaries of the carotid triangle** are (Fig. 7.41):
   - **Inferomedial** – superior belly of the omohyoid muscle
   - **Inferolateral** – anterior border of the sternocleidomastoid muscle
   - **Superior** – posterior belly of the digastric muscle
2. Transect the sternocleidomastoid muscle about 5 cm superior to its attachments to the sternum and clavicle. Do not damage the cutaneous branches of the cervical plexus that radiate from the posterior border of the sternocleidomastoid muscle. Free the superior portion of the sternocleidomastoid muscle from the surrounding fascia and reflect it superiorly.
3. Find the accessory nerve (XI) where it crosses the deep surface of the sternocleidomastoid muscle near the base of the skull. Trace the accessory nerve superiorly as far as possible. Recall that the accessory nerve passes through the jugular foramen.
4. To allow better access to deeper structures cut the **facial vein** where it empties into the internal jugular vein.
5. Palpate the **tip of the greater horn of the hyoid bone** (Fig. 7.46). Find the hypoglossal nerve superior to the tip of the greater horn of the hyoid bone. Observe that a muscular branch of the occipital artery crosses superior to the hypoglossal nerve. The hypoglossal nerve carries axons of spinal nerve C1 that branch off as the **nerve to the thyrohyoid muscle**. [G 739; N 28; R 178; C 443]
6. Use blunt dissection to trace the **hypoglossal nerve** anteriorly. Verify that the hypoglossal nerve passes medial to the **posterior belly of the digastric muscle** (Fig. 7.46).
7. The **superior root of the ansa cervicalis** travels with the hypoglossal nerve (Fig. 7.47). The superior root of the ansa cervicalis is mainly composed of fibers from C1. The **inferior root of the ansa cervicalis** (C2, C3) passes around the carotid sheath to join the superior root. Thus, a loop (L., *ansa*, handle) is formed.
8. Clean the ansa cervicalis and trace its delicate branches to the lateral borders of the infrahyoid muscles (Fig. 7.47).
9. Use a probe to raise the posterior border of the thyrohyoid muscle and identify the **thyrohyoid membrane** that extends between the thyroid cartilage and the hyoid bone (Fig. 7.48). Find the **internal branch of the superior laryngeal nerve** where it passes through the thyrohyoid membrane. The internal branch of the superior laryngeal nerve supplies the mucosa of the larynx with sensory fibers.
10. Follow the internal branch of the superior laryngeal nerve proximally until it is joined by the **external branch of the superior laryngeal nerve**. The nerve proximal to the joining is the **superior laryngeal nerve** (Fig. 7.48).
11. Trace the external branch of the superior laryngeal nerve distally and observe that it innervates the **cricothyroid muscle**. It also innervates part of the inferior pharyngeal constrictor muscle.
12. While preserving the ansa cervicalis, use scissors to open the **carotid sheath**. The carotid sheath contains the common carotid artery, internal carotid artery, internal jugular vein, and vagus nerve (X).

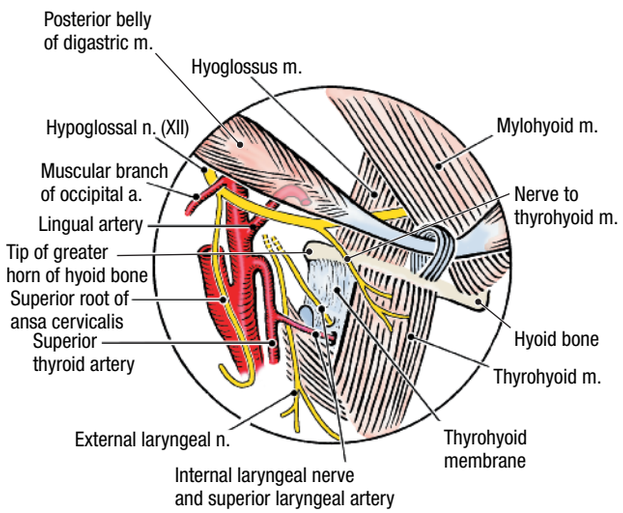

Figure 7.46. The carotid triangle of the neck. The tip of the greater horn of the hyoid bone is an important reference point.

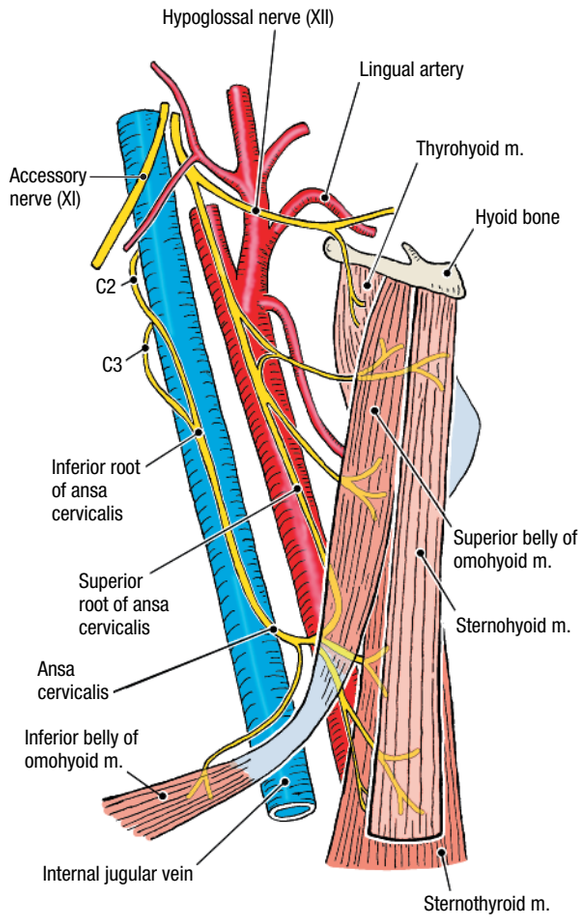

Figure 7.47. The ansa cervicalis.

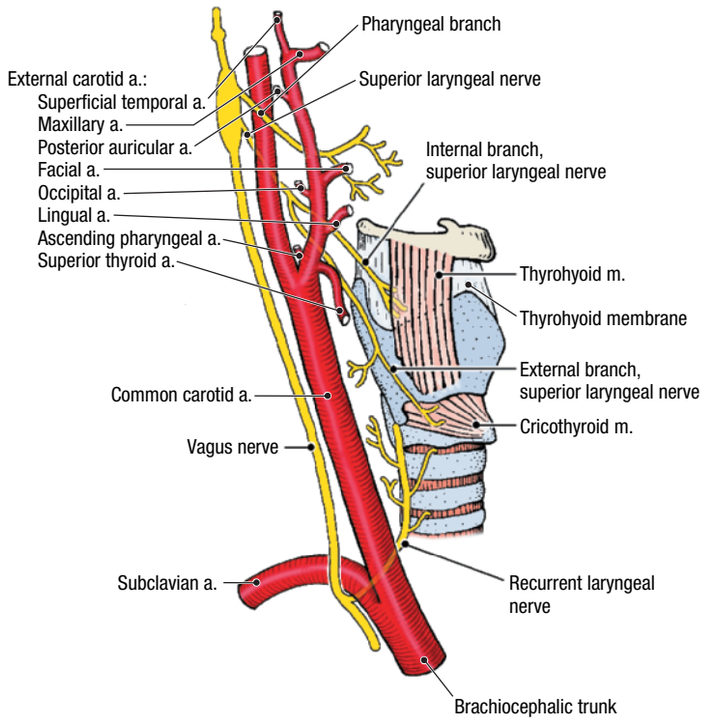

Figure 7.48. Branches of the external carotid artery and right vagus nerve (X) in the neck.

13. Observe that the **internal jugular vein** is located lateral to the common carotid or internal carotid artery in the carotid sheath. Use an illustration to study its largest tributaries: **common facial vein, superior thyroid vein**, and **middle thyroid vein**. Use blunt dissection to separate the internal jugular vein from the common or internal carotid artery. To clear the dissection field, remove the tributaries of the internal jugular vein.
14. At the level of the superior horn of the thyroid cartilage, find the origin of the **external carotid artery** (Fig. 7.48). Use blunt dissection to follow the external carotid artery superiorly until it passes on the medial side of (deep to) the posterior belly of the digastric muscle. **[G 741; N 30; R 179; C 443]**
15. The external carotid artery has six branches in the carotid triangle (Fig. 7.48). Each branch has a companion vein that may be removed to clear the dissection field. Identify:
    - **Ascending pharyngeal artery** – the first branch to arise from the external carotid artery. It branches from the medial surface near the carotid bifurcation. To find the ascending pharyngeal artery, insert a probe medial to the external carotid artery and slide the probe inferiorly until it is stopped by the ascending pharyngeal artery.
    - **Superior thyroid artery** – arises from the anterior surface of the external carotid artery inferior to the greater horn of the hyoid bone. The superior thyroid artery descends to the superior pole of the lobe of the thyroid gland. The **superior laryngeal artery** is a branch of the superior thyroid artery, which pierces the thyrohyoid membrane together with the internal laryngeal nerve.
    - **Lingual artery** – arises from the anterior surface of the external carotid artery at the level of the greater horn of the hyoid bone (Fig. 7.48). It passes deeply into the muscles of the tongue. Do not follow it at this time.
    - **Facial artery** – arises from the anterior surface of the external carotid artery immediately superior to the lingual artery (Fig. 7.48). The facial artery courses deep to the submandibular gland before appearing on the face. Do not follow it at this time. In 20% of cases, the lingual and facial arteries arise from a common trunk.
    - **Occipital artery** – arises from the posterior surface of the external carotid artery and supplies the scalp (Fig. 7.48).
    - **Posterior auricular artery** – arises from the posterior surface of the external carotid artery and passes posterior to the ear to supply the scalp.
16. Clean the **bifurcation of the common carotid artery**. Observe the **carotid sinus**, a dilation of the origin of the internal carotid artery. The wall of the carotid sinus contains pressoreceptors that monitor blood pressure. The carotid sinus is innervated by the glossopharyngeal nerve (IX).
17. The **carotid body** is a small mass of tissue located on the medial aspect of the carotid bifurcation. The carotid body monitors changes in oxygen and carbon dioxide concentration of the blood. The carotid body is innervated by the glossopharyngeal nerve (IX).
18. Identify the **internal carotid artery** and note that it has no branches in the neck.
19. Identify the **vagus nerve (X)** within the carotid sheath where it lies between and posterior to the vessels (Fig. 7.48). To see the vagus nerve, retract the internal jugular vein laterally and the common carotid artery medially.

SUBMANDIBULAR TRIANGLE [G 739; N 28; R 179; C 461]

1. The contents of the **submandibular triangle** are the submandibular gland, facial artery, facial vein, stylohyoid muscle, hypoglossal nerve (XII), and lymph nodes. The **boundaries of the submandibular triangle** are (Fig. 7.41):
    - **Superior** – inferior border of the mandible
    - **Anteroinferior** – anterior belly of the digastric muscle
    - **Posteroinferior** – posterior belly of the digastric muscle
    - **Floor** – mylohyoid and hyoglossus muscles
    - **Roof** – investing layer of deep cervical fascia
2. Refer to a skull. On the temporal bone, identify the **mastoid process** and the **styloid process**.
3. Examine the **inner aspect of the mandible** and identify: **[G 655; N 13; R 55; C 543]**
    - **Digastric fossa**
    - **Mylohyoid line**
    - **Submandibular fossa**
    - **Mylohyoid groove**

4. On the cadaver, identify the submandibular gland and use a probe to define its borders. Note that a portion of the gland extends deep to the mylohyoid muscle.
5. Use blunt dissection to separate the facial artery and vein from the submandibular gland. Note that the facial vein passes superficial to the submandibular gland and the facial artery courses deep to the gland.
6. Preserve the facial vessels and remove the superficial part of the submandibular gland. Do not disturb the deep part of the gland.
7. Identify the **anterior and posterior bellies of the digastric muscle.** The anterior attachment of the anterior belly is the digastric fossa of the mandible and it is innervated by the mylohyoid nerve (a branch of V_3). The posterior attachment of the posterior belly is the mastoid process of the temporal bone and it is innervated by the facial nerve (VII). The two bellies attach to each other by an **intermediate tendon**. The intermediate tendon is attached to the body and the greater horn of the hyoid bone by a fibrous sling. The digastric muscle elevates the hyoid bone and depresses the mandible.
8. Identify the **tendon of the stylohyoid muscle**, which attaches to the body of the hyoid bone by passing on either side of the intermediate tendon of the digastric muscle. The stylohyoid muscle is innervated by the facial nerve and it elevates the hyoid bone.
9. Use a probe to follow the **hypoglossal nerve (XII)** into the submandibular triangle. Observe that the nerve passes deep to the **mylohyoid muscle** (Fig. 7.46).

SUBMENTAL TRIANGLE [G 748; N 27; R 172; C 460]

1. The contents of the **submental triangle** are the submental lymph nodes. The submental triangle is an unpaired triangle that crosses the midline. The **boundaries of the submental triangle** are (Fig. 7.41):
   - **Right and left** – anterior bellies of the right and left digastric muscles
   - **Inferior** – hyoid bone
   - **Floor** – mylohyoid muscle
   - **Roof** – investing layer of the deep cervical fascia
2. Use a probe to clean the superficial fascia from the surface of the right and left mylohyoid muscles. Each mylohyoid muscle has a proximal attachment on the mylohyoid line of the mandible and distal attachments on the hyoid bone and the mylohyoid raphe. The mylohyoid muscle is innervated by the mylohyoid nerve and it supports the floor of the oral cavity.

After you dissect . . .

Replace the sternocleidomastoid muscle and the infrahyoid muscles in their normal anatomical positions. Review the cutaneous branches of the cervical plexus. Review the attachments and actions of the infrahyoid muscles. Review the ansa cervicalis. Use the dissected specimen to review the positions of the common carotid and internal carotid arteries, internal jugular vein, and vagus nerve within the carotid sheath. Follow each branch of the external carotid artery through the regions dissected, noting their relationships to muscles, nerves, and glands. Trace the branches of the superior laryngeal nerve. Review the course of the hypoglossal nerve. Note the relationship of the superior laryngeal nerve and the hypoglossal nerve to the internal and external carotid arteries.

THYROID AND PARATHYROID GLANDS [G 757; N 70, 72; R 180; C 451]

Before you dissect . . .

The cervical viscera include the pharynx, esophagus, larynx, trachea, thyroid gland, and parathyroid glands. The thyroid gland and parathyroid glands lie between the infrahyoid muscles and the larynx and trachea, and will be dissected now. The other cervical viscera will be dissected later.

Dissection Instructions

1. Once again, reflect the sternocleidomastoid and sternohyoid muscles.
2. Use a probe to loosen the sternothyroid muscle from deeper structures. Use scissors to transect the sternothyroid muscle near the sternum and reflect it superiorly.
3. Observe the **thyroid gland**. The thyroid gland is located at vertebral levels C5-T1. Laterally, the thyroid gland is in contact with the carotid sheath (Fig. 7.49B).
4. Identify the **right lobe** and **left lobe** of the **thyroid gland**. The two lobes are connected by the **isthmus**, which crosses the anterior surface of tracheal rings 2 and 3 (Fig. 7.49A).
5. Frequently, the thyroid gland has a **pyramidal lobe** that extends superiorly from the isthmus. The pyramidal lobe is a remnant of development that shows the route of descent of the thyroid gland.
6. Identify the **superior thyroid artery** and recall that it is a branch of the external carotid artery. The inferior thyroid artery will be dissected later.
7. The **superior and middle thyroid veins** are tributary to the internal jugular vein. The **right and left inferior thyroid veins** descend into the thorax on the anterior surface of the trachea. The right and left inferior thyroid veins drain into the right and left brachiocephalic veins, respectively.
8. Use scissors to cut the isthmus of the thyroid gland. Use blunt dissection to detach the capsule of the thyroid gland from the 1st tracheal ring. Spread the lobes widely apart.
9. On both sides of the cadaver, use blunt dissection to display the **recurrent laryngeal nerve** that ascends immediately posterior to the thyroid gland in the groove between the trachea and esophagus. Note the close relationship of the recurrent laryngeal nerve to the thyroid gland.

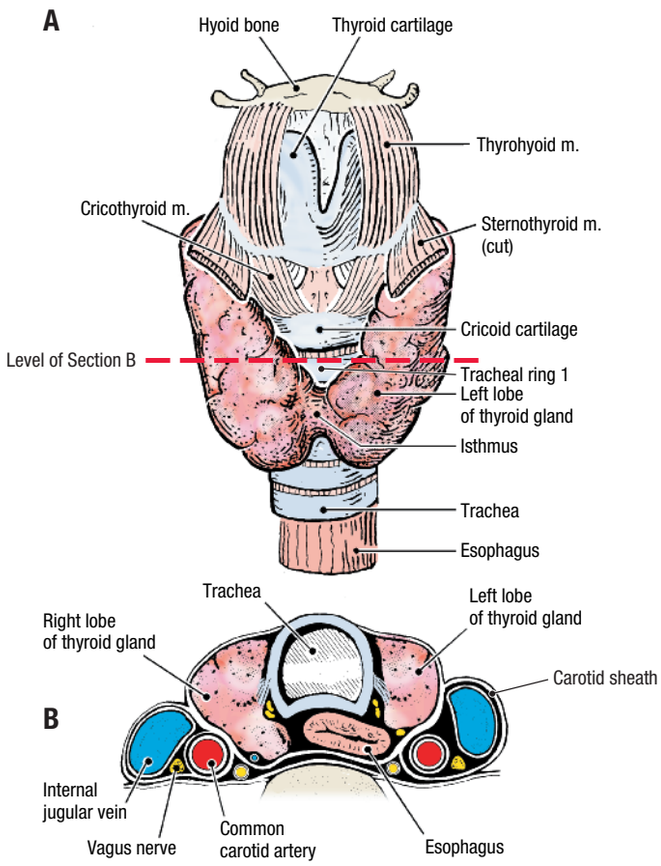

Figure 7.49. The relationships of the thyroid gland. **A.** Anterior view. Dashed line indicates the level of section. **B.** Transverse section.

CLINICAL CORRELATION

Recurrent Laryngeal Nerve

If a recurrent laryngeal nerve is injured by a thyroid tumor or during thyroidectomy (removal of the thyroid gland), paralysis of the laryngeal muscles will occur on the affected side. The result is hoarseness of the voice.

10. Cut all blood vessels leading to or from the left lobe of the thyroid gland. Use a probe to free the left lobe from surrounding connective tissue and remove it.
11. Examine the posterior aspect of the left lobe of the thyroid gland and attempt to identify the **parathyroid glands**. The parathyroid glands are about 5 mm in diameter and may be darker in color than the thyroid gland. Usually, there are two parathyroid glands on each side. However, the number may vary from 1 to 3.

CLINICAL CORRELATION

Parathyroid Glands

The parathyroid glands play a vital role in the regulation of calcium metabolism. During thyroidectomy, these small endocrine glands are in danger of being damaged or removed. To maintain proper serum calcium levels, at least one parathyroid gland must be retained during surgery.

After you dissect . . .

Review the relationship of the thyroid gland to the infrahyoid muscles, carotid sheaths, larynx and trachea. Use an illustration and the dissected specimen to review the blood supply and venous drainage of the thyroid gland. Note that there are only two thyroid arteries (superior and inferior) but there are three thyroid veins (superior, middle and inferior). Review the relationship of the parathyroid glands to the thyroid gland. Use an embryology textbook to review the origin and migration of the thyroid and parathyroid glands during development.

ROOT OF THE NECK [G 756; N 29; R 180; C 444]

Before you dissect . . .

The **root (base) of the neck** is the junction between the thorax and the neck. The root of the neck is an important area because it lies superior to the **superior thoracic aperture**. All structures that pass between the head and thorax or the upper limb and thorax must pass through the root of the neck. The **boundaries of the root of the neck** are:

- **Anterior** – the manubrium of the sternum
- **Lateral** – the first pair of ribs
- **Posterior** – the body of vertebra T1

The order of dissection will be as follows: The anterior thoracic wall will be removed. The branches of the subclavian artery will be dissected. The course of the vagus and phrenic nerves will be studied. The muscles that form the floor of the posterior cervical triangle will be studied. Some of these structures will be followed superiorly or inferiorly beyond the boundaries of the root of the neck.

Dissection Instructions

1. The clavicle has been cut at its midlength during dissection of the thorax.
2. Reflect the sternocleidomastoid muscle, sternohyoid muscle, and sternothyroid muscle.
3. Use scissors to cut the fascial sling that binds the omohyoid muscle to the clavicle. Use blunt dissection to free the distal portion of the sternocleidomastoid muscle from structures that lie deep to it. Preserve the anterior jugular vein.
4. On each side, cut the internal thoracic artery close to the subclavian artery. Remove the anterior thoracic wall.
5. Clean the **omohyoid muscle**. Note that its inferior belly and superior belly are joined by an **intermediate tendon**. Review its attachments and action.
6. Follow the **external jugular vein** through the investing layer of deep cervical fascia. It is a tributary of the subclavian vein. To expose the blood vessels in the root of the neck, remove the investing layer of deep cervical fascia that forms the roof of the lower part of the posterior cervical triangle.
7. Identify the **subclavian vein** (Fig. 7.50). Use blunt dissection to loosen the subclavian vein from struc-

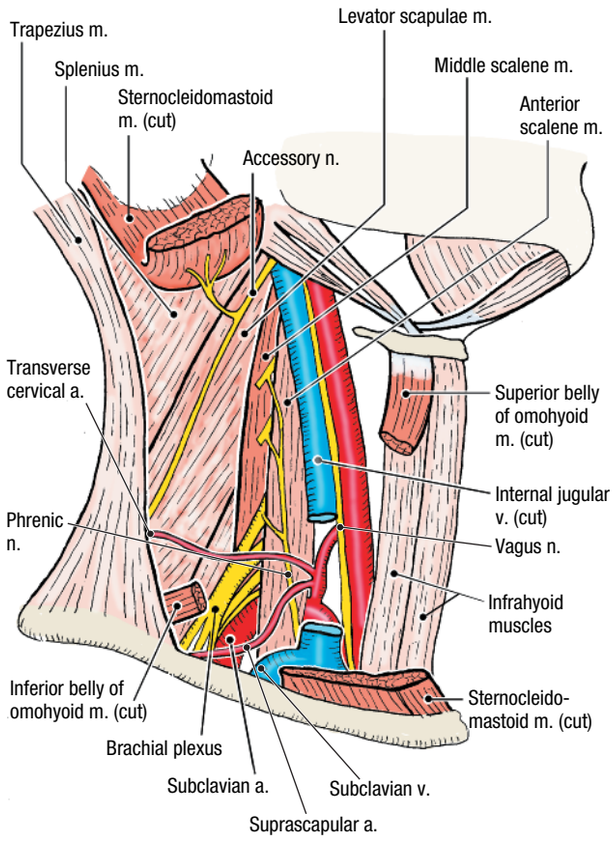

Figure 7.50. The root of the neck.

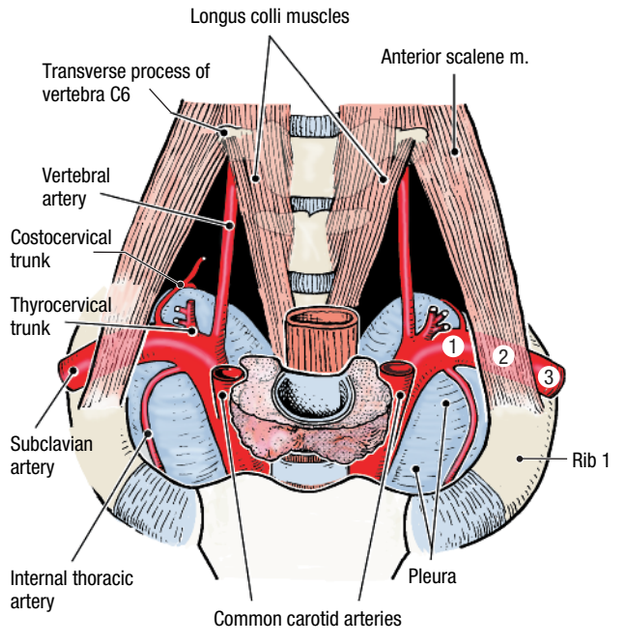

Figure 7.51. Subclavian artery.

tures that lie deep to it. The subclavian vein receives tributaries that correspond to the branches of the subclavian artery. To clear the dissection field, remove the tributaries of the subclavian vein.

8. Follow the subclavian vein proximally to the point where it is joined by the **internal jugular vein** to form the **brachiocephalic vein**.
9. Identify the **subclavian artery**. Observe that the right subclavian artery is a branch of the brachiocephalic trunk and the left subclavian artery is a branch of the aortic arch. **[G 760; N 29; R 168, 180; C 459]**
10. The subclavian artery has three parts that are defined by the presence of the anterior scalene muscle (Fig. 7.51):
    - **First part** – from its origin to the medial border of the anterior scalene muscle
    - **Second part** – posterior to the anterior scalene muscle
    - **Third part** – between the lateral border of the anterior scalene muscle and the lateral border of the first rib
11. The **first part of the subclavian artery** has three branches:
    - **Vertebral artery** – courses superiorly between the anterior scalene muscle and the longus colli muscle (Fig. 7.51). Trace the vertebral artery superiorly until it passes deeply to enter the transverse foramen of vertebra C6.
    - **Internal thoracic artery** – arises from the anteroinferior surface of the subclavian artery and passes inferiorly to supply the anterior thoracic wall (Fig. 7.51).
    - **Thyrocervical trunk** – arises from the anterosuperior surface of the subclavian artery (Fig. 7.51). The thyrocervical trunk has three branches:
      Transverse cervical artery – crosses the root of the neck about 2 to 3 cm superior to the clavicle and deep to the omohyoid muscle (Fig. 7.52). It supplies the trapezius muscle.
      Suprascapular artery – passes laterally and posteriorly to the region of the suprascapular notch (Fig. 7.52). It passes superior to the transverse scapular ligament and supplies the supraspinatus and infraspinatus muscles.
      Inferior thyroid artery – passes medially toward the thyroid gland. Trace the inferior thyroid artery toward the thyroid gland and note that it passes posterior to the **cervical sympathetic trunk**. The **ascending cervical artery** is a branch of the inferior thyroid artery.
12. The **second part of the subclavian artery** has one branch, the **costocervical trunk** (Fig. 7.51). The costocervical trunk arises from the posterior aspect of the second part of the subclavian artery and passes posteriorly, making it difficult to find. The costocervical trunk divides into the **deep cervical artery** and the **supreme intercostal artery**. The supreme intercostal artery gives rise to posterior intercostal arteries 1 and 2.
13. The **third part of the subclavian artery** has one branch, the **dorsal scapular artery**. The dorsal scapular artery passes between the superior and middle trunks of the brachial plexus to supply the muscles of

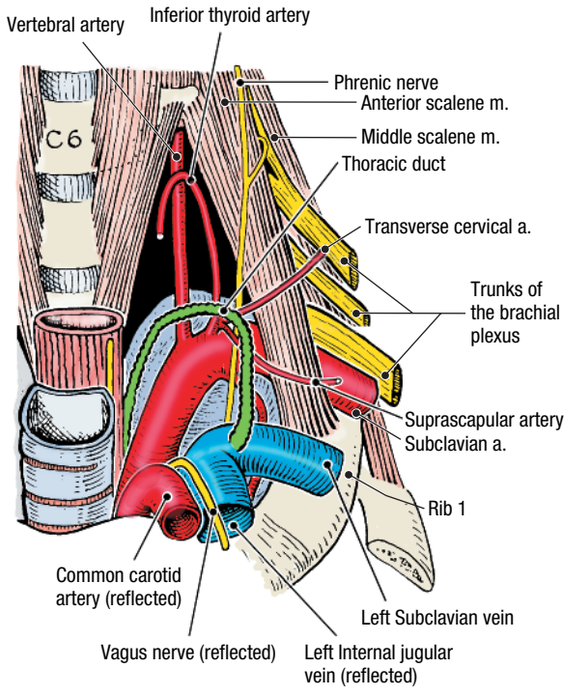

Figure 7.52. Termination of the thoracic duct.

the scapular region. In about 30% of cases the dorsal scapular artery arises from the transverse cervical artery instead of from the subclavian artery.

14. Find the **thoracic duct**, which ascends from the thorax into the neck. The thoracic duct is posterior to the esophagus at the level of the superior thoracic aperture, then arches anteriorly and to the left to join the venous system near the junction of the **left subclavian vein** and the **left internal jugular vein** (Fig. 7.52). The thoracic duct is usually a single structure, which has the same diameter as a small vein, but it may be represented by several smaller ducts. **[G 758; N 202; R 178; C 156]**
15. On the right side of the neck, several small lymphatic vessels join with lymph vessels from the right upper limb and right side of the thorax to form the **right lymphatic duct**, which drains into the junction of the right subclavian and right internal jugular veins.
16. On both sides, find the **vagus nerve** in the carotid sheath and follow it into the thorax. Note that the vagus nerve passes posterior to the root of the lung. **[G 756; N 28; R 180; C 445]**
17. The right vagus nerve passes anterior to the subclavian artery where it gives off the **right recurrent laryngeal nerve**. The **left recurrent laryngeal nerve** is given off as the left vagus nerve passes the aortic arch.
18. Follow the right and left recurrent laryngeal nerves superiorly along the lateral surface of the trachea and esophagus. Trace them as far as the first tracheal ring. Do not follow them into the larynx at this time.
19. Verify that the **phrenic nerve** crosses the anterior surface of the anterior scalene muscle (Fig. 7.52). Follow the phrenic nerve into the thorax and confirm that it passes anterior to the root of the lung.
20. Identify the cervical portion of the **sympathetic trunk**. Note that the inferior cervical sympathetic ganglion is located in the root of the neck. Verify that the cervical sympathetic trunk is continuous with the thoracic sympathetic trunk.
21. Examine the muscles that form the floor of the posterior cervical triangle. Identify the **splenius capitis**, **levator scapulae**, and the **anterior**, **middle**, and **posterior scalene muscles**. **[G 758; N 29; R 181; C 452]**
22. Use blunt dissection to define the borders of the **anterior scalene** and **middle scalene muscles**. The anterior and middle scalene muscles attach to the first rib. The first rib and the adjacent borders of the anterior and middle scalene muscles form the boundaries of the **interscalene triangle**. Observe (Fig. 7.52):
    - The **subclavian artery** and the **roots of the brachial plexus** pass through the interscalene triangle (posterior to the anterior scalene muscle).
    - The **subclavian vein**, **transverse cervical artery**, and **suprascapular artery** cross the anterior surface of the anterior scalene muscle.
    - The **phrenic nerve** descends vertically across the anterior surface of the anterior scalene muscle.
23. Use blunt dissection to clean the **roots of the brachial plexus** at the level of the interscalene triangle. Identify the parts of the supraclavicular portion of the brachial plexus: **roots**, **trunks**, and **divisions**.

CLINICAL CORRELATION

Interscalene Triangle

The **interscalene triangle** becomes clinically significant when anatomical variations (additional muscular slips, an accessory cervical rib, or exostosis on the 1st rib) narrow the interval. As a result, the subclavian artery and/or roots of the brachial plexus may be compressed, resulting in ischemia and nerve dysfunction in the upper limb.

After you dissect . . .

Replace the anterior thoracic wall in its correct anatomical position. Replace the infrahyoid muscles and sternocleidomastoid muscle in their correct anatomical positions. Review the boundaries of the posterior cervical triangle. Review the attachments of the infrahyoid muscles. Review the distribution of the cutaneous branches of the cervical plexus. Remove the anterior thoracic wall. Review the origin and course of the brachiocephalic artery, left common carotid artery, and left subclavian artery in the superior mediastinum. Review the three parts and the branches of the subclavian artery. Review the distribution of the transverse cervical, suprascapular, and dorsal scapular arteries to the posterior thoracoappendicular and scapulohumeral muscles. Use an illustration and the dissected specimen to review the course of the vertebral artery from its origin to the posterior cranial fossa.

PAROTID REGION

Before you dissect . . .

The parotid region (parotid bed) is the area occupied by the parotid gland and the vessels and nerves that pass through it. The parotid gland develops as an evagination of the oral mucosa and it occupies all available space around the ramus of the mandible. Therefore, the parotid gland is in close contact with vessels, muscles, bones, and ligaments in the region. The superficial portion of the parotid gland was removed to expose the branches of the facial nerve. The goal of this dissection is to remove the remainder of the parotid gland piece-by-piece, preserving the nerves and vessels that pass through it.

The order of dissection will be as follows: The branches of the facial nerve will be reviewed and then followed posteriorly toward the stylomastoid foramen. Parotid tissue will be removed during this process. The facial nerve will be transected near the lobe of the ear and reflected anteriorly to preserve its branching pattern. The retromandibular vein will be followed superiorly through the parotid gland as more parotid tissue is removed. The external carotid artery will then be followed superiorly as additional parotid tissue is removed.

SKELETON OF THE PAROTID REGION

Refer to a skull and identify (Fig. 7.53):

- **Temporal bone** [G 654; N 4; R 25; C 481]
  - **Mandibular fossa**
  - **External acoustic meatus**
  - **Styloid process**
  - **Stylomastoid foramen**
  - **Mastoid process**
- **Mandible** [G 654; N 13; R 55; C 543]
  - **Head**
  - **Neck**
  - **Angle**
  - **Ramus**

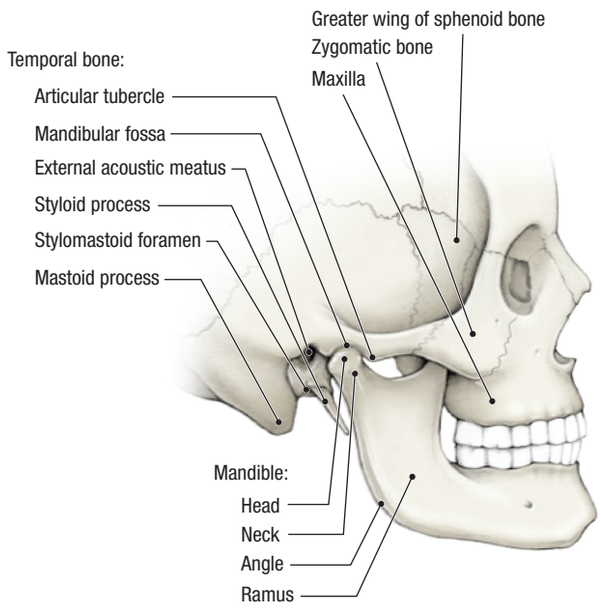

Figure 7.53. Skeleton of the parotid region in lateral view.

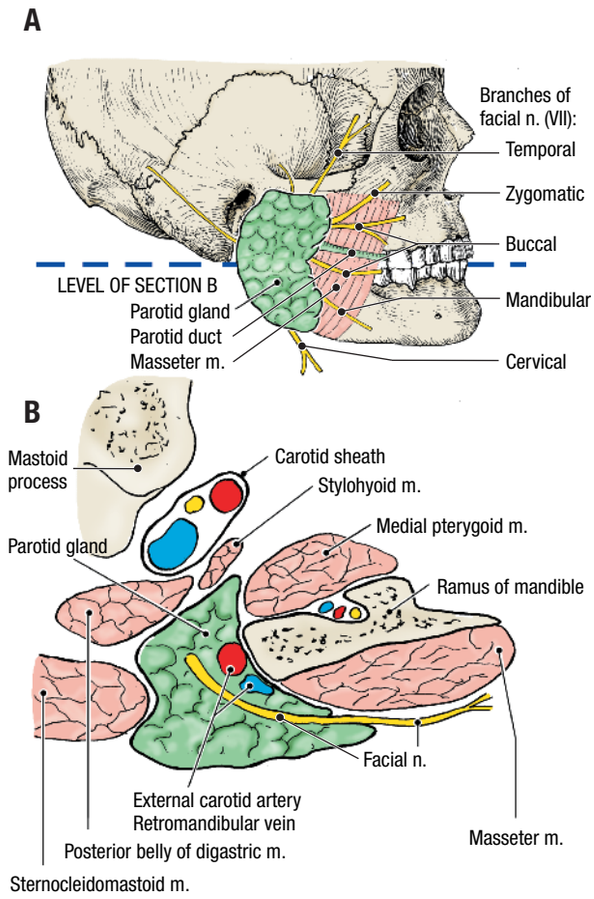

Figure 7.54. Topographic relations of the parotid gland. A. Lateral view. Dashed line indicates the level of section B. B. Transverse section through the parotid bed.

Use the skull and an illustration to define the **boundaries of the parotid bed** (Fig. 7.54B): [G 653; N 30; R 77; C 467]

- **Posterior** – mastoid process and posterior belly of the digastric muscle
- **Anterior** – medial pterygoid muscle, ramus of the mandible, and masseter muscle
- **Medial** – styloid process and associated muscles (stylopharyngeus, styloglossus, and stylohyoid)
- **Posterosuperior** – floor of the external acoustic meatus

Dissection Instructions

1. Review the course of the parotid duct. The parotid duct enters the oral vestibule lateral to the second maxillary molar tooth.
2. Review the branches of the facial nerve: temporal, zygomatic, buccal, mandibular, and cervical (Fig. 7.54A). [G 652; N 21; R 77; C 469]
3. The parotid gland is enclosed within the **parotid sheath**. The parotid sheath and the stroma of the parotid gland are continuations of the investing layer of the deep cervical fascia. This tough connective tissue will not yield to probe dissection. To dissect into the parotid gland, use the tip of a scalpel blade as you would normally use a probe.
4. Trace the facial nerve branches posteriorly toward the lobe of the ear. Remove small pieces of the parotid

gland and place them in the tissue container. The branches will unite to form the **facial nerve**.

5. Follow the facial nerve as far as possible toward the stylomastoid foramen. Cut the facial nerve, leaving a short stump emerging from the stylomastoid foramen. Reflect the facial nerve and all of its branches anteriorly.
6. Cut the **parotid duct** at the anterior margin of the parotid gland and reflect the duct anteriorly. Do not disturb its passage through the buccinator muscle.
7. Identify the **auriculotemporal nerve**, a branch of the mandibular nerve (V_3). The auriculotemporal nerve passes between the head of the mandible and the external acoustic meatus. It crosses the zygomatic process of the temporal bone to innervate the skin of the anterior side of the ear and temporal region. The auriculotemporal nerve carries postganglionic parasympathetic nerve fibers from the otic ganglion to the parotid gland.
8. In the neck, find the **external jugular vein**. Use blunt dissection to follow the external jugular vein superiorly to the point where it is formed by the joining of the posterior auricular vein and the retromandibular vein.
9. Use blunt dissection to follow the retromandibular vein superiorly until it enters the parotid gland. Do not cut the posterior belly of the digastric muscle. Switch to the scalpel dissection technique and remove small pieces of parotid tissue as you follow the retromandibular vein through the parotid gland.
10. Trace the retromandibular vein to the point where it is formed by the joining of the **maxillary vein** and the **superficial temporal vein**. The maxillary vein will be dissected later.
11. Follow the **superficial temporal vein** superiorly and note that it crosses the superficial surface of the zygomatic arch. The branches of the superficial temporal vein are in the connective tissue layer of the scalp. The auriculotemporal nerve crosses the zygomatic arch posterior to the superficial temporal vein.
12. Return to the neck and find the **external carotid artery**. Use blunt dissection to follow the external carotid artery to the inferior border of the parotid gland, then switch to the scalpel dissection technique. **[G 653; N 30; R 79; C 476]**
13. Follow the external carotid artery superiorly. It passes along the posterior edge of the ramus of the mandible (Fig. 7.54B). Posterior to the neck of the mandible, the external carotid artery divides into its two terminal branches, the **maxillary artery** and the **superficial temporal artery**. The maxillary artery will be dissected later.
14. Use the scalpel dissection technique to clean the **superficial temporal artery**. The superficial temporal artery crosses the zygomatic process of the temporal bone just anterior to the external acoustic meatus. At this location, the superficial temporal artery is anterior to the auriculotemporal nerve. The superficial temporal artery supplies the lateral portion of the scalp.
15. Clean the lateral surface of the **posterior belly of the digastric muscle** and the **stylohyoid muscle**. Use the scalpel technique to remove all other remnants of the parotid gland.

CLINICAL CORRELATION

Parotid Gland

Because of the close relationship between the parotid gland and the external acoustic meatus, swelling of the parotid gland (as occurs in mumps, for example) pushes the ear lobe superiorly and laterally. During parotidectomy (surgical excision of the parotid gland), the facial nerve is in danger of being injured. If the facial nerve is damaged, the facial muscles are paralyzed.

After you dissect . . .

Replace the facial nerve in its correct anatomical position and approximate the cut ends. Replace the parotid duct in its correct anatomical position. Use an illustration, a skull and the dissected specimen to review the course of the facial nerve from the internal acoustic meatus to the facial muscles. Review the superficial venous drainage of the lateral side of the head and neck, beginning with the superficial temporal veins and ending with the subclavian vein in the root of the neck. Review the origin, course, and branches of the external carotid artery. Review the boundaries of the parotid bed.

TEMPORAL REGION

Before you dissect . . .

The **temporal region** consists of two fossae: temporal and infratemporal. The **temporal fossa** is located superior to the zygomatic arch and it contains the temporalis muscle. The **infratemporal fossa** is inferior to the zygomatic arch and deep to the ramus of the mandible. The infratemporal fossa contains the medial and lateral pterygoid muscles, branches of the mandibular nerve (V_3), and the maxillary artery and vein. The infratemporal and temporal fossae are in open communication with each other through the interval between the zygomatic arch and the lateral surface of the skull.

The dissection will proceed as follows: The masseter muscle will be studied and reflected. The zygomatic arch will be removed and the temporalis muscle will be studied. The superior part of the ramus of the mandible will then be removed and the maxillary artery will be traced across the infratemporal fossa. The branches of the mandibular nerve will be dissected. The medial and lateral pterygoid muscles will be studied and the temporomandibular joint will be dissected.

SKELETON OF THE TEMPORAL REGION

Refer to a skull and identify the following (Fig. 7.03): **[G 654; N 4; R 25; C 481]**

- **Superior and inferior temporal lines** – on the parietal bone
- **Temporal fossa** – formed by parts of four cranial bones: parietal, frontal, squamous part of temporal, and greater wing of sphenoid. Review the location of the pterion.

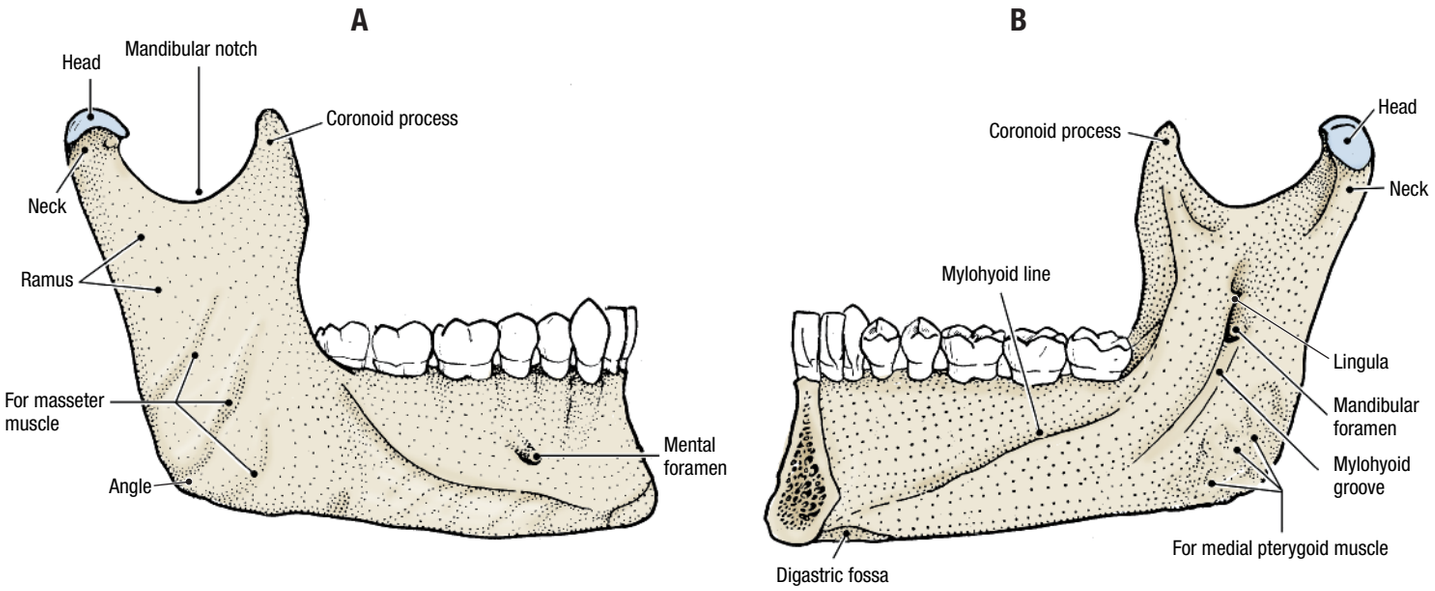

Figure 7.55. Mandible. **A.** External surface. **B.** Internal surface.

- **Zygomatic arch** – formed by **the zygomatic process of the temporal bone** and the **temporal process of the zygomatic bone**
- **Mandibular fossa and articular tubercle** – on the temporal bone (Fig. 7.53)

On the **external surface of the mandible**, identify (Fig. 7.55A): **[G 654; N 13; R 55; C 543]**

- **Head**
- **Neck**
- **Mandibular notch**
- **Coronoid process**
- **Ramus**
- **Angle**

On the **internal surface of the mandible**, identify (Fig. 7.55B):

- **Lingula** – for the attachment of the sphenomandibular ligament
- **Mandibular foramen** – for the inferior alveolar nerves and vessels
- **Mylohyoid groove** – for the mylohyoid nerve and vessels

Remove the mandible from the skull and view the bones of the infratemporal fossa from the lateral perspective. Identify (Fig. 7.56): **[G 655; N 4; C 503]**

- **Pterygomaxillary fissure** – between the lateral plate of the pterygoid process and the maxilla
- **Inferior orbital fissure** – between the greater wing of the sphenoid bone and the maxilla
- **Infratemporal surface** of the maxilla
- **Greater wing of the sphenoid bone** – contains the **foramen ovale** and the **foramen spinosum**
- **Lateral plate of the pterygoid process** of the sphenoid bone
- **Pterygopalatine fossa** – at the superior end of the pterygomaxillary fissure
- **Sphenopalatine foramen** – opening into the nasal cavity

Reposition the mandible on the skull and identify the **boundaries of the infratemporal fossa**:

- **Lateral** – ramus of the mandible
- **Anterior** – the infratemporal surface of the maxilla
- **Medial** – lateral plate of the pterygoid process
- **Roof** – greater wing of the sphenoid bone

Dissection Instructions

REMOVAL OF THE ZYGOMATIC ARCH

1. Reflect the facial nerve branches and the parotid duct anteriorly.
2. Clean the lateral surface of the **masseter muscle**. The superior attachment of the masseter muscle is the inferior border of the zygomatic arch and its inferior attachment is the lateral surface of the ramus of the mandible. The masseter muscle elevates the mandible (closes the jaw) and protrudes the mandible. **[G 656; N 50; R 58; C 467]**

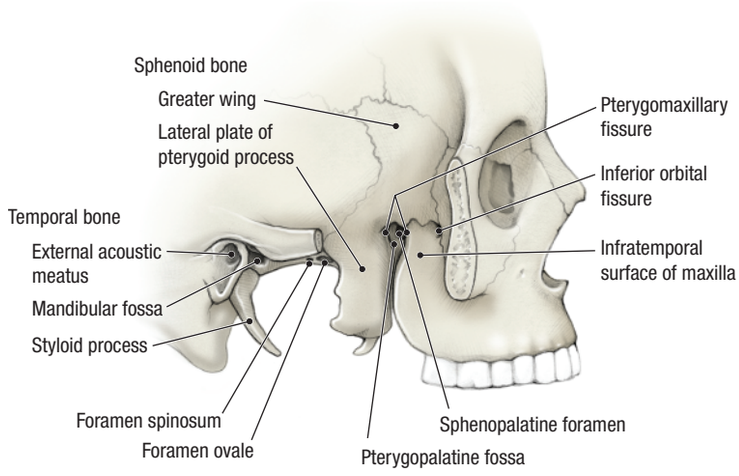

Figure 7.56. Skeleton of the infratemporal region.

3. Use scissors to cut the **temporal fascia** along its attachment to the superior border of the zygomatic arch.
4. Insert a probe deep to the zygomatic arch as far anteriorly as possible (arrow 1, Fig. 7.57). Use a saw to cut through the zygomatic bone to the probe.
5. Insert the probe deep to the zygomatic arch near the anterior border of the head of the mandible (arrow 2, Fig. 7.57). Use a saw to cut through the zygomatic arch to the probe.
6. Reflect the masseter muscle and the attached portion of the zygomatic arch in the inferior direction. Use a scalpel to detach the masseter muscle from the lateral surface of the coronoid process and the superior part of the ramus of the mandible, but leave the masseter muscle attached to the inferior part of the ramus. During reflection, the nerve and vessels to the masseter muscle will be cut.

TEMPORAL FOSSA [G 656; N 50; R 58; C 467]

1. Note that the superficial temporal vessels and the auriculotemporal nerve are located in the scalp, superficial to the temporal fascia.
2. The temporal fascia is attached to the superior temporal line and was cut at that location when the calvaria was removed. Cut the temporal fascia along the superior border of the zygomatic arch and remove the fascia completely.
3. Identify the **temporalis (temporal) muscle**. Observe that the:
   - Temporalis muscle is attached to the deep surface of the temporal fascia.
   - Inferior attachment of the temporalis muscle is the coronoid process of the mandible.
   - Fibers of the anterior portion of the temporalis muscle have a vertical direction (important for elevation of the mandible).
   - Fibers of the posterior portion of the temporalis muscle have a more horizontal direction (important for retrusion of the mandible).

INFRATEMPORAL FOSSA [G 658; N 36; R 80; C 478]

1. The ramus of the mandible must be removed to view the contents of the infratemporal fossa. *Wear eye protection for all steps that require the use of bone cutters.*
2. Insert a probe through the mandibular notch and push it anteroinferiorly toward the third mandibular molar tooth (arrow 1, Fig. 7.58). Keep the probe in close contact with the deep surface of the mandible. Use a saw to cut through the coronoid process to the probe.
3. Reflect the coronoid process together with the temporalis muscle in the superior direction. Use blunt dissection to release the temporalis muscle from the skull and note that the temporal nerves enter the muscle from its deep surface. The temporal nerves are accompanied by deep temporal arteries.
4. Insert a probe medial to the neck of the mandible (arrow 2, Fig. 7.58). Use a saw to cut through the neck of the mandible to the probe.
5. Hold a mandible beside the cadaver and estimate the position of the lingula. Use a pencil to mark the position of the lingula on the lateral surface of the cadaver's mandible.
6. Insert the handle of a probe medial to the neck of the mandible and slide it inferiorly until it catches on the lingula (arrow 3, Fig. 7.58). Use a saw to cut down to the probe and remove the superior part of the ramus of the mandible.
7. Deep to the mandible, identify the **lateral pterygoid muscle** (Fig. 7.59A). The lateral pterygoid muscle has two heads. The anterior attachment of the superior head is the infratemporal surface of the greater wing of the sphenoid bone. The anterior attachment of the inferior head is the lateral surface of the lateral plate of the pterygoid process. The posterior attachments of the lateral pterygoid muscle are the neck of the mandible and the articular disc within the capsule of the temporomandibular joint. The lateral pterygoid muscle depresses the mandible (opens the jaw). [G 662; N 51; R 59; C 478]

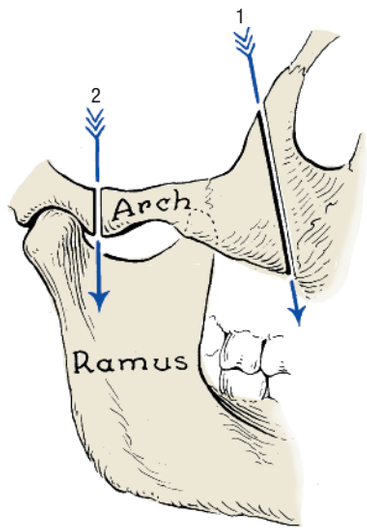

Figure 7.57. How to cut the zygomatic arch.

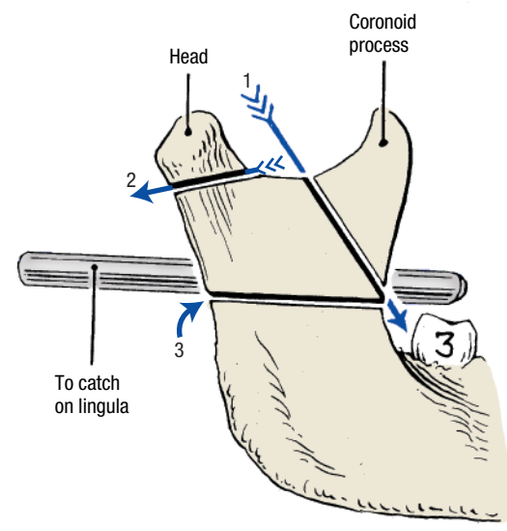

Figure 7.58. How to cut the ramus of the mandible.

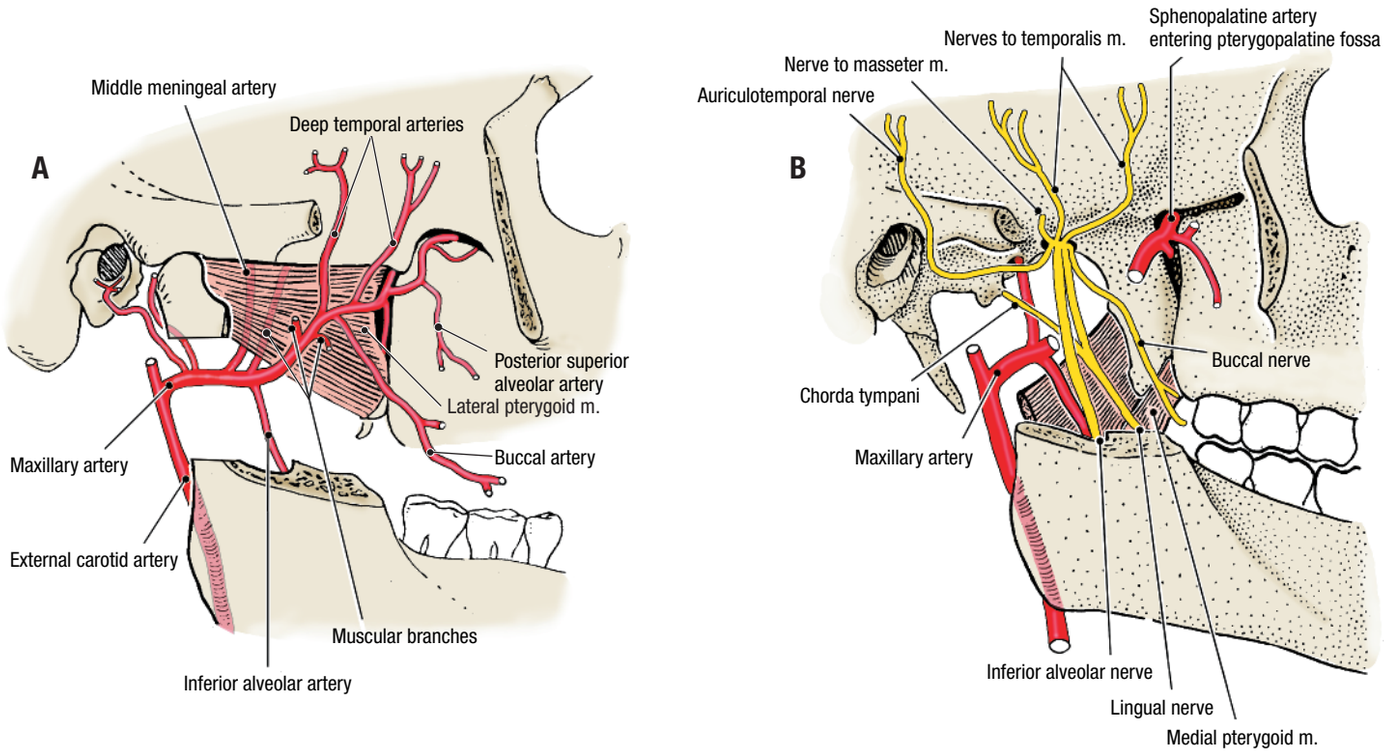

Figure 7.59. Arteries and nerves of the infratemporal fossa. **A.** Branches of the maxillary artery. **B.** Branches of the mandibular nerve (V_3).

8. Identify the **medial pterygoid muscle** (Fig. 7.59B). The proximal attachments of the medial pterygoid muscle are the maxilla and the medial surface of the lateral plate of the pterygoid process. The distal attachment of the medial pterygoid muscle is the inner surface of the ramus of the mandible. The medial pterygoid muscle elevates the mandible (closes the jaw).
9. On the superficial surface of the medial pterygoid muscle, identify the **inferior alveolar nerve** and **vessels** (Fig. 7.59A,B). Clean the inferior alveolar nerve and follow it to the mandibular foramen. The mylohyoid nerve arises from the inferior alveolar nerve at the mandibular foramen.
10. The inferior alveolar nerve and vessels enter the mandibular foramen and pass distally in the **mandibular canal**. Note that the inferior alveolar nerve provides sensory innervation to the **mandibular teeth**. The **mental nerve** is a branch of the inferior alveolar nerve, which passes through the mental foramen to innervate the chin and lower lip.
11. Identify the **lingual nerve**. The lingual nerve emerges between the lateral and medial pterygoid muscles just anterior to the inferior alveolar nerve. The lingual nerve passes medial to the third mandibular molar tooth and it innervates the mucosa of the anterior 2/3 of the tongue and floor of the oral cavity.

CLINICAL CORRELATION

Dental Anesthesia

A mandibular nerve block is produced by injecting an anesthetic agent into the infratemporal fossa. Understand from your dissection that the mandibular nerve block will not only anesthetize the mandibular teeth but also the lower lip, the chin, and the tongue.

12. Identify the **maxillary artery** where it arises from the bifurcation of the external carotid artery (Fig. 7.59A). The maxillary artery crosses either the superficial surface (2/3) or the deep surface (1/3) of the lateral pterygoid muscle. If the maxillary artery in your specimen passes deep to the lateral pterygoid muscle, perform step 14 first and then return to step 13. **[G 659, 660; N 36; R 80; C 479]**
13. Use blunt dissection to trace the maxillary artery through the infratemporal fossa. The maxillary artery has 15 branches. Identify only the following (Fig. 7.59A):
    - **Middle meningeal artery** – arises medial to the neck of the mandible and passes through the foramen spinosum to supply the dura mater.
    - **Deep temporal arteries (anterior and posterior)** – pass across the roof of the infratemporal

fossa at bone level and enter the deep surface of the temporalis muscle.
- **Masseteric artery** – passes through the mandibular notch to enter the deep surface of the masseter muscle (cut in a previous dissection step).
- **Inferior alveolar artery** – enters the mandibular foramen with the inferior alveolar nerve.
- **Buccal artery** – passes anteriorly to supply the cheek.

14. Remove the **lateral pterygoid muscle** to see the deeper part of the infratemporal fossa. Define the inferior border of the lateral pterygoid muscle by inserting a probe between it and the medial pterygoid muscle. Use scissors to cut the lateral pterygoid muscle close to its posterior attachments to the neck of the mandible and the articular disc. Remove the muscle in a piecemeal fashion to preserve superficially positioned nerves and vessels.
15. Use a probe to follow the **inferior alveolar nerve** and the **lingual nerve** to the foramen ovale in the roof of the infratemporal fossa. Identify the **chorda tympani**, which joins the posterior side of the lingual nerve (Fig. 7.59B).
16. Follow the maxillary artery toward the **pterygopalatine fossa**. Within the pterygopalatine fossa the maxillary artery divides into four terminal branches: posterior superior alveolar artery, infraorbital artery, descending palatine artery and sphenopalatine artery. Identify only the **posterior superior alveolar artery**, which enters the infratemporal surface of the maxilla (Fig. 7.59A). The other branches will be dissected later.

TEMPOROMANDIBULAR JOINT [G 665; N 14; R 56; C 473]

1. Identify the capsule of the **temporomandibular joint**. The joint capsule is loose and its lateral surface is reinforced by the **temporomandibular ligament**.
2. Insert the point of a scalpel into the temporomandibular joint close to the mandibular fossa and open the **superior synovial cavity** of the joint (Fig. 7.60). Remove the head of the mandible along with the articular disc.

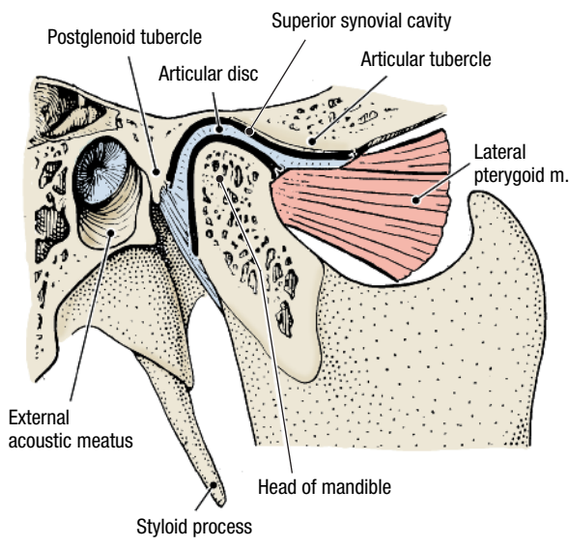

Figure 7.60. The temporomandibular joint.

3. Examine the isolated specimen and note that the tendon of the lateral pterygoid muscle is attached to the neck of the mandible and the articular disc (Fig. 7.60). Cut the articular capsule to open the **inferior synovial cavity** and observe the shape and variable thickness of the articular disc.
4. Two types of movements occur in the temporomandibular joint. In the superior synovial cavity, gliding movements occur between the articular disc and the articular tubercle (protrusion and retrusion). In the inferior synovial cavity, hinge movements occur between the head of the mandible and the articular disc.
5. Place your 5th digit in the cartilaginous portion of your external acoustic meatus. Perform hinge movements of the mandible, then protrude and retrude your mandible as you palpate the head of the mandible.

After you dissect . . .

Review the attachments and actions of the four muscles of mastication (masseter, temporalis, medial pterygoid and lateral pterygoid). In the middle cranial fossa, review the origin of the mandibular nerve (V_3) at the trigeminal ganglion and trace it to the foramen ovale. Follow the mandibular nerve through the foramen ovale into the infratemporal fossa. Review the sensory and motor branches of the mandibular nerve. Follow the external carotid artery from its origin at the level of the hyoid bone to the infratemporal fossa. Review the course of the superficial temporal artery and the maxillary artery. Follow the branches of the maxillary artery that were dissected to their regions of supply. Note the relationship of the middle meningeal artery to the auriculotemporal nerve. Use an illustration and the dissected specimen to review the termination of the maxillary artery in the pterygopalatine fossa.

CRANIOVERTEBRAL JOINTS AND REMOVAL OF THE HEAD

Before you dissect . . .

The head must be detached from the vertebral column to allow a posterior approach to the cervical viscera. The joints between the skull and the first cervical vertebra (craniovertebral joints) are the logical site for separation of the head from the vertebral column.

The order of dissection will be as follows: The retropharyngeal space will be opened from the base of the skull to the superior thoracic aperture. The ligaments of the craniovertebral joints will be cut. The atlanto-occipital joints (left and right) will be disarticulated and the prevertebral muscles will be cut.

SKELETON OF THE SUBOCCIPITAL REGION

Refer to a skeleton and identify the following: [G 320; N 15, 17, 18; R 193; C 419, 420]

- **Atlas (C1)** (Fig. 7.61)
  - **Anterior arch**
  - **Superior articular facet**
  - **Transverse process**
  - **Posterior arch**
- **Axis (C2)**
  - **Dens**

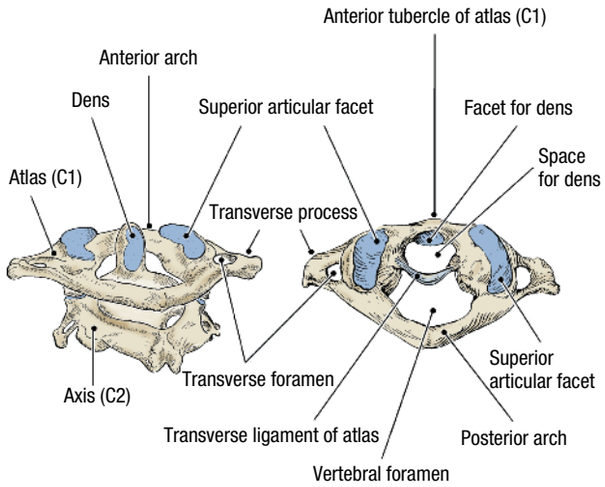

Figure 7.61. Skeleton and ligaments of the atlanto-axial joint.

- **Occipital bone** (Fig. 7.62)
  - **Occipital condyle**
  - **Pharyngeal tubercle**
  - **Foramen magnum**
- **Atlanto-occipital joint** – between the occipital condyle and the superior articular facet of the atlas
- **Transverse ligament of the atlas** – holds the dens to the anterior arch of the atlas (Fig. 7.61)

Dissection Instructions

RETROPHARYNGEAL SPACE

1. Review the structures that pass through the foramen magnum: brainstem, vertebral arteries (left and right), and the cervical roots of the accessory nerves (left and right). Review the hypoglossal nerve (XII) where it enters the hypoglossal canal. Review the structures that enter the jugular foramen: glossopharyngeal nerve (IX), vagus nerve (X), accessory nerve (XI), and sigmoid sinus.
2. Reflect the sternocleidomastoid muscle on both sides, taking care to separate each muscle from deeper structures all the way to the mastoid process.
3. Insert the fingers of both hands posterior to the carotid sheaths (arrow in Fig. 7.63). Push your fingers medially until they meet posterior to the cervical viscera. Your fingers are now in the **retropharyngeal space**.
4. To separate the viscera from the vertebral column, work your fingers superiorly as far as the basilar part of the occipital bone. This is the superior limit of the retropharyngeal space. Work your fingers inferiorly toward the superior thoracic aperture. Note that the retropharyngeal space extends into the superior mediastinum.

CRANIOVERTEBRAL JOINTS

1. Turn the cadaver to the prone position. A wedge-shaped portion of the occipital bone was removed earlier (Fig. 7.64).
2. If not already done during the dissection of the suboccipital region, use bone cutters to remove the posterior arch of the atlas (Fig. 7.64). Open the spinal dura mater and remove the cervical spinal cord.
3. Strip the dura mater from the anterior border of the foramen magnum and identify the **tectorial membrane** (Fig. 7.65). The tectorial membrane is continuous with the posterior longitudinal ligament. Superior to the anterior border of the foramen magnum, cut the tectorial membrane and reflect it inferiorly as far as possible (Fig. 7.65). **[G 321; N 18; R 193; C 420]**
4. Anterior to the tectorial membrane identify the **cruciate ligament of the atlas** (Fig. 7.65). The cruciate ligament has three parts:
   - **Superior longitudinal band**
   - **Transverse ligament of the atlas**
   - **Inferior longitudinal band**
5. Use a scalpel to cut the superior longitudinal band. Anterior to the cruciate ligament of the atlas, identify the left and right **alar ligaments** (Fig. 7.65). The alar

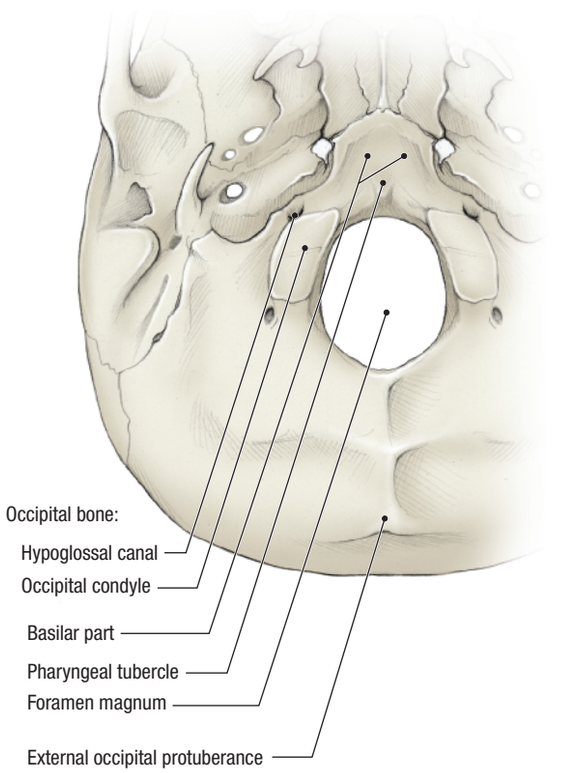

Figure 7.62. Occipital bone, inferior view.

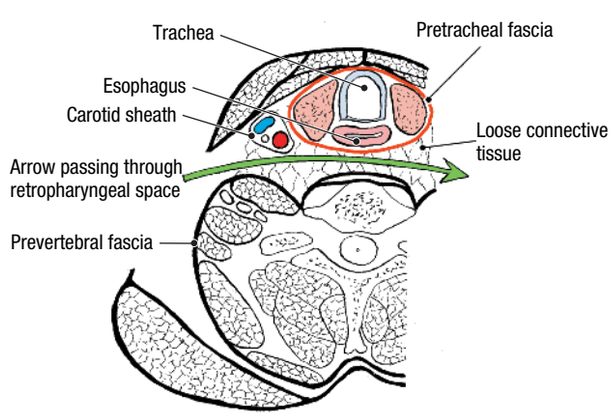

Figure 7.63. Transverse section through the neck.

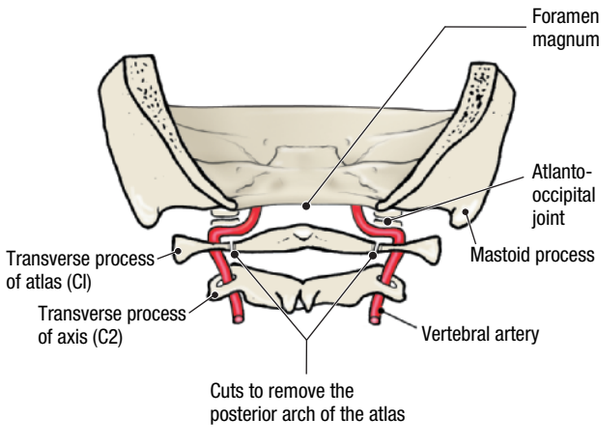

Figure 7.64. Atlanto-occipital joint in posterior view.

ligaments extend from the dens to the lateral margins of the foramen magnum and they control lateral rotation and side-to-side movements of the head.

6. Use a scalpel to cut the alar ligaments close to the dens. Note that the rotation of the head is now very easy and extensive.

REMOVAL OF THE HEAD

1. Use a scalpel to open the capsule of the **atlanto-occipital joint** on both sides (Fig. 7.64). Force a chisel into each atlanto-occipital joint and disarticulate it.
2. Turn the cadaver to the supine position. Retract the cervical viscera and contents of the carotid sheath anteriorly. **[G 761; N 26; C 456]**
3. Identify the **sympathetic trunk** and the **superior cervical sympathetic ganglion** on the anterior surface of the cervical vertebral column. On the left side, sever the **internal carotid nerve** just superior to the superior cervical ganglion and leave the sympathetic trunk attached to the vertebral column. On the right side, reflect the sympathetic trunk and the superior cervical ganglion with the head and cervical viscera.
4. Protect cranial nerves IX, X, XI, and XII where they emerge from the base of the skull near the internal jugular vein. Insert a scalpel blade between the transverse process of the atlas and the occipital bone and sever the **rectus capitis lateralis muscle** on each side (Fig. 7.66). Repeat this cut on the opposite side of the neck.
5. More medially, sever the **rectus capitis anterior** and **longus capitis muscles**. Repeat this cut on the opposite side of the neck. Cut across the median plane just superior to the anterior arch of the atlas. Push the head anteriorly to detach it from the vertebral column.

PREVERTEBRAL AND LATERAL VERTEBRAL REGIONS [G 760; N 124; R 180; C 452]

1. On the anterior surface of the cervical vertebral column, examine the **prevertebral fascia.** The prevertebral fascia covers the prevertebral muscles (longus colli and longus capitis muscles) and the lateral vertebral muscles (anterior, middle and posterior scalene muscles).
2. On the left side of the cervical vertebral column, study the **sympathetic trunk**. Identify the **superior**, **middle**, and **inferior cervical sympathetic ganglia**. Observe the **gray rami communicantes** that connect the sympathetic ganglia with the ventral rami of cervical spinal nerves. Frequently, the inferior cervical ganglion is fused with the 1st thoracic ganglion to form the **cervicothoracic (stellate) ganglion**.

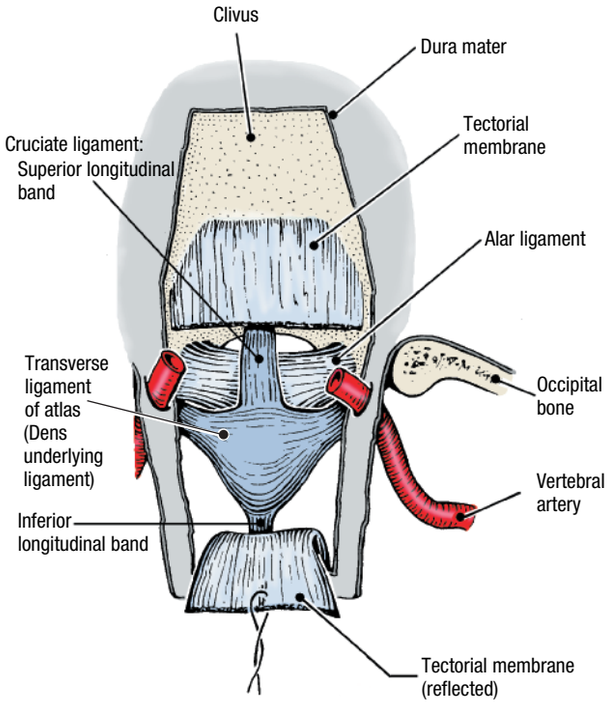

Figure 7.65. Atlantoaxial joint, posterior view.

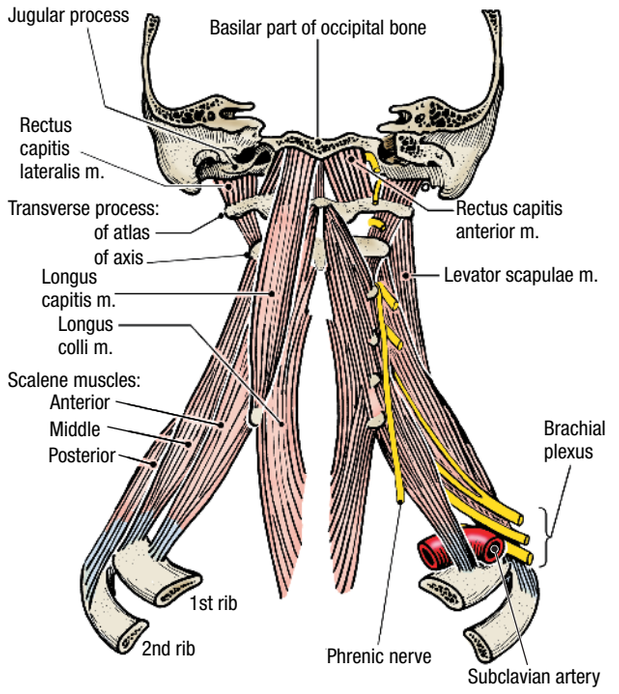

Figure 7.66. Prevertebral muscles.

3. Identify the **longus colli, longus capitis** and **anterior scalene muscles** (Fig. 7.66). Review the contributions to the brachial plexus made by the ventral rami of spinal nerves C5-C8.
4. Follow the vertebral artery into the transverse foramen of vertebra C6 and observe where it emerges from the transverse foramen of the atlas (C1). Appreciate that the vertebral artery is well protected within the foramina transversaria.

After you dissect . . .

Use a skull to review the anatomy of the occipital bone. In the cadaver, review the structures that pass through the foramen magnum, hypoglossal canal, and jugular foramen. Use a skeleton to study the atlanto-axial and atlanto-occipital joints. Review the course of the sympathetic trunk from the upper thorax to the base of the skull. Review the origin and relationships of the roots of the brachial plexus.

PHARYNX

Before you dissect . . .

The airway crosses the digestive tract in the pharynx. The pharynx extends from the base of the skull to the inferior border of the cricoid cartilage (vertebral level C6). The **pharyngeal wall** consists of three layers. From outside inward these layers are:

- **Buccopharyngeal fascia** – the adventitia of the pharynx that is continuous with the connective tissue that covers the buccinator muscle
- **Muscular layer** – composed of an outer circular part and an inner longitudinal part
- **Mucous membrane**

The order of dissection will be as follows: The external surface of the pharynx will be dissected from the posterior direction. The pharyngeal plexus of nerves will be identified and the borders of the pharyngeal constrictor muscles will be defined. The stylopharyngeus muscle and glossopharyngeal nerve will be identified. The contents of the carotid sheath will be examined and cranial nerves IX, X, XI, and XII will be followed from the base of the skull to their regions of distribution. The sympathetic trunk will be studied.

Dissection Instructions

MUSCLES OF THE PHARYNGEAL WALL [G 767, 768; N 63; R 165; C 548, 550]

1. The cadaver should be in the supine position. Push the head anteroinferiorly and let the chin rest on the thorax. Use a probe to clean the buccopharyngeal fascia from the posterior surface of the pharynx.
2. Identify the **inferior pharyngeal constrictor muscle**. The anterior attachments of the inferior pharyngeal constrictor muscle are the oblique line of the thyroid cartilage and the lateral surface of the cricoid cartilage (Fig. 7.67B). The posterior attachment of the inferior pharyngeal constrictor muscle is the **pharyngeal raphe**. Beginning near the thyroid cartilage, use blunt dissection to clean the superior border of the inferior pharyngeal constrictor muscle.
3. Identify the **middle pharyngeal constrictor muscle**. The anterior attachments of the middle pharyngeal constrictor muscle are the greater horn of the hyoid bone and the inferior portion of the stylohyoid ligament (Fig. 7.67B). The posterior attachment of the middle pharyngeal constrictor muscle is the pharyngeal raphe. Note that the inferior part of the middle pharyngeal constrictor muscle lies deep to the inferior pharyngeal constrictor muscle. Use blunt dissection to clean the superior border of the middle pharyngeal constrictor muscle.
4. Superior to the middle pharyngeal constrictor, identify the **superior pharyngeal constrictor muscle**. The anterior attachment of the superior pharyngeal constrictor muscle is the **pterygomandibular raphe** and its posterior attachments are the pharyngeal raphe and **pharyngeal tubercle** of the occipital bone (Fig. 7.67A). Note that the inferior part of the superior pharyngeal constrictor muscle lies deep to the middle pharyngeal constrictor muscle.
5. Use blunt dissection to define the superior border of the superior pharyngeal constrictor muscle. The dense connective tissue membrane that attaches the superior edge of the superior constrictor to the base of the skull is the **pharyngobasilar fascia**.
6. To find the **stylopharyngeus muscle**, palpate the greater horn of the hyoid bone. One finger's width above the greater horn of the hyoid bone, the stylopharyngeus muscle passes between the superior pharyngeal constrictor and the middle pharyngeal constrictor muscles (Fig. 7.67A).
7. Use a probe to clean the posterior and lateral surfaces of the stylopharyngeus muscle. Identify the **glossopharyngeal nerve (IX)** that courses around the lateral surface of the stylopharyngeus muscle to enter the pharynx (Fig. 7.68A). **[G 769; N 67; R 163; C 551]**
8. Examine the inferior border of the inferior constrictor muscle (Fig. 7.68B). Note that the most inferior fibers of the inferior constrictor muscle are continuous with the circular fibers of the esophagus. At this location the **recurrent laryngeal nerve** enters the pharyngeal wall.
9. Identify the **pharyngeal plexus of nerves** (Fig. 7.68A). The pharyngeal plexus is located on the posterolateral aspect of the pharynx. The pharyngeal plexus receives branches from the glossopharyngeal nerve (sensory to the pharyngeal mucosa), vagus nerve (motor to the pharyngeal constrictor muscles), and superior cervical sympathetic ganglion (vasomotor).
10. Identify the **contents of the carotid sheath** from the posterior view (Fig. 7.68A). Follow the internal carotid artery superiorly as far as possible. Note that the internal jugular vein is lateral to the internal carotid artery.
11. Identify the **glossopharyngeal nerve (IX)**, **vagus nerve (X)**, and **accessory nerve (XI)** where they exit

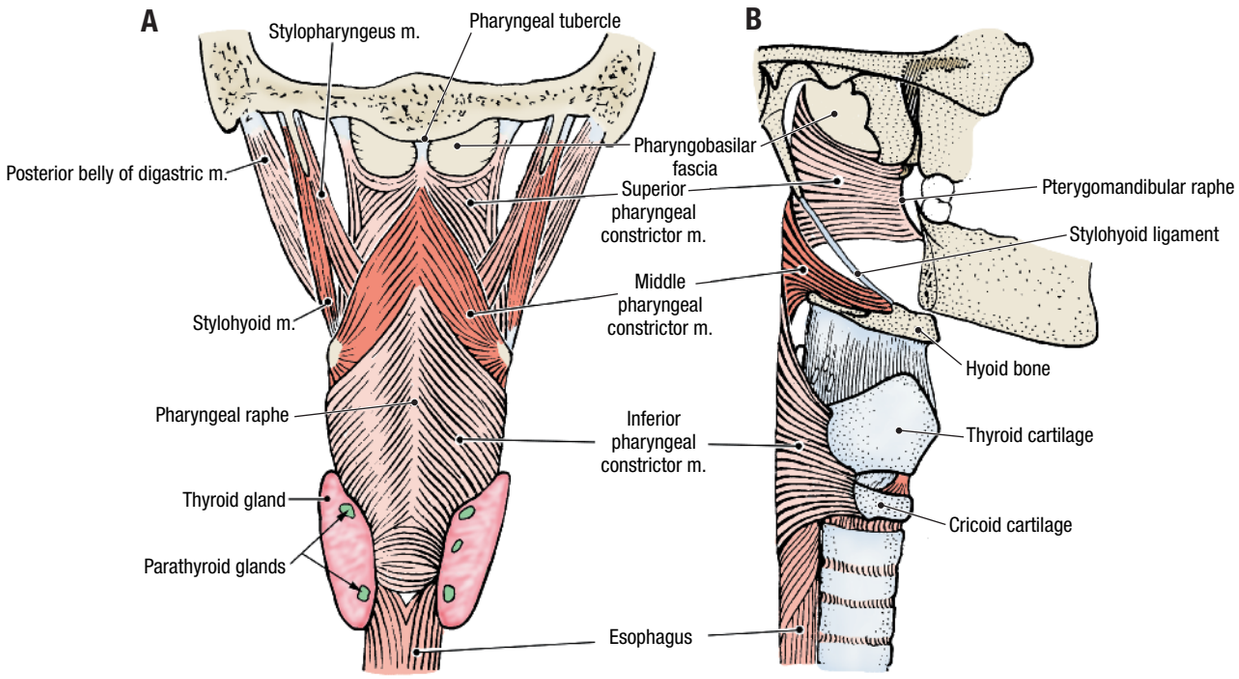

Figure 7.67. Muscles of the pharynx. **A.** Posterior view. **B.** Lateral view.

the jugular foramen medial to the internal jugular vein (Fig. 7.68A).

- **Glossopharyngeal nerve (IX)** – passes between the internal and external carotid arteries as it approaches the stylopharyngeus muscle.
- **Vagus nerve** – lies posterior to the internal carotid artery and internal jugular vein in the carotid sheath. Trace the vagus nerve from the base of the skull to the thorax. The **superior laryngeal nerve** arises from the vagus nerve about 2.5 cm inferior to the base of the skull. Trace the branches of the superior laryngeal nerve to the larynx (Fig. 7.68B).

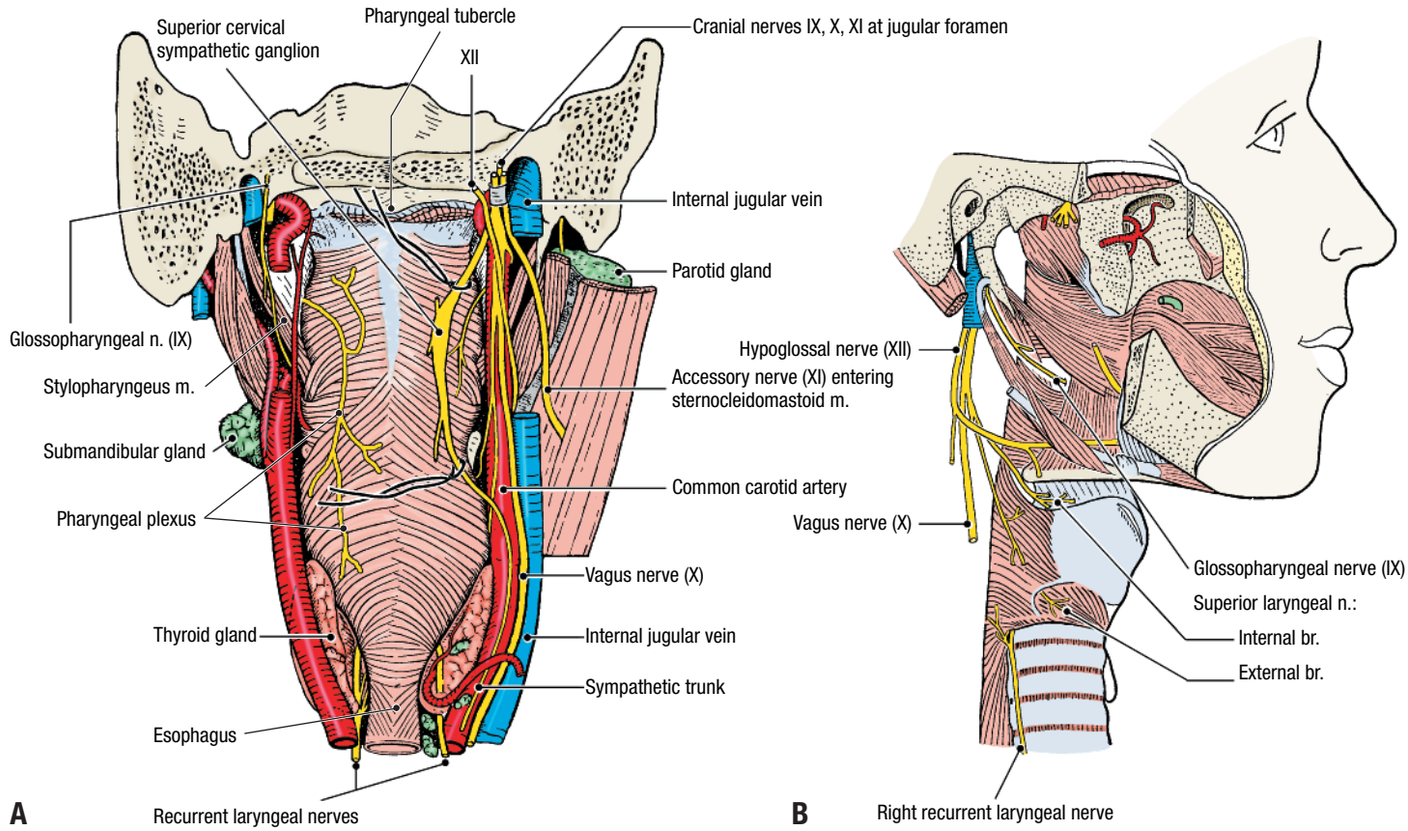

Figure 7.68. Nerves and vessels related to the pharyngeal wall. **A.** Posterior view. **B.** Lateral view.

The **pharyngeal branch of the vagus nerve** arises near the base of the skull. Follow the pharyngeal branch to the pharyngeal plexus.

- **Accessory nerve (XI)** – passes between the internal jugular vein and the internal carotid artery to reach the deep surface of the sternocleidomastoid muscle (Fig. 7.68A).

12. Identify the **hypoglossal nerve (XII)** in the submandibular triangle and follow it posteriorly and superiorly as far as the base of the skull (Fig. 7.68B). Note that the hypoglossal nerve passes lateral to the internal and external carotid arteries.
13. On the right side of the cadaver, verify that the **superior cervical sympathetic ganglion** and the **sympathetic trunk** are posterior to the carotid sheath (Fig. 7.68A).

BISECTION OF THE HEAD

1. Use scissors to cut the posterior wall of the pharynx in the midline. Start at the superior end of the esophagus and cut through the pharyngeal raphe up to the pharyngeal tubercle.
2. Use a scalpel to divide the uvula and the soft palate in the median plane.
3. Turn the specimen and use a scalpel to cut through the upper lip in the midline.
4. The skull must be sawed just lateral to the median plane. The nasal septum may not be in the median plane, so you must examine each nasal cavity and decide on which side the saw cut should be made in order to avoid the nasal septum.
5. On the chosen side, use a scalpel to cut through the cartilages of the external nose parallel to the nasal septum.
6. Examine a skull and study the bones through which you must cut:
   - **Nasal bone** and **frontal bone**
   - **Cribriform plate** of one ethmoid bone
   - **Body of the sphenoid bone**
   - **Hard palate**
   - **Basilar part of the occipital bone** as far as the **foramen magnum**
7. Saw through the skull from superior to inferior. Begin lateral to the crista galli and keep the blade close to the nasal septum. Cut through the nasal and frontal bones, ethmoid bone, body of the sphenoid, dorsum sellae, basilar part of the occipital bone, and hard palate. Stop when the saw has passed into the foramen magnum. Do not cut the tongue or mandible at this time.
8. The two superior halves of the head should separate from each other. The tongue should be exposed.

INTERNAL ASPECT OF THE PHARYNX [G 788; N 59; R 153; C 549]

1. The lumen of the pharynx communicates anteriorly with three cavities: nose, mouth, and larynx (Fig. 7.69). Identify the parts of the pharynx: **nasopharynx**, **oropharynx**, and **laryngopharynx (hypopharynx)**.
2. The **nasopharynx** lies posterior to the nose and superior to the soft palate (Fig. 7.69). Identify the posterior nasal aperture (**choana)** that is the transition region from the nasal cavity to the nasopharynx. The choanae of the two sides are separated by the posterior end of the nasal septum. [G 774; N 60; C 525]
3. On the lateral wall of the nasopharynx identify the **opening of the pharyngotympanic tube (auditory tube, eustachian tube)**.
4. Posterior to the opening of the pharyngotympanic tube, identify the **torus tubarius**, which is the cartilage of the pharyngotympanic tube that is covered by mucosa (Fig. 7.69). The **salpingopharyngeal fold** extends posteroinferiorly from the torus tubarius.
5. Posterior to the torus tubarius identify the **pharyngeal recess**. The **pharyngeal tonsil (adenoid)** is located in the mucous membrane of the pharyngeal recess.
6. The **oropharynx** lies posterior to the oral cavity. It is bounded superiorly by the soft palate and inferiorly by the epiglottis of the larynx (Fig. 7.69).

CLINICAL CORRELATION

Adenoids

Enlarged pharyngeal tonsils are called adenoids. Adenoids obstruct the flow of air from the nose through the nasopharynx, making mouth breathing necessary.

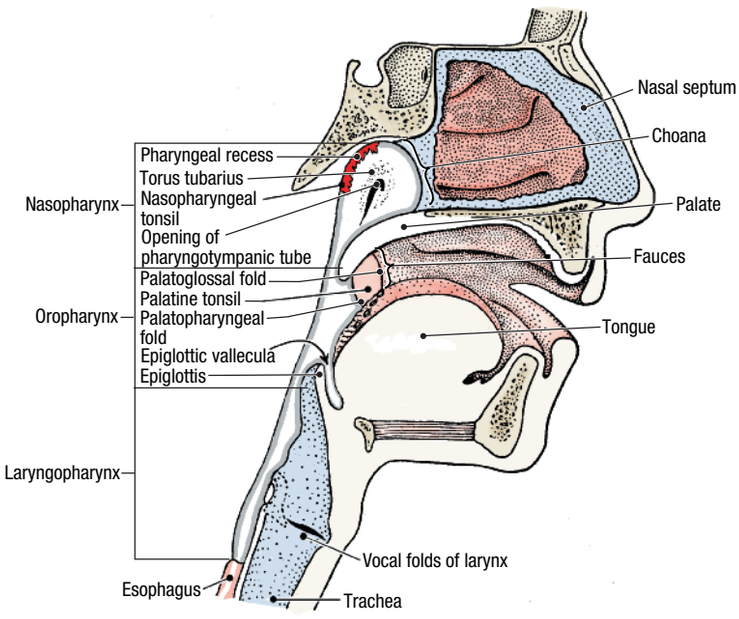

Figure 7.69. Regions of the pharynx.

7. In the oropharynx, identify the **palatoglossal fold**. The palatoglossal fold forms a dividing line between the oral cavity and the oropharynx. The transitional region between the right and left palatoglossal folds is called the **fauces**.
8. Identify the **palatopharyngeal fold**, which is posterior to the palatoglossal fold. The palatopharyngeal fold descends along the lateral wall of the oropharynx. Between the palatoglossal fold and the palatopharyngeal fold is the **palatine tonsil**. Use a mirror to identify the palatine tonsil on yourself.
9. The **laryngopharynx** lies posterior to the larynx. This portion of the pharynx extends from the epiglottis to the lower border of the cricoid cartilage (Fig. 7.69). **[G 770; N 62; R 161; C 552]**
10. In the midline of the laryngopharynx, identify the **epiglottis** and the **inlet (aditus) of the larynx**. Farther inferiorly, identify the **piriform recess**, which is lateral to the midline. The borders of the piriform recess are:
    - **Medial** – larynx
    - **Lateral** – thyroid cartilage
    - **Posterior** – inferior pharyngeal constrictor muscle

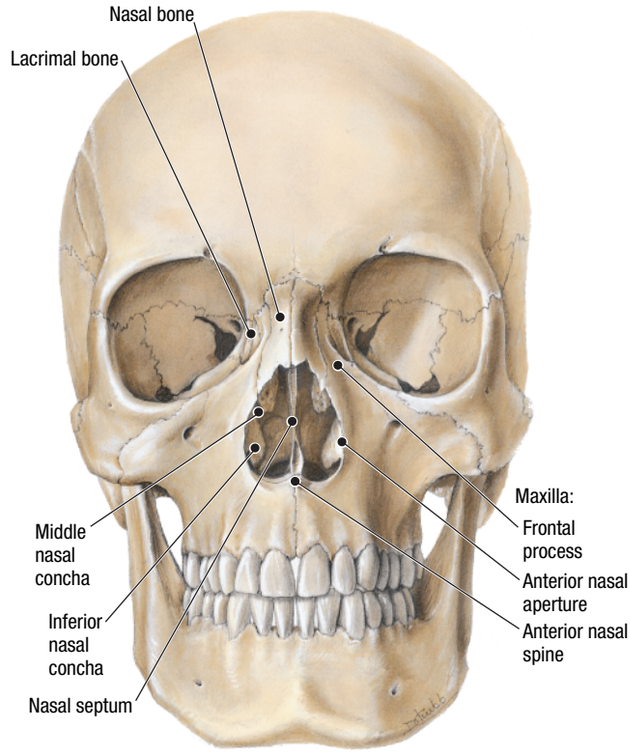

Figure 7.70. Skeleton of the nasal region.

After you dissect . . .

Review the attachments, innervation, and action of the pharyngeal constrictor muscles. Use a textbook description and the cadaver to review the pharyngeal plexus. Trace each of the following cranial nerves from the posterior cranial fossa to its area of distribution: glossopharyngeal (IX), vagus (X), accessory (XI), and hypoglossal (XII). Review the relationships of the contents of the carotid sheath.

NOSE AND NASAL CAVITY

Before you dissect . . .

The nostril (naris) is the anterior entrance to the nasal cavity. Posteriorly, the nasal cavity opens into the nasopharynx through the choanae. The nasal cavity is lined by mucosa that is attached directly to bones and cartilages. The bones and cartilages give the walls of the nasal cavity their characteristic shape. The superior 1/3 of the nasal mucosa is olfactory in nature and the remainder is respiratory in nature. The nasal mucosa is highly vascular and capable of engorgement.

The order of dissection will be as follows: The nose and nasal cartilages will be studied. The nasal septum will be examined and removed. The features of the lateral nasal wall will be studied. The openings of the paranasal sinuses will be identified. The maxillary sinus will be opened and examined.

SKELETON OF THE NASAL CAVITY

Refer to a skull. In an anterior view of the skull, identify (Fig. 7.70): **[G 589; N 2; R 26; C 480]**

- **Nasal bone**
- **Lacrimal bone**
- **Maxilla**
  - **Frontal process**
  - **Anterior nasal aperture**
  - **Anterior nasal spine**
- **Nasal septum** – bony part
- **Middle nasal concha** – part of the ethmoid bone
- **Inferior nasal concha**

Identify the following features of the lateral nasal wall (Fig. 7.71): **[G 681; N 34; R 48; C 523]**

- **Ethmoid bone**
  - **Cribriform plate**
  - **Superior nasal concha**
  - **Middle nasal concha**
- **Lacrimal bone**
- **Inferior nasal concha**
- **Maxilla**
  - **Palatine process**
  - **Incisive canal**
- **Sphenoid bone**
  - **Opening of the sphenoidal sinus**
  - **Sphenoidal sinus**
  - **Body**
  - **Medial plate of the pterygoid process**
  - **Lateral plate of the pterygoid process**
- **Palatine bone**
  - **Perpendicular plate**
  - **Horizontal plate**
- **Sphenopalatine foramen**

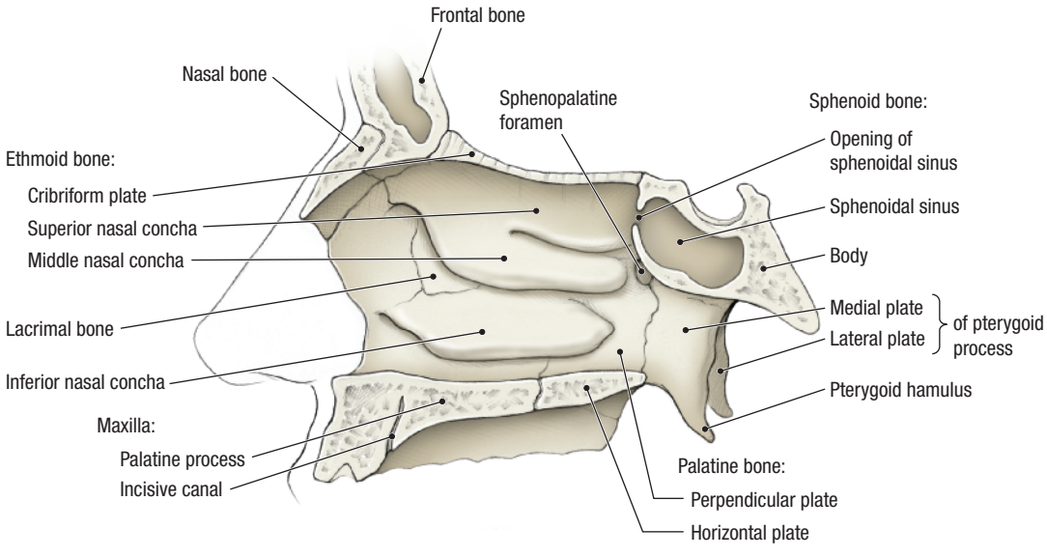

Figure 7.71. Skeleton of the lateral wall of the nasal cavity.

Dissection Instructions

EXTERNAL NOSE [G 680; N 32; R 49; C 522]

1. On the cadaver, palpate the nasal bone. Inferior to the nasal bone palpate the **lateral nasal cartilage** (Fig. 7.72). The lateral nasal cartilage gives shape to the bridge of the nose.
2. The lateral nasal cartilage is an extension of the **septal cartilage**. The septal cartilage separates the right and left nasal cavities and forms the anterior part of the nasal septum.
3. Lateral to the septal cartilage is the **alar cartilage** (Fig. 7.72). The alar cartilage gives shape to the nostril.

NASAL CAVITY

1. The **boundaries of the nasal cavity** are:
   Roof – a narrow region bounded by the nasal septum and by parts of three other bones: nasal bone, cribriform plate of ethmoid bone, and sphenoid bone.
   Floor – palatine process of the maxilla and horizontal plate of the palatine bone
   Medial wall – nasal septum
   Lateral wall – maxilla, lacrimal bone, ethmoid bone, inferior nasal concha, and perpendicular plate of the palatine bone
2. In the cadaver, observe that the bones and cartilages of the nasal cavity are obscured by the mucosa that covers them. The vessels and nerves of the nasal cavity are contained within this mucosa.

NASAL SEPTUM [G 681; N 35; R 141; C 524]

1. Examine the half of the head that contains the **nasal septum**. Strip the mucosa completely off of the nasal septum and identify: **perpendicular plate of the ethmoid bone**, **vomer**, and **septal cartilage** (Fig. 7.73).
2. Use a probe and forceps to remove the bony and cartilaginous parts of the nasal septum. Leave intact the mucosa that lines the other side of the nasal septum. In the mucosa of the nasal septum, identify the **nasopalatine nerve** and the **sphenopalatine artery**

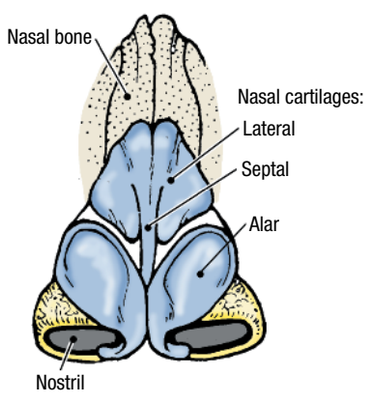

Figure 7.72. Cartilages of the external nose.

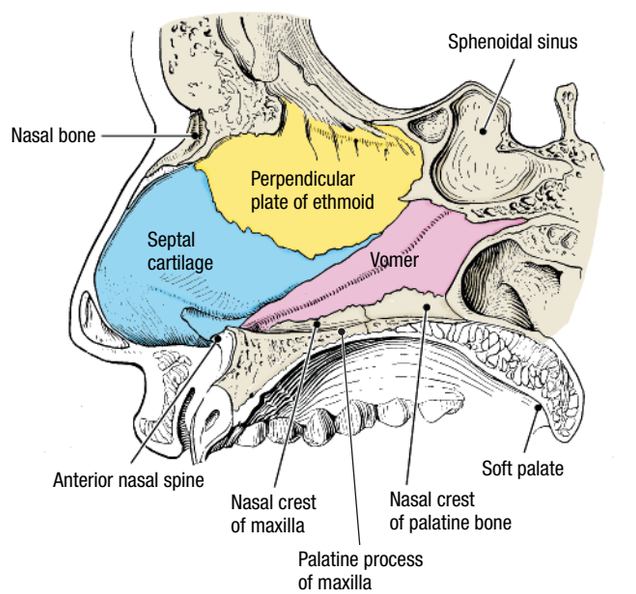

Figure 7.73. The nasal septum.

(Fig. 7.74). Note that the nasopalatine nerve and the sphenopalatine artery pass diagonally down the nasal septum from the sphenopalatine foramen to the incisive canal. In addition to the nasal septum, the nasopalatine nerve and sphenopalatine artery supply a portion of the oral mucosa that covers the hard palate.

3. Note that the mucosa near the cribriform plate is the **olfactory area** (Fig. 7.74). The olfactory area also extends down the lateral wall of the nasal cavity for a short distance.

LATERAL WALL OF THE NASAL CAVITY [G 684, 685; N 33; R 142, 143; C 525]

1. Remove the mucosa and remnants of the nasal septum.
2. Inspect the **lateral wall of the nasal cavity** (Fig. 7.75). Identify:
   - **Sphenoethmoidal recess** – above the superior concha
   - **Superior concha**
   - **Superior meatus** – inferior to the superior concha
   - **Middle concha**
   - **Middle meatus** – inferior to the middle concha
   - **Inferior concha**
   - **Inferior meatus** – inferior to the inferior concha
   - **Vestibule** – the area superior to the nostril and anterior to the inferior meatus
   - **Atrium** – the area superior to the vestibule and anterior to the middle meatus
3. Use scissors to remove the **inferior concha**. Use a probe and forceps to remove the mucosa from the lateral wall of the inferior meatus. Identify the opening of the **nasolacrimal duct** (Fig. 7.76).
4. Use scissors to remove the **middle concha**. In the middle meatus identify a curved slit, the **semilunar hiatus (hiatus semilunaris)** (Fig. 7.76). Posterior to the curvature of the semilunar hiatus identify the **ethmoidal bulla (bulla ethmoidalis)**.
5. Within the semilunar hiatus, identify (Fig. 7.76):
   - **Opening of the frontal sinus**

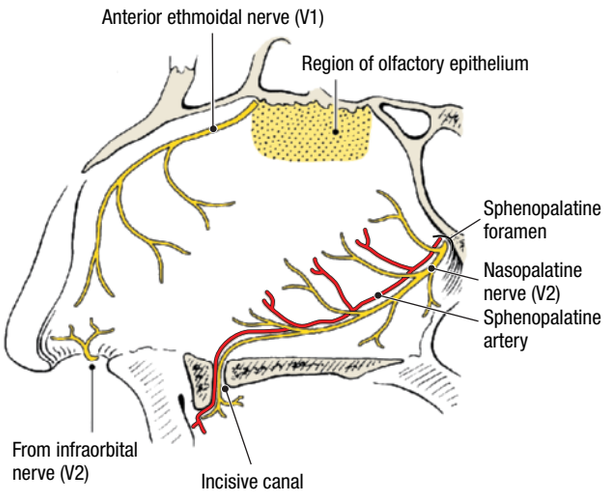

Figure 7.74. Nerve and arterial supply to the mucosa of the nasal septum.

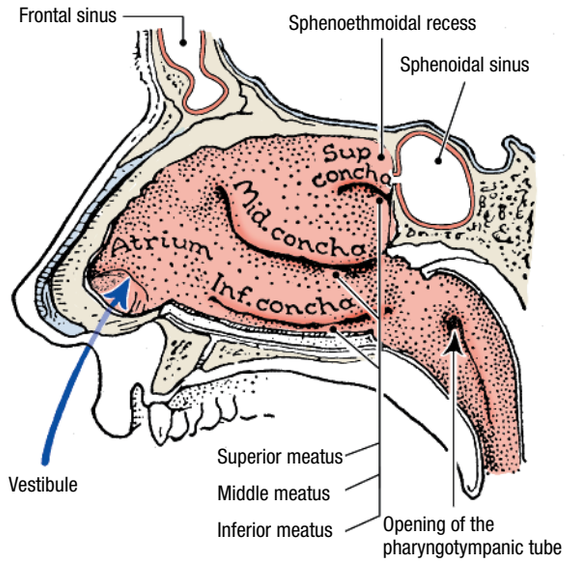

Figure 7.75. Conchae and meatuses of the lateral wall of the nasal cavity.

   - **Opening of the anterior ethmoidal cells**
   - **Opening of the maxillary sinus**
6. Identify the **opening of the middle ethmoidal cells** on the summit of the ethmoidal bulla.
7. Identify the **opening of the posterior ethmoidal cells** in the superior meatus.
8. Identify the **opening of the sphenoidal sinus** in the sphenoethmoidal recess.
9. Examine the **sphenoidal sinus** (Fig. 7.76). The sphenoidal sinus is a paired structure that is lined by mucosa that is continuous with the mucosa of the nasal cavity. Note that the sphenoidal sinus lies directly inferior to the hypophyseal fossa and pituitary gland. [G 687; N 44; R 142; C 528]

CLINICAL CORRELATION

Sphenoidal Sinus

Surgical approaches to the pituitary gland take advantage of the fact that the sphenoidal sinus and nasal cavity provide a direct approach.

10. Note that the **ethmoidal cells** are located between the nasal cavity and the orbit (Figs. 7.77, 7.78). The ethmoidal cells may be observed from the superior perspective by reviewing the dissection of the orbit that was completed previously.
11. Use an illustration to study the **maxillary sinus** and note the following (Fig. 7.78):
    - The maxillary sinus is a three-sided pyramid with an average adult capacity of 15 ml.
    - The roof of the maxillary sinus is the floor of the orbit and the infraorbital nerve innervates the mucosa of the sinus.

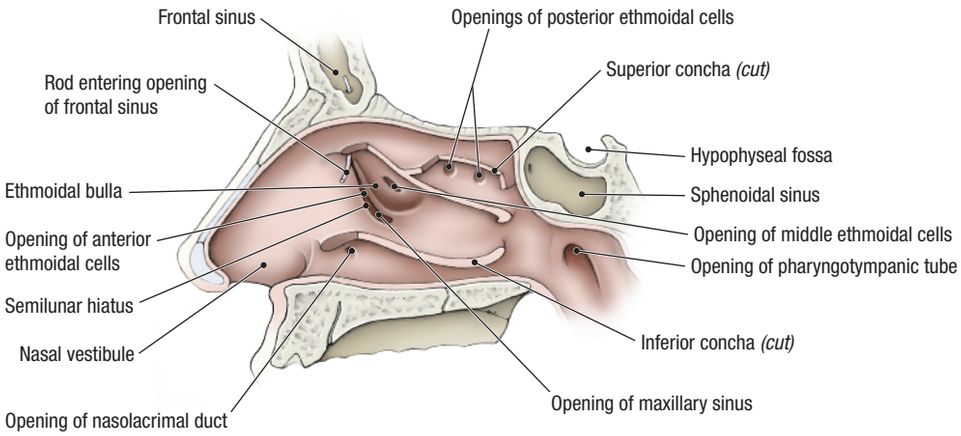

Figure 7.76. Openings in the lateral wall of the nasal cavity.

- The floor of the maxillary sinus is the alveolar process of the maxilla.
- The opening of the maxillary sinus is near its roof.
- The roots of the maxillary teeth may project into the maxillary sinus.

CLINICAL CORRELATION

Maxillary Sinus

When the head is in the upright position, the maxillary sinus cannot drain. If infections of the maxillary sinus persist, to promote drainage an opening is surgically created through the inferior meatus near the floor of the maxillary sinus.

When the roots of maxillary teeth project into the maxillary sinus, they are covered only by mucosa. During extraction of a maxillary molar or premolar tooth, the mucosa superior to the projecting root may be torn. As a result, a fistula may be formed between the oral cavity and the maxillary sinus.

HARD PALATE AND SOFT PALATE

Before you dissect . . .

The palate forms the floor of the nasal cavity and the roof of the oral cavity. The palate consists of two portions: the **hard palate** forms the anterior 2/3 and the **soft palate** constitutes the posterior 1/3. The palate is covered by nasal mucosa on its superior surface and oral mucosa on its inferior surface. Numerous mucous glands (**palatine glands)** are present on the oral surface of the palate.

The order of dissection will be as follows: The mucosal folds of the inner pharyngeal wall will be reviewed. The mucosa will be stripped from the inner surface of the pharynx and the muscles that constitute the inner longitudinal muscle layer will be examined. Muscles that move the soft palate will then be studied. The nerves and blood vessels of the palate will be identified. The palatine canal and pterygopalatine fossa will be dissected from the medial aspect. The pterygopalatine ganglion will be dissected. The nerves and vessels of the nasal cavity and palate will be summarized.

After you dissect . . .

Use an illustration and the dissected specimen to review the features of the lateral wall of the nasal cavity. Review the relationship of the paranasal sinuses to the orbit, anterior cranial fossa, and nasal cavity. Review the drainage point of each paranasal sinus.

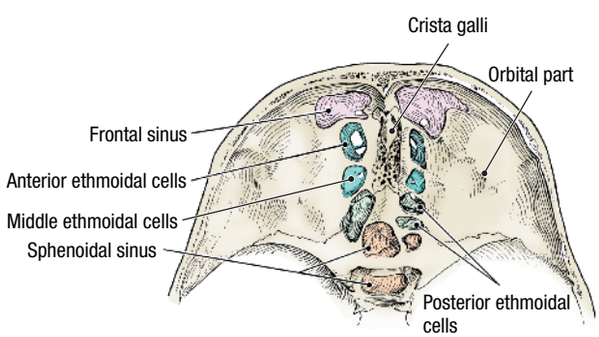

Figure 7.77. Ethmoidal cells in superior view.

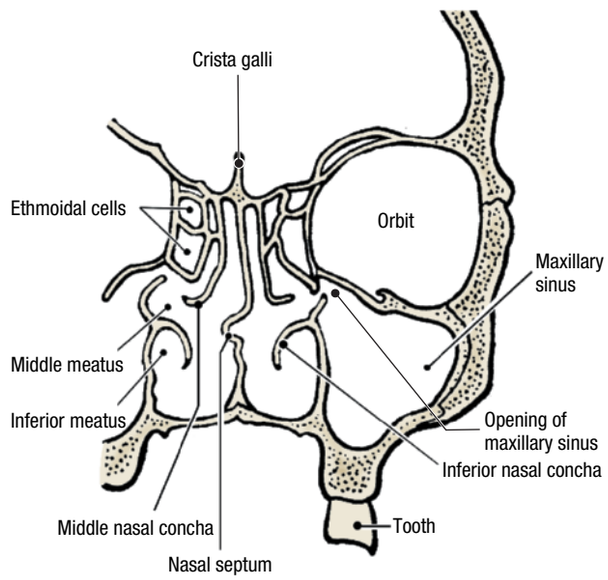

Figure 7.78. Relationship of the maxillary sinus to the orbit and nasal cavity.

SKELETON OF THE PALATE

Refer to a skull. From an inferior view, identify (Fig. 7.79): **[G 672; N 8; R 45; C 544]**

- **Maxilla**
  - **Incisive foramen**
  - **Alveolar process**
  - **Palatine process**
- **Palatine bone**
  - **Horizontal plate**
  - **Greater palatine foramen**
  - **Lesser palatine foramina**
  - **Posterior nasal spine**
- **Sphenoid bone**
  - **Hamulus of the medial plate of the pterygoid process**
  - **Medial plate of the pterygoid process**
  - **Lateral plate of the pterygoid process**
  - **Scaphoid fossa**
  - **Pterygoid canal**

In the infratemporal fossa, identify (Fig. 7.80): **[G 655; N 4; C 503]**

- **Inferior orbital fissure**
- **Sphenopalatine foramen**
- **Pterygopalatine fossa**
- **Pterygomaxillary fissure**

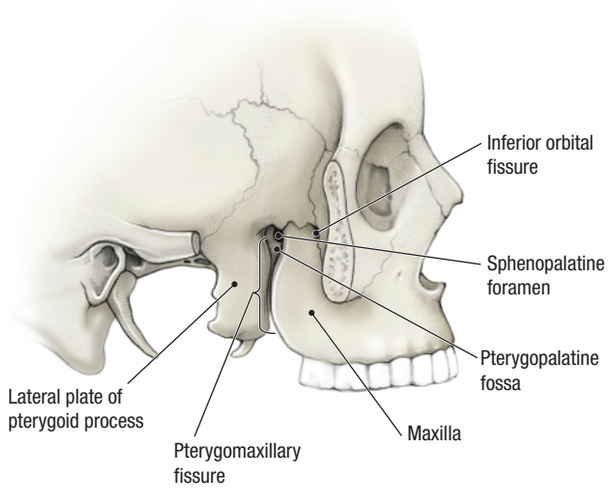

Figure 7.80. Entry to the pterygopalatine fossa and nasal cavity from the infratemporal fossa.

Dissection Instructions

SOFT PALATE

1. Review the mucosal features of the inner pharyngeal wall (Fig. 7.81): **[G 774, 775; N 60; R 142; C 531]**
   - **Torus tubarius**
   - **Opening of the pharyngotympanic tube**
   - **Salpingopalatine fold**
   - **Salpingopharyngeal fold**
   - **Palatoglossal fold**
   - **Palatopharyngeal fold**
2. Examine the cut edge of the **soft palate** and observe (Fig. 7.81):
   - The thickness of the soft palate is partly due to the presence of palatine glands.
   - The strength of the soft palate is due to the palatine aponeurosis.
   - The mobility of the soft palate is due to muscles that attach to its posterior 2/3.
3. Remove the mucosa from the palatopharyngeal fold and identify the **palatopharyngeus muscle** (Fig. 7.82). The superior attachments of the palatopharyngeus muscle are the hard palate and palatine aponeurosis and its inferior attachments are the thyroid cartilage and pharyngeal wall. The palatopharyngeus muscle elevates the larynx during swallowing.

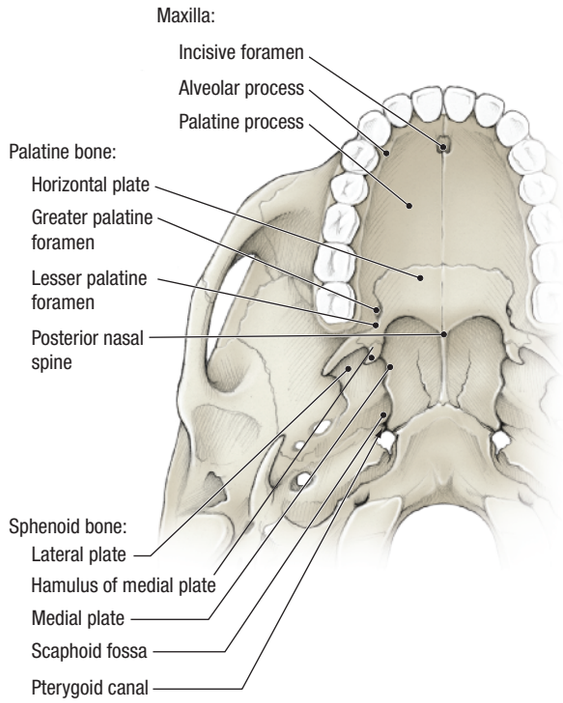

Figure 7.79. Skeleton of the palate, inferior view.

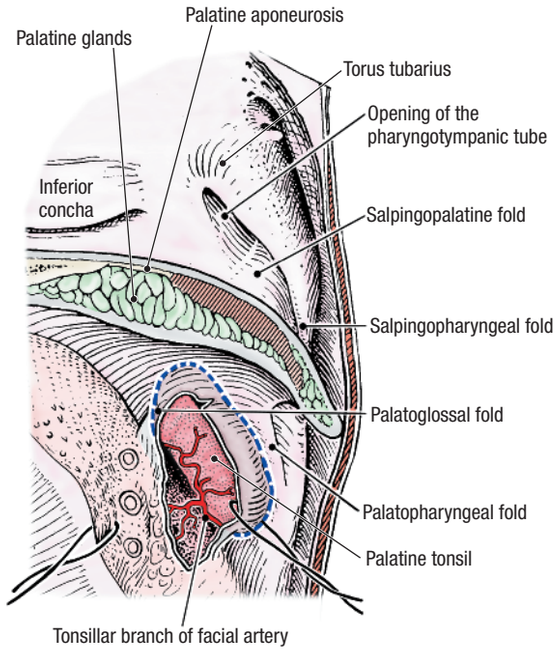

Figure 7.81. Mucosal folds in the pharynx.

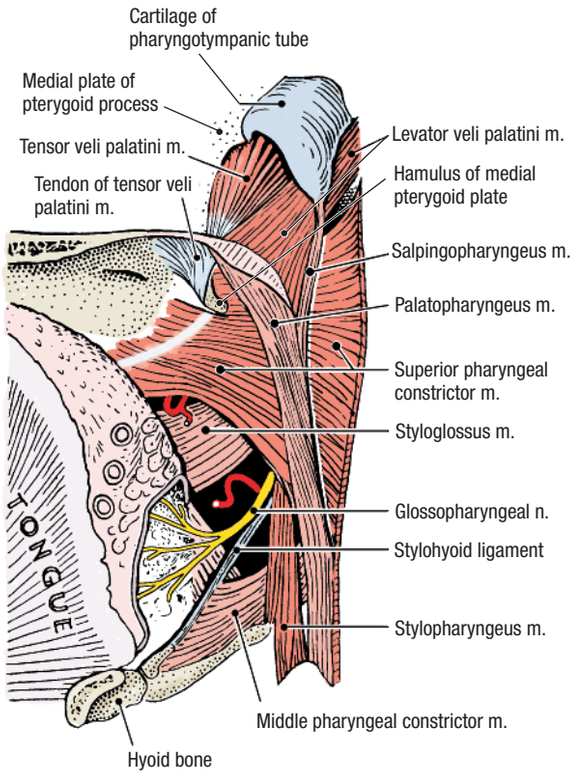

Figure 7.82. Muscles of the pharyngeal wall, internal view. Bed of the palatine tonsil.

4. Remove the mucosa from the salpingopharyngeal fold and identify the **salpingopharyngeus muscle** (Fig. 7.82). The superior attachment of the salpingopharyngeus muscle is the cartilage of the pharyngotympanic tube. Its distal attachments and action are the same as the palatopharyngeus muscle, with which it blends. Note that the palatopharyngeus and salpingopharyngeus muscles contribute to the inner longitudinal muscle layer of the pharynx.
5. Remove the remaining mucosa from the inner surface of the nasopharynx and oropharynx. Identify the **stylopharyngeus muscle**, which enters the pharynx between the superior and middle pharyngeal constrictor muscles (Fig. 7.82). The stylopharyngeus muscle lies anterior and parallel to the palatopharyngeus and salpingopharyngeus muscles.
6. The gap between the superior border of the superior pharyngeal constrictor muscle and the base of the skull is closed by the **pharyngobasilar fascia**. Passing through this gap are the **pharyngotympanic tube** and the **levator veli palatini muscle** (Fig. 7.82).
7. The **pharyngotympanic tube (auditory tube)** connects the nasopharynx to the tympanic cavity. The distal 2/3 of the pharyngotympanic tube is cartilaginous and the proximal 1/3 passes through the temporal bone.
8. Remove the mucosa from the **salpingopalatine fold** and identify the **levator veli palatini muscle** (Fig. 7.82). The superior attachments of the levator veli palatini muscle are the cartilage of the pharyngotympanic tube and the adjacent part of the temporal bone. Its distal attachment is the palatine aponeurosis of the soft palate. The levator veli palatini muscle elevates the soft palate.
9. Remove the mucosa from the posterior border of the **medial plate of the pterygoid process** (Fig. 7.82). Identify the **tensor veli palatini muscle**, which lies lateral to the medial plate. The superior attachment of the tensor veli palatini muscle is the **scaphoid fossa**. The belly of the tensor veli palatini muscle is located between the medial and lateral plates of the pterygoid process and its tendon turns medially around the **hamulus of the medial pterygoid plate** to attach to the palatine aponeurosis. The tensor veli palatini muscle tenses the soft palate. Palpate the hamulus and find the tendon of the tensor veli palatini muscle.
10. Six muscles of the soft palate and pharynx are innervated by the vagus nerve via the pharyngeal plexus: salpingopharyngeus, levator veli palatini, palatoglossus, palatopharyngeus, glossopharyngeus, and musculus uvulae. The tensor veli palatini muscle is innervated by the mandibular nerve (V_3).
11. To remove the mucosa from the hard palate, use a probe to raise the mucosa on the inferior surface of the hard palate where it was cut during head bisection. Grasp the mucosa with your fingers and peel it from medial to lateral. Detach the mucosa along the medial side of the alveolar process of the maxilla. **[G 673; N 48; R 145; C 531]**
12. Identify the **greater palatine nerve** and **vessels** where they emerge from the **greater palatine foramen** (Fig. 7.83). Use blunt dissection to follow the greater palatine nerve anteriorly. Note that the **nasopalatine nerve** supplies the mucosa over the anterior part of the hard palate.
13. Posterior to the greater palatine nerve, identify the **lesser palatine nerve** and use blunt dissection to follow it to the soft palate.

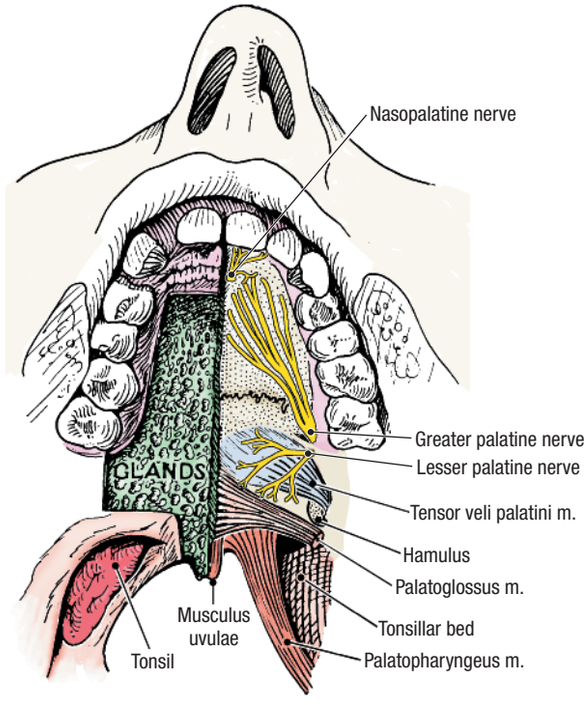

Figure 7.83. Nerves of the hard and soft palate.

TONSILLAR BED [G 776; N 60; R 145; C 531]

1. Identify the **palatine tonsil** (Fig. 7.81). The palatine tonsil is located in the triangular interval between the **palatoglossal fold** and the **palatopharyngeal fold**. In older individuals, the palatine tonsil may be inconspicuous or absent.
2. Use blunt dissection to remove the mucosa from the palatoglossal fold and identify the **palatoglossus muscle**, which lies within the fold. The superior attachment of the palatoglossus muscle is the palatine aponeurosis and its inferior attachment is the lateral side of the tongue. The palatoglossus muscle elevates the tongue and depresses the soft palate.
3. If the cadaver has a palatine tonsil, use blunt dissection to remove it (Fig. 7.81). Section the tonsil and observe the **crypts** that extend into its surface.
4. Remove the mucosa from the **tonsillar bed** (Fig. 7.82). The tonsillar bed is bounded anteriorly by the palatoglossal fold and posteriorly by the palatopharyngeal fold. The **styloglossus muscle** and the **glossopharyngeal nerve** pass deep to the tonsillar bed.
5. The superior attachment of the **styloglossus muscle** is the styloid process and its inferior attachment is the lateral side of the tongue. The styloglossus muscle retracts the tongue and draws it superiorly. The styloglossus muscle is innervated by the hypoglossal nerve (XII).
6. The **glossopharyngeal nerve (IX)** passes between the superior and the middle pharyngeal constrictor muscles to enter the tonsillar bed. The glossopharyngeal nerve innervates the mucosa of the posterior 1/3 of the tongue and the posterior wall of the pharynx.

SPHENOPALATINE FORAMEN AND PTERYGOPALATINE FOSSA [G 673; N 38; R 145; C 527]

1. Do not dissect the arterial network of the lateral nasal wall, but use an illustration to study the following branches of the **sphenopalatine artery**:
   - **Posterior lateral nasal artery** – to the lateral nasal wall
   - **Posterior septal branch** – to the nasal septum
2. Remove the mucosa from the posterior part of the lateral nasal wall.
3. Use a probe to locate the **sphenopalatine foramen** (Fig. 7.84). Insert a probe into the sphenopalatine foramen and direct it inferiorly toward the greater palatine foramen. Pull the probe medially to break open the medial wall of the greater palatine canal.
4. Identify the **greater palatine nerve**, the **lesser palatine nerve**, and the **descending palatine artery** in the greater palatine canal (Fig. 7.85). The descending palatine artery is one of the terminal branches of the maxillary artery.
5. At the inferior end of the greater palatine canal, use a fine probe to separate the nerves and vessels. Note that the descending palatine artery divides to give rise to the **greater palatine artery** and the **lesser palatine artery**.

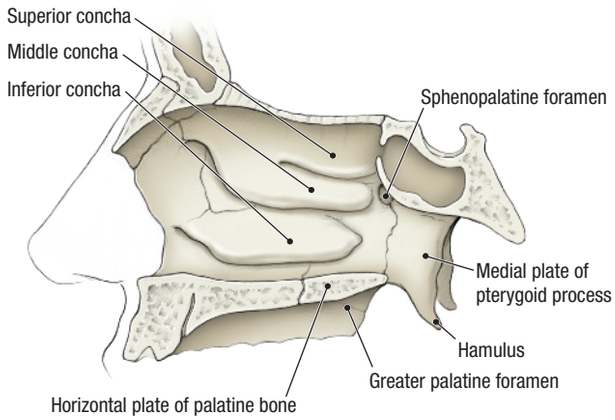

Figure 7.84. Skeleton of the lateral nasal wall.

6. Place the fine probe between the greater palatine nerve and the lesser palatine nerve and slide it superiorly until it stops. This is the inferior extent of the **pterygopalatine ganglion** (Fig. 7.85).
7. The **nerve of the pterygoid canal** enters the pterygopalatine fossa from posteriorly. To find it, remove the mucosa from the floor of the sphenoidal sinus. Observe the ridge in the floor of the sphenoidal sinus that is produced by the pterygoid canal (Fig. 7.85). Use a probe to break open the pterygoid canal and identify the nerve of the pterygoid canal.
8. Follow the nerve of the pterygoid canal anteriorly toward the pterygopalatine ganglion. The nerve of the pterygoid canal contains preganglionic parasympathetic axons from the greater petrosal nerve and postganglionic sympathetic axons from the deep petrosal nerve.

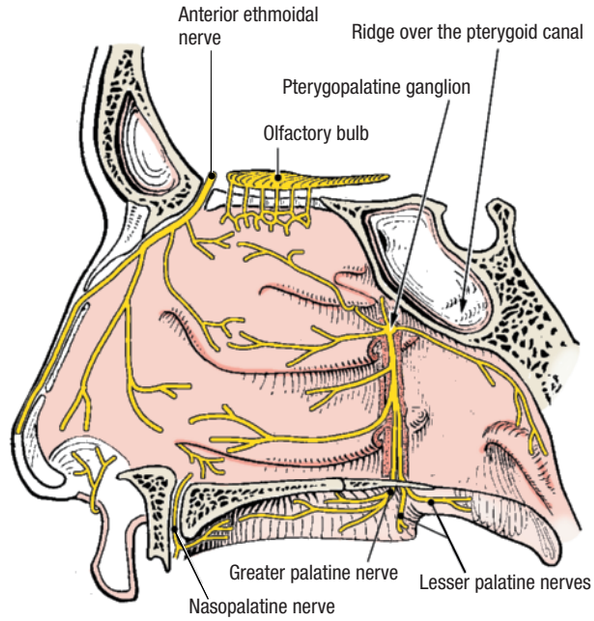

Figure 7.85. Nerve supply to the mucosa of the lateral wall of the nasal cavity. Pterygopalatine ganglion.

9. Turn the specimen and approach it from the lateral aspect. Deep in the **infratemporal fossa** identify: [G 659; N 65; R 80; C 478]
   - **Maxillary artery** – courses deeply toward the pterygomaxillary fissure. The maxillary artery gives off the **descending palatine artery**, the **sphenopalatine artery**, and the **infraorbital artery** at this location. Note that the sphenopalatine artery passes first through the pterygopalatine fossa and then through the sphenopalatine foramen to enter the nasal cavity. The descending palatine artery enters the greater palatine canal where it was dissected from the medial side. The infraorbital artery passes through the inferior orbital fissure to enter the infraorbital canal and emerge on the face at the infraorbital foramen.
   - **Maxillary nerve (V_2)** – courses from the foramen rotundum to the inferior orbital fissure. The maxillary nerve passes through the pterygopalatine fossa and gives off pterygopalatine branches that will form the greater and lesser palatine nerves.
   - **Pterygopalatine ganglion** – attached to the maxillary nerve by two pterygopalatine branches. The pterygopalatine ganglion is the location for synapse of preganglionic axons of the facial nerve that course first in the greater petrosal nerve and then in the nerve of the pterygoid canal. Postganglionic axons that arise in the pterygopalatine ganglion distribute with branches of the maxillary nerve. The pterygopalatine ganglion stimulates secretion from the mucosa of the nasal cavity, paranasal sinuses, nasopharynx, roof of the mouth and soft palate. The pterygopalatine ganglion also stimulates the lacrimal gland.

After you dissect . . .

Use the dissected specimen and an illustration to reconstruct the branching pattern of the maxillary nerve. Use a skull and the dissected specimen to follow the maxillary nerve from the trigeminal ganglion through the foramen rotundum, pterygopalatine fossa, and inferior orbital fissure to the infraorbital groove. Review the distribution of the following branches of the maxillary nerve: greater palatine, lesser palatine, nasopalatine, and infraorbital nerves. Return to the carotid triangle of the neck and follow the external carotid artery superiorly into the infratemporal fossa. Review the origin of the maxillary artery and its course through the infratemporal fossa. Review all branches of the maxillary artery that you dissected previously. Use an illustration to review the four terminal branches of the maxillary artery (posterior superior alveolar, infraorbital, descending palatine, and sphenopalatine) and use the dissected specimen to review these branches where you have dissected them. Review the muscles that move the soft palate. State their attachments and actions. Review the pharyngeal wall, placing the pharyngeal constrictor muscles, the muscles of the soft palate, and the mucosa into the correct layers. Review the pharyngeal plexus on the posterior surface of the pharynx and recall its role in innervation of the pharyngeal mucosa and the muscles of the pharynx and soft palate. Use the dissected specimen and an illustration to review the course of the glossopharyngeal nerve from the jugular foramen to the posterior 1/3 of the tongue.

ORAL REGION

Before you dissect . . .

The **oral region** includes the oral cavity and its contents (teeth, gums, and tongue), the palate, and the part of the oropharynx that contains the palatine tonsils. The palate and palatine tonsils have been dissected previously. The **oral cavity** consists of the **oral vestibule** and the **oral cavity proper**. The oral vestibule is bounded externally by the lips and cheeks and internally by the teeth and gums. The oral cavity proper is the area between the alveolar arches and teeth. The largest content of the oral cavity proper is the tongue.

The order of dissection will be as follows: The superficial features of the oral region will be examined on a living person. On the cadaver, the tongue will be inspected, then the tongue and mandible will be bisected in the midline. The intrinsic muscles of the tongue will be inspected. The sublingual region will be studied and the dissection of the deep part of the submandibular gland will be completed. Finally, the extrinsic muscles of the tongue will be studied.

SURFACE ANATOMY OF THE ORAL VESTIBULE [N 47; C 530]

Use a mirror to examine your mouth and a clean finger to palpate the following structures through the mucosa that lines your oral vestibule:

- **Zygomatic bone** – its inferior border
- **Maxilla**
  - **Anterior (facial) surface**
  - **Infratemporal surface**
  - **Alveolar process**
- **Mandible**
  - **Coronoid process** and the **tendon of the temporalis muscle**
  - **Alveolar process**
- **Masseter muscle** – best palpated when the teeth are clenched
- **Communication between the oral vestibule and the oral cavity proper** – posterior to the third molar tooth

Turn down your lower lip and lift your upper lip. Identify the **frenulum** in the midline of each lip.

Examine the inner surface of your cheek. Identify the **opening of the parotid duct** located lateral to the 2nd maxillary molar tooth.

SURFACE ANATOMY OF THE ORAL CAVITY PROPER

Observe the borders of your oral cavity:

- **Lateral and anterior** – the teeth and gums
- **Superior** – the hard palate
- **Inferior** – the mucosa covering the tongue and sublingual area
- **Posterior** – the palatoglossal folds (right and left)

In your oral cavity, identify:

- **Tongue**
  - **Body**
  - **Apex**
  - **Median sulcus**
- **Sublingual area**
  - **Frenulum of the tongue (sublingual frenulum)**

Sublingual fold (plica sublingualis)
Sublingual caruncle
Opening of submandibular duct – on the sublingual caruncle
Deep lingual veins – seen on either side of the frenulum of the tongue

Dissection Instructions

TONGUE [G 666; N 54; R 147; C 539]

1. Inspect the **tongue** in the cadaver specimen. Identify (Fig. 7.86):
   - **Root** – the posterior 1/3
   - **Body** – the anterior 2/3
   - **Apex**
   - **Dorsum**
     Foramen cecum – in the midline at the point of the terminal sulcus
     Terminal sulcus (sulcus terminalis) – divides the anterior 2/3 from the posterior 1/3
     Lingual tonsil – posterior to the terminal sulcus
     Lingual papillae – four types: vallate, filiform, fungiform, and foliate
     Median sulcus
2. Note that the **body of the tongue** lies horizontally in the oral cavity and the **root of the tongue** lies more vertically. The root of the tongue constitutes the anterior wall of the oropharynx.
3. At the root of the tongue, identify the **median glossoepiglottic fold**, a midline fold of mucosa that runs from the dorsum of the tongue to the **epiglottis** (Fig. 7.86). More laterally, identify the **lateral glossoepiglottic fold**, one on each side. Between these folds is a depression called the **epiglottic vallecula**.

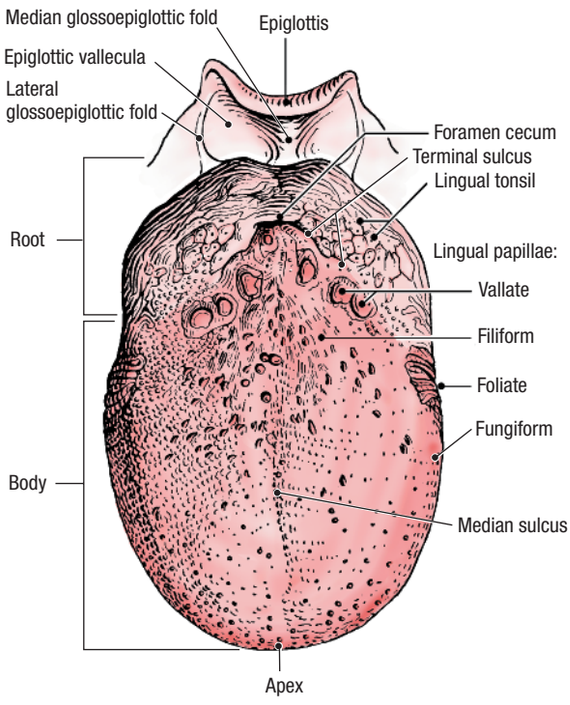

Figure 7.86. Dorsum of the tongue.

BISECTION OF THE MANDIBLE AND FLOOR OF THE MOUTH

1. Use a new scalpel blade. Turn the specimen to expose the submental triangle.
2. Use the scalpel to split the **mylohyoid muscles** along their median raphe. Use a probe to separate the mylohyoid muscles from deeper structures.
3. Identify the **geniohyoid muscle**, which is deep to the mylohyoid muscle. The anterior attachment of the geniohyoid muscle is the inferior mental spine of the mandible and its posterior attachment is the body of the hyoid bone. The geniohyoid muscle pulls the hyoid bone anteriorly.
4. Use blunt dissection to separate the geniohyoid muscles in the midline. Use a saw to cut through the mandible in the median plane. Do not allow the saw to pass between the geniohyoid muscles on the deep side of the mandible.
5. Do not bisect the epiglottis, the hyoid bone or the larynx at this time. Use a scalpel to bisect the tongue in the median plane, beginning at the apex and proceeding toward the epiglottis. Cut as far inferiorly as the hyoid bone.

SUBLINGUAL REGION [G 743; N 47; R 151; C 532]

1. On the sectioned surface of the tongue, identify the **genioglossus muscle**. The anterior attachment of the genioglossus muscle is the superior mental spine of the mandible and its posterior attachments are the hyoid bone and the tongue. The genioglossus muscle protrudes the tongue.
2. Use the cadaver specimen to review the sublingual features that were identified in your oral cavity:
   - **Frenulum of the tongue**
   - **Sublingual fold**
   - **Sublingual caruncle**
   - **Opening of the submandibular duct**
3. Use a probe to incise the mucous membrane between the sublingual fold and mandible. Start the incision at the frenulum of the tongue and stop near the 2nd mandibular molar tooth. Use a probe and forceps to peel the mucosa laterally and medially.
4. Identify the **sublingual gland** immediately deep to the mucosa (Fig. 7.87). The sublingual gland rests on the mylohyoid muscle. The sublingual gland has about 12 small ducts that drain along the summit of the sublingual fold.
5. Use a probe to dissect along the medial side of the sublingual gland and find the **submandibular duct** (Fig. 7.87). Follow the submandibular duct anteriorly to its opening on the sublingual caruncle. Use a probe to trace the submandibular duct posteriorly to the **deep part of the submandibular gland**. Note that the submandibular gland is folded around the posterior border of the mylohyoid muscle.

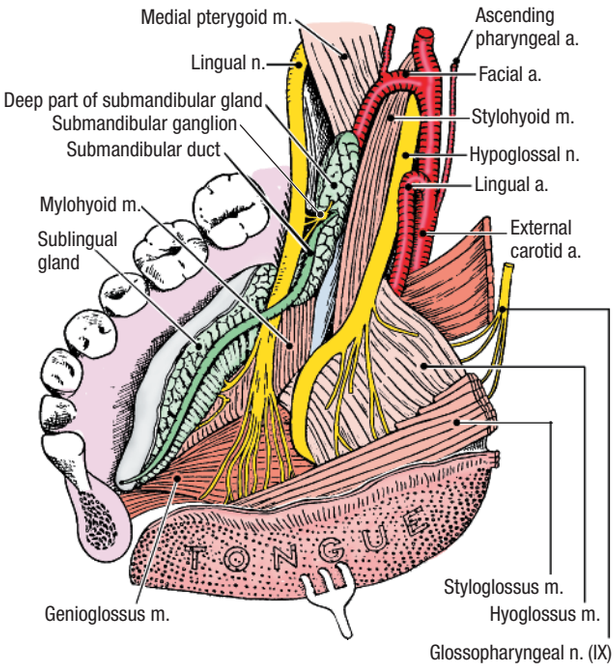

Figure 7.87. Dissection of the sublingual region (right side).

6. Turn the specimen to expose the infratemporal fossa. Find the **lingual nerve** and trace it into the sublingual region. Observe that the lingual nerve passes lateral, inferior, and medial to the submandibular duct (Fig. 7.87). The lingual nerve has several branches that supply the mucosa of the anterior 2/3 of the tongue with general sensation and taste fibers. **[G 743; N 57; R 151; C 537]**
7. Near the third mandibular molar tooth, identify the **submandibular ganglion** that is suspended from the lingual nerve by two short branches. Read a text book description of the parasympathetic function of the submandibular ganglion.
8. Turn the specimen so that the submandibular triangle is exposed. Find the **hypoglossal nerve (XII)** and use a probe to trace it into the sublingual region. Note that the hypoglossal nerve passes between the submandibular gland and the hyoglossus muscle (Fig. 7.87). Observe that both the hypoglossal nerve and the lingual nerve pass between the hyoglossus muscle and the mylohyoid muscle to enter the sublingual region. The course of the hypoglossal nerve is inferior to the course of the lingual nerve.
9. From the lateral perspective, define the attachment of the mylohyoid muscle to the hyoid bone. Use scissors to detach the mylohyoid muscle from the hyoid bone and reflect the muscle superiorly.
10. Identify the **hyoglossus muscle**, which is deep to the mylohyoid muscle (Fig. 7.88). The inferior attachments of the hyoglossus muscle are the body and greater horn of the hyoid bone and its superior attachment is the side of the tongue. The hyoglossus muscle depresses and retracts the tongue.
11. Near the superior end of the hyoglossus muscle, identify the **styloglossus muscle** (Fig. 7.88). The proximal attachment of the styloglossus muscle is the styloid process and its distal attachment is the side of the tongue. The styloglossus muscle retracts the tongue and draws it superiorly. **[G 746; N 55]**
12. Return to the carotid triangle and locate the **lingual artery** where it arises from the external carotid artery (Fig. 7.88). Follow the lingual artery until it passes medial to the hyoglossus muscle. Do not follow the lingual artery into the tongue. Use an illustration to study the branches of the lingual artery.
13. On one side only, make a transverse section through the body of the tongue. On the cut surface, note the **intrinsic muscles of the tongue** consisting of **vertical**, **transverse**, **superior longitudinal**, and **inferior longitudinal fibers**. **[G 669; N 56; R 147; C 540]**
14. The intrinsic muscles of the tongue and the extrinsic muscles of the tongue (styloglossus, genioglossus, and hyoglossus) are innervated by the **hypoglossal nerve (XII)**.

CLINICAL CORRELATION

Hypoglossal Nerve

The genioglossus muscle protrudes the tongue. If one genioglossus muscle does not function (hypoglossal nerve dysfunction on that side), the tongue cannot be protruded in the midline. The functional side of the tongue protrudes normally and side with the dysfunctional nerve is protruded less or not at all. Therefore, in testing for hypoglossal nerve lesions, the protruded tongue deviates toward the side of the nerve lesion.

After you dissect . . .

Replace the tongue in its correct anatomical position. Review the surface features of the tongue. Review the innervation of the lingual mucosa. Follow the submandibular duct from the submandibular triangle to the sublingual caruncle. Trace the lingual nerve from the infratemporal fossa to the tongue. Note the relationship of the lingual nerve to the submandibular duct, hyoglossus muscle, and mylohyoid muscle. Review the chorda tympani and the role that it plays in sensory innervation of the

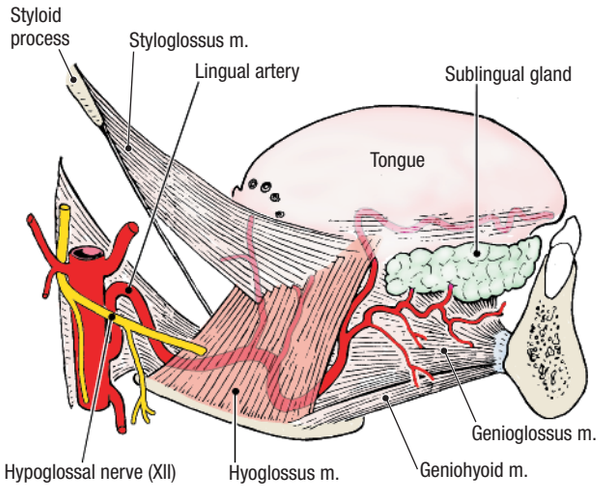

Figure 7.88. Blood supply to the tongue from a lateral view.

tongue and parasympathetic innervation of the submandibular and sublingual glands. Locate the submandibular ganglion and state its function. Trace the hypoglossal nerve from the base of the skull to the tongue, noting its relationships to arteries and muscles. Organize the muscles of the tongue into extrinsic and intrinsic groupings and state the attachments, innervation, and action of each extrinsic muscle. Use an illustration and the dissected specimen to review the origin and course of the facial and lingual arteries.

LARYNX

Before you dissect . . .

The larynx is contained in the visceral part of the neck. The thyroid gland lies anterior to it and the pharynx posterior to it. The larynx is the entrance to the airway and it contains the **glottis**, a valve that serves the dual function of controlling the airway and producing sound during phonation. The *intrinsic* muscles of the larynx control the glottis. The *extrinsic* muscles of the larynx (infrahyoid muscles, suprahyoid muscles, and stylopharyngeus muscle) control the position of the larynx in the neck. Usually, the larynx is located at vertebral levels C3-C6.

The order of dissection will be as follows: Illustrations and models will be used to study the cartilages of the larynx. Dissection of the larynx involves removal of the mucous membrane and identification of the underlying muscles. First, the mucosa will be removed from the posterior part of the larynx to expose two intrinsic muscles. One lamina of the thyroid cartilage will then be reflected to expose the remaining intrinsic muscles. The larynx will be opened and the mucosal features will be studied. Finally, the nerves to the larynx will be reviewed.

SKELETON OF THE LARYNX [G 778; N 73; R 156; C 558]

The **skeleton of the larynx** is responsible for maintaining a patent airway. It consists of a series of articulating cartilages that are united by membranes. Use an illustration and a model of the larynx to study the cartilages and membranes (Fig. 7.89). Identify:

- **Epiglottic cartilage** – an unpaired, heart-shaped cartilage that lies posterior to the tongue and hyoid bone. The **stalk** of the epiglottic cartilage is attached within the angle formed by the thyroid laminae.
- **Thyrohyoid membrane** – connects the superior border of the thyroid cartilage to the hyoid bone. When the suprahyoid and infrahyoid muscles move the hyoid bone, the larynx also moves.
- **Thyroid cartilage** – formed by two **laminae** that are joined in the anterior midline to form the **laryngeal prominence**. The **superior horn** of the thyroid cartilage projects superiorly. The **inferior horn** of the thyroid cartilage articulates with the cricoid cartilage through the **cricothyroid joint**.
- **Cricoid cartilage** – shaped like a ring (G. *krikos*, ring). Its **lamina** is a broad, flat area that is positioned posteriorly and its **arch** is located anteriorly.

The **arytenoid cartilages** are situated on the superior border of the lamina of the cricoid cartilage. Each arytenoid cartilage is pyramid-shaped and articulates with the cricoid cartilage through a synovial joint. Each arytenoid cartilage has a **muscular process** for attachment of intrinsic laryngeal muscles and a **vocal process** for attachment of the vocal ligament. The arytenoid cartilages are capable of several movements:

- Tilting anteriorly and posteriorly
- Sliding toward each other (adduction)
- Sliding away from each other (abduction)
- Rotation

Use an illustration to identify the **vocal ligaments** (Fig. 7.89). The posterior end of each vocal ligament is attached to the vocal process of an arytenoid cartilage. The anterior end of each vocal ligament is attached to the inner surface of the thyroid cartilage at the angle formed by the laminae.

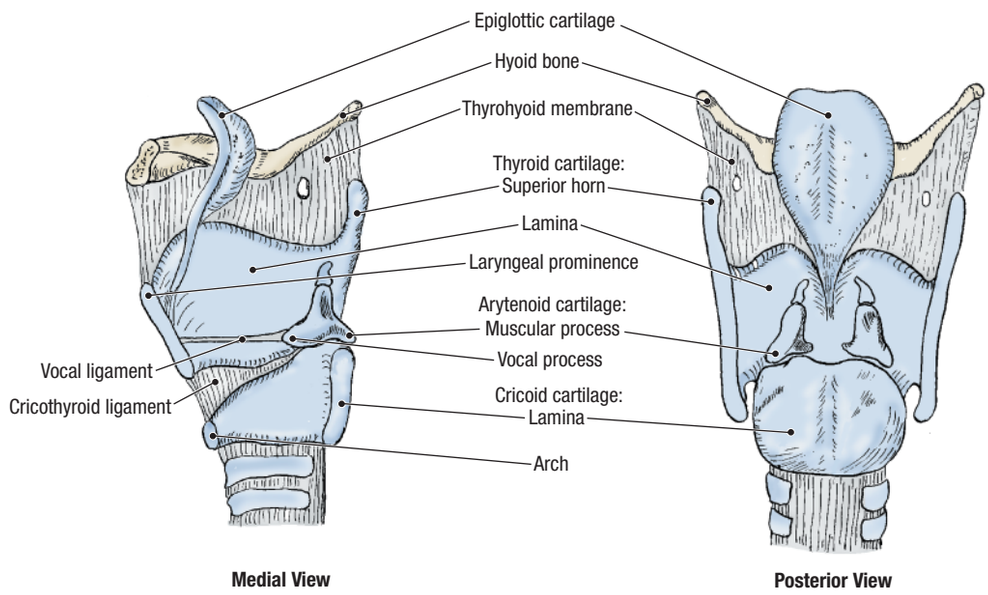

Figure 7.89. Cartilages of the larynx.

Dissection Instructions

INTRINSIC MUSCLES OF THE LARYNX [G 784, 785; N 74; R 158; C 560, 561]

1. Review the external features of the larynx that have been dissected previously:
   - Infrahyoid muscles
     - Sternohyoid muscle
     - Omohyoid muscle
     - Sternothyroid muscle
     - Thyrohyoid muscle
   - Internal branch of the superior laryngeal nerve
   - Superior laryngeal artery
   - External branch of the superior laryngeal nerve
2. On the external surface of the larynx, identify the **cricothyroid muscle**. The proximal attachment of the cricothyroid muscle is the lateral surface of the cricoid cartilage and its distal attachment is the inferior margin of the thyroid cartilage. The cricothyroid muscle tilts the thyroid cartilage anteriorly which lengthens the vocal fold. The cricothyroid muscle is innervated by the external branch of the superior laryngeal nerve.
3. To expose the posterior surface of the larynx, push the head forward and allow the chin to rest on the thoracic wall.
4. Palpate the **lamina of the cricoid cartilage**. Lateral to the lamina identify the **piriform recess**.
5. Remove the mucosa from the piriform recess. Immediately deep to the mucosa identify the **internal branch of the superior laryngeal nerve** and the **inferior laryngeal nerve** (Fig. 7.90).
6. Use a probe to strip the mucosa from the lamina of the cricoid cartilage and expose the **posterior cricoarytenoid muscle** (Fig. 7.90). The proximal attachment of the posterior cricoarytenoid muscle is the posterior surface of the lamina of the cricoid cartilage and its distal attachment is the muscular process of the arytenoid cartilage. The posterior cricoarytenoid muscle causes the arytenoid cartilage to rotate, moving the vocal process laterally (abduction of the vocal folds).
7. Superior to the posterior cricoarytenoid muscle identify the **arytenoid muscle** (Fig. 7.90). The arytenoid muscle attaches to both arytenoid cartilages. Observe that the arytenoid muscle has **transverse fibers** and **oblique fibers**. The arytenoid muscle slides the arytenoid cartilages together (adduction of the vocal folds).
8. The **cricothyroid joint** is a synovial joint that is reinforced by short ligaments. Observe that the recurrent laryngeal nerve enters the larynx by passing posterior to the cricothyroid joint. At this point, the name of the recurrent laryngeal nerve changes to **inferior laryngeal nerve**.
9. On the left side only, cut through the cricothyroid ligaments and disarticulate the cricothyroid joint. Use scissors to cut the left lamina of the thyroid cartilage about 8 mm to the left of the midline. Reflect the thyroid lamina inferiorly. It should remain attached to the cricoid cartilage by the cricothyroid muscle.
10. Deep to the thyroid lamina, identify the **lateral cricoarytenoid muscle** (Fig. 7.90). The inferior attachment of the lateral cricoarytenoid muscle is the arch of the cricoid cartilage and its superior attachment is the muscular process of the arytenoid cartilage. The lateral cricoarytenoid muscle causes the arytenoid cartilage to rotate, moving the vocal process medially (adduction of the vocal fold).
11. Identify the **thyroarytenoid muscle**, which is located superior to the lateral cricoarytenoid muscle (Fig. 7.90). The anterior attachment of the thyroarytenoid muscle is the inner surface of the thyroid cartilage and

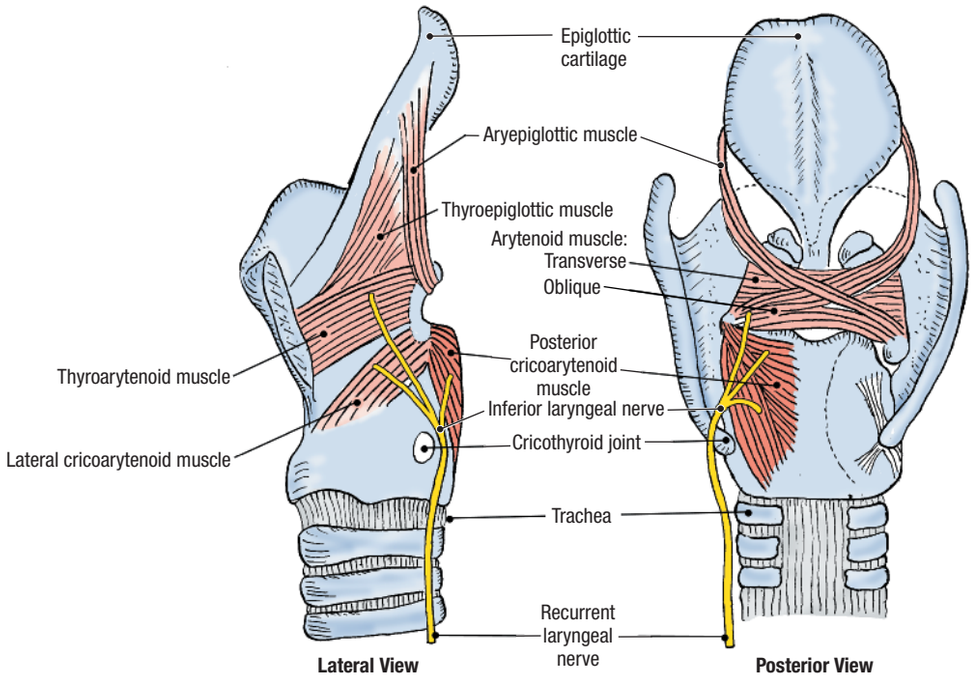

Figure 7.90. Intrinsic muscles of the larynx.

its posterior attachment is the anterior surface of the arytenoid cartilage. The thyroarytenoid muscle tilts the arytenoid cartilage anteriorly, relaxing the vocal fold.

12. The **vocalis muscle** is formed by the medial fibers of the thyroarytenoid muscle. The vocalis muscle is attached to the vocal ligament and it modifies the tension in localized parts of the vocal fold, modulating pitch. The vocalis muscle cannot be seen in dissection.
13. Other delicate muscles (thyroepiglottic muscle and aryepiglottic muscle) are found superior to the thyroarytenoid muscle. Do not attempt to dissect them.
14. Observe the vocal folds from a superior view. The interval between the vocal folds is called the **rima glottidis**. The rima glottidis and the vocal folds are collectively called the **glottis**.
15. Review the function of the intrinsic muscles of the larynx. **The posterior cricoarytenoid muscle is the only muscle that opens the rima glottidis**. The cricothyroid muscle tilts the thyroid cartilage anteriorly and tenses the vocal fold (higher pitch of voice). The thyroarytenoid muscle tilts the thyroid cartilage posteriorly and relaxes the vocal fold (lower pitch of voice).

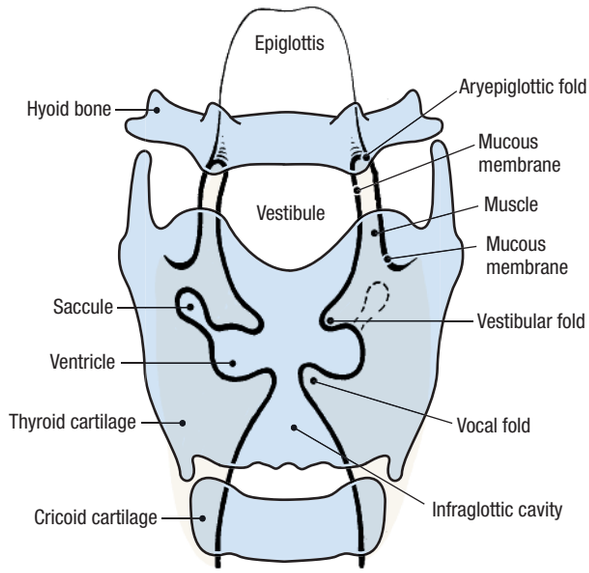

Figure 7.91. Schematic drawing of the laryngeal cavity, anterior view.

CLINICAL CORRELATION

Glottis

Laryngospasm is a spasmodic closure of the glottis and it is life threatening. Spasm of the intrinsic laryngeal muscles that close the glottis may be produced by irritating chemicals and sometimes as a side effect of medications.

The vocal folds can be readily visualized and inspected with the aid of a mirror (indirect laryngoscopy) or with a laryngoscope (direct laryngoscopy). Persistent hoarseness is an indication for laryngoscopy. Persistent hoarseness may be caused by changes of the vocal folds or it may indicate that the recurrent laryngeal nerve is compressed in the thorax or neck.

INTERIOR OF THE LARYNX [G 781; N 59; R 159; C 562]

1. Use scissors to cut the arytenoid muscle, lamina of the cricoid cartilage, and trachea in the median plane. In addition, cut the arch of the cricoid cartilage in the anterior midline.
2. Open the larynx and observe that the **laryngeal cavity** has three parts (Fig. 7.91):
   - **Vestibule** – superior to the vestibular folds
   - **Ventricle** – the depression between the vestibular fold and the vocal fold
   - **Infraglottic cavity** – inferior to the vocal folds and continuous with the trachea
3. Examine the **epiglottis** and note that it moves posteriorly during swallowing to close the laryngeal inlet.
4. Inspect the mucosa that lines the interior of the larynx and identify the **vestibular fold (false vocal fold)** and the **vocal fold (true vocal fold)**. The **vocal ligament** is located within the vocal fold.
5. Examine the **ventricle**. The ventricle may extend into a recess called the **saccule** (Fig. 7.91).
6. Review the **nerve supply to the larynx**:
   - **Internal branch of the superior laryngeal nerve** – provides sensory innervation to the mucosa superior to the vocal folds.
   - **External branch of the superior laryngeal nerve** – innervates the cricothyroid muscle (and also the inferior pharyngeal constrictor muscle).
   - **Inferior laryngeal branch of the recurrent laryngeal nerve** innervates all of the intrinsic muscles of the larynx except the cricothyroid muscle, and provides sensory innervation to the mucosa inferior to the vocal folds.

After you dissect . . .

Replace the head and larynx in their correct anatomical positions. Use a cross-sectional drawing of the neck and the dissected specimen to review the relationship of the larynx to the vertebral column, carotid sheaths, and other cervical viscera (Fig. 7.40). Trace the vagus nerves (right and left) into the thorax and follow the recurrent laryngeal nerves from the thorax to the larynx. Review the branches of the external carotid artery. Follow the superior thyroid artery to the thyroid gland and review the course of the superior laryngeal artery as it passes through the thyrohyoid membrane to enter the larynx. Recall that the superior laryngeal artery courses with the internal branch of the superior laryngeal nerve. Review the course of the superior laryngeal nerve from the vagus nerve to its bifurcation. Follow the external laryngeal branch to the cricothyroid muscle. Use the dissected specimen to review the attachments and action of each intrinsic laryngeal muscle that was identified during dissection. Review the movements of the vocal folds during phonation, quiet breathing, and rapid breathing.

EAR

Before you dissect . . .

The ear is composed of three parts: external ear, middle ear, and internal ear. The external ear consists of the **auricle** and the **external acoustic meatus**. The middle ear is within the **tympanic cavity of the temporal bone**. The **ossicles** (bones of the middle ear) are located in the middle ear. The **internal ear** (vestibulocochlear organ) is the neurological part of the ear, which is contained within the petrous portion of the temporal bone.

The order of dissection will be as follows: The parts of the external ear will be examined. The facial nerve will be followed from the posterior cranial fossa into the internal acoustic meatus and the roof of the tympanic cavity will be removed. The auditory ossicles will be identified and one ossicle will be removed. The tympanic membrane will be studied. Features of the medial wall of the tympanic cavity will be examined.

TEMPORAL BONE

Refer to a skull. On the intracranial surface of the **temporal bone**, identify (Fig. 7.92): **[G 615; N 9; R 34; C 497]**

- **Groove for the greater petrosal nerve**
- **Tegmen tympani** – a portion of the floor of the middle cranial fossa
- **Internal acoustic meatus**

On the external surface of the temporal bone review the following: **[G 595; N 8; R 50; C 498]**

- **External acoustic meatus**
- **Mastoid process**
- **Stylomastoid foramen**
- **Jugular fossa**
- **Carotid canal**
- Bony portion of the **pharyngotympanic tube**

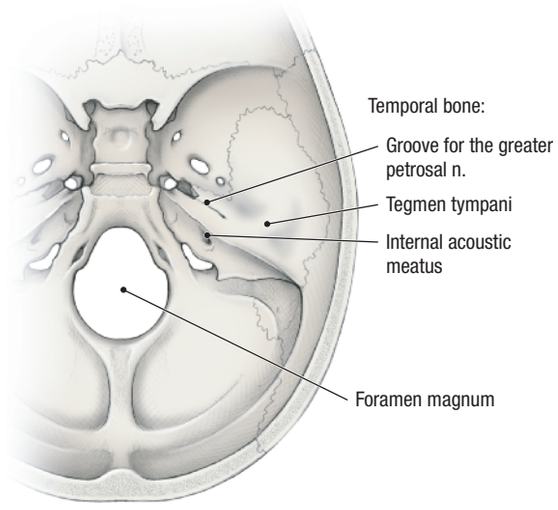

Figure 7.92. Temporal bone, superior view.

Dissection Instructions

EXTERNAL EAR [G 696; N 88; R 122; C 564]

1. Examine the **auricle** of the cadaver and identify (Fig. 7.93A):
   - **Helix** – the rim of the auricle
   - **Antihelix** – the curved prominence anterior to the helix
   - **Concha** – the deepest part of the auricle
   - **Tragus**
   - **Antitragus**
   - **Lobule of the auricle**
2. Note that the **auricular cartilage** gives the auricle its shape (Fig. 7.93B). There is no cartilage in the lobule. Palpate the auricular cartilage on yourself. By palpation, verify that the auricular cartilage is continuous with the cartilage of the external acoustic meatus.
3. The **external acoustic** meatus begins at the deepest part of the concha and ends at the tympanic membrane (a distance of about 2.5 cm in adults). The proximal 2/3 of the external acoustic meatus is bony and the distal 1/3 is cartilaginous.
4. Note that the external acoustic meatus is S-shaped, first curving posterosuperiorly and then anteroinferiorly. The external acoustic meatus is straightened for examination by pulling the auricle upward, outward, and backward.
5. Study an illustration of the external surface of the tympanic membrane and relate its surface features to the structures that lie in the middle ear. **[G 699; N 88; R 124; C 567]**

MIDDLE EAR [G 707; N 92; R 128; C 574]

1. If the dura mater is still present in the middle cranial fossa, peel it off of the superior surface of the temporal bone. Start at the superior border of the petrous part of the temporal bone and peel the dura mater in an anterior direction.
2. The **tympanic cavity** is an air-filled space within the temporal bone. It is separated from the external acoustic meatus by the **tympanic membrane**.
3. Refer to a schematic illustration of the middle ear and preview the features of the **walls of the tympanic cavity** (Fig. 7.94): **[G 701-703; N 87; R 120; C 566]**
   - **Lateral** – the **tympanic membrane**
   - **Posterior** – the **aditus** (L., *aditus*, inlet or access), an opening into the **mastoid air cells**

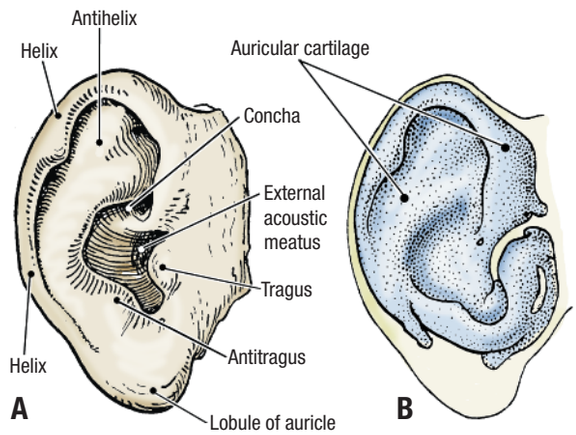

Figure 7.93. A. External ear and **B.** auricular cartilage.

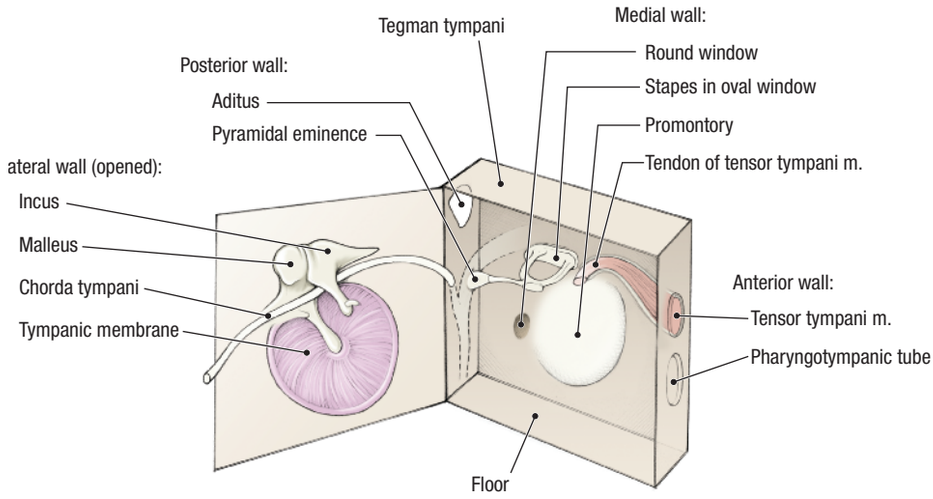

Figure 7.94. Schematic drawing of the walls of the tympanic cavity. Right ear in lateral view with the lateral wall opened.

- **Medial** – the **promontory** and **oval window (fenestra vestibuli)** containing the base (footplate) of the **stapes**
- **Anterior** – the opening of the **pharyngotympanic tube**
- **Superior** – tegmen tympani
- **Inferior** – the floor of the tympanic cavity, which is closely related to the **jugular fossa** and the **jugular bulb**

4. If a decalcified temporal bone is available, make the cuts with a scalpel. If only your cadaver specimen is available, the temporal bone must be cut with a chisel and bone cutters. *Wear eye protection for all steps that require bone to be cut*. Perform this dissection on one side only.
5. In the **posterior cranial fossa,** identify the **facial nerve (VII)** and the **vestibulocochlear nerve (VIII)** as they enter the internal acoustic meatus (Fig. 7.95).
6. Remove the roof of the internal acoustic meatus and follow the course of the **facial** and **vestibulocochlear nerves**. Remain superior to the nerves when removing bone. **[G 707; N 89; C 575]**
7. Identify the **geniculate ganglion** and the origin of the **greater petrosal nerve** (Fig. 7.95). The greater petrosal nerve runs in the groove for the greater petrosal nerve and exits the middle cranial fossa by passing into the foramen lacerum. The greater petrosal nerve joins the deep petrosal nerve to form the **nerve of the pterygoid canal**. The greater petrosal nerve carries preganglionic parasympathetic fibers to the pterygopalatine ganglion.
8. The **lesser petrosal nerve** runs a course that is parallel and lateral to the greater petrosal nerve (Fig. 7.95). The lesser petrosal nerve exits the cranial cavity by passing through the foramen ovale or a tiny foramen just posterior to the foramen ovale. The lesser petrosal nerve carries preganglionic parasympathetic fibers to the otic ganglion.
9. Observe that the facial nerve turns posteriorly at the geniculate ganglion, travels a short distance in a posterolateral direction, then turns inferiorly. Do not attempt to follow the facial nerve further. Use an illustration to note that the facial nerve passes posterior to

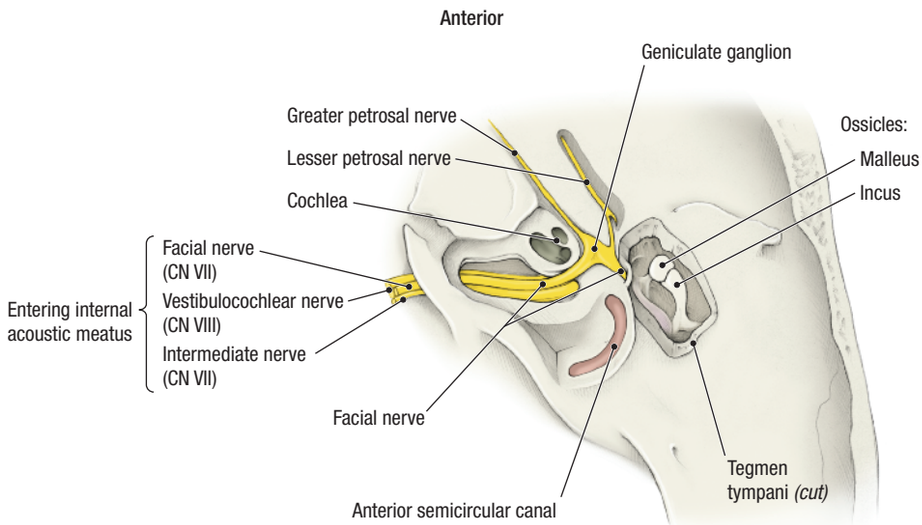

Figure 7.95. Middle ear following dissection, right side, superior view.

the tympanic cavity within the temporal bone and exits the skull at the stylomastoid foramen.

10. The **cochlea** is anterior to the internal acoustic meatus in the angle formed by the facial nerve, the geniculate ganglion and the greater petrosal nerve. In the dissected specimen the cochlea may be seen as a series of openings in the bone.
11. Remove the **tegmen tympani**. Observe the three **auditory ossicles** within the tympanic cavity (Fig. 7.95). Note that the **malleus** is attached to the tympanic membrane, the **incus** occupies an intermediate position, and the **stapes** is the most medial of the auditory ossicles. The malleus and incus are easily seen from the superior view. The stapes is located more inferiorly, making observation difficult.
12. Use forceps to remove the incus. Leave the malleus attached to the tympanic membrane.
13. On the lateral wall of the tympanic cavity, identify the **tympanic membrane** and the **chorda tympani.** The chorda tympani crosses the handle of the malleus and passes between the malleus and the incus. **[G 703; N 89; R 124; C 569]**
14. On the medial wall of the tympanic cavity, identify (Fig. 7.94): **[G 702; N 89; R 124; C 570]**
    - **Promontory** – an elevation on the medial wall
    - **Stapes** – still attached to the **vestibular window**. Look for the **stapedius tendon,** about 1 mm long, passing from the pyramidal eminence to the stapes.
    - **Round window (fenestra cochleae)** – posteroinferior to the promontory
    - **Tensor tympani muscle** – crosses the tympanic cavity from the medial wall to the superior part of the handle of the malleus.
15. Note that the tympanic cavity and its associated recesses and air cells are covered with mucous membrane. The **glossopharyngeal nerve (IX)** innervates the mucous membrane of the tympanic cavity.

INTERNAL EAR [G 708; N 91; R 127; C 575]

The vestibulocochlear organ is best seen in sectioned histological material. If you wish to dissect the internal ear, utilize a decalcified temporal bone. Refer to appropriate atlas illustrations and use a single-edge razor blade to cut thin slices of the temporal bone. This procedure will expose the canals, chambers, and nerve pathways of the internal ear. A dissecting microscope should be used to visualize these structures.

After you dissect . . .

Use an illustration to review the external appearance of the tympanic membrane. Relate the tympanic membrane to the handle of the malleus and the chorda tympani. Review the course of the facial nerve from the internal acoustic meatus to the facial muscles. Review the course of the greater petrosal nerve from the geniculate ganglion to the pterygopalatine ganglion. Summarize the distribution of the postganglionic axons that arise in the pterygopalatine ganglion. Review the course of the special sensory fibers contained in the chorda tympani beginning at the tongue and ending at the internal acoustic meatus. Where are the cell bodies for these sensory axons located? Review the course of the preganglionic parasympathetic axons that synapse in the submandibular ganglion. Review the distribution of the postganglionic axons that arise from the submandibular ganglion. Review all branches of the glossopharyngeal nerve, including those that give rise to the lesser petrosal nerve. Review the course of the lesser petrosal nerve from the tympanic cavity to the otic ganglion. Review the distribution of the postganglionic parasympathetic axons that arise in the otic ganglion.

INDEX

Page numbers in *italics* indicate figure.

A

abdomen
  abdominal aorta, 92, *92*
  abdominal viscera, *75*, 75–76, *76*
  celiac trunk, 78–80, *79*
  diaphragm, *94*, 94–95
  dissection instructions, 74, *74*
  duodenum, 86, *86*, *87*
  gallbladder, 75, *75*, *76*, 78, *78*, 81, *82*
  gastrointestinal tract removal, 88–89
  hepatic portal vein, 87
  inferior mesenteric artery, 84–85, *85*
  kidneys, 90–91, *91*
  large intestines, 75, *76*, 85–86, *86*
  liver, 75, *75*, *76*, 78, *78*, 80–81, *81*
  pancreas, *86*, 86–87, *87*
  peritoneum and peritoneal cavity, 74–77, *75*
  posterior viscera, 89–92, *90*
  quadrant system for description of, 64, *64*
  regional system for description of, 64, *64*
  scrotum, 72
  skeleton of, 66, *66*
  skin incisions, *65*, *65*
  small intestines, 75, *76*, 83–84, *84*
  spermatic cord, *72*, 72–73
  spleen, 80, *80*
  superficial fascia, *65*, 65–66
  superior mesenteric artery, *82*, 82–83, *83*
  suprarenal glands, 91–92, *92*
  surface anatomy, 64, *64*
  testis, 73, *73*
abdominal aorta, 92, *92*
abdominal viscera, posterior, 89–92, *90*
abdominal wall
  layers of, *65*, *65*
  muscles of, 66–72
    deep inguinal ring, 69
    external oblique, 67, *68*
    internal oblique, 67–69, *68*
    rectus abdominis, 70–71, *71*
    transversus abdominis, 69
  posterior, *93*, 93–94
  reflection of, 73–74
  superficial veins of, 65–66
abducent nerve, *165*, 167, *167*, *172*, 172–173
abductor digiti minimi muscle, 33, 143, *143*
abductor hallucis muscle, 143, *143*
abductor pollicis brevis muscle, 33
abductor pollicis longus tendon, 36
accessory nerve, *165*, *167*, 168, 176, *176*, *193*, 194
Achilles tendon, 140, *141*
acoustic meatus, external, 208, *208*
acromioclavicular joint, 37, *38*
adductor brevis muscle, 129, *130*
adductor canal, 128
adductor hallucis muscle, 144, *144*
adductor longus muscle, 129
adductor magnus muscle, 129, *130*, 134, *135*
adductor pollicis muscle, 34, *34*
adenoids, 194, *194*
alar cartilage, 196, *196*
alar ligaments, 190–191, *191*
alveolar artery
  inferior, 189
  posterior superior, *188*, 189
alveolar nerve, inferior, *188*, 188–189
anal canal, *106*, 106–107, *117*, 117–118
anal columns, 107, 118
anal nerve, inferior, 99, *99*
anal sphincter muscles, 99, *99*, *106*, 107, *117*, 118
anal triangle, *97*, 97–99
  ischioanal fossa, 98–99, *99*
  skin incisions, 98, *98*
anal valves, *106*, 107, 118
anatomical position, 2, *2*
anatomical snuffbox, 36, *36*
anconeus muscle, 25, *26*
anesthesia, dental, 188
ankle, 147, *148*
  lateral ligament of, 147, *148*
  medial ligament of, 147, *148*
anorectal flexure, 106, 117
ansa cervicalis, 177–178, *178*
antebrachial fascia, 22
anterior cruciate ligament, *147*
anular ligament, 39, *39*
aorta
  abdominal, 92, *92*
  arch of, *53*, 60, *61*
  ascending, *53*, 54, *54*
  thoracic, *62*, 62–63
aortic hiatus, *94*, 95
aortic sinus, 55–56, 59
aortic valve, 55, *55*, 58–59
appendicular artery, 83, 85
appendix, 75, *76*, 85, *85*
arachnoid granulation, 159, *160*
arachnoid mater
  of brain, 160, *160*, *161*
  of spine, 13
arcades, 83, *83*
arch of the aorta, *53*
arcuate artery, *138*, 139
arcuate ligaments, *94*, 94–95
areola, 44, *44*
arm, 22–26. *see also* forearm
  anterior compartment of, *22*, *23*, 23–24
  cubital fossa, 24–25
  fascia of, 22
  posterior compartment of, *22*, 25–26, *26*
  skeleton of, 22–23, *23*
artery to the atrioventricular node, 56
articular disc, 37, *37*, 40
articular processes, 5, *5*
arytenoid cartilage, 205, *205*
arytenoid muscle, 206, *206*
ascending aorta, *53*, 54, *54*
ascending colon, 75, *76*, 85
atlanto-occipital joint, *190*, 190–191, *191*
atlas (C1 vertebra), 5, 11, *11*, 189
  cruciate ligament of, 190, *191*
  transverse ligament of, 190, *190*
atrioventricular bundle, 59
atrioventricular groove (sulcus), 54
atrioventricular node, 57, *57*, 59
atrioventricular valve, *57*, 57–59, *59*
atrium
  left, 58, *58*
  right, 56–57, *57*
auditory ossicles, *209*, 210
auricular artery, posterior, 179, *179*
auricular cartilage, 208, *208*
auricular nerve, greater, 175, *176*
auriculotemporal nerve, 185
axilla, 19–22
  axillary artery, *20*, 20–21
  boundaries of, 19, *19*
  brachial plexus, *21*, 21–22
  defined, 19
axillary artery, *20*, 20–21
axillary vein, *19*, 20
axillary fascia, 45
axillary nerve, 18, 21, *21*
  injury to, 22
axillary sheath, *19*, 20
axis (C2 vertebra), 5, 11, *11*, 189, *190*
azygos, arch of, 60
azygos vein, 62, *62*

B

back
  muscles of
    deep, 9–11, *10*
    intermediate, 9
    superficial, 7–9, *8*
  skeleton of, 4–6, *5*
  skin incisions, 7
  spinal cord, 12–14, *13*
  spinal meninges, 12–14, *14*
  suboccipital region, *11*, 11–12
  superficial fascia, 7, 7
  surface anatomy, 4, *4*
  triangles of, 9
  vertebral column, 12–14, *13*
basilar artery, 164, *164*
basilic vein, 16, *16*
Bell's palsy, 155
biceps brachii muscle, *23*, 23–24
biceps brachii tendon, 24
biceps femoris muscles, 134, *135*
bicipital aponeurosis, *23*, 24–25
bicuspid valve, *57*, 57–59, *59*
blunt dissection, 2
brachial artery, 20, *20*, *23*, 24, *25*, 28
brachial fascia, 22
brachial plexus, *21*, 21–22
  infraclavicular part, *21*, 21–22
  roots of, 183, *183*
  three cords of, 21, *21*
brachialis muscle, *23*, 24
brachiocephalic trunk, 60, *61*
brachiocephalic veins, 60, *60*
brachioradialis muscle, 25, *26*
brachioradialis tendon, 35
brain
  cranial fossae, *164*, 164–168
  cranial meninges, 159–161, *160*, *161*
  dural infoldings, *162*, 163
  dural venous sinuses, *162*, 163

brain *(continued)*
gross anatomy, 163–164, *164*
lateral surface of, 164, *164*
lobes of, 164, *164*
removal of, 161–163
brainstem, 164, *164*
breast, 43–44, *44*
cancer of, 44
ligaments of, 44, *44*
bronchi(us)
left and right main, 61, *61*
lobar, 51, *51*
main, 51, *51*
segmental, 51
bronchial arteries, 51, 63
buccal artery, 189
buccal nerve, 154, *154*
buccinator muscle, *154*, 154–155, *155*
bulbospongiosus muscle, 101, *101*, 112
bulbourethral glands, 102–103

C

cadaver, care of, 1
calcaneal tendon, 140, *141*
calcaneocuboid joint, 148–149, *149*
calcaneus bones, 137, *137*
calvaria, 152, *152*
removal of, *157*, 158
calyx
major, 91, *91*
minor, 91, *91*
Camper's fascia, 65
caput medusae, 66
cardiac notch, 50, *51*
cardiac tamponade, 54
cardiac veins, 55, *55*
carina, 61, *61*
carotid artery, 60, *61*
bifurcation of common, 179, *179*
external, 179, *179*, *184*, 185
internal, *167*, 168, 179
carotid body, 179
carotid canal, *167*, 168
carotid nerve, internal, 191
carotid sheath, 178, *179*, 193
carotid sinus, 179
carotid triangle, *178*, 178–179
carpal bones, 30, *30*
carpal tunnel, 31–33
contents of, *30*, 31
defined, 30
how to open, 31, *32*
transverse section through, *30*
carpal tunnel syndrome, 32
cauda equina, 13, *13*
cavernous sinus, *167*, 167–168
cecum, 75, *76*, *84*, 84–85, 89, *89*
celiac ganglia, 95
celiac trunk, 78–80, *79*
cephalic vein, 16, *16*, 45–46
cerebellar tentorium, 161–163, *162*
cerebellum, 164, *164*
cerebral arteries, 162, 164, *165*
cerebral falx, 161, *162*, 163
cerebral veins, 160, *160*, *162*, 162–163
cerebrospinal fluid (CSF), lumbar puncture for, 14, *14*
cervical artery
ascending, 182, *183*
transverse, 182, *183*
cervical enlargement, 12, *13*
cervical ligament, transverse, 114, *114*
cervical nerve, transverse, 175, *176*
cervical plexus, 175, *176*
cervical vertebra, 5–6, *6*
cervical viscera, 174, *175*
chalazion cyst, 170
childbirth, 113
chorda tympani, *188*, 189, *209*, 210
chordae tendineae, *57*, 58–59
ciliary ganglion, 172
circumflex femoral arteries, 127, *127*
circumflex humeral arteries, 18, *20*, 20–21
circumflex humeral vein, posterior, 18
clavicular notch of the manubrium, 37, *37*
clavipectoral fascia, 45
clean
a nerve, 2
a vessel, 2
defined, 2
the border of a muscle, 2
clitoris, 112, *112*
cluneal nerves, 123, *123*
coccygeal ligament, *13*, 14
coccygeal plexus, 119
coccygeus muscle, *109*, 110, 121, *121*
coccyx, 6, *6*
cochlea, *209*, 210
colic arteries, 83, 85, *85*
colic flexure
left, 76, *76*
right, 75, *76*
collateral ligament
fibular, 146, *147*
radial, 39, *39*
tibial, 146, *147*
ulnar, 39, *39*
Colles' fascia, 100, *100*, 111
colon
ascending, 75, *76*, 85
descending, 76, *76*, 86
sigmoid, 76, *76*, 86
transverse, 76, *76*, 86, 89
common tendinous ring, 172, *172*, 173, *173*
communicating artery
anterior, 164, *164*
posterior, 164, *164*
conchae, 197, *197*, *201*
conducting system of the heart, 57, 59
conjunctiva, 170
contact impressions, 50, *51*
conus arteriosus (infundibulum), *57*, 58
conus medullaris (medullary cone), 13, *13*
coracoacromial ligament, 38, *38*
coracobrachialis muscle, *23*, 24
coracoclavicular ligament, 37, *38*
coronary arteries, *55*, 55–56, 59
coronary groove (sulcus), 54
coronary ligament, 76
corpus cavernosum penis, *102*, 102–103
corpus spongiosum penis, *102*, 102–103
costal cartilages, 46
costal parietal pleura, 47
costocervical trunk, 182
costoclavicular ligament, 37, *37*
costodiaphragmatic recesses, 49, *49*
costomediastinal recesses, 49, *49*
cranial fossae, *164*, 164–168
anterior, 166
middle, 166–168
posterior, *167*, 168
skeleton of, 164, *165*, 166
cranial meninges, 159–161, *160*, *161*
cranial nerves, 164, *165*, 166–168, *167*. *see also* specific nerve
craniovertebral joints, 190–191, *191*
cremaster fascia, 68–69
cremaster muscle, *68*, 68–69
cricoarytenoid muscles, 206, *206*
cricoid cartilage, 205, *205*
cricothyroid joint, 206
cricothyroid muscle, 178, *179*, 206, *206*
crista galli, 161, *162*
cruciate ligament
anterior, 146, *147*
posterior, 146, *147*
cubital fossa, 24–25
boundaries of, 25
defined, 24
cuneiform bones, 137, *137*
cutaneous nerves
lateral femoral, *123*, 124
of abdomen, 66
of face, 152, *152*
of foot, 142, *142*
of scapular region, *16*, 16–17
of the arm, 17, 21
of the forearm, 17, 21, *23*, 24
of the thigh, 94, 123, *123*, 132, *132*
of upper limb, 17
cystic artery, 79, *79*, 81
cystic duct, 78, *79*

D

deep artery of the arm, *23*, 24
deep palmar arch, 34
deep perineal pouch
female, *112*, 112–113
male, 103, *103*
define, defined, 2
deltoid muscle, 18, *18*
deltopectoral triangle, 16, 45
dental anesthesia, 188
denticulate ligaments, 14
depressor anguli oris muscle, 155, *155*
descending artery, left anterior, 55
descending colon, 76, *76*, 86
diaphragm, 48, *49*, *94*, 94–95
digastric muscle, 178, *178*, 180, 185
digital synovial sheaths, 31
dissect, defined, 2
dissection
blunt, 2
instruments for, *1*, 1–2
lab safety, 3
routine for, 3
sharp, 2
dorsal digital nerves, 124
dorsal primary ramus of a spinal nerve, 7, 7, 14, *14*
dorsal venous arch of foot, 124, *124*
dorsal venous vein, 16, *16*
dorsalis pedis artery, 138, *138*, 144
ductus deferens, 72, 104–105, *105*
ampulla of, 105, *105*
duodenal papilla, 88
duodenojejunal junction, 84, *84*
duodenum, 86, *86*, *87*
dura mater, 159, *160*, *161*
dural infoldings, 162, *163*
layers of, 159
of spine, 13–14
dural infoldings, *162*, 163
dural sac, 13, *13*
dural venous sinuses, *162*, 163

E

ear, 208–210
external, 208, *208*
inner, 210
middle, 208–210, *209*
ejaculatory duct, 105, *105*
elbow joint, 27, *27*, 39, *39*
endometrium, 116
endopelvic fascia, 114, *114*
endothoracic fascia, 49, 52

epidural space, 12
epigastric anastomoses, 71
epigastric artery, *65*, 71
epigastric vein, *65*, 71
epiglottic cartilage, 205, *205*
epiglottis, *194*, 195, 203, *203*, 207, *207*
erect posture, 97
erector spinae muscle, 10, *10*
esophageal arteries, 63
esophageal hiatus, 94, *94*, 95
esophagus, 62, *62*
ethmoid bone, 164, *165*, 166, 195, *196*
ethmoidal bulla, 197, *198*
ethmoidal cells, 197, *198*
ethmoidal foramina, 169
ethmoidal nerve, 172, *172*
eversion joints, of foot, 148–149, *149*
extensor carpi radialis brevis tendon, 35
extensor carpi radialis longus tendon, 35
extensor carpi ulnaris tendon, 35
extensor digiti minimi tendon, 35
extensor digitorum brevis muscle, 138, *138*
extensor digitorum longus muscle, 138, *138*
extensor digitorum tendons, 35
extensor expansion, 35
extensor hallucis brevis muscle, 138, *138*
extensor hallucis longus muscle, 138, *138*
extensor indicis tendon, 36
extensor muscles
  deep, 35–36, *36*
  superficial, 35
extensor pollicis brevis tendon, 36
extensor pollicis longus tendon, 36
extensor retinaculum, 35
external acoustic meatus, 208, *208*
external oblique muscle, 67, *68*
eyeball, 168–170, *170*, 173–174. *see also* orbit
eyelid
  dissection instructions, 170–171
  lower, 170

F

face, 152–156, *154*
  cutaneous nerve distribution of, 152, *152*
  facial artery, 153–154, *154*
  facial nerve, 153–154, *154*
  facial vein, 154, *154*
  lower lip, 155
  muscles of, *155*
    oral opening, 155, *155*
    orbital opening, 154–155, *155*
  orbit, 168–174
  sensory nerves of, 155, *156*
  superficial fascia of, 153
facial artery, 153–154, *154*, 179, *179*
facial nerve, 153–155, *154*, *165*, *167*, 168, 209, *209*
facial vein, 154, *154*
falciform ligament, 74, 76, 81, *81*
fallopian tube, 116
falx cerebri, 161, *162*, 163
femoral artery, 127, *127*
femoral hernia, 125
femoral nerve, 94, *123*, 124, 128, 129, *129*
femoral sheath, 125, *126*
femoral triangle, *126*, 126–128
femoral vein, 127, *127*
femur, 125, *126*, 131, *131*, 134, 146, *146*
fibrous digital sheath, 31, *31*
fibula, 134, 136, *137*
fibular artery, 140–141, *141*
fibular collateral ligament, 146, *147*
fibular nerve
  common, 134, *135*, *138*, 138–139
  deep, *138*, 139
  superficial, *123*, 124, 139
fibularis longus tendon, 144
fibularis tertius muscle, 138, *138*
filum terminale externum (coccygeal ligament), *13*, 14
filum terminale internum, *13*, 14
flexor carpi radialis tendon, 27, *28*
flexor carpi ulnaris tendon, 28, *28*
flexor digiti minimi brevis muscle, 33
flexor digiti minimi muscle, 144, *144*
flexor digitorum brevis muscle, *142*, 142–143
flexor digitorum longus muscle, 140, *141*
flexor digitorum longus tendons, 143, *143*
flexor digitorum profundus muscle, 29, 32–33, *33*
flexor digitorum superficialis muscle, 32–33, *33*
flexor digitorum superficialis tendon, 28, *28*
flexor hallucis brevis muscle, 143–144, *144*
flexor hallucis longus muscle, 140, *141*, 144
flexor pollicis brevis muscle, 33
flexor pollicis longus muscle, 29, 33
flexor retinaculum, 30, *30*, 31
flexor tendons in finger, 31, *31*
foot
  inversion and eversion joints, 148–149, *149*
  muscles of, *138*
  plantar aponeurosis, 142, *142*
  plantar muscles
    first layer, 142–143, *143*
    second layer, 143, *143*, 144
    third layer, 143–144, *144*
  skeleton of, 137, *137*
  sole of, 142–144, *143*, *144*
foramen ovale, 57
foramen rotundum, 167, *167*
foramen spinosum, 166, *167*
forceps, 1, *1*
forearm, 26–30
  compartments of, 26, *26*
  extensor region, 35–36, *36*
  flexor region
    deep group, 29
    superficial group, 27–28, *28*
    vessels and nerves, 27–29, *28*
  skeleton of, 27, *27*
fossa ovalis, 56–57
frontal bone, *151*, *165*, 166, 168
frontal lobe, 164, *164*
frontal nerve, 171, *171*
frontal sinus, 171

G

gallbladder, 75, *75*, *76*, 78, *78*, 81, *82*
gastric artery
  left, *79*, 79–80
  right, 79, *79*
  short, 80
gastric veins, 80
gastro-omental arteries, *79*, 80, 87, *87*
gastrocnemius muscle, 140, *141*
gastroduodenal artery, 79, *79*
gastroesophageal varices, 87
gastrointestinal tract. *see also* specific organ
  removal of, 88–89
gastrolienal ligament, 76
gastrophrenic ligament, 76
gastrosplenic ligament, 76–77
gemellus muscles, *132*, 133
genioglossus muscle, 203, *204*
geniohyoid muscle, 203, *204*
genitalia
  external, female, 110, *111*
  internal
    female, *115*, 115–116
    male, 104–105, *105*
genitofemoral nerve, 93
glans penis, 102
glenohumeral joint, 37–38, *38*
glenohumeral ligaments, 38, *38*
glenoid cavity, 38, *38*
glenoid labrum, 38, *38*
glossopharyngeal nerve, *165*, *167*, 168, 192–193, *193*, *199*, 201, 210
glottis, 205, 207
gluteal aponeurosis, 131
gluteal artery
  inferior, 108–109, 119, *119*, 132
  superior, 108, 119, *119*, 120
gluteal nerve, inferior, 132
gluteal region, 130–133
  muscles of, *131*, *132*
  skeleton of, 130–131, *131*
gluteal vein, inferior, 132
gluteus maximus muscle, 98, *98*, 131, *131*, *132*
gluteus medius muscle, 132, *132*
gluteus minimus muscle, *132*, 133
gracilis muscle, 129
gray rami communicantes, 109, 120, 192
greater omentum, 75, *75*

H

hamulus of the medial plate, 200, *200*
hand
  carpal tunnel, 31–33
  dorsum of, 35–36, *36*
  palm of, 30–35
    deep, 34, *34*
    hypothenar muscles, 33–34
    superficial, 30–31, *31*, *32*
    thenar muscles, 33
  skeleton of, 30, *30*
hard palate, 198, *200*
haustra, 86
head
  brain
    cranial fossae, *164*, 164–168
    cranial meninges, 159–161, *160*, *161*
    dural infoldings, *162*, 163
    dural venous sinuses, *162*, 163
    gross anatomy, 163–164, *164*
    removal of, 161–163
  craniovertebral joints, 189–192
  ear, 208–210
  face, 152–156, *154*
  nose and nasal cavity, 195–198
  oral region, 202–205
  orbit, 168–174
  palate, 198–202
  parotid region, *184*, 184–185
  removal of, 191, *191*
  scalp, 156–157
  skin incisions, 153, *153*
  skull
    anterior view, 150, *151*
    interior of, 158–161
    lateral view, 150, *151*, 152
  surface anatomy, 150, *150*
  temporal region, 185–189
heart
  apex of, 53
  base of, 53
  borders of, 53
  cardiac veins, 55, *55*
  chambers of, 53, *53*
  conducting system of the, 57, 59
  coronary arteries, *55*, 55–56, 59
  external features of, 54–56
  how to open, 56, *56*
  in thorax, 52–53, *53*
  internal features of, 56–59
  left atrium, 58, *58*
  left ventricle, 58–59, *59*

heart *(continued)*
removal of, 54, *54*
right atrium, 56–57, *57*
right ventricle, *57*, 57–58
surfaces of, 55
hematoma, subdural, 160
hemiazygos vein, *62*, 62–63
hemopericardium, 54
hemorrhoids, 107, 118
hemostat, 1, *1*
hemothorax, 49
hepatic arteries, 79, *79*
hepatic ducts, 78–79, *79*
hepatic flexure, 75, *76*
hepatic lymph nodes, 79
hepatic portal vein, 80, 87
hepatic veins, 81, *81*
hepatoduodenal ligament, 78, *78*
hernia
femoral, 125
inguinal, 69, *70*
hip bone, 96, *97*
hip joint, *145*, 145–146, *146*
hordeolum, 170
humerus, 17, *17*, 22, *23*, 27, *27*
hyoglossus muscle, 204, *204*
hyoid muscle, 178, *178*
hypogastric plexus, inferior, 119
hypoglossal canal, *167*, 168
hypoglossal nerve, *165*, *167*, 168, 180, *193*, 194, 204, *204*
hypophyseal fossa, *167*, 168
hypothenar muscles, 30, 33–34

I

ileocecal junction, 84, *84*
ileocolic artery, 83, *84*
ileum, 75, *76*, *82*, 82–84, 89, *89*
iliac artery
common, 92, *92*
female, 118, *119*
male, 107, *107*
external
female, 118, *119*
male, 107, *107*
internal
female, 118–119, *119*
male, *107*, 107–108
iliac vein
common
female, 119
male, 108
external
female, 119
male, 108
internal
female, 119
male, 108
iliacus muscle, 93, *93*
iliococcygeus muscle, *109*, 110, 121, *121*
iliocostalis muscle, 10, *10*
iliofemoral ligament, 145, *145*
iliohypogastric nerve, 6, 66, 94
ilioinguinal ligament, 67
ilioinguinal nerve, 66, 69, 94
iliolumbar artery, 108, 119, *119*
iliopsoas muscle, 93, *93*, 127, 145
ilium, 4, *5*
incus, *209*, 210
inferior vena cava, 81, *81*, 92, *92*
infraglottic cavity, 207, *207*
infraorbital nerve, 155, *156*
infraspinatus muscle, *18*, 19
infratemporal fossa, 185, 187–189, *188*, 199, *199*, 202
boundaries of, 186
skeleton of, 186, *186*
infundibulum, *57*, 58
inguinal canal, 66, *67*, 69
inguinal hernia, 69, *70*
inguinal ligament, 67
inguinal lymph nodes, superficial, 124, *124*
inguinal ring
deep, 67, *67*, 69
superficial, 66–67, *67*
intercavernous sinuses, *167*, 168
intercostal arteries, 45, *47*, 63
intercostal muscles, 46–47, *47*, 63
external, 46, *47*
internal, 45, *47*
intercostal nerves, 44, 47, *47*, 63
intercostal space, 46–47, *47*
intercostal veins, 45, *47*, 62, *62*
intercrural fibers, 67
intermediate tendon, 180
internal iliac artery
anterior division
female, 118–119, *119*
male, *107*, 108
male, *107*, 107–108
posterior division
female, 119, *119*
male, *107*, 108
internal oblique muscle, *68*
interosseous artery, 36
interosseous muscles, 144
dorsal, 34, *34*
palmar, 34, *34*
interosseous nerve, 36
interphalangeal joints, *40*, 41
interventricular grooves (sulcus), 54
interventricular septum, 57, 59, *59*
intervertebral disk, 5, *5*
intervertebral foramen, 5, 14, *14*
intestinal arteries, 83, *83*
intestines
large, 75, *76*, 85–86, *86*
small, 75, *76*, 83–84, *84*
intragluteal injections, 133
inversion joints, of foot, 148–149, *149*
ischioanal fossa, 98–99, *99*
ischiocavernosus muscle, 101, *101*
ischiofemoral ligament, 145, *145*
ischiorectal fossa, 98–99, *99*

J

jejunum, 75, *76*, *82*, 82–84, 89, *89*
jugular vein
external, 175, *176*, 181, 185
internal, 163, 179, *179*, 183, *183*

K

kidney stones, 91
in females, 117
in males, 106
kidneys, 90–91, *91*
knee injuries, 147
knee joint, 146–147, *147*

L

lab safety, 3
labium majus, 72
lacrimal apparatus
dissection instructions, 170–171
parts of, 169–170, *171*
lacrimal canaliculi, 171, *171*
lacrimal gland, 170, *171*
lacrimal groove, 170, *171*
lacrimal nerve, 171, *171*
lacrimal sac, 171, *171*
lactiferous ducts, 44, *44*
lactiferous sinus, 44, *44*
lamina papyracea, 169
laminae of vertebra, 12, *13*
large intestines, 75, *76*, 85–86, *86*
laryngeal artery, superior, 179, *179*
laryngeal cavity, 207, *207*
laryngeal nerve, 207
external branch of superior, 178, *179*
inferior, 206, *206*
left recurrent, 53, *53*, 60, *61*
recurrent, 180–181, 183, 192, *193*
superior, *193*, 194, 206, *206*
laryngopharynx, *194*, 195
laryngospasm, 207
larynx, 205–207
interior of, 207, *207*
intrinsic muscles of, *206*, 206–207
nerve supply to, 207
skeleton of, 205, *205*
lateral (inferior) crus, 67
lateral ligament of ankle, 147, *148*
lateral thoracic artery, *20*
latissimus dorsi muscle, 8, *8*
left anterior descending artery, 55, 56
left crus, 94, *94*
leg, 136–139
compartments of, 136, *136*
anterior, 137–139, *138*
lateral, 139
posterior, 140–142, *141*
motor nerve territories of, 141, *142*
skeleton of, 136, *137*
levator ani muscle, *109*, 110, 121, *121*
levator labii superioris muscle, 155, *155*
levator palpebrae superioris muscle, 172, *172*
levator scapulae muscle, *8*, 9
levator veli palatini muscle, 200, *200*
lienorenal ligament, 76–77
ligamenta flava, 12
ligamentum arteriosum, 53, *53*, 60, *61*
ligamentum teres hepatis, 76
ligamentum venosum, 81, *81*
limbs. *see* lower limb; upper limb
linea alba, 71, *71*
lingual artery, 179, *179*, 204, *204*
lingual nerve, 188, *188*, 204, *204*
lingula, 50
lip, lower, 155
liver, 80–81, *81*
features of, 78, *78*
location of, 75, *75*, *76*
pathology, 81
long ciliary nerve, 172, *172*
longissimus muscle, 10, *10*
longus capitis muscle, 191, *191*
longus colli muscle, *191*, 192
lower limb
cutaneous nerves, *123*
deep fascia, 125
foot, 137–139
muscles of, *138*
skeleton of, 137, *137*
sole of, 142–144, *143*, *144*
gluteal region, 130–133
joints of, 145–149
ankle, 147, *148*

hip, *145*, 145–146, *146*
inversion and eversion, 148–149, *149*
knee, 146–147, *147*
leg, 136–139
anterior compartment, 137–139, *138*
lateral compartment, 139
posterior compartment, 140–142, *141*
skin incisions, 122–123, *123*
superficial fascia
anterior, *123*, 124–125
posterior, *123*, 123–124
superficial veins, *123*
surface anatomy, 122, *122*
thigh
anterior compartment, 124–129
medial compartment, 129–130, *130*
posterior compartment, 133–136, *135*
lumbar artery, 92, *92*
lumbar enlargement, 12, *13*
lumbar plexus, 93–94
lumbar puncture, for cerebrospinal fluid (CSF), 14, *14*
lumbar splanchnic nerves, 94
lumbar triangle, 9
lumbar vertebra, 6, *6*
lumbocostal arches, 94, *94*
lumbosacral trunk, 94, 108, *108*, 120, *120*
lumbrical muscles, 143, *143*
lungs, 49, *49*
fissures of, 50, *50*
in the thorax, 50, *50*
lobes of, 50, *50*
removal of, 50–51
surfaces of, 50
lymph drainage
female pelvis, 121
male pelvis, 110
of mammary gland, 44
lymph nodes
celiac, 81
hepatic, 79, 81
mesenteric, 83
superficial inguinal, 124, *124*
tracheobronchial, 61

M

malleus, *209*, 210
mammary gland, 44, *44*
mandible, 150, 152, 184, 202
bisection of, 203
external surface, *152*, 186, *186*
internal surface, 179, 186, *186*
mandibular nerve, 152, *165*, *167*, 168, *188*
mandibular teeth, 188
masseter muscle, 186
masseteric artery, 189
maxilla, *151*, 169, 195, *196*, 199, *199*, 202
maxillary artery, 185, 188, *188*, 202
maxillary nerve, 152, *165*, 167, *167*, 202
maxillary sinus, 197–198, *198*
maxillary vein, 185
medial (superior) crus, 67
medial ligament of ankle, 147, *148*
medial meniscus, 147, *147*
medial palpebral ligament, 170, *170*
median cubital vein, 16, *16*
median nerve, 21, *21*, *23*, 24, 28, 30–31
mediastinal pleura, 52
mediastinum, 49, 52, *52*
anterior, 52
boundaries of, 52
middle, 52–54, *53*, *54*
posterior, 52, 61–63, *62*
subdivisions of, 52, *52*
superior, 59–61, *60*, *61*
medullary cone, 13, *13*
membranous urethra, *103*, 103–104, *104*
meningeal artery, middle, 160, 166, *167*, 188, *188*
meninges, spinal, 12–14, *14*
menisci, 147, *147*
mental nerve, 155, *156*, 188
mesenteric artery
inferior, 84–85, 85, *85*
superior, *82*, 82–83, *83*, 85
mesenteric lymph nodes, 83
mesenteric vein
inferior, 85
superior, 83
mesentery, *75*, 77
root of, 84, *84*
mesoappendix, 77, 85
metacarpal bones, 30, *30*
metacarpophalangeal joints, 40, *40*
middle mediastinum, 52–54, *53*, *54*
mitral valve, *57*, 57–59, *59*
moderator band, *57*, 58–59
muscular triangle, of neck, 177, *177*
musculocutaneous nerve, 21, *21*, *23*, 24, 26
mylohyoid muscle, *178*, 180, 203

N

nasal cartilage, 196, *196*
nasal cavity
boundaries of, 196
conchae and meatuses of, *197*
lateral wall, 197, *197*
skeleton of, 195, *195*, *196*
nasal septum, *196*, 196–197, *197*
nasociliary nerve, *172*, 172–173
nasolacrimal duct, 171, *171*, *197*, *198*
nasopalatine artery, 196–197, *197*
nasopalatine nerves, 200, *200*
nasopharynx, 194, *194*
navicular fossa, 102
neck
anterior triangle, 176–180
bones and cartilages, 176, *177*
boundaries of, *175*, 176
carotid triangle, *178*, 178–179
muscular triangle, 177, *177*
submandibular triangle, *175*, 179–180
submental triangle, *175*, 180
superficial fascia, *176*, 177
craniovertebral joints, 189–192
larynx, 205–207
lateral vertebral region, 191–192
muscular triangle, 177, *177*
parathyroid gland, 181
pharynx, 192–195
posterior triangle, 174–176, *176*
boundaries of, 174, *175*
skin incisions, 174, *175*
structures in, 174–176
prevertebral region, 191–192
root of, 181–183, *182*
boundaries of, 181
subclavian artery, *182*, 182–183
thyroid gland, 180–181, *181*
transverse section through, 174, *175*
nerve injuries, 22
nipple, 44, *44*
noncoronary cusp, 59
nose, 196, *196*. *see also* nasal cavity

O

oblique muscle
external, 67, 68
internal, 67–69, *68*
superior, 171–172, *172*
oblique pericardial sinus, 53, *54*
obliquus capitis inferior muscle, 11
obliquus capitis superior muscle, 12
obturator artery, 108, 118, *119*
obturator externus muscle, 130, *130*, 145
obturator internus muscle, *109*, 110, 121, *121*, *132*, 133
obturator nerve, 94, *123*, 124, 130
occipital artery, 7, *7*, 179, *179*
occipital bone, *151*, 158, *165*, 166, 190, *190*
removal of, 158, *159*
occipital lobe, 164, *164*
occipital nerve
greater, 7, *7*
lesser, 175, *176*
occipitofrontalis muscle, 157, *157*
oculomotor nerve, *165*, 166, *167*, *172*, 172–173
olfactory area, 197, *197*
olfactory nerve, 166, *167*
omental appendices, 86
omental foramen, 77, *77*
omentum
greater, *75*, 75–76
lesser, *75*, 76
omohyoid muscle, 177, *177*, 181
ophthalmic artery, 164, *164*, 172–173, *173*
ophthalmic nerve, 152, *165*, 166–167, *167*
ophthalmic veins, 172
opponens digiti minimi muscle, 33
opponens pollicis muscle, 33
optic nerve, *165*, 166, *167*, *172*, 173
oral cavity, 202
oral cavity proper, 202–203, *203*
oral opening, muscles of, 155, *155*
oral region, 202–205
mandible, 203 (*see also* mandible)
sublingual area, 202–204, *204*
surface anatomy, 202–203, *203*
tongue, 203, *203*
oral vestibule, surface anatomy, 202–203, *203*
orbicularis oculi muscle, 154–155, *155*, 170, *170*
orbicularis oris muscle, 155, *155*
orbit, 168–174
eyeball, 169–170, *170*
eyelid, 169–170, *170*
left, anterior approach, *173*, 173–174
right, superior approach, *171*, 171–173
skeleton of, 168–169, *169*
orbital fissure, 169
orbital opening, muscles of, 154–155, *155*
orbital septum, 170, *170*
oropharynx, *194*, 195
ovarian fossa, *115*, 116
ovarian vein, 90
ovary, *115*, 116

P

palate, 198–202
hard, 198
nerves of, *200*
pterygopalatine fossa, 201, *201*
skeleton of, 199, *199*
soft, 198–200, *200*
sphenopalatine foramen, 201, *201*
tonsillar bed, *199*, 201
palatine arteries, 201, *201*
palatine bone, 195, *196*, 199, *199*
palatine glands, 198
palatine nerves, 201, *201*
palatine tonsil, *194*, 195, *199*, *200*
palatoglossal fold, *194*, 195, *199*, 201
palatoglossus muscle, *199*, 201

palatopharyngeal fold, *194*, 195, *199*, 201
palatopharyngeus muscle, 199, *200*
palm of hand, 30–35
  deep, 34, *34*
  hypothenar muscles, 33–34
  superficial, 30–31, *31*, *32*
  thenar muscles, 33
palmar aponeurosis, 30
palmar digital arteries, 31
palmaris brevis muscles, 30–31
palmaris longus muscle, 31
palmaris longus tendon, 27, *28*
pancreas, *86*, 86–87, *87*
pancreatic arteries, 87, *87*
pancreatic ducts, 87, *87*
pancreaticoduodenal arteries, 83, 87, *87*
papillary muscles, *57*, 58, 59
parametrium, 116
pararectal fossa, 104, 113
parathyroid gland, 181
paravesical fossa, 104, 113
parietal peritoneum, 74
parietal pleura, 49, *49*, 52
parotid duct, 185
parotid sheath, 184
parotid bed, boundaries of, 184, *184*
parotid duct, 153, *154*
parotid gland, 153–154, *154*, *184*, 184–185
parotid plexus, 154
parotid region, *184*, 184–185
patella, 125, *126*
patellar ligament, 128
patellar tendon reflex, 128
pectinate line, *106*, 107, 118
pectineus muscle, 127–129, *130*
pectoral fascia, 44–45
pectoral nerves, 21, *21*, 45–46
pectoral region, 43–46
  breast, 43–44, *44*
  muscles of, *45*, 45–46
  skin incisions, 43, *43*
  superficial fascia, 44
pectoralis major muscle, 45, *45*
pectoralis minor muscle, 45, *45*
pelvic brim, 96–97, *97*
pelvic cavity
  female, 113–116
    internal genitalia, *115*, 115–116
    peritoneum, *113*, 113–114
  male, *103*, 103–105
    internal genitalia, 104–105, *105*
    peritoneum, *103*, 104
pelvic diaphragm, 96, *96*
  female, 120–121, *121*
  inferior surface of, 99, *99*
  male, *109*, 109–110
pelvic inlet, 96, *96*
pelvic ligaments, 96, *97*
pelvic outlet, 97
pelvic splanchnic nerves, *108*, 109, 120, *120*
pelvis, 125, *126*, 130, *131*, 134
  anal triangle, 97–99
  female
    internal iliac artery, 118–119, *119*
    lymph drainage of, 121
    pelvic cavity, 113–116
    pelvic diaphragm, 120–121, *121*
    rectum and anal canal, *117*, 117–118
    sacral plexus, 119–120, *120*
    urinary bladder, *116*, 116–117, *117*
    urogenital triangle, 110–113
  greater (false), 97
  lesser (true), 97
  male, *103*, 103–105
    internal iliac artery, *107*, 107–108
    lymph drainage of, 110
    pelvic cavity, *103*, 103–105
    pelvic diaphragm, *109*, 109–110
    rectum and anal canal, *106*, 106–107
    sacral plexus, *108*, 108–109
    urinary bladder, 105–106, *106*
    urogenital triangle, 99–103
  perineum, *97*, 97–99
  skeleton of, *96*, 96–97, *97*
penis, 101–102, *102*
  bulb of, 101, *101*
  corpus cavernosum, *102*, 102–103
  corpus spongiosum, *102*, 102–103
  crus of, 101, *101*
  deep fascia of, 102, *102*
  dorsal artery of, 102, *102*
  dorsal nerve of, 102, *102*
  dorsal vein of, 102, *102*, 108
  glans, 102
  parts of, 101, *101*
perforating arteries, 129, *130*
pericardiacophrenic vessels, 50, 52
pericardial cavity, 53, *54*
pericardial effusion, 54
pericardial sinus
  oblique, 53, *54*
  transverse, 53, *54*
pericardium, 50, *50*, 52
  how to open, 52, *53*
pericranium, *157*, 158
perimetrium, 116
perineal body, 100–101, 112
perineal membrane, 104, *105*, *111*, 111–112
perineal pouch
  deep
    female, *112*, 112–113
    male, 103, *103*
  superficial
    female, *111*, 111–112, *112*
    male, *100*, 100–101
perineum
  anal triangle, *97*, 97–99
  urogenital triangle
    female, 110–113
    male, 99–103
periorbita, 169, 171
peritoneal cavity, 74–77, *75*
peritoneal sacs, *75*, 77
peritoneum, 74, 76–77
  female pelvis, *113*, 113–114
  male pelvis, *103*, 104
  parietal, 74, 76
  visceral, 74, 76
peroneal artery, 140–141, *141*
peroneal nerve, *123*, 124, 139
petrosal nerves, 209, *209*
petrosal sinus, superior, 166, *167*
phalanges, 30, *30*
pharyngeal artery, ascending, 179, *179*
pharyngeal constrictor muscles, 192, *193*
pharyngeal plexus, 192, *193*
pharyngeal raphe, 192, *193*
pharyngeal recess, 194, *194*
pharyngeal tonsil, 194, *194*
pharyngeal tubercle, 192, *193*
pharyngeal wall
  layers of, 192
  muscles of, 192–193, *193*, *200*
  nerves of, 192–194, *193*
pharynx, 192–195
  internal aspect of, 194–195
  mucosal folds, 199, *199*
  pharyngeal wall, 192–194, *193*
  regions of, *194*
phrenic nerve, 183, *183*
phrenic nerves, 50, 52, 95
phrenic veins, 60, *60*
phrenicocolic ligament, 77
pia mater
  of brain, 161
  of spine, 13–14
piriform recess, 195, 206
piriformis muscle, 132, *132*
pisiform bone, 27, *27*, 30
plane of sternal angle, 52
plantar aponeurosis, 142, *142*
plantar arterial arch, 144
plantar artery, deep, *138*, 139
plantar calcaneonavicular ligament, 149, *149*
plantar digital nerves, 143, *143*
plantar ligaments, 149, *149*
plantar muscles
  first layer, 142–143, *143*
  second layer, 143, *143*, 144
  third layer, 143–144, *144*
plantar nerves, 143, *143*
plantaris muscle, 140, *141*
platysma muscle, 44, 153, *154*, 174, *176*
pleural cavities, 48–49, *49*
pleural effusion, 49
pleural recesses, 49, *49*
pleural reflection, lines of, 49, *49*
pleural tap, 47, *47*
pneumothorax, 49
pollicis brevis muscles, 33
popliteal artery, 135, *136*
popliteal fossa, 134–135, *135*
popliteus muscle, 135, *136*, 140, *141*
porta hepatis, 81, *81*
posterior cruciate ligament, *147*
prevertebral fascia, 191
probe, 1, *1*
pronator quadratus muscle, 29
pronator teres muscle, *23*, 24, 27, *28*
proper palmar digital nerves, 31
prostate, 105, *105*
psoas major muscle, 93, *93*
psoas minor muscle, 93, *93*
pterion, 152, 160
pterygoid canal, nerve of, 201, *201*, 209
pterygoid muscle, 187, *188*
  lateral, 187, *188*, 189
  medial, 188
pterygoid process, medial plate of, 200, *200*
pterygomandibular raphe, 192, *193*
pterygopalatine fossa, 189, 201, *201*
pterygopalatine ganglion, 202
pubic arch, 96, *97*
pubocervical ligament, 114, *114*
pubococcygeus muscle, *109*, 110, 121, *121*
pubofemoral ligament, 145, *145*
puborectalis muscle, *109*, 110, 121, *121*
pudendal artery, internal, 99, 103, 108, 119, *119*
pudendal canal, 99
pudendal nerve, 99, 103, 109, 120, *120*, 132, *132*
pudendal nerve block, 113
pudendal vein, internal, 99
pulmonary ligament, 49
pulmonary trunk, *53*, 53–54, *54*, *57*, 58
pulmonary valve, *57*, 57–58
pulmonary veins, 50, *51*, 54, *54*, 58, *58*
pyramidalis muscle, 71

Q

quadrangular space, 18, *18*
quadratus femoris muscle, *132*, 133
quadratus lumborum muscle, 93, *93*

quadratus plantae muscle, 143, *143*
quadriceps femoris muscle, 128–129, *129*
quadriceps reflex, 128

R

radial artery, *23*, 24, 28, 36, *36*
radial bursa, 31
radial collateral ligament, 39, *39*
radial groove, 25
radial nerve, 17, 21, *21*, *25–26*, 28, 36
radial recurrent artery, 28
radiocarpal joint, 40, *40*
radiocarpal ligaments, 39
radioulnar joint
  distal, 27, *27*, 39–40, *40*
  intermediate, 39
  proximal, 27, *27*, 39, *39*
radius, 23, *23*, 27, *27*
rami communicantes, 63, 94
  gray, 63, 109, 120, 192
  white, 63
rectal artery, 85, *85*
  inferior, 99
  middle, 108, 119, *119*
  superior, 85, *85*
rectal examination, 106
rectal folds, transverse, *106*, 107, 117
rectal nerve, inferior, 99, *99*
rectouterine pouch, 113, *113*
rectovesical pouch, 104
rectovesical septum, 105
rectum, 76, *76*, 86, *106*, 106–107, *117*, 117–118
rectus abdominis muscle, 70–71, *71*
rectus capitis anterior muscle, 191, *191*
rectus capitis lateralis muscle, 191, *191*
rectus capitis posterior major muscle, 11–12
rectus femoris muscle, 128, *129*
rectus muscle
  inferior, 173, *173*
  lateral, 172, *172*
  medial, 173, *173*
  superior, 172, *172*
rectus sheath, 70
reflect, defined, 2
renal arteries, 91
renal calculi, 91
renal capsule, 91, *91*
renal cortex, 91, *91*
renal medulla, 91, *91*
renal papillae, 91, *91*
renal pelvis, 91, *91*
renal sinus, 91, *91*
renal vein, 90
retract, defined, 2
retromammary space, 44, *44*
retroperitoneal organs, 74
retroperitoneal space, 89–92, *90*
retropharyngeal space, 190
rhomboid muscles, *8*, 9
ribs, 42, *42*
  false, 42
  floating, 43
  true, 42
rima glottidis, 207
rotator cuff, muscles of, 19
round ligament of the liver, 76
round ligament of the uterus, 66

S

sacral artery, lateral, 108, 119, *119*
sacral canal, 12, *13*
sacral plexus
  female, 119–120, *120*
  male, *108*, 108–109
sacral splanchnic nerves, 109, 120
sacroiliac ligaments, 96, *97*
sacrotuberous ligament, 98
sacrum, 6, *6*, 96, *97*
sagittal sinus
  inferior, *162*, 163
  superior, 159, *160*, *162*, 163
salpingopharyngeus muscle, 200, *200*
saphenous nerve, *123*, 124
saphenous opening, 124, 125, *126*
saphenous vein, great, *123*, 124
scalene muscles, 183, *183*, 191, *192*
scalp, 156–157
  layers of, 156, *156*
  sensory nerves of, *157*
  skin incisions, 156–157, *157*
scalpel, 1, *1*
scaphoid, tubercle of, 30, *30*
scapula, 4, *5*, 17, *17*, 43, *43*
scapular anastomosis, *18*, 19
scapular artery, dorsal, 182–183
scapular region, 17–19
  cutaneous nerves, *16*, 16–17
  fascia of, 15, 17
  skeleton of, 17, *17*
  skin incisions, 15–16, *16*
  superficial veins, 16, *16*
  surface anatomy, 15, *15*
Scarpa's fascia, 65
sciatic foramina, 96, *97*
sciatic nerve, 108, *108*, 120, *120*, 132, *132*, 134, *135*
sciatic notches, 96, *97*
scissors, 1, *1*
scissors technique, 2, *2*
scrotal ligament, 72
scrotal septum, 72
scrotum, 72
secondarily retroperitoneal organs, 74
sellar diaphragm, *167*, 168
semilunar hiatus, 197, *198*
semimembranosus muscle, 134, *135*
seminal vesicle, 105, *105*
seminiferous tubules, 73, *73*
semispinalis muscle, 10, *10*
semitendinosus muscle, 134, *135*
septa, 73, *73*
septal cartilage, 196, *196*
septomarginal trabecula (moderator band), *57*, 58–59
serous pericardium
  parietal layer, 53
  visceral layer, 53
serratus anterior muscle, *21*, 22, *45*, 46
serratus posterior inferior muscle, 9
serratus posterior superior muscle, 9
sesamoid bones, 144, *144*
sharp dissection, 2
shoulder. *see* glenohumeral joint; scapular region
  diaphragmatic pain referred to, 176
sigmoid arteries, 85, *85*
sigmoid colon, 76, *76*, 86
sigmoid mesocolon, 77
sigmoid sinus, *162*, 163
sinoatrial node, 57, *57*
skin, removal of, 3, *3*
skull, 161, *162*
  anterior view, 150, *151*
  interior of, 158–161
  lateral view, 150, *151*, 152
  removal of calvaria, *157*, 158
  removal of occipital bone, 158, *159*
  superior view, 152, *152*
small intestines, 75, *76*, 83–84, *84*
small saphenous vein, 124
soft palate, 198–200, *200*
sole of foot, 142–144, *143*, *144*
soleus muscle, 140, *141*
spermatic cord, *72*, 72–73
sphenoid bone, *165*, 166, 169, 195, *196*, 199, *199*
sphenoidal sinus, 197, *198*
sphenopalatine artery, 196–197, *197*, 201, *201*
sphenopalatine foramen, 201, *201*
sphincter urethrae muscle, 103
spinal cord, 12–14, *13*
spinal ganglion, 14, *14*
spinal meninges, 12–14, *14*
spinal nerves, 12, *13*, 14, *14*
spinalis muscle, 10, *10*
splanchnic nerves, 63, 95
spleen, 75, *75*, *76*, 80, *80*
splenic artery, 80
splenic flexure, 76, *76*
splenic vein, 85, 87
splenius muscle, 10, *10*
spongy urethra, *102*, 102–103
stapes, *209*, 210
sternal angle, plane of, 52
sternoclavicular joint, 37, *37*
sternoclavicular ligament, anterior, 37, *37*
sternohyoid muscle, 177, *177*
sternothyroid muscle, 177, *177*
sternum, 43, *43*
stomach
  internal features of, 88, *88*
  location of, 75, *75*, *76*
  parts of, 77, *78*
straight sinus, *162*, 163
strip a vein, 2
styloglossus muscle, 201, 204, *204*
stylohyoid muscle, 185
stylopharyngeus muscle, 192, *193*, 200, *200*
subarachnoid space, 13, 160
subclavian artery, 20, *20*, *182*, *183*
  first part, 182
  left, 60, *61*
  second part, 182
  third part, 182–183
subclavian vein, 181–182, *182*
subclavius muscle, *45*, 46
subcostal nerve, 66, 93
subdural hematoma, 160
sublingual area, 202–204, *204*
sublingual gland, 203, *204*
submandibular duct, 203, *204*
submandibular ganglion, 204
submandibular gland, 203, *204*
submandibular triangle, *175*, 179–180
submental triangle, *175*, 180
suboccipital nerve, *11*, 12
suboccipital region, skeleton of, 189–190, *190*
suboccipital triangle, 11–12
subpubic angle, 96, *97*
subscapular artery, 20, *20*
subscapular nerves, 21, *21*
subscapularis muscle, *21*, 22
subtalar joint, 148–149, *149*
sulcus, of the heart, 54
superficial perineal pouch
  female, *111*, 111–112, *112*
  male, *100*, 100–101
superior oblique muscle, *172*
superior rectus muscle, *172*
superior thoracic artery, *20*
superior vena cava, *53*, 54, *54*, 60, *60*
supraclavicular nerves, 175, *176*
supraorbital nerve, 155, *156*, 157

suprarenal glands, 91–92, *92*
suprascapular artery, *18*, 19, 182, *183*
suprascapular nerve, *18*, 19
supraspinatus muscle, 18, *18*
sural nerve, 124
suspensory ligaments of breast, 44, *44*
sustentaculum tali, 144
sympathetic trunk, 63, 94, 109, 120
  cervical portion of, 183, 191–192
  sacral portion of, 109

T

talonavicular joint, 148–149, *149*
tarsal artery, lateral, *138*, 139
tarsal bones, 137, *137*
tarsal glands, 170, *170*
tarsal plates, 170, *170*
tectorial membrane, 190, *191*
tegmen tympani, *209*, 210
temporal artery
  deep, 188, *188*
  superficial, 185
temporal bone, *151*, *165*, 166, 184, 208, *208*
temporal fossa, 185, 187
temporal lobe, 164, *164*
temporal region, 185–189
  infratemporal fossa, 187–189, *188*
  removal of zygomatic arch, 186–187, *187*
  skeleton of, 185–186, *186*
  temporal fossa, 187
  temporomandibular joint, 189, *189*
temporal vein, superficial, 185
temporalis muscle, *157*, 158, 187
temporomandibular joint, 189, *189*
teniae coli, 86
tensor of the fascia lata, *132*, 133
tensor veli palatini muscle, 200, *200*
tentorial notch, 163
teres major muscle, 18, *18*
teres minor muscle, 18, *18*
testicular arteries, 73, 90
testicular varicocele, 90
testicular vein, 90
thenar muscles, 30, 33
thigh
  anterior compartment, 124–129
    adductor canal, 128
    femoral triangle, *126*, 126–128
    quadriceps femoris muscle, 128–129, *129*
    saphenous opening, 125, *126*
  compartments of, 125, *126*, *128*
  deep artery of the, 127, *127*, 129
  medial compartment, 129–130, *130*
  motor nerve territories of, 136, *136*
  popliteal fossa, 134–135, *135*
  posterior compartment, 133–136, *135*
  skeleton of, 125, *126*
  transverse section, *128*
thoracic aorta, *62*, 62–63
thoracic aperture
  inferior (thoracic outlet), 48
  superior (thoracic inlet), 48
thoracic arteries, 20, *20*, 48
  internal, 48, *48*, 182, *182*
  lateral, 20, *20*, 46, *46*
  superior, 20, *20*
thoracic duct, 62, *62*, 183, *183*
thoracic nerve, long, 22
  injury to, 22
thoracic vertebra, 4–5, *5*, 42, *43*
thoracic wall, removal of the anterior, 47–48, *48*
thoraco-acromial artery, 20, *20*, 45–46
thoracoabdominal nerves, 66
thoracoappendicular group of muscles, anterior, *45*, 45–46
thoracocentesis, 47, *47*
thoracodorsalis nerve, injury to, 22
thorax
  heart, 52–53, *53*
  intercostal space and muscles, 46–47, *47*
  lungs, *50*, 50–51, *51*
  mediastinum, 52, *52*
    middle, 52–54, *53*, *54*
    posterior, 61–63, *62*
    superior, 59–61, *60*, *61*
  pectoral region, 43–46
  pleural cavities, 48–49, *49*
  removal of the anterior thoracic wall, 47–48, *48*
  skeleton of, 42–43, *43*
  surface anatomy, 42, *42*
thymus, 60
thyroarytenoid muscle, 206, *206*
thyrocervical trunk, 182, *182*
thyrohyoid membrane, 178, 205, *205*
thyrohyoid muscle, 177, *177*
thyroid artery
  inferior, 182, *183*
  superior, 179, *179*, 180
thyroid cartilage, 205, *205*
thyroid gland, 180–181, *181*
thyroid veins, 180
tibia, 125, *126*, 134, 136, *137*
tibial arteries, *141*
  anterior, 138, *138*, 140
  posterior, 140
tibial collateral ligament, 146, *147*
tibial nerve, 134, *135*, 140, *141*
tibialis anterior muscle, 138, *138*
tibialis posterior muscle, 140, *141*
tibialis posterior tendon, 144
tongue, 202, *203*
  body of, 203
  dorsum of, 203, *203*
  intrinsic muscles of, 204, *204*
tonsillar bed, *199*, 201
torus tubarius, 194, *194*
trabeculae carneae, *57*, 58–59
trachea, bifurcation of, 61, *61*
tracheal rings, 61, *61*
tracheobronchial lymph nodes, 61
tracheotomy, 177
transversalis fascia, 71, *71*
transverse colon, 76, *76*, 86, 89
transverse intermuscular septum, 140
transverse mesocolon, 77
transverse pericardial sinus, 53, *54*
transverse perineal muscle
  female
    deep, 112, *112*
    superficial, 111, *112*
  male
    deep, 103, *103*
    superficial, 100, *101*
transverse process, 5, *5*
transverse scapular ligament, *18*, 19
transverse sinuses, 159, *160*, *162*, 163
transverse tarsal joint, 148–149, *149*
transversospinal group of muscles, 10–11
transversus abdominis muscle, *69*, 93, *93*
transversus thoracis muscle, 48
trapezium, tubercle of, 30, *30*
trapezius muscle, 7, 7–8, *8*, 18
triangle of auscultation, 9
triangular ligaments, 76
triceps brachii muscle, 18, *18*, 25, *26*
tricuspid valve, *57*, 57–58
trigeminal ganglion, 167
trigeminal nerve, 155, *165*, 167, *167*
trigone
  female, 116, *117*
  male, 106
trochlear nerve, *165*, 166, *167*, 171, *171*
tunica albuginea, 73, *73*
tunica vaginalis, 73, *73*
tympanic cavity, 208–210, *209*
tympanic membrane, 208, *209*, 210

U

ulna, 27, *27*
ulnar artery, *23*, 24, 28–29, 31, 34
ulnar bursa, 31
ulnar collateral arteries, *23*, 24
ulnar collateral ligament, 39, *39*
ulnar nerve, 17, 21, *21*, *23*, 24, 29, 31, 34
ulnar recurrent arteries, 29
umbilical artery, 108, 118, *119*
umbilical folds, 74
upper limb
  arm, *22*, 22–26, *23*
  axilla, *19*, 19–22
  forearm, *26*, 26–30, *27*
    extensor region of, 35–36, *36*
    flexor region of, 26–30
  hand
    dorsum of, 35–36, *36*
    palm of, 30–35
  joints of, 37–41
    acromioclavicular, 37, *38*
    elbow, 39, *39*
    glenohumeral, 37–38, *38*
    interphalangeal, *40*, 41
    metacarpophalangeal, 40, *40*
    sternoclavicular, 37, *37*
    wrist, 40, *40*
  scapular region, 17–19
    cutaneous nerves, *16*, 16–17
    deep fascia of, 17
    fascia of, 15
    skin incisions, 15–16, *16*
    superficial veins, 16, *16*
    surface anatomy, 15, *15*
ureter, 91, *91*
urethra
  female, 113, *117*
  male, *102*, 102–103
    injury to, 100, *100*
    interior of the prostatic, 104, *105*
    membranous, *103*, 103–104, *104*
    parts of, 104, *105*
urethral orifice, external, 102
urethral sphincter muscle, external, 103–104, *104*, *112*, 113
urinary bladder
  female, *116*, 116–117, *117*
  male, 105–106, *106*
urogenital diaphragm, 103
urogenital hiatus, 109, 120
urogenital triangle, 97–98
  female, *97*, 110–113
    clitoris, 112, *112*
    deep perineal pouch, *112*, 112–113
    external genitalia, 110, *111*
    skin removal, 110–111, *111*
    superficial perineal pouch, *111*, 111–112, *112*
  male, *97*, 99–103
    deep perineal pouch, 103, *103*
    penis, 101–102, *102*
    skin removal, 99–100
    spongy urethra, *102*, 102–103
    superficial perineal pouch, *100*, 100–101
uterine artery, 118, *119*
uterine cavity, *115*, 116

uterine tube, 114, *114*, *115*, 116
uterosacral ligament, 114, *114*
uterus, *115*, 115–116
  broad ligament of, 114
  round ligament of, 114

V

vagal trunk, 62
vagina, 115, *115*
vaginal artery, 119, *119*
vaginal fornix, 115, *115*
vagus nerve, 50, *165*, *167*, 168, 179, *179*, 183, *183*
  left, 53, *53*, 60, *61*, 62, *62*
  pharyngeal branch, *193*, 194
  right, 62, *62*
vas deferens, 72
vasa recta, 83, *83*
vasectomy, 73
vastus intermedius muscle, 129, *129*
vastus lateralis muscle, 128–129, *129*
vastus medialis muscle, 129, *129*
vein, strip a, 2
vena cava
  inferior, 81, *81*, 92, *92*
  superior, *53*, 54, *54*, 60, *60*
vena caval foramen, *94*, 95
venous plexus, 119
ventral primary ramus of a spinal nerve, 14
ventricle
  left, 58–59, *59*
  right, *57*, 57–58
vertebra
  C1, 5, 11, *11*, 189–190, *190*, *191*
  C2, 5, 11, *11*, 189, *190*
  cervical, 5–6, *6*
  laminae of, 12, *13*
  lumbar, 6, *6*
  thoracic, 4–5, *5*, 42, *43*
vertebra prominens, 5
vertebral arteries, *11*, 12, 164, *165*, 182, *182*
vertebral column, 4, *5*, 12–14, *13*
vertebral venous plexuses, 12
vesical artery, inferior, 108
vesicouterine pouch, 113, *113*
vestibular fold, 207, *207*
vestibulocochlear nerve, *165*, *167*, 168, 209, *209*
visceral peritoneum, 74
visceral pleura, 49, *49*
vocal fold, 207, *207*
vocal ligaments, 205, *205*
vocal process, 205, *205*
vocalis muscle, 207
vulva, 110, *111*

W

wrist
  anterior aspect of, *28*
  bones of, *30*
  joint of, 40, *40*

Z

zygomatic arch, 186
  removal of, 186–187, *187*
zygomatic bone, *151*
zygomaticus major muscle, 155, *155*