Radovan Hudák, David Kachlík
Ondřej Volný et al.

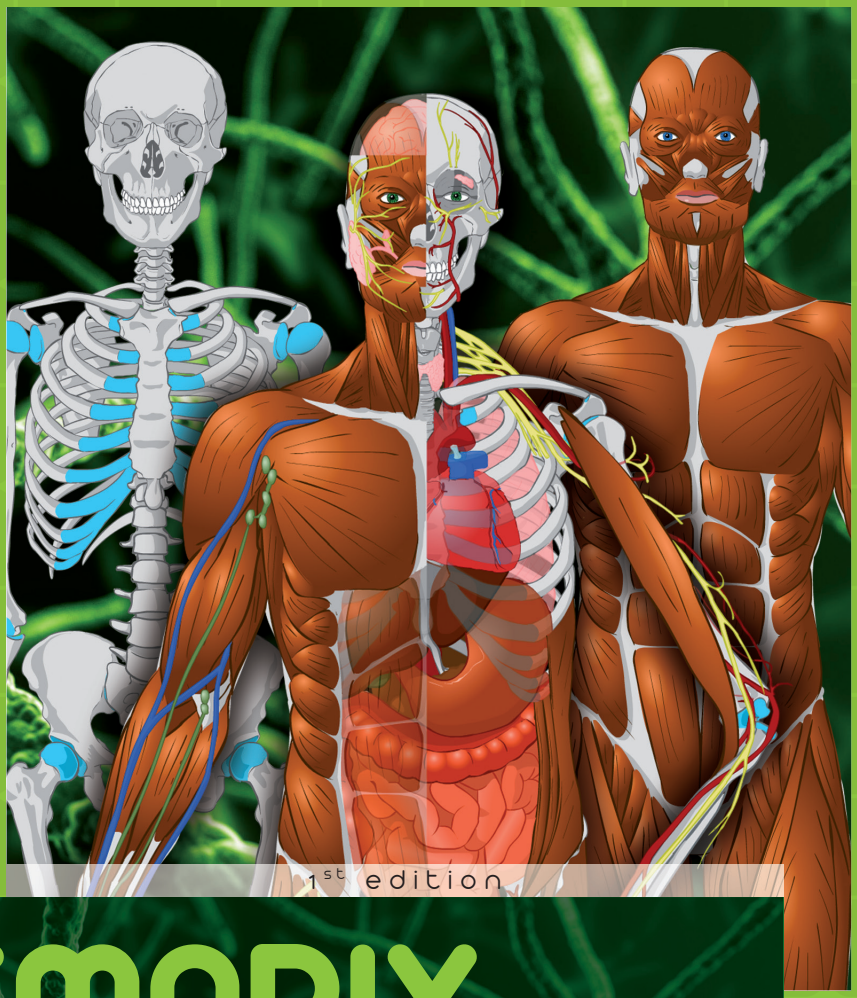

1st edition

MEMORIX ANATOMY

Entire human anatomy in English and Latin

MEMORIX

This copy belongs to anyone

Be an Anatomist from the heart

Book contents:

1. General anatomy 1
2. Bones 17
3. Joints 67
4. Muscles 97
5. Digestive system 169
6. Respiratory system 205
7. Urinary system 225
8. Genital system 237
9. Heart and blood vessels 263
10. Lymphatic and immune systems 317
11. Peripheral nervous system 335
12. Central nervous system 389
13. Senses and skin 501
14. Endocrine system 521
15. Topography 529

Practice anatomy with personalized questions.
Free web app – www.PracticeAnatomy.com

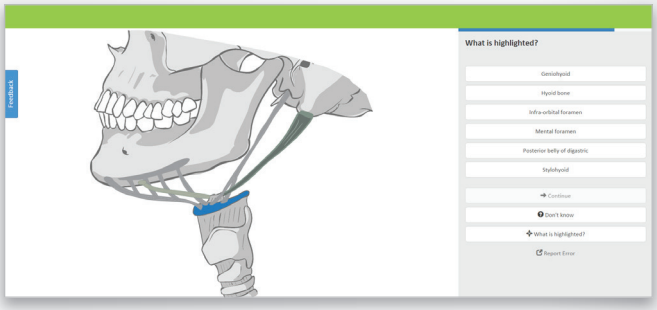

Anatomy terms in free online dictionary
www.AnatomicalTerms.co.uk

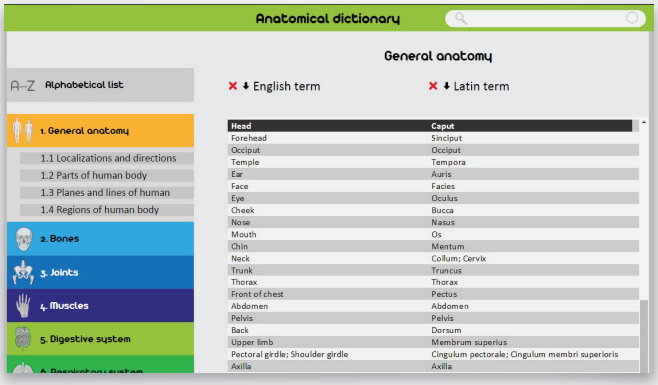

Practice anatomy anywhere and anytime
Mobile app coming soon



More information at
www.memorix.co.uk

Radovan Hudák
David Kachlík
Ondřej Volný
et al.

MEMORIX ANATOMY

Comprehensive Book of Human Anatomy in English and Latin

1st edition, E-book version

MEMORIX

This copy belongs to ali yaghoubi

Radovan Hudák, David Kachlík, Ondřej Volný
MEMORIX ANATOMY

Editors' and Publisher's Disclaimer
The editors, co-authors, and publisher paid the maximum possible attention so that the information herein reflect the current state of knowledge at the time of preparation of this work for publication. Although this information has been carefully reviewed, it is not possible to guarantee its complete flawlessness with absolute certainty. For these reasons, any claims to compensation, whether for direct or indirect damages, are excluded.

This E-book or any part thereof may not be copied, reproduced, or otherwise distributed without the written permission of the publisher.

Order ID: #201730009

ali yaghoubi
rigo utca 21
6724 szeged
HU

Copyright owner and publisher of the E-book:
MEMORIX s.r.o.,
Plzeňská 1270/97, 150 00 Praha 5, Czech Republic
www.memorix.cz
Published: 2015
Last edit: 23. 10. 2016

© MEMORIX, 2015
© Radovan Hudák, David Kachlík, Ondřej Volný, 2015

Illustrations: Jan Balko, Simona Felšőová, Šárka Zavázalová, Radovan Hudák
Typesetting: Radovan Hudák, Matej Halaj, Vojtěch Kunc
Chiefs of copy editing and proofreading: Petr Vaněk, Adam Whitley
Copy editing and proofreading: Zuzana Balážová, Pavel Filip, Michal Vilímovský
Design: Radovan Hudák, Karel Novotný
Cover: Jan Balko, Karel Novotný, Radovan Hudák, Renata Brtnická

ISBN: 978-80-906331-0-0

Editors

Radovan Hudák, MD
Assistant Professor, Department of Anatomy
Second Faculty of Medicine, Charles University, Prague, Czech Republic

David Kachlík, MD, PhD
Professor, Department of Anatomy
Second Faculty of Medicine, Charles University, Prague, Czech Republic

Ondřej Volný, MD
Assistant Professor, First Department of Neurology
St. Anne' Faculty Hospital and Faculty of Medicine, Masaryk University, Brno, Czech Republic
Assistant Professor, Department of Anatomy,
Faculty of Medicine, Masaryk University, Brno, Czech Republic

Co-authors

Barbora Beňová, MD
Clinician, Department of Paediatric Neurology,
Second Faculty of Medicine, Charles University and Motol University Hospital, Prague, Czech Republic

Martin Čepelík, MD
Clinician and Assistant Professor, Department of Pediatric Trauma and Surgery,
Third Faculty of Medicine, Charles University and Thomayer Hospital, Prague, Czech Republic

Ladislav Douda, MD
Clinician, Department of Internal Medicine,
Second Faculty of Medicine, Charles University and Motol University Hospital, Prague, Czech Republic

Matej Halaj, MD
Clinician, Department of Neurosurgery,
Faculty of Medicine and University Hospital, Olomouc, Czech Republic

Vojtěch Kunc
Student,
Second Faculty of Medicine, Charles University, Prague, Czech Republic

Jakub Miletín, MD
Clinician, Department of Plastic Surgery,
Assistant Professor, Department of Anatomy
Third Faculty of Medicine and University Hospital Královské Vinohrady, Prague, Czech Republic

Petr Vaněk
Clinician, Department of Radiology
University Hospital Brno, Brno, Czech Republic

Adam Whitley
Clinician, Department of Surgery,
Third Faculty of Medicine and University Hospital Královské Vinohrady, Prague, Czech Republic
Postgraduate student, Department of Anatomy,
Second Faculty of Medicine, Charles University, Prague, Czech Republic

Illustrators

Jan Balko, MD
Clinician, Department of Patology and Molecular Medicine,
Second Faculty of Medicine, Charles University and Motol University Hospital, Prague, Czech Republic

Simona Felšőová
Clinician, Department of Dermatovenerology,
Teplice Hospital, Czech Republic

Šárka Zavázalová, MD
Clinician, Department of Otorhinolaryngology,
Third Faculty of Medicine, Charles University and Central Military Hospital, Prague, Czech Republic

This copy belongs to ali yaghoubi

Contents

Foreword or Why is Memorix Anatomy revolutionary? XII
Memorix Education System XV
Acknowledgements to co-workers XVI
Acknowledgements to student organisations XVIII
Memorix team XX

1 General anatomy 1

1 **Definitions and history** 2
2 **Terms and abbreviations** 3
3 **Histology** 4
4 **Embryology** 5
5 **Anatomical changes in childhood** 6
6 **Anatomical changes in puberty** 7
7 **Planes and lines of the human body** 8
8 **Terms of location and direction of the human body** 9
9 **Parts of the human body** 10
10 **Regions of the human body** 11
11 **Eponyms** 12
12 **Review questions and figures** 14
13 **Acknowledgements and references** 16

2 Bones 17

1 **General overview** 18
2 **Skull** – Cranium 21
2.1 **Frontal bone** – Os frontale 22
2.2 **Occipital bone** – Os occipitale 23
2.3 **Sphenoidal bone (sphenoid)** – Os sphenoidale 24
2.4 **Parietal bone** – Os parietale 26
2.5 **Temporal bone** – Os temporale 27
2.6 **Ethmoidal bone (ethmoid)** – Os ethmoidale 30
2.7 **Inferior nasal concha** – Concha nasalis inferior 30
2.8 **Lacrimal bone, nasal bone and vomer** – Os lacrimale, os nasale et vomer 31
2.9 **Zygomatic bone** – Os zygomaticum 31
2.10 **Palatine bone** – Os palatinum 32
2.11 **Maxilla** – Maxilla 33
2.12 **Mandible** – Mandibula 34
2.13 **Hyoid bone** – Os hyoideum 35
2.14 **Skull of a newborn** 35
2.15 **Skull anthropometry** 36
3 **Vertebral column** – Columna vertebralis 37
3.1 **Cervical vertebrae** – Vertebrae cervicales 38
3.2 **Thoracic vertebrae** – Vertebrae thoracicae 39
3.3 **Lumbar vertebrae** – Vertebrae lumbales 39
3.4 **Sacrum and coccyx** – Os sacrum et os coccygis 40
4 **Thorax** – Thorax 41
5 **Bones of the upper limb** – Ossa membri superioris 42
5.1 **Clavicle (collarbone)** – Clavicula 42
5.2 **Scapula (shoulder blade)** – Scapula 43
5.3 **Humerus** – Humerus 44
5.4 **Ulna (elbow bone)** – Ulna 45
5.5 **Radius (radial bone)** – Radius 46
5.6 **Bones of the hand** – Ossa manus 47
6 **Bones of the lower limb** – Ossa membri inferioris 48
6.1 **Pelvis** – Pelvis 49
6.1.1 **Hip bone (pelvic bone)** – Os coxae 50
6.2 **Femur (thigh bone)** – Femur 52
6.3 **Patella (kneecap)** – Patella 53
6.4 **Tibia (shinbone)** – Tibia 53
6.5 **Fibula (calf bone)** – Fibula 54
6.6 **Bones of foot** – Ossa pedis 54
7 **Figures** 57
7.1 **Cranial base** 57
8 **Tables** 58
8.1 **Openings of the skull and their content** 58
8.2 **Structures of the upper limb** 60
8.3 **Structures of the lower limb** 62
9 **Review questions and figures** 64
10 **Acknowledgements and references** 66

3 Joints 67

1 **General overview** 68
1.1 **General organisation of the synovial joint** 69
2 **Joints of the skull** – Juncturae cranii 72
3 **Vertebral joints** – Juncturae columnae vertebralis 73
3.1 **Vertebral synovial joints** – Articulationes columnae vertebralis 74
4 **Thoracic joints** – Juncturae thoracis 75
5 **Joints of the upper limb** – Juncturae membri superioris 76
5.1 **Sternoclavicular joint** – Articulatio sternoclavicularis 76
5.2 **Acromioclavicular joint** – Articulatio acromioclavicularis 76
5.3 **Shoulder (glenohumeral) joint** – Articulatio humeri (glenohumeralis) 77
5.4 **Elbow joint** – Articulatio cubiti 78
5.5 **Distal radio-ulnar joint and radio-ulnar syndesmosis** – Articulatio radioulnaris distalis et syndesmosis radioulnaris 79
5.6 **Wrist joint** – Articulatio radiocarpalis 79
5.7 **Joints of the hand** – Articulationes manus 80
6 **Joints of the lower limb** – Juncturae membri inferioris 82
6.1 **Sacro-iliac joint** – Articulatio sacroiliaca 82
6.2 **Synarthroses of the pelvic girdle** – Synarthroses cinguli pelvici 82
6.3 **Hip joint** – Articulatio coxae 83
6.4 **Knee joint** – Articulatio genus 84
6.5 **Tibiofibular joint** – Articulatio tibiofibularis 86
6.6 **Interosseous membrane of the leg and tibiofibular syndesmosis** – Membrana interossea cruris et syndesmosis tibiofibularis 86
6.7 **Joints of the foot** – Articulationes pedis 86
6.7.1 **Arches of the foot** 86
7 **Tables** 90
7.1 **Movements of the head, neck and temporomandibular joint** (muscles) 90
7.2 **Movements of the limbs** (degree of freedom) 91
7.3 **Movements of the upper limb** (muscles) 92
7.4 **Movements of the lower limb** (muscles) 93
8 **Review questions and figures** 94
9 **Acknowledgements and references** 96

4 Muscles 97

1 **General overview** ... 98
2 **Muscles of the head** – Musculi cranii ... 102
2.1 **Facial muscles** – Musculi faciei ... 102
2.2 **Masticatory muscles** – Musculi masticatorii ... 108
2.3 **Fasciae of the head** ... 109
3 **Muscles of the neck** – Musculi colli ... 110
3.1 **Superficial muscle group** – Musculi colli superficiales ... 111
3.2 **Suprahyoid muscles** – Musculi suprahyoidei ... 112
3.3 **Infrahyoid muscles** – Musculi infrahyoidei ... 113
3.4 **Scaleni** – Musculi scaleni ... 114
3.5 **Deep muscle group** – Musculi colli profundi ... 115
3.6 **Cervical fascia** – Fascia cervicalis ... 115
4 **Muscles of the back** – Musculi dorsi ... 116
4.1 **Superficial layer (spinohumeral muscles)** ... 117
4.2 **2nd layer (spinoscapular muscles)** ... 118
4.3 **3rd layer (spinocostal muscles)** ... 118
4.4 **Muscles of the back proper** – Musculi dorsi proprii ... 119
4.5 **Fasciae of the back** ... 123
5 **Muscles of the thorax** – Musculi thoracis ... 124
5.1 **Muscles of the thorax – thoracohumeral muscles** ... 125
5.2 **Muscles of the thorax proper** ... 126
5.3 **Diaphragm** – Diaphragma ... 127
5.4 **Fasciae of the thorax** ... 127
6 **Muscles of the abdomen** – Musculi abdominis ... 128
6.1 **Anterior group** ... 128
6.2 **Lateral group** ... 129
6.3 **Posterior group** ... 130
6.4 **Fasciae of the abdomen** ... 130
7 **Pelvic diaphragm / pelvic floor** – Diaphragma pelvis ... 131
7.1 **Fasciae of the pelvis** ... 132
8 **Muscles of the upper limb** – Musculi membri superioris ... 133
8.1 **Muscles of the shoulder joint** ... 133
8.2 **Muscles of the arm** – Musculi brachii ... 134
8.3 **Muscles of the forearm** – Musculi antebrachii ... 136
8.3.1 **Anterior group** ... 137
8.3.2 **Lateral group** ... 139
8.3.3 **Posterior group** ... 140
8.4 **Muscles of the hand** – Musculi manus ... 142
8.4.1 **Muscles of the thenar eminence (thumb group)** ... 143
8.4.2 **Muscles of the hypothenar eminence (little finger group)** ... 144
8.4.3 **Interossei and lumbricals** ... 145
8.5 **Tendinous sheaths of the upper limb** – Vaginae tendinum membri superioris ... 146
8.6 **Fasciae of the upper limb** ... 147
9 **Muscles of the lower limb** – Musculi membri inferioris ... 148
9.1 **Muscles of the hip joint** ... 148
9.1.1 **Anterior group** ... 149
9.1.2 **Posterior group** ... 150
9.2 **Muscles of the thigh** – Musculi femoris ... 152
9.2.1 **Anterior group** ... 153
9.2.2 **Medial group** ... 154
9.2.3 **Posterior group** ... 155
9.3 **Muscles of the leg** – Musculi cruris ... 156
9.3.1 **Anterior group** ... 157
9.3.2 **Lateral group** ... 157
9.3.3 **Posterior group** ... 158
9.4 **Muscles of the foot** – Musculi pedis ... 160
9.4.1 **Dorsal group** ... 161
9.4.2 **Medial group (group of the great toe)** ... 161
9.4.3 **Lateral group (group of the little toe)** ... 162
9.4.4 **Middle group** ... 162
9.4.5 **Interossei and lumbricals** ... 163
9.5 **Tendinous sheaths of the lower limb** – Vaginae tendinum membri inferioris ... 164
9.6 **Fasciae of the lower limb** ... 165
10 **Review questions and figures** ... 166
11 **Acknowledgements and references** ... 168

5 Digestive system 169

1 **General overview** ... 170
2 **Oral cavity** – Cavitas oris ... 172
2.1 **Cheek** – Bucca ... 172
2.2 **Lips** – Labia oris ... 173
2.3 **Gum** – Gingiva ... 173
2.4 **Teeth** – Dentes ... 174
2.5 **Tongue** – Lingua ... 176
2.6 **Palate** – Palatum ... 178
2.6.1 **Hard palate** – Palatum durum ... 178
2.6.2 **Soft palate** – Palatum molle ... 179
2.7 **Palatine tonsil** – Tonsilla palatina ... 178
2.8 **Salivary glands** – Glandulae salivariae ... 180
3 **Pharynx** – Pharynx ... 182
4 **Oesophagus** – Oesophagus ... 185
5 **Stomach** – Gaster ... 186
6 **Small intestine** – Intestinum tenue ... 188
6.1 **Duodenum** – Duodenum ... 188
6.2 **Jejunum and ileum** – Jejunum et ileum ... 190
7 **Large intestine** – Intestinum crassum ... 191
7.1 **Caecum** – Caecum ... 192
7.1.1 **Vermiform appendix** – Appendix vermiformis ... 193
7.2 **Colon** – Colon ... 193
7.2.1 **Ascending colon** – Colon ascendens ... 193
7.2.2 **Transverse colon** – Colon transversum ... 194
7.2.3 **Descending and sigmoid colon** – Colon descendens et sigmoideum ... 194
7.3 **Rectum** – Rectum ... 195
8 **Liver** – Hepar ... 196
9 **Gallbladder** – Vesica biliaris/fellea ... 199
10 **Pancreas** – Pancreas ... 200
11 **Peritoneum** – Peritoneum ... 201
12 **Review questions and figures** ... 202
13 **Acknowledgements and references** ... 204

6 Respiratory system 205

1 **General overview** ... 206
2 **Nose** – Nasus ... 206
3 **Nasal cavity** – Cavitas nasi ... 207
4 **Paranasal sinuses** – Sinus paranasales ... 208
5 **Pharynx** – Pharynx ... 209
6 **Larynx** – Larynx ... 210
7 **Trachea** – Trachea ... 214
8 **Bronchi** – Bronchi ... 215
9 **Lungs** – Pulmones ... 216
10 **Pleura** – Pleura ... 220
11 **Mechanics of breathing movements** ... 221
12 **Tables – Laryngeal muscles by function** ... 222
13 **Review questions and figures** ... 222
14 **Acknowledgements and references** ... 224

This copy belongs to ali yaghoubi

7 Urinary system 225

1 **General overview** ... 226
2 **Kidneys** – Renes ... 227
3 **Renal pelvis and renal calices** – Pelvis renalis et calices renales ... 230
4 **Ureter** – Ureter ... 230
5 **Urinary bladder** – Vesica urinaria ... 231
6 **Female urethra** – Urethra feminina ... 233
7 **Dynamics of micturition** ... 233
8 **Review questions and figures** ... 234
9 **Acknowledgements and references** ... 236

8 Genital system 237

1 **Development of the genital system** ... 238
2 **Male genital system** – Organa genitalia masculina ... 239
2.1 **Testis** – Testis ... 240
2.2 **Epididymis** – Epididymis ... 242
2.3 **Ductus deferens** – Ductus deferens ... 243
2.4 **Spermatic cord** – Funiculus spermaticus ... 243
2.5 **Seminal glands** – Glandulae vesiculosae ... 244
2.6 **Bulbo-urethral glands** – Glandulae bulbourethrales ... 244
2.7 **Prostate** – Prostata ... 245
2.8 **Scrotum** – Scrotum ... 246
2.9 **Penis** – Penis ... 247
2.10 **Male urethra** – Urethra masculina ... 248
3 **Female genital system** – Organa genitalia feminina ... 249
3.1 **Ovary** – Ovarium ... 250
3.2 **Uterine/Fallopian tube** – Tuba uterina Falloppii ... 251
3.3 **Uterus** – Uterus ... 252
3.4 **Vagina** – Vagina ... 254
3.5 **Female external genitalia (vulva)** – Organa genitalia feminina externa (vulva) ... 255
4 **Perineum and its muscles** – Perineum et musculi perinei ... 256
5 **Anatomy in pregnancy** ... 257
6 **Fetal membranes, placenta and umbilical cord** ... 258
7 **Fetal anatomy and anatomy of labour** ... 259
8 **Review questions and figures** ... 260
9 **Acknowledgements and references** ... 262

9 Heart and blood vessels 263

1 **General overview of the blood vessels** ... 264
2 **General overview of the heart** ... 265
3 **Heart** – Cor ... 266
3.1 **Right atrium** – Atrium dextrum ... 268
3.2 **Right ventricle** – Ventriculus dexter ... 269
3.3 **Left atrium** – Atrium sinistrum ... 270
3.4 **Left ventricle** – Ventriculus sinister ... 271
3.5 **Valves** – Valvae ... 272
3.6 **Cardiac skeleton** – Skeleton cordis ... 273
3.7 **Conducting system of the heart** – Complexus stimulans cordis ... 273
3.8 **Fetal circulation** ... 274
3.9 **Coronary arteries** – Arteriae coronariae ... 275
3.10 **Veins of the heart** – Venae cordis ... 275
3.11 **Clinical anatomy of the heart** ... 276
4 **Arteries** – Arteriae ... 277
4.1 **Aorta** – Aorta ... 277
4.2 **Ascending aorta and aortic arch** – Aorta ascendens et arcus aortae ... 277
4.3 **Common carotid artery** – Arteria carotis communis ... 278
4.4 **External carotid artery** – Arteria carotis externa ... 278
4.4.1 **External carotid artery – ventral and medial branches** ... 279
4.4.2 **External carotid artery – dorsal branches** ... 280
4.4.3 **Superficial temporal artery** – Arteria temporalis superficialis ... 280
4.4.4 **Maxillary artery** – Arteria maxillaris ... 281
4.5 **Subclavian artery** – Arteria subclavia ... 282
4.5.1 **Vertebral artery** – Arteria vertebralis ... 282
4.5.2 **Subclavian artery – other branches** ... 283
4.6 **Axillary artery** – Arteria axillaris ... 284
4.7 **Brachial artery** – Arteria brachialis ... 284
4.8 **Radial and ulnar arteries and superficial and deep palmar arches** – Arteria radialis et ulnaris, arcus palmaris superficialis et profundus ... 285
4.9 **Thoracic aorta** – Aorta thoracica ... 286
4.10 **Abdominal aorta** – Aorta abdominalis ... 287
4.10.1 **Coeliac trunk** – Truncus coeliacus ... 288
4.10.2 **Inferior and superior mesenteric artery** – Arteria mesenterica superior et inferior ... 289
4.11 **Common iliac artery** – Arteria iliaca communis ... 290
4.11.1 **Internal iliac artery (parietal branches)** – Arteria iliaca interna ... 290
4.11.2 **Internal iliac artery (visceral branches)** – Arteria iliaca interna ... 291
4.11.3 **External iliac artery** – Arteria iliaca externa ... 291
4.12 **Femoral and popliteal artery** – Arteria fermoralis et arteria poplitea ... 292
4.13 **Anterior and posterior tibial arteries** – Arteria tibialis anterior et posterior ... 293
5 **Veins** – Venae ... 294
5.1 **Superior vena cava** – Vena cava superior ... 294
5.2 **Internal jugular vein** – Vena jugularis interna ... 295
5.3 **External jugular vein** – Vena jugularis externa ... 296
5.4 **Subclavian and axillary veins** – Vena subclavia et vena axillaris ... 296
5.5 **Veins of the upper limb** – Venae membri superioris ... 297
5.6 **Inferior vena cava** – Vena cava inferior ... 297
5.7 **Portal vein** – Vena portae ... 298
5.8 **Porto-caval anastomoses** ... 299
5.9 **Cavo-caval anastomoses** ... 299
5.10 **Common iliac vein** – Vena iliaca communis ... 300
5.10.1 **Internal iliac vein** – Vena iliaca interna ... 300
5.10.2 **External iliac vein** – Vena iliaca externa ... 301
5.11 **Veins of the lower limb** – Venae membri inferioris ... 301
6 **Schemes** ... 302
6.1 **Schemes of the heart** ... 302
6.2 **Schemes of arteries** ... 304
6.3 **Schemes of veins** ... 310
7 **Tables**
7.1 **Tables of perforators** – Venae perforantes ... 311
8 **Review questions and figures** ... 314
9 **Acknowledgements and references** ... 316

10 Lymphatic and immune systems 317

1 **General overview** ... 318
2 **Lymphatic vessels** – Vasa lymphoidea ... 319
3 **Thymus** – Thymus ... 320
4 **Bone marrow** – Medulla ossium ... 320
5 **Spleen – Splen** (lien) ... 321
6 **Tonsils** – Tonsillae ... 322
7 **Non-encapsulated lymphoid tissue** ... 323
8 **Lymph nodes** – Nodi lymphoidei (nodi lymphatici, lymphonodi) ... 323
8.1 **Lymph nodes of the head** – Nodi lymphoidei capitis ... 324
8.2 **Lymph nodes of the neck** – Nodi lymphoidei colli ... 324
8.3 **Lymph nodes of the upper limb** – Nodi lymphoidei membri superioris ... 325
8.4 **Thoracic lymph nodes** – Nodi lymphoidei thoracis ... 326
8.5 **Abdominal lymph nodes** – Nodi lymphoidei abdominis ... 327
8.6 **Pelvic lymph nodes** – Nodi lymphoidei pelvis ... 328
8.7 **Lymph nodes of the lower limb** – Nodi lymphoidei membri inferioris ... 328
8.8 **Sentinel lymph nodes of the respiratory and digestive system** ... 329
8.9 **Sentinel lymph nodes of the urinary and genital system** ... 330
9 **Schemes** ... 331
9.1 **Lymphatic drainage of the abdomen and pelvis** (lymph nodes) ... 331
9.2 **Lymphatic drainage of the abdomen and pelvis** (lymphatic trunks) ... 331
10 **Review questions and figures** ... 332
11 **Acknowledgements and references** ... 334

11 Peripheral nervous system 335

1 **General overview** ... 336
1.1 **General structure of the spinal nerve** ... 337
1.2 **Reflex arch** ... 338
2 **Spinal nerves** – Nervi spinales ... 339
2.1 **Cervical plexus** – Plexus cervicalis (C1–C4) ... 340
2.2 **Brachial plexus** – Plexus brachialis (C4–T1) ... 342
2.2.1 **Supraclavicular part of the brachial plexus** ... 342
2.2.2 **Infraclavicular part of the brachial plexus** ... 343
2.3 **Thoracic nerves** – Nervi thoracici (T1–T12) ... 346
2.4 **Lumbar plexus** – Plexus lumbalis (T12–L4) ... 346
2.5 **Sacral plexus** – Plexus sacralis (L4–S4) ... 348
2.6 **Dermatomes and myotomes** ... 350
2.7 **Peripheral nerve fields** – Areae nervinae ... 351
3 **Cranial nerves** – Nervi craniales ... 352
3.1 N. I **Olfactory nerve** – Nervus olfactorius ... 354
3.2 N. II **Optic nerve** – Nervus opticus ... 354
3.3 N. III **Oculomotor nerve** – Nervus oculomotorius ... 355
3.4 N. IV **Trochlear nerve** – Nervus trochlearis ... 355
3.5 N. V **Trigeminal nerve** – Nervus trigeminus ... 356
3.6 N. VI **Abducent / Abducens nerve** – Nervus abducens ... 360
3.7 N. VII **Facial nerve** – Nervus facialis ... 360
3.8 N. VIII **Vestibulocochlear nerve** – Nervus vestibulocochlearis ... 362
3.9 N. IX **Glossopharyngeal nerve** – Nervus glossopharyngeus ... 363
3.10 N. X **Vagus nerve** – Nervus vagus ... 364
3.11 N. XI **Accessory nerve** – Nervus accessorius ... 366
3.12 N. XII **Hypoglossal nerve** – Nervus hypoglossus ... 366
4 **Autonomic nervous system (ANS)** ... 367
4.1 **Sympathetic part** – Pars sympathica ... 368
4.2 **Parasympathetic part** – Pars parasympathica ... 371
4.3 **Mixed autonomic plexuses** ... 372
4.4 **Enteric nervous system** ... 374
5 **Schemes** ... 375
5.1 **Scheme of the peripheral nervous system** ... 375
5.2 **Cervical plexus** ... 375
5.3 **Brachial plexus** ... 376
5.4 **Brachial plexus – final branches** ... 376
5.5 **Lumbar and sacral plexus** ... 378
5.6 **Sacral plexus – branches** ... 379
5.7 **N. I, II, III, IV, VI** ... 380
5.8 **N. V** ... 381
5.9 **N. VII, VIII, IX** ... 382
5.10 **N. X, XI, XII** ... 383
5.11 **Parasympathetic and sympathetic innervation of the head** ... 384
6 **Review questions and figures** ... 385
7 **Acknowledgements and references** ... 388

This copy belongs to ali yaghoubi

12 Central nervous system 389

1 **General overview** ... 390
1.1 **Microscopic structure – neurons** ... 390
1.2 **Microscopic structure – neuroglia** ... 391
1.3 **Distribution of white and grey matter** ... 391
1.4 **Nervous system development** ... 392
1.5 **Brain development** ... 393
1.6 **Nervous tracts** – Tractus nervosi ... 394
1.7 **Directions, planes and special terms of the CNS** ... 395
1.8 **Function of the CNS** ... 396
2 **Spinal cord** – Medulla spinalis ... 398
2.1 **Spinal cord – white and grey matter** ... 400
3 **Brainstem** – Truncus encephali ... 402
3.1 **Medulla oblongata** – Medulla oblongata ... 404
3.2 **Pons** – Pons ... 406
3.3 **Midbrain** – Mesencephalon ... 408
3.4 **Cranial nerves nuclei** ... 410
3.5 **Tracts of the cranial nerves** ... 411
3.6 **Nuclei of the brainstem** ... 412
3.7 **Tracts of the brainstem** ... 413
4 **Reticular formation** – Formatio reticularis ... 414
5 **Cerebellum** – Cerebellum ... 418
6 **Diencephalon** – Diencephalon ... 424
6.1 **Epithalamus** – Epithalamus ... 425
6.2 **Subthalamus** – Subthalamus ... 425
6.3 **Thalamus** – Thalamus ... 426
6.4 **Hypothalamus** – Hypothalamus ... 430
7 **Telencephalon** – Telencephalon ... 432
7.1 **Cerebral cortex** – Cortex cerebri (pallium) ... 434
7.2 **Functional cortical areas** ... 435
7.3 **Basal ganglia** – Nuclei basales ... 439
7.4 **Cerebral white matter** – Corpus medullare ... 442
8 **Limbic system** ... 444
8.1 **Limbic system development** ... 448
9 **Sensory** ... 450
9.1 **Ascending tracts** ... 452
10 **Motor control** ... 456
10.1 **Descending (motor) tracts** ... 458
11 **Special sensory tracts**
11.1 **Visual pathway** ... 462
11.2 **Vestibular pathway** ... 464
11.3 **Auditory pathway** ... 465
11.4 **Olfactory pathway** ... 466
11.5 **Gustatory pathway** ... 467
12 **Ventricular system of the brain** ... 468
12.1 **Cerebrospinal fluid** – Liquor cerebrospinalis ... 470
13 **Meninges** – Meninges ... 471
14 **Arteries of the brain** – Arteriae cerebri ... 472
15 **Veins of the brain** – Venae cerebri ... 474
15.1 **Dural venous sinuses** – Sinus durae matris ... 475
16 **Blood supply of the spinal cord** ... 476
17 **Chemical system of the brain** ... 477
18 **Psychomotor development** ... 478
19 **Sections**
19.1 **Cross-sections of the spinal cord** ... 482
19.2 **Cross-sections of the medulla oblongata** ... 483
19.3 **Cross-sections of the pons** ... 484
19.4 **Cross-sections of the midbrain** ... 485
19.5 **Sagittal and transverse section of the brain** ... 486
19.6 **Frontal sections of the brain** ... 487
20 **Table – Cerebral sulci** ... 488
21 **Schemes**
21.1 **Scheme of cranial nerves nuclei** ... 488
21.2 **Scheme of the ventricular system, arteries of the brain and venous sinuses** ... 489
21.3 **Schemes of somatosensory tracts** ... 490
21.4 **Schemes of special sensory tracts** ... 491
21.5 **Schemes of motor tracts** ... 492
21.6 **Scheme of afferentation and efferentation of the cerebellum** ... 493
22 **Review questions and figures** ... 494
23 **Acknowledgements and references** ... 500

13 Senses and skin 501

1 **Senses** ... 502
1.1 **Internal environment – Interoceptors** ... 502
1.2 **Olfactory organ** – Organum olfactorium ... 503
1.3 **Gustatory organ** – Organum gustatorium ... 503
1.4 **Organ of hearing and balance** – Organum vestibulocochleare ... 504
1.5 **Visual organ** – Organum visus ... 508
1.5.1 **Accessory visual structures** – Structurae accessoriae oculi ... 512
1.6 **Touch, pain, proprioception** – Tactus, nociceptio, proprioceptio ... 514
2 **Skin / Integument** – Integumentum commune ... 515
2.1 **Breast and mammary gland** – Mamma et glandula mammaria ... 517
3 **Review questions and figures** ... 518
4 **Acknowledgements and references** ... 520

14 Endocrine system 521

1 **General overview** ... 522
2 **Diffuse neuroendocrine system (DNES) and paraganglia** ... 522
3 **Hypophysis / pituitary gland** – Hypophysis / glandula pituitaria ... 523
4 **Pineal gland** – Glandula pinealis / corpus pineale ... 524
5 **Endocrine component of the pancreas – pancreatic islets** ... 524
6 **Thyroid and parathyroid gland** – Glandula thyroidea et glandulae parathyroideae ... 525
7 **Suprarenal/adrenal glands** – Glandula suprarenalis ... 526
8 **Summary of the endocrine glands and their hormones** ... 527
9 **Review questions and figures** ... 527
10 **Acknowledgements and references** ... 528

15 Topography 529

1 **Topography of the head** 530
1.1 **Topography of the scalp and calvaria** 531
1.2 **Layers of the cheek** 531
1.3 **Orbit** – Orbita 532
1.4 **Common tendinous ring** – Anulus tendineus communis 534
1.5 **Cavernous sinus** – Sinus cavernosus 534
1.6 **Internal acoustic meatus** – Meatus acusticus internus 534
1.7 **Tympanic cavity** – Cavitas tympani 535
1.8 **Nasal cavity** – Cavitas nasi 536
1.9 **Internal surface of the cranial base** – Basis cranii interna 537
1.10 **Temporal fossa** – Fossa temporalis 537
1.11 **Infratemporal fossa** – Fossa infratemporalis 538
1.12 **Pterygopalatine fossa** – Fossa pterygopalatina 539
1.13 **Subdivisions of the infratemporal fossa** 540
1.13.1 **Pterygomandibular space** – Spatium pterygomandibulare . 540
1.13.2 **Parapharyngeal space** – Spatium parapharyngeum 540
1.13.3 **Prestyloid space** – Spatium prestyloideum 541
1.13.4 **Retrostyloid space** – Spatium retrostyloideum 541
1.13.5 **Retropharyngeal space** – Spatium retropharyngeum 541
2 **Topography of the neck** 542
2.1 **Regions of the neck** – Regiones cervicales 542
2.1.1 **Submandibular triangle** – Trigonum submandibulare 543
2.1.2 **Carotid triangle** – Trigonum caroticum 543
2.1.3 **Submental triangle** – Trigonum submentale 544
2.1.4 **Muscular/omotracheal triangle** – Trigonum musculare/omotracheale 544
2.1.5 **Lesser supraclavicular fossa** – Fossa supraclavicularis minor 544
2.1.6 **Omoclavicular triangle** – Trigonum omoclaviculare 545
2.1.7 **Omotrapezoid triangle** – Trigonum omotrapezium 545
2.1.8 **Scalene fissure** – Fissura scalenorum 545
2.1.9 **Scalenovertebral triangle** – Trigonum scalenovertebrale 546
2.2 **Spaces of the neck** 546
2.3 **Layers of the neck, cervical fascia** – Fascia cervicalis 547
3 **Topography of the thorax** 548
3.1 **Layers of the thoracic wall** 548
3.2 **Intercostal space** – Spatium intercostale 549
3.3 **Organ projections on the thoracic wall** 549
3.4 **Mediastinum** – Mediastinum 550
3.5 **Topography of the oesophagus, trachea and aorta** 552
3.6 **Openings of the diaphragm** 553
4 **Topography of the abdomen** 554
4.1 **Structure of the anterior and lateral abdominal wall** 555
4.1.1 **Rectus sheath** – Vagina musculi recti abdominis 555
4.2 **Inguinal canal** – Canalis inguinalis 556
4.3 **Inguinal region** – Regio inguinalis 558
4.3.1 **Common sites of hernia** 558
4.4 **Abdominal cavity** – Cavitas abdominis 559
4.5 **Retroperitoneal space** – Retroperitoneum 559
4.6 **Peritoneal cavity** – Cavitas peritonealis 560
4.6.1 **Root of the transverse mesocolon** – Radix mesocoli transversi 560
4.6.2 **Bursa omentalis** 561
4.6.3 **Hepatoduodenal ligament and cystohepatic triangle** 562
4.6.4 **Paracolic spaces** 562
4.6.5 **Mesenteries, omenta, peritoneal ligaments and recesses of the peritoneal cavity** 563
5 **Topography of the lesser pelvis** – Pelvis minor 564
5.1 **Peritoneal cavity of the pelvis** – Cavitas peritonealis pelvis 564
5.2 **Subperitoneal space** – Subperitoneum 565
5.3 **Perineal region** – Regio perinealis 566
5.4 **Urogenital triangle** – Trigonum urogenitale 566
5.5 **Ischioanal fossa** – Fossa ischioanalis 567
5.6 **Pudendal canal** – Canalis pudendalis 567
5.7 **Layers of the scrotum** 567
6 **Topography of the back** 568
6.1 **Vertebral canal** – Canalis vertebralis 568
6.2 **Suboccipital triangle** – Trigonum suboccipitale 569
6.3 **Superior and inferior lumbar triangles** – Trigonum lumbale superius et inferius 569
7 **Topography of the upper limb** 570
7.1 **Topography of the shoulder** – Regio deltoidea 570
7.1.1 **Suprascapular and spinoglenoid notches** – Incisura scapulae et spinoglenoidalis 570
7.1.2 **Axilla** – Fossa axillaris 571
7.1.3 **Triangular and quadrangular space** – Foramen omotricipitale et humerotricipitale 572
7.1.4 **Clavipectoral triangle** – Trigonum clavipectorale/deltopectorale 572
7.2 **Topography of the arm** – Regio brachialis 573
7.2.1 **Radial canal** – Canalis nervi radialis 573
7.3 **Topography of the elbow** – Regio cubitalis 574
7.3.1 **Cubital fossa** – Fossa cubitalis 574
7.3.2 **Pronator, cubital and supinator canals** – Canalis pronatorius, cubitalis et supinatorius 575
7.4 **Topography of the forearm** – Regio antebrachialis 575
7.5 **Topography of the wrist** – Regio carpalis 576
7.5.1 **Anatomical snuff box** – Foveola radialis 576
7.5.2 **Ulnar canal** – Canalis ulnaris 576
7.5.3 **Carpal tunel** – Canalis carpi 577
7.6 **Topography of the hand** – Regio manus 577
8 **Topography of the lower limb** 578
8.1 **Topography of the hip** – Regio coxae 578
8.1.1 **Greater and lesser sciatic foramina** – Foramen ischiadicum majus et minus 578
8.1.2 **Suprapiriform and infrapiriform foramen, lesser sciatic foramen** – Foramen suprapiriforme et infrapiriforme, foramen ischiadicum minus 579
8.1.3 **Vascular and muscular space** – Lacuna vasorum et musculorum 579
8.1.4 **Obturator canal** – Canalis obturatorius 580
8.2 **Topography of the thigh** – Regio femoris 580
8.2.1 **Femoral triangle and iliopectineal fossa** – Trigonum femorale et fossa iliopectinea 581
8.2.2 **Adductor canal** – Canalis adductorius 581
8.2.3 **Popliteal fossa** – Fossa poplitea 582
8.3 **Topography of the leg** – Regio cruris 582
8.3.1 **Fibular canal, tendinous arch of the soleus and musculofibular canal** – Canalis fibularis, arcus tendineus musculi solei, canalis musculofibularis 583
8.4 **Topography of the ankle** – Regio tarsalis 583
8.4.1 **Lateral retromalleolar space** 583
8.4.2 **Tarsal tunnel/canal** – Canalis malleolaris 584
8.4.3 **Structures in front of the medial malleolus** 584
8.5 **Topography of the foot** – Regio pedis 585
8.5.1 **Dorsum of the foot** – Dorsum pedis 585
8.5.2 **Sole** – Planta 585
9 **Sections** 586
9.1 **Sections of the head** 586
9.2 **Sections of the neck** 587
9.3 **Sections of the thorax** 588
9.4 **Sections of the abdomen** 589
9.5 **Sections of the pelvis** 590
9.6 **Sections of the arm and forearm** 592
9.7 **Sections of the wrist and hand** 593
9.8 **Sections of the thigh and leg** 594
9.9 **Section of the foot** 595
10 **Review questions and figures** 595
11 **Acknowledgements and references** 600

This copy belongs to ali yaghoubi

„**Anatomy**, albeit it is feminine, **has its own charm and logic,**“ said one professor of anatomy a long time ago. Although **anatomy is as old as humanity itself, its charm is immortal and its logic still maintained**. Owing to these characteristics, anatomy belongs among favorite subjects, which students look forward to learning long before starting their university studies. However, **a great deal of specialized terms and information takes often smiles off students' faces** during their first week of school. Students usually don't give up and become devoted to studying, but the more they learn, the more they forget. They learn joints, but forget bones. When they manage to know the digestive system by heart, they in turn push out the muscles of the whole body. Forgetting things once learned brings them feelings of hopelessness and doubt whether they have what it takes to study medicine at all. The problem, though, is often not the amount of information, but rather their **way of learning and reviewing**. There are **many thousand-page anatomy textbooks** on the market comprising the immensity of anatomy, but there is just **a few of those that would provide information in a concise, clear, and understandable form**. And that is why **Memorix Anatomy** was created.

Dissatisfaction as a reason for change

Even most of us (the authors of this book) had to study anatomy for the first time and pass our first year of medical school just a few years ago. Just like the vast majority of medical students, we too wished to own a big book of anatomy of our own. We wanted to take pride in its complexity, size, and infinity in front of every person we knew. We felt so proud that we were medical students that we bought **three volumes of an anatomy textbook from one author, several other books by other authors, with two more color atlases** on top of that. We had more books from one field than from any other subject altogether and a **beautiful (but naive) idea we would once know it all**. **Do you recognize that feeling?** The excitement that you will be able to know in detail the origins and insertions of 300 muscles, the passages of the fourteen branches of the maxillary artery, or all the nuclei, tracts, and circuits in the brain? **An amazing image!** Amazing until you realize what we all know, but are unwilling to admit: **the fact that our memory has a limited capacity and chooses only the information our brain evaluates as important**. However, this is often not necessarily the information that is truly important.

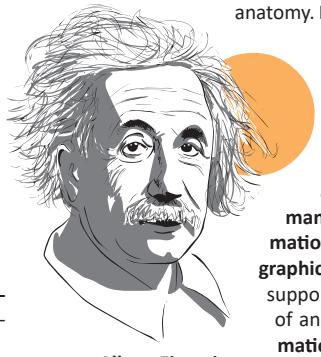

Albert Einstein

There was relatively enough time for studying at the beginning and we devoured important information along with the less important. As the final exam was approaching, so was the schoolwork volume exponentially growing, and the time was growing less and less. It became **necessary to distinguish the importance of information, adjust one's system, and study effectively**. Our large textbooks didn't suit us anymore and we were looking for something more clear and concise. **We were seeking tables, schemes, structured text, and simple images.** But we just could not find a book that would meet our needs.

One of the editors of this book, **Radovan Hudák**, had thought already during his study of medicine that he could **initiate the creation of such book as a student**. He contacted an **experienced anatomist, associate professor David Kachlík, M.D.**, with a question whether he wanted to collaborate on the **creation of a comprehensive, yet easy-to-understand anatomy book**. He thought it over and agreed. This initiated the creation of **Memorix Anatomie** (the Czech forerunner of this book), which was **in the spirit of Albert Einstein's** "**Everything should be made as simple as possible – but not simpler.**"

The base of success lies in cooperation

Before we started to build a team of authors, we asked ourselves a question, **„Who is this textbook intended for? For students, anatomists, or perhaps clinicians?"** We came to the conclusion that it was for all. Where a quality textbook should arise, it was necessary to have **a collaboration not only with anatomists who would guarantee quality anatomical content of the book, students who would ensure its comprehensibility, but also physicians who would add clinically important information**. Thus, more than half of the team of authors has been formed by **students who have already spent several years teaching anatomy to younger students from the position of student tutors**. The second part of the team consisted of **anatomists and clinicians**, who also significantly engaged themselves in anatomy. Even our **three illustrators have come from medical school**, so they knew very well what kind of pictures are best understood by students. The work of the Memorix team was also contributed to by **a large number of reviews by dozens of other anatomists, students, and physicians**.

The creation of this book cost us thousands of hours of hard work, but after 1.5 years we managed to finish it and get it to the students. **On a mere 600 pages, we have managed to summarize the most important anatomical information, which we have supplemented with more than 1,500 graphically uniform pictures.** The text and images are mutually supportive in order to significantly accelerate the understanding of anatomical structures. **Less important and interesting information were, together with clinical notes, set aside the main content** and placed in the middle column of each double page.

The sorting of the chapters, structured text, and large number of pictures has made **Memorix Anatomie a clear, systematic, and concise textbook designed for the effective learning and rapid reviewing of anatomy**.

After the success in the Czech and Slovak Republic, one of the co-authors of the Czech version, **Ondřej Volný**, couldn't resist and immediately initiated **the creation of an English version**. Again, the work involved a large number of **students, anatomists, and clinicians, only this time, from around the world**. Apart from the aforementioned features of the book, the Memorix book will be helpful to many students by having **all the structures described with English and Latin terms** right next to each other.

With the Memorix Anatomy book, we want to contribute to a **better understanding of anatomy among students**. We don't want them to see learning anatomy as necessary evil, but actually the other way around – to learn it with affection. **We would also like to motivate all students not to be afraid to address teachers with their ideas for improving teaching.** They will certainly appreciate it. And if not, contact us (*anatomy@memorix.cz*), because we will gladly hear out your thoughts and opinions. Who knows, we may create another useful study material together.

On behalf of the Memorix team
Radovan Hudák, David Kachlík, Ondřej Volný
Prague, Czech Republic, August 20, 2015

Anatomy can be learned very quickly. But it can also be quickly forgotten. To keep the anatomical knowledge in your memory, **it is necessary to study and repeat systematically**. That is why we created the **Memorix Education System** with **specialists in teaching psychology and andragogy** (teaching of adults). We decided to use a **structured text** instead of a continuous one, as it is considered **more efficient in the process of studying, memorizing, and reviewing**. **We separated important anatomical information described in the main content from the less important**, which we put in the middle column. **Clinical correlations** have their place in the middle spread, as well. Special emphasis is put on **charts and schemes** serving as a tool for better memory consolidation and revision.

Steps of the Memorix Education System

1. Chapter structure
- schedule your study time and plan your study process
- look through the chapter headings, its divisions and subdivisions
- study the introduction windows and briefly look at pictures and schemes

2. Study the chapter in detail
- go through the chapter step-by-step
- reread the main sentences, study the main text and pictures carefully and in more detail
- try to find all the answers to your questions
- highlight all information which you consider to be important, make notes, redraw pictures and create mind maps

3. Interesting things
- look through the less important but interesting anatomical information in the middle column

4. Clinical notes
- read the clinical notes and try to understand the correlations between anatomy and clinical medicine

5. Schemes and charts
- use the schemes and charts for effective revision and quick orientation

6. Review questions and figures
- answer all the questions
- describe all the pictures presented in the revision part
- if you are not able to answer a question or describe a picture, return to the chapter and try to find it

7. Anatomy presenting
- present the information you have learnt to your classmates
- engage in discussions about the topics

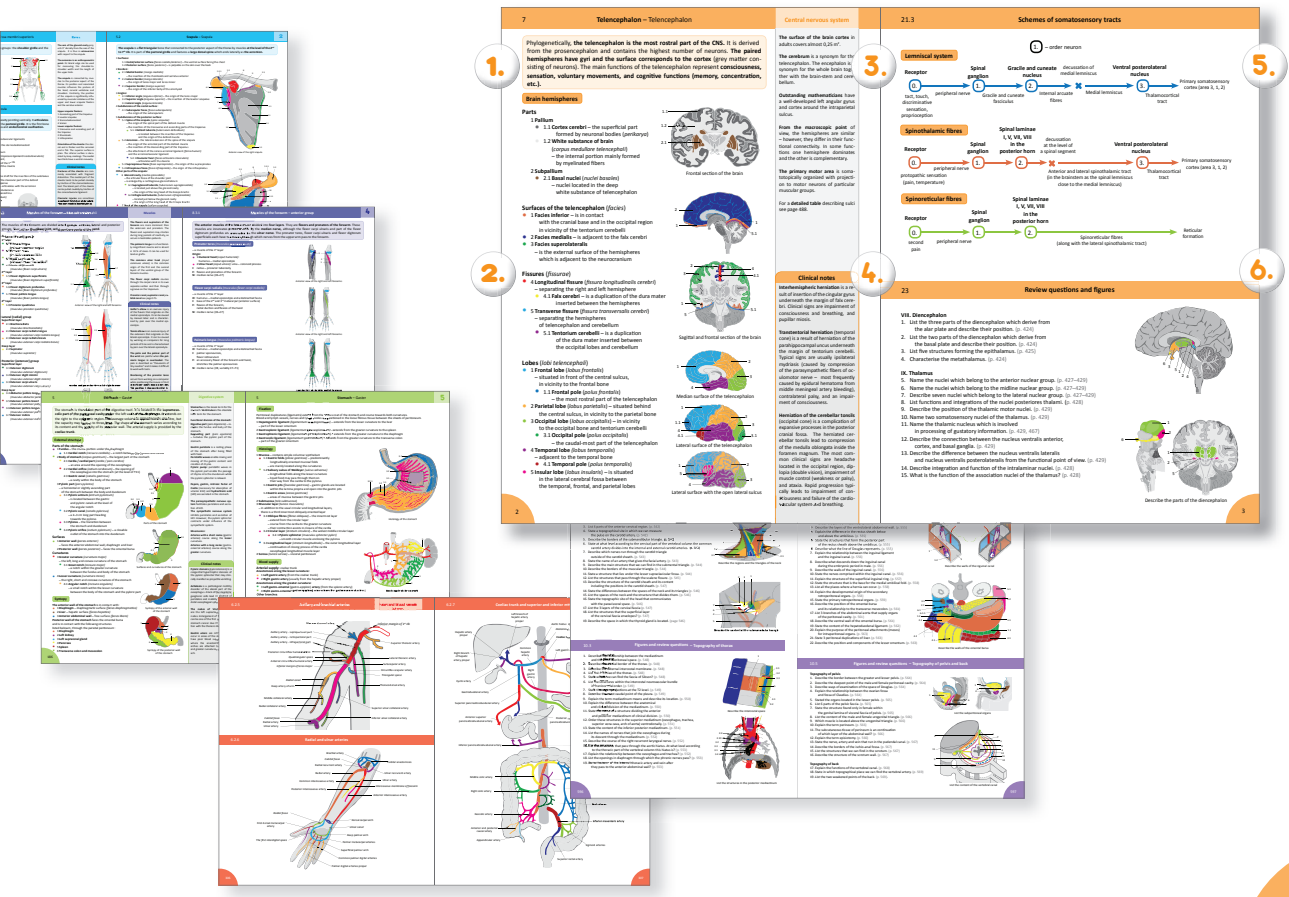

This copy belongs to ali yaghoubi

Designing a format, creating an outline, and building a quality team of authors, illustrators, and typesetters was just a fraction of the work. **Writing and constant efforts to improve the texts, illustrations, and schemes followed.** The integral part of the process was the involvement of **dozens of anatomists, clinicians, students, proofreaders, and native speakers** whose reviews and input have significantly contributed to the quality of our book. Certainly, we could not have sailed through all of this on our own. That is why **we would like to acknowledge all** who have contributed to the emergence of this revolutionary and unique anatomy textbook.

Firstly, we appreciate all of the time and energy of all the co-authors: **Jakub Miletín, Matej Halaj, Ladislav Douda, Barbora Beňová, Martin Čepelík, Vojtěch Kunc, Petr Vaněk, and Adam Whitley**. We are thankful for this hardworking team that made the Memorix Anatomy dream a reality. It was a great pleasure for the main authors to work with all of you.

We are grateful for our stunning illustrators, whose illustrative drawings and schemes make anatomy easier to understand and also visually attractive. Many thanks to the brilliant **Jan Balko**, charming **Simona Felšőová**, and precise **Šárka Zavazalová** for thousands of hours spent with electronic paintbrush, their ubiquitous tablets, and enthusiasm for colorful anatomy. We really appreciate the carthorse work of our typesetters, who are responsible for time-consuming manual corrections of all arising comments and revisions – many thanks to the tireless **Vojtěch Kunc**, tenacious **Matej Halaj**, and diligent **Daniel Slovák**. We also value very much the help of our certified language proofreaders: **Zuzana Balážová**, **Pavel Filip**, and **Michal Vilimovský** led by the extraordinary **Petr Vaněk**, and the willing native speakers led by the outstanding **Adam Whitley**; their cooperation and detective work contributed to the high-quality English in Memorix Anatomy. We appreciate all the help of our andragogist, **Miroslava Dvořáková**, who helped us with building of the Memorix Education System and who precisely answered all questions related to the didactic value of this textbook.

We wish to express our gratitude to all **anatomic reviewers** from all over the world, led by reviewer-in-chief and excellent clinical anatomist **Václav Báča**. Many thanks to **Nihal Apaydın** (Turkey), **Marcela Bezdíčková** (Czech Republic/Wales), **Susana N. Biasutto** (Argentina), **Phil Blyth** (New Zealand), **Adriana Boleková** (Slovakia), **Stephen Carmichael** (USA), **Ayhan Cömert** (Turkey), **Hans J. ten Donkelaar** (Netherlands), **Lada Eberlová** (Czech Republic), **Georg Feigl** (Austria), **Quentin Fogg** (Australia), **Guiliana Gobbi** (Italy), **Marek Joukal** (Czech Republic), **Dzintra Kažoka** (Latvia), **Darina Kluchová** (Slovakia), **Květuše Lovásová** (Slovakia), **Veronica Macchi** (Italy), **Pavel Šnajdr** (Czech Republic), and **Trifon Totlis** (Greece). Their contribution to Memorix Anatomy was always constructive and anatomically and personally enriching, and we cannot possibly thank them enough for all of the advice and suggestions they provided.

We very much value the help of **clinical reviewers**, who were able to contribute their precious time to Memorix Anatomy. Many thanks to physiotherapist **Zdeněk Čech** (Czech Republic), gynecologist **Andrej Černý** (Czech Republic), neuroradiologist **Christopher d'Esterre** (Canada), neurologist **Aravind Ganesh** (Canada), orthopedist **Vojtěch Havlas** (Czech Republic), cardiologist **Anna Chaloupka** (Czech Republic), gastroenterologist **Markéta Ječmenová** (Czech Republic), cardiosurgeon and vascular surgeon **Štepán Jelínek** (Czech Republic), internist **Dale Kalina** (Canada), neurologist **Robert Kuba** (Czech Republic), ophthalmologist **Helena Menšíková** (Czech Republic), urologist **Ivo Minárik** (Czech Republic), oncogynecologist **Lucie Mouková** (Czech Republic), internist **Jan Novák** (Czech Republic), neurologist **Eva Plaňanská** (Czech Republic), neurologist **Ondřej Strýček** (Czech Republic), and hematooncologist **Martin Štork** (Czech Republic). It was particularly their dedication, enthusiasm, and insight which has earned our frank gratitude and which has made this a better anatomy textbook with relevant and useful clinical notes.

Our gratitude also goes out to dozens of students who went carefully over the contents of the book page after page. They helped us discover quite a number of flaws and errors, thus improving the understanding of the entire text.

We wish to thank to **Memorix Anatomy godfathers**: **Vladimír Komárek** (Dean of Second Faculty of Medicine, Charles University in Prague, professor of neurology and Head of Department of Paediatric Neurology, Second Faculty of Medicine, Charles University in Prague and Motol University Hospital) and **Martin Bareš** (Vice-Rector for Development of Masaryk University in Brno, professor of neurology at First Department of Neurology, St. Anne's Faculty Hospital and Faculty of Medicine, and professor of neurology at University of Minnesota).

And last but not least, we are immensely appreciative of all anatomists, clinicians, students, and members of the Memorix team, who participated in the creation of the Czech predecessor of this book: Memorix Anatomie.

Finally, we would like to sincerely thank to our families, friends, and loved ones for the continuous help, unconditional support, and endless motivation.

Radovan Hudák, David Kachlík, Ondřej Volný



25 Anatomists



56 Medical doctors



94 Medical students



36 Other people

...worked hard creating MEMORIX ANATOMY for You!

Anatomic reviewers

Assoc. prof. Václav Báča, MD, PhD – *chief reviewer*
Assoc. prof. Nihal Apaydın, MD
Marcela Bezdíčková, MD PhD
Prof. Susana N. Biasutto, MD
Assoc. prof. Adriana Boleková, MD, PhD
Emer. prof. Stephen Carmichael, PhD, DSc.
Assoc. prof. Ayhan Cömert, MD
Prof. Hans J. ten Donkelaar, MD, PhD
Lada Eberlová, MD, PhD
Dr.med.univ. Georg Feigl
Quentin Fogg, PhD
Prof. Guiliana Gobbi , MD
Marek Joukal, MD
Assoc. prof. Dzintra Kažoka, MD
Prof. Darina Kluchová, MD, PhD
Assoc. prof. Květuše Lovásová, VDM, PhD
Assoc. prof. Veronica Macchi, MD, PhD
Pavel Šnajdr, MD, PhD
Trifon Totlis, MD, PhD

and further 4 anatomists which reviewed the Czech edition of Memorix Anatomy

Clinical reviewers

Zdeněk Čech, MSc.
Andrej Černý, MD
Christopher d'Esterre, PhD
Aravind Ganesh, MD
Assoc. prof. Vojtěch Havlas, MD, PhD
Anna Chaloupka, MD
Markéta Ječmenová, MD
Štepán Jelínek, MD
Dale Kalina, MD
Prof. Robert Kuba, MD, PhD
Helena Menšíková, MD
Ivo Minárik, MD, FEBU
Lucie Mouková, MD, PhD
Jan Novák, MD
Eva Plaňanská, MD
Ondřej Strýček, MD
Martin Štork, MD

and further 33 clinicians which reviewed the Czech edition of Memorix Anatomy

Student reviewers

Jan Brtek
Max Cameron
Antonio Franca
Eva Fürstová
Therese George
Daniel Glanc
Monika Hejduková
Lucie Holubičková
Petr Kala
Linda Kašičková
Daanish Khorasani
Michal Klíma
Matěj Krchov
Adéla Kuklová
Vojtěch Kunc
Adam Kubica
Miroslav Kyselica
Verena Leppmeier
Lukáš Mach
Domenico Messina
Klára Macháčková
Lucie Mládenková
Lenka Molčányjová, MSc.
Shannon Motsuka, MSc.
Ramkumar Nagarajan
Jakub Ivan Němec
René Novysedlák
Lucie Olivová
Dominik Paugsch
Emília Petríková
Jamie Sherrington
Sebastian Schmitz
Kateřina Tomanová
Petr Urban
Prokop Vodička
Christoph Wawoczny
Rachel White
Danil Yershov

and further 52 medical students which reviewed the Czech edition of Memorix Anatomy

Others

Prof. Vladimír Komárek, MD, CSc.,
Prof. Martin Bareš, MD, PhD
Dr. Miroslava Dvořáková, Ph.D.
Stanislav Juhaňák, MD
Gabriela Holubová
Peter Magic
Helena Menšíková, MD
Michaela Pospěchová
Daniel Slovák
Prokop Vodička

The creation of the Czech and English version of Memorix Anatomy involved together over 200 people. We sincerely thank you from the depths of our anatomical hearts.

Acknowledgements to student organisations

Student clubs bring together active students to work, create, and help with enthusiasm. These organizations prepare unique projects that **educate students, elicit smiles on the faces of patients, and inform thousands of fellow citizens about health care**. Members of these organizations are not paid for their work, but **their reward is the feeling of a job well done, the gained experiences, and the possible appreciation from others**. I myself, as well as many co-authors, are grateful to many of these associations for what they have taught us about communication, time and projects management, teamwork and many other areas. If it weren't for student organizations and active students, this book would have never been created. We thank you.

IFMSA Czech Republic (IFMSA CZ), the largest medical student organisation in the Czech Republic, is a part of IFMSA, a federation of medical student organisations spanning the world. Projects like Medicafé, Teddy Bear Hospital, World Health day and many others, provide medical students with first hand experience dealing with public health and many other topics. IFMSA CZ also holds successful fundraising events, that help various non-profit organisations. IFMSA CZ organises more than 300 clinical and research exchanges yearly. These exchanges are open to all our members, giving them an opportunity to travel, meet other cultures, whilst furthering their medical knowledge and experience. www.ifmsa.cz

Slovak Medical Student's Association (SloMSA) connects 4 Local Medical Student's Associations in Slovakia and provides projects in public health, medical education, reproductive health and in many other fields of medicine. Our Association also provides more than 150 month exchange programs for medical students to more than 40 countries worldwide every year. www.slomsa.sk

This copy belongs to ali yaghoubi

Editors – anatomy is our passion, anatomy is our life

Radovan Hudák



I devoted my childhood to basketball, which I played at a professional level, but a **knee injury changed my life course towards medicine**. Sports have continued to stay in my heart and have shifted me to **medical disciplines related to the construction and movement of the human body**, such as **anatomy, kinesiology and orthopedics**. In medical school I was actively involved in **student organisations and the academic senate** and in the third year of my medical studies, **I started teaching anatomy**. My goal is to **teach students in both a fun and an easily understood manner**. I like active people and I try to be one of them. I guess **I'm a workaholic** but I love it.

David Kachlík

During my medical studies at university, the true, **decisive and fatal crossroad of my life came into the picture: the dissection room**. That space destined my future life career and medical specialization. **Fascination by the hidden corners and nooks of the human body** led me to my future teaching and scientific way of life. The driving force of my effort was the desire to **mediate the knowledge to students in an easily accessible and gripping manner**. Whenever I saw a light of cognition in my students' eyes, my endeavor came to fruition. **The result of my effort is this book**. Although it pulled me away from my children a bit, **it became a kind of my child itself**.



Ondřej Volný



I was born in Ostrava, where I have graduated from both elementary and high school. After that, my feet lead me to Brno to the Medical Faculty. **My big dream is to one day be on the world's stage**, though I haven't yet tried actual acting. Instead, every week I **„perform" in front of students during anatomy classes**. I like challenges, which is why I chose **the brain and nervous system as a chapter in Memorix, as well as in my professional life**. I focused on neurology, anatomy, and research at **Hotchkiss Brain Institute at the University of Calgary**. Currently, I work as an assistant professor at the **First Department of Neurology in Brno**.

Illustrators – a drawing of the human body is a pleasure of our senses

Jan Balko



My name is Jan Balko and I work at the Department of Pathology in Prague. I have taken part in creation of Memorix Anatomy right before my graduation. It has been my task to **paint the majority of the pictures including the cardiovascular system, bones, joints, muscles** etc. Luckily, there were two co-workers, who helped me a lot. We have managed to **finish hundreds of pictures in just a single year**. It was our wish to **make them simple and colourful**. **Simplicity makes it possible to redraw the pictures by the students themselves** and **the motley colours help distinguish all the anatomical structures**. I hope you will be satisfied with our work.

Simona Felšőová

I have had a passion for drawing ever since I was a little girl. **I could spend upon hours and hours improving my sketches**. **I didn't think for another second when I was offered to draw illustrations for Memorix**. I like the fact that I could **combine medicine and art** while producing **something undoubtedly useful for young students to understand the basics of human anatomy**. I take a keen interest in illustrating and graphics and I want to take part in future graphical projects. My life's goal is to **help people every day by becoming an excellent and sensitive physician**.



Šárka Zavázalová



For a long time the **only partnership between me and medicine was an emergency room and an otorhinolaryngology ward**. At present, as a physician, I gain strength for **doing my job through my lifetime hobby – drawing and painting**. I'm extremely happy that I was challenged to utilize my hobby by **making illustrations for this marvellous textbook – friendly not only to medical students but also to forgetful physicians** – as well as myself. I hope this book will accompany you on your journey through medical school and medical career.

Barbora Beňová



Starting as a young and eager book-loving student of medicine, as soon as I could **I immersed myself into the complexity of anatomy** bringing it to today's young, eager and book-loving students. Working as an anatomy assistant I was offered a wonderful chance to co-author this amazing textbook. **The complexity of human anatomy strikes me every day in my practice**. Currently as **a resident of paediatric neurology and a PhD student in neuroscience**, I turn back to the very first edition of "Memorix Anatomie" to recall all the lost and newly regained knowledge of brain anatomy.

Martin Čepelík

Since childhood as I remember I have always wanted to become a physician. I have also been **inclined to teaching and anatomy** united these two paths into one. Although I am now working as **a surgeon in the Department of Pediatric Trauma and Surgery** in Prague, I still gladly remember my days in the Department of Anatomy, and **my knowledge of anatomy helps me a lot in what I do now**. I am proud and thankful to be a part of such great team that worked hard on the Memorix Anatomy and I hope that **it will be as rewarding for you to read it as it was for us to create it**.



Ladislav Douda



The relationship between structure, function and clinical relevance is the main goal of studying and teaching anatomy. The ability to explain, to answer frequently asked questions and anatomical difficulties, and simply to be closer to the readers and behave student-friendly, these are the rudiments of Memorix Anatomy. **This excellent textbook makes studying anatomy interesting and dynamic**. In this matter, it not only deserves an exceptional attention but also an exceptional humility of authors before their own work.

Matej Halaj

After years of hard work in judo, hockeyball and contemplating studying at lawschool, I decided to leave it all behind and **instead pursue medschool**. As a medical student I get the opportunity to **teach anatomy at our anatomy department in Brno**. It was something remarkable for me. That's the reason why I said: "Yes!" when Rado Hudák asked me, if I wanted to work on Memorix Anatomy. Currently **I work as a resident of Neurosurgery** in Olomouc and **I open Memorix almost every day**. I hope that anatomy with **Memorix will soon become your passion**.



Vojtěch Kunc



"Do you like it?" With this question one Georgian orthopedist **asked for my opinion after a complicated surgery**. I laughed. Why would an experienced surgeon ask a newbie, who was only seeing that operation for the first time? But it was not a joke. **The surgery was not finished until every member of the team verified that he or she was satisfied by it**. This humble attitude I have also found this humble attitude within the **Memorix team**. **Both are connected by the desire for perfection**. I hope this book will serve you well and I would also like to ask you: **do you like it?**

Jakub Miletín

I have been interested in surgery and anatomy since my first years at the university. Thanks to the friendly attitude of the department of anatomy, **I had almost unlimited options to study this wonderful discipline**. **Its knowledge helps me a lot in my surgical profession**, so I decided to continue teaching anatomy at the Third Faculty of Medicine. **I always try to transmit my knowledge to the students in as a comprehensible way as possible**. Memorix Anatomy was **a great challenge to be able to explain the topographical anatomy intelligibly, yet still thoroughly**.



Petr Vaněk



I am ambitious and have been since an early age. As a child, I grew up **dreaming of playing sports** in the pro-ranks and couldn't picture myself doing anything else. Later on, I moved to the United States and began to fulfill this dream. But there is one saying, "**We plan, God laughs.**" And so, after a series of injuries, my sports career was over. This life lesson, which has taught me much about the importance of health, has brought me a new ambition: **restoring the health of others**, which after all, may be **more rewarding than anything else**. And **it all begins with anatomy**.

Adam Whitley

I was inspired to teach anatomy by the excellent student lecturers who taught me during the dissection course in my first year of studies. I grew up in England, and moved to Prague in 2010 **to study at the Second Faculty of Medicine at Charles University**. I have now been teaching anatomy for four years and I have taught students of both the second and first medical faculties. **I have enjoyed working on Memorix Anatomy and I believe it provides a unique way of presenting the complexities of human anatomy in a simple and concise format**.



This copy belongs to ali yaghoubi

Dedicated to everyone who is the anatomist from the heart.
Furthermore, to those who have their dreams
and are not afraid to make them come true.

”Everything should be made as simple as possible,
but not simpler.“

Albert Einstein

Memorix Anatomy

1 General anatomy

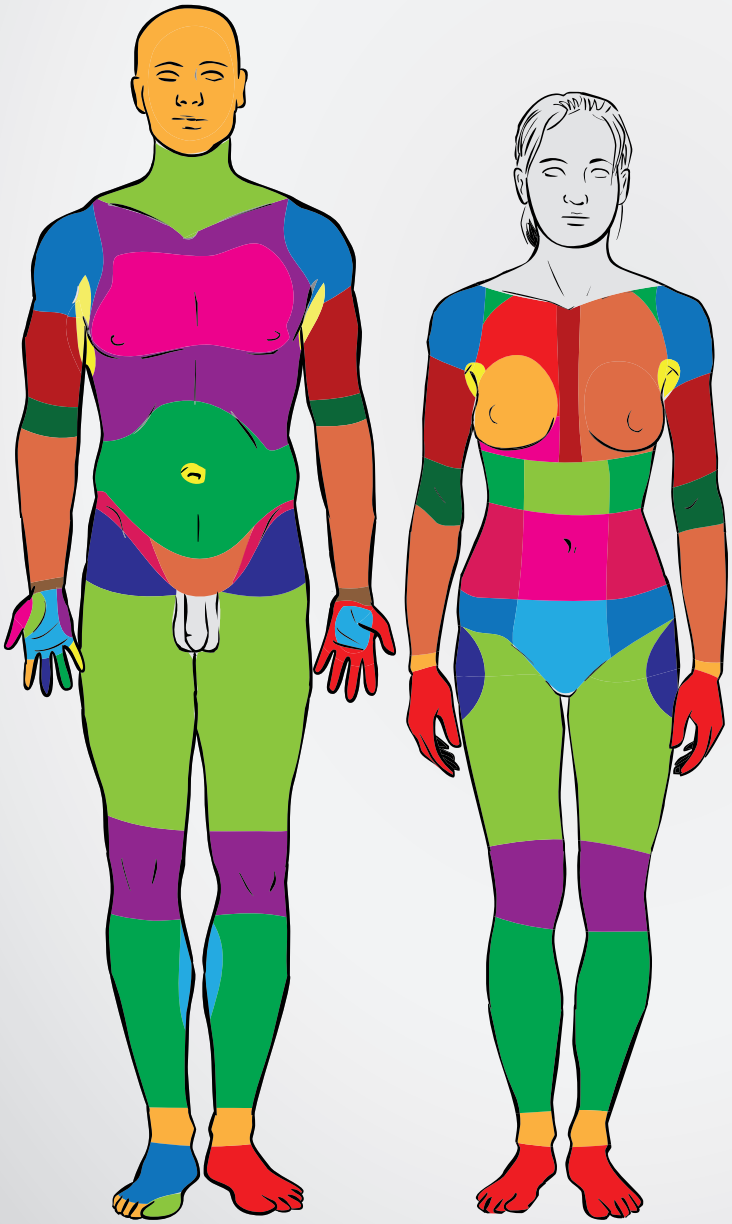

David Kachlík
Radovan Hudák
Ondřej Volný
Adam Whitley

Definitions and history 2
Terms and abbreviations 3
Histology 4
Embryology 5
Anatomical changes in childhood 6
Anatomical changes in puberty 7
Planes and lines of the human body 8
Terms of location and direction 9
Parts of the human body 10
Regions of the human body 11
Eponyms 12
Review questions and figures 14
Acknowledgements and references 16

This copy belongs to ali yaghoubi

Anatomy is a scientific field concerned with the structure of the human body. The term "anatomy" comes from the Greek "**anatemnein**", which literally means "to cut". Anatomy describes the shape, internal structure and location of the individual parts of the body to enable an understanding of their function, demonstrating that structure and function are inseparably connected. As a **preclinical science**, it provides the foundation for of all fields of clinical medicine. We – medical students, physiotherapists, nurses and physicians – would not be able to get by without anatomy and that is why we keep coming back to it.

Definitions

Morphology – a scientific field that includes anatomy, histology and embryology
– a study of the structure and development of the human body
Anatomical terminology – terms describing particular parts of the human body
Anatomical nomenclature – international official anatomical terminology in Latin
Terminologia anatomica (TA 1998) – the most recent version of the anatomical nomenclature
Obsolete terms – terms that have been replaced or removed from the terminologia anatomica
Eponyms – anatomical terms named after living, dead or fictitious people
– terms usually named after the person who first described or discovered the structure
– in clinical medicine some eponyms are used more frequently than the Latin terms
Standard/norm – a set of characteristics occurring most often
Variation – a small deviation from the standard without any functional changes
Anomaly – a significant deviation from the standard causing functional changes

Classifications

According to size:

Macroscopic anatomy – description of the body with the naked eye or with small magnification
Microscopic anatomy/histology – description of the body with the use of microscopic technology
– description of stained slices of tissue viewed under the microscope

According to function:

Normal – study of the structure of the healthy human body
Pathological – study of the anatomical changes that occur with disease

Subspecialities of anatomy:

Systematic anatomy – description of organs according to their development and structure
Topographic anatomy – description of the spatial relationship of different organs to each other and their placement in the body

Others:

Clinical/applied anatomy – use of anatomical findings in clinical medicine
Surface anatomy – description of how the surface of the body appers to the naked eye
– description of body proportions
Comparative anatomy – description of the similarities and differences in the anatomy of humans and animals

World history

1600 B.C.	**Egypt**	**Erbs papyrus** the first description of the heart, vessels and some other organs and diseases
460–377 B.C.	**Greece**	**Hippocrates of Kos** performed the first human anatomical descriptions
384–322 B.C.	**Greece**	**Aristotle of Stageira** described the differences between arteries and veins and performed animal dissections
335–280 B.C.	**Greece**	**Herophilos and his student Erasistratos** performed the first human dissection
1st century B.C.	**Greece**	**Rufus of Ephesos** wrote the first book of anatomical terminology
129–205/211	**Rome**	**Galen of Pergamon** performed dissections on animals and the first detailed anatomical works
980–1037	**Persia**	**Avicenna** wrote "The Canon of Medicine", the definitive textbook of medicine in the Middle Ages
1213–1288	**Egypt**	**Ibn al-Nafis** wrote the first description of the pulmonary circulation and capillaries
1514–1565	**Italy**	**Andreas Vesalius** wrote the first modern anatomy textbook "De humani corporis fabrica" in 1543

Anatomy is a descriptive science that almost universally uses mainly **Latin and Greek terms.** Every term has an **English equivalent**. Many of the English equivalents are similar to the Latin, but some are completely different. As Latin is still the first language of medical terminology, **it is important to know at least the basic terms in both languages.**

Basic terms (latin – english)

Abdomen – abdomen, belly
Ala – wing
Angulus – angle
Apex – apex, top
Arcus – arc
Arteria – artery
Articulatio – joint
Brevis – short
Canalis – canal
Capitulum – small head
Caput – head
Cartilago – cartilage
Cauda – tail
Cavitas – cavity
Caecus – blind
Cerebrum – brain
Cervix – neck
Circumferentia – circumference
Collum – neck
Cornu – horn
Corpus – body
Costa – rib
Cranium – cranium
Crista – crest
Dexter – right
Dorsum – back, dorsum
Ductus – duct
Eminentia – prominence, eminence
Et – and
Excavatio – pouch
Extensor – extensor (muscle)
Extremitas – extremity
Facies – surface
Fissura – fissure
Flexor – flexor (muscle)
Foramen – foramen, opening
Fossa – fossa, hole, pit
Fovea – pit, snare
Ganglion – ganglion
Glandula – gland
Hallux – toe
Hiatus – opening in organ
Impressio – impression
Incisura – notch
Interosseus – located between bones
Labium – lip
Latus – flank
Ligamentum – ligament
Linea – line
Longitudinalis – longitude
Longus – long
Lympha – lymph
Magnus – big
Major – greater
Manus – hand
Margo – border
Maximus – the biggest
Medulla – marrow
Membrum – limb
Minimus – the smallest
Minor – lesser
Musculus – muscle
Nervus – nerve
Nucleus – nucleus
Nutritium – nourishing
Nodus – node
Obliquus – oblique
Os – bone
Os – mouth
Ostium – entrance, opening
Paries – wall
Pars – part
Parvus – small
Pelvis – pelvis
Pectoralis – pectoral, related to chest
Pectus – front of chest
Planum – plane
Plexus – plexus
Pollex – thumb
Processus – process
Profundus – deep, profound
Prominentia – prominence
Ramus – branch
Rima – crack, fissure
Seu – i.e / in other words
Sinister – left
Sinus – cavity, hollow, sinus
Septum – enclosed place, septum
Spatium – space, room
Spina – spine
Sulcus – groove
Superficialis – shallow, superficial
Recessus – space, recces
Tendo – tendon
Teres – rounded, teres
Thorax – chest, thorax
Tonsilla – tonsil
Transversalis – transverse
Truncus – trunk
Tuber – hump, tuber
Tuberculum – small bump, tubercle
Tuberositas – tuberosity
Vas, vasa – vessel
Vena – vein
Venter – belly
Vesica – bladder
Vertebra – vertebra

Basic abbreviations

a. – aa. (arteria – arteriae)
v. – vv. (vena – venae)
n. – nn. (nervus – nervi)
lig. – ligg. (ligamentum – ligamenta)
m. – mm. (musculus – musculi)
proc. – procc. (processus – processus)
r. – rr. (ramus – rami)
n. l. – nn. l. (nodus lymphoideus – nodi lymphoidei)
art. – **artt.** (articulatio – articulationes)
ncl. – **ncll.** (nucleus – nuclei)
gl. (glandula)
ggl. (ganglion)
pl. (plexus)
ant. (anterior)
post. (posterior)
int. (internus)
ext. (externus)
med. (medialis)
lat. (lateralis)
sup. (superior)
inf. (inferior)
prof. (profundus)
supf. (superficialis)
dx. (dexter)
sin. (sinister)
l. sin. (lateris sinistri) – of the left side
l. dx. (lateris dextri) – of the right side
ANS – autonomic nervous system
CNS – central nervous system
ENS – enteric nervous system
PNS – peripheral nervous system
GIT – gastrointestinal tract
UGT – urogenital tract
UL / LL – upper limb / lower limb

This copy belongs to ali yaghoubi

Histology is a science that describes cells, tissues, organs and organ systems on a microscopic level. **The cell is the fundamental unit of the body.** During development cells come together to form tissues. **A tissue** is a set of cells and extracellular matrix with a specific function. **There are four types of tissues** that combined together form **organs**. A set of organs forms **an organ system**, which is characterised by its specific functional characteristics.

The cell *(celulla)*

The eukaryotic animal cell is the structural and functional unit of the human body.

- 1 **Plasmalemma / cell membrane** – the envelope of the cell
  - a biomembrane made up of a phospholipid bilayer
  - is semi-permeable and regulates the transport of substances into and out of the cell
- 2 **Cytoplasm** – contains the cytosol, organelles, cytoskeleton and cellular inclusions
  - 3 **Organelles** – structures in the cytoplasm that are surrounded by biomembranes
    - 3.1. **Mitochondria** – produce energy for the cell
    - 3.2 **Rough/granular endoplasmic reticulum (RER)** – contains ribosomes on its surface
      - produces and modifies proteins, which are destined to become parts of the cell or are exported into the extracellular matrix
    - 3.3 **Smooth/agranular endoplasmic reticulum (SER)** – synthesises steroids, membrane proteins and glycogen
      - the SER in liver hepatocytes carries out detoxification
      - the SER in skeletal muscle cells stores calcium ions
    - 3.4 **Golgi complex** –performs posttranslational modification and packaging and secretion of proteins
    - 3.5 **Lysosome** – degrades intracellular and extracellular proteins
    - 3.6 **Peroxisome** – contains a lot of enzymes and takes part in detoxification
      - degrades fatty acids and amino acids
- 4 **Nucleus** – contains genetic material in the form of chromatin
  - 4.1 **Nucleolus** – a structure within the nucleus that synthesises ribosomes
- 5 **Ribosome** – is located in the cytoplasm and creates proteins for the needs of the cell
- 6 **Cytoskeleton** – a network that supports the shape and functions of the cell
  - 6.1 **Microfilaments** – orchestrate cellular movement and intracellular transport
  - 6.2 **Intermediate filaments** – provide integrity and support to the cell
  - 6.3 **Microtubules** – facilitate intracellular transport
- 7 **Cytoplasmic inclusions** – deposits of lipids, saccharides, proteins or pigments
  - are either produced by the cell or acquired from outside the cell

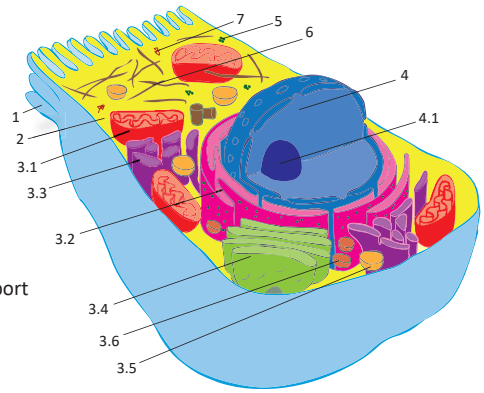

Eukaryotic cell

Tissues *(textus)*

1 **Epithelial tissue** – an avascular tissue, made of tightly connected cells and very little extracellular material
- is separated from other tissues by the basal lamina
- has three major characteristics: number of cell layers, height of the cells and cell surface apparatus (microvilli, kinocilia and stereocilia)

1.1 **Surface epithelium** – has a protecting and supporting function, forms mucous membranes and covers the surface of the body
1.2 **Glandular epithelium** – makes up endocrine glands, which secrete their contents into the blood and exocrine glands, which secrete their contents into body cavities or onto the body surface
1.3 **Specialised epithelium** – includes sensory neuroepithelium and the epithelial part of the thymus

2 **Connective tissue** – has mechanical, protective and supporting functions
- consists of cells in a variable amount of extracellular material know as the extracellular matrix
- the extracellular matrix has a fibrillar component of collagen and elastic fibers and an amorphous component of glycosaminoglycans

2.1 **Connective tissue proper** – possesses many cells in an extracellular matrix and has a gel-like consistency
2.1.1 **Loose connective tissue** – fills spaces between organs and can be found in the walls of organs beneath the mucosa
2.1.2 **Dense connective tissue** – makes up ligaments, tendons and articular capsules
2.2 **Cartilage tissue** – is composed of cells in an extracellular matrix and has a solid but elastic consistency
2.2.1 **Hyaline cartilage** – is located on the contact surfaces of bones inside joints and forms epiphyseal growth plates
– is integral in the process of bone healing, is found in the wall of the trachea and bronchi and forms part of the ribs
2.2.2 **Fibrous cartilage** – is found in intervertebral discs and in the pubic symphysis
2.2.3 **Elastic cartilage** – is found in the auricle of the ear and in the epiglottis
2.3 **Bone/osseous tissue** – is composed of a small proportion of cells in a firm extracellular matrix that is mineralised by calcium

3 **Muscle tissue** – is made up of cells that contain myofibrils (actin and myosin), which give them the ability to contract
3.1 **Smooth muscle tissue** – is found in the walls of organs and vessels and is innervated by the autonomic nervous system
3.2 **Skeletal striated muscle tissue** – is located on the skeleton and innervated by somatomotor cranial and spinal nerves
3.3 **Striated cardiac muscle** – is found only in the heart and has its own electrical conduction system

4 **Nerve tissue** – is made up of neurons and supporting cells (neuroglia)
4.1 **Neurons** – cells that are able to accept, process and transmit impulses
4.2 **Neuroglia** – protect and support neurons

+ **"Liquid/trophic tissue"** – comprises interstitial fluid, blood and lymph

Embryology is a scientific field concerned with the **creation and development of the embryo and foetus, all the way from a fertilised oocyte to birth**. Embryology also deals with anomalies that occur during development that give rise to **congenital defects**. The **3 germ layers** arise during the third week of the development in the form of the **trilaminar germ disc**, which comprises the endoderm, mesoderm and ectoderm. **The pharyngeal arches** originate from mesenchyme as pairs of arc–shaped prominences **in the region of head and neck** of the embryo during the fourth and fifth week of development.

Developmental periods

1. **Prenatal/gestation/intrauterine period** – extends from fertilisation to birth
   1.1 **Fertilisation** – the process of fusion of an egg and a sperm to form a zygote
   1.2 **Blastogenesis** – occurs during the first two weeks after the fertilisation
   – under unfavourable external influences only two things can happen following the "all or nothing principle": either the embryo will survive or it will be aborted
   1.3 **Embryonic period** – extends from fertilisation to the end of the eighth week
   – all organ systems are formed
   – the embryo is most vulnerable to toxic, radioactive, metabolic, pharmacological and other influences that may cause developmental defects
   1.4 **Foetal period** – extends from the end of the 8th week to birth
   – the organ systems continue to grow and develop
2. **Perinatal period** – starts at the beginning of the 28th week of intrauterine development and ends one week after birth
3. **Postnatal period** – extends from birth to death

Primary germ layers

1 **Ectoderm** – the outer layer of the trilaminar germ disc
– differentiates to form epithelial tissues including the epithelium of the skin and its appendages (hair, nails and sweat glands), the epithelium of the inital and terminal parts of the gastrointestinal tract, the adenohypophysis and the neurogenic placodes
1.1 **Neuroectoderm** – a derivative of the ectoderm that gives rise to the neural tube and the neural crest
– the neural tube differentiates into the brain and the spinal cord
– the cells of the neural crest migrate to various part of the body
– the neural crest forms the peripheral nerves and ganglia, fibrous tissue in the head and neck, melanocytes, the receptors cells of the carotid body, the medulla of the suprarenal glands and some structures in the heart
2 **Mesoderm** – the middle layer of the trilaminar germ disc
2.1 **Paraxial mesoderm** – forms somites, which develop into bones, muscles and the dermis
2.2 **Intermediate mesoderm** – forms the urogenital tract
2.3 **Lateral plate mesoderm** – forms the body wall
+ **Mesenchyme** – embryonic connective tissue that forms vessels, smooth muscles, haematopoietic tissue and mature connective tissue
3 **Endoderm** – the inner layer of the trilaminar germ disc
– gives rise to the epithelium of the liver, pancreas, gastrointestinal tract (apart from the mouth, nasopharynx and anus), auditory tube, trachea, bronchi, alveoli, urinary bladder, upper part of the urethra, thyroid gland, parathyroid glands and thymus

Pharyngeal arches *(arcus pharyngei)*

Each pharyngeal arch contains an artery, muscle tissue, a cranial nerve and a connective tissue element of cartilage, ligament or bone.

- 1 **First pharyngeal arch**
  bones: mandible, maxilla, zygomatic bone, malleus and incus
  muscles: masticatory muscles, anterior belly of the digastricus, mylohyoid, tensor veli palatini and tensor tympani
  cranial nerve: trigeminal nerve
  artery: terminal part of the maxillary artery
- 2 **Second pharyngeal arch**
  bones: stapes, styloid process and the lesser horn and upper part of the body of the hyoid bone
  muscles: mimetic muscles, platysma, stapedius, stylohyoid and the posterior belly of the digastricus
  cranial nerve: facial nerve; **artery:** stapedial artery
- 3 **Third pharyngeal arch**
  bones: greater horn and the lower part of the body of the hyoid bone
  muscles: stylopharyngeus
  cranial nerve: glossopharyngeal nerve;
  artery: common carotid artery and the first part of the internal carotid artery
- 4 **Fourth and sixth pharyngeal arch**
  cartilage: laryngeal skeleton
  muscles: musculature of the pharynx and larynx
  cranial nerve: vagus nerve - the superior laryngeal nerve is from the 4th arch and the recurrent laryngeal nerve is from the 6th arch
  artery: the aortic arch and right subclavian artery are from the 4th arch and the pulmonary arteries and ductus arteriosus are from the 6th arch

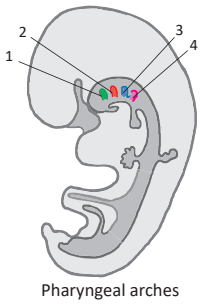

Pharyngeal arches in the embryo

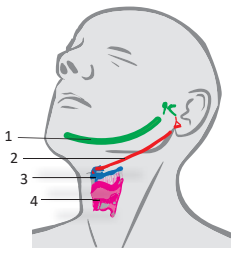

Derivatives of the pharyngeal arches

This copy belongs to ali yaghoubi

In comparison to other animals, **the human undergoes an extraordinary process of growth and development during childhood and puberty**. The two major periods of acceleration of growth are in **infancy** and **puberty**. Growth in-between these periods is slower. This allows time for the child to develop psychologically before undergoing **full physical transformation into adulthood**. Organs and organ systems grow both **isometrically** (proportionally) and **allometrically** (disproportionally) in relation to other organs and organ systems.

Head

Proportions of the head to the rest of the body
– the head forms half the length of the embryo in the 6th–7th week of intrauterine development
– the length of the head equals one quarter the length of the newborn at birth
– the circumference of the head and thorax are equal by the 5th month of life and from this moment onwards the thorax will grow faster
– the head is the fastest growing part of the body in the 1st year of life
– the head forms about one eighth the length of the body in adulthood

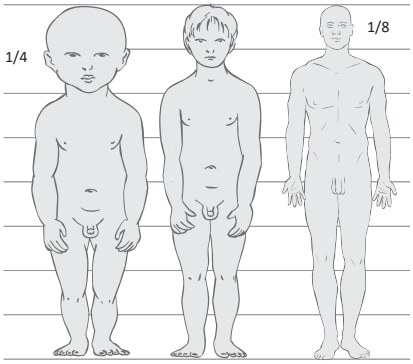

Thorax

Heart – in childhood, the proportion of the weight of the heart to the rest of the body is about twice as high as it is in adulthood
Lungs and respiratory passage – the lower respiratory tract elongates until the 1st year and then enlarges only in diameter
– the number of alveoli increases until the 8th year of life and then only increase in size
Oesophagus – is about half the length of the trunk in newborns
– is about one quarter the length of the trunk in adults

Abdomen

Stomach – the ratio of the weight of the stomach to the rest of the body is highest in children
Liver – forms about 5 % of body weight in children and about 2.5 % of body weight in adults
Kidneys – the final number of nephrons is reached by the 35th–36th week of intrauterine development
Testes – are formed in the lumbar region
– in the 3rd month of intrauterine development, the unequal growth of the thorax and the traction of the gubernaculum testis begin to move the testes caudally through the retroperitoneum and inguinal canal into the scrotum
– by the 8th month of intrauterine development, the testes are fully descended in the scrotum

Central nervous system

The weight of the brain – about 300–400 g in newborns or approximately 10 % of total body weight
– gyri and sulci appear on the surface of the cerebral cortex in the 4th month of intrauterine life
– reaches 75 % of the weight of an adult brain by the end of the 1st year of life
– reaches 100 % the weight of an adult brain in the 15th year of life
– the adult brain weighs 1300–1400 g, which is approximately 2% of total body weight
– the increase in brain weight after birth is caused mainly by myelination and an increase in the number of neuroglial cells
Spinal cord – is as long as the vertebral canal at the start of embryonic development
– the vertebral canal grows faster than the spinal cord from the 3rd month of intrauterine development
– the spinal cord therefore does not fill out the whole length of the vertebral canal
– the final level of the caudal border of the spinal cord is L1 – L2

The anterior fontanelle *(fonticulus anterior)* closes during the 1st–3rd year of life. **The posterior fontanelle** *(fonticulus posterior)* usually closes by the 3rd month of life. However it may already be closed at birth.

The volume of cerebrospinal fluid in a newborn born by a spontaneous vaginal delivery is about half that of a newborn born by a Caesarean section. During the baby's passage through the birth canal, the cerebrospinal fluid is forced into the venous sinuses.

The menarche is the onset of menstruation in girls. It is one of the first signs of puberty and appears between the 10th–17th year of age. In Central Europe, it usually occurs between the 12th–13th year of age. In the last couple of decades sexual maturation has been occurring progressively earlier.

The onset of puberty has been occurring earlier in life and the average height of the population has been steadily increasing over the last century. This phenomenon, known as **"the secular trend of puberty''** has been attributed to a better quality of nutrition.

The skull of a newborn is discussed on page 35.
The descent of testes is discussed on page 241.
The anatomy of pregnancy, the embryo and birth are discussed on page 257.
Vertebromedullary topography is described on page 398.
Psychomotor development is discussed on page 478.
The breast and mammary gland is described on page 517.

Clinical notes

A prominent pulsating fontanelle can be a sign of increased intracranial pressure, meningitis or other serious conditions. A sunken fontanelle on the other hand can indicate poor hydration of the baby.

Premature puberty *(pubertas praecox)* is characterised by onset of secondary sex characteristics before the 8th year in girls and before the 9th year in boys. It occurs in about 0.6 % of all children, more often in girls.

Pubertas tarda is a term for delayed puberty.

During puberty, the process of **psychosomatic maturation** of a child into an adult takes place. This process is accompanied by a set of **anatomical and physiological changes** that are integrally linked to each other. Using these changes to evaluate the stage of puberty is far more informative than relying solely on the age of the child. The onset of these changes can vary in children of the same sex in the range of 3–4 years. Generally speaking, **puberty starts in males 1–2.5 years later than in females**. **The Tanner scale** is commonly used to assess the level of changes occurring during puberty. In males, the growth of pubic hair, testes, penis and scrotum are evaluated. In females, development of breasts and the growth of pubic hair are evaluated.

Pubic hair in both genders

Stage Ph1 (< 10 years of age)
– no pubic hair
Stage Ph 2 (10–11.5 years of age)
– a small amounts of long fine weakly pigmented hair located around the root of the penis and the scrotum in males and on the mons pubis and labia majora in females
Stage Ph 3 (11.5–13 years of age) – the hair becomes darker, thicker and curly and spreads out on the skin overlying the pubic symphysis
Stage Ph 4 (13–15 years of age)
– the pubic hair is of adult type in quality, but in a smaller amount than in an adult
– in girls, the pubic hair covers a triangular shaped area of skin on the mons pubis and labia majora
Stage Ph 5 (>15 years of age)
– pubic hair of an adult, grows on adjacent parts of thighs
– female type: the upper border of the pubic hair is sharp and horizontally straight
– male type: usually continues cranially in a narrow triangle reaching as high as the navel

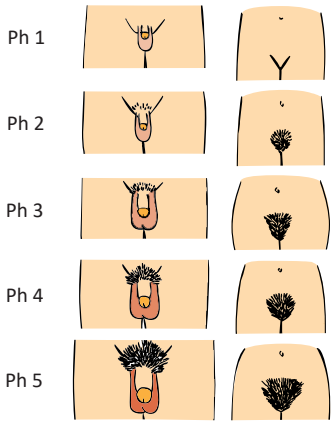

Male external genital organs

Stage G 1 (< 9 years of age)
– the volume of the testes is less than 1.5 ml
– the size of penis is 3 cm or less
Stage G 2 (9–11 years of age) – the volume of the testes is 1.6–6 ml
– the scrotum and testes enlarge
– the skin of the scrotum becomes thinner, wider and reddish
– the length of the penis remains unchanged
Stage G 3 (11–12.5 years of age) – the volume of the testes is 6–12 ml
– the scrotum and penis enlarge
– the penis grows to about 6 cm in length
Stage G 4 (12.5–14 years of age) –the volume of the testes is 12–20 ml
– the scrotum enlarges and becomes darker coloured
– the penis grows to about 10 cm in length
– the rate of growth of the width of the penis increases
Stage G 5 (> 14 years of age) – the volume of the testes is greater than 20 ml
– the external genital organs reach adult size and shape
– the length of the penis is approximately 15 cm

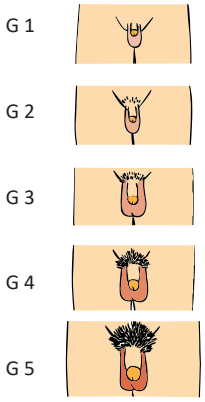

Male external genital organs

Female breast

Stage M 1 (<10 years of age) – *mamma puerilis / mamma neutralis*
– no gland tissue is present
– the unpigmented areola is in the same plane as the skin
Stage M 2 (10–11.5 years of age) – *mamma areolata*
– a small mass of glandular tissue is palpable in the area of the areola
Stage M 3 (11.5–13 years of age) – the breast is pointy and cone-shaped
– the gland grows beyond the margins of the areola
Stage M 4 (13–15 years of age) – the areola is raised above the plane of the skin
– the areola is slightly pigmented
– the areolar tubercles of the areolar glands are not visible
– the nipple is not yet erectile
Stage M 5 (>15 years of age) – the definitive appearance of a mature breast
– the areola is again in the same plane as the skin
– the areola is hyperpigmented
– the areolar tubercles are visible on the surface of the areola
– the nipple is erectile

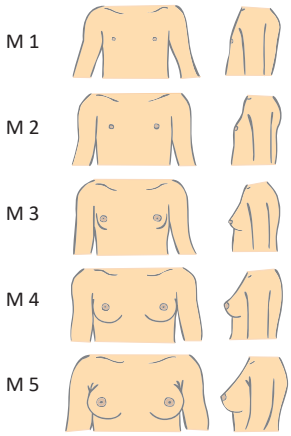

Female breast

This copy belongs to ali yaghoubi

To avoid confusion, the structures of the human body are described in a specific posture. This posture is called **the anatomical position and is an upright posture with the upper limbs on the sides of the body with the palms facing forward.** To help us orientate structures on the human body, we use **three principle perpendicular planes of reference**. These are the sagittal plane, the frontal plane and the transverse plane. **The sagittal plane** runs through the body from the back to the front. **The frontal plane** is parallel to the forehead and divides the body into posterior and anterior portions. **The transverse plane** runs through the body horizontally, dividing it into cranial and caudal portions. **The mid-sagittal or median plane** is a sagittal plane found **exactly at the midpoint of the body** and cuts the body into **symmetrical left and right halves.**

Planes of the human body *(plana corporis humani)*

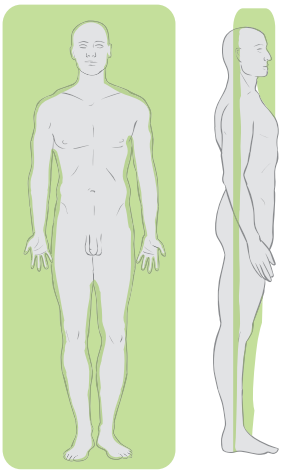

● **Frontal plane** / coronal plane (*planum frontale*)

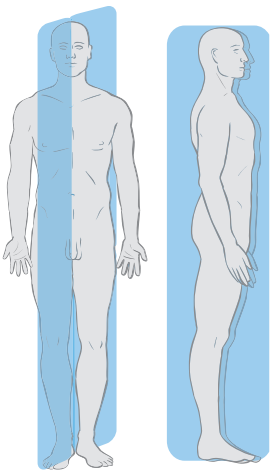

● **Sagittal plane** (*planum sagittale*)

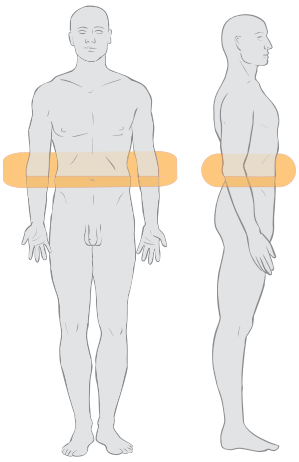

● **Transverse plane** / horizontal plane / axial plane / cross-section (*planum transversalium*)

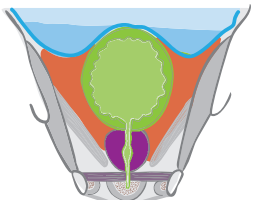

Frontal section of the male pelvis

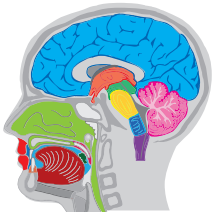

Sagittal section of the head

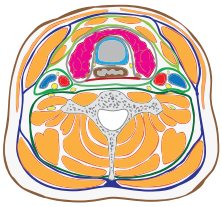

Transverse section of the neck

Lines of the human body *(lineae corporis humani)*

- 1 **Anterior median line** *(linea mediana anterior)* – runs vertically through the centre of the thorax and abdomen
- 2 **Sternal line** *(linea sternalis)* – runs vertically along the lateral side of the sternum
- 3 **Parasternal line** *(linea parasternalis)* – runs vertically in-between the sternal and midclavicular line
- 4 **Midclavicular line** *(linea medioclavicularis)* – runs vertically through the midpoint of the clavicle
- 5 **Anterior axillary line** *(linea axillaris anterior)* – runs vertically through the anterior axillary skin fold
- 6 **Midaxillary line** *(linea axillaris media)* – runs vertically through the apex of the axilla
- 7 **Posterior axillary line** *(linea axillaris posterior)* – runs vertically through the posterior axillary skin fold
- 8 **Scapular line** *(linea scapularis)* – runs vertically through the middle of the inferior angle of the scapula
- 9 **Paravertebral line** *(linea paravertebralis)* – runs vertically along the side of the vertebral column
- 10 **Posterior median line** *(linea mediana posterior)* – runs vertically through the middle of the vertebral column, passing through the spinous processes of the vertebrae

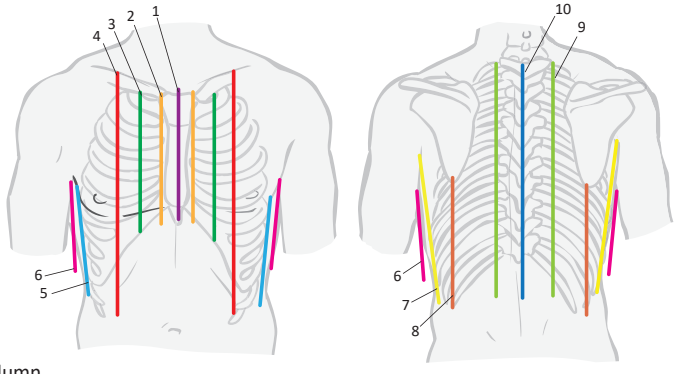

Lines of the human body

Locations and directions are basic orientation descriptions used in both gross and clinical anatomy. They are not only used to describe individual organs but are also used in **topographical anatomy** to decribe the spatial relationships of one organ to another.

Locations and directions used on the whole body

- 1 **Anterior** – towards the front
- 2 **Posterior** – towards the back
- 3 **Superior** – upwards
- 4 **Inferior** – downwards
- 5 **Internal/inner** (*internus*)
- 6 **External/outer** (*externus*)
- 7 **Superficial** *(superficialis)*
- 8 **Deep** *(profundus)*
- 9 **Right** *(dexter)*
- 10 **Left** *(sinister)*
- 11 **Cranial** (*cranialis*) – towards the head
- 12 **Caudal** (*caudalis*)– towards the tail bone
- 13 **Ventral** (*ventralis*) – towards the front
- 14 **Dorsal** (*dorsalis*) – towards the back
- 15 **Medial** *(medialis)* – towards the centre of the body or towards the axis of the limb
- 16 **Lateral** *(lateralis)* – away from the centre of the body or away from the axis of the limb
- 17 **Ipsilateral** – refers to something on the same side of the body
- 18 **Contralateral** – refers to something on the opposite side of the body

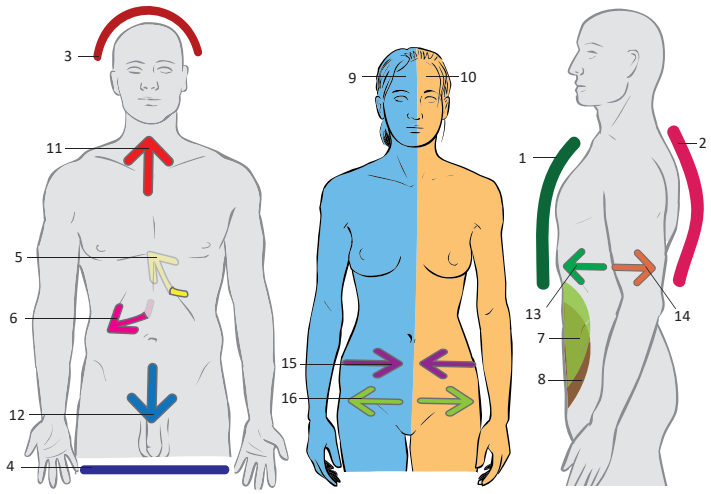

Locations and directions used on the limbs

Directions on the upper and lower limbs:

- 1 **Proximal** (*proximalis*) – towards the trunk
- 2 **Distal** *(distalis)* – away from the trunk
- 3 **Medial** *(medialis)* – towards the middle axis
- 4 **Lateral** *(lateralis)* – away from the middle axis

Directions on the upper limb:

- 5 **Ulnar** *(ulnaris)* – on or towards the ulnar side of the forearm
- 6 **Radial** *(radialis)* – on or towards the radial side of the forearm
- 7 **Palmar**/volar *(palmaris/volaris)* – on or towards the palm
- 8 **Dorsal** *(dorsalis)* – on or towards the dorsum of the hand

Directions on the lower limb:

- 9 **Tibial** *(tibialis)* – on or towards the tibial side of the leg
- 10 **Fibular**/peroneal *(fibularis/peroneus)* – on or towards the fibular side of the leg
- 11 **Plantar** *(plantaris)* – on or towards the sole
- 12 **Dorsal** *(dorsalis)* – on or towards the dorsum of the foot

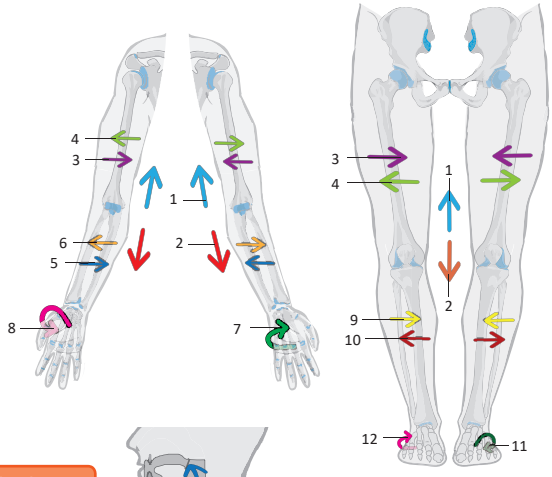

Terms of direction specific for the gastrointestinal tract and the brain

Directions in the gastrointestinal tract:

- 1 **Oral** *(oralis)* – towards the oral cavity
- 2 **Aboral** *(aboralis)* – towards the anal canal

Directions in the brain:

- 3 **Rostral/frontal/cranial** *(rostralis/frontalis/cranialis)* – towards the forehead
- 4 **Caudal/occipital** *(caudalis/occipitalis)* – towards the occiput
- 5 **Dorsal** *(dorsalis)* – towards the cranial vault (calvaria)
- 6 **Ventral/basal** *(ventralis/basalis)* – towards the cranial base

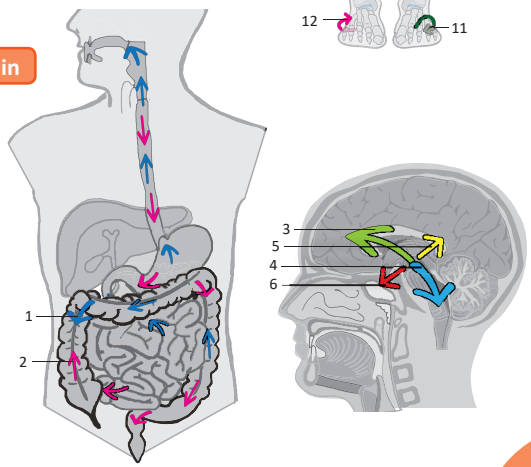

This copy belongs to ali yaghoubi

The following terms are used to describe **specific parts of the human body in the standard anatomical position. Constitutional typology** describes body shape according to the height and width of the body, length of the limbs and the amount of muscle and body fat.

Parts of the human body *(partes corporis humani)*

1 **Head** *(caput)*
2 **Neck** *(collum)*
3 **Shoulder** *(omos)*
4 **Axilla, armpit** *(axilla)*
5 **Arm** *(brachium)*
6 **Elbow** *(cubitus)*
7 **Forearm** *(antebrachium)*
8 **Wrist** *(carpus)*
9 **Hand** *(manus)*
10 **Palm** *(palma, vola)*
11 **Thenar eminence** *(thenar / eminentia thenaris)*
12 **Hypothenar eminence** *(hypothenar / eminentia hypothenaris)*
13 **Thumb** *(pollex / digitus primus)*
14 **Index finger** *(index / digitus secundus)*
15 **Middle finger** *(digitus medius/tertius)*
16 **Ring finger** *(digitus anularis/quartus)*
17 **Little finger** *(digitus minimus/quintus)*
18 **Thorax**
19 **Front of chest** *(pectus)*
20 **Abdomen**
21 **Navel** *(umbilicus)*
22 **Pelvis**
23 **Groin** *(inguen)*
24 **Hip** *(coxa)*
25 **Thigh** *(femur)*
26 **Knee** *(genu)*
27 **Leg** *(crus)*
28 **Ankle** *(tarsus)*
29 **Metatarsus**
30 **Foot** *(pes)*
31 **Toes** (*digiti pedis*)
32 **Big toe** *(hallux / digitus primus)*
33 **Nape of neck** *(nucha)*
34 **Upper limb** *(membrum superius)*
35 **Dorsum of hand** *(dorsum manus)*
36 **Fingers** *(digiti manus)*
37 **Back** *(dorsum)*
38 **Loin** *(lumbus)*
39 **Buttocks** *(nates/clunes)*
40 **Lower limb** *(membrum inferius)*
41 **Posterior side of knee** *(poples)*
42 **Calf** *(sura)*
43 **Heel** *(calx)*
44 **Sole** *(planta)*

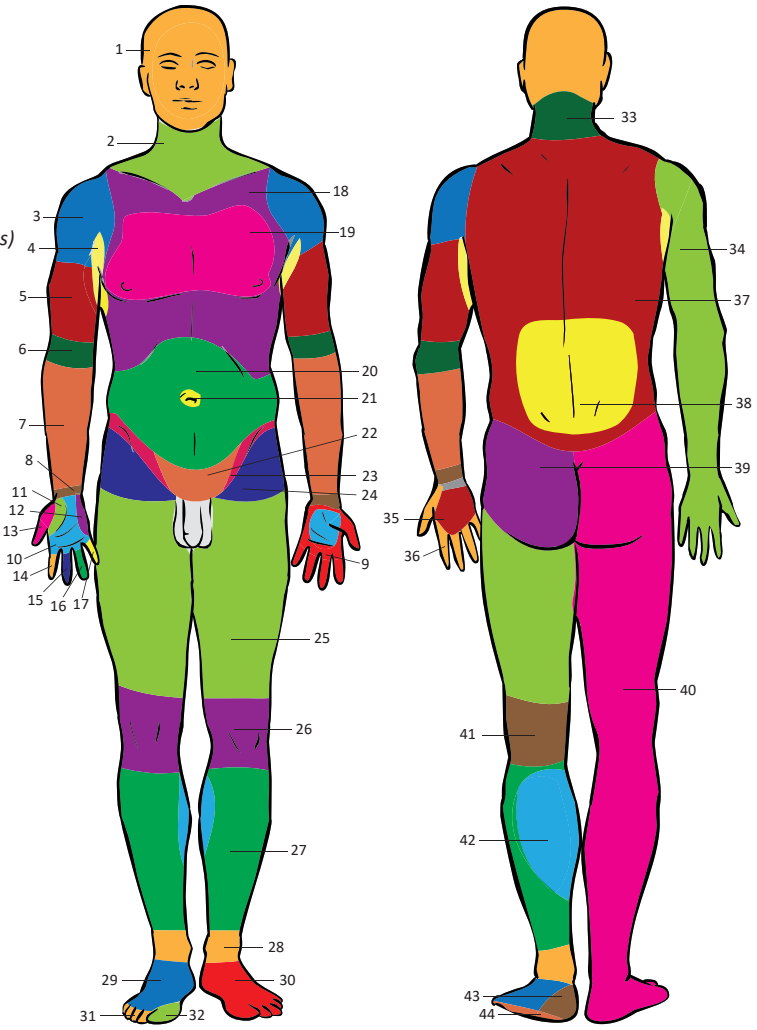

Constitutional typology

Asthenic type / ectomorph
– weak skeleton, poorly developed muscles
– slim trunk, long limbs, small head and oblong shaped face
Athletic type / mesomorph
– strong skeleton, well developed muscles
– long head with flat nose
– prominent bones of the face forming sharp facial features
Pyknic type / endomorph
– fat stocky figure
– round head with a wide straight nose

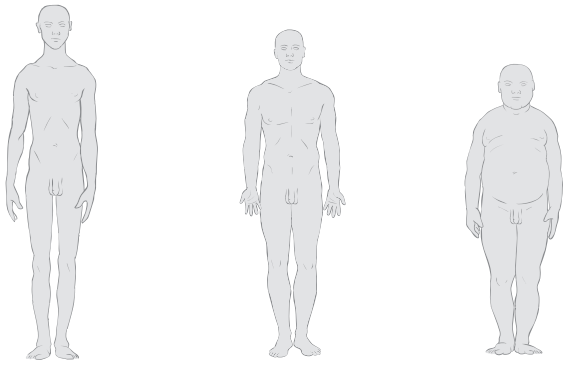

Asthenic type Athletic type Pycnic type

Regions of the human body (*regiones corporis humani*)

Regions of the head *(regiones capitis):*

- 1 **Frontal region** (*regio frontalis*)
- 2 **Parietal region** (*regio parietalis*)
- 3 **Occipital region** (*regio occipitalis*)
- 4 **Temporal region** (*regio temporalis*)
- 5 **Auricular region** (*regio auricularis*)
- 6 **Mastoid region** (*Regio mastoidea*)

Facial regions *(regio facialis):*

- 7 **Orbital region** (*regio orbitalis*)
- 8 **Infra-orbital region** (*regio infraorbitalis*)
- 9 **Buccal region** (*regio buccalis*)
- 10 **Parotid region** (*regio parotideomasseterica*)
- 11 **Zygomatic region** (*regio zygomatica*)
- 12 **Nasal region** (*regio nasalis*)
- 13 **Oral region** (*regio oralis*)
- 14 **Mental region** (*regio mentalis*)

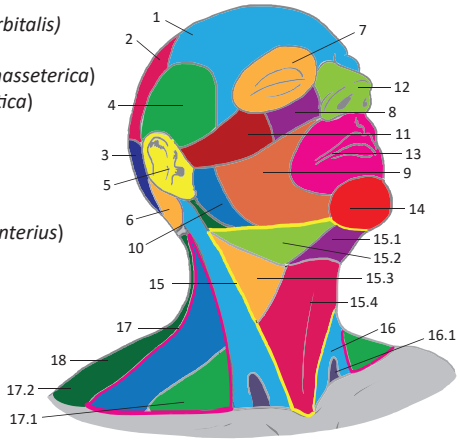

Regions of the head and neck

Regions of the neck *(regiones cervicales):*

- 15 **Anterior cervical region/triangle** (*regio cervicalis anterior / trigonum cervicale anterius*)
  - 15.1 **Submental triangle** (*trigonum submentale*)
  - 15.2 **Submandibular triangle** (*trigonum submandibulare*)
  - 15.3 **Carotid triangle** (*trigonum caroticum*)
  - 15.4 **Muscular/omotracheal triangle** (*trigonum musculare/omotracheale*)
- 16 **Sternocleidomastoid region** (*regio sternocleidomastoidea*)
  - 16.1 **Lesser supraclavicular fossa** (*fossa supraclavicularis minor*)
- 17 **Lateral cervical region / posterior triangle of the neck** (*regio cervicalis lateralis / trigonum cervicale laterale*)
  - 17.1 **Omoclavicular triangle / subclavian triangle** (*trigonum omoclaviculare*)
  - 17.2 **Omotrapezoid triangle** (*trigonum omotrapezium*)
- 18 **Posterior cervical region** (*regio cervicalis posterior*)

Thoracic regions *(regiones thoracicae):*

- 1 **Parasternal region** *(regio presternalis)*
- 2 **Clavicopectoral/deltopectoral triangle** *(trigonum clavipectorale/deltopectorale)*
- 3 **Pectoral region** *(regio pectoralis)*
- 4 **Mammary region** *(regio mammaria)*
- 5 **Inframammary region** *(regio inframammaria)*
- 6 **Axillary region** *(regio axillaris)*

Abdominal regions *(regiones abdominales)*:

- 7 **Epigastric region** (*regio epigastrica / epigastrium*)
- 8 **Hypochondrium** *(regio hypochondriaca / hypochondrium)*
- 9 **Umbilical region** *(regio umbilicalis / mesogastrium)*
- 10 **Lateral region** *(regio lateralis / mesogastrium)*
- 11 **Pubic region** *(regio pubica / hypogastrium)*
- 12 **Inguinal region** *(regio inguinalis / hypogastrium)*

Regions of the back *(regiones dorsales):*

- 13 **Vertebral region** *(regio vertebralis)*
- 14 **Scapular region** *(regio scapularis)*
- 15 **Infrascapular region** *(regio infrascapularis)*
- 16 **Lumbar region** *(regio lumbalis)*
- 17 **Sacral region** *(regio sacralis)*

Perineal region *(regio perinealis):*

- 18 **Anal triangle** *(regio analis)*
- 19 **Urogenital triangle** *(regio urogenitalis)*

Regions of the upper limb *(regiones membri superioris):*

- 20 **Deltoid region** *(regio deltoidea)*
- 21 **Brachial region** *(regio brachialis)*
- 22 **Cubital region** *(regio cubitalis)*
- 23 **Antebrachial region** *(regio antebrachialis)*
- 24 **Carpal region** *(regio carpalis)*
- 25 **Hand region** *(regio manus)*

Regions of the lower limb *(regiones membri inferioris):*

- 26 **Gluteal region** *(regio glutealis)*
- 27 **Hip region** *(regio coxae)*
- 28 **Femoral region** *(regio femoris)*
- 29 **Knee region** *(regio genus)*
- 30 **Popliteal region** *(regio poplitea)*
- 31 **Leg region** *(regio cruris)*
- 32 **Ankle region** *(regio tarsalis)*
- 33 **Foot region** (*regio pedis*)

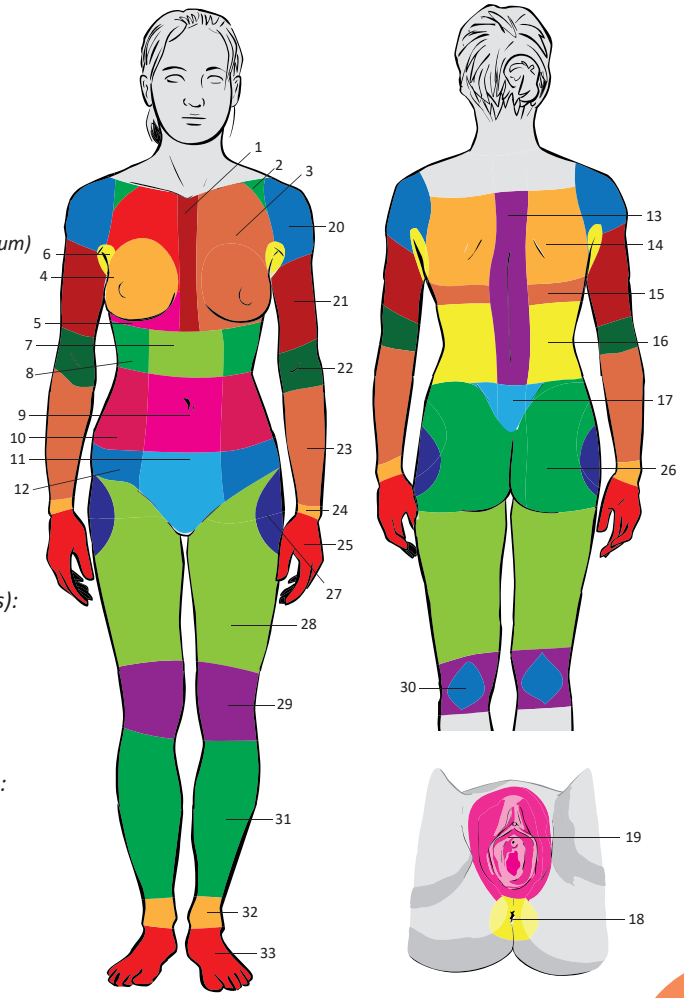

This copy belongs to ali yaghoubi

Anatomical terminology uses **eponyms**. Eponyms are terms named after the person that discovered or described the anatomical structure. Their use lies **predominantly in clinical anatomy.**

1. **ACHILLES** **Achilles' tendon** – the tendon of the triceps surae, named after a Greek mythological warrior
2. **ALCOCK** **Alcock's canal** – a space on the inner side of the obturator internus
3. **ARANTIUS** **Arantius' duct** – a shunt found in the foetus that allows blood to pass from the umbilical vein to the inferior vena cava, bypassing the liver
4. **ASCHOFF** **Aschoff-Tawara's node** – the AV node of the conducting system of the heart
5. **AUERBACH** **Auerbach's myenteric plexus** – a nervous plexus within the muscular layer of the gastrointestinal tract
6. **BARTHOLINUS** **Bartholin's glands** – mucous glands in the vestibule of the vagina
   Bartholin's duct – the largest excretory duct of the sublingual salivary gland
7. **BAUHIN** **Bauhin's valve** – a narrowing at the transition between the small and large intestines
8. **BILLROTH** **Cords of Billroth** – the red pulp cords between sinusoids in the spleen
9. **BOCHDALEK** **Bochdalek's triangle** – a triangular defect between the lumbar and costal parts of the diaphragm
   Bochdalek' flower spray – a protrusion of the choroid plexus of the fourth ventricle through the lateral aperture into the subarachnoid space
10. **BÖHME** **Cannon-Böhm point** – a point located between the middle and left thirds of the transverse colon that marks the transition of parasympathetic innervation from the vagus nerve to the sacral splanchnic nerves
11. **BOTALLO** **Ductus Botalli** – a foetal shunt connecting the pulmonary trunk to the aortic arch
12. **BOWMAN** **Bowman's capsule** – a sac, enclosing the glomerulus, forming the first part of the nephron
13. **BROCA** **Broca's area** – an area of cortex located in the posterior part of the inferior frontal gyrus in the speech dominant hemisphere (Brodman areas 44 and 45)
14. **BRODMANN** **Brodman's map** – a cytoarchitectural map of the cerebral cortex
15. **CAJAL** **Cajal's nucleus** – a group of neurons located in the periaqueductal grey substance of the tegmentum of the midbrain
16. **CALOT** **Calot's triangle** – an anatomical space containing a potential ligation site of the cystic atery
17. **CAMPER** **Fascia of Camper** – a fibrous-adipose layer of the anterior abdominal wall
18. **CHOPART** **Chopart's joint** – a joint line located transversely through the tarsal bones
19. **CLARKE** **Stilling-Clarke's nucleus** – a nucleus located in the posterior horn of the spinal cord
20. **CLAUDIUS** **Claudius' fossa** – a slight depression that houses the ovary, located between the internal iliac vessels and the sacrum
21. **CLOQUET** **Cloquet's node** – the most proximal of the deep inguinal lymph nodes, located in the lacuna vasorum
22. **COCKETT** **Cockett's** perforators – three connections between the superficial and deep venous system, located on the medial side of the calf
23. **CORTI** **Organ of Corti** – the auditory organ proper
24. **DOUGLAS** **Pouch of Douglas**– the deepest space of the peritoneal cavity in women
25. **EUSTACHIO** **Eustachian tube** – the auditory tube, a connection between the nasopharynx and tympanic cavity,
    Eustachian valve – the valve of the inferior vena cava, located in the right atrium of the heart
26. **FALLOPPIO** **Fallopian canal** – the part of the facial canal located in the petrous part of the temporal bone
    Fallopian tube – the uterine tube
27. **FLACK** **Keith-Flack's node** – the SA node of the conducting system of the heart
28. **FROHSE** **Frohse's arcade** – a fibrous arch in the supinator canal
29. **GALENOS** **Vein of Galen** – the largest cerebral vein, drains blood from the deep parts of the brain into the straight sinus
30. **GASSER** **Gasser's ganglion** – the sensory ganglion of the trigeminal nerve
31. **GEROTA** **Gerota's fascia** – covers the perinephric fat capsule
32. **GOLGI** **Golgi complex** – a cellular organelle
    Golgi tendon organ – a proprioceptor found in tendons
33. **GRAAF** **Graafian follicle** – the mature ovarian follicle
34. **GUYON** **Guyon's canal** – a space on the wrist through which the ulnar neurovascular bundle enters the hand
35. **HALLER** **Tripus Halleri** – the coeliac trunk, a branch of the aorta that trifurcates into three visceral branches
    Haller's anastomosis – an arterial connection between the branches of the superior and inferior mesenteric artery
36. **HAVERS** **Haversian system** – the osteon, a complex of concentric lamellae of bone surrounding the Haversian canal
    Haversian canal – the canal of the osteon, contains vessels, nerves and loose connective tissue
37. **HENLE** **Loop of Henle** – a loop in the nephron between the proximal and distal tubules
38. **HESSELBACH** **Hesselbach's triangle** – a weakening in the anterior abdominal wall where direct abdominal hernias occur
    Corona mortis of Hesselbach – an aberrant obturator artery crossing the linea terminalis and passing into the lesser pelvis
39. **HIGHMORE** **Antrum of Highmore** – the maxiliary sinus, an air-filled cavity in the maxillary bone
40. **HIS** **Bundle of His** – a part of the conducting system of the heart
41. **HUNTER** **Hunter's canal** – the adductor canal, a space on the medial side of the thigh through which the femoral vessels pass
42. **HYRTL** **Hyrtl's canal** – a space containing the fibular vessels, located between the flexor hallucis longus, interosseous membrane and fibula
43. **KEITH** **Keith-Flack node** – the SA node of the conducting system of the heart
44. **KIESSELBACH** **Kiesselbach's plexus** – a vascular plexus located in the nasal septum with a high propensity to bleed
45. **KILLIAN** **Killian's triangle** – a narrowing at the transition between the pharynx and oesophagus

46. KOHLRAUSCH **Kohlrauch's fold** – the right transverse fold of the rectum
47. LANGERHANS **Islets of Langerhans** – the hormone-producing part of the pancreas
48. LIEBERKÜHN **Crypts of Lieberkühn** – glands of the small intestine
49. LISFRANC **Lisfranc's joint** – an articular line located transversely through the metatarsal bones
50. LUSCHKA **Foramina of Luschka** – paired lateral openings draining cerebrospinal fluid from the fourth ventricle into the subarachnoid space
51. LUYS **Luys' body** – the subthalamicus nucleus of the diencephalon
52. MAGENDIE **Foramen of Magendie** – an unpaired median opening draining cerebrospinal fluid from the fourth ventricle into the subarachnoid space
53. MALPHIGI **Renal corpuscle of Malphigi** – the initial part of the nephron
54. McBURNEY **McBurney's point** – the projection of the appendix on the surface of the anterior abdominal wall
55. MECKEL **Meckel's cavity** – a cavity within the dura mater housing the trigeminal ganglion
56. MECKEL **Meckel's diverticle** – a blind variable developmental pouch located on the ventral side of the ileum
57. MEIBOM **Meibomian glands** – apocrine glands of the eyelid
58. MEISSNER **Meissner's plexus** – a nervous plexus in the submucosa of the gastrointestinal tract
Meissner's corpuscles – tactile receptors located in the dermis
59. MONRO **Foramina of Monro** – paired apertures connecting the lateral and third ventricles
Monro line – a line connecting the navel and right superior anterior iliac spine
60. MÜLLER **Müllerian duct** – the embryonic precursor of the female genital tract
61. ODDI **Sphincter of Oddi** – the sphincter of the bile duct
62. PAWLIK **Pawlik's triangle** (*area trigonalis vaginae*) – a triangular space where the anterior wall of vagina and the trigone of the urinary bladder are in contact
63. PEYER **Peyer's patches** – lymphoid nodules aggregated in the submucosa of the ileum
64. POUPART **Poupart's ligament** – the inguinal ligament
65. PURKYNĚ **Purkynje's (Purkyně's) fibers** – terminal branches of the conducting system of the heart located beneath the endocardium in the ventricles
Purkynje's (Purkyně's) cells – large efferent neurons within the Purkinje cell layer *(stratum purkinjese)* of the cerebellar cortex
66. RANVIER **Nodes of Ranvier** – gaps in the myelin sheath of neurons between Schwann's cells
67. RATHKE **Rathke's pouch** – a pouch in the upper part of the stomodeum that gives rise to the adenohypophysis
68. RETZIUS **Veins of Retzius** – retroperitoneal venous connections between the portal and caval venous systems
Retzius' space – a space between the pubic symphysis and the urinary bladder
69. REXED **Rexed laminae** – 10 layers of grey matter on the transverse section of the spinal cord
70. ROLANDO **Rolando's substance** – a nucleus located in the posterior horn of the spinal cord
Rolandic sulcus – the central sulcus of the cerebral cortex
71. SANTORINI **Santorini's papilla** – the opening of the accessory pancreatic duct into the duodenum
72. SCARPA **Fascia of Scarpa** – a subcutaneous fibrous layer of the anterior abdominal wall
73. SCHLEMM **Schlemm's canal** – a channel that drains aqueous humor into the bloodstream
74. SCHWANN **Schwann cells** – cells covering the axons in the peripheral nervous system
Schwann's sheath – the neurolemma, the outer layer of the Schwann cell
75. SORGIUS **Sorgius node** – the sentinel lymph node of spreading breast tumours, located on the second or third slip of the serratus anterior
76. STENSEN **Stensen duct** – the excretory duct of the parotid gland
77. SYLVIUS **Aqueduct of sylvius** – connects the third and fourth ventricles in the brainstem
Sylvian fissure – divides the frontal and parietal lobes from the temporal lobe
78. TAWARA **Tawara's branches** – right and left branches of the atrioventricular bundle in the conducting system of the heart
79. TREITZ **Muscle/ligament of Treitz** – the suspensory muscle (or ligament) of the duodenum extending from the right crus of the diaphragm to the duodenojejunal flexure
Treitz's retropancreatic membrane – the fibrous remnant of the dorsal mesoduodenum separating the pancreas from the great retroperitonal vessels
Treitz's intersigmoid recess – a peritoneal recess between the parietal peritoneum and the sigmoid mesocolon
80. VATER **Ampulla of Vater** – the common opening of the pancreatic duct and the bile duct in the duodenum
Vater-Pacinian corpuscles – tactile receptors in the skin
81. VIRCHOW **Virchow-Robin spaces** – pouches of the subarachnoid space located around vessels under the pia mater
Virchow-Troisier lymph nodes – the left supraclavicular lymph nodes
82. WALDEYER **Waldeyer's ring** – a group of tonsils arranged in a ring in the pharynx
83. WERNICKE **Wernicke's area** – an area of the cerebral cortex located in the superior temporal gyrus (Brodmann area 22) in the dominant hemisphere
84. WHARTON **Wharton's duct** – the excretory duct of the submandibular gland
Wharton's jelly – connective tissue in the umbilical cord
85. WILLIS **Circle of Willis** – a circular arterial anastomosis located at the base of the brain

This copy belongs to ali yaghoubi

I. Definitions and history

1. Explain the difference between anatomical terminology and nomenclature. (p. 2)
2. Explain the phrase “obsolete term”. (p. 2)
3. Explain what an eponym is. (p. 2)
4. Explain the difference between systematic and topographic anatomy. (p. 2)
5. State the author, year and name of the publication of the first modern textbook of anatomy. (p. 2)

II. Terms and abbreviations

6. List all the different structures termed “sinus”. (p. 3)
7. Explain the difference between the abbreviations “gl.” and “gll.”. (p. 3)
8. Define the abbreviations “l.sin.” and “l.dx.”. (p. 3)
9. Give the abbreviations of the terms “superior” and “inferior”. (p. 3)

III. Histology

10. Describe the function of the smooth and granular endoplasmic reticulum. (p. 4)
11. List all the components of the cytokeleton. (p. 4)
12. Name all the different types of epithelium and state where each type can be found. (p. 4)
13. Name three types of cartilage and describe where they can be found. (p. 4)
14. Name three types of muscle tissue and describe where they can be found. (p. 4)

IV. Embryology

15. Explain the term “primary germ layers”. (p. 5)
16. Name the parts of the human body that originate from the endoderm. (p. 5)
17. List all the places to which the cells of the neural crest migrate. (p. 5)
18. State which muscles have a branchiogenic origin. (p. 5)
19. State which cranial nerves innervate which muscles. (p. 5)
20. Define the embryogenic period. (p. 5)
21. Name the three primary germ layers and some structures that originate from them. (p. 5)
22. List the muscles that originate from each pharyngeal arch. (p. 5)

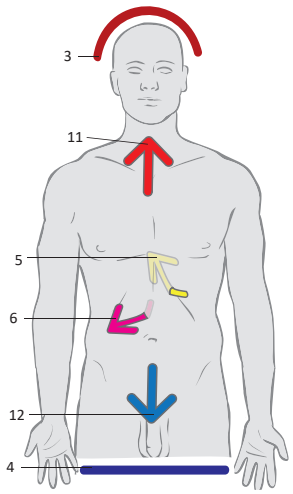

Describe the anatomical terminology for directions and locations

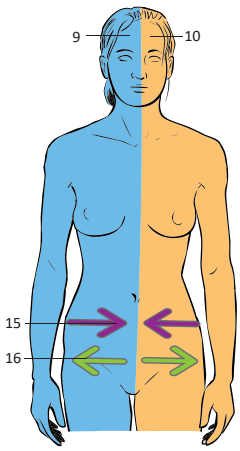

Describe the anatomical terminology for directions and locations

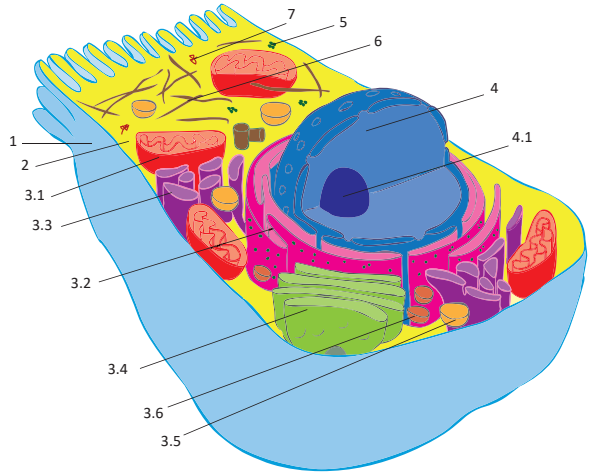

Name and describe the components of the eukaryotic cell

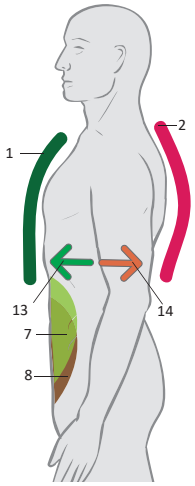

Describe the anatomical terminology for directions and locations

V. Anatomical changes in childhood

23. Define the term “menarche”. (p. 6)
24. State to which level the spinal cord extends in an adult and explain why. (p. 6)
25. State the weight of the brain of a newborn and an adult. (p. 6)
26. State all the organs that change location during development and explain why they do this. (p. 6)
27. Describe the changes of the ratio of the size of the head and trunk during development. (p. 6)

VI. Anatomical changes in puberty

28. Explain what is the Tanner scale. (p. 7)
29. Describe the shape changes of the breast in females. (p. 7)
30. List the different stages of development of the male external genital organs (p. 7)

VII. Planes and lines of the human body

31. Describe in detail the basic anatomical position. (p. 8)
32. Define the median plane. (p. 8)
33. State and define which lines go through the lateral side of the thorax. (p. 8)

VIII. Terms of direction and location

34. Define the term “contralateral”. (p. 9)
35. Explain the differences in terminology of direction on the trunk, limbs and brain. (p. 9)
36. List the terms of direction and location used on the upper limb. (p. 9)
37. Define the term “aboral”. (p. 9)

IX. Parts of the human body and constitutional typology

38. State the Latin term for the thumb and big toe. (p. 10)
39. Descibe the asthenic body type. (p. 10)

X. Regions of the human body

40. List the four regions of the neck and list the triangles that can be found in each region (p. 11)
41. List the six regions of the abdomen. (p. 11)

XI. Eponyms

42. List two structures named after J. E. Purkyně. (p. 12)
43. List the embryonal vascular ducts and explain their function. (p. 12–13)
44. List all lymph nodes that have eponyms. (p. 12–13)
45. State all parts of the body associated with the eponym “Treitz”. (p. 12)

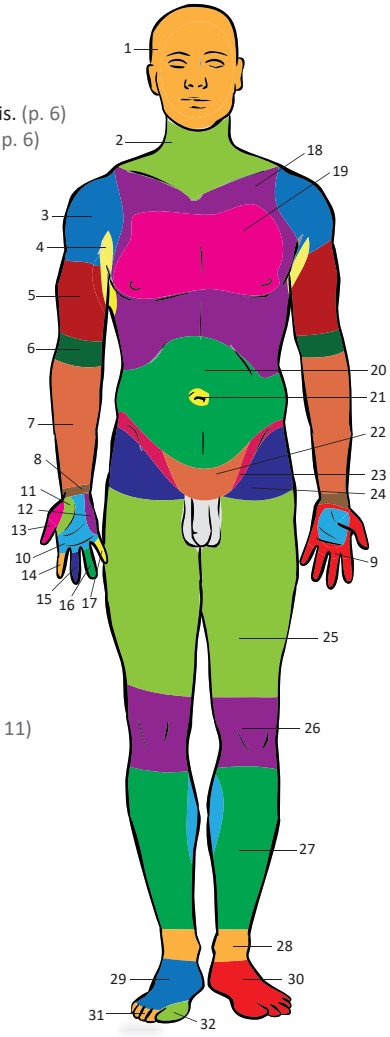

Describe the main regions of the human body

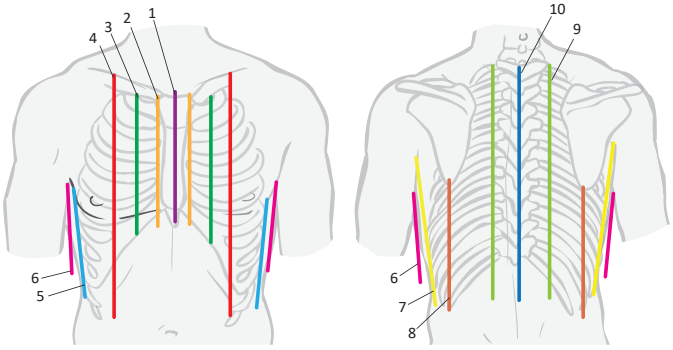

Describe the anatomical lines of the human body

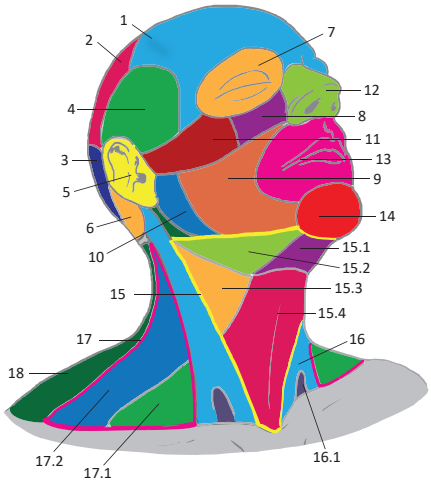

Describe the regions of the head and neck

This copy belongs to ali yaghoubi

We would like to **thank the following anatomists and medical students** for their endless help, devotion and feedback in the preparation of this chapter.

Anatomists

Assoc. prof. Václav Báča, MD, PhD – Department of Anatomy, Third Faculty of Medicine, Prague, Czech Republic
Emer. Prof. Stephen Carmichael, PhD, DSc. – Mayo Clinic, Rochester, USA

Medical students

Lucie Olivová
Rachel White
Klára Macháčková

13 References

1. ABRAHAMS, P. H.; SPRATT, J. D.; LOUKAS, M. and A. N. van SCHOOR. McMinn and Abrahams' Clinical Atlas of Human Anatomy: with Student Consult Online Access (Mcminn's Color Atlas of Human Anatomy). 7th Ed. Philadelphia: Mosby Elsevier, 2013, 388 p. ISBN 978-0723-43697-3.
2. AGUR, A. M. R. and A. F. DALLEY. Grant's Atlas of Anatomy. 13th Ed. Philadelphia: Lippincot Williams & Wilkins, 2012, 888 p. ISBN 978-1-60831-756-1.
3. FCAT. Terminologia anatomica: international anatomical terminology. Stuttgart: Thieme Verlag, 1998, 300 p. ISBN 978-3-13-114361-4.
4. CHUNG, K. W.; CHUNG, H. M. and N. L. HALLIDAY. BRS Gross Anatomy. 8th Ed. Philadelphia: Lippincott Williams & Wilkins, 2015. 544 p. ISBN 978-1-4511-9307-7.
5. LANZ, T. and W. WACHSMUTH. Praktische Anatomie. 7 bands. Berlin: Springer, 2003, 3658 p. ISBN 978-3-540-40571-9.
6. MOORE, K. L.; DALLEY, A. F. and A. AGUR. Clinically oriented anatomy. 7th Ed. Philadelphia: Lippincot Williams & Wilkins, 2014. 1139 p. ISBN 978-1-4511-1945-3.
7. NETTER, F. H. Atlas of Human Anatomy. Professional Edition. 6th Ed. Oxford: Elsevier. 2014. 640 p. ISBN 978-1-455-75888-3.
8. ROHEN, J. W. LUTJEN-DRECOLL, E. and C. YOKOCHI. Color Atlas of Anatomy: A Photographic Study of the Human Body. 7th Ed. Stuttgart: Lippincot Williams & Wilkins, 532 p. ISBN 978-1-58255-856-1.
9. WILLIAMS, P. L., ed. Gray´s Anatomy: the anatomical basis of medicine and surgery. 38th Ed. New York: Churchill Livingstone, 1995, 2092 p. ISBN 0-443-05717-6.

Memorix Anatomy

2 Bones



Martin Čepelík
David Kachlík
Radovan Hudák
Ondřej Volný
Adam Whitley

Contents of the book	VI
General overview	18
Skull	21
Vertebral column	37
Thorax	41
Bones of the upper limb	42
Bones of the lower limb	48
Figures – cranial base	57
Tables	58
Review questions and figures	64
Acknowledgements and references	66

This copy belongs to ali yaghoubi

Osteology is the study of bone (osseous) tissue. Bone tissue is a type of connective tissue characterised by a **hard mineralised ground substance, collagen fibres and specialised cells**. Bone tissue has **structural, supportive and protective functions**. **Ossification** is the formation of new bone either from a fibrous or cartilaginous model.

Overview of the skeleton

1 **Axial skeleton** *(skeleton axiale)*
- 1.1 **Skull** *(cranium)*
- 1.2 **Vertebral column** *(columna vertebralis)* – spine
- 1.3 **Thorax** *(skeleton thoracis)* – chest
  - 1.3.1 **Ribs** *(costae)*
  - 1.3.2 **Sternum** – breastbone

2 **Appendicular skeleton** *(skeleton appendiculare)* – skeleton of the limbs
- 2.1 **Bones of upper limb** *(ossa membri superioris)*
- 2.2 **Bones of lower limb** *(ossa membri inferioris)*

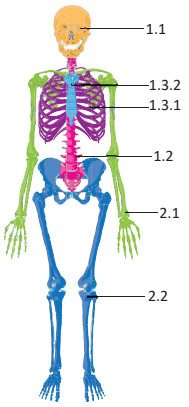

Overview of the skeleton

Types of bones

- 1 **Long bones** *(os longum)* – are characterised by a long shaft with articular facets on both ends
  – include the humerus, ulna, radius, femur, tibia, fibula, metacarpals, metatarsals and phalanges
- 2 **Short bones** *(os breve)* – are characterised by being roughly as long as they are wide
  – include the carpal bones and tarsal bones
- 3 **Flat bones** *(os planum)* – are characterised by being composed of two layers of compact bone with a layer of spongy bone in-between
  – include the sternum, scapula, ilium and several bones of the skull
  - 3.1 **Flat bones of the skull**
    – are composed of an internal table and external table composed of compact bone and a diploë composed of spongy bone
    – include the squamous part of the temporal, frontal and occipital bone
- 4 **Irregular bones** *(os irregulare)* – irregularly shaped bones that do not fit in any other category
  – include the temporal bone, vertebra, ischium and pubis
- 5 **Pneumatised bones** *(os pneumaticum)*
  – contain air-filled cavities
  - 5.1 include parts of the frontal bone, sphenoidal bone, ethmoidal bone and maxilla
  - 5.2 the tympanic cavity and mastoid air cells are pneumatised spaces in the temporal bone
- 6 **Sesamoid bones** *(os sesamoideum)*
  – are bones located inside tendons
  – include the patella and the sesamoid bones of the thumb and big toe

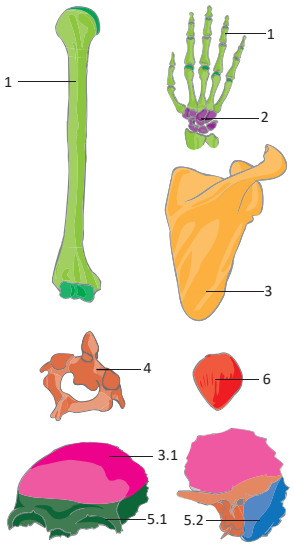

Types of bones

Parts of long bones

- 1 **Diaphysis** – the middle part of a long bone where the primary ossification centre is located
- 2 **Epiphysis** – the distal end of a long bone where the secondary ossification center is located
- 3 **Apophysis** – part of a bone (usually a tubercle) that contains a secondrary ossification centre but isn't an epiphysis
- 4 **Metaphysis** – is located between the epiphysis and diaphysis and has its own blood supply
  4.1 **Epiphyseal plate** *(lamina epiphysialis)*
  – contains growth cartilage (*cartilago epiphysialis*)
  – present only in children

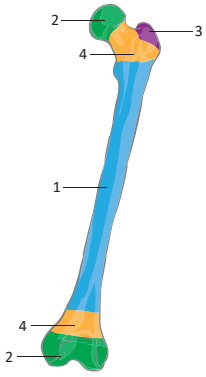

Parts of long bones

Bones

Os is the Latin term for bone and **osteon** is the Greek term.

Osteology is a science concerned with the study of bones.

The inorganic component of bones is approximately 60 % of total bone weight in adults and approximately 48 % in children.

The periosteum adheres firmly to the bone, but can still be separated from the surface. It adheres significantly less in children.

In clinical practice, the metacarpals, metatarsals and phalanges are classified as short tubular bones. **Anatomically**, they are classified as long bones.

Physis is a clinical term used for the growth plate.

Clinical notes

The periosteum is significantly firmer in children than in adults. It tears much less in fractures and helps to stabilise the bone fragments after reduction.

Soft tissues such as muscles and periosteum can be wedged (interposed) between bone fragments and can hinder closed reduction of a fractured bone. If the periosteum becomes wedged into the fracture line after reduction, the fracture will not heal and a pseudoarthrosis (false joint) may develop.

Closed reduction, internal fixation (CRIF) is reduction of a fractured bone with internal osteosynthesis (bone reconnecting) without performing a skin incision.

Open reduction, internal fixation (ORIF) is an open reduction of fracture fragments performed by incising the skin and surgically putting the fragments back into place.

Fracture healing occurs in several stages. First, a haematoma develops over the fracture site. The hematoma is then organised into granulation tissue. A fibrocartilaginous callus then takes form, which is later replaced by an osseous callus. The osseous callus is then remodelled and the fracture is finally healed.

Histology

1 **Bone/osseous tissue** *(textus osseus)*
- 1.1 **Cells**
  - 1.1.1 **Osteoblasts** – synthesise the bone matrix
  - 1.1.2 **Osteocytes** – mature osteoblasts that no longer synthesise bone matrix
    - – reside in spaces in bone tissue called lacunae
    - – participate in the regulation of the serum calcium level
  - 1.1.3 **Osteoclasts** – bone-resorbing cells
  - 1.1.4 **Osteoprogenitor cells / pre-osteoblasts**
    - – mesenchymal stem cells that are located in the periosteum and endosteum
- 1.2 **The bone matrix**
  - 1.2.1 **Organic components** – consist of collagen fibres (ossein) and unmineralised ground substance that consists of proteins (osteocalcin, osteonectin, osteopontin etc.), glycosaminoglycans, lipids and carbohydrates
  - 1.2.2 **Inorganic components** – include tricalcium phosphate, hydroxyapatite and calcium carbonate
- 1.3 **Type of bone tissue**
  - 1.3.1 **Primary bone / woven bone** *(textus osseus fibroreticularis)*
    - – irregularly organised collagen fibres
    - – present in bone development
    - – in adults, primary bone is located in the wall of the bony labyrinth of the inner ear, around the sutures of the skull and at points of attachment of muscles and ligaments to bone
    - – present during bone healing after fractures
  - 1.3.2 **Secondary bone / lamellar bone** *(textus osseus lamellaris)*
    - 1.3.2.1 **Osteon / Haversian system**
      - –the fundamental structural unit of secondary bone
      - –consists of a system of concentric bony lamiellae surrounding a central canal called the Harversian canal
      - –**The Haversian canal** *(canalis osteoni, canalis centralis)* contains nerves and vessels and communicates with the periosteum, medullary cavity, and other Haversian canals via the transverse Volkmann's canals
- 1.4 **Organisation of bone tissue**
  - 1.4.1 **Compact bone** *(substantia compacta)*
    - – forms the superficial layer of bone under the periosteum
  - 1.4.2 **Trabecular bone / cancellous bone / spongy bone** *(substantia spongiosa, substantia trabecularis)* – composed of a branching system of rods of bone tissue located under the bone cortex
    - – found inside short bones and in the terminal ends of long bones
    - – the diploë is trabecular bone located between two lamellae of compact bone in the flat bones of the skull

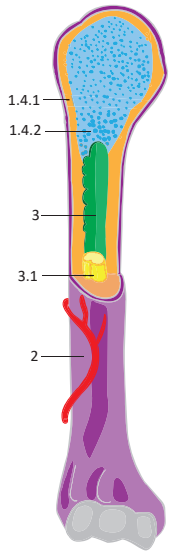

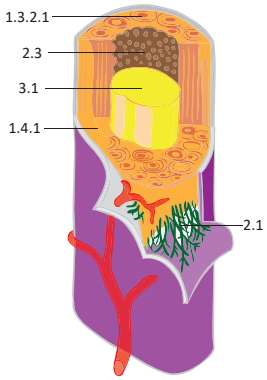

2 **Periosteum**
- – the fibrous covering of the entire external bone surface except for the articular surfaces, which are covered by cartilage
- – has a rich innervation and blood supply
- – bone grows in width by "periosteal apposition"
- – **the periosteum consists of 2 layers:**
  - – **the fibrous layer** *(stratum fibrosum)*
    - – the external layer, composed of parallel collagen fibers
  - – **the osteogenic layer** *(stratum osteogeneticum)*
    - – the internal layer, made up of osteoprogenitor cells, which are active when the bone is growing in width and during healing of fractures
- 2.1 **Sharpey's fibres / perforating collagen fibre bundles** *(fasciculi collageni perforantes)* – strong collagen fibers connecting the periosteum to the bone surface
- 2.2 **Volkmann's canals / transverse canals** *(canales transversi)*
  - – run transversely through the osteons and carry nerves and vessels from the periosteum to the Haversian canals
- 2.3 **Endosteum** – the internal fibrous layer similar to the periosteum
  - – located between bone tissue and bone marrow

3 **Medullary cavity / medulla** *(cavitas medullaris)*
- 3.1 **Bone marrow** *(medulla ossium)* – the tissue of the medullary cavity

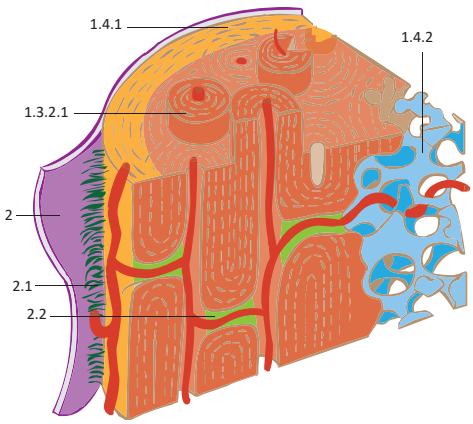

This copy belongs to ali yaghoubi

Bone marrow (*Medulla osium*)

Bone marrow is a tissue located inside the medullary (marrow) cavity of long bones and in the spaces between trabeculae.

- 1 **Red bone marrow** *(medulla ossium rubra)*
  - – a haematopoietic organ
  - – is composed of reticular connective tissue containing haematopoietic stem cells capable of differentiating into all types of blood cells
  - – contains a network of sinusoids (thick capillaries with large pores)
  - – haematopoiesis starts in the 2nd–3rd month of intrauterine life
  - – from birth until adulthood haematopoiesis occurs in the medullary cavity of long bones
  - – in adults, haematopoiesis takes place in the epiphyses of long bones, ribs, sternum, wing of the ilium and diploe of flat bones of the skull
- 2 **Yellow bone marrow** *(medulla ossium flava)*
  - – is composed mostly of adipose tissue and has no haematopoietic function
  - – is located in the medulla of long bones in adults
  - – red marrow transforms is replaced by adipose tissue as it transforms into yellow marrow

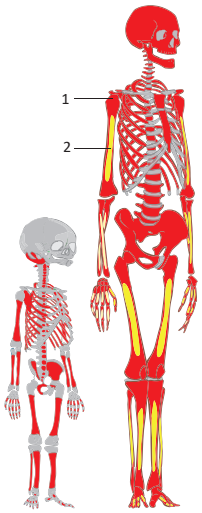

Development and bone ossification

- 1 **Intramembranous ossification** *(ossificatio membranacea, ossificatio desmalis)*
  - – development of bone tissue from a fibrous model of embryonic connective tissue (mesenchyme)
  - – osteoblasts differentiate directly from mesenchymal cells
  - – occurs in the desmocranium, clavicle and sesamoid bones
- 2 **Enchondral ossification** *(ossificatio chondralis)*
  - – development of bone from a hyaline cartilage model
  - – mesenchymal tissue forms a hyaline cartilage model, which subsequently transforms into bone tissue
  - 2.1 **Perichondral ossification** *(ossificatio perichondralis)*
    - – formation of new bone from the external surface of the bone
  - 2.2 **Endochondral ossification** *(ossificatio endochondralis)*
    - – formation of new bone from the internal surface of the bone
    - – both perichondral and endochondral ossification occur in long bones
    - – only endochondral occurs in short bones
  - 2.3 **Ossification centres of long bones**
    - 2.3.1 **Primary ossification centres**
      - – are located in diaphyses (shafts) of long bones
    - 2.3.2 **Secondary ossification centres**
      - – are located in epiphyses and apophyses of long bones
- 3 **Bone growth**
  - 3.1 **Growth in width** – by periosteal ossification
  - 3.2 **Growth in length** – occurs in growth cartilage in children

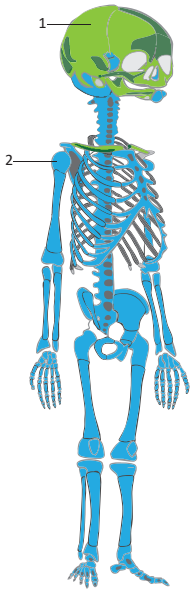

Innervation and vascular supply of bone

1 **Arteries**
- – periosteal vessels are thin but form a rich plexus in the periosteum
- – they supply the majority of both compact and trabecular bone via Volkmann's canals

1.1 **Nutrient arteries** *(arteriae nutriciae)*
- – enter the diaphysis at an inclined angle and supply both the bone marrow and cortex
- – 1–2 nutrient arteries supply each diaphysis
- – the epiphysis is supplied by its own artery, which degenerates after growth arrest
- – after growth arrest, the epiphysis is supplied by vessels from the metaphysis

2 **Veins**
- – usually run parallel with the arteries
- – diploic veins *(venae diploicae)* are found inside the diploe of the flat skull bones and lack valves

3 **Nerves**
- – provide a rich somatosensory innervation to the periosteum,
- – Pacinian corpuscles are found in the periosteum
- – visceromotor nerves supply vessels in bones

The splanchnocranium is an obsolete term for the viscerocranium.

The pericranium is a synonym of the periosteum of the skull.

The auditory ossicles (*ossicula auditus*) are a part of the viscerocranium. For further details see page 506.

The bones of the skull develop from mesenchymal tissue surrounding the developing brain. According to their developmental origin and type of ossification, the bones of the skull are divided into three main groups: **the chondrocranium, desmocranium and viscerocranium**.

The chondrocranium includes the bones of the skull that develop by endochondral ossification. These bone are phylogenetically the oldest part of the skull.

The desmocranium includes the bones of the cranial vault that develop by intramembranous ossification.

The viscerocranium includes the bones that make up the facial skeleton. It is phylogenetically the youngest part of the skull. The facial bones develop from mesenchyme of the pharyngeal arches by intramembranous ossification. The exceptions are the auditory ossicles and the hyoid bone, which develop by endochondral ossification.

The desmocranium includes the parietal bone, upper part of the squama of the occipital bone, frontal bone, squamous and tympanic part of the temporal bone, nasal bone, lacrimal bone, vomer, zygomatic bone, maxilla, mandible, palatine bone, inferior nasal concha and the the medial plate of the pterygoid process of the sphenoidal bone.

Long bones ossify predominantly by endochondral ossification which begins at the primary ossification centre in the diaphysis and expands towards both epiphyses. The epiphyses ossify from a separate ossification center: the secondary ossification centre.

Clinical notes

Cleidocranial dysostosis is a hereditary disorder of intramembranous ossification that affects the clavicles and flat bones of the skull. It may be associated with an impairment of ossification of the pelvis and bones of the limbs.

The neurocranium, or more colloquially the "**brain case**", is a group of bones in the skull that encloses and protects the brain and its associated organs of vision, audition and balance. The neurocranium is divided into the **cranial vault** and the **cranial base**. **The viscerocranium** (facial skeleton) is a group of bones in the skull that surrounds and protects the proximal parts of the digestive and respiratory systems.

Overview of the bones of the skull

1 **Neurocranium** – brain box or brain case
Cranial vault / calvaria
- 1.1 **Parietal bone** *(os parietale)*
- 1.2 **Frontal bone** *(os frontale)*
- 1.3 **Occipital bone** *(os occipitale)*

Cranial base (*basis cranii*)
- 1.4 **Temporal bone** *(os temporale)*
- 1.5 **Sphenoid bone** *(os sphenoidale)*
- 1.6 **Ethmoid bone** *(os ethmoidale)*

2 **Viscerocranium** – facial skeleton
- 2.1 **Lacrimal bone** *(os lacrimale)*
- 2.2 **Nasal bone** *(os nasale)*
- 2.3 **Vomer**
- 2.4 **Inferior nasal concha** *(concha nasalis inferior)*
- 2.5 **Zygomatic bone** *(os zygomaticum)*
- 2.6 **Palatine bone** *(os palatinum)*
- 2.7 **Maxilla**
- 2.8 **Mandible** *(mandibula)*
- 2.9 **Hyoid bone** *(os hyoideum)*

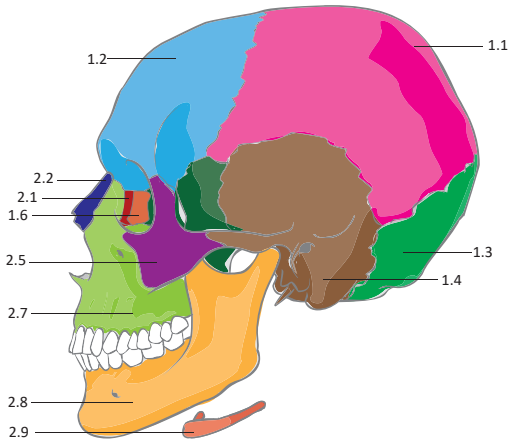

Lateral view *(norma lateralis)*

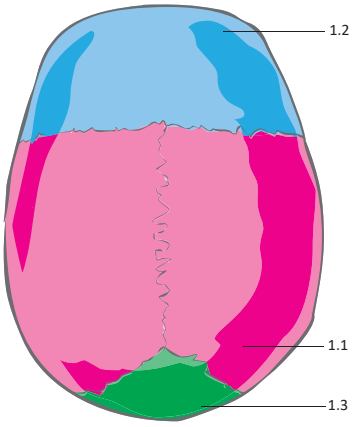

Superior view *(norma superior/verticalis)*

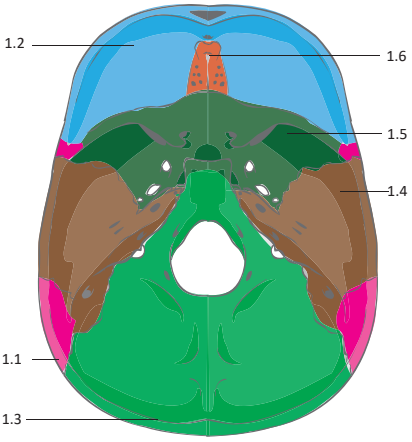

Superior view *(norma superior/verticalis)*

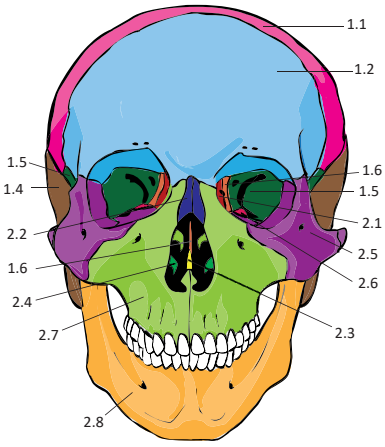

Anterior view (*norma facialis/frontalis*)

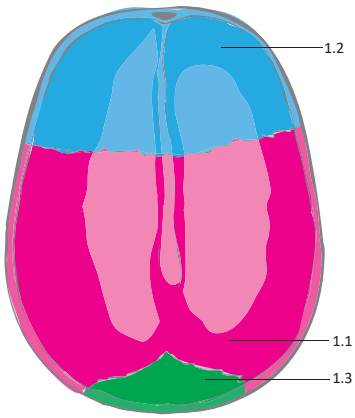

Inferior view *(norma inferior/basalis)*

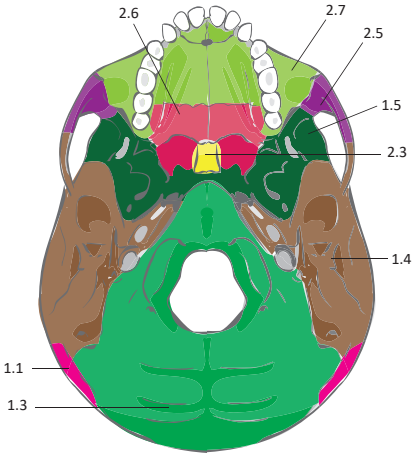

Inferior view *(norma inferior/basalis)*

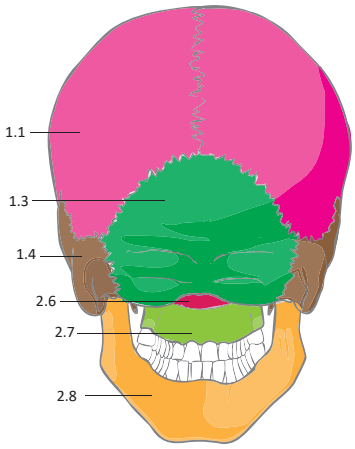

Posterior view *(norma occipitalis)*

This copy belongs to ali yaghoubi

Originally a paired bone of the cranial vault which develops by **intramembranous ossification, the frontal bone** is an unpaired **pneumatised bone** and contains a paranasal sinus: **the frontal sinus.** The frontal bone consists of **a squamous part, a nasal part and two paired orbital parts.**

- 1 **Squamous part** *(squama frontalis)*
  External surface *(facies externa)*
  - 1.1 **Frontal tuber** *(tuber frontale)* – paired large elevations containing ossification centers
  - 1.2 **Superciliary arch** *(arcus superciliaris)* – paired arches located above the orbits
  - 1.3 **Glabella** – a flattened area above the nasal root and between the superciliary arches
  - 1.4 **Supra-orbital margin** *(margo supraorbitalis)* – the superior border of the orbit
    - 1.4.1 **Frontal notch/foramen** *(incisura/foramen frontale)*
      – a notch or foramen above the orbit that is only occasionally present
      – transmits the medial branch of the supra-orbital nerve
    - 1.4.2 **Supra-orbital notch/foramen** *(incisura/foramen supraorbitalis)*
      – a notch or foramen above the orbit that is always present
      – contains the supra-orbital vessels and the lateral branch of the supra-orbital nerve
  - 1.5 **Zygomatic process** *(processus zygomaticus)*
    – connects to the zygomatic bone
  - 1.6 **Temporal line** *(linea temporalis)*
    – the upper border of the origin of the temporalis muscle
    – continues on the parietal bone
  - 1.7 **Parietal margin** *(margo parietalis)*
    – connects with the parietal bone to form the coronal suture

  Internal surface *(facies interna)*
  - 1.8 **Groove for superior sagittal sinus** *(sulcus sinus sagittalis superioris)*
    – contains the superior sagittal sinus
  - 1.9 **Frontal crest** *(crista frontalis)*
    – the site of attachment of the falx cerebri
    – the anterior continuation of the groove for the superior sagittal sinus
- 2 **Orbital part** *(pars orbitalis)*
  - 2.1 **Lacrimal fossa** *(fossa glandulae lacrimalis)*
    – a fossa on the lateral part of the roof of the orbit for the lacrimal gland
  - 2.2 **Trochlear fovea** *(fovea trochlearis)*
    – fossa containing the trochlear spine

    2.3 **Trochlear spine** *(spina trochlearis)*
    – the attachment of the trochlea of the superior oblique muscle
  - 2.4 **Anterior and posterior ethmoidal foramina** *(foramen ethmoidale anterius et posterius)*
    – formed by connection with the ethmoidal bone
    – transmit the anterior and posterior ethmoidal artery, vein and nerve
  - 2.5 **Ethmoidal notch** *(incisura ethmoidalis)*
    – a notch for the ethmoidal bone
  - 2.6 **Sphenoidal margin** *(margo sphenoidalis)*
- 3 **Nasal part** *(pars nasalis)*
  – a small unpaired part of the bone located at the nasal root where the nasal spine and nasal margin are found
- 4 **Frontal sinus** *(sinus frontalis)* – a paired paranasal sinus
  – develops in children after the first year of life
  – the full volume is reached at the end of the growth period
  – opens into the middle nasal meatus

  4.1 **Septum of the frontal sinuses** *(septum sinuum frontalium)*
  – separates the left and right frontal sinus

  4.2 **Opening of the frontal sinus** *(apertura sinus frontalis)*
  – the entrance to the frontal sinus

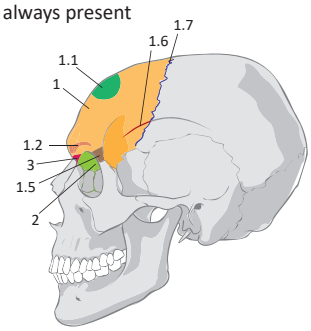

Lateral view of the skull

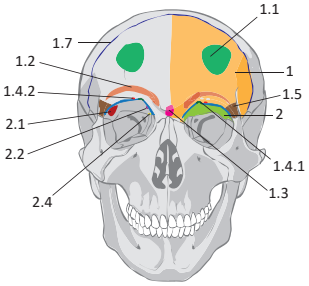

Anterior view of the skull

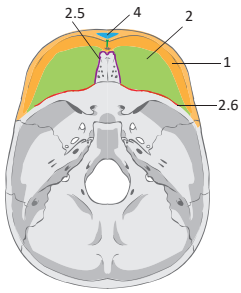

Internal surface of the cranial base

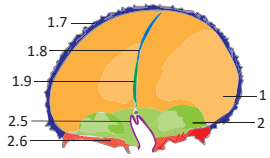

Posterior view of the frontal bone

The frontal foramen and the supra-orbital foramen *(foramina frontalis et supraorbitalis)* are variable openings which can replace the frontal and supraorbital notch *(incisura frontalis et supraorbitalis).*

Gyral impressions *(impressions gyrarum)* are impressions of the cerebral gyri on the inner surface of the frontal bone. **The cerebral juga** are eminences between these impressions.

The spheno-occipital synchondrosis ossifies at the age of eighteen.

The transverse occipital suture lies in the upper part of the occipital squama and marks the boundary between the upper part of the occipital bone, which develops by intramembranous ossification, and the lower part of the occipital bone, which develops by endochondral ossification.

Failure of fusion the transverse occipital suture *(sutura occipitalis transversa)* gives rise to the **interparietal bones (Inca bones)**. These bones occur in 30 % of the Native American population but only in 5 % of the European population.

The sutura mendosa is formed after incomplete fusion of the squamous part of the occipital bone. It projects medially or vertically from the lambdoid suture and is variable in length.

The trochlear spine is a cartilaginous pulley in the trochlear fovea which is ossified in less than 15 % of population.

The orbitocranial canal connects the orbit to the anterior cranial fossa. It opens into the anterior ethmoidal foramen.

The orbitoethmoidal canal connects the orbit to the ethmoidal air cells. It opens into the posterior ethmoidal foramen.

The internal occipital crest *(crista occipitalis interna)* is a vertical osseous crest. Sometimes it is replaced by the groove for the occipital sinus.

The foramen caecum of the frontal bone is a small hole on the cranial surface of the squama of the frontal bone. It represents a remnant of a foetal foramen and contains an emissary vein, which persists after birth in about 1 % of the population.

The occipital bone is an unpaired bone composed of four main parts: **the squamous part, the basilar part and the two lateral parts.** The basilar parts, the lateral parts and a portion of the squamous part contribute to **the cranial base**. These parts develop by **endochondral ossification**. A portion of the squamous part forms part of **the cranial vault** and develops by **intramembranous ossification**.

- 1 **Foramen magnum** – a large opening that contains the medulla oblongata as it changes into the spinal cord
  – contains the vertebral arteries, the anterior spinal artery, the paired posterior spinal arteries, the spinal root of the accessory nerve and the spinal vein
- 2 **Basilar part** *(pars basilaris)* – lies anterior to the foramen magnum and articulates with the sphenoid bone
  - 2.1 **Clivus** – a slope on the internal surface located beneath the brain stem, basilar artery and basilar venous plexus
  - 2.2 **Pharyngeal tubercle** *(tuberculum pharyngeum)* – an unpaired tubercle for the attachment of the pharyngeal raphe to the base of the skull
  - 2.3 **Groove for the inferior petrosal sinus** *(sulcus sinus petrosi inferioris)*
  - 2.4 **Spheno-occipital synchondrosis** *(synchondrosis sphenooccipitalis)*
    – a cartilaginous connection between the sphenoid and occipital bone
- 3 **Lateral parts** *(partes laterales)* – located laterally to the foramen magnum
  - 3.1 **Occipital condyles** *(condyli occipitales)* – protuberances for articulation with the atlas
  - 3.2 **Hypoglossal canal** *(canalis nervi hypoglossi)*
    – transmits the hypoglossal nerve and venous plexus of the hypoglossal canal
  - 3.3 **Condylar fossa** *(fossa condylaris)* – located behind the occipital condyle and may contain the condylar canal which transmits the condylar emissary vein
  - 3.4 **Jugular notch** *(incisura jugularis)* – forms the jugular foramen with the jugular notch of the temporal bone
    - 3.4.1 **Jugular process** *(processus jugularis)* – a prominence at the end of the jugular notch for the origin of the rectus capitis anterior
    - 3.4.2 **Intrajugular process** *(processus intrajugularis)* – is located inside the jugular notch and separates the jugular foramen into two compartments
- 4 **Squamous part** *(squama occipitalis)*

  External surface *(facies externa)*
  - 4.1 **Highest nuchal line** *(linea nuchalis suprema)* – the attachment of the nuchal fascia
  - 4.2 **Superior nuchal line** *(linea nuchalis superior)*
    – the attachment of the trapezius and sternocleidomastoid
  - 4.3 **Inferior nuchal line** *(linea nuchalis inferior)*
    – the attachment of the rectus capitis posterior major and minor
  - 4.4 **Occipital plane** *(planum occipitale)* – the attachment of some back muscles
  - 4.5 **External occipital protuberance** *(protuberantia occipitalis externa)*
    – a palpable tubercle on the posterior surface of the skull
  - 4.6 **External occipital crest** *(crista occipitalis externa)*
    – a vertical crest for attachment of the nuchal ligament
  - 4.7 **Lambdoid border** *(margo lambdoideus)* – forms the lambdoid suture with the parietal bone
  - 4.8 **Mastoid border** *(margo mastoideus)* – connects to the temporal bone to form the occipitomastoid suture

  Internal surface *(facies interna)*
  - 4.9 **Cruciform eminence** *(eminentia cruciformis)* – a cross-shaped prominence formed by the grooves for the occipital, superior sagittal and transverse sinuses
    – divides the occipital bone into two cerebral fossae and two cerebellar fossae
  - 4.10 **Internal occipital protuberance** *(protuberantia occipitalis interna)*
    – contains the confluence of sinuses, which is the connection point of the transverse, straight, superior sagittal and occipital sinuses
  - 4.11 **Groove for superior sagittal sinus** *(sulcus sinus sagittalis superioris)*
    – contains the superior sagittal sinus and the attachment of the falx cerebri
  - 4.12 **Groove for transverse sinus** *(sulcus sinus transversi)*
    – contains the transverse sinus as well as the attachment of the tentorium cerebelli
  - 4.13 **Groove for sigmoid sinus** *(sulcus sinus sigmoidei)* – contains the sigmoid sinus
  - 4.14 **Groove for occipital sinus** *(sulcus sinus occipitalis)*
    – contains the occipital sinus and the attachment of the falx cerebelli
  - 4.15 **Groove for marginal sinus** *(sulcus sinus marginalis)*
    – contains the marginal sinus and surrounds the foramen magnum
  - 4.16 **Cerebral fossae** *(fossae cerebrales)*
    – contains the posterior part of the occipital lobes of the telencephalon
  - 4.17 **Cerebellar fossae** *(fossae cerebellares)* – contains the cerebellar hemispheres
    – separated from the cerebral fossae by the tentorium cerebelli

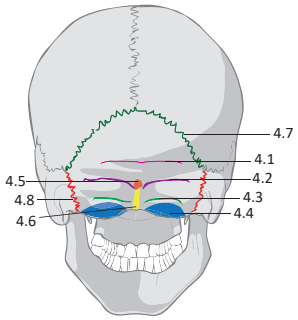

Posterior view of the skull

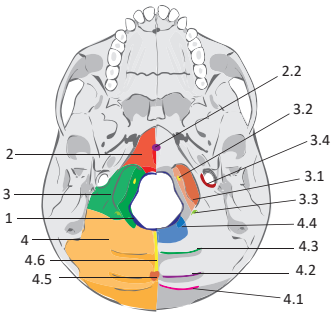

External surface of the cranial base

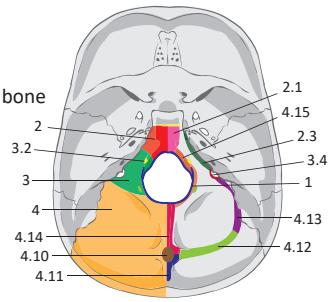

Internal surface of the cranial base

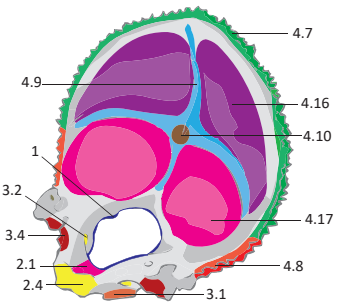

Oblique view of the occipital bone

This copy belongs to ali yaghoubi

The sphenoidal bone is an unpaired bone of the base of the skull that develops predominantly by **endochondral ossification.** It consists of an unpaired **body and three paired projections: the greater wing, lesser wing and pterygoid process**. The spenoidal bone connects the middle cranial fossa to several topographical spaces of the skull via various foramina. These topographical spaces are the infratemporal fossa, pterygopalatine fossa, tympanic cavity and the orbit. **The sphenoidal bone is an pneumatised bone** and contains a paired paranasal sinus: **the sphenoidal sinus**.

Basic parts

- 1 **Body of the sphenoid** *(corpus ossis sphenoidalis)*
- 2 **Lesser wings** *(alae minores ossis sphenoidalis)*
- 3 **Greater wings** *(alae majores ossis sphenoidalis)*
- 4 **Pterygoid processes** *(processus pterygoidei)*
- 5 **Superior orbital fissure** *(fissura orbitalis superior)*
  – an opening located between the greater and lesser wings
- 6 **Inferior orbital fissure** *(fissura orbitalis inferior)*
  – an opening between the greater wing and the maxilla



Left superior posterior view of the sphenoid

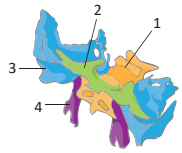

Left superior anterior view of the sphenoid

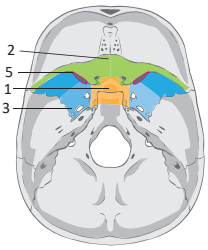

Internal surface of the cranial base

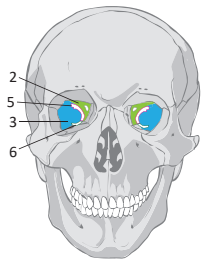

Anterior view of the skull

Body of sphenoid *(corpus ossis sphenoidalis)*

- 1 **Sella turcica**
  - 1.1 **Hypophysial fossa** *(fossa hypophysialis)*
    – contains the hypophysis
  - 1.2 **Dorsum sellae** – the posterior wall
  - 1.3 **Posterior clinoid processes** *(processus clinoidei posteriores)*
    – the attachment of the sellar diaphragm and tentorium cerebelli
- 2 **Carotid sulcus** *(sulcus caroticus)*
  – a groove for the internal carotid artery
  – located lateral to the sella turcica
- 3 **Sphenoidal lingula** *(lingula sphenoidalis)*
  – the posterior margin of the carotid sulcus
- 4 **Prechiasmaticus sulcus**
  – a shallow groove located anterior to the optic chiasma
- 5 **Sphenoidal sinus** *(sinus sphenoidalis)*
  – a paired paranasal sinus located inside the sphenoid body and under the sella turcica
  - 5.1 **Septum of sphenoidal sinuses** *(septum sinuum sphenoidalium)*
    – separates the left and right sphenoidal sinuses
  - 5.2 **Opening of sphenoidal sinus** *(apertura sinus sphenoidalis)*
    – connects the sphenoidal sinus to the superior nasal meatus
  - 5.3 **Sphenoidal concha** *(concha sphenoidalis)*
    – a rudimentary paired nasal concha that narrows the opening of the sphenoidal sinus
- 6 **Sphenoidal crest** *(crista sphenoidalis)*
  – a vertical crest in the midline of the ventral surface of the sphenoid body that articulates with the perpendicular plate of the ethmoidal bone
- 7 **Sphenoidal rostrum** *(rostrum sphenoidale)*
  – a vertical crest on the inferior surface of the sphenoid body that articulates with the vomer

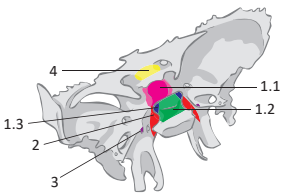

Left superior posterior view of the sphenoid

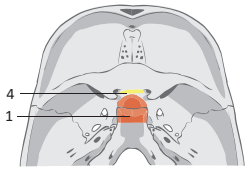

Internal surface of the cranial base

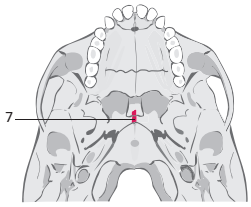

External surface of the cranial base

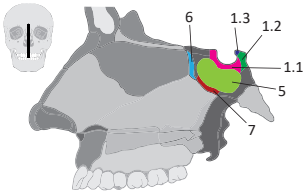

Medial wall of the nasal cavity

The majority of the sphenoidal bone develops by **endochondral ossification**. However, the greater wings and the medial plate of the pterygoid process develop by **intramembranous ossification**.

The middle clinoid process *(processus clinoideus medius)* is a variable binate prominence situated medial to the carotid groove that serves for the insertion of the sellar diaphragm.

The foramen of Arnold and *canaliculus innominatus* are obsolete terms for the **foramen petrosum**.

The foramen of Vesalius is an obsolete term for the **foramen venosum**.

The pterygospinous process of Civini *(processus pterygospinosus)* is a variable feature located on the posterior aspect of the lateral plate of the pterygoid process. It is a sharp bony protuberance that serves as the attachment of the **pterygospinous ligament**. The pterygospinous ligament can ossify to create the **foramen of Hyrtl,** containing the motor root of the mandibular nerve.

The vomerovaginal canal *(canalis vomerovaginalis)* is a small canal without any content, formed between the vaginal process of the pterygoid process and the vomer.

The cavernous sinus is discussed on page 534.

Clinical notes

The pterion is a craniometric point at the point where the greater wing of the sphenoid bone, the parietal bone and the frontal bone meet. It is the weakest point of the skull. The middle meningeal artery is located underneath it on the internal surface of the skull. Trauma to this region may result in bleeding of the middle meningeal artery, which results in an epidural hematoma.

From the developmental point of view, the pterion is the location of the fibrous sphenoidal fontanelle.

The pituitary gland can be accessed via the sphenoidal sinus. This is know as **the transnasal transsphenoidal approach** and can be used to remove pituitary tumours.

Lesser wing *(ala minor ossis sphenoidalis)*

- 1 **Anterior clinoid process** *(processus clinoidei anteriores)*
  – the attachment of the tentorium cerebelli
- 2 **Optic canal** *(canalis opticus)*
  – leads to the orbit
  – transmits the optic nerve and ophthalmic artery

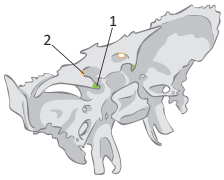

Left superior posterior view of the sphenoid

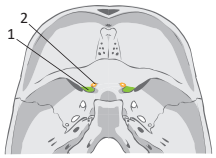

Cranial base

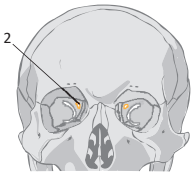

Anterior view of the skull

Greater wing *(ala major ossis sphenoidalis)*

- 1 **Infratemporal crest** *(crista infratemporalis)*
  – forms the border between the temporal and infratemporal fossae
  – the origin of the superior head of the lateral pterygoid muscle
- 2 **Spine of sphenoidal bone** *(spina ossis sphenoidalis)*
  – the most dorsal part of the sphenoid
  – points downwards and is located near the foramen spinosum
  – the attachment of the sphenomandibular ligament, pterygospinous ligament and anterior ligament of the malleus
  – the origin of the tensor veli palatini
- 3 **Foramen rotundum** – transmits the maxillary nerve (n. V2)
- 4 **Foramen ovale** – transmits the mandibular nerve (n. V3) and the venous plexus of foramen ovale
- 5 **Foramen spinosum** – transmits the middle meningeal vessels and the meningeal branch of the mandibular nerve
- 6 **Petrosal foramen** *(foramen petrosum)*
  – a variable opening for the lesser petrosal nerve
- 7 **Sphenoidal emissary foramen / foramen venosum**
  – a variable opening for the sphenoidal emissary vein
- 8 **Sulcus of the auditory tube** *(sulcus tubae auditivae)*
  – contains the auditory tube *(tuba auditivea)*, which connects the tympanic cavity to the nasopharynx
- 9 **Surfaces**:
  - 9.1 **Cerebral surface** *(facies cerebralis)*
  - 9.2 **Temporal surface** *(facies temporalis)*
  - 9.3 **Infratemporal surface** *(facies infratemporalis)*
  - 9.4 **Maxillary surface** *(facies maxillaris)*
  - 9.5 **Orbital surface** *(facies orbitalis)*
- 10 **Margins**:
  - 10.1 **Zygomatic margin** *(margo zygomaticus)*
  - 10.2 **Frontal margin** *(margo frontalis)*
  - 10.3 **Parietal margin** *(margo parietalis)*
  - 10.4 **Squamosal margin** *(margo squamosus)*

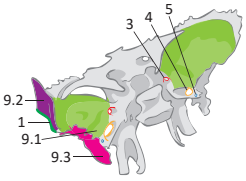

Left superior posterior view of the sphenoid

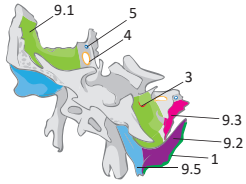

Left superior anterior view of the sphenoid

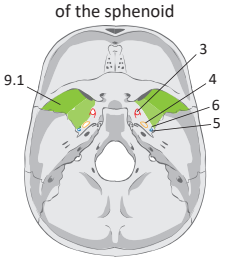

Internal view of the cranial base

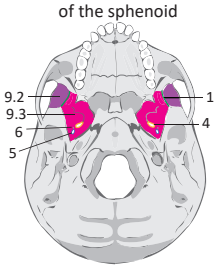

External view of the cranial basel

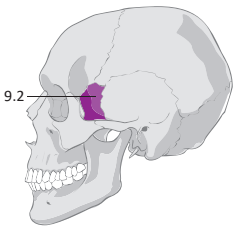

Lateral view of the skull

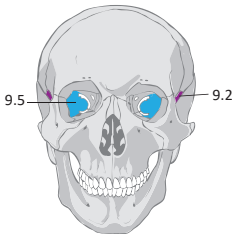

Anterior view of the skull

Pterygoid process *(processus pterygoideus)*

- 1 **Lateral plate** *(lamina lateralis)*
  – the origin of the inferior head of the lateral pterygoid muscle
- 2 **Medial plate** *(lamina medialis)* – the attachment of the pharyngobasilar fascia and superior constrictor of the pharynx
  - 2.1 **Pterygoid hamulus** *(hamulus pterygoideus)*
    – serves as a pulley for the tensor veli palatini tendon
- 3 **Pterygoid notch** *(incisura pterygoidea)*
  – a notch between the lateral and medial plates
- 4 **Pterygoid fossa** *(fossa pterygoidea)*
  – a fossa located between the lateral and medial plates
  – the origin of the medial pterygoid muscle
- 5 **Scaphoid fossa** *(fossa scaphoidea)*
  –is located cranial to the pterygoid fossa
  – the origin of the tensor veli palatini
- 6 **Pterygoid canal of Vidius** *(canalis pterygoideus)*
  – transmits the vessels and nerve of the pterygoid canal
- 7 **Vaginal process** *(processus vaginalis)*
  – a small prominence under the body of the sphenoid
  – forms the palatovaginal canal, which transmits the pharyngeal nerve and the pharyngeal branch of the maxillary artery

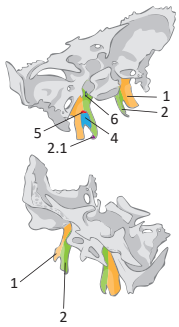

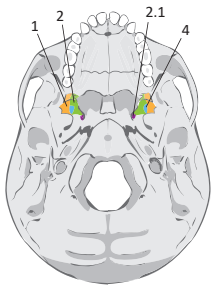

Inferior aspect of the skull

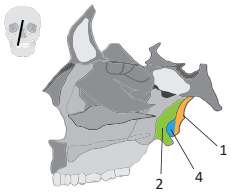

Lateral wall of the nasal cavity

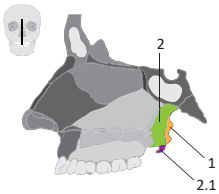

Medial wall of the nasal cavity

This copy belongs to ali yaghoubi

The parietal bone is a paired bone in the cranial vault that develops by **intramembranous ossification**. It is square-shaped with an outward convexity formed by **the parietal eminence** *(tuber parietale)*.

1 **Surfaces**

Internal surface *(facies interna)*

- 1.1 **Groove for the superior sagittal sinus** *(sulcus sinus sagittalis superioris)*
  – contains the superior sagittal sinus
- 1.2 **Groove for the middle meningeal artery** *(sulcus arteriae meningeae mediae)*
  – contains the middle meningeal artery
- 1.3 **Grooves for arteries** *(sulci arteriosi)*
  – grooves for the branches of the middle meningeal artery

External surface *(facies externa)*

- 1.4 **Superior temporal line** *(linea temporalis superior)*
  – the attachment of the temporal fascia
- 1.5 **Inferior temporal line** *(linea temporalis inferior)*
  – the inferior margin of the origin of the temporalis muscle
- 1.6 **Parietal tuber** *(parietal eminence, tuber parietale)*
  – contains an ossification center
  – a thickened part of the bone with an outward convexity
- 1.7 **Groove for the sigmoid sinus** *(sulcus sinus sigmoidei)*
  – a short groove for the sigmoid sinus located over the mastoid angle

2 **Parietal foramen** *(foramen parietale)*

– transmits the parietal emissary vein
– located close to the sagittal border

3 **Margins**

- 3.1 **Occipital border** *(margo occipitalis)*
  – connects to the occipital bone, forming the lambdoid suture *(sutura lambdoidea)*
- 3.2 **Squamous border** *(margo squamosus)*
  – connects to the temporal bone, forming the squamous suture *(sutura squamosa)*
- 3.3 **Sagittal border** *(margo sagittalis)*
  – connects to the contralateral parietal bone, forming the sagittal suture *(sutura sagittalis)*
- 3.4 **Frontal border** *(margo frontalis)*
  – connects to the frontal bone, forming the coronal suture *(sutura coronalis)*

4 **Angles**

4.1 **Frontal angle** *(angulus frontalis)*
4.2 **Occipital angle** *(angulus occipitalis)*
4.3 **Mastoid angle** *(angulus mastoideus)*
4.4 **Sphenoidal angle** *(angulus sphenoidalis)*

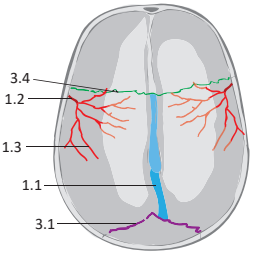

Internal view of the cranial vault

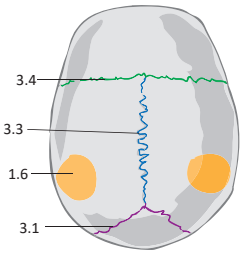

External view of the cranial vault

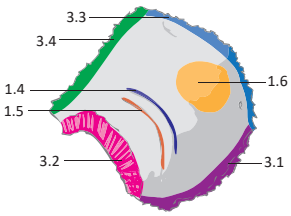

External view of the left parietal bone

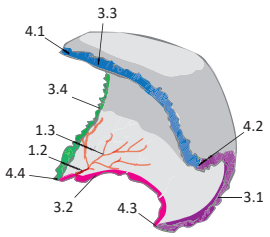

Internal view of the right parietal bone

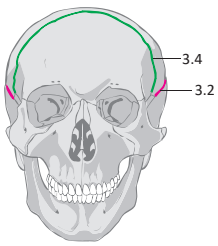

Anterior view of the skull

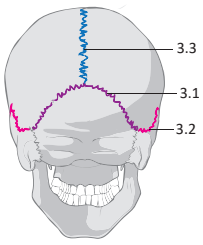

Posterior view of the skull

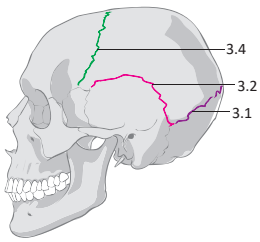

Lateral view of the skull

The granular foveolae (*foveolae granulares*) are small depressions located adjacent to the groove for the superior sagittal sinus. They are impressions formed by arachnoid granlulations.

Arachnoid granulations / arachnoid villi *(granulationes arachnoideae)* are pouches of arachnoid that project into the dural venous sinuses to allow cerebrospinal fluid to be absorbed into the blood. They are also known as **Pacchionian granulations**.

Clinical notes

The triangle of Macewan is an eponym for the **suprameatal triangle** *(foveola suprameatica)*. The suprameatal triangle can be used to approach the mastoid antrum, which lies 1.5–2 cm deep to the surface of the bone.

The temporal bone is a paired bone that consists of three main parts: **the squamous part, the tympanic part and the petrous part**. The squamous and tympanic parts of the temporal bone develop by **intramembranous ossification**. The petrous part and the styloid and mastoid process develop by **endochondral ossification. The middle and inner ear** are hidden inside the petrous bone. They open to the surroundings via **the internal and external acoustic openings**. The double-curved **facial canal**, housing the **facial nerve**, is located within the petrous part. **The mastoid process** is a pneumatised bony prominence containing small air filled cavities called **mastoid air cells**.

Basic parts

- 1 **Squamous part** *(pars squamosa)*
- 2 **Tympanic part** *(pars tympanica)*
  - – forms the walls of the external acoustic meatus
  - – has the shape of the letter "U"
- 3 **Petrous part** *(pars petrosa)*

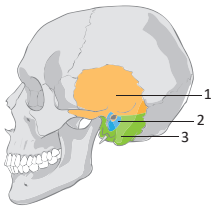

Basic parts of the temporal bone, lateral view of the skull

Squamous part *(pars squamosa)*

- 1 **Parietal border** *(margo parietalis)* – connects to the parietal bone, forming the squamous suture *(sutura squamosa)*
- 2 **Sphenoidal margin** *(margo sphenoidalis)* – connects to the sphenoidal bone, forming the sphenosquamous suture *(sutura sphenosquamosa)*
- 3 **Groove for middle temporal artery** *(sulcus arteriae temporalis mediae)*
  - – a shallow vertical groove on the internal surface of the bone
- 4 **Zygomatic process** *(processus zygomaticus)* – the origin of the masseter
  - – the attachment of the lateral temporomandibular ligament and temporal fascia
  - – forms the zygomatic arch with the temporal process of the zygomatic bone
  - 4.1 **Articular surface** *(facies articularis)*
  - 4.2 **Articular tubercle** *(tuberculum articulare)*
    - – a prominence in front of the mandibular fossa
    - – forms part of the temporomandibular joint
  - 4.3 **Supramastoid crest** *(crista supramastoidea)*
    - – part of the origin of the temporal muscle and temporal fascia
    - – the dorsal continuation of the zygomatic process
  - 4.4 **Suprameatal triangle** *(foveola suprameatica)*
    - – a small fossa located above the external acoustic meatus
  - 4.5 **Suprameatal spine** *(spina suprameatica)*
    - – a variable osseous spine located under the suprameatal triangle
- 5 **Mandibular fossa** *(fossa mandibularis)*
  - – the articular fossa for the temporomandibular joint

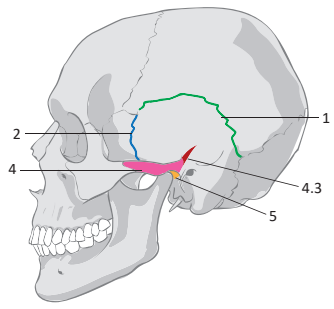

Lateral view of the skull

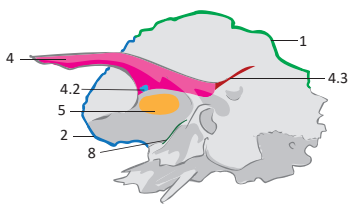

External oblique view of the left temporal bone

Tympanic part *(pars tympanica)*

- 6 **External acoustic opening** *(porus acusticus externus)* – the opening of the ear canal
  - – is composed of a bony part and a cartilaginous part
- 7 **Osseous external acoustic meatus** *(meatus acusticus externus osseus)*
  - – the bony part of the external acoustic meatus
  - 7.1 **Tympanic ring** *(anulus tympanicus)*
    - – a bony ring at the medial end of the external acoustic opening, covered by the tympanic membrane / eardrum
    - 7.1.1 **Tympanic sulcus** *(sulcus tympanicus)*
      - – a groove in the tympanic ring for the attachment of the tympanic membrane
    - 7.1.2 **Tympanic notch** *(incisura tympanica)*
      - – a notch in the upper part of the tympanic ring
      - – contains the pars flaccida of the tympanic membrane
- 8 **Petrotympanic fissure** *(fissura petrotympanica)*
  - – a fissure located between the tympanic and petrous parts of the temporal bone
  - – transmits the chorda tympani, anterior tympanic vessels and anterior ligament of the malleus
- 9 **Tympanomastoid fissure** *(fissura tympanomastoidea)*
  - – the end of the mastoid canaliculus
  - – transmits the auricular branch of the vagus nerve
- 10 **Tympanosquamous and petrosquamous fissure** *(fissura tympanosquamosa et petrosquamosa)*

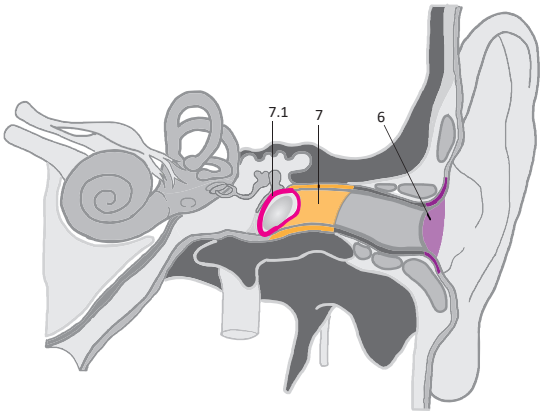

Frontal section of the principal parts of the ear

This copy belongs to ali yaghoubi

Petrous part *(pars petrosa)*

- 1 **Apex of the petrous part** *(apex partis petrosae)*
  – points ventromedially
  - 1.1 **Internal opening of the carotid canal** *(apertura interna canalis carotici)* – transmits the internal carotid artery into the cranial cavity
    – is located in the dorsal wall of the foramen lacerum
  - 1.2 **Musculotubal canal** *(canalis musculotubarius)*
    - 1.2.1 **Canal for auditory tube** *(semicanalis tubae auditivae)*
      – the bony part of the auditory tube
    - 1.2.2 **Canal for tensor tympani muscle** *(semicanalis musculi tensoris tympani)*
      – contains the tensor tympani muscle
- 2 **Anterior surface** *(facies anterior)*
  - 2.1 **Trigeminal impression** *(impressio trigeminalis)*
    – a shallow fossa for the trigeminal ganglion *(ganglion trigeminale)*
    – located near the apex of the petrous part
  - 2.2 **Groove for greater petrosal nerve** *(sulcus nervi petrosi majoris)*
    – the continuation of the hiatus for the greater petrosal nerve
    – transmits the greater petrosal nerve
  - 2.3 **Groove for lesser petrosal nerve** *(sulcus nervi petrosi minoris)*
    – the continuation of the hiatus for the lesser petrosal nerve
    – transmits the lesser petrosal nerve from the tympanic cavity to the foramen ovale
  - 2.4 **Arcuate eminence** *(eminentia arcuata)*
    – a bulge formed by the anterior semicircular canal of the inner ear
  - 2.5 **Tegmen tympani** – the roof of the tympanic cavity, located anteromedial to the arcuate eminence
    – a weakened part of the skull
    – is perforated by the veins of the tympanic cavity
- 3 **Superior border** *(margo superior)*
  – the attachment of the tentorium cerebelli
  – contains the groove for the superior petrosal sinus
  - 3.1 **Groove for superior petrosal sinus** *(sulcus sinus petrosi superioris)*
- 4 **Posterior surface** *(facies posterior)*
  - 4.1 **Internal acoustic opening** *(porus acusticus internus)*
    – transmits the facial nerve, vestibulocochlear nerve and labyrinthine vessels from the posterior cranial fossa to the middle and internal ear
  - 4.2 **Subarcuate fossa** *(fossa subarcuata)*
    – a small depression that may contain a small residual vein from development
  - 4.3 **External opening of vestibular canaliculus** *(apertura externa canaliculi vestibuli)*
    – contains the endolymphatic sac
    – the location of endolymph resorption
    - 4.3.1 **Vestibular canaliculus** *(canaliculus vestibuli)*
      – contains the endolymphatic duct
- 5 **Posterior border** *(margo posterior)* – connects to the occipital bone
  - 5.1 **Groove for inferior petrosal sinus** *(sulcus sinus petrosi inferioris)*
  - 5.2 **Jugular notch** *(incisura jugularis)* – forms the jugular foramen *(foramen jugulare)* with the jugular notch of the occipital bone
  - 5.3 **Intrajugular process** *(processus intrajugularis)* – a projection inside the jugular notch that divides the jugular foramen into two compartments

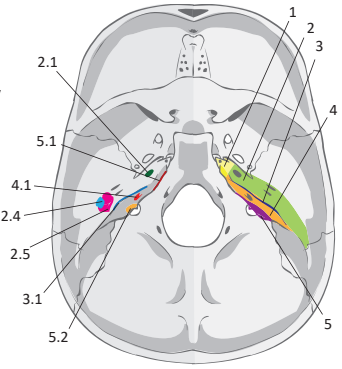

Internal view of the cranial base

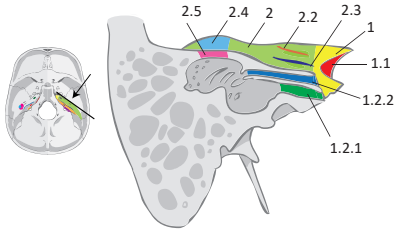

A cross section of the right temporal bone viewed from the right

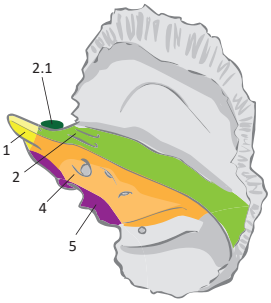

Internal oblique view of the right temporal bone

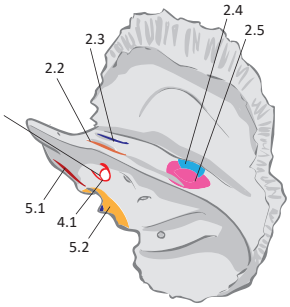

Internal oblique view of the right temporal bone,

The pyramid *(pyramis)* is an obsolete term for the petrous part of the temporal bone.

The pyramidal crest is an obsolete term for the superior border of the petrous part of the temporal bone.

The ventrobasal surface is an obsolete term for the portion of the petrous part of the temporal bone which forms most of the walls of tympanic cavity. It can be accessed after removal of tympanic part of the temporal bone.

The facial nerve, see page 361.

The tympanic cavity, see page 506.

The internal acoustic meatus, see page 507.

Petrous part *(pars petrosa)*

- 6 **Inferior surface** *(facies inferior)*
  - 6.1 **Jugular fossa** *(fossa jugularis)*
    – a fossa for the wide origin (superior bulb) of the internal jugular vein
    6.1.1 **Mastoid canaliculus** *(canaliculus mastoideus)*
    – transmits the auricular branch of the vagus nerve
  - 6.2 **External opening of the carotid canal** *(apertura externa canalis carotici)*
    – the entrance of the carotid canal *(canalis caroticus)*
    – transmits the internal carotid artery, the internal carotid plexus and the internal carotid venous plexus
  - 6.3 **Petrosal fossula** *(fossula petrosa)* – a little fossa between the jugular fossa and the external opening of the carotid canal
    – the entrance of the tympanic canaliculus
    – transmits the tympanic nerve and the inferior tympanic vessels to the tympanic cavity
  - 6.4 **External opening of the cochlear canaliculus** *(apertura externa canaliculi cochleae)* – is located between the jugular fossa and the external opening of the carotid canal
    6.4.1 **Cochlear canaliculus** *(canaliculus cochleae)*
    – contains the vein of the cochlear aqueduct
  - 6.5 **Styloid process** *(processus styloideus)*
    – the origin of the stylohyoid, styloglossus and stylopharyngeus
    – the attachment of the stylohyoid and stylomandibular ligaments
  - 6.6 **Mastoid process** *(processus mastoideus)*
    – a large pneumatised bony projection
    – the attachment of the sternocleidomastoid, splenius capitis and longissimus capitis
    6.6.1 **Mastoid cells** *(cellulae mastoideae)* – air filled cavities that communicate anteriorly with the mastoid antrum
  - 6.7 **Mastoid notch** *(incisura mastoidea)*
    – the origin of the posterior belly of the digastricus
  - 6.8 **Occipital groove** *(sulcus arteriae occipitalis)*
    – a groove for the occipital artery, located medial to the mastoid notch
  - 6.9 **Mastoid foramen** *(foramen mastoideum)* – transmits the mastoid emissary vein
  - 6.10 **Groove for sigmoid sinus** *(sulcus sinus sigmoidei)*
    – is located on the internal surface of the mastoid process
    – contains the internal entrance of the mastoid foramen
  - 6.11 **Stylomastoid foramen** *(foramen stylomastoideum)*
    – the external opening of the facial canal
    – transmits the facial nerve and the stylomastoid vessels

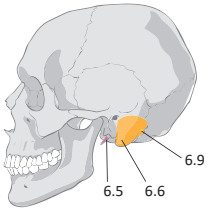

Lateral view of the skull

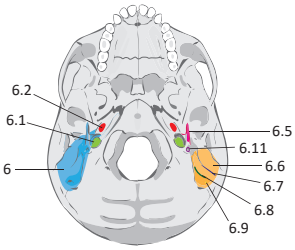

Inferior surface of the cranial base

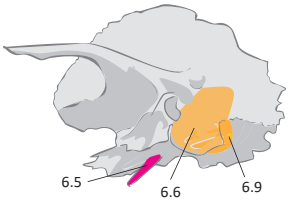

External oblique view of the left temporal bone

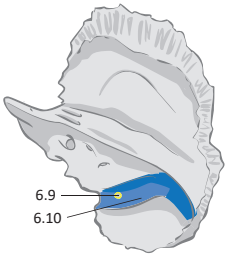

Internal oblique view of the right temporal bone

Facial canal of Falloppio *(canalis nervi facialis)*

The facial canal is a double-curved canal located inside the petrous part of the temporal bone. It contains the facial nerve.

1. **The entrance** is the area facialis of the fundus of the internal acoustic meatus.
2. **The labyrinthine part** *(pars labyrinthica)* runs ventrolaterally above the cochlea at a right angle to the long axis of the petrous part of the temporal bone.
3. **The geniculum** houses the geniculate ganglion of the facial nerve. Here the canal makes a **90° turn laterocaudally**. The greater petrosal nerve leaves in a small canal that also contains the petrosal branch of the middle meningeal artery.
4. **The tympanic part** *(pars tympanica)* runs dorsolaterally and parallel to the long axis of the petrosal part of the temporal bone between the medial and upper walls of the tympanic cavity.
5. The canal reaches the the posterior wall of the middle ear and makes a **90° turn downwards** forming the prominence of the facial canal *(prominentia canalis nervi facialis)* in the mastoid antrum.
6. **The mastoid part** *(pars mastoidea)* runs caudally in the posterior wall of the tympanic cavity. Two canals branch off here: the pyramidal eminence containing the nerve to the stapedius and the canaliculus of the chorda tympani which contains the chorda tympani and the posterior tympanic vessels.
7. **The exit** is the stylomastoid foramen, which trasmits the both the facial nerve and the stylomastoid vessels.

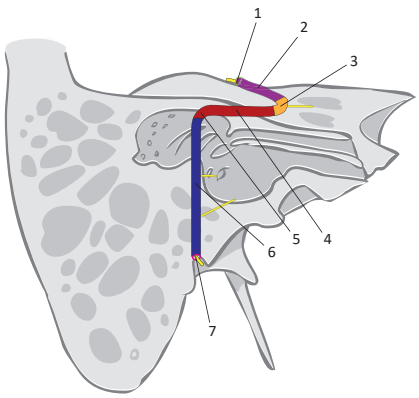

Section of the right temporal bone viewed from the right

This copy belongs to ali yaghoubi

The ethmoidal bone is an unpaired bone in the cranial base that develops by **endochondral ossification**. It consists of **a horizontal plate, a vertical plate and the ethmoidal labyrinth**. The ethmoidal bone is a **pneumatised bone** containing a paranasal sinus: **the ethmoidal air cells.**

- 1 **Perpendicular plate** *(lamina perpendicularis)* – part of the nasal septum
- 2 **Horizontal/cribriform plate** *(lamina cribrosa)*
- 2.1 **Cribriform foramina** *(foramina cribrosa)* – transmit the olfactory nerves *(fila olfactoria)*
  - 2.2 **Crista galli** – a bony plate located in the middle of the ethmoid bone, protruding above the cribriform plate
    – part of the attachment of the falx cerebri
- 3 **Ethmoidal labyrinths** *(labyrinthi ethmoidales)*
  - 3.1 **Orbital plate** *(lamina orbitalis)* – the outer wall of ethmoidal cells, facing the orbit
  - 3.2 **Anterior and posterior ethmoidal foramina** *(foramen ethmoidale anterius et posterius)*
    – are located between the ethmoidal and frontal bones
    – transmit the anterior and posterior ethmoidal artery, vein and nerve
- 4 **Ethmoidal cells** *(celullae ethmoidales)*
  - 4.1 **Anterior and middle ethmoidal cells** *(celullae ethmoidales anteriores et mediae)*
    – open into the middle nasal meatus via the ethmoidal infundibulum
    - 4.1.1 **Ethmoidal bulla** *(bulla ethmoidalis)* – a bulge in the lateral wall of the middle nasal meatus formed by the anterior ethmoidal cells
  - 4.2 **Posterior ethmoidal cells** *(celullae ethmoidales posteriores)*
    – open into the superior nasal meatus
- 5 **Nasal conchae** *(conchae nasales)* – project medially into the nasal cavity
  – divide the nasal cavity into the nasal meati
  - 5.1 **Superior nasal concha** *(concha nasalis superior)*
  - 5.2 **Middle nasal concha** *(concha nasalis media)*
    - 5.2.1 **Uncinate process** *(processus uncinatus)* – a dorsolateral arched projection of the middle nasal concha caudally to the inferior nasal concha

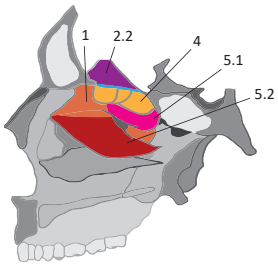

Lateral wall of the nasal cavity

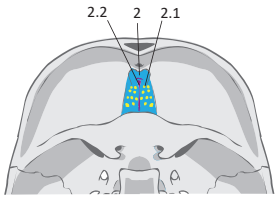

Internal view of the cranial base

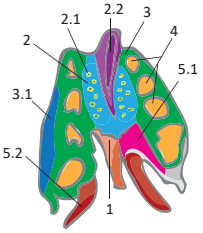

Posterior oblique view of the ethmoidal bone

The cerebral falx *(falx cerebri)* is a fold of dura mater located between the two cerebral hemispheres.

The supreme nasal concha *(concha nasalis suprema)* is a variable concha located on the roof of the nasal cavity.

Lamina papyracea ossis ethmoidalis is an obsolete term for the orbital plate of the ethmoid bone. As the name implies, this part of the ethmoid bone is very thin and liable to fracture.

The uncinate process of the middle nasal concha *(processus uncinatus conchae nasalis mediae)* is connected to the ethmoidal process of the inferior nasal concha. These two processes form the semilunar hiatus, which lies within the maxillary hiatus.

2.7 **Inferior nasal concha** – Concha nasalis inferior

Unlike the other conchae, **the inferior nasal concha** is an independent bone. The inferior nasal concha is connected to the maxilla and separates the **inferior nasal meatus** from the middle nasal meatus.

- 1 **Inferior nasal concha** *(concha nasalis inferior)*
  - 1.1 **Maxillary process** *(processus maxillaris)*
    – connects to the lateral wall of the nasal cavity
  - 1.2 **Lacrimal process** *(processus lacrimalis)* – connects to the lacrimal bone
  - 1.3 **Ethmoidal process** *(processus ethmoidalis)*
    – connects to the uncinate process of the middle nasal concha

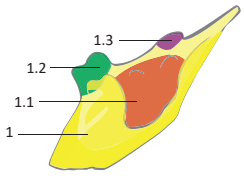

Left anterior view of the left inferior nasal concha

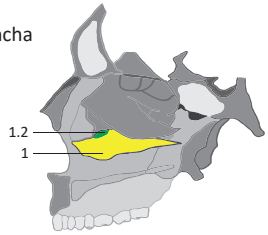

Inferior nasal concha viewed from the left

The lacrimal bone is a small paired bone that develops by **intramembranous ossification** and forms part of the medial wall of the orbit. **The nasal bone** is also a small paired bone that develops by **intramembranous ossification**. It is attached to the nasal part of the frontal bone. **The vomer** is a small unpaired sagitally oriented bone that develops by **intramembranous ossification** and forms the dorsal part of the nasal septum.

- 1 **Lacrimal bone** *(os lacrimale)*
  - 1.1 **Lacrimal groove** *(sulcus lacrimalis)*
    - – a rounded vertical groove
    - 1.1.1 **Fossa for the lacrimal sac** *(fossa sacci lacrimalis)*
      - – is formed by the lacrimal bone and maxilla
    - 1.1.2 **Posterior lacrimal crest** *(crista lacrimalis posterior)*
      - – the dorsal border of the lacrimal fossa
      - – the attachment of the medial palpebral ligament and the origin of the deep part of the orbicularis oculi
  - 1.2 **Nasolacrimal canal** *(canalis nasolacrimalis)*
    - – a bony canal that leads to the nasal cavity
    - – contains the nasolacrimal duct
    - – is bordered by the lacrimal hamulus
- 2 **Nasal bone** *(os nasale)*
  - 2.1 **Ethmoidal groove** *(sulcus ethmoidalis)*
    - – a groove for the nasal branch of the anterior ethmoidal nerve
  - 2.2 **Nasal foramen** *(foramen nasale)*
    - – transmits the external nasal branch of the anterior ethmoidal nerve
- 3 **Vomer**
  - – forms the dorsal third of the nasal septum
  - – divides at its cranial aspect into the paired alae of the vomer, which are connected to the rostrum of the sphenoidal bone
  - – caudally connected to the nasal crest of the hard palate
  - – ventrocranially connected to the perpendicular plate of the ethmoidal bone

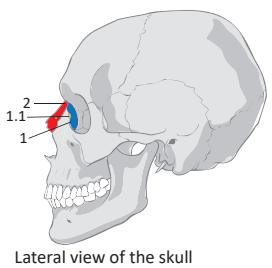

Lateral view of the skull

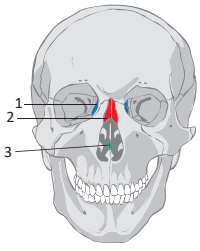

Anterior view of the skull

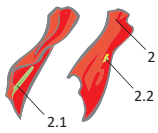

Anterior oblique view of the nasal bones

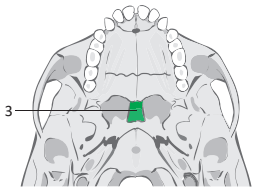

External view of the cranial base

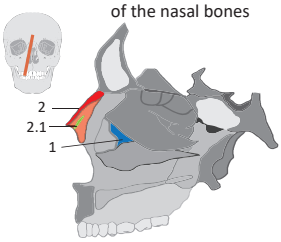

Lateral view of the nasal cavity

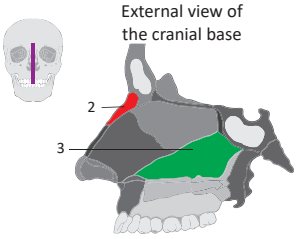

Middle wall of the nasal cavity

The zygomatic bone is a paired bone of the **viscerocranium** that develops by **intramembranous ossification**. Together with the **zygomatic process of the temporal bone** it forms the **zygomatic arch.** It contains the **zygomatic nerve**, which bifurcates inside the bone into two terminal branches that innervate the skin overlying the zygomatic bone and the temporal fossa.

- 1 **Orbital surface** *(facies orbitalis)*
  - – forms the lateral and caudal walls of the orbit
  - 1.1 **Zygomatico-orbital foramen** *(foramen zygomaticoorbitale)*
    - – the entrance for the zygomatic nerve
- 2 **Temporal surface** *(facies temporalis)*
  - – forms the anterior wall of the temporal fossa
  - 2.1 **Zygomaticotemporal foramen** *(foramen zygomaticotemporale)*
    - – transmits the zygomaticotemporal nerve
- 3 **Lateral surface** *(facies lateralis)*
  - – forms the skeleton of the zygomatic region of the face
  - 3.1 **Zygomaticofacial foramen** *(foramen zygomaticofaciale)*
    - – transmits the zygomaticofacial nerve

Projections

- 4 **Frontal process** *(processus frontalis)*
- 5 **Temporal process** *(processus temporalis)*
  - – forms the zygomatic arch with the zygomatic process of the temporal bone
- 6 **Orbital tubercle** *(tuberculum orbitale)* – the attachment of the lateral palpebral ligament and the suspensory ligament of the eyeball

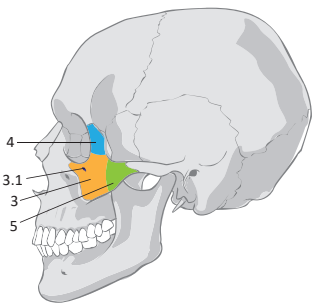

Lateral view of the skull

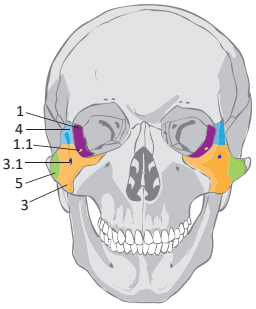

Anterior view of the skull

This copy belongs to ali yaghoubi

The palatine bone is a paired bone of the viscerocranium that develops by **intramembranous ossification**. It consists of two plates arranged perpendicularly to each other in an L-shape. These are **the horizontal plate** and **the perpendicuar plate**. The horizontal plate articulates with the maxilla, forming the hard palate.

- 1 **Horizontal plate** *(lamina horizontalis)*
  - 1.1 **Median palatine suture** *(sutura palatina mediana)*
    – connects the two palatine bones in the midline
  - 1.2 **Nasal crest** *(crista nasalis)* – a bony ridge adjacent to the median palatine suture and facing the nasal cavity
  - 1.3 **Palatine crest** *(crista palatina)* – a bony ridge adjacent to the median palatine suture and facing the oral cavity
  - 1.4 **Posterior nasal spine** *(spina nasalis posterior)*
    – the dorsal projection of the nasal crest
    – the origin of the musculus uvulae
  - 1.5 **Greater palatine foramen** *(foramen palatinum majus)*
    – an opening on the lateral surface near the connection with the maxilla
    – the terminal opening of the greater palatine canal, which transmits the greater palatine nerve and vessels
  - 1.6 **Lesser palatine foramina** *(foramina palatina minora)*
    – are located dorsal to the greater palatine foramen
    – the terminal openings of the lesser palatine canals, which transmit the lesser palatine nerves and vessels
  - 1.7 **Pyramidal process** *(processus pyramidalis)*
    – connects to the lateral plate of the pterygoid process
    – the origin of the medial pterygoid muscle
  - 1.8 **Nasal surface** *(facies nasalis)* – forms the dorsal part of the floor of the nasal cavity
  - 1.9 **Palatine surface** *(facies palatina)*
    – forms the dorsal part of the hard palate
- 2 **Perpendicular plate** *(lamina perpendicularis)*
  - 2.1 **Ethmoidal crest and conchal crest** *(crista ethmoidalis et crista conchalis)*
    – projections for the attachment of the middle and inferior nasal conchae
  - 2.2 **Orbital and sphenoidal process** *(processus orbitalis et sphenoidalis)*
    – two cranial processes
    – form the sphenopalatine notch
  - 2.3 **Sphenopalatine foramen** *(foramen sphenopalatinum)* – an opening formed by the sphenoid bone and the sphenopalatine notch of the palatine bone
    – transmits the sphenopalatine artery and posterior superior lateral and medial nasal branches of the maxillary nerve
  - 2.4 **Grater palatine canal** *(canalis palatinus major)*
    – is located between the maxillary bone and a groove on the maxillary surface of the palatine bone
    – transmits the greater palatine nerve and vessels
  - 2.5 **Lesser palatine canals** *(canales palatini minores)*
    – branches of the greater palatine canal
    – transmit the lesser palatine nerves and vessels
  - 2.6 **Maxillary surface** *(facies maxillaris)*
    – points towards the maxilla
  - 2.7 **Nasal surface** *(facies nasalis)*
    – forms the dorsal part of the lateral wall of the nasal cavity

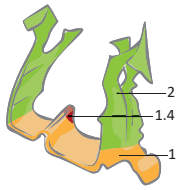

Anterior oblique view of the palatine bones

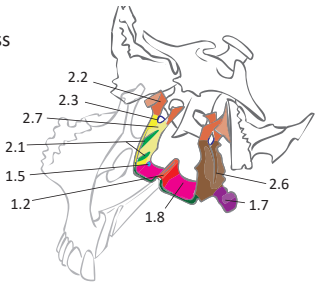

Anterior oblique view of the palatine bones

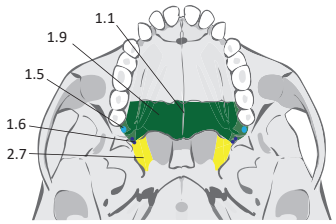

External view of the cranial base

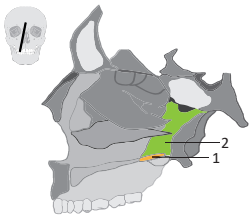

Oblique section through the nasal cavity

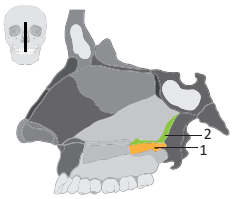

Middle wall of the nasal cavity

Involution of the alveolar processes. After loss of the teeth, the alveolar processes *(processus alveolaris)* of both the maxilla and mandible diminish in size.

Palatine spines *(spinae palatinae)* are longitudinal ridges on the inferior (palatinal) surface of the maxilla.

Palatine grooves *(sulci palatini)* are grooves between the palatine spines for the branches of the greater palatine nerve and vessels *(nervus et vasa palatina majora).*

The maxillary hiatus is narrowed by the ethmoidal bulla, the uncinate process of the middle nasal concha and the palatine bone.

The incisive fossa *(fossa incisiva)* is an anatomical term that is used for two different structures:
1. **A shallow pit above the first incisive** tooth on the anterior surface of the maxilla. This is the origin of the depressor septi nasi muscle *(musculus depressor septi nasi)*
2. **A pit behind the incisive teeth on the incisive bone** where the incisive foramina and the lower ends of the incisive canals are situated.

The maxilla is a paired bone of the **viscerocranium** that develops by **intramembranous ossification**. It consists of a **body** with **four surfaces** and **four processes.** The maxilla is a **pneumatised bone** and contains the largest paranasal sinus: **the maxillary sinus.**

- 1 **Body of maxilla** *(corpus maxillae)*
  - **Orbital surface** *(facies orbitalis)* – forms the floor of the orbit
    - 1.1 **Infra-orbital groove** *(sulcus infraorbitalis)* – a groove for the infra-orbital nerve and vessels
    - 1.2 **Infra-orbital canal** *(canalis infraorbitalis)*
      – the extension of the infra-orbital groove through the maxilla to the anterior surface
    - 1.3 **Infra-orbital margin** *(margo infraorbitalis)* – the caudal margin of the orbit
  - **Anterior surface** *(facies anterior)*
    - 1.4 **Infra-orbital foramen** *(foramen infraorbitale)* – the anterior opening of the infra-orbital canal
    - 1.5 **Canine fossa** *(fossa canina)* – is located lateral to the canine tooth root
      – the origin of the levator anguli oris
    - 1.6 **Nasal notch** *(incisura nasalis)* – forms the caudal border of the piriform aperture (the orifice of the nasal cavity)
  - **Infratemporal surface** *(facies infratemporalis)* – forms the anterior wall of the infratemporal fossa
    - 1.7 **Maxillary tuberosity** *(tuber maxillae)*
    - 1.8 **Alveolar foramina** *(foramina alveolaria)* – transmit the posterior superior alveolar branches of the maxillary nerve and the posterior superior alveolar vessels to the upper posterior teeth
  - **Nasal surface** *(facies nasalis)* – the medial surface of the maxilla
    – forms part of the lateral wall of the nasal cavity
    - 1.9 **Lacrimal notch** *(incisura lacrimalis)*
      – borders the entrance of the nasolacrimal canal
    - 1.10 **Lacrimal groove** *(sulcus lacrimalis)*
      – forms the nasolacrimal canal with the inferior nasal concha
    - 1.11 **Conchal crest** *(crista conchalis)*
      – a projection for the attachment of the inferior nasal concha
    - 1.12 **Maxillary hiatus** *(hiatus maxillaris)*
      – the opening of the maxillary sinus into the middle nasal meatus
    - 1.13 **Maxillary sinus / antrum of Highmore** *(sinus maxillaris)*
      – a paranasal sinus that opens into the middle nasal meatus

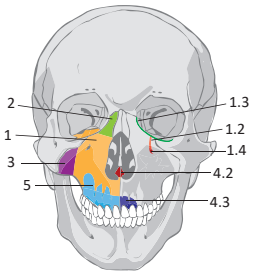

Anterior view of the skull

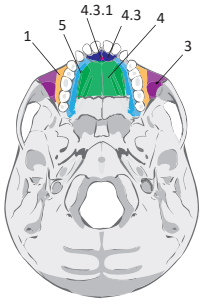

External view of the cranial base

Processes:

- 2 **Frontal process** *(processus frontalis)*
  - 2.1 **Anterior lacrimal crest** *(crista lacrimalis anterior)*
    – together with the lacrimal bone forms a fossa for the lacrimal sac
    – the attachment of the medial palpebral ligament
  - 2.2 **Ethmoidal crest** *(crista ethmoidalis)*
    – a projection for the attachment of the middle nasal concha
- 3 **Zygomatic process** *(processus zygomaticus)*
- 4 **Palatine process** *(processus palatinus)* – forms the hard palate
  – connects to the contralateral palatine process, forming the median palatine suture
  - 4.1 **Nasal crest** *(crista nasalis)* – an elevation projecting into the nasal cavity located above the median palatine suture
  - 4.2 **Anterior nasal spine** *(spina nasalis anterior)*
    – the ventral prominence of the nasal crest
  - 4.3 **Incisive bone** *(os incisivum, premaxilla)*
    – the ventral part of maxilla that holds the incisor teeth
    – develops as an independent bone (the primary palate)
    – is separated from the maxilla by the incisive suture, which is only present in some adults
    - 4.3.1 **Incisive foramen** *(foramen incisivum)*
      – a paired opening located in the midline on the median palate suture
    - 4.3.2 **Incisive canal** *(canalis incisivus)* – a paired canal connecting the nasal and oral cavities
      – transmits the nasopalatine nerve and a branch of the sphenopalatine artery

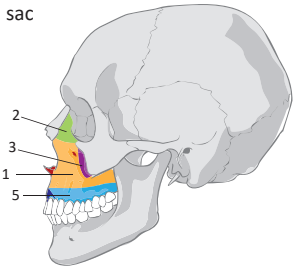

Lateral view of the skull

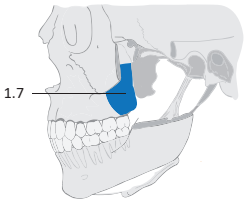

Lateral view of the skull

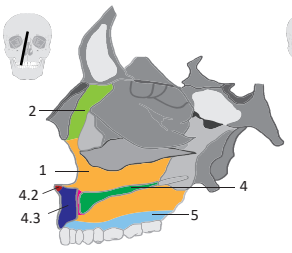

Lateral wall of the nasal cavity

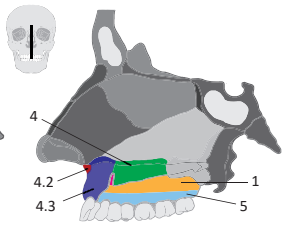

Medial wall of the nasal cavity

- 5 **Alveolar process** *(processus alveolaris)* – contains the dental alveoli (teeth sockets)
  - 5.1 **Alveolar arch** *(arcus alveolaris)* – an ellipsoid arch of the dental alveoli
  - 5.2 **Alveolar yokes** *(juga alveolaria)* – surround the dental roots
  - 5.3 **Dental alveoli** *(alveoli dentales)* – spaces for the teeth
  - 5.4 **Interalveolar septa** *(septa interalveolaria)* – septa between the teeth
  - 5.5 **Interradicular septa** *(septa interradicularia)* – septa between roots of the teeth

This copy belongs to ali yaghoubi

The mandible is an unpaired bone of **the viscerocranium** that develops as a paired bone by both **intramembranous** and **endochondral ossification**. It consists of a **body** and two broad **rami**. The mandible is the only skull bone that is connected with the rest of the skull by a synovial joint: **the temporomandibular joint**. It serves as a place of insertion for all the **masticatory muscles**.

- 1 **Body of mandible** *(corpus mandibulae)* – the unpaired central part of the bone
  - 1.1 **Base of mandible** *(basis mandibulae)* – the rounded caudal margin of the mandible
  - 1.2 **Mental protuberance** *(protuberantia mentalis)* – the unpaired prominence of the chin
    - 1.2.1 **Mental tubercle** *(tuberculum mentale)* – is located on the mental protuberance
  - 1.3 **Mental foramen** *(foramen mentale)* – the external opening of the mandibular canal
    – transmits the inferior alveolar nerve and vessels
  - 1.4 **Digastric fossa** *(fossa digastrica)* – the attachment of the anterior belly of the digastricus
  - 1.5 **Superior and inferior mental spines** *(spina mentalis superior et inferior)*
    – the genioglossus originates on the superior mental spine
    – the geniohyoid originates on the inferior mental spine
  - 1.6 **Mylohyoid line** *(linea mylohyoidea)* – the origin of the superior constrictor of the pharynx and the mylohyoid and the attachment of the pterygomandibular raphe
  - 1.7 **Sublingual fossa** *(fovea sublingualis)* – is located above the mylohyoid line
    – the location of the sublingual salivary gland
  - 1.8 **Submandibular fossa** *(fovea submandibularis)* – is located below the mylohyoid line
    – the location of the of submandibular salivary gland
  - 1.9 **Alveolar part** *(pars alveolaris)* – houses the teeth
    - 1.9.1 **Alveolar arch** *(arcus alveolaris)*
      – a parabolic arch of dental alveoli
    - 1.9.2 **Alveolar yokes** *(juga alveolaria)*
      – woven bone surrounding the dental roots
    - 1.9.3 **Dental alveoli** *(alveoli dentales)* – spaces for the teeth
- 2 **Ramus of mandible** *(ramus mandibulae)*
  - 2.1 **Angle of mandible** *(angulus mandibulae)*
    - 2.1.1 **Masseteric tuberosity** *(tuberositas masseterica)*
      – a tuberosity on the external surface of the angle
      – the insertion of the masseter
    - 2.1.2 **Pterygoid tuberosity** *(tuberositas pterygoidea)*
      – a tuberosity on the internal surface of the angle
      – the insertion of the medial pterygoid and the attachment of the stylomandibular ligament
  - 2.2 **Mandibular foramen** *(foramen mandibulae)*
    – the entrance of the mandibular canal
    - 2.2.1 **Mandibular canal** *(canalis mandibulae)*
      – runs through the ramus and body of the mandible
      – transmits the inferior alveolar nerve and inferior alveolar vessels
  - 2.3 **Mylohyoid groove** *(sulcus mylohyoideus)*
    – a groove for the mylohyoid nerve and vessels
  - 2.4 **Condylar process** *(processus condylaris)*
    - 2.4.1 **Head of mandible** *(caput mandibulae)*
      – the articular head of the temporomandibular joint
    - 2.4.2 **Neck of mandible** *(collum mandibulae)*
      – the attachment of the lateral temporomandibular ligament
    - 2.4.3 **Pterygoid fovea** *(fovea pterygoidea)*
      – the insertion of the lateral pterygoid muscle
  - 2.5 **Coronoid process** *(processus coronoideus)*
    – the attachment of the temporal muscle
    - 2.5.1 **Temporal crest** *(crista temporalis)*
      – is located between the anterior border of the coronoid process and the external surface of the body of the mandible
      – the insertion of the temporal muscle
  - 2.6 **Mandibular notch** *(incisura mandibulae)* – a notch located between the condylar and coronoid process that transmits the masseteric artery and vein

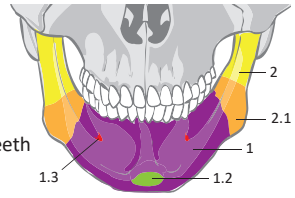

Anterior view of the skull

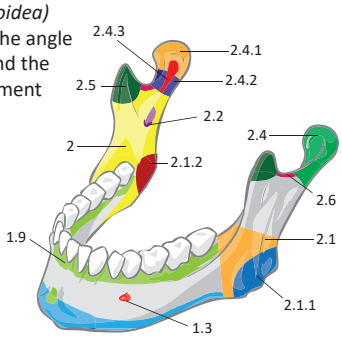

Anterior oblique view of the mandible

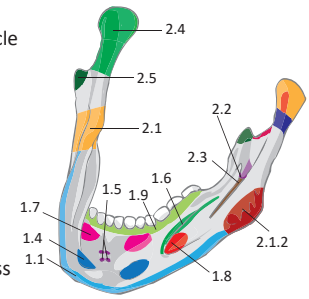

Posterior oblique view of the mandible

The retromolar triangle *(trigonum retromolare)* is a triangular space located behind the third molar.

The retromolar fossa *(fossa retromolaris)* is a depression located in the retromolar triangle.

The lingula of the mandible *(lingula mandibulae)* delimits the mandibular foramen anteriorly and serves as the attachment for the sphenomandibular ligament.

The oblique line *(linea obliqua)* is a line on the outer surface of the mandible leading to the mental tubercle and separating the base of the mandible *(basis mandibulae)* from the alveolar part *(pars alveolaris)*. It serves as an origin for some of the facial muscles.

Small and independent centres of ossification may occur in certain fontanelles. This leads to formation of some small accessory skull bones. Such bones include **the bregmatic bone** *(os bregmaticum)* in the anterior fontanelle and **the epipteric bone** *(os epipticum)* in the posterior fontanelle**.**

Sutural bones *(ossa suturarum)* are also known as **Wormian bones**. They are variable small irregular bones located within the cranial sutures, most frequently around the parietal bones.

Clinical notes

The hyoid bone is sensitive to palpation in disorders of the infrahyoid and suprahyoid muscles (especially the digastric muscle).

Venepuncture can be performed through the anterior fontanelle to get a sample of dural venous blood.

Premature closure of the sutures of the newborn skull results in a condition called **craniosynostosis** and can result in a misshaped skull, intellectural diability and hydrocephalus.

The brain of newborns and infants may be viewed by ultrasound through the anterior fontanelle.

The anterior and posterior fontanelles help orientate the head of the baby during delivery.

The hyoid bone is an unpaired bone located between the muscles of neck **at the level of C2–C3**. The hyoid bone develops by **enchondral ossification**. It has muscular attachments for the larynx, pharynx, tongue and floor of the mouth.

- 1 **Body of hyoid bone** (*corpus ossis hyoidei*)
  - the unpaired central portion of the bone
  - the insertion of the geniohyoid, mylohyoid, stylohyoid, sternohyoid and superior belly of the omohyoid
  - the attachment of the thyrohyoid membrane and the thyoepiglottic ligament
- 2 **Greater horn** *(cornu majus)*
  - paired lateral parts of the bone
  - projects dorsally from the body
  - the origin of the middle constrictor of the pharynx
  - the attachment of the thyrohyoid membrane
  - the insertion of the thyrohyoid muscle
  - the attachment of a fibrous sling that pulls the intermediate tendon of the digastricus towards the hyoid bone
- 3 **Lesser horn** *(cornu minus)*
  - a paired short projection from the body
  - projects dorsocranially from the lateral part of the body
  - the origin of the middle constrictor of the pharynx
  - the attachment of the stylohyoid ligament

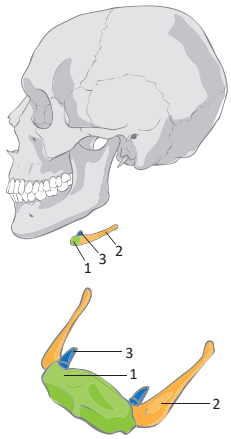

Left superior anterior view of the hyoid bone

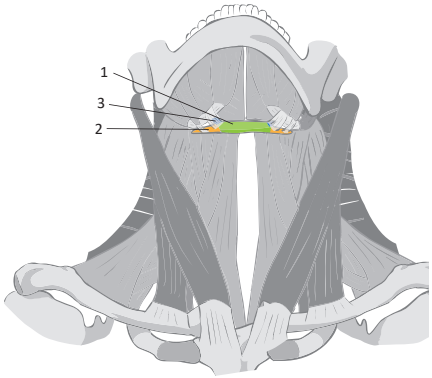

2.14 Skull of a newborn

In contrast to the skull of an adult, **the skull of a newborn** has a large neurocranium and a small viscerocranium. **The dorsoventral diameter is 11.5 cm, the transverse dimension is 9.5 cm and the circumference is 34 cm. Fontanelles** are gaps in the infant skull located at the junctions of two or more sutures and are covered by fibrous membranes.

1 **Frontal bone** *(os frontale)* – a paired bone connected by the frontal suture

2 **Fontanelles** *(fonticuli cranii)* – gaps between skull bones covered by fibrous membranes

- 2.1 **Anterior fontanelle** *(fonticulus anterior)* – is diamond shaped
  - is located at the junction between the coronal and sagittal suture
  - closes by the 2nd year of life
- 2.2 **Posterior fontanelle** *(fonticulus posterior)* – is triangle-shaped
  - is located at the junction between the sagittal and lambdoid suture
  - closes by the 3rd month of life and sometimes is not even palpable at birth
  - an orientation point for obstetricians
- 2.3 **Sphenoidal fontanelle** *(fonticulus sphenoidalis)*
  - has an irregular square shape
  - is located on the medial wall of the temporal fossa between the parietal bone, frontal bone, the squamous part of the temporal bone and the greater wings of the sphenoid bone
  - closes by the 6th month of life
- 2.4 **Mastoid fontanelle** *(fonticulus mastoideus)*
  - closes by 6th–18th month of life
  - is located between the mastoid process, parietal bone and occipital bone

3 **Mandible** *(mandibula)* – has a very small body and rami
- the mandibular symphysis is located in the midline of the body and closes by the first year of life
- has no alveolar process
- has an obtuse angle between the body and rami
- the shape of the newborn mandible allows significant protraction during breastfeeding

4 **Paranasal sinuses** – are not developed or are just slightly implied

5 **Hard palate** – the incisive suture is present between the maxilla and the incisive bone

6 **Tympanic part of the temporal bone** – forms an opened ring

7 **Cranial sutures** – are not fused in the newborn skull, which makes the skull more flexible during delivery

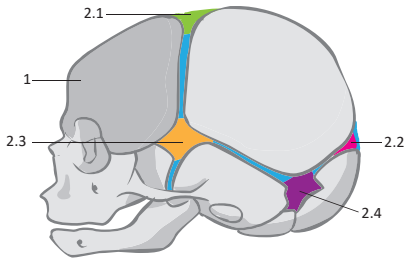

Lateral view of a newborn skull

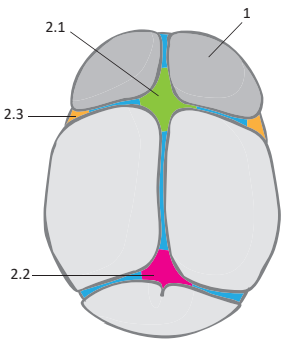

Superior view of newborn skull

This copy belongs to ali yaghoubi

Craniometric landmarks are used for measuring the dimensions of the skull. They can be applied to determine the sex of the skull. Outside of clinical medicine, **craniometry** is used in **forensic pathology, biological anthropology and archaeology.**

The basic anthropometric plane

- **Auriculo-orbital plane** – is also known as Frankfurt's (horizontal) plane
  – traverses the lower margin of the orbit and upper margin of the external acoustic meatus
  – establishes the anatomical position of the human skull

Craniometric landmarks

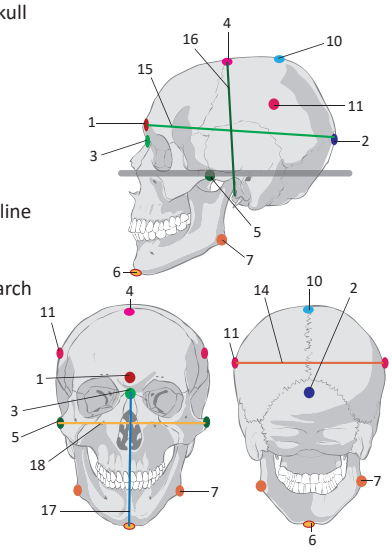

1 **Glabella** – a flattened area above the nasal root
2 **Opisthocranion** – a point located on the posterior part of the skull
– the most distant landmark from the glabella
3 **Nasion** – lies on the nasofrontal suture in the midline
4 **Bregma** – is found at the intersection of the coronal and sagittal sutures
5 **Zygion** – the most lateral point on the zygomatic arch
6 **Gnathion** – the most caudal point in the midline of the mandible
7 **Gonion** – is located at the angle of the mandible
8 **Basion** – is located in the middle of the ventral margin of the foramen magnum
9 **Opisthion** – is located in the middle of the dorsal margin of the foramen magnum
10 **Vertex** – the highest point of the skull
11 **Euryon** – the most lateral point on the skull
– is usually located on the parietal bone
12 **Pterion** – the intersection of the temporal, frontal and sphenoidal bones
– is located over the sphenoidal fontanelle in the skull of a newbown
13 **Asterion** – is located on the mastoid fontanelle

Craniometric measurement

14 **Width of skull:** euryon to euryon
15 **Length of skull**: glabella to opisthocranion
16 **Height of skull**: basion to bregma
17 **Height of face:** nasion to gnathion
18 **Width of face:** zygion to zygion

Sex differences in the skull

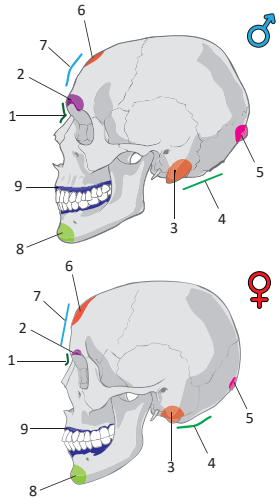

1 **Nasofrontal transition**
– is distinct in men but continuous in women
2 **Superciliary arches**
– are distinct in men but discrete in women
3 **Mastoid processes**
– is distinct in men but discrete in women
4 **Occipital plane**
– is flat in men but curved in women
5 **External occipital protuberance**
– is distinct in men but discrete in women
6 **Frontal tubers**
– is discrete in men but distinct in women
7 **Shape of the forehead**
– is sloped in men but steep in women
8 **Shape of the chin**
– is square-shaped in men but round in women
9 **Alveolar processes**
– protrude further outwards in men

Sclerotomes are formed from mesenchymal cells from the paraxial mesoderm. They are situated bilaterally to the neural tube and notochord. Their medial parts give rise to the vertebral bodies. Their lateral parts surround the neural tube and give rise to the vertebral arches. **The complete vertebra** is formed by fusion of two halves of two adjacent sclerotomes: the caudal half of the more cranial sclerotome and the cranial half of the more caudal sclerotome.

Kyphoses of the vertebral column are partially developed at birth. **Lordoses** are formed after birth when the baby activates and fully uses the muscles of the back. This occurs through lifting the head, which forms the **cervical lordosis,** and by erecting the trunk and walking, which forms the **lumbar lordosis**.

Abbreviations used for transitions points in the vertebral column:
AO – atlanto-occipital joint
CT – cervicothoracic transition
TL – thoracolumbar transition
LS – lumbosacral transition

Movements of the vertebral column are discussed on page 75.

Clinical notest

Pain in CT and TL transitions can occur as a result of changes in the curvatures of the vertebral column.

Scoliosis is a sideways curvature of the spine. It occurs most often during the growth spurt just before puberty.

Hyperlordosis and hyperkyphosis are pathological conditions caused by excessive anteroposterior curvatures of the vertebral column. Loss of the natural lower curvature of the spine is called flat back or flat back syndrome.

The spinous processes are sensitive to palpation in muscular disorders, particulary in disorders affecting the erector spinae muscles.

The advantage of vertebral column is its ability to help treat orthopaedic conditions of the distal parts of the body. **The disadvantage** is its capability to develop problems that originate in distal parts of the body.

The individual segments of the spine are often hypomobile. By contrast transitions of the vertebral column (AO, CT, TL, LS) are hypermobile and have a tendency to become overloaded.

The vertebral column is derived from the sclerotomes. **The vertebrae** are the individual bony units of the vertebral column. We differentiate **7 cervical vertebrae, 12 thoracic vertebrae, 5 lumbar vertebrae, 5 fused sacral vertebrae and 4–5 fused coccygeal vertebrae**. The vertebral column has four ventrodorsal curves (two kyphoses and two lordoses) and a slight lateral curve (a physiological scoliosis).

Vertebra – general organisation

- 1 **Vertebral body** *(corpus vertebrae)*
  - – the large ventral part of the vertebrae
  - 1.1 **Intervertebral surface** *(facies intervertebralis)*
    - – connects to the intervertebral disc
  - 1.2 **Anular epiphysis** *(epiphysis anularis)* – a ring of compact bone on the external margin of the upper and lower surface of the vertebral body
    - – contains a secondary ossification centre
- 2 **Vertebral arch** *(arcus vertebrae)* – attaches to the dorsal surface of the vertebral body
  - 2.1 **Pedicle** *(pediculus arcus vertebrae)* – the anterior part of the vertebral arch
    - – the narrowest part of the arch
    - – connect to the vertebral body
  - 2.2 **Lamina** *(lamina arcus vertebrae)* – the posterior part of the vertebral arch
  - 2.3 **Superior and inferior vertebral notch** *(incisura vertebralis superior et inferior)*
    - – paired notches located on the anterior part of the vertebral arch
    - – the superior notch is shallow and the inferior notch is deep)
    - 2.3.1 **Intervertebral foramen** *(foramen intervertebrale)*
      - – is formed by connection of the notches of adjacent vertebrae
      - – transmits the spinal nerve with some small vessels
  - 2.4 **Vertebral foramen** *(foramen vertebrale)* – is bordered by the body and arch
    - 2.4.1 **Vertebral canal** *(canalis vertebralis)*
      - – contains the spinal cord with its meninges and vessels
      - – is formed by connection of adjacent vertebral foramina
- 3 **Processes**
  - 3.1 **Spinous process** *(processus spinosus)* – an unpaired palpable process
  - 3.2 **Transverse process** *(processus transversus)*
    - – a paired process, palpable only on the cervical vertebrae
  - 3.3 **Superior and inferior articular process** *(processus articularis superior et inferior)*
    - – paired articular processes pointing cranially and caudally respectively

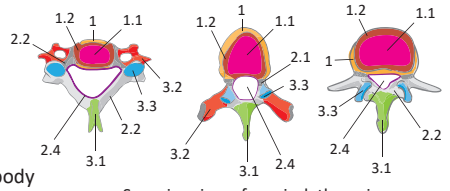

Superior view of cervical, thoracic and lumbar vertebrae

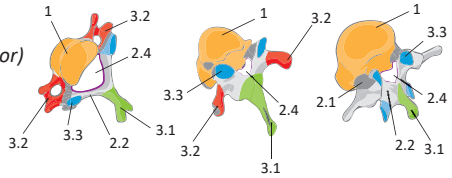

Posterior oblique view of cervical, thoracic and lumbar vertebrae

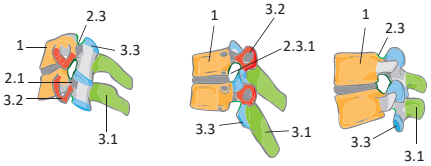

Lateral view of cervical, thoracic and lumbar vertebrae

Basic classification of vertebrae

- 1 **Cervical vertebrae (C)** – 7 vertebrae of the neck
- 2 **Thoracic vertebrae (T)** – 12 vertebrae of the thorax
- 3 **Lumbar vertebrae (L)** – 5 vertebrae of the loin
- 4 **Sacrum (S)** – is formed from 5 fused vertebrae
- 5 **Coccyx (Co)** –is formed from 4–5 fused rudimentary vertebrae

Curvatures of the vertebral column

6 **Primary curvatures** *(curvaturae primariae)*
- – are kyphoses, which are curves with a dorsal convexity
- 6.1 **Thoracic kyphosis** *(kyphosis thoracica)*
- 6.2 **Sacral kyphosis** *(kyphosis sacralis)*

7 **Secondary curvatures** *(curvaturae secundariae)*
- – are lordoses, which are curves with a ventral convexity
- 7.1 **Cervical lordosis** *(lordosis cervicalis)*
  - – develops as the child starts to use the muscles of the neck and raise his/her head
- 7.2 **Lumbar lordosis** *(lordosis lumbalis)*
  - – develops when the child stands-up and learns to walk

8 **Scoliosis**
- – is a lateral curve of the vertebral column, pathologic when distinct
- – is characterised by wedging and rotation of vertebrae
- – C-type and S-type

8.1 **Physiological scoliosis** – is a lateral curve at the level of T3 without rotation of the vertebrae

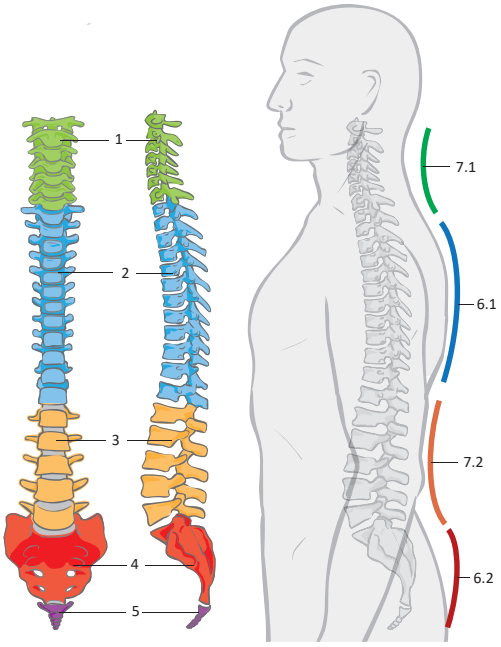

Anterior and lateral view of the vertebral column

This copy belongs to ali yaghoubi

The cervical vertebral column consists of 7 vertebrae and forms **the cervical kyphosis.** The cervical vertebrae share similar morphological features. **The atlas (C1)** greatly differs from the basic structure of the vertebrae as it does not have a vertebral body. During development, its body fuses with the dens and becomes part of C2. The cervical vertebral column is **connected to the skull** and thus participates in **skull movements**.

Cervical vertebra *(vertebra cervicalis)*

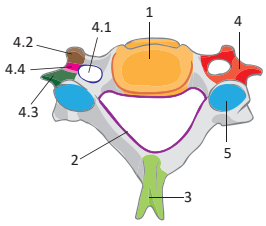

- 1 **Body** – is small and oval to kidney-shaped
  - 1.1 **Uncus of body** *(uncus corporis)*
    – a paired eminence on the lateral sides of the body
- 2 **Vertebral foramen** – is triangular-shaped
- 3 **Spinous process** – is bifid (with the exception of C1 and C7)
- 4 **Transverse process**
  - 4.1 **Transverse foramen** *(foramen transversarium)* – transmits the vertebral artery (C6–C1) and the vertebral vein (C1–C7)
  - 4.2 **Anterior tubercle** *(tuberculum anterius*) – a remnant of the cervical rib
  - 4.3 **Posterior tubercle** *(tuberculum posterius)*
    – the embryological derivative of the transverse process
  - 4.4 **Groove for spinal nerve** *(sulcus nervi spinalis)*
    – the continuation of the intervertebral foramen
- 5 **Articular process** – is located between the transverse and frontal planes
  – superior articular process points dorsocranially
  – inferior articular process points ventrocaudally

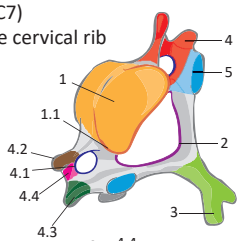

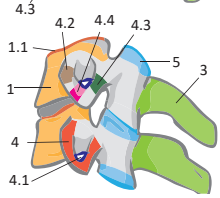

Superior, oblique superior and lateral view of the cervical vertebrae

Atlas (C1)

Specific features of the atlas:

- 1 **Lateral mass** *(massa lateralis)*
  - 1.1 **Superior articular surface** *(facies articularis superior)*
    – articulates with the occipital condyle on the occipital bone
    – is concave and kidney-shaped
  - 1.2 **Inferior articular surface** *(facies articularis inferior)*
    – is flat with a rotund surface for articulation with the axis
- 2 **Anterior arch** *(arcus anterior atlantis)*
  – the attachment of the anterior atlanto-occipital membrane and anterior atlanto-axial ligament
  - 2.1 **Facet for dens** *(fovea dentis)* – aritculates with the dens
    – is located on the dorsal surface of the anterior arch
  - 2.2 **Anterior tubercle** *(tuberculum anterius)* – the attachment of the longus colli and anterior longitudinal ligament
    – is located on the ventral surface of the anterior arch
- 3 **Posterior arch** *(arcus posterior atlantis)*
  – the attachment of the posterior atlanto-occipital membrane
  - 3.1 **Groove for vertebral artery** *(sulcus arteriae vertebralis)*
    – paired grooves located on the cranial aspect of the posterior arch for the vertebral artery and vein and the suboccipital nerve
  - 3.2 **Posterior tubercle** *(tuberculum posterius)*
    – the embryological remnant of the spinous process
    – the origin of the rectus capitis posterior minor and the attachment of the nuchal ligament

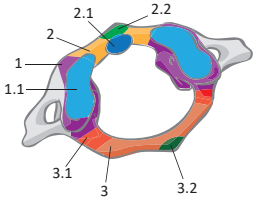

Superior view of the atlas

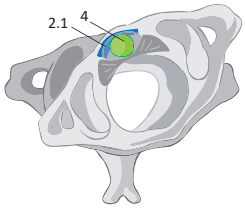

Reciprocal movements of C1 and C2

Axis (C2)

Specific features of the axis :

- 4 **Dens** *(dens axis)* – the embryological remnant of the body of the atlas
  – articulates with the anterior arch of the atlas
  - 4.1 **Anterior articular facet** *(facies articularis anterior)*
    – articulates with the atlas
  - 4.2 **Posterior articular facet** *(facies articularis posterior)*
    – articulates with the transverse ligament of the atlas
  - 4.3 **Apex** *(apex dentis)* – the embryological remnant of the body of the occipital vertebra

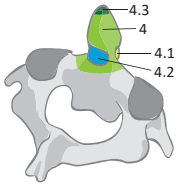

Posterior oblique view of the axis

The weakest spot on the axial skeleton is the T5 vertebra.

Vertebra prominens is the clinical term for vertebra C7. It has an accentuated non-bifurcated spinous process with a spherical end. It is an orientation point used during palpation of the vertebral column.

Accentuated spinous processes can also be found on vertebra C6 and even T1. When palpating spinous processes the patient's head must be in dorsiflexion. The first palpable vertebra going in a craniocaudal direction is C7. The other cervical spinous processes are not palpable.

Epistropheus is an obsolete term for the vertebra C2 (axis).

The atlas is named after the Greek god atlas who held the celestial sphere on his shoulders. The atlas mountain range in North Africa also bear his name.

The groove for the vertebral artery can be changed into a canal by an osseous bridge.

Clinical notes

Disorders of the cervical spine can lead to compression of the vertebral artery which results in reduced blood supply to the brain. This causes a syndrome called vertebrobasilar insufficiency, which is characterised by a constellation of various symptoms depending on which part of the brain is affected. Symptoms include fatigue, headache, vertigo, tinnitus and unconsciousness. The disorder is most commonly caused by atherosclerosis of the vertebral ateries.

The transverse processes of the atlas and axis may be sensitive to touch and pressure. This is typically caused by a **hypertonic levator scapula**, which typically occurs in people with sedentary lifestyles or from carrying heavy weights.

Fracture of the dens axis with posterior dislocation causes immediate death by compression of the medulla oblongata. This is the mechanical principle of death caused by hanging.

Sandberg projection is the X-ray picture of the dens axis taken from the front with an open mouth. The dens axis is **approached surgically** through the posterior pharyngeal wall.

The thoracic vertebral column consists of **12 vertebrae** that share morphological characteristics and form the **thoracic kyphosis**. **The connections of the ribs** to the thoracic vertebrae restrict the movements of the thoracic vertebral column.

Thoracic vertebrae *(vertebrae thoracicae)*

- 1 **Body** – is heart-shaped and rougly as tall as it is wide
  - 1.1 **Aortic impression** *(impressio aortica)*
    - – a shallow impression for the descending aorta
    - – is found on the vertebral bodies T4–T9
  - 1.2 **Superior and inferior costal facets** *(fovea costalis superior et inferior)*
    - – articular facets for articulation with the head of the rib
    - – vertebrae T1–T9 have two pairs of facets
    - – vertebrae T10–T12 have only one pair of facets
- 2 **Vertebral foramen** – is round or diamond-shaped
- 3 **Spinous process** – are long and point caudally
- 4 **Transverse process**
  - 4.1 **Transverse costal facet** *(fovea costalis processus transversi)*
    - – articulates with the costal tubercle of the rib
    - – are not present on T11 and T12
- 5 **Articular processes**
  - – project in the frontal plane
  - – the superior articular facets point dorsally
  - – the inferior articular facets point ventrally
  - – the exception is vertebra T12 which has caudal facets in sagittal plane

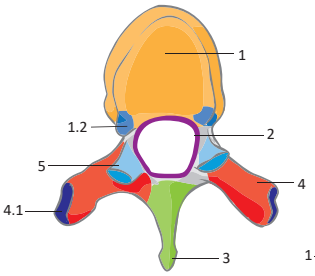

Superior view of a thoracic vertebra

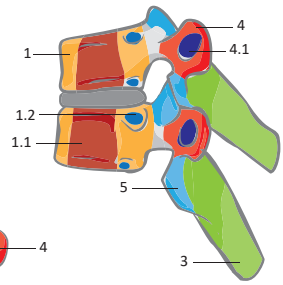

Lateral view of two thoracic vertebrae

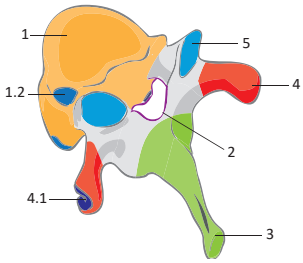

Posterior oblique view of a thoracic vertebra

The lumbar vertebral column consists of **5 large vertebrae** that share morphological characteristics and form the **lumbar lordosis**. Transverse processes are less well developed on the lumbar vertebrae. With respect to their embryological origin, **the costal processes** are the lumbar equivalents of the ribs.

Lumbar vertebrae *(vertebrae lumbales)*

- 1 **Body** – is tall, wide and kidney-shaped
  - – is taller ventrally than it is dorsally
  - – the body of L5 is wedge-shaped
- 2 **Vertebral foramen** – is triangular
- 3 **Spinous process** – is flat and quadrate-shaped when viewed from the side
- 4 **Costal process** *(processus costalis)*
  - – the embryological remnant of the lumbar rib
  - 4.1 **Mammillary process** *(processus mammillaris)*
    - – the embryological remnant of the transverse process
  - 4.2 **Accessory process** *(processus accessorius)*
- 5 **Articular process** – is in the sagittal plane
  - – the cranial facets points medially
  - – the caudal facets points laterally

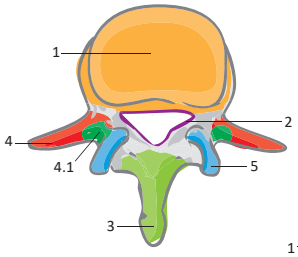

Superior view of a lumbar vertebra

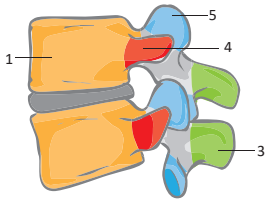

Lateral view of two lumbar vertebrae

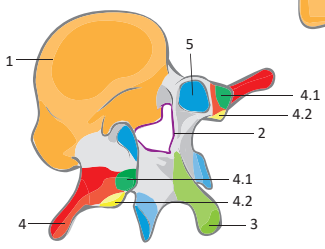

Posterior oblique view of a lumbar vertebra

This copy belongs to ali yaghoubi

The sacrum is formed by fusion of the 5 sacral vertebrae. It forms a ventral concavity known as the **sacral kyphosis**. The **sacral canal** runs through the entire bone and contains **the cauda equina**. The cranial border of the sacrum, called **the promontory**, projects ventrally. **The coccyx** consists of **4–5 fused rudimentary vertebrae.**

Sacrum *(os sacrum)*

- 1 **Base** *(basis ossis sacri)* – the cranial part of the sacrum
  - 1.1 **Promontory** *(promontorium)* – a ventral bulging on the cranial margin – a part of the linea terminalis, which is the borderline between the greater and lesser pelvis
  - 1.2 **Superior articular process** *(processus articulares superiores)* – articulates with the corresponding inferior articular process of the 5th lumbar vertebra
- 2 **Lateral parts** *(partes laterales ossis sacri)* – paired lateral parts formed by fusion of remnants of the sacral ribs
  - 2.1 **Wing** *(ala ossis sacri)* – the cranial surface of the lateral part of the sacrum
  - 2.2 **Auricular surface** *(facies auricularis)* – articulates with the ilium
  - 2.3 **Sacral tuberosity** *(tuberositas ossis sacri)* – the attachment of the interosseous and posterior sacro-iliac ligament interosseum et posterius
- 3 **Apex** *(apex os sis sacri)* – connects to the coccyx via an intervertebral disc
- 4 **Pelvic surface** *(facies pelvica)* – the smooth ventral surface of the sacrum – forms the dorsal wall of the lesser pelvis
  - 4.1 **Transverse ridges** *(lineae transversae)* – lines of fusion of the vertebrae – the origin of the piriformis
  - 4.2 **Anterior sacral foramina** *(foramina sacralia anteriora)* – 4 pairs of openings – transmit the anterior rami of the sacral spinal nerves and spinal branches of vessels
- 5 **Dorsal surface** *(facies dorsalis)* – a roughened surface – the origin of the muscles of the back, septa and fasciae
  - 5.1 **Median sacral crest** *(crista sacralis mediana)* – fused spinous processes
  - 5.2 **Medial sacral crest** *(crista sacralis medialis)* – fused articular processes
  - 5.3 **Lateral sacral crest** *(crista sacralis lateralis)* – fused transverse processes
  - 5.4 **Posterior sacral foramina** *(foramina sacralia posteriora)* – 4 pairs of openings – transmit the posterior branches of the sacral spinal nerves S1–S4
  - 5.5 **Sacral canal** *(canalis sacralis)* – the extension of the vertebral canal
    - 5.5.1 **Sacral hiatus** *(hiatus sacralis)* – the caudal end of the sacral canal – transmits spinal nerves S5 and Co
    - 5.5.2 **Sacral cornua/horns** *(cornua sacralia)* – lateral borders the of sacral hiatus – remnants of the articular processes

Coccyx *(os coccygis)* – tailbone

- 6 **Coccyx** *(os coccygis)*
  - 6.1 **Coccygeal cornua** *(cornua coccygea)* – horns pointing cranially – remnants of the articular processes

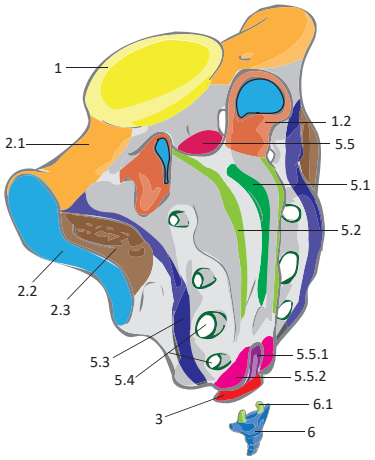

Posterior oblique view of the sacrum and coccyx

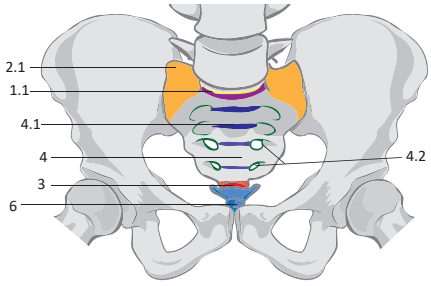

Anterior view of the pelvis

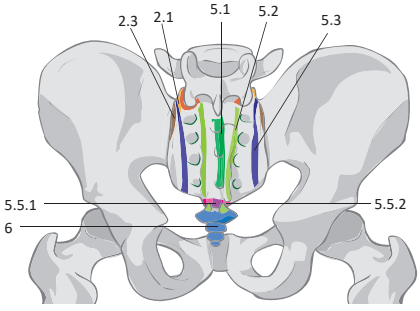

Posterior view of the pelvis

The intercostal spaces (*spatia intercostalia*) are filled with intercostal muscles. The intercostal neurovascular bundle courses along the lower border of the rib – see Page 549.

A thoracocentesis (also known as a pleural tap) is performed above the upper edge of a rib in order to prevent injury of intercostal vessels and nerves running in the costal groove.

The ribs are lifted up during **inspiration**, which expands the intrathoracic volume. During **expiration,** the ribs are lowered and the intrathoracic volume is reduced.

Clinical notes

Coccygeal syndrome is caused by shortening of the muscles that insert on the coccyx. These muscles are the levator ani and the ischiococcygeus. This leads to a variety of symptoms that develop in various other parts of body such premenstrual pain, headache, neck pain and pain during walk.

A sternal puncture is peformed by sticking a needle into the bone marrow cavity of the sternum. It is typically used for the diagnosis of haematological disorders.

Single rib fractures may be very painful but usually do not require treatment. **Multiple rib fractures** lead to a condition called flail chest, which is characterised by paradoxical breathing. In **paradoxical breathing**, the fracture fragments move in the opposite direction to the normal movements of the chest. Multiple rib fractures require intensive treatment.

Cervical ribs are an anatomical abnormality occurring unilaterally or bilaterally on vertebra C7. Although cervical ribs are usually asymptomatic, they may encroach on the surrounding structures. Compression of the brachial plexus and subclavian artery is a cause of **thoracic outlet syndrome**, which is characterised by sensory disturbances in the ipsilateral arm.

The thorax consists of **the sternum** and **twelve pairs of ribs.** The first seven pairs of ribs are the **true ribs**, attached by cartilage directly to the sternum. The 8th to 10th ribs are called **false ribs** and they are connected by cartilage to the ribs directly above them. The 11th and 12th ribs are **floating ribs** with sharp ventral ends that terminate freely between the abdominal muscles. In general, the ribs belong to the flat bones.

Rib *(costa)*

- 1 **Head** *(caput costae)* – articulates with the vertebral body
  - 1.1 **Articular facet** *(facies articularis capitis costae)*
    – articulates with the costal facets on the thoracic vertebral bodies
  - 1.2 **Crest** *(crista capitis costae)*
    – divides the articular facet into an upper and lower facet
    – not present on the 1st and 10th–12th ribs
- 2 **Neck** *(collum costae)*
- 3 **Body** *(corpus costae)* – the shaft of the rib
- 4 **Tubercle** *(tuberculum costae)* – is located behind the neck and points dorsally
  - 4.1 **Articular facet of tubercle** *(facies articularis tuberculi costae)*
    – articulates with the transverse process of the vertebra
    – is not present on the 11th and 12th rib
- 5 **Angle** *(angulus costae)* – a curvature of a rib in its dorsal third or quarter
- 6 **Costal groove** *(sulcus costae)*
  – a groove on the caudal margin of the dorsal surface of a rib
  – transmits the intercostal vein, intercostal artery and intercostal nerve (in this cranio-caudal order)
- 7 **Crest** *(crista costae)* – covers the costal groove from the ventral side
- 8 **Costal cartilage** *(cartilago costalis)* – a cartilaginous extension on the ventral end of the ribs
  – the costal cartilage of the true ribs articulates with the sternum
  – the costal cartilages of the false ribs articulates with the next rib above
  – is not present in floating ribs

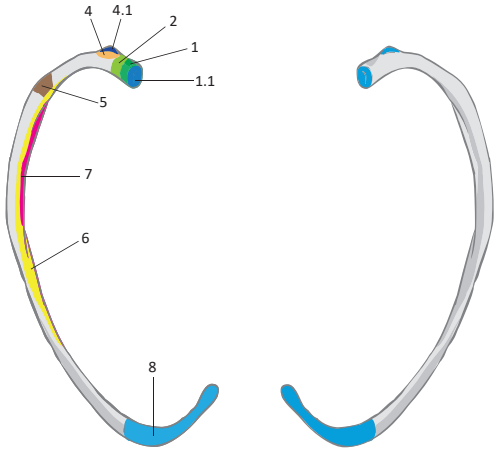

Superior view of a rib

First and second rib *(costa prima et secunda)* – unique features

1 **First rib** *(costa prima)* – is short and flat
– the costal cartilage usually ossifies, transforming the sternocostal synchondrosis into a synostosis
- 1.1 **Scalene tubercle** *(tuberculum musculi scaleni anterioris)*
  – the insertion of the scalenus anterior
- 1.2 **Groove for subclavian artery** *(sulcus arteriae subclaviae)*
  – is located behind the scalene tubercle
- 1.3 **Groove for subclavian vein** *(sulcus venae subclaviae)*
  – is located in front of the scalene tubercle

2 **Second rib** *(costa secunda)*
- 2.1 **Tuberosity for serratus anterior** *(tuberositas musculi serrati anterioris)*
  – the origin of one of the digitations of the serratus anterior

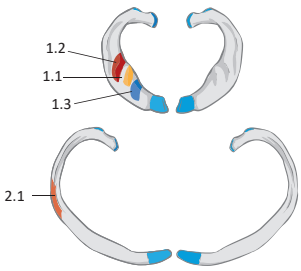

Superior view of the first and second ribs

Sternum – breast bone

- 1 **Manubrium of sternum** *(manubrium sterni)* – the cranial part of the sternum
  – the origin of the sternohyoid, sternothyroid and the sternal part of the sternocleidomastoid
  - 1.1 **Jugular notch** *(incisura jugularis)*
    – forms a skin depression above the sternum called the jugular fossa
  - 1.2 **Clavicular notch** *(incisura clavicularis)* – articulates with the clavicle
  - 1.3 **Costal notch** *(Incisura costalis)* – articulates with the 1st rib
- 2 **Sternal angle of Louis** *(angulus sternalis Ludovici)* – an obtuse angle between the manubrium and body of the sternum at the level of the 2nd rib
- 3 **Body of sternum** *(corpus sterni)*
  - 3.1 **Costal notches** *(incisurae costales)* – articulate with the 3rd–7th rib
- 4 **Xiphoid process** *(processus xiphoideus)* – a process of variable length and shape
  – can be bifurcated and may be partially or fully composed of cartilage

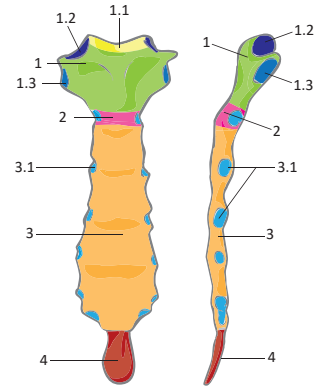

Anterior and lateral view of the sternum

Thorax – chest

- 1 **Thoracic cage** *(cavitas thoracis)* – is bordered by the ribs, sternum and thoracic vertebral column
- 2 **Superior thoracic aperture** *(apertura thoracis superior)* – the thoracic inlet
- 3 **Inferior thoracic aperture** *(apertura thoracis inferior)* – the thoracic outlet
- 4 **Right and left costal margin** *(arcus costalis dexter et sinister)* – the costal arches

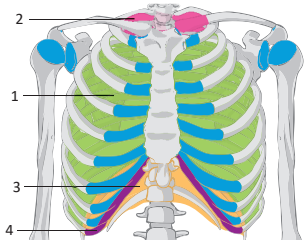

This copy belongs to ali yaghoubi

The bones of the upper limb are divided into two groups: the **shoulder girdle** and the **free part of the upper limb.**

1 **Pectoral girdle** *(cingulum pectorale)* – shoulder girdle
- 1.1 **Clavicle** *(clavicula)* – collar bone
- 1.2 **Scapula** – shoulder blade

2 **Free part of upper limb**
(pars libera membri superioris)
- 2.1 **Humerus**
- 2.2 **Ulna** – elbow bone
- 2.3 **Radius** – radial bone
- 2.4 **Bones of hand** *(ossa manus)*
  - 2.4.1 **Carpal bones** *(ossa carpi)* – wrist bones
  - 2.4.2 **Metacarpals** *(ossa metacarpi)* – bones of the palm
  - 2.4.3 **Phalanges** – bones of the fingers

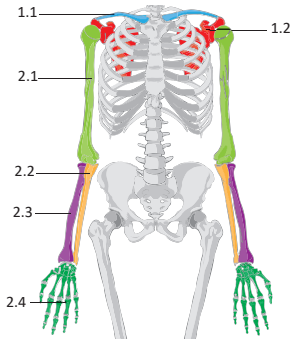

5.1 **Clavicle** – Clavicula

The clavicle is a **S-shaped** bone with a medial convexity pointing ventrally. It **articulates with the scapula and the sternum** and is part of the **pectoral girdle**. It is the first bone to ossifiy, which it does by both **intramembranous** and **endochondral ossification.**

- 1 **Sternal end** *(extremitas sternalis)*
  – the attachment of the anterior and posterior sternoclavicular ligaments and the interclavicular ligament
  – the origin of the sternohyoid and clavicular part of the sternocleidomastoid
  - 1.1 **Sternal facet** *(facies articularis sternalis)*
    – articulates with the manubrium of the sternum
  - 1.2 **Impression for costoclavicular ligament** *(impressio ligamenti costoclavicularis)*
    – the attachment of the costoclavicular ligament, which connects the clavicle to the cartilage of the 1st rib
- 2 **Body of clavicle** (*corpus claviculae)* – the shaft of the clavicle
  – the origin of the clavicular part of pectoralis major
  - 2.1 **Subclavian groove** *(sulcus musculi subclavii)*
    – a shallow groove on the caudal surface of the shaft for the insertion of the subclavius
- 3 **Acromial end** *(extremitas acromialis)*– the origin of the clavicular part of the deltoid and the insertion of the descending part of the trapezius
  - 3.1 **Acromial facet** *(facies articularis acromialis)* – articulates with the acromion
  - 3.2 **Coracoclavicular tuberosity** – a large bony protuberance
    – has two parts: the conoid tubercle and trapezoid line
    - 3.2.1 **Conoid tubercle** *(tuberculum conoideum)*
      – the attachment the conoid ligament
    - 3.2.2 **Trapezoid line** *(linea trapezoidea)*
      – the attachement of the trapezoid ligament
      – the conoid ligament and trapezoid ligament form the coracoclavicular ligament

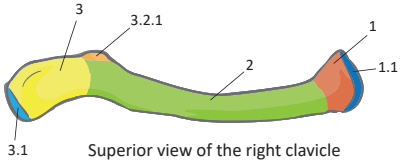

Superior view of the right clavicle

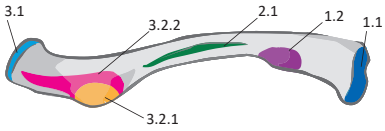

Inferior view of the right clavicle

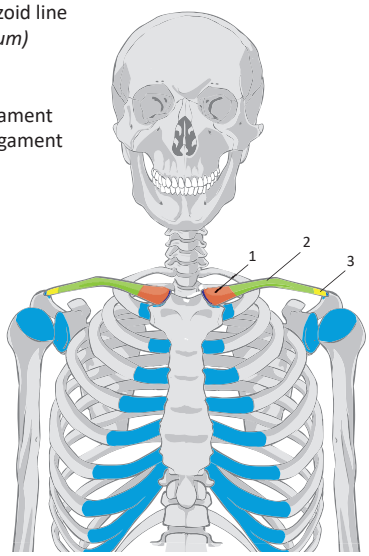

The axis of the glenoid cavity projects 9° dorsally from the axis of the scapula. It is thus in **retroversion** with respect to the scapula.

The acromion is an anthropometric point. Its lateral edge can be used for measuring the shoulder-to-shoulder width and the length of the upper limb.

The scapula is connected by muscles to the posterior aspect of the thorax. Its position and associated muscles influence the posture of the head, cervical vertebrae and shoulders. Contrarily, the position of the scapula is significantly influenced by muscular imbalance of the upper and lower scapular fixators and the serratus anterior.

Upper scapular fixators:
1 descending part of the trapezius
2 Levator scapulae
3 Sternocleidomastoid
4 Scaleni

Lower scapular fixators:
1 transverse and ascending part of the trapezius
2 Rhomboids
3 Infraspinatus

Orientation of the clavicle: the sternal end is thicker and the acromial end is flat. The superior surface is smooth. The inferior surface is decorated by bony markings. The medial two thirds have a ventral convexity.

Clinical notes

Fractures of the clavicle are commonly associated with fragment dislocation. The medial part of the clavicle tends to be pulled cranially by the sternocleidomastoid. The lateral part of the clavicle can become caudally displaced by the coracoclavicular ligament.

Clavicular injuries are sometimes associated with injury of the subclavian artery and/or brachial plexus.

Fractures of the scapula occur very rarely and are almost always a consequence of direct violence or a fall.

The superior angle of the scapula is a common area of tenderness found by palpation in a physical examination. This pain can be caused by overuse of the levator scapulae.

A winged scapula is an out of place scapula. In **medial winging,** the scapula moves upward and medially. This can be caused by weakening of the lower fixators or injury to the long thoracic nerve. In **lateral winging,** the scapula moves downwards and laterally. This can be caused by damage to the accessory nerve.

The scapula is a **flat triangular** bone that connects to the posterior aspect of the thorax by muscles **at the level of the 2nd to 7th rib**. It is part of **the pectoral girdle** and features a **large dorsal spine**, which ends laterally as **the acromion.**

1 **Surfaces:**
- 1.1 **Costal/anterior surface** *(facies costalis/anterior)* – the ventral surface facing the chest
- 1.2 **Posterior surface** *(facies posterior)* – is palpable on the skin over the back

2 **Borders:**
- 2.1 **Medial border** *(margo medialis)*
  - the insertion of the rhomboids and serratus anterior
- 2.2 **Lateral border** *(margo lateralis)*
  - the origin of teres major and teres minor
- 2.3 **Superior border** *(margo superior)*
  - the origin of the inferior belly of the omohyoid

3 **Angles:**
- 3.1 **Inferior angle** *(angulus inferior)* – the origin of the teres major
- 3.2 **Superior angle** *(angulus superior)* – the insertion of the levator scapulae
- 3.3 **Lateral angle** *(angulus lateralis)*

4 **Subdivisions of the costal surface:**
- 4.1 **Subscapular fossa** *(fossa subscapularis)*
  - the origin of the subscapularis

5 **Subdivisions of the posterior surface:**
- 5.1 **Spine of scapula** *(spina scapulae)*
  - the origin of the spinal part of the deltoid muscle
  - the insertion of the transverse and ascending parts of the trapezius
  - 5.1.1 **Deltoid tubercle** *(tuberculum deltoideum)*
    - is located between the insertion of the trapezius and the origin of the deltoid muscle
- 5.2 **Acromion** – the lateral extension of the spine of the scapula
  - the origin of the acromial part of the deltoid muscle
  - the insertion of the descending part of the trapezius
  - the attachment of the coraco-acromial ligament *(fornix humeri)* and the acromioclavicular ligament
  - 5.2.1 **Clavicular facet** *(facies articularis clavicularis)*
    - articulates with the clavicle
- 5.3 **Supraspinous fossa** *(fossa supraspinata)* – the origin of the supraspinatus
- 5.4 **Infraspinous fossa** *(fossa infraspinata)* – the origin of the infraspinatus

Other parts of the scapula:
- 6 **Glenoid cavity** *(cavitas glenoidalis)*
  - the articular fossa of the shoulder joint
  - is enlarged by a cartilaginous glenoid labrum
  - 6.1 **Supraglenoid tubercle** *(tuberculum supraglenoidale)*
    - is located just above the glenoid cavity
    - the origin of the long head of the biceps brachii
  - 6.2 **Infraglenoid tubercle** *(tuberculum infraglenoidale)*
    - located just below the glenoid cavity
    - the origin of the long head of the triceps brachii
- 7 **Neck of scapula** *(collum scapulae)*
  - a narrowed area between the glenoid cavity and the rest of the scapula
  - the attachment of the articular capsule of the shoulder joint
- 8 **Coracoid process** *(processus coracoideus)*
  - the origin of the coracobrachialis and the short head of the biceps brachii
  - the insertion of the pectoralis minor
  - the attachment of the coraco-acromial ligament, coracoclavicular ligament and coracohumeral ligament
- 9 **Suprascapular notch** *(incisura scapulae)*
  - a notch on the superior border of the scapula next to the coracoid process
  - covered by the superior transverse scapular ligament
  - the suprascapular nerve runs through the notch under the ligament
  - the suprascapular artery and vein pass over the ligament
- 10 **Spinoglenoid notch** *(incisura spinoglenoidalis)*
  - a notch between the glenoid cavity and the spine of the scapula
  - covered by the inferior transverse scapular ligament
  - transmits the suprascapular nerve and vessels

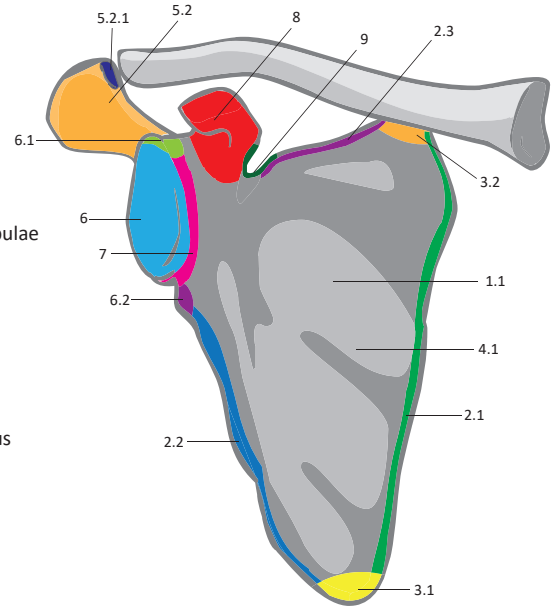

Anterior view of the right scapula

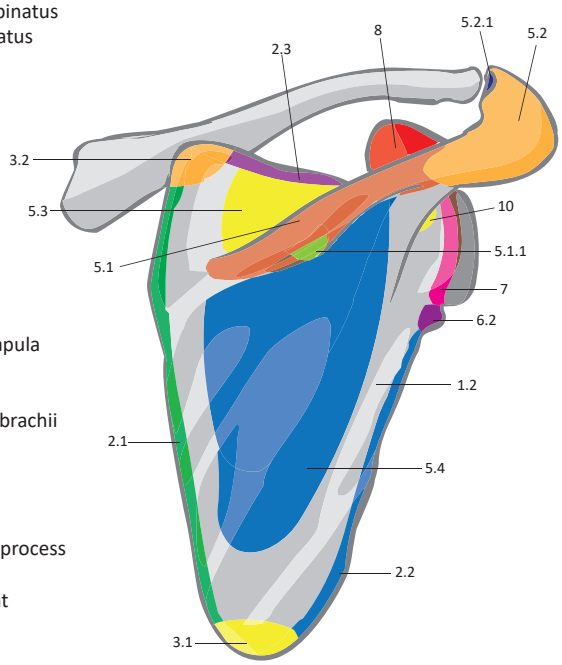

Posterior view of the right scapula

This copy belongs to ali yaghoubi

The humerus is a long bone of the free upper limb. It is divided into a head, a shaft and a condyle. **The head of the humerus** is a component of the shoulder joint. Two projections, the greater and lesser tubercle, are located on the head and serve as insertion sites for the rotator cuff muscles. **The radial nerve and the deep brachial artery** run around **the shaft of the humerus** in a groove on the posterior surface called the **radial groove**. The distal end of the humerus is called **the condyle of the humerus.** It is a component of the elbow joint. It posses **a medial and lateral epicondyle**, which serve as origin sites for the muscles of the forearm.

- 1 **Head** *(caput humeri)* – the articular head of the shoulder joint
  - 1.1 **Anatomical neck** *(collum anatomicum)*
    – the attachment of the articular capsule of the shoulder joint
  - 1.2 **Greater tubercle** *(tuberculum majus)*
    – projects dorslaterally from the head
    – the insertion of the supraspinatus, infraspinatus and teres minor
    – the attachment of the coracohumeral ligament and transverse humeral ligament
    - 1.2.1 **Crest of greater tubercle** *(crista tuberculi majoris)*
      – the insertion of the pectoralis major
  - 1.3 **Lesser tubercle** *(tuberculum minus)*
    – projects ventromedially from the head
    – the insertion of the subscapularis
    – the attachment of the glenohumeral ligaments and transverse humeral ligament
    - 1.3.1 **Crest of lesser tubercle** *(crista tuberculi minoris)*
      – the insertion of the teres major and latissimus dorsi
  - 1.4 **Intertubercular sulcus** *(sulcus intertubercularis)*
    – the bicipital groove
    – a groove between the greater and lesser tubercles
    – the long head of the biceps runs through it in a tendinous sheath
- 2 **Surgical neck** *(collum chirurgicum)*
  – a narrow part of the humerus located below the head
- 3 **Shaft of humerus** *(corpus humeri)*
  – the body of the humerus
  - 3.1 **Deltoid tuberosity** *(tuberositas deltoidea)*
    – the insertion of the deltoid muscle
  - 3.2 **Radial groove** *(sulcus nervi radialis)*
    – an oblique groove for the radial nerve and the deep brachial vessels
    – is located on the posterior surface of the shaft
    – is bordered by the medial and lateral heads of the triceps brachii, which form the radial canal
  - 3.3 **Nutrient foramen** *(foramen nutricium)*
    – the entrance of vessels into the medullary cavity
    – points distally

  Surfaces:
  - 3.4 **Anteromedial surface** *(facies anteromedialis)*
  - 3.5 **Anterolateral surface** *(facies anterolateralis)*
  - 3.6 **Posterior surface** *(facies posterior)*

  Margins:
  - 3.7 **Medial border** *(margo medialis)*
  - 3.8 **Lateral border** *(margo lateralis)*
- 4 **Condyle of humerus** *(condylus humeri)*
  – the widened distal end of the humerus

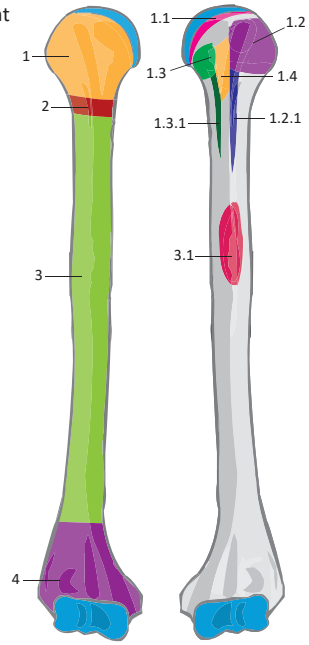

Anterior view of the left and right humerus

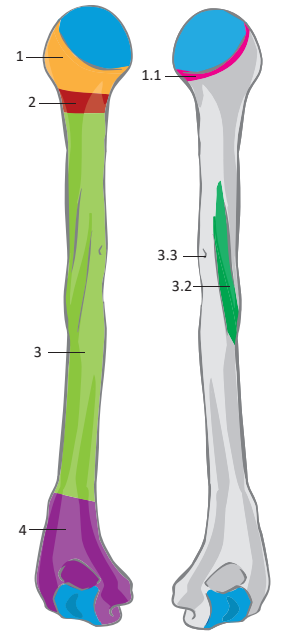

Posterior view of the left and right humerus

The angle of inclination of the humerus is the angle between the head and body and is about 130°.

In children, the **proximal epiphyseal cartilage** contributes to 80 % of the growth of the humerus.

The ulnar nerve is located superficially as it runs through the groove for the ulnar nerve. Hitting the ulnar nerve at this point causes a tingling feeling spreading down the arm, hence the colloquial term for this region: ''the funny bone''.

Clinical notes

Fractures of the distal humerus can cause injury to the ulnar nerve.

The surgical neck of the humerus is an area of frequent fractures in adults. Injury to the anterior and posterior circumflex arteries can occur causing ischaemia and necrosis of the head of the humerus.

Injuries of the diaphysis of the humerus can damage the radial nerve and deep brachial artery, which are located in the groove for the radial nerve.

The muscles of the rotator cuff are inserted on the greater and lesser tubercles. They are responsible for the stability of the shoulder joint. During shoulder joint replacement operations these muscles and their insertions must be preserved.

Pain over the greater tubercle occurs when excessive internal rotation ruptures the rotator cuff muscles. **Pain over the lesser tubercle** can be caused by an overuse injury of internal rotation.

The osseous plate between the olecranon fossa and coronoid fossa may contain a hole called the **supratrochlear foramen**. This can cause hypermobility of the elbow joint, capable of hyperextension.

"Golfer's elbow" is an overuse injury of the flexor group of muscles that attach to the medial epicondyle. The symptoms are precipitated by striking a golf club on the ground, which stretches the flexor origin on the medial epicondyle and causes pain located in this region.

"Tennis elbow" is an overuse injury of the common extensor tendon attachment on the lateral epicondyle. It is typically caused by backhand strokes in tennis and working on computers for long periods of time. It is characterised by pain over the lateral epicondyle of the humerus.

4 **Condyle of the humerus** *(condylus humeri)* – the widened distal end of the humerus
- 4.1 **Medial supraepicondylar ridge** *(crista supraepicondylaris medialis)*
  – the origin of the humeral head of the pronator teres
- 4.2 **Lateral supraepicondylar ridge** *(crista supraepicondylaris lateralis)*
  – the origin of the brachioradialis and extensor carpi radialis longus
- 4.3 **Medial epicondyle** *(epicondylus medialis)*
  – the common origin of the flexor muscles of the hand
  - 4.3.1 **Groove for ulnar nerve** *(sulcus nervi ulnaris)*
- 4.4 **Lateral epicondyle** *(epicondylus lateralis)*
  – the origin of the common extensor tendon and the anconeus
- 4.5 **Capitulum** *(capitulum humeri)*
  – the articular head of the humeroradial joint
- 4.6 **Trochlea** *(trochlea humeri)*
  – the articular head of the humeroulnar joint
- 4.7 **Olecranon fossa** *(fossa olecrani)*
  – is located dorsally on the condyle of the humerus
  – contains the olecranon of the ulna when the forearm is extended
- 4.8 **Coronoid fossa** *(fossa coronoidea)*
  – is located ventromedially on the condyle of the humerus
  – contains the coronoid process of the ulna when the forearm is flexed
- 4.9 **Radial fossa** *(fossa radialis)*
  – is located ventrolaterally on the condyle of the humerus
  – contains the head of the radius when the forearm is flexed

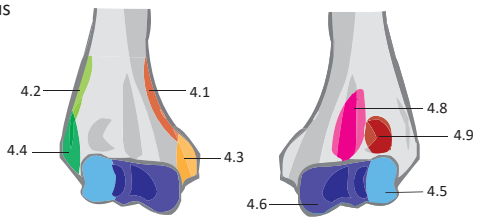

Anterior view of the distal end of the right and left humerus

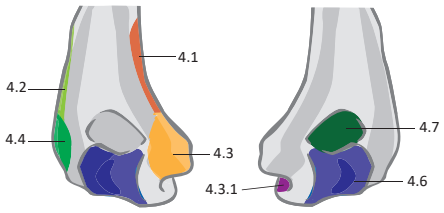

Posterior view of the distal end of the right and left humerus

5.4 **Ulna** – Ulna

The ulna is a long bone located on the **medial aspect of the forearm**. It acts as a **rotary axis for the radius** during pronation and supination of the forearm.

- 1 **Proximal end** – is widened
  - 1.1 **Olecranon** – the insertion of triceps brachii and the attachment of the olecranohumeral and oblique ligaments
  - 1.2 **Coronoid process** *(processus coronoideus ulnae)*
    – the ventral border of the trochlear notch
    – the attachment of the humerocoronoid and oblique ligaments
  - 1.3 **Tuberosity of ulna** *(tuberositas ulnae)*
    – the insertion of the brachialis
  - 1.4 **Radial notch** *(incisura radialis)*
    – the articular fossa for the head of the radius
  - 1.5 **Trochlear notch** *(incisura trochlearis)*
    – the articular cavity for the trochlea of the humerus
  - 1.6 **Supinator crest** *(crista musculi supinatoris)*
    – the origin of the supinator muscle
- 2 **Shaft** *(corpus ulnae)* – the body of the ulna
  - 2.1 **Nutrient foramen** *(foramen nutricium)*
    – the entrance of vessels into the medullary cavity
    – points proximally

  Surfaces:
  - 2.2 **Anterior surface** *(facies anterior)*
  - 2.3 **Posterior surface** *(facies posterior)*
  - 2.4 **Medial surface** *(facies medialis)*

  Borders:
  - 2.5 **Interosseous border** *(margo interosseus)*
    – the attachment of the interosseous membrane of the forearm
  - 2.6 **Anterior border** *(margo anterior)*
  - 2.7 **Posterior border** *(margo posterior)* – is palpable in its entire course
- 3 **Head** *(caput ulnae)* – the distal narrow end
  - 3.1 **Articular circumference** *(circumferentia articularis)* – the annular articular facet around the head
    – an articular surface in the distal radio-ulnar joint
  - 3.2 **Ulnar styloid process** *(processus styloideus ulnae)* – a palpable projection on the dorsal side of the distal forearm
    – the attachment of the palmar ulnocarpal ligament and ulnar collateral ligament of the wrist joint

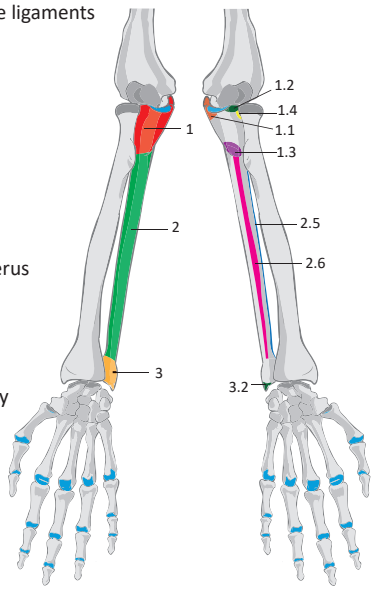

Anterior view of the right and left ulna situated in the forearm

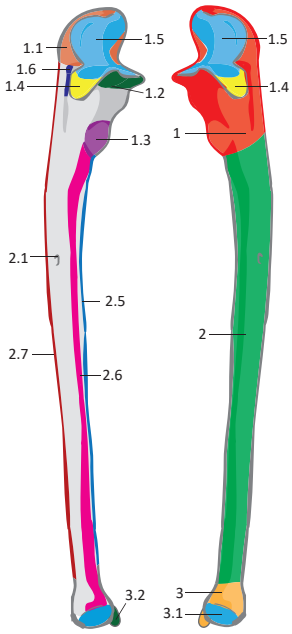

Anteriolateral view of the right and left ulna

This copy belongs to ali yaghoubi

The radius is a long bone located on the **lateral aspect of the forearm**. During pronation and supination, the radius rotates around the ulna.

- 1 **Head of radius** *(caput radii)* – is located on the proximal end of the bone
  - 1.1 **Articular facet** *(fovea articularis)* – the articular fossa for the capitulum of the humerus
  - 1.2 **Articular circumference** *(circumferentia articularis)*
    - an annular articular facet around the head of the humerus
    - the articular head of the proximal radio-ulnar joint
- 2 **Neck** *(collum radii)* – the attachment of the articular capsule
- 3 **Shaft** *(corpus radii)* – the body of the radius
  - 3.1 **Radial tuberosity** *(tuberositas radii)* – a tuberosity on the proximal part of the radius
    - the insertion of the biceps brachii
  - 3.2 **Pronator tuberosity** *(tuberositas pronatoria radii)*
    - a tuberosity in the middle of the radial shaft
    - the insertion of the pronator teres
  - 3.3 **Nutrient foramen** *(foramen nutricium)*
    - the entrance of vessels into the medullary cavity, points proximally

  Surfaces:
  - 3.4 **Anterior surface** *(facies anterior)*
  - 3.5 **Posterior surface** *(facies posterior)*
  - 3.6 **Lateral surface** *(facies lateralis)*

  Borders:
  - 3.7 **Interosseous border** *(margo interosseus)*
    - the attachment of the interosseous membrane of the forearm and the oblique cord
  - 3.8 **Anterior border** *(margo anterior)*
  - 3.9 **Posterior border** *(margo posterior)*
- 4 **Distal end** – is widened
  - 4.1 **Radial styloid process** *(processus styloideus radii)*
    - a palpable projection on the dorsal side of the distal forearm
    - the attachment of the palmar radiocarpal ligament
    - the attachment of the radial collateral ligament of the wrist joint
  - 4.2 **Suprastyloid crest** *(crista suprastyloidea)* – the insertion of the brachioradialis
  - 4.3 **Grooves for tendons of extensors** *(sulci tendinum musculorum extensorum)*
    - grooves for the tendons of the extensor muscles: extensor pollicis longus, extensor carpi radialis longus, extensor carpi radialis brevis, extensor digitorum and extensor indicis
  - 4.4 **Dorsal tubercle of Lister** *(tuberculum dorsale)*
    - the attachment of the dorsal radiocarpal ligament
    - the most prominent tubercle between the grooves for the extensor tendons
  - 4.5 **Ulnar notch** *(incisura ulnaris)* – the articular fossa of the distal radio-ulnar joint
  - 4.6 **Carpal articular surface** *(facies articularis carpalis)*
    - the articular fossa for articulation with the scaphoid and lunate

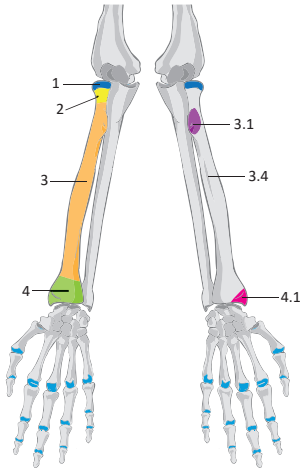

Anterior view of the right and left ulna situated in the forearm

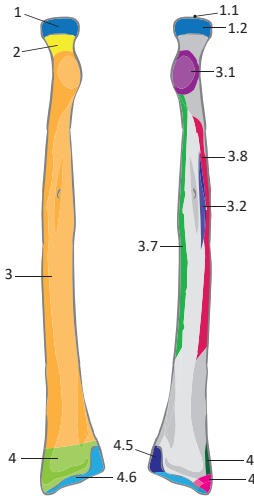

Anterior view of the right and left radius

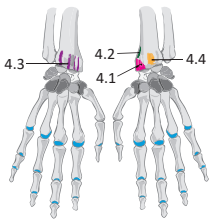

Posterior view of the distal part of the right and left radius

In children, the distal epiphyseal cartilage contributes to 75–80 % of forearm growth.

Ossification of the carpal bones proceeds in a circle starting with the capitate. It serves as an X-ray marker of bone age.

The obsolete term "navicular bone of the hand" is often used in clinical practice for the scaphoid bone.

The pisiform *(os pisiforme)* develops as a sesamoid bone enclosed in the tendon of the flexor carpi ulnaris *(musculus flexor carpi ulnaris).*

The greater and lesser multangular bones *(os multangulum majus et minus*) are obsolete terms for the trapezium and trapezoid *(os trapezium et trapezoideum)* respectively.

Clinical notes

Pain around the head of the radius develops in overuse of supination.

The radial styloid process *(processus styloideus radii)* becomes painful after excessive forearm flexion and in overuse of flexion of the digits when the forearm is in a position halfway between supination and pronation.

Colles' fracture is an extra-articular fracture of the distal radius with dorsal dislocation of the fragments. It is caused by falling on an extended wrist. It is the most common type of fracture.

Smith's fracture is an extra-articular fracture of the distal radius with ventral dislocation of the fragments. It is caused by falling on a flexed wrist.

Fractures of the scaphoid are the most common fractures of the carpal bones. They are characterised by pain over the anatomical snuff box.

The blood supply of the scaphoid enters its distal end. Fractures of the scaphoid neck can lead to impairment of the blood supply of the proximal fragment. This causes avascular necrosis.

The most common type of injury to the lunate is dislocation.

The bones of the hand consist of **8 carpal bones, 5 metacarpals and 14 phalanges**. The carpal bones are short bones arranged in **two transverse rows**. The metacarpals and phalanges are long monoepiphyseal bones arranged in 5 longitudinal lines, corresponding to the 5 fingers.

Carpal bones *(ossa carpi)* – wrist bones

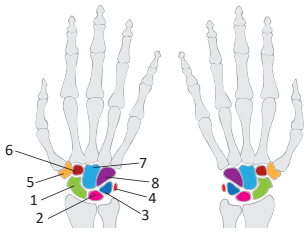

Anterior view of the bones of the left and right hand

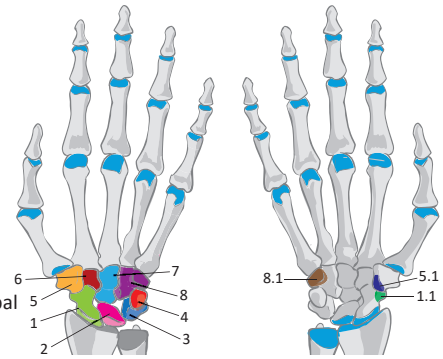

Anterior view of the bones of the left and right hand

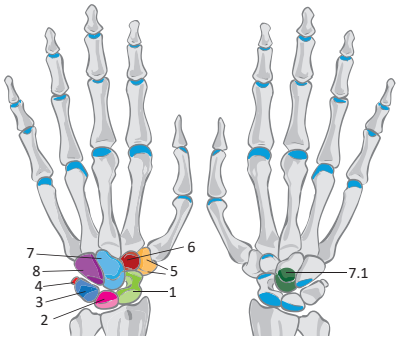

Posterior view of the bones of the left and right hand

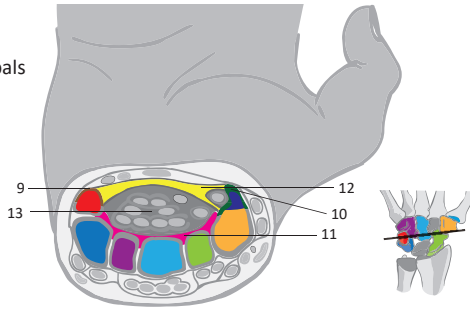

Proximal view of a cross section through the right wrist

Proximal row:

- 1 **Scaphoid** *(os scaphoideum)* – has a facet on its proximal surface for articulation with the radius
  - has a facet on its distal surface for articulation with the trapezium
  - has a semilunar-shaped facet on its medial surface for articulation with the lunate
  - forms an articular fossa with the lunate that articulates with the head of the capitate
  - 1.1 **Tubercle** (tuberculum ossis scaphoidei) – contributes to the radial carpal eminence
- 2 **Lunate** *(os lunatum)* – has a facet on its proximal surface for articulation with the radius
  - has a concave fossa on its distal surface for articulation with the capitate
  - has a semilunar facet on its distal surface for articulartion with the scaphoid
  - has a quadrate facet on its medial surface for articulation with the triquetrum
- 3 **Triquetrum** *(os triquetrum)* – has an oval-shaped facet on its distal surface for articulation with the pisiform
  - has a quadrate-shaped facet on its lateral surface for articulation with the lunate
  - has a facet on its distal surface for articulation with the hamate
- 4 **Pisiform** *(os pisiforme)* – forms part of the ulnar carpal eminence
  - is attached to the triquetrum
  - the origin of the abductor digiti minim and the insertion of the flexor carpi ulnaris
  - the attachment of the pisohamate and pisometacarpal ligaments

Distal row:

- 5 **Trapezium** *(os trapezium)*
  - has a saddle-shaped facet on its distal surface for articulation with the 1st metacarpal
  - has a small facet for articulation with the 2nd metacarpal
  - the facets on its medioproximal surface articualte with the scaphoid and trapezoid
  - has a groove on its ventral surface for the tendon of the flexor carpi radialis
  - 5.1 **Tubercle** *(tuberculum ossis trapezii)* – contributes to the radial carpal eminence
- 6 **Trapezoid** *(os trapezoideum)*
  - has a facet on its proximal surface for articulation with the scaphoid
  - has a roof-shaped facet on its distal surface for articulation with the 2nd metacarpal
  - has a facet on its lateral surface for articulation with the trapezium
  - has a facet on its medial surface for articulation with the capitate
- 7 **Capitate** *(os capitatum)*
  - has a facet on its proximal surface for articulation with the scaphoid and lunate
  - has a facet on its lateral surface for articulation with the trapezoid
  - has a facet on its medial surface for articulation with the hamate
  - has a facet on its distal surface for articulation with the 3rd metacarpal
  - 7.1 **Head of capitate** *(caput ossis capitati)* – the centre of the wrist
    - the attachment of the radiate carpal ligament
    - articulates with a articular fossa formed by the scaphoid and lunate
- 8 **Hamate** *(os hamatum)*
  - has a facet on its lateral surface for articulation with the capitate
  - has a facet on its medioproxima surface for articulation with the triquetrum
  - has two facets on its distal surface for articulation with the 4th and 5th metacarpals
  - 8.1 **Hook of hamate** *(hamulus ossis hamati)*
    - part of the ulnar carpal eminence
    - the attachment of the pisohamate ligament
    - the origin of the flexor digiti minimi and opponens digiti minimi

Wrist *(carpus)*

- 9 **Ulnar carpal eminence** *(eminentia carpi ulnaris)*
  - the medial border of the carpal groove
  - is composed of the pisiform and the hook of the hamate
  - the origin of the hypothenar muscles
- 10 **Radial carpal eminence** *(eminentia carpi radialis)* – the lateral border of the carpal groove
  - is composed of the scaphoid tubercle and the tubercle of the trapezium
  - the origin of the thenar muscles
- 11 **Carpal groove** *(sulcus carpi)* – a deep concave groove formed by the carpal bones for the tendons of the flexor muscles of the hand
- 12 **Flexor retinaculum** *(retinaculum musculorum flexorum)* – covers the carpal groove, stretched between the carpal eminences
- 13 **Carpal tunnel** *(canalis carpi)* – a space between the two carpal eminences, the carpal groove and the flexor retinaculum

This copy belongs to ali yaghoubi

Each **metacarpal** possesses only one growth cartilage, which is located in the distal end of the bone. The metacarpals are thus known as **monoepiphyseal bones**. The growth cartilages are located in the distal part of the bone, with the exception of the 1st metacarpal, which has its growth cartilage in the proximal part. **The thumb** has a **proximal and distal phalanx**. **The other digits** have three phalanges: **a proximal, medial and distal phalanx.**

Metacarpals *(ossa metacarpi)*

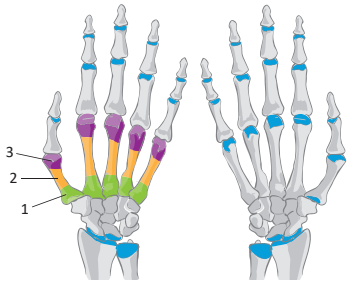

General organization

- 1 **Base** *(basis ossis metacarpi)*
- 2 **Shaft** *(corpus ossis metacarpi)*
- 3 **Head** *(caput ossis metacarpi)*

I **1st metacarpal** *(os metacarpi primum)*
– has a saddle-shaped facet on its base for articulation with the trapezium

II **2nd metacarpal** *(os metacarpi secundum)*
– the longest metacarpal
– has a roof-shaped facet on its base for articulation with trapezoid
– has a figure of eight shaped facet on its medial surface for articulation with the 3rd metacarpal

III **3rd metacarpal** *(os metacarpi tertium)* – has a facet on its base for articulation with the capitate
– has a figure of eight-shaped facet on its lateral surface for articulation with the 2nd metacarpal
– has two facets on its medial surface for articulation with the 4th metacarpal

IV **4th metacarpal** *(os metacarpi quartum)*
– has a facet on its base for articulation with the hamate
– has two facets on its lateral surface for articulation with the 3rd metacarpal
– has a facet on its medial surface for articulation with the 5th metacarpal

V **5th metacarpal** *(os metacarpi quintum)* – has a facet on the base for articulation with the hamate
– has a facet on its lateral surface for articulation with 4th metacarpal
– the tubercle of the 5th metacarpal is located on the medial aspect of the bone and is the insertion of the extensor carpi ulnaris and the attachment of the pisometacarpal ligament

Phalanges *(ossa digitorum)*

- 1 **Proximal phalanx** *(phalanx proximalis)*
  - 1.1 **Base** *(basis)* – has an oval-shaped articular fossa for articulation with the metacarpal
  - 1.2 **Shaft** *(corpus)* – body
  - 1.3 **Head** *(caput)* – is pulley-shaped
- 2 **Middle phalanx** *(phalanx media)*
  - 2.1 **Base** *(basis)* – has an articular fossa with a ridge
  - 2.2 **Shaft** *(corpus)* – body
  - 2.3 **Head** *(caput)* – is pulley-shaped
- 3 **Distal phalanx** *(phalanx distalis)*
  - 3.1 **Base** *(basis)* – has an articular fossa with a ridge
  - 3.2 **Shaft** *(corpus)* – body
  - 3.3 **Tuberosity of distal phalanx** *(tuberositas phalangis distalis)*

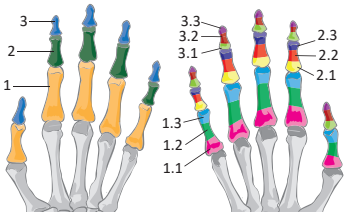

6 Bones of the lower limb – Ossa membri inferioris

The bones of the lower limb are divided into the **pelvic girdle** and **the free part of the lower limb.**

1 **Pelvic girdle** *(cingulum pelvicum)*
- 1.1 **Hip bone** *(os coxae)* – pelvic bone

2 **Free part of lower limb** *(pars libera membri inferioris)*
- 2.1 **Femur** – thigh bone
- 2.2 **Patella** – kneecap
- 2.3 **Tibia** – shinbone
- 2.4 **Fibula** – calf bone
- 2.5 **Bones of foot** *(ossa pedis)*
  - 2.5.1 **Tarsal bones** *(ossa tarsi)*
  - 2.5.2 **Metatarsals** *(ossa metatarsi)*
  - 2.5.3 **Phalanges** – bones of the toes

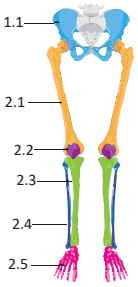

The axis of the hand passes through the third finger.

The sesamoid bones of the hand *(ossa sesamoidea manus)* are located in the tendons of the flexor pollicis brevis over the metacarpophalangeal joint.

The bones of the limbs develop from mesenchymal tissue in the limb buds. The bones of the upper limb begin to develop at the beginning of the 2nd month of intrauterine life, a few days before the bones of the lower limb start to develop.

During birth, the pelvic ligaments and joints become loosened by the effect of the hormone relaxin, which is produced in the corpus luteum and placenta. This allows the pubic symphysis to be mildly expanded and the coccyx to be dorsally displaced during delivery.

Sex differences of the pelvis:
The promontory sticks out less in women.
The pelvic inlet has a transverse oval shape in women and a heart-shape in men.
The wings of the ilium are more widely open in women.
The pubic symphysis is shorter in women.
The inferior pubic rami form an angle termed the pubic arch in women. In men, they form an acute angle called the pubic angle.
The sacrum is shorter and wider in women. The angle between the base and anterior surface is sharper and the size of the auricular surface is smaller.
The coccyx is shorter and more mobile in women.
The preauricular groove is present in women only.

The bispinal distance *(distantia bispinalis)* is an obsolete term for the interspinous distance.

Bicristal distance *(distantia bicristalis)* is an obsolete term for the intercristal distance.

Clinical notes

Traumatic pelvic fractures are complex injuries with many bone fragments. Injury of the pelvic organs and vascular plexuses leads to large blood loss (3–4 liters) and hypovolemic shock.

The pelvis consists of the **left and right hip bones** and **the sacrum.** The **linea terminalis** divides pelvis into the **greater pelvis**, which contains the small and large intestine, and **the lesser pelvis**, which contains the urinary bladder, the male and female internal genital organs and the rectum.

Bony pelvis

- 1 **Right hip bone** *(os coxae dextrum)*
- 2 **Left hip bone** *(os coxae sinistrum)*
- 3 **Sacrum**

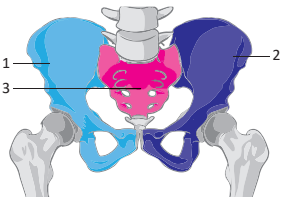

Anterior view of the pelvis

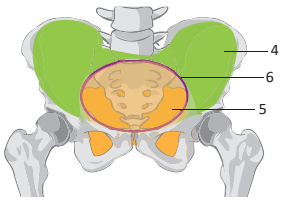

Anterior view of the pelvis

General organization

- 4 **Greater pelvis** *(pelvis major)*
- 5 **Lesser pelvis** *(pelvis minor)*
- 6 **Linea terminalis** – forms the pelvic inlet
  - – the borders of linea terminalis:
    - 6.1 **Promontory** *(promontorium)* – the dorsocranial border
    - 6.2 **Arcuate line** *(linea arcuata)* – the lateral border
    - 6.3 **Pecten pubis** *(pecten ossis pubis)* – the lateral border
    - 6.4 **Pubic symphysis** *(symphysis pubica)* – the ventrocaudal border

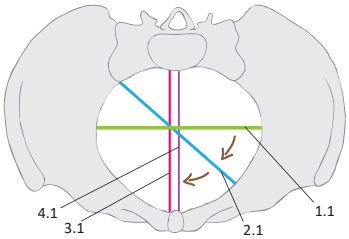

Internal pelvic diameters in planes

Pelvic planes and internal pelvic diameters

- 1 **Pelvic inlet** *(apertura pelvis superior, aditus pelvis)*
  - 1.1 **Transverse diameter** *(diameter transversa)* – 13 cm
    - – the longest diameter of the pelvic inlet
- 2 **Amplitudo pelvis** – the pelvic plane with the largest dimensions
  - – bordered by S2–S3, the the acetabulum and the pubic symphysis
  - 2.1 **Oblique diameter** *(diameter obliqua)* – 13.5 cm
    - – the longest diameter of amplitudo pelvis
- 3 **Angustia pelvis** – the pelvic plane with the smallest dimensions
  - – is bordered by the apex of the sacrum, the margin of the ischial spine and the caudal margin of the pubic symphysis
  - 3.1 **Median conjugate** *(conjugata mediana, diameter recta)* – 11 cm
    - – the distance between caudal margin of pubic symphysis and the sacrococcygeal symphysis
    - – the longest diameter of angustia pelvis
- 4 **Pelvic outlet** *(apertura pelvis inferior, exitus pelvis)* – consists of two planes
  - – is bordered by the caudal end of the coccyx, the ischial tuberosities and the caudal margin of the pubic symphysis
  - – is made up of two triangles: the urogenital triangle and the anal triangle
  - 4.1 **Straight diameter** *(diameter recta)* – 9.5 cm
    - – the distance between the caudal end of the coccyx and the caudal margin of the pubic symphysis
    - – during delivery the foetus pushes the coccyx dorsally, increasing this diameter to 11.5 cm

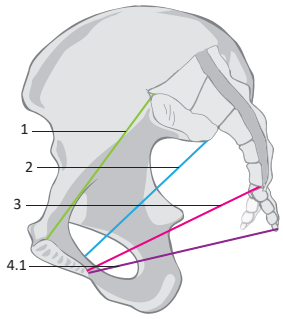

Sagittal section of the pelvis showing the pelvic diameters

Other internal diameters

- 5 **Diagonal conjugate** *(conjugata diagonalis)* – 12.5–13 cm
  - – the distance between the promontory and the caudal margin of the pubic symphysis
- 6 **True conjugate** *(conjugata vera, conjugata obstetrica)* – 10.5–11 cm
  - – the distance between promontory and retropubic eminence, which is the most dorsal point on the pubic symphysis
- 7 **Anatomical conjugate** *(conjugata anatomica, diameter recta aperturae pelvis superioris)* – 12 cm
  - – the distance between the promontory and the upper margin of pubic symphysis

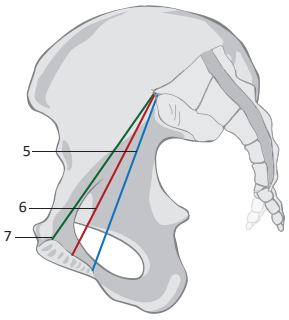

Internal pelvic diameters

External pelvic diameters

- 1 **Interspinous distance** *(distantia interspinosa)* – 25–26 cm
  - – the distance between both anterior superior iliac spines
- 2 **Intercristal distance** *(distantia intercristalis)* – 28–29 cm
  - – the distance between both iliac crests
- 3 **Intertrochanteric distance** *(distantia intertrochanterica)* – 31–32 cm
  - – the distance between both greater trochanters
- 4 **External conjugate of Baudelocque** *(conjugata externa, diameter)* – 18–20 cm
  - – the distance between the upper margin of pubic symphysis and the spinous process of L5

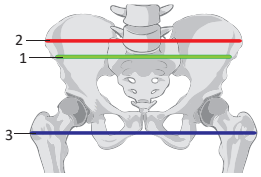

Anterior and posterior view of the pelvis

This copy belongs to ali yaghoubi

The hip bone consists of **3 fused bones: the ilium, ischium and pubis**. These three bones **articulate at the acetabulum** to form the articular cavity of the hip joint. **Two hip bones** together with the **sacrum** form the **bony pelvis.**

General organisation

- 1 **Ilium** *(os ilium)*
- 2 **Ischium** *(os ichii)*
- 3 **Pubis** *(os pubis)*

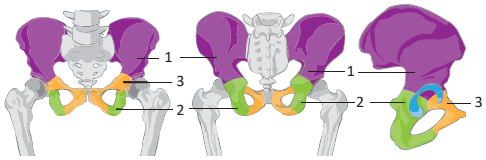

Anterior, posterior and lateral views of the pelvis

Ilium *(os ilium)*

- 1 **Body of ilium** *(corpus ossis ilii)* – the smaller caudal part of the ilium
  – forms the upper third of the acetabulum
  - 1.1 **Supra-acetabular groove** *(sulcus supraacetabularis)*
    – the origin of the reflected head of the rectus femoris
- 2 **Ala of ilium** *(ala ossis ilii)* – the wing of the ilium, the larger cranial part of the ilium

Components of the ala of the ilium:

- 3 **Iliac fossa** *(fossa iliaca)* – a ventromedial concave fossa, the origin of the iliacus
- 4 **Sacropelvic surface** *(facies sacropelvica)* – the medial surface behind and below the iliac fossa
  - 4.1 **Auricular surface** *(facies auricularis)* – articulates with the sacrum
  - 4.2 **Iliac tuberosity** *(tuberositas iliaca)*
    – the attachment of the posterior interosseous sacro-iliac ligament
- 5 **Gluteal surface** *(facies glutea)* – the dorsolateral surface, the origin of the gluteal muscles
  - 5.1 **Posterior gluteal line** *(linea glutea posterior)* – the border between origins of the gluteus maximus and medius
  - 5.2 **Anterior gluteal line** *(linea glutea anterior)*
    – the border between the origins of the gluteus medius and minimus
  - 5.3 **Inferior gluteal line** *(linea glutea inferior)*
    – the caudal borderline of the origin of the gluteus minimus
- 6 **Iliac crest** *(crista iliaca)* – has three lips (lines) for attachment of the abdominal wall muscles
  – **outer lip** *(labium externum)*: the origin of the latissimus dorsi and tensor fasciae latae, the insertion of the external oblique and the attachment of the fascia lata
  – **intermediate zone** *(linea intermedia)*: the origin of the internal oblique
  – **inner lip** *(labium internum)*: the origin of the transversus abdominis, the attachment of the thoracolumbar fascia and the insertion of the quadratus lumborum
  - 6.1 **Tuberculum of iliac crest** *(tuberculum iliacum)*
    – a bony projection formed by the origin of the gluteus medius
  - 6.2 **Anterior superior iliac spine** *(spina iliaca anterior superior)*
    – the origin of the sartorius and tensor fasciae latae and the attachment of the inguinal ligament
  - 6.3 **Anterior inferior iliac spine** *(spina iliaca anterior inferior)*
    – the origin of the straight head of the rectus femoris and the attachment of the iliofemoral ligament
  - 6.4 **Posterior superior iliac spine** *(spina iliaca posterior superior)*
  - 6.5 **Posterior inferior iliac spine** *(spina iliaca posterior inferior)*
- 7 **Arcuate line** *(linea arcuata)* – part of linea terminalis

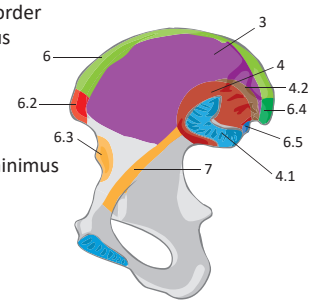

The medial side of the right hip bone

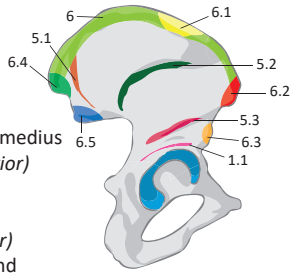

The lateral side of the right hip bone

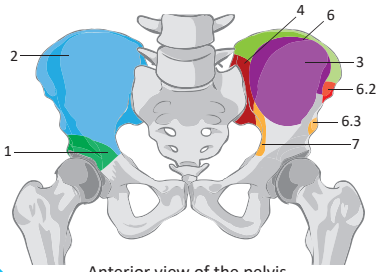

Anterior view of the pelvis

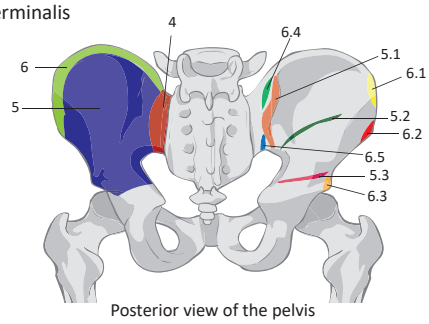

Posterior view of the pelvis

The preauricular groove *(sulcus preauricularis)* is a groove at the transition between the hip bone and sacrum. It is a typical feature of the female pelvis.

In children, the individual parts of the pelvis are separated by cartilage at the acetabulum. This cartilage has a shape of an inverted letter Y *(cartilago ypsiloformis)* and ossifies between the 14th and 16th year of life.

The appearance of the symphysial surface *(facies symphysialis)* can be used in forensic medicine to estimate age.

The groove for the dorsal nerve of the penis/clitoris *(sulcus nervi dorsalis penis/clitoridis)* is a shallow and narrow groove situated on the inferior pubic ramus and on the frontal surface of the pubic bone. It is present in 90 % of cases.

Clinical notes

The dorsal aspect of the iliac crest *(crista iliaca)* can become sensitive to touch in the presence of a hypertonic or spastic quadratus lumborum.

The superior part of the pubis becomes sensitive in the presence of a hypertonic rectus abdominis. This can occur in patients with an inguinal hernia and after surgical repair of such hernias.

The pubic bone can become sensitive in hypertonicity of the thigh adductors.

The ala of the ilium is used for harvesting spongy bone grafts for the treatment of complicated fractures in orthopaedics and traumatology.

A trephine biopsy is a procedure in which a cylindrically shaped core of bone is obtained for histopathological evaluation. Samples are drawn from the hip bone, usually from the area of the posterior superior iliac spine and occasionally from the anterior superior iliac spine.

Pubis *(os pubis)*

- 1 **Body** *(corpus ossis pubis)* – connects to the pubic symphysis
  - 1.1 **Pubic tubercle** *(tuberculum pubicum)*
    - – the attachment of the inguinal ligament and superior pubic ligament
  - 1.2 **Pubic crest** *(crista pubica)* – the insertion of the rectus abdominis
    - – the origin of the pyramidalis
  - 1.3 **Symphysial surface** *(facies symphysialis)*
    - – the medial surface articulates at the pubic symphysis
- 2 **Superior pubic ramus** *(ramus superior ossis pubis)* – forms the ventral one third of the acetabulum
  - 2.1 **Obturator crest** *(crista obturatoria)*
    - – is located between the pubic tubercle and acetabular notch
    - – the attachment of the pubofemoral ligament
  - 2.2 **Pecten pubis** *(pecten ossis pubis)* – forms part of the linea terminalis
    - – the origin of the pectineus
    - – the attachment of the inguinal falx and the lacunar and pectineal ligaments
- 3 **Inferior pubic ramus** *(ramus inferior ossis pubis)*
  - – forms the ischiopubic ramus with the ramus of the ischium
  - 3.1 **Phallic crest** *(crista phallica)* – origin of the erectile bodies of the penis and clitoris

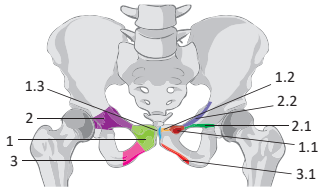

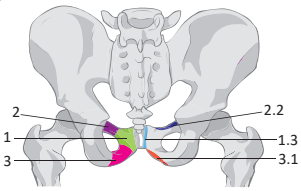

Ischium (*os oschii*)

- 1 **Body** *(corpus ossis ischii)* – the thicker dorsal part that forms the dorsal third of the acetabulum
- 2 **Ramus** *(ramus ossis ischii)* – runs ventrally from the body
  - – forms the ischiopubic ramus with the inferior pubic ramus
  - 2.1 **Ischial tuberosity** *(tuber ischiadicum)*
    - – the origin of the semimembranosus, semitendinosus, biceps femoris, adductor magnus, gemellus inferior, quadratus femoris, superficial transverse perineal muscle and ischiocavernosus
    - – the attachment of the sacrotuberous and ischiofemoral ligaments
    - – is palpable when the thigh is flexed at the hip joint
  - 2.2 **Lesser sciatic notch** *(incisura ischiadica minor)*
    - – forms the lesser sciatic foramen with the sacrospinous and sacrotuberous ligaments
  - 2.3 **Ischial spine** *(spina ischiadica)*
    - – the border between the greater and lesser sciatic notches
    - – the insertion of the iliococcygeus, ischiococcygeus and the origin of gemellus superior
    - – the attachment of sacrospinous ligament

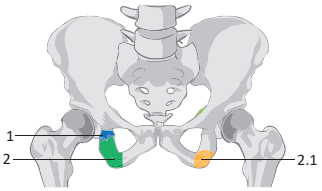

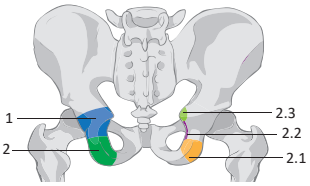

Common features of the hip bone

- 1 **Acetabulum** – the articular fossa of the hip joint composed of all 3 hip bones
  - – is enlarged by a fibrocartilaginous acetabular labrum
  - 1.1 **Acetabular margin** *(limbus acetabuli)* – an elevated ridge around the acetabulum
  - 1.2 **Acetabular notch** (*incisura acetabuli*)
    - – a caudal notch on the acetabular margin
  - 1.3 **Lunate surface** *(facies lunata)* – the articular surface of the acetabulum
    - – ends caudally at the acetabular notch
  - 1.4 **Acetabular fossa** *(fossa acetabuli)* – is filled with a fat pad *(pulvinar acetabuli)*
- 2 **Obturator foramen** *(foramen obturatum)*
  - – is surrounded by the ischium and pubis
  - – is almost fully closed by the obturator membrane
  - – the origin of the obturator externus and internus
  - 2.1 **Obturator groove** *(sulcus obturatorius)*
    - – is located on the internal side of the superior pubic ramus
    - – forms the obturator canal with the obturator membrane
    - – transmits the obturator nerve and vessels
  - 2.2 **Anterior and posterior obturator tubercle** *(tuberculum obturatorium anterius et posterius)*
    - – variable bony projections
- 3 **Greater sciatic notch** *(incisura ischiadica major)* – together with the sacrospinous and sacrotuberous ligaments forms the greater sciatic foramen
- 4 **Ischiopubic ramus** *(ramus ischiopubicus)* – the caudal border of the obturator foramen formed by the ramus of the ischium and the inferior pubic ramus
- 5 **Iliopubic ramus** *(eminentia iliopubica)* – the insertion of the psoas minor
  - – the transition of the arcuate line into the pecten pubis

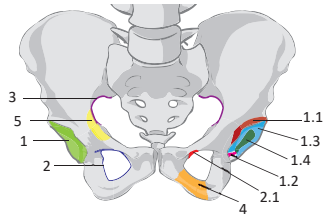

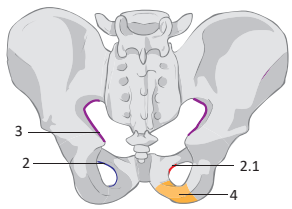

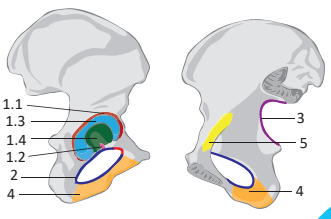

This copy belongs to ali yaghoubi

The femur is the longest bone of the human body. It is covered by a thick layer of muscles and therefore only a small proportion is palpable from the skin.

- 1 **Head** *(caput femoris)* – forms the articular head of the hip joint
  - 1.1 **Fovea of head of femur** *(fovea capitis femoris)*
    – the site of attachment of the ligament of the head of the femur
- 2 **Neck** *(collum femoris)* – the articular capsule of the hip joint attaches to the dorsal 2/3 of the neck
- 3 **Shaft of the femur** *(corpus femoris)* – the body of the femur
  - 3.1 **Greater trochanter** *(trochanter major)*
    – the insertion of the gluteus medius, gluteus minimus, piriformis, obturator internus, gemellus superior and gemellus inferior
  - 3.2 **Trochanteric fossa** *(fossa trochanterica)*
    – the insertion of the obturator externus
  - 3.3 **Lesser trochanter** *(trochanter minor)*
    – a dorsomedial prominence
    – the insertion of the iliopsoas
  - 3.4 **Intertrochanteric line** *(linea intertrochanterica)*
    – a ventral line connecting both trochanters
    – the attachment of the articular capsule of the hip joint
    – the attachment of the iliofemoral ligament
    – the origin of the vastus medialis and vastus lateralis
  - 3.5 **Intertrochanteric crest** *(crista intertrochanterica)*
    – a dorsal crest connecting both trochanters
    - 3.5.1 **Quadrate tubercle** *(tuberculum quadratum)*
      – the insertion of the quadratus femoris
  - 3.6 **Pectineal line** *(linea pectinea)* – the insertion of the pectineus
    – is located below the lesser trochanter
  - 3.7 **Gluteal tuberosity** *(tuberositas glutea)* – the insertion of the gluteus maximus
    – is located below the greater trochanter
  - 3.8 **Linea aspera** – an attachment site for many muscles of the thigh and also for the intermuscular septa
    - 3.8.1 **Medial lip** *(labium mediale)*
      – the attachment of the medial femoral intermuscular septum
      – the origin of the vastus medialis and the insertion of the adductor longus, adductor brevis and adductor magnus
    - 3.8.2 **Lateral lip** *(labium laterale)*
      – the attachment of the lateral femoral intermuscular septum
      – the origin of the short head of the biceps femoris and vastus lateralis
  - 3.9 **Lateral supracondylar line** *(linea supracondylaris lateralis)*
    – the origin of the plantaris
  - 3.10 **Medial supracondylar line** *(linea supracondylaris medialis)*
  - 3.11 **Popliteal surface** *(facies poplitea)* – the floor of the popliteal fossa
- 4 **Condyles of femur** *(condyli femoris)* – the distal end of the femur
  – articular surfaces that articulate with the tibia
  - 4.1 **Medial condyle** *(condylus medialis femoris)*
    - 4.1.1 **Medial epicondyle** *(epicondylus medialis)*
      – the attachment of the tibial collateral ligament
      – the origin of the medial head of the gastrocnemius
    - 4.1.2 **Adductor tubercle** *(tuberculum adductorium)*
      – the insertion of the extensor part of the adductor magnus
  - 4.2 **Lateral condyle** *(condylus lateralis femoris)*
    - 4.2.1 **Lateral epicondyle** *(epicondylus lateralis)*
      – the attachment of the fibular collateral ligament
      – the origin of the lateral head of the gastrocnemius
    - 4.2.2 **Groove for the popliteus** *(sulcus popliteus)*
      – the origin of the popliteus
  - 4.3 **Intercondylar line** *(linea intercondylaris)*
    – the attachment of the oblique popliteal ligament
  - 4.4 **Intercondylar fossa** *(fossa intercondylaris)*
    – the attachment of the cruciate ligaments of the knee joint
  - 4.5 **Patellar surface** *(facies patellaris)* – the ventral surface for articulation with the patella

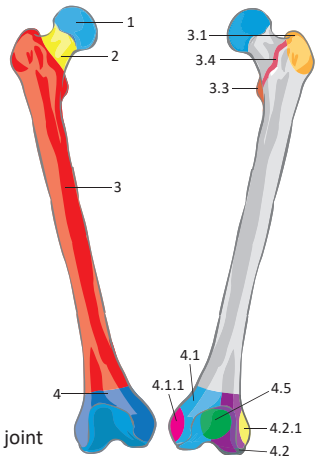

Anterior view of the right and left femur

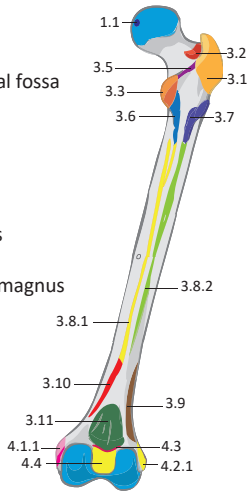

Posterior view of the right femur

The angle of inclination of the femur is formed between the neck and the body. It measures approximately 125°.

Torsion of the femur is measured by a line running between the condyles and a line through the neck of the femur. It is approximately 10°.

The greater and lesser trochanter are apophyses and have their own ossification centres.

The third trochanter *(trochanter tertius)* is an alternative term for the gluteal tuberosity in case it is very prominent.

Tubercle of Gerdy is a clinical term for the tuberosity of the iliotibial tract.

In children, **the proximal epiphyseal cartilage** of the tibia and fibula contributes 55 % of the growth of these bones. **The distal epiphyseal cartilages** contribute 45 %.

The pilon (or pylon) is a clinical term for the distal part of the tibia.
The tibial plateau is a clinical term for the proximal part of the tibia.

The internal and external supracondylar tubercles are variable tubercles found on the femoral condyles. They serve as the places of origin for the two heads of the gastrocnemius.

The greater trochanter is always palpable. In obese it is marked by the shallow skin depression.

Clinical notes

The greater trochanter may become sensitive in a radiculopathy of the spinal root L5. It is sometimes sensitive to touch in disoders of the hip.

Limited mobility of the patella can be caused by a hypertonic quadriceps femoris.

Pain provoked by pressure on the patella can occur in knee joint disorders.

Intra-osseous access to the tibia can be used in critical care medicine for application of infusions and medications. The bone marrow is accessed by a puncture approximately 1 cm below the tuberosity of the tibia.

Overload of the quadriceps femoris insertion on the tibial tuberosity can lead to disruption.

The patella is a sesamoid bone located in **the tendon of the quadriceps femoris**. It is part of the knee joint.

- 1 **Base of patella** *(basis patellae)* – the wide proximal part
- 2 **Apex of patella** *(apex patellae)* – the pointy distal end
- 3 **Articular surface** *(facies articularis)* – the dorsal surface
  - – is divided into a lateral and a medial facet
  - – the medial facet is smaller than the lateral facet
- 4 **Anterior surface** *(facies anterior)* – the roughened ventral surface
  - – incorporates part of the tendon of the quadriceps femoris

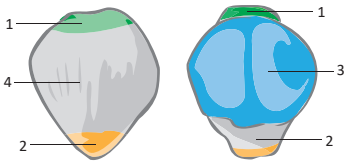

Anterior and posterior view of the right patella

6.4 **Tibia** – Tibia

The tibia is a **weight bearing bone of the leg** which forms the **shin**. It is a long bone. The distal end of the tibia forms the **medial malleolus**. **The anterior margin and the medial surface** are not covered by muscles and are therefore **palpable** in their entire course.

- 1 **Condyles of tibia** *(condyli tibiae)* – form the widened proximal end of the bone
  - – the tibia has two condyles: the medial condyle and the lateral condyle
  - – the sartorius, gracilis and semitendinosus are attached to the medial condyle as a common tendon called the pes anserinus
  - 1.1 **Superior articular surface** *(facies articularis superior)*
    - – an articular surface for articulation with the femoral condyles
  - 1.2 **Intercondylar eminence** *(eminentia intercondylaris)*
    - – an eminence located in the middle of the superior articular surface
    - – comprises the medial and lateral tubercle
  - 1.3 **Anterior intercondylar area** *(area intercondylaris anterior)*
    - – the attachment of the anterior cruciate ligament and menisci
  - 1.4 **Posterior intercondylar area** *(area intercondylaris posterior)*
    - – the attachment of the posterior cruciate ligament and menisci
  - 1.5 **Fibular articular facet** *(facies articularis fibularis)*
    - – articulates with the head of the fibula
  - 1.6 **Tuberosity for iliotibial tract** *(tuberositas tractus iliotibialis)*
    - – a small prominence for the attachment of the iliotibial tract
- 2 **Shaft** *(corpus tibiae)* – the body of the tibia
  - 2.1 **Soleal line** *(linea musculi solei)*
    - – the origin of the soleus muscle
  - 2.2 **Tibial tuberosity** *(tuberositas tibiae)*
    - – the insertion of the quadriceps femoris (as the patellar ligament)

  Surfaces:
  - 2.3 **Medial surface** *(facies medialis)*
    - – is palpable as it is not covered by muscles
  - 2.4 **Lateral surface** *(facies lateralis)*
  - 2.5 **Posterior surface** *(facies posterior)*

  Borders:
  - 2.6 **Anterior border** *(margo anterior)*
    - – is palpable as it is not covered by muscles
  - 2.7 **Interosseous border** *(margo interosseus)*
    - – the attachment of the interosseous membrane of the leg
  - 2.8 **Medial border** *(margo medialis)*
- 3 **Distal end**
  - 3.1 **Medial malleolus** *(malleolus medialis)* – the medial side of the ankle
    - 3.1.1 **Malleolar groove** *(sulcus malleolaris)*
      - – forms the malleolar canal together with the flexor retinaculum
      - – tendons of the tibialis posterior and flexor digitorum longus pass through it
    - 3.1.2 **Articular facet** *(facies articularis malleoli medialis)*
      - – articulates with the talus
  - 3.2 **Fibular notch** *(incisura fibularis)* – forms part of the tibiofibular syndesmosis
  - 3.3 **Inferior articular surface** *(facies articularis inferior)*
    - – articulates with the trochlea of the talus

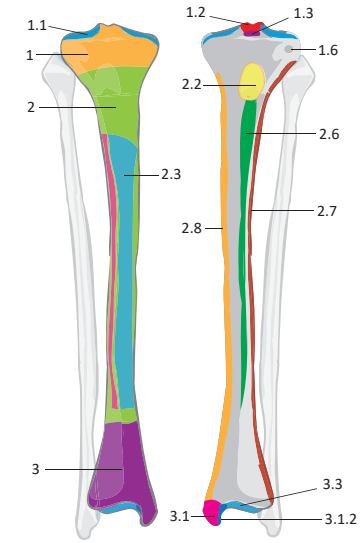

Anterior view of the left and right tibia

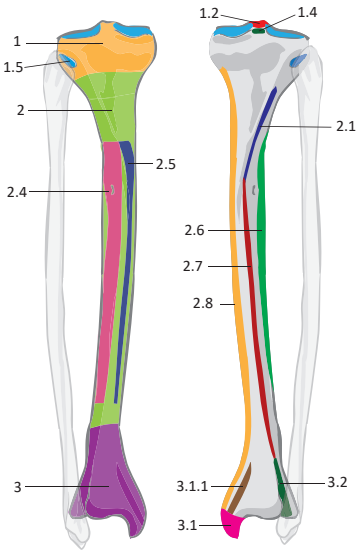

Posterior view of the left and right tibia

This copy belongs to ali yaghoubi

The fibula is a long bone located on the **lateral aspect of the leg**. **It does not bear any weight** of the body and serves only for attachments of muscles. The distal end of the fibula forms the **lateral malleolus.**

- 1 **Head** *(caput fibulae)*
  - – the insertion of the biceps femoris
  - – the attachment of the fibular collateral ligament, arcuate popliteal ligament and anterior and posterior ligaments of the head of the fibula
  - – the origin of the soleus and fibularis longus
  - 1.1 **Apex of head of fibula** *(apex capitis fibulae)*
  - 1.2 **Articular facet** *(facies articularis capitis fibulae)*
    - – articulates with the tibia
- 2 **Neck** *(collum fibulae)* – the common fibular nerve runs around the neck
- 3 **Shaft** *(corpus fibulae)*

  Surfaces:
  - 3.1 **Lateral surface** *(facies lateralis)*
  - 3.2 **Medial surface** *(facies medialis)*
  - 3.3 **Posterior surface** *(facies posterior)*

  Borders:
  - 3.4 **Anterior border** *(margo anterior)*
  - 3.5 **Posterior border** *(margo posterius)*
  - 3.6 **Interosseous border** *(margo interosseus)*
    - – the attachment of the interosseous membrane of the leg
  - 3.7 **Medial crest** *(crista medialis)*
- 4 **Lateral malleolus** *(malleolus lateralis)*
  - 4.1 **Articular facet** *(facies articularis malleoli lateralis)*
    - – articulates with the talus
  - 4.2 **Malleolar fossa** *(fossa malleoli lateralis)*
    - – for the posterior talofibular ligament
  - 4.3 **Malleolar groove** *(sulcus malleolaris)*
    - – transmits the tendons of the fibularis longus and brevis in a common tendon sheath under the superior fibular retinaculum

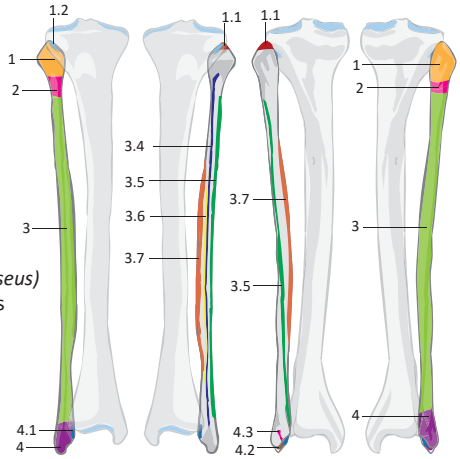

Anterior and posterior view of the right and left fibulae

6.6 **Bones of the foot** – Ossa pedis

The bones of the foot consist of **7 tarsal bones, 5 metatarsal bones and 14 phalanges**. The tarsal bones form the **longitudinal and transverse arch of the foot.** The longitudinal arch is divided into a medial and lateral arch. **The lateral arch** consists of the calcaneus, cuboid and the 5th metatarsal. **The medial** arch consists of the calcaneus, talus, navicular bone, the three cuneiform bones and the 1st metatarsal. The general organisation of **the metatarsals and phalanges of the foot** is similar to the organisation of the metacarpals and phalanges of the hand.

Tarsal bones *(ossa tarsi)*

- 1 **Talus** – ankle bone
- 2 **Calcaneus** – heel bone
- 3 **Navicular** *(os naviculare)*
- 4 **Medial cuneiform** *(os cuneiforme mediale)*
- 5 **Intermediate cuneiform** *(os cuneiforme intermedium)*
- 6 **Lateral cuneiform** *(os cuneiforme laterale)*
- 7 **Cuboid** *(os cuboideum)*

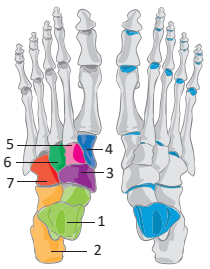

Superior view of the left and right foot

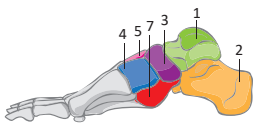

Medial view of the right foot

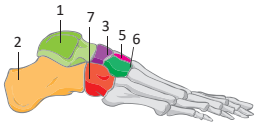

Lateral view of the right foot

Bones

Almost 60 % of the surface area of the talus is covered by cartilage. It receives blood only from areas that are not covered by cartilage. Its blood supply is very liable to compromise in trauma.

The calcaneus is made up of a large proportion trabecular bone. It has a thicker compact layer close to the insertion of the calcaneal tendon.

Astragalus is a Greek term for talus.

Perone is a Greek term for fibula. Peroneus is often used synonymously with fibularis.

The tuberosity above the articular facet of the lateral malleolus *(facies articularis malleoli lateralis)* serves for the attachment of the tibiofibular syndesmosis.

A groove for the tendon of the flexor hallucis longus is located on both the talus and calcaneus. Together they form a canal for this tendon in its tendinous sheath.

The tarsal sinus *(sinus tarsi)* is situated between the talar sulcus *(sulcus tali)* and calcaneal sulcus *(sulcus calcanei)*. It is filled with the interosseous talocalcaneal ligament.

Clinical notes

The common fibular nerve *(nervus fibularis communis)* runs superficially behind the head and neck of the fibula. It can be injured by trauma or by an incorrectly positioned cast compressing the nerve.

The calcaneus is the most frequently injured bone of the tarsus.

A calcaneal spur *(calcar calcanei)* is an osseous projection formed inside the ligament and muscle attachments on the calcaneal tuberosity (its plantar surface) or less often at the attachment of the calcaneal tendon. It forms due to repeated stress on the calcaneus and can cause pain during walking.

Pain in the calcaneus can develop in the presence of calcaneal spurs, in hypertonicity of the triceps surae and quadratus plantae, in overload of the plantar aponeurosis and in depression of the transverse arch of the foot.

Talus

- 1 **Body** *(corpus tali)*
  - 1.1 **Trochlea of talus** *(trochlea tali)* – the articular head of the ankle (talocrural) joint
    - 1.1.1 **Lateral process** *(processus lateralis tali)* – the attachment of the lateral talocalcaneal ligament

    Articular facets:
    - 1.1.2 **Superior facet** *(facies articularis superior)* – articulates with the inferior surface of the tibia
    - 1.1.3 **Lateral malleolar facet** *(facies articularis malleolaris lateralis)* – a large lateral facet
      – articulates with the articular facet of the lateral malleolus of the fibula
    - 1.1.4 **Medial malleolar facet** *(facies articulatis malleolaris medialis)* – a small medial facet
      – articulates with the articular facet of the medial malleolus of the tibia
  - 1.2 **Posterior process** *(processus posterior tali)*
    - 1.2.1 **Groove for tendon of flexor hallucis longus** *(sulcus tendinis musculi flexoris hallucis longi)*
    - 1.2.2 **Latetal tubercle** *(tuberculum laterale)* – the attachment of the posterior talofibular ligament
    - 1.2.3 **Medial tubercle** *(tuberculum mediale)* – the attachment of the medial talocalcaneal ligament
  - 1.3 **Posterior calcaneal articular facet** (facies articularis calcanea posterior) – articulates caudally with the calcaneus
- 2 **Neck** *(collum tali)* – the attachment of the articular capsule, anterior talofibular ligament and talonavicular ligament
  - 2.1 **Middle calcaneal articular facet** *(facies articularis calcanea media)* – articulates with the calcaneus caudally
  - 2.2 **Sulcus tali** – a groove located between the posterior articular facet and the middle and anterior articular facets
- 3 **Head** *(caput tali)* – the head of the talonavicular joint
  - 3.1 **Navicular articular surface** *(facies articularis navicularis)* – articulates with the navicular bone
  - 3.2 **Anterior calcaneal articular facet** *(facies articularis calcanea anterior)* – articulates caudally with the calcaneus

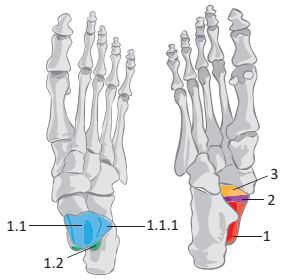

Superior and inferior views of the right foot

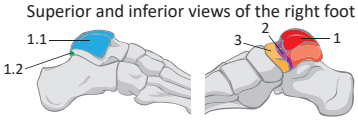

Lateral and medial views of the right foot

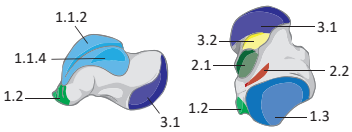

Medial and inferior views of the talus

Calcaneus

- 1 **Calcaneal tuberosity** *(tuber calcanei)* – is located the dorsal surface of the calcaneus
  – the insertion of the triceps surae (as the Achilles tendon) and the plantaris
  – the attachment of the plantar aponeurosis
  - 1.1 **Medial process** *(processus medialis)* – the attachment of the flexor retinaculum
    – the origin of the abductor hallucis and flexor digitorum brevis
  - 1.2 **Lateral process** *(processus lateralis)* – the origin of the abductor digiti minimi
- 2 **Calcaneal tubercle** *(tuberculum calcanei)* – is located on the plantar surface
  – the attachment of the plantar calcaneocuboid ligament and part of the long plantar ligament
- 3 **Sustentaculum tali** – the talar shelf, projects medially
  – the attachment of the tibiocalcaneal part of the medial collateral ligament, medial talocalcaneal ligament and plantar calcaneonavicular ligament
  - 3.1 **Groove for tendon of flexor hallucis longus** *(sulcus tendinis musculi flexoris hallucis longi)*
- 4 **Fibular trochlea** *(trochlea fibularis)*
  – a bony projection, under which runs the tendon of the fibularis longus

  5 **Talar articular surfaces** *(facies articulares talares)* – articulates with the talus
  - 5.1 **Anterior articular talar surface** *(facies articularis talaris anterior)*
  - 5.2 **Middle articular talar surface** *(facies articularis talaris media)*
  - 5.3 **Posterior articular talar surface** *(facies articularis talaris posterior)*
- 6 **Calcaneal sulcus** *(sulcus calcanei)* – forms the tarsal sinus with the sulcus tali
  – a groove between the posterior articular facet and the middle and anterior articular facets
- 7 **Articular surface for cuboid** *(Facies articularis cuboidea)* – a facet on the ventral surface of the bone

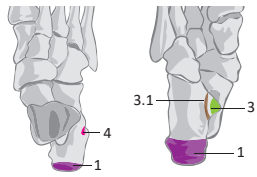

Superior and inferior views of the right foot

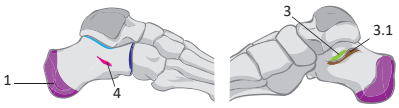

Lateral and medial views of the right foot

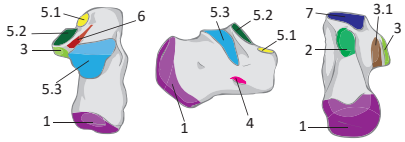

Superior, lateral and inferior views of the calcaneus

Navicular *(os naviculare)*

– has a proximal articular cavity for articulation with the talus
– has 3 distal facets for articulation with the cuneiform bones
– has a laterodistal facet for articulation with the cuboid

- 1 **Tuberosity** *(tuberositas ossis navicularis)* – a palpable tuberosity located on the medial side of the foot
  – the insertion of the tibialis posterior
  – the attachment of the tibionavicular part of the medial collateral ligament and the plantar calcaneonavicular ligament

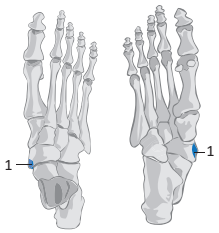

Superior and inferior views of the right foot

This copy belongs to ali yaghoubi

Cuboid *(os cuboideum)*

– has a facet on its medial surface for articulation with the lateral cuneiform
– has a narrow facet for articulation with the navicular
– has a facet on its proximal surface for articulation with the calcaneus
– has two facets on its distal surface for articulation with the 4th and 5th metatarsals

- 1 **Tuberosity of cuboid** *(tuberositas ossis cuboidei)* – is located lateroplantarly
  – the attachment of the deep fibres of the long plantar ligament
- 2 **Groove for tendon of fibularis longus** *(sulcus tendinis musculi fibularis longi)* – a groove on the plantar surface
- 3 **Calcaneal process** *(processus calcaneus)*
  – is located proximally and points towards the calcaneus

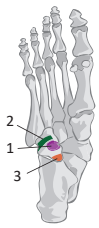

Inferior view of the right foot

Cuneiform bones *(ossa cuneiformia)*

- 4 **Medial cuneiform** *(os cuneiforme mediale)* – the largest cuneiform
  – is wedge-shaped with a dorsal facing apex
  – has a facet on its proximal surface for articulation with the navicular
  – has a kidney-shaped facet for articulation with the 1st metatarsal
- 5 **Intermediate cuneiform** *(os cuneiforme intermedium)*
  –the smallest cuneiform
  – is wedge-shaped with a plantar facing apex
  – has a triangular-shaped facet for articulation with the 2nd metatarsal
- 6 **Lateral cuneiform** *(os cuneiforme laterale)*
  – is wedge shaped with a plantar facing apex
  – has a facet on its proximal surface for articulation with the navicular
  – has an oval-shaped facet for articulation with the cuboid

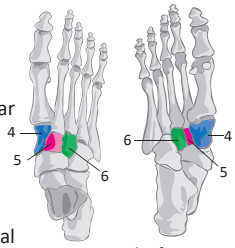

Superior and inferior views of the right foot

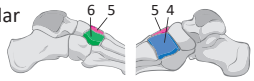

Lateral and medial views of the right foot

Metatarsals *(ossa metatarsi)*

General organization

- 1 **Base** *(basis ossis metatarsi)*
- 2 **Shaft** *(corpus ossis metatarsi)*
- 3 **Head** *(caput ossis metatarsi)*

I **1st metatarsal** *(os metatarsi primum)* – the thickest metatarsal
– has a kidney-shaped facet for articulation with the medial cuneiform
- 1.1 **Tuberosity of 1st metatarsal** *(tuberositas ossis metatarsi primi)* – the insertion of the muscles of the big toe

II **2nd metatarsal** *(os metatarsi secundum)* – the longest metatarsal
– has a triangular facet for articulation with the intermediate cuneiform
– articulates with the medial and lateral cuneiform bones

III **3rd metatarsal** *(os metatarsi tertium)* – has a triangular facet on its proximal surface for articulation with lateral cuneiform bone

IV **4th metatarsal** *(os metatarsi quartum)* – has a quadrate-shaped facet on its proximal surface for articulation with the cuboid

V **5th metatarsal** *(os metatarsi quintum)*
– has a facet on its proximal surface for articulation with the cuboid
- 5.1 **Tuberosity of 5th metatarsal bone** *(tuberositas ossis metatarsi quinti)*
  – the insertion of the fibularis brevis
  – the origin of the abductor digiti minimi

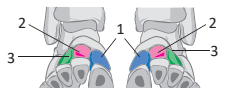

Anterior view of cross sections through the metatarsals of the right and left foot

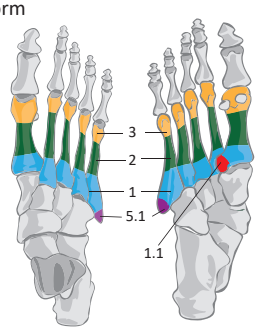

Superior and inferior view of the right foot

Phalanges *(ossa digitorum)* – bones of the toes

- 1 **Proximal phalanx** *(phalanx proximalis)*
  - 1.1 **Base** *(basis)* – has an oval-shaped articular fossa
  - 1.2 **Shaft** *(corpus)* – body
  - 1.3 **Head** *(caput)* – is pulley-shaped
- 2 **Middle phalanx** *(phalanx media)*
  - 2.1 **Base** *(basis)* – forms an articular fossa
  - 2.2 **Shaft** *(corpus)* – body
  - 2.3 **Head** *(caput)* – is pulley-shaped
- 3 **Distal phalanx** *(phalanx distalis*)
  - 3.1 **Base** *(basis)* – forms an articular fossa
  - 3.2 **Shaft** *(corpus)* – body
  - 3.3 **Tuberosity of distal phalanx** *(tuberositas phalangis distalis)*

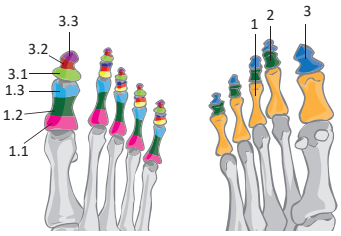

Superior and inferior view of the right foot

The tuberosity of the fifth metatarsal bone has its own centre of ossification.

The sesamoid bones of foot *(ossa sesamoidea pedis)* are located in the flexor hallucis brevis tendons over the first metatarsophalangeal joint.

Os peroneum is a small accessory bone (present in 25 %) located at the lateral plantar aspect of the cuboid within the tendon of the fibularis longus as it arches around the cuboid.

Clinical notes

March fractures are a form of fatigue fractures that affect the second and third metatarsal bone after prolonged periods of marching or running. They occur most frequently in firm shoes with hard soles.

Avulsion fractures can occur on the tuberosity of the fifth metatarsal by traction at the fibularis brevis attachment.

Pain and swelling around the heads of the metatarsals develop in depression of transverse arch of the foot and insufficient foothold of calcaneus.

Metatarsalgia of Morton is a painful disorder caused by compression of nerves in the intermetatarsal spaces.

Hammer toe *(digitus malleus)* is a common foot deformity. It is caused by a disbalance between the short and long foot muscles. It is characterised by flexion at the proximal interphalangeal joint and hyperextension in the distal interphalangeal joint. The most common cause is wearing of ill-fitting shoes, which puts pressure on the proximal phalanges and cause blisters and painful corns *(clavi)*.

A bunion *(hallux valgus)* is a foot deformity, characterised by lateral deviation of the big toe. A bulge can develop in the area of the first metatarsophalangeal joint. This disorder is more common in women who wear shoes with stiletto heels.

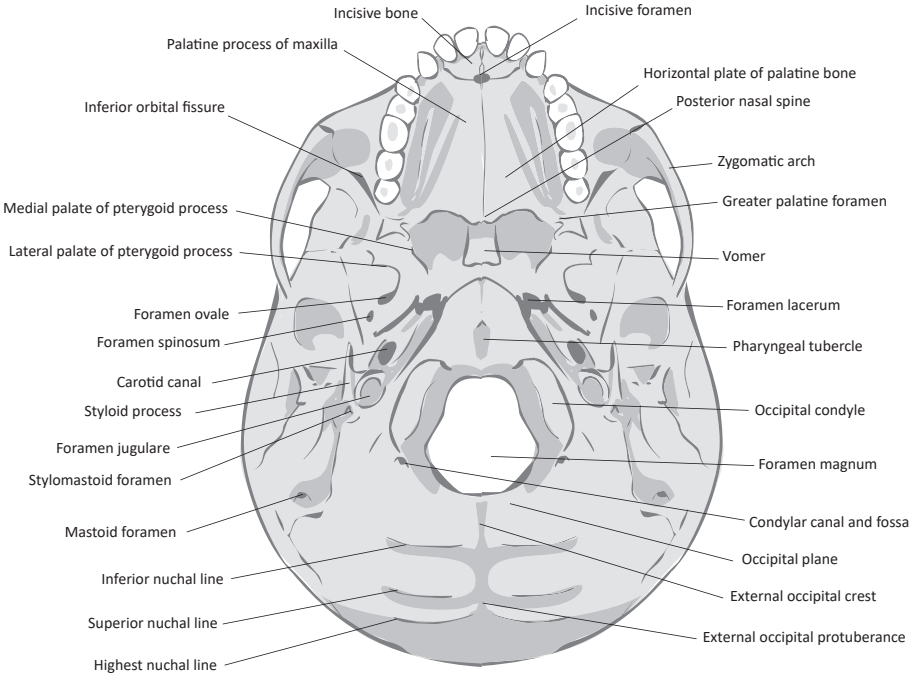

External view of the cranial base (*basis cranii externa*)

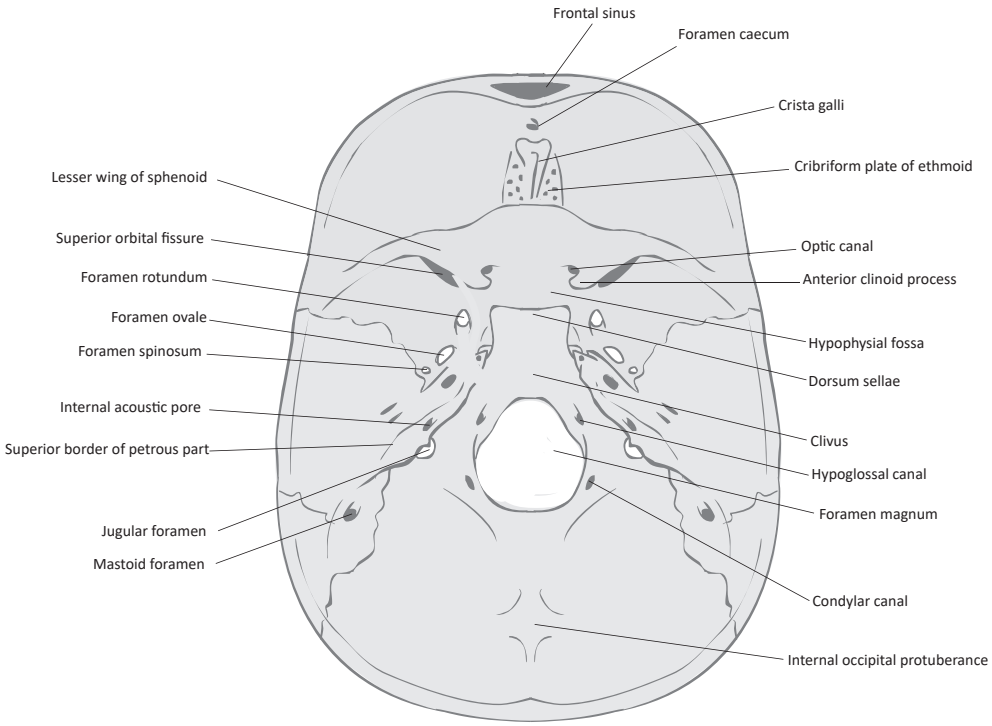

Internal view of the cranial base (*basis cranii interna*)

This copy belongs to ali yaghoubi

From	Through	To	Content
Alveolar canals of the maxilla	**Alveolar canals of the maxilla**	Dental alveoli of the maxilla	Posterior superior alveolar branches (nerves) Posterior superior alveolar artery
Diploë	**Diploic canals**	Diploë	Diploic veins
Hard palate	**Incisive canals**	Nasal cavity	Nasopalatine nerves and posterior septal branches of sphenopalatine artery
Greater palatine canal	**Lesser palatine canals**	Lesser palatine foramina on the hard palate	Lesser palatine nerve, artery and vein
Carotid canal	**Caroticotympanic canaliculi**	Carotid wall of the tympanic cavity	Caroticotympanic arteries and nerves
Scala tympani of the chochlea of the bony labyrinth	**Cochlear canaliculus**	Inferior surface of the petrous part of the temporal bone on the external surface of the cranial base	Cochlear aqueduct Vein of cochlear aqueduct
Mastoid part of the facial canal	**Canaliculus for chorda tympani**	Tympanic cavity	Chorda tympani Posterior tympanic artery and vein
Jugular fossa	**Mastoid canaliculus**	Tympanomastoid fissure	Auricular branch of vagus nerve
Petrosal fossula	**Tympanic canaliculus**	Jugular wall of the tympanic cavity	Tympanic nerve Inferior tympanic artery and vein
Vestibule of the bony labyrinth	**Vestibular canaliculus**	Posterior surface of the petrous part of the temporal bone on the internal surface of the cranial base	Endolymphatic duct
External opening of the carotid canal on the external surface of the cranial base in the foramen lacerum	**Carotid canal**	Internal opening of carotid canal in the middle cranial fossa	Internal carotid artery Internal carotid venous plexus Internal carotid plexus (sympathetic nerves)
Posterior cranial fossa	**Condylar canal**	External surface of cranial base	Condylar emissary vein Meningeal branch of the ascending pharyngeal artery
Infra-orbital groove	**Infra-orbital canal**	Infra-orbital foramen	Infra-orbital nerve Infra-orbital artery and vein
Mandibular foramen	**Mandibular canal**	Mental foramen	Inferior alveolar artery and vein Inferior alveolar nerve
External surface of cranial base	**Canal for tensor tympani** (part of the musculotubal canal)	Carotid wall of the tympanic cavity	Tensor tympani
External surface of cranial base	**Canal for auditory tube** (part of the musculotubal canal)	Carotid wall of the tympanic cavity	Auditory tube (Eustachian tube)
Geniculum of facial canal	**Canal for greater petrosal nerve**	Hiatus for greater petrosal nerve	Greater petrosal nerve Petrosal branch of middle meningeal artery
Tegmental wall of the tympanic cavity	**Canal for lesser petrosal nerve**	Hiatus for lesser petrosal nerve	Lesser petrosal nerve Superior tympanic arteriy and vein
Fossa for lacrimal sac	**Nasolacrimal canal**	Inferior nasal meatus	Nasolacrimal duct
Internal acoustic meatus	**Facial canal**	Stylomastoid foramen	Facial nerve Stylomastoid artery and vein
Posterior cranial fossa	**Hypoglossal canal**	External surface of the cranial base	Hypoglossal nerve Venous plexus of hypoglossal canal Meningeal branch of ascending pharyngeal artery
Middle cranial fossa	**Optic canal**	Apex of the orbit	Ophthalmic artery Ophthalmic plexus Optic nerve
Pterygopalatine fossa	**Greater palatine canal**	Greater palatine foramen	Greater palatine nerve Greater palatine artery and vein
Pterygopalatine fossa	**Palatovaginal canal**	External surface of cranial base	Pharyngeal nerve Pharyngeal branch of the maxillary artery
External surface of the cranial base	**Pterygoid canal of *Vidius***	Pterygopalatine fossa	Nerve of pterygoid canal (formed from greater petrosal nerve and deep petrosal nerve) Artery and vein of the pterygoid canal

From	Through	To	Content
Anterior cranial fossa	**Foramen caecum**	Nasal cavity	Emissary vein of the foramen caecum
Medial wall of the orbit	**Anterior ethmoidal foramen** (origin of the orbitocranial canal)	Cribriform plate (anterior cranial fossa)	Anterior ethmoidal nerve Anterior ethmoidal artery and vein
Medial wall of the orbit	**Posterior ethmoidal foramen** (origin of the orbitoethmoidal canal)	Posterior ethmoidal cells	Posterior ethmoidal nerve Posterior ethmoidal artery and vein
Supra-orbital margin of orbit	**Frontal foramen / notch**	Facial aspect	Medial branch of the supra-orbital nerve
Posterior cranial fossa	**Jugular foramen**	External surface of cranial base	Internal jugular vein (the superior bulb is located above the foramen and is formed by the sigmoid sinus and inferior petrosal sinus) Glossopharyngeal nerve Vagus nerve Accessory nerve Posterior meningeal artery Ramus meningeus arteriae occipitalis
Middle cranial fossa	**Foramen lacerum**	External surface of cranial base	Internal carotid artery Internal carotid plexus Internal carotid venous plexus Deep petrosal nerve Greater petrosal nerve Lesser petrosal nerve Recurrent branch of the foramen lacerum
Groove for sigmoid sinus (posterior cranial fossa)	**Mastoid foramen**	Occipital aspect	Mastoid emissary vein Meningeal branch of the occipital artery
Posterior cranial fossa	**Foramen magnum**	External surface of cranial base	Transition of the medulla oblongata to the spinal cord Vertebral arteries Anterior spinal artery Posterior spinal arteries Emissary veins Spinal roots of accessory nerves Tectorial membrane Longitudinal bands of the cruciate ligament of the atlas Apical ligament of the dens
Middle cranial fossa	**Foramen ovale**	Infratemporal fossa	Mandibular nerve Venous plexus of the foramen ovale Accessory meningeal artery
Internal surface of calvaria	**Parietal foramen**	External surface of calvaria	Parietal emissary vein
Middle cranial fossa	**Foramen petrosum**	Infratemporal fossa	Lesser petrosal nerve
Middle cranial fossa	**Foramen rotundum**	Pterygopalatine fossa	Maxillary nerve
Pterygopalatine fossa	**Sphenopalatine foramen**	Nasopharyngeal meatus of nasal cavity	Sphenopalatine artery and vein Posterior superior lateral and medial nasal branches of the maxillary nerve
Middle cranial fossa	**Foramen spinosum**	Infratemporal fossa	Middle meningeal artery Middle meningeal artery and vein Meningeal branch of the mandibular nerve
Middle cranial fossa	**Foramen squamosum**	Temporal region	Squamous emissary vein
Supra-orbital margin of the orbit	**Supra-orbital foramen / notch**	Forehead	Lateral branch of the supra-orbital nerve Supra-orbital artery and vein
Middle cranial fossa	**Foramen venosum of Vesalius**	Foramen venosum	Emissary vein of the foramen venosum
Lateral wall of the orbit	**Zygomatico-orbital foramen**	Zygomaticofacial and zygomatic-otemporal foramen	Zygomatic nerve which divides in the canal into the zygomaticotemporal branch and zygomaticofacial branch

This copy belongs to ali yaghoubi

From region	Through	To region	Content
Pterygopalatine fossa	**Inferior orbital fissure**	Orbit	Zygomatic nerve, Infra-orbital nerve and artery Inferior ophthalmic vein Orbital muscle (covers most of its lateral part)
Middle cranial fossa	**Superior orbital fissure**	Orbit	Oculomotor nerve, Trochlear nerve, Abducent nerve Ophthalmic nerve (nasociliary nerve, frontal nerve and lacrimal nerve) Superior ophthalmic vein
Temporal region	**Petrotympanic fissure**	Carotid wall of the tympanic cavity	Chorda tympani Anterior tympanic artery and vein Anterior ligament of malleus
Infratemporal fossa	**Pterygomaxillary fissure**	Pterygopalatine fossa	Maxillary artery Venous tributaries to the pterygoid plexus
Middle cranial fossa	**Petrosphenoidal fissure**	External surface of the cranial base	Lesser petrosal nerve
Middle cranial fossa	**Hiatus for lesser petrosal nerve**	Tegmental wall of the tympanic cavity	Lesser petrosal nerve Superior tympanic artery and vein
Anterior cranial fossa	**Cribriform plate (via cribriform foramina)**	Nasal cavity	Olfactory nerves Anterior meningeal artery and vein Anterior ethmoidal nerve
Posterior cranial fossa	**Internal acoustic opening (in the internal acoustic meatus)**	Facial canal and the bony labyrinth of the temporal bone	Facial nerve Vestibulocochlear nerve Labyrinthine artery and vein
Middle cranial fossa	**Tegmen tympani**	Tegmental wall of the tympanic cavity	Tympanic veins

8.2 Structures of the upper limb

Structure	Muscle – origin (O), insertion (I)	Ligament, articular capsule
	Scapula	
Subscapular fossa	O: subscapularis	
Spine of scapula	O: deltoid (spinal part) I: trapezius (transverse and ascending part)	Inferior transverse scapular ligament
Supraspinous fossa	O: supraspinatus	
Infraspinous fossa	O: infraspinatus	
Acromion	O: deltoid, I: trapezius (transverse part)	Coraco-acromial ligament, acromioclavicular ligament
Medial border of scapula	I: levator scapulae, rhomboid major and minor, serratus anterior	
Lateral border of scapula	O: teres minor, teres major	
Superior border of scapula	O: omohyoid (inferior belly)	
Suprascapular notch		Superior transverse scapular ligament
Spinoglenoid notch		Inferior transverse scapular ligament
Inferior angle of scapula	O: teres major	
Superior angle of scapula	I: levator scapulae	
Supraglenoid tubercle	O: biceps brachii (long head)	
Infraglenoid tubercle	O: triceps brachii (long head)	
Neck of scapula		Articular capsule
Coracoid process	O: biceps brachii (short head), coracobrachialis I: pectoralis minor	Coracoacromial ligament, coracohumeral ligament, coracoclavicular ligament

Structure	Muscle – origin (O), insertion (I)	Ligament, articular capsule
Clavicle		
Sternal end	O: sternohyoid	Anterior and posterior sternoclavicular ligament, Interclavicular ligament
Body of clavicle	O: sternocleidomastoid O: pectoralis major (clavicular head)	
Subclavian groove	I: subclavius	
Acromial end	O: deltoid (clavicular part) I: trapezius (descending part)	Acromioclavicular ligament
Humerus		
Anatomical neck		Inferior glenohumeral ligament, articular capsule
Greater tubercle	I: supraspinatus, infraspinatus, teres minor	Transverse humeral ligament, coracohumeral ligament
Lesser tubercle	I: subscapularis	Transverse humeral ligament, glenohumeral ligaments
Crest of greater tubercle	I: pectoralis major	
Crest of lesser tubercle	I: teres major, latissimus dorsi	
Intertubercular sulcus (bicipital groove)	tendon of the long head of the biceps brachii	
Deltoid tuberosity	I: deltoid	
Medial supraepicondylar ridge	O: pronator teres (humeral head)	
Lateral supraepicondylar ridge	O: brachioradialis, extensor carpi radialis longus	
Lateral epicondyle	Common origin of the extensors of the hand, anconeus	Radial collateral ligament
Medial epicondyle	Common origin of the flexors of the hand	Humerocoronoid ligament, olecranohumeral ligament
Radius		
Neck of radius		Articular capsule
Radial tuberosity	I: biceps brachii	
Pronator tuberosity	I: pronator teres	
Interosseous border of radius		Radio-ulnar syndesmosis (interosseous membrane of forearm, oblique cord)
Dorsal tubercle		Dorsal radiocarpal ligament
Radial styloid process		Palmar radiocarpal ligament, radial collateral ligament of the wrist joint
Suprastyloid crest	I: brachioradialis	
Ulna		
Olecranon	I: triceps brachii	Olecranohumeral ligament and oblique ligament
Coronoid process		Humerocoronoid ligament and oblique ligament
Tuberostiy of ulna	I: brachialis	
Interosseous border of ulna		Radio-ulnar syndesmosis (interosseous membrane of the forearm, oblique cord)
Supinator crest	O: supinator	
Bones of the hand – Ossa manus		
Tubercle of scaphoid	O: abductor pollicis brevis	
Tubercle of trapezium	O: abductor pollicis brevis, opponens pollicis, superficial head of flexor pollicis brevis	
Pisiform	I: flexor carpi ulnaris O: abductor digiti minimi	Pisohamate ligament, pisometacarpal ligament
Hook of the hamate	O: flexor digiti minimi brevis, opponens digiti minimi	Pisohamate ligament

This copy belongs to ali yaghoubi

Structure	Muscle – origin (O), insertion (I)	Ligament, capsule
Hip bone – Os coxae		
Acetabular notch		Transverse acetabular ligament
Outer lip of iliac crest	O: tensor fasciae latae, latissimus dorsi I: external obliquue	Fascia lata
Intermediate zone of iliac crest	O: internal obliquue	
Inner lip of iliac crest	O: transverus abdominis, quadratus lumborum, erector spinae	Thoracolumbar fascia
Anterior superior spina iliaca	O: sartorius, tensor fasciae latae	Inguinal ligament
Anterior inferior spina iliaca	O: rectus femoris (straight head)	Iliofemoral ligament
Posterior inferio spina iliaca	O: piriformis (small part)	
Iliac fossa	O: iliacus	
Gluteal surface	O: gluteus maximus, medius, minimus	
Supra-acetabular groove	O: rectus femoris (reflected head)	
Iliac tuberosity		Posterior and interosseous sacro-iliac ligament
Ischial tuberosity	O: semimembranosus, semitendinosus, biceps femoris, adductor magnus, gemellus inferior, quadratus femoris, superficial transverse perineal muscle, ischiocavernosus	Sacrotuberous ligament, ischiofemoral ligament
Ischial spine	O: gemellus superior I: illiococcygeus, ischiococcygeus	Sacrospinous ligament
Iliopubic ramus	I: psoas minor	Pubofemoral ligament
Pubic tubercle		Inguinal ligament, superior pubic ligament
Pubic crest	I: rectus abdominis, pyramidalis	
Pecten pubis	O: pectineus, I: psoas minor	Lacunar ligament, inguinal falx, pectineal ligament
Obturator crest		Pubofemoral ligament
Phallic crest		Crus of penis/clitoris
Obturator groove		Passage of obturator nerve and vasa
Femur		
Fovea for ligament		Ligament of head of femur
Neck of femur		Capsule of the hip joint (dorsal side)
Greater trochanter	I: gluteus medius, minimus, piriformis, superior and inferior gemelli, obturatorius internus	
Lesser trochanter	I: iliopsoas	
Trochanteric fossa	I: obturatorius externus	
Intertrochanteric line	O: vastus medialis and lateralis	Iliofemoral ligament, capsule of the hip joint
Intertrochanteric crest	I: quadratus femoris	
Medial lip of linea aspera	O: vastus medialis, adductor longus, adductor brevis, adductor magnus	Medial intermuscular septum
Lateral lip of linea aspera	O: short head of biceps femoris, vastus lateralis	Lateral intermuscular septum
Pectinal line	A: pectineus	
Gluteal tuberosity	A: gluteus maximus	

Structures	Muscle – origin (O), insertion (I)	Ligament, capsule
Femur		
Adductor tubercle	I: adductor magnus	
Lateral supracondylar line	O: plantaris	
Groove for popliteus	O: popliteus	
Intercondylar fossa		Anterior and posterior cruciate ligament
Intercondylar line		Oblique popliteal ligament, articular capsule
Medial epicondyle		Tibial collateral ligament
Lateral epicondyle		Fibular collateral ligament
Tibia		
Anterior intercondylar area		Anterior cruciate ligament, lateral meniscus
Posterior intercondylar area		Posterior cruciate ligament, medial meniscus
Tibial tuberosity	I: quadriceps femoris (patellar ligament)	
Iliotibial tract tuberosity		Iliotibial tract (thickened part of fascia lata)
Soleal line	O: soleus (part of triceps surae)	
Interosseus border of tibia		Interosseous membrane
Malleolar groove of tibia	The tendon of tibialis posterior and the tendon of the flexor digitorum longi run through this groove	
Fibular notch		Tibiofibular syndesmosis
Fibula		
Head of fibula	O: soleus, fibularis longus I: biceps femoris	Fibular collateral ligament, arcuate popliteal ligament, anterior and posterior ligament of the fibular head
Interosseus border of fibula		Interosseous membrane of the leg
Fibular malleolar groove	The tendons of fibularis longus and brevis run through this groove	
Lateral malleolar fossa		Posterior talofibular ligament
Bones of the foot – Ossa pedis		
Neck of talus		Anterior talofibular ligament, talonavicular ligament
Sulcus tali and calcaneal sulcus		Talocalcaneal interosseous ligament
Lateral process of talus		Lateral talocalcaneal ligament
Groove for tendon of flexor hallucis longus and calcaneal sulcus	Flexor hallucis longus runs through this groove	
Medial tubercle of posterior process of talus		Medial talocalcaneal ligament
Lateral tubercle of posterior process of talus		Posterior talofibular ligament
Calcaneal tuberosity	I: triceps surae, plantaris	
Medial process of calcaneal tuberosity	O: abductor hallucis, flexor digitorum brevis	Flexor retinaculum
Lateral process of calcaneal tuberosity	O: abductor digiti minimi	
Sustentaculum tali		Tibiocalcaneal part of the medial ligament, medial talocalcaneal ligament, plantar calcaneonavicular ligament
Groove for tendon of fibularis longus	Tendon of fibularis longus runs through this groove	
Tuberosity of navicular	I: tibialis posterior	Tibionavicular part of the medial ligament, plantar calcaneonavicular ligament
Tuberosity of cuboid		Long plantar ligament
Tuberosity of the fifth metatarsal	O: abductor digiti minimi, A: fibularis brevis	

This copy belongs to ali yaghoubi

I. General osteology

1. Explain the term “apophysis”. Give at least two examples of apophyses. (p. 18)
2. Explain the term “Haversian system”. Specify where we can find it. (p. 19)
3. State where we can find red bone marrow in adults. (p. 20)

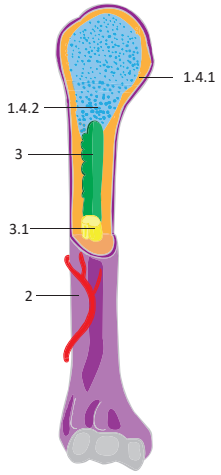

Describe general structure of bone

II. Bones of the skull

4. State the circumference and dorsoventral diameter of the skull of a newborn. (p. 35)
5. Name three bones of the skull that develop by endochondral ossification and three bones that develop by intramembranous ossification. (p. 20)
6. State at least three openings of the greater wing of the sphenoidal bone and list their contents. (p. 25)
7. Name two bones of the skull that feature an impression for the sigmoid sinus. (p. 23, 29)
8. Name three bones of the skull that feature an impression of the superior sagittal sinus. (p. 22, 23, 26)
9. Name the bone that possesses the superior nuchal line and describe its purpose. (p. 23)
10. Name the two bones of the skull that form the jugular foramen. (p. 23, 28)
11. State 5 dural venous sinuses that form impressions on the occipital bone. (p. 23)
12. List the borders of both the superior and inferior orbital fissure. (p. 24)
13. Name the two processes of the ramus of the mandible and state what they are for. (p. 34)
14. State at least 5 differences between the male and female skull. (p. 36)
15. Explain the term “premaxilla”. (p. 33)
16. Specify at which vertebral level we can find the hyoid bone. (p. 35)

III. Bones of the thorax and vertebral column

17. List 5 typical features of cervical vertebrae. (p. 38)
18. State the two cervical vertebrae that differ from the general structure of cervical vertebrae and describe their differences. (p. 38)
19. Describe the differences of vertebra T12 from the general structur of the thoracic vertebrae. (p. 39)
20. State the 5 subdivisions of the vertebral column and specify the number of vertebrae that form them. (p. 37)
21. Describe the sacral promontory and explain its significance. (p. 40)
22. List the curvatures of the vertebral column and specify the ages in which they develop. (p. 37)
23. State the term used for the 11th and 12th ribs and explain how they are different from the other ribs. (p. 41)
24. List the 3 structures that run in the costal groove and state the order in which they run. (p. 41)
25. Name the rib number of the rib that connects to the sternum at the level of the sternal angle. (p. 41)
26. Specify the location by ribs of the scapula. (p. 43)

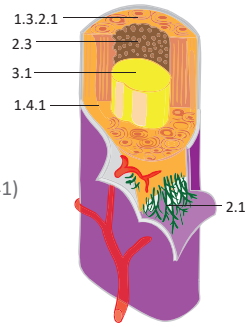

Describe general structure of bone

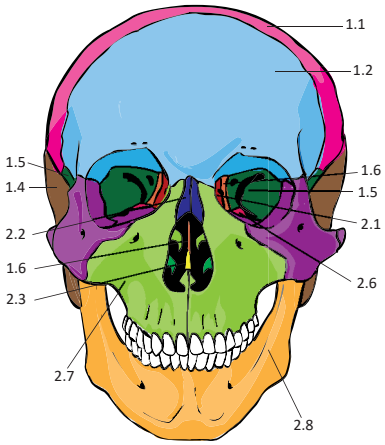

Name the bones of the skull

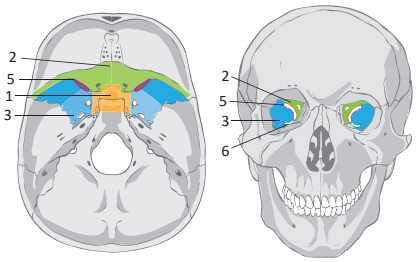

List the parts of the sphenoid bones

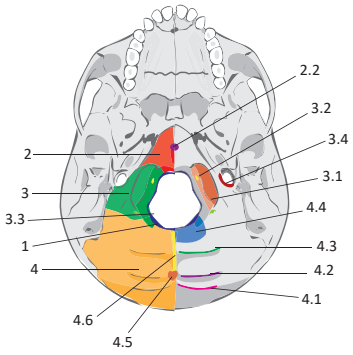

List the parts of the occipital bone

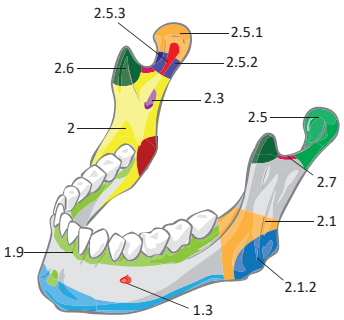

Name the parts of the mandible

IV. Bones of the upper limb

27. Name the ligament that bridges the suprascapular notch and the structures that run above and below this ligament. (p. 43)
28. Name the structure that is located between the greater and lesser tubercles of the humerus. (p. 44)
29. Name the nerve that forms a bony marking on the body of the humerus. (p. 44)
30. List the two articular surfaces of the condyle of the humerus. (p. 45)
31. Give the name of the muscle that inserts on the radial tuberosity. (p. 46)
32. Name the muscle that inserts on the ulnar tuberosity. (p. 45)
33. List three palpable parts of the ulna. (p. 45)
34. Name the bone that is the functional centre of the carpus. (p. 47)
35. List 4 bones that articulate with the lunate (p. 47)
36. List two carpal bones that articulate with the hamate. (p. 47)
37. Describe the difference between the 2nd metacarpal and other metacarpals. (p. 48)

V. Bones of the lower limb

38. List the three bones that form the hip bone. (p. 49)
39. List the 3 parts of the pubis and specify how these parts are connected together. (p. 51)
40. Describe where the intertrochanteric crest and intertrochanteric line can be found and specify their purpose. (p. 52)
41. Explain the term "angle of inclination of the femur". (p. 52)
42. Specify where on the tibia the cruciate ligaments of the knee attach. (p. 53)
43. Specify where the tibial tuberosity can be found and which structure inserts on it. (p. 53)
44. Name the bone that forms the medial malleolus (p. 53)
45. Name the bone that forms the lateral malleolus. (p. 54)
46. List 2 bones that articulate with the medial cuneiform bone. (p. 56)
47. Describe the difference of the 5th metatarsal from the other metatarsals (p. 56)

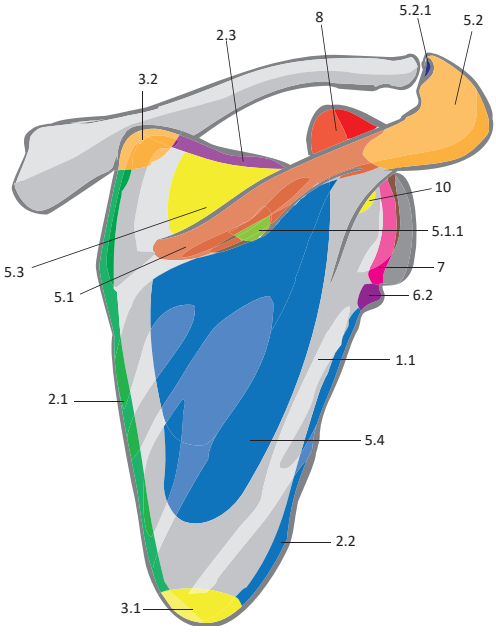

Describe the parts of the scapula

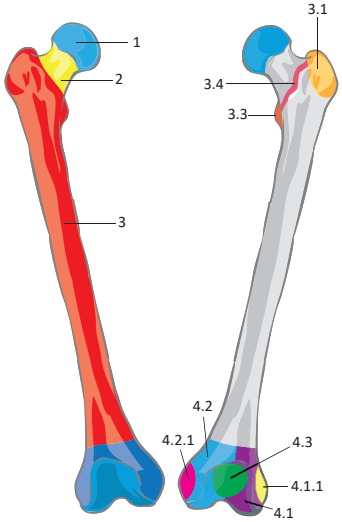

Describe the parts of the femur



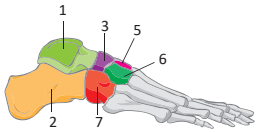

Name the tarsal bones

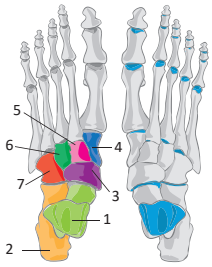

Name the tarsal bones

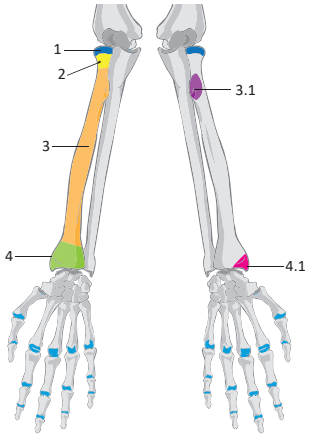

List the parts of the radius

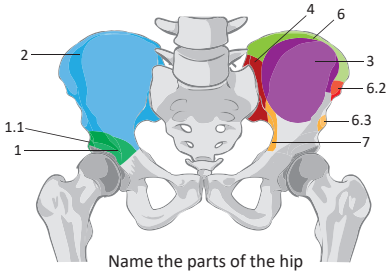

Name the parts of the hip

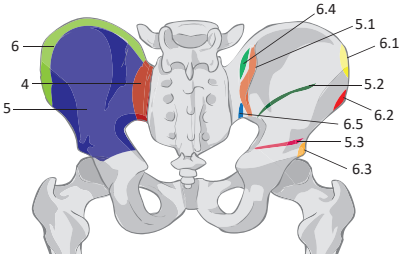

Name the parts of the hip

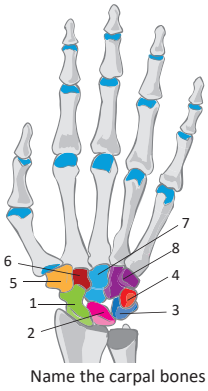

Name the carpal bones

This copy belongs to ali yaghoubi

We would like to **thank the following anatomists, physicians and medical students** for their invaluable help, devotion and feedback in the preparation of this chapter.

Anatomists

Assoc. prof. Václav Báča, MD, PhD – Department of Anatomy, Third Faculty of Medicine, Prague, Czech Republic
Assoc. prof. Adriana Boleková, MD, PhD – Department of Anatomy, Pavol Jozef Šafárik University, Košice, Slovakia
Prof. Guiliana Gobbi – Università di Parma, Anatomia Umana e Antropometria, Italy
Pavel Šnajdr, MD, PhD – Department of Anatomy, First Faculty of Medicine, Prague, Czech Republic
Georg Feigl, Univ.-Ass. OA Priv.-Doz. Dr.med.univ. – Medical University of Graz, Institute of Anatomy, Austria
Petr Hájek, MD, PhD – Department of Anatomy, Charles University, Hradec Králové, Czech Republic

Clinicians

Assoc. prof. Vojtěch Havlas, MD, PhD – Department of Orthopaedics, Second Faculty of Medicine, Charles University in Prague and Motol University Hospital, Czech Republic

Medical students

Lucie Mládenková
Eva Fürstová

10 References

1. AGUR, A. M. R. and A. F. DALLEY. Grant's Atlas of Anatomy. 13th Ed. Philadelphia: Lippincot Williams & Wilkins, 2012, 888 p. ISBN 978-1-60831-756-1.
2. CHUNG, K. W.; CHUNG, H. M. and N. L. HALLIDAY. BRS Gross Anatomy. 8th Ed. Philadelphia: Lippincott Williams & Wilkins, 2015. 544 p. ISBN 978-1-4511-9307-7.
3. LANZ, T. and W. WACHSMUTH. Praktische Anatomie. 7 bands. Berlin: Springer, 2003, 3658 p. ISBN 978-3-540-40571-9.
4. MOORE, K. L.; DALLEY, A. F. and A. AGUR. Clinically oriented anatomy. 7th Ed. Philadelphia: Lippincot Williams & Wilkins, 2014. 1139 p. ISBN 978-1-4511-1945-3.
5. NETTER, F. H. Atlas of Human Anatomy. Professional Edition. 6th Ed. Oxford: Elsevier. 2014. 640 p. ISBN 978-1-455-75888-3.
6. WILLIAMS, P. L., ed. Gray´s Anatomy: the anatomical basis of medicine and surgery. 38th Ed. New York: Churchill Livingstone, 1995, 2092 p. ISBN 0-443-05717-6.

Memorix Anatomy

3 Joints

Martin Čepelík
David Kachlík
Radovan Hudák
Ondřej Volný
Adam Whitley

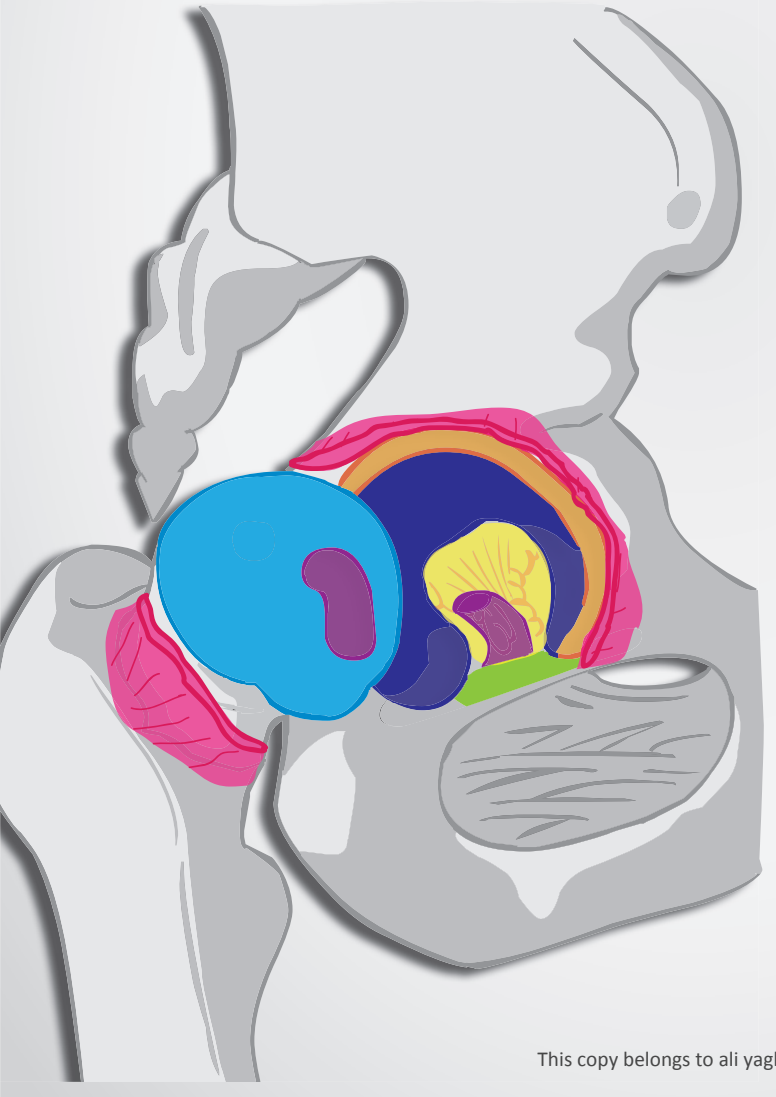

General overview	68
Joints of the skull	72
Vertebral joints	73
Thoracic joints	75
Joints of the upper limb	76
Joints of the lower limb	82
Tables	90
Review questions and figures	94
Acknowledgements and references	96

This copy belongs to ali yaghoubi

Joints are connections between the bones of the skeleton. The two main types of joints are **synarthoses** and **diarthroses (synovial joints)**. In synarthroses, the opposing bone surfaces are connected to each other by connective tissue. The articulating surfaces in diarthroses are separated form each other by a space called the joint cavity.

Joints *(junctures)* – classification

1 **Synarthrosis** – a continuous connection of bones made by connective tissue
- 1.1 **Fibrous joint** – a connection of bones through fibrous connective tissue
  - 1.1.1 **Syndesmosis**
  - 1.1.2 **Membrane** *(membrana)*
  - 1.1.3 **Suture** *(sutura)*
- 1.2 **Cartilaginous joint** *(junctura cartilaginea)* – a connection of bones made by cartilage
  - 1.2.1 **Synchondrosis**
  - 1.2.2 **Symphysis**
- 1.3 **Bony union** *(junctura ossea)*
  - 1.3.1 **Synostosis**

2 **Diarthrosis / synovial joint** *(diarthrosis / articulatio / juncutra synovialis)* – a mobile connection of bones

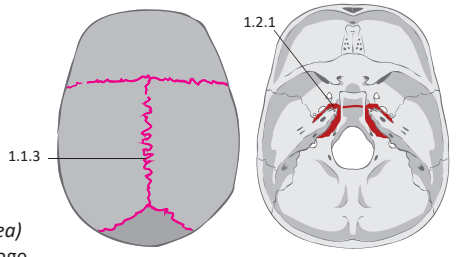

The cranial vault and cranial base viewed from above

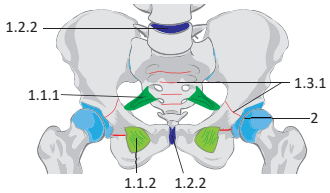

Fibrous joint *(junctura fibrosa)*

1 **Syndesmosis** – a connection of bones through fibrous connective tissue
- 1.1 **Tibiofibular syndesmosis** *(syndesmosis tibiofibularis)*
- 1.2 **Ligament** *(ligamentum)* – a band of fibrous connective tissue connecting one bone to another
  - 1.2.1 **Collagenous fibrous tissue** – makes up most ligaments
  - 1.2.2 **Elastic fibrous tissue** – makes up the ligamenta flava of the vertebral column
- 1.3 **Gomphosis / socket** – the joint between the dental alveolus and tooth root

2 **Membranes** *(membranae)* – flat fibrous sheaths attached to bones
- 2.1 **Interosseous membrane of forearm and leg and obturator membrane** *(membrana interossea antebrachii et cruris et membrana obturatoria)*

3 **Sutures** *(suturae)* – fibrous joints between the bones of the skull
- 3.1 **Serrate suture** *(suturae serrata)* – comprises most sutures of the skull – the articulating surfaces are jagged like a saw and interdigitate with each other
  - 3.1.1 **Limbous suture** *(sutura limbosa)* – a type of serrate suture
    - – the interdigitating processes of the suture overlap each other
    - – found between the frontal and parietal bones
  - 3.1.2 **Denticulate suture** *(sutura denticulata)* – a type of serrate suture
    - – the interdigitating processes of the suture are tooth shaped
    - – located between the two parietal bones
- 3.2 **Squamous suture** (*sutura squamosa)* – found between the temporal and parietal bones
- 3.3 **Plane suture** *(sutura plana)* – found between the horizontal plates of the palatine bones
- 3.4 **Schindylesis** – found between the vomer and sphenoidal rostrum

Cartilaginous joint *(junctura cartilaginea)*

1 **Synchondrosis** – a connection of bones by hyaline cartilage
- 1.1 **Costochondral synchondroses** *(synchondroses costochondrales)* – are located between the ribs and costal cartilages
- 1.2 **Cranial synchondroses** *(synchondroses cranii)* – connections of bones of the cranial base
- 1.3 **Epiphysial plates** *(laminae epiphysiales)* – the growth plates of long bones

2 **Symphysis** – a connection of bones by fibrous cartilage in regions of high pressure
- 2.1 **Pubic symphysis** *(symphysis pubica)* – is located between the bodies of the pubic bones
- 2.2 **Intervertebral discs** *(disci intervertebrales)* – are located between the vertebrae
- 2.3 **Xiphosternal and manubriosternal joint** *(symphysis xiphosternalis et manubriosternalis)*

Bony union *(junctura ossea)*

1 **Synostoses** – connections of bone by bone, develop secondarily to another type of synarthrosis
- 1.1 **(Intra)membranous synostoses** – develop from fibrous joints, occurs in the cranial sutures
- 1.2 **Enchondral synostoses** – develop from cartilaginous joint – occurs in the acetabulum and in all epiphyseal plates

Joints

Arthron is the Greek term for joint.
Arthrology is the study of joints.

Abbreviations of some joints:
SC – sternoclavicular joint
AC – acromioclavicular joint
GH – glenohumeral joint
PIP – proximal interphalangeal joint
DIP – distal interphalangeal joint
SI – sacroiliac joint

The anatomical position is an upright standing position with the upper limbs hanging alongside the body with the palms facing forward. Joints are described in the anatomical position.

It is best to fix joints in the middle position when treating fractures, unless the type of injury needs a special type of fixation.

The blood supply of joints is provided by an arterial plexus (rete articulare).

Innervation of joints is usually provided by the same nerves which innervate the muscles that move the joint.

Arthrodia is an obsolete term a for freely moving ball and socket joint.
Enarthrosis is an obsolete term for cotyloid joint.

Amphiarthroses are slightly movable joints. The articulating surfaces are flat with a degree of incongruity that prevents all but slight sliding movements. The sacroiliac joint and the calcaneo-cuboid joint are examples of amphiarthroses.

Facet joint is a clinical term for a plane joint.

Clinical notes

Osteoarthrosis is a degenerative joint disease that has a predilection for the large weight bearing joints. The most commonly affected joints are the hip (coxarthrosis), knee (gonarthrosis), shoulder (omarthrosis) and vertebral column (spondylarthrosis).

Rheumatoid arthritis is an inflammatory systemic autoimmune disease that can affect any of the joints of the human body. The synovium is primarily affected, but as the disease progresses the cartilage and underlying bone are also damaged. This disease has to be treated by permanent suppression of the immune system.

Joint-play is a passive movement in joints that cannot be performed actively. These are reciprocal shifts of articular surfaces, slight rotations and distractions.

A synovial joint is a **connection between two or more bones** that **allows a significant degree of mobility**. **The articulating surfaces** in synovial joints are **covered by hyaline cartilage** and the joint is covered by an **articular capsule**. Under the capsule and between the two articulating surfaces lies a space called the **joint cavity**, which is filled with synovial fluid.

Synovial joint – description

1 **Type** – synovial joints are classified according to the number of articulating bones and the presence of articular discs or menisci into simple, compound and complex joints
2 **Shape** – is determined by the shape of the articular surfaces, which determines the range and type of movements
3 **Articular surface** *(facies articulares)* – can be flat, convex or concave
3.1 **Articular head** *(caput articulare)* – is convex
3.2 **Articular fossa** *(fossa articularis)* – is concave
4 **Articular capsule** *(capsula articularis)* – is composed of an internal synovial layer that supplies articular surfaces with nutrients and an external fibrous layer that provides mechanical stability to the joint
5 **Ligaments** – are found within the joint, outside the joint or within the articular capsule
– limit movements and stabilise joints
6 **Accessory features** – specialised structures that function to improve the mobility and stability of the joint
– specialised structures that compensate incongruity of articular surfaces, enlarge articular fossa, reduce attrition or prevent impaction of articular capsule
7 **Movements / range of motion** – describes in degrees the extent of a movement in a particular axis of a joint
– 0° indicates a joint in the neutral position
8 **Neutral/middle position** – the position of the joint that has the least tension in the articular capsule

Types of synovial joints

- 1 **Simple joints** *(articulatio simplex)* – an articulation of two bones in the abscence of articular discs and menisci
- 2 **Compound and complex joints**
  - 2.1 **Compound joints** – articulations of more than two bones
    – include the elbow joint
  - 2.2 **Complex joints** – indicates the presence of an articular disc or meniscus
    – include the wrist joint
    – some joints can be both complex and compound

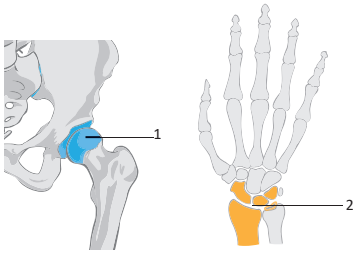

Shapes of synovial joints

1 **Ball-and-socket joint / spheroidal joint** *(articulatio spheroidea)*
– allows rotational movements in three orthogonal axes
– the articular head has a shape of a ball and the articular fossa resembles a socket
- 1.1 **Free** – the surface of the articular fossa is smaller than the surface of the articular head
  –allows a large range of joint motion and is represented by the shoulder joint
- 1.2 **Limited/cotyloid joint** *(articulatio cotylica)* – the surface of the fossa is deeper than the surface of the head
  – allows a limited range of joint motion and is represented by the hip joint

2 **Ellipsoid/condylar joint** *(articulatio ellipsoidea)*
– the articular surfaces are elipse-shaped (biconvex head and biconcave fossa)
– allows rotational movements in the long axis of the joint and lateral sliding movements of the articular head
– includes the wrist joint and the atlanto-occipital joint

3 **Saddle joint** *(articulatio sellaris)* – the articular surfaces resemble a horse rider sitting on a saddle
– allows movements in two planes, includes the carpometacarpal joint of the thumb

4 **Cylindrical joint** *(articulatio cylindrica)* – has the shape of a cylinder
– allows movements in one plane
- 4.1 **Hinge joint** *(ginglymus)* – the axis of movement is perpendicular to the long axis of the bone
  - 4.1.1 **Trochlear joint** *(articulatio trochlearis)* – is cylinder-shaped
    – one articular surface possess a long cylindrical fossa with a ridge perpendicular to its long axis
    – the other articular suface has a small perpendicular indentation in which the ridge articulates
    – movements to the side are restricted by the shape of the joint and by collateral ligaments
    – includes the interphalangeal joints and the humero-ulnar joint
- 4.2 **Pivot joint** *(articulatio trochoidea)* – a pivot-shaped articular surface that rotates in its long axis around a ring-shaped articular surface
  – includes the proximal and distal radio-ulnar joint and the median atlanto-axial joint

5 **Bicondylar joint** *(artiulatio bicondylaris)* – has an articular head with two condyles
– movements are possible in three axes and is represented by the temporomandibular joint

6 **Plane joint** *(articulatio plana)* – has flat articular surfaces, which allow sliding movements
– usually has strong ligaments that limit the extent of joint motion
– includes the acromioclavicular joint, femoropatellar joint and zygapophysial joint

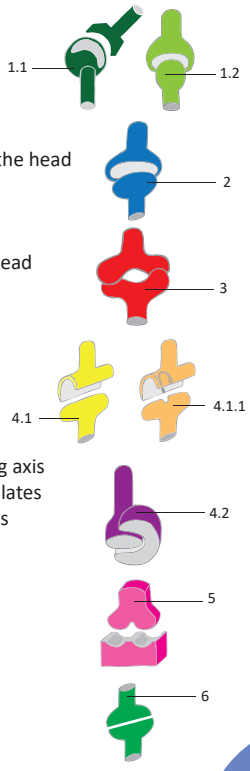

This copy belongs to ali yaghoubi

Articular surfaces *(facies articulares)*

- 1 **Articular head** *(caput articulare)* – is convex
- 2 **Articular fossa** *(fossa articularis)* – is concave
- 3 **Articular surface** *(facies articularis)*
  - – can be divided by grooves and ridges into a number of smaller articular facets

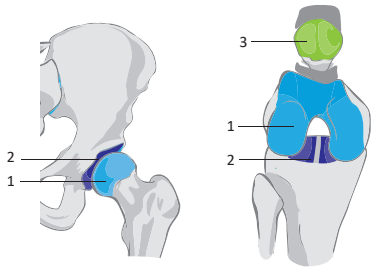

Articular cartilage

- – covers the articular surfaces of joints
- – composed of hyaline carilage in most joints but can be composed of fibrocartilage in joints exposed to great stress, such as the sacro-iliac and sternoclavicular joints

Articular capsule *(capsula articularis)*

- – the articular capsule surrounds the articular cavity
- – it is attached to the circumference of the articular surfaces of the articulating bones
- 1 **Fibrous membrane/layer** *(membrana fibrosa / stratum fibrosum)*
  - – the external layer of the joint capsule
  - – provides mechanical protection to the joint
  - – composed of dense connective tissue
  - – often thickened by articular ligaments
- 2 **Synovial membrane/layer** *(membrana synovialis / stratum synoviale)*
  - – the internal layer of the joint capsule
  - – produces synovial fluid
  - – supplies the joint cartilage with nutrients
  - – composed of a layer of synoviocytes resting on an outer layer of loose connective tissue
  - 2.1 **Synovial fold** *(plica synovialis)*
    - – a fold of the synovial membrane
    - – the surface of the fold is divided into small projections called synovial vili *(villi synoviales)*
  - 2.2 **Articular recess** *(recessus articularis)*
    - – a recesses within the articular cavity lined
- 3 **Articular/joint cavity** *(cavitas articularis)*
  - – a space filled with synovial fluid, located between the articular surfaces and the synovial membrane

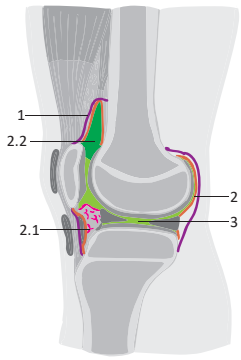

Sagittal section of the knee joint

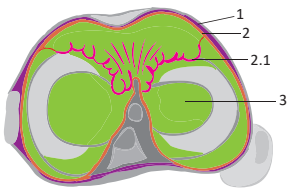

Transverse section of the knee joint

Ligaments

- – ligaments strengthen the articular capsule and stabilise connections between bones
- – they limit the range of joint motion
- 1 **Capsular ligaments** *(ligamenta capsularia)*
  - – part of the fibrous membrane of the articular capsule
  - – include the glenohumeral ligaments of the shoulder joint
- 2 **Intracapsular ligaments** *(ligamenta intracapsularia)*
  - – run inside the joint between the fibrous membrane and the synovial membrane
  - – include the cruciate ligaments of the knee joint
- 3 **Extracapsular ligaments** *(ligamenta extracapsularia)*
  - – run outside the joint
  - – present in all joints in the human body

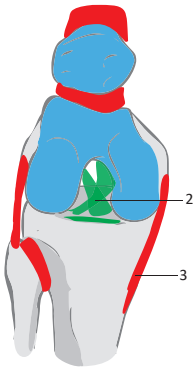

Open knee joint

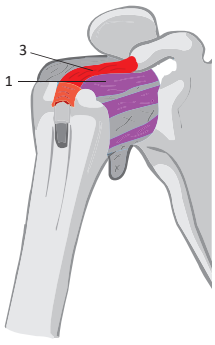

Oblique view of the shoulder joint

Synovial bursae *(bursae synoviales)* are cavities lined with synovium and filled with synovial fluid. They act as cushions to prevent compression of muscles and ligaments in areas of higher stress. Some bursae may communicate with articular cavities although most do not.

Meniscoid folds / meniscoids are prominences of synovial membrane filled with connective tissue. One end is firmly connected to the joint capsule and the other moves freely in the articular cavity. Meniscoid folds cover surface bumps on articular surface to maintain a flat smooth articular surface. Meniscoid folds occur in the zygapophysial joints and the small joints of the hands and feet.

Articular recesses *(recessus articularis)* are synovial membrane-lined pouches extending outwards from the joint capsule. According to some theories, they can cause functional joint restriction.

Synovial fluid *(synovia)* is a translucent yellowish fluid produced by synovial cells *(synoviocyti)*. Synovial fluid enables the articular surfaces to slide smoothly across each other with minimal resistance. It consists of plasma filtrate, hyaluronic acid, leukocytes and macrophages and nourishes the avascular parts of articular cartilage. In large joints, its volume is approximately 2–4 ml.

The tendon of the long head of the biceps brachii, which runs through the shoulder joint is, also an accessory of the joint.

Clinical notes

Joint restriction is a term given to reduced range of motion at a joint. It can have specific causes such as joint mice stuck between the articular surfaces or, in the case of functional joint restriction, have no fully elucidated cause.

Loose bodies / joint mice *(mus intraarticularis)* are small pieces of cartilage or bone that have broken off from the articular surface and are freely moving in the joint cavity. They typically occur in osteoarthritis and osteochondrosis dissecans. Loose bodies can prevent the joint from moving, causing joint restriction.

Bursitis is a term used for painful inflammation of synovial bursa that is not caused by infection nor an autoimunne process. It may originate after long-term overloading, high pressure or after injury. **Purulent bursitis** is a term used for infectious inflammation of synovial bursa.

Accessory features of synovial joints

1 **Discs and menisci** *(disci et menisci)* – are composed of fibrocartilage
– are located in joint cavities between the articular surfaces
– compensate the incongruity of the articular surfaces
- 1.1 **Articular discs** *(discus articularis)* – divide the articular cavity into two parts
  – are found in the sternoclavicular, temporomandibular and radiocarpal joint
- 1.2 **Menisci** *(meniscus articularis)*
  – are crescent-shaped structures that only partially divide the joint cavity
  – are found in the knee joint

- 2 **Labrum** *(labrum articulare)*
  – is composed of fibrocartilage and forms an elevated margin on the articular surface
  – enlarges the articular cavity in the shoulder joint and the hip joint

3 **Fibrocartilage** *(fibrocartilago)* – enlarges the surface of the articular fossa
– is found in metacarpophalangeal, metatarsophalangeal, interphalangeal and talocalcaneonavicular joints

- 4 **Synovial bursae** *(bursae synoviales)* – cavties lined by the synovial membrane and containing synovial fluid
  – may be connected to a joint cavity, but the majority are not
- 5 **Articular muscles** *(musculi articulares)* – small muscles that attach to the articular capsule
  – prevent damage of articular capsule and provide dynamic stabilisation of joints
  – play a significant role in the elbow joint and knee joint
- 6 **Articular fat pads** *(corpora adiposa)* – fill the incongruities of articular surfaces
  – are found in the knee joint, hip joint and elbow joint

7 **Synovial / capsular fold** *(plica synovialis)* – synovial fold of the articular capsule inside the cavity
– is found in the knee and elbow joints

8 **Recess** *(recessus*) – a pouch of the articular cavity, is found e.g. in the knee or elbow joint

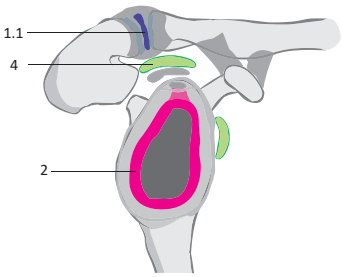

Lateral view of the shoulder joint and coracoacromial ligament

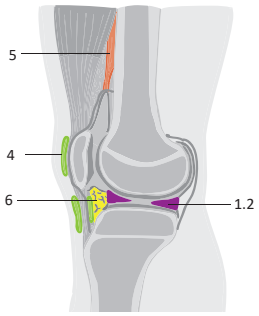

Sagittal section of the knee joint

Movements

Main movements:

- 1 **Flexion and extension** – movements in the sagittal plane around the transvere axis
  - 1.1 **Flexion / ventral flexion** *(flexio)*
  - 1.2 **Extension** *(extensio)*
- 2 **Abduction and adduction**
  – movements in the frontal plane around the sagittale axis
  - 2.1 **Abduction** *(abductio)* – away from the midline
  - 2.2 **Adduction** *(adductio)* – towards the midline
    2.2.1 **Hyperadduction** – movements over the midline to the contralateral side
- 3 **Rotation** – movement around the long (lingitudinal/vertical) axis of the bone
  - 3.1 **External/lateral rotation** *(rotatio externa)*
  - 3.2 **Internal/medial rotation** *(rotatio interna)*

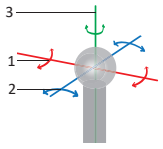

The three orthogonal axes in which rotational movements are possible

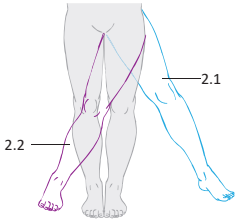

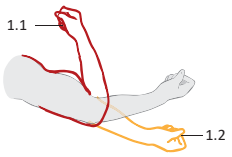

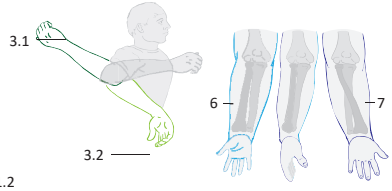

Other movements:

- 4 **Circumduction** *(circumductio)* – a combination of flexion, abduction, extension and adduction
- 5 **Torsion** *(torsio)* – rotational movements of two structures in opposite directions
  – occurs in the vertebral column
- 6 **Supination** *(supinatio)*
  – rotation of the forearm and hand until the hand palm points ventrally
  – the radius and ulna lie parallel to each other in complete supination
- 7 **Pronation** *(pronatio)*
  – rotation of the forearm and hand that results in the palm pointing dorsally
  – the radius crosses over the ulna during pronation
- 8 **Inversion** *(inversio)* – combination of flexion, adduction and supination of the foot
- 9 **Eversion** *(eversio)* – combination of extension, abduction and pronation of the foot
- 10 **Protraction** *(protractio)* – forward movement of the scapula or mandible
- 11 **Retraction** *(retractio)* – backward movement of the scapula or mandible
- 12 **Elevation** *(elevatio)* – upward movement of the scapula or mandible
- 13 **Depression** *(depressio)* – downward movement of the scapula or mandible
- 14 **Lateroflexion** *(lateroflexio)* – flexion of the vertebral column to the side
- 15 **Ulnar duction** *(ductio ulnaris)* – medial flexion of the hand
- 16 **Radial duction** *(ductio radialis)* – lateral flexion of the hand
- 17 **Opposition** *(oppositio)* – movement of the thumb towards the other fingers
- 18 **Reposition** *(repositio)* – movement of the thumb away from the other fingers

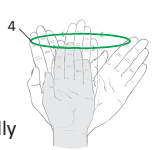



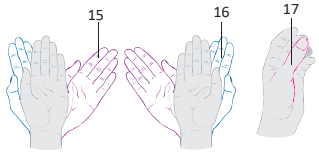

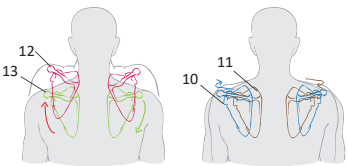

This copy belongs to ali yaghoubi

In the skull, **all the main types of joints are found**. The bones of the cranial vault are connected by **sutures,** which, during course of aging, change to **synostoses**. The majority of the bones of the base of the skull are connected to each other by **synchondroses.** The mandible is connected to the temporal bone by a **synovial joint.**

Synarthroses of the skull

1 **Sutures** – fibrous joints of the cranial vault
– there are 33 sutures in the skull
- 1.1 **Sagittal suture** *(sutura sagittalis)*
- 1.2**Coronal suture** *(sutura coronalis)*
- 1.3 **Lambdoid suture** *(sutura lambdoidea)*
- 1.4 **Squamous suture** *(sutura squamosa)*

2 **Fontanelles** *(fonticuli cranii)* – joints of the skull of a newborn
– soft fibrous tissue that covers gaps between the cranial bones

3 **Ligaments**
- 3.1 **Stylohyoid ligament** *(ligamentum stylohyoideum)*
- 3.2 **Sphenomandibular ligament** *(ligamentum sphenomandibulare)*
- 3.3 **Pterygospinous ligament** *(ligamentum pterygospinale)*
- 3.4 **Pterygomandibular raphe** *(raphe pterygomandibularis)*

4 **Gomphosis** – joints between dental alveoli and the roots of teeth

5 **Synchondroses** – firm continuous connections between bones that are mediated by hyaline cartilage
- 5.1 **Sphenopetrosal synchondrosis** *(synchondrosis sphenopetrosa)*
- 5.2 **Petro-occipital synchondrosis** *(petro-occipital synchondrosis)*
- 5.3 **Spheno-occipital synchondrosis** *(synchondrosis sphenooccipitalis)*
  – closes at the 18th–20th years of life
- 5.4 **Anterior and posterior intra-occipital synchondrosis** *(synchondrosis intraoccipitalis anterior et posterior)*
  – closes at the 4th–7th years of life
- 5.5 **Spheno-ethmoidal synchondrosis** *(synchondrosis sphenoethmoidalis)*
  – closes after the 10th year of life

6 **Synostoses** – direct connection of bones
– occur after closure of the sutures and synchondroses

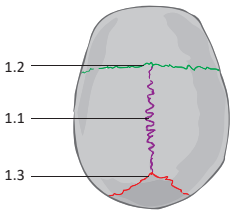

Superior view of the calvaria

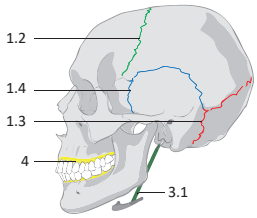

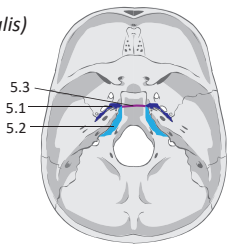

Superior view of the cranial base

Temporomandibular joint *(articulatio temporomandibularis)*

1 **Type:** complex
2 **Shape:** bicondylar
3 **Articular head:** the head of the mandible
4 **Articular fossa:** the mandibular fossa of the temporal bone
5 **Capsule:** loose
6 **Ligaments:**
- 6.1 **Lateral and medial ligaments** *(ligamentum laterale et mediale)*
- 6.2 **Sphenomandibular ligament** *(ligamentum sphenomandibulare)*
- 6.3 **Stylomandibular ligament** *(ligamentum stylomandibulare)*

7 **Accessory features:** articular disc
8 **Movements:**
- 8.1 **Protraction and retraction**
- 8.2 **Depression and elevation**
- 8.3 **Lateropulsion**

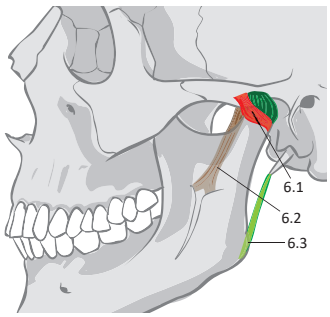

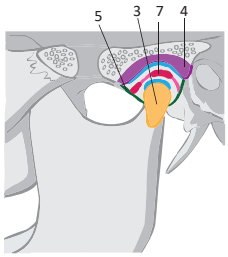

Detail of the joint

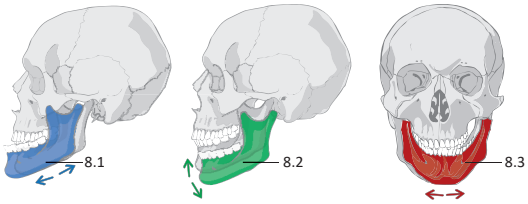

The fibrocartilage of the intervertebral discs absorbs fluid during sleep. During wakefulness, it gradually releases this fluid. Therefore, humans are actually taller in the morning than in the evening. In adults, this difference in height can be as much as 2 cm.

The nucleus pulposus of the intervertebral disc is made of an incompressible fluid and behaves like a ball bearing.

In the majority of the population, the frontal suture fuses by the age of 2. However, 5–8 % of the population have a **persistent frontal suture** *(sutura frontalis persistens, sutura metopica)* separating the two frontal bones. Such individuals may have abnormally shaped foreheads.

Transverse occipital suture and sutura mendosa see page 22.
Fontanelles see page 35.

Lateropulsion and mediopulsion are terms for lateral excursions of the mandible in chewing. **Lateropulsion** is a movement of the mandible to the side. This movement occurs during chewing. The lateral pterygoid muscle working unilaterally produces these movements. **Mediopulsion** is a movement back to the middle position of the joint

Ligamenta interarcualia is an obsolete term for the yellow ligaments *(ligamenta flava).*

Clinical notes

Disorders of the temporomandibular joint cause pain in the temporal region. It is thus important to evaluate the temporomandibular joint in patients with unilateral headache originating in this region.

The lateral pterygoid muscles prevent the articular disc of the temporomandibular joint from becoming displaced and causing joint restriction. It is inserted through the capsule directly into the articular disc.

Spinal disc herniation *(prolapsus disci intervertebralis)* occurs when the anulus fibrosus tears and the nucleus pulposis protrudes through the tear. The herniating disc can impinge the spine nerve roots causing radiculopathy. For more details see the peripheral nervous system chapter.

In the vertebral column, all the main types of joints are found. **Fibrous joints** are represented by the long and short ligaments of the vertebral column. The intervertebral joints are a type of **cartilaginous joint**. The sacral and coccygeal vertebrae fuse together as **synostoses** during development to form the sacraum and coccyx, respectively. **Synovial joints** exist between the superior and inferior articular facets of adjacent vertebrae.

Syndesmoses

1 **Long ligaments**

- 1.1 **Anterior longitudinal ligament** *(ligamentum longitudinale anterius)*
  - – is located on the ventral surface of the vertebral bodies C1 to S1
  - – stabilises and fixates the vertebral column to the vertebral bodies
  - 1.1.1 **Anterior sacrococcygeal ligament** *(ligamentum sacrococcygeum anterius)*
    - – the caudal continuation of the anterior longitudinal ligament
- 1.2 **Posterior longitudinal ligament** *(ligamentum longitudinale posterius)*
  - – is located on the dorsal surface of vertebral bodies inside the vertebral canal
  - – prevents prolapse of intervertebral discs into the vertebral canal
  - 1.2.1 **Deep posterior sacrococcygeal ligament** *(ligamentum sacrococcygeum posterius profundum)*
    - – the caudal continuation of the posterior longitudinal ligament
  - 1.2.2 **Tectorial membrane** *(membrana tectoria)*
    - – the cranial continuation of the posterior longitudinal ligament
    - – runs through the foramen magnum into the skull
    - – covers the dorsal surface of the median atlanto-axial joint
- 1.3 **Superficial posterior sacrococcygeal ligament** *(ligamentum sacrococcygeum posterius superficiale)*
  - – runs from the median sacral crest across the sacral and coccygeal horns to the posterior surface of the coccyx
  - – borders the sacral hiatus

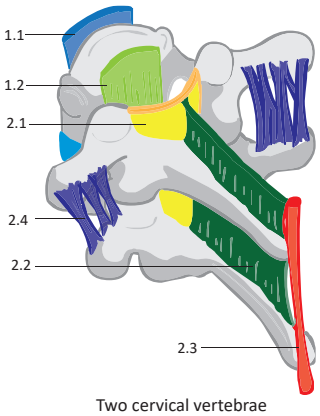

Two cervical vertebrae viewed obliquely from above, behind and left

2 **Short ligaments**

- 2.1 **Ligamenta flava** *(ligamenta flava)* – are composed of elastic connective tissue
  - – run between the vertebral arches
  - – maintain an erect vertebral column
  - – allow passive extension of the vertebral column
- 2.2 **Interspinous ligaments** *(ligamenta interspinalia)*
  - – run in between the spinous processes of adjacent vertebrae
- 2.3 **Supraspinous ligament** *(ligamentum supraspinale)* – connects the tips of the spinous processes of the cervical, thoracic and upper lumbar vertebrae
  - 2.3.1 **Nuchal ligament** *(ligamentum nuchae)*
    - – the cranial continuation of the supraspinous ligaments
    - – runs from the spinous process of C7 to the external occipital protuberance
- 2.4 **Intertransverse ligaments** *(ligamenta intertransversaria)*
  - – are located between the transverse processes of the vertebrae

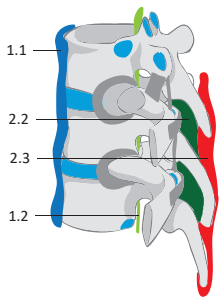

Three thoracic vertebrae viewed from the left

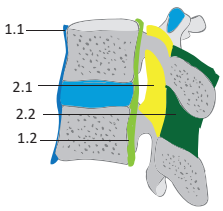

Sagittal section of two lumbar vertebrae

Synchondroses

- 1 **Intervertebral discs** *(disci intervertebrales)* – 23 discs in total
  - – evenly distribute pressure during movements of the vertebral column
  - – are compressed by neighboring vertebrae to allow movements of the spine
  - 1.1 **Anulus fibrosus** *(anulus fibrosus)* – a ring of fibrous cartilage
    - – constitutes most of the mass of the intervertebral disc
  - 1.2 **Nucleus pulposus** *(nucleus pulposus)*
    - – a spherical incompressible gel-like substance located in the middle of the intervertebral disc

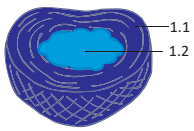

Intervertebral disc

- 2 **Lumbosacral symphysis** *(symphysis lumbosacralis)*
  - – an intervertebral disc located between the vertebra L5 and the sacrum
  - – is supported by the long and short ligaments of the vertebral column
- 3 **Sacrococcygeal symphysis** *(symphysis sacrococcygea)*
  - – an intervertebral disc located between the sacrum and coccyx that ossifies by the 40th year of life
  - – during pregnancy, this joint becomes looser due to the effect of the hormone relaxin
  - – is supported by the anterior, lateral and posterior sacrococcygeal ligaments, which are each divided into superfical and deep parts

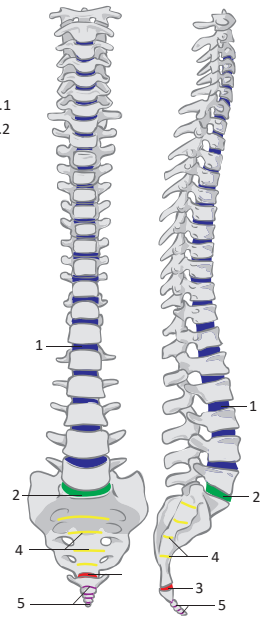

Synostoses

- 4 **Synostoses of the sacrum**
- 5 **Synostoses of the coccyx**

This copy belongs to ali yaghoubi

The zygapophysial joints are synovial joints connecting the superior and inferior articular processes of neighboring vertebrae. **The craniovertebral joints** consist of the joints connecting the occipital bone to the atlas and the joints between the atlas and axis.

Zygapophysial joints *(articulationes zygapophysiales)*

– there are 22 paired zygapophysial joints from the vertebrae C2 to S1
1 **Type:** simple
2 **Shape:** plane
3 **Articular surfaces**: the superior and inferior articular processes of neighboring vertebrae
4 **Capsule:** is attached to the circumferences of the articular surfaces
5 **Ligaments:** long and short ligaments of the vertebral column
6 **Accessory features:**
6.1 **Meniscoid fold**: a fold of the synovial membrane filled with fibrous tissue
7 **Movements:** limited sliding movements

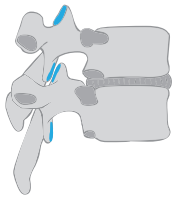

Atlanto-occipital joint *(articulatio atlantooccipitalis)*

– a paired joint between the atlas and occipital bone
1 **Type:** simple
2 **Shape:** ellipsoid
3 **Articular head:** the condyle of the occipital bone
4 **Articular fossa:** the superior articular process of the atlas
5 **Capsule:** is attached to the circumferences of the articular surfaces
6 **Ligaments:** the anterior and posterior altanto-occipital membrane
7 **Movements:** anteflexion, retroflexion and a slight degree of lateral flexion

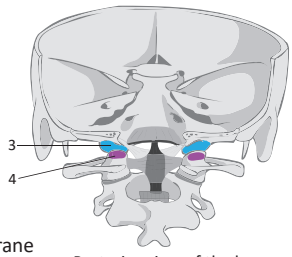

Posterior view of the base of the skull and the first two cervical vertebrae

Median atlanto-axial joint *(articulatio atlantoaxialis mediana)*

– an unpaired joint between the atlas and axis in the midline
1 **Type:** simple
2 **Shape:** pivot
3 **Articular head:** the dens of the axis
4 **Articular fossa:** the facet for the dens on the posterior surface of the anterior arch of the atlas
5 **Ligaments:**
5.1 **Cruciate ligament of atlas** *(ligamentum cruciforme atlantis)*
5.1.1 **Transverse ligament of atlas** *(ligamentum transversum atlantis)*
5.1.2 **Longitudinal bands** *(fasciculi longitudinales)*
5.2 **Alar ligaments** *(ligamenta alaria)*
5.3 **Apical ligament of dens** *(ligamentum apicis dentis)*
5.4 **Tectorial membrane** *(membrana tectoria)*
– covers the dorsal surface of the joint
6 **Movements:** 30° rotation of the atlas around the dens in each direction

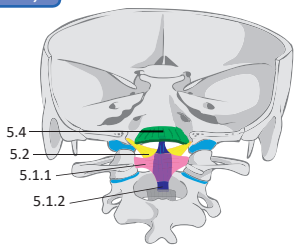

Posterior view of the cranial base and the first two cervical vertebrae

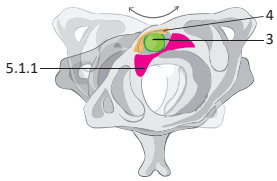

Superior view of rotation of the atlas around the dens

Lateral atlanto-axial joint *(articulatio atlantoaxialis lateralis)*

– paired lateral articulations between the atlas and axis
1 **Type:** simple
2 **Shape:** plane
3 **Head:** the inferior articular facet of the atlas
4 **Cavity:** the superior articular facet of the axis
5 **Movement:** very limited movements in all three axes
– inclination of the atlas

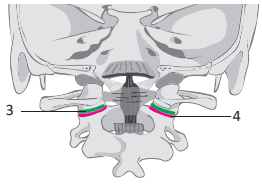

Posterior view of the cranial base and the first two cervical vertebrae

The atlanto-occipital joint allows forward and backward movements of the head, which occur when nodding the head.

The median atlanto-axial joint allows rotatory movements, which occur when shaking the head.

Dorsiflexion is a clinical term for retroflexion of the vertebral column.

The costotransverse foramen *(foramen costotransversarium)* is a space between the neck of the rib and transverse process of the vertebra. It contains the costotransverse ligament.

The radiate sternocostal ligaments extend from the perichondrium of the ribs to the periosteum of the sternum and blend with the fibres from the contralateral radiate sternocostal ligaments, forming the **sternal membrane** *(membrana sterni)*.

The costoxiphoid ligaments *(ligamenta costoxiphoidea)* extend from the sixth and seventh costal cartilages to the xiphoid process of the sternum.

We describe rotational movements of the individual vertebrae. However, when the whole spine rotates this is called torsion. Torsional movements require the vertebral segments to move in opposite directions to each other.

Clinical notes

Costochondritis is inflammation of the costochondral costal cartilages. It is a common cause of chest pain and can mimic acute coronary syndrome.

Rib restriction (restriction of the sternocostal joint) typically causes pain that is worsened by breathing movements.

Movements of the vertebral column

1 **Anteflexion and retroflexion**
- 1.1 **Cervical spine:** 0–50° ventrally and 0–70° dorsally
- 1.2 **Thoracic spine:** minimal, limited by the ribs
- 1.3 **Lumbar spine:** 0–25° ventrally and 0–90° dorsally

2 **Lateroflexion**
- 2.1 **Cervical spine:** 0–45°
- 2.2 **Thoracic spine:** minimal, limited by the ribs
- 2.3 **Lumbar spine:** 0–35°

3 **Rotation** (torsion)
- 3.1 **Cervical spine:** 0–70° (0-30° in the median atlanto-axial joint)
- 3.2 **Thoracic spine:** 0–30°
- 3.3 **Lumbar spine:** 0–10° (provided in the discs)

4 **Spring movements**

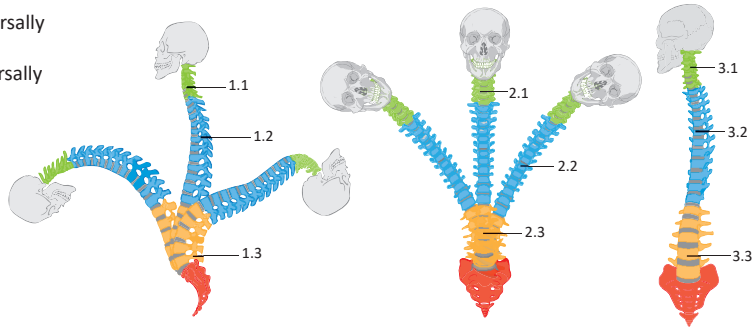

anteflexion – retroflexion lateroflexion torsion

Movements of the ribs expand and contract the thorax, producing the inspiration and expiration movements of breathing. These movements are made possible by the **costovertebral joints**, which connect the ribs to the vertebral column, and by the **sternocostal joints**, which connect the ribs to the sternum. True ribs articulate with the sternum. The ventral ends of false ribs articulate with the rib above via interchondral joints. Floating ribs have no articulation at their ventral ends.

Synarthroses of the thorax

1 **Syndesmoses**
- 1.1 **External intercostal membrane** *(membrana intercostalis externa)*
  – the ventral continuation of the external intercostal muscles
  – is located in the ventral third of the intercostal space
- 1.2 **Internal intercostal membrane** *(membrana intercostalis interna)*
  – the dorsal continuation of the internal intercostal muscles
  – is located in the dorsal third of the intercostal space

2 **Synchondroses**
- 2.1 **Synchondrosis of first rib** *(synchondrosis costae primae)*
  – an articulation between the first rib and the manubrium of the sternum
- 2.2 **Costochondral synchondroses** *(synchondroses costochondrales)*
  – articulations between the ventral ends of the 1st–10th rib and their costal cartilages

3 **Symphyses**
- 3.1 **Manubriosternal joint** *(symphysis manubriosternalis)* – fuses by the 60th year of life
- 3.2 **Xiphosternal joint** *(symphysis xiphosternalis)* – fuses by the 40th–60th year of life

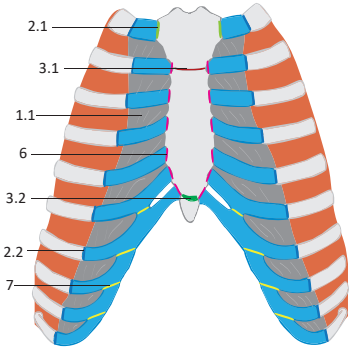

Costovertebral joints *(articulationes costovertebrales)*

- 4 **Joint of head of rib** *(articulatio capitis costae)*
  - 4.1 **Articular head:** the head of the rib which is divided by a small crest into two articular facets
  - 4.2 **Articular fossa:** the superior and inferior costal facets of the vertebral body
  - 4.3 **Ligaments:** the radiate and intra-articular ligaments of the head of the rib *(ligamentum capitis costae intraarticulare et ligamentum capitis costae radiatum)*
- 5 **Costotransverse joint** *(articulatio costotransversaria)*
  - 5.1 **Articular head:** tubercle of rib
  - 5.2 **Articular fossa:** transverse costal facet
  - 5.3 **Ligaments:** superior and lateral costotransverse ligaments *(ligamenum costotransversarium superius et laterale)*

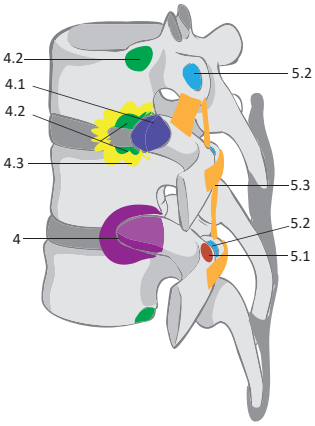

Three thoracic vertebrae viewed from the left

Sternocostal joints *(articulationes sternocostales)*

- 6 **Sternocostal joint** *(articulationes sternocostales)*
  6.1 **Articular head:** cartilage of the 2nd–7th rib
  6.2 **Articular fossa:** costal notches on the sternum for the 2nd–7th rib
  6.3 **Ligaments:** the radiate sternocostal ligaments *(ligamenta sternocostalia radiata)* forming the sternal membrane *(membrana sterni)* and the intra-articular sternocostal ligaments *(ligamenta sternocostalia intraarticularia)*
- 7 **Interchondral joints** *(articulationes interchondrales)* – between the cartilages of the 6th–9th rib

This copy belongs to ali yaghoubi

The vast majority of the joints of the upper limb are **synovial joints**. The radius and ulna, however, are connected to each other by a **fibrous interosseous membrane**.

- 1 **Sternoclavicular joint** *(articulatio sternoclavicularis)*
- 2 **Acromioclavicular joint** *(articulatio acromioclavicularis)*
- 3 **Glenohumeral joint / shoulder joint** *(articulatio humeri/glenohumeralis)*
- 4 **Elbow join** *(articulatio cubiti)*
- 5 **Radio-ulnar syndesmosis** *(syndesmosis radioulnaris)*
- 6 **Distal radio-ulnar joint** *(articulatio radioulnaris distalis)*
- 7 **Wrist joint** *(articulatio radiocarpalis)*
- 8 **Joints of hand** *(articulationes manus)*

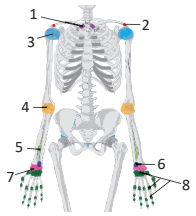

5.1 Sternoclavicular joint – Articulatio sternoclavicularis

The sternoclavicular joint is a **complex joint** that allows only **very limited movements**. It cooperates with the other joints of the pectoral girdle.

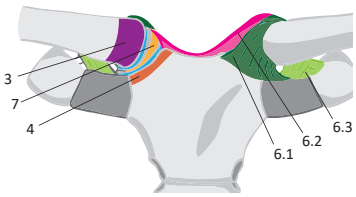

1 **Type:** complex
2 **Shape:** ball-and-socket
- 3 **Articular head:** the sternal facet of the clavicle
- 4 **Articular fossa:** the clavicular notch on the sternum

5 **Capsule:** is attached to the circumferences of the articular surfaces
6 **Ligaments:**
- 6.1 **Anterior and posterior sternoclavicular ligament** *(ligamentum sternoclaviculare anterius et posterius)*
  – are connected to the capsule ventrally and dorsally, respectively
- 6.2 **Interclavicular ligament** *(ligamentum interclaviculare)*
  – dorsally interconnects the two clavicles
- 6.3 **Costoclavicular ligament** *(ligamentum costoclaviculare)*
  – connects the clavicle to the cartilage of the first rib

- 7 **Accessory features:** articular disc

8 **Movements:** very limited in all directions

5.2 Acromioclavicular joint – Articulatio acromioclavicularis

The acromioclavicular joint is a **simple plane joint** that allows only a **limited degree of movement**. It variably contains an articular disc. It cooperates with the other joints of the pectoral girdle in producing movements of the upper limb.

1 **Type:** simple
2 **Shape:** plane
3 **Articular surfaces:**
- 3.1 **Clavicular facet of the acromion** *(facies articularis clavicularis acromii)*
- 3.2 **Acromial facet of the clavicle** *(facies articularis acromialis claviculae)*

- 4 **Capsule:** firm, attached to the circumference of articular surfaces

5 **Accessories:** an articular disc is present in 50 % of the population
6 **Ligaments:**
- 6.1 **Acromioclavicular ligament** *(ligamentum acromioclaviculare)*
  – strengthens the cranial part of the joint
- 6.2 **Coraco-acromial ligament** *(ligamentum coracoacromiale)*
  – limits abduction of the arm above 90°
- 6.3 **Coracoclavicular ligament** *(ligamentum coracoclaviculare)*
  – limits movements of the scapula, composed of two parts
  - 6.3.1 **Trapezoid ligament** *(ligamentum trapezoideum)*
  - 6.3.2 **Conoid ligament** *(ligamentum conoideum)*

7 **Movements**: very limited in all directions

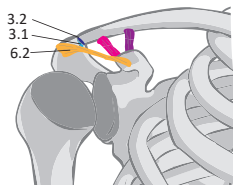

Anterior view of the right shoulder

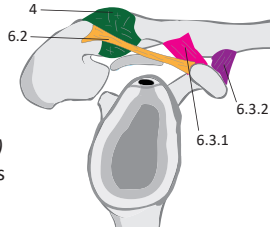

Lateral view of the right shoulder

Fornix humeri is a fibrous arch above the shoulder joint shaped by the coracoacromial ligament. Abduction of the arm greater than 90° is limited by the greater tubercle coming into contact with the fornix humeri. The arm can only be abducted further by concomitant external rotation of the scapula.

The shoulder is a collective term for:
1 The glenohumeral joint
2 The acromioclavicular joint
3 The sternoclavicular joint
4 The functional connection between the scapula and thorax ("scapulothoracic joint")
Movements of the shoulder are facilitated by movements at these four connections.

The foramen of Weitbrecht *(foramen ovale Weitbrechti)* is one of two weak spots in the glenohumeral joint capsule, located between the superior and middle glenohumeral ligaments.

The blood supply of the shoulder joint is provided mainly by the posterior humeral circumflex artery.
The innervation of the shoulder joint is provided by the suprascapular nerve**.**

Neutral position of the sternoclavicular and acromioclavicular joint corresponds to the anatomical position.

Clinical notes

Violent impacts transferred from the upper limb lead more often to a fracture of the clavicle than to a dislocation of the sternoclavicular joint, because of firmness of the articular capsule and ligaments.

Due to its small articular fossa and large articular head, the shoulder joint is **frequently dislocated**. An anterior inferior shoulder dislocation is the most frequent type of shoulder dislocation, occuring in more than 90 % of cases.

Shoulder impingement syndrome is inflammation of the tendons of the rotator cuff muscles typically caused by overuse of these muscles. The inflammated tendons swell up and movements of the shoulder become painful.

A **SLAP lesion** *(superior labral tear from anterior to posterior)* is an injury to the glenoid labrum, characterised by a tear of the uppermost part of the labrum adjacent to the insertion of the long head of the biceps brachii.

The shoulder joint is a ball-and-socket joint with the greatest **extent of movement** of all the joints of the human body. It allows **movements in all three planes**. The incongruity between the shallow **articular fossa** and the large articular head inflicts great instability on the joint. This is compensated by the **rotator cuff muscle**s which attach to the head of the humerus and hold it firmly in the articular fossa of the scapula.

1 **Type:** simple
2 **Shape:** ball-and-socket
3 **Articular head:** the head of the humerus
4 **Articular fossa:** the glenoid cavity of the scapula
5 **Capsule:** attaches to the neck of the scapula and the anatomical neck of the humerus
- 5.1 **Axillary recess** *(recessus axillaris)*
  – the caudal recess of the articular capsule
- 5.2 **Intertubercular synovial sheath** *(vagina synovialis intertubercularis)*
  – the synovial sheath of the tendon of the long head of the biceps brachii

6 **Ligaments:**
- 6.1 **Coracohumeral ligament** *(ligamentum coracohumerale)* – runs from the coracoid process of the scapula to the greater tubercle of the humerus
- 6.2 **Glenohumeral ligaments** *(ligamenta glenohumeralia)* – three capsular ligaments
  – run through the fibrous layer of the articular capsule
  - 6.2.1 **Superior glenohumeral ligament** *(ligamentum glenohumerale superius)*
  - 6.2.2 **Middle glenohumeral ligament** *(ligamentum glenohumerale medium)*
  - 6.2.3 **Inferior glenohumeral ligament** *(ligamentum glenohumerale inferius)*
- 6.3 **Coraco-acromial ligament** *(ligamentum coracoacromiale)*
  – lies above the joint between the coracoid process and acromion
- 6.4 **Transverse humeral ligament** *(ligamentum transversum humeri)*
  – runs over the greater and lesser tubercle of the humerus
  – bridges the intertubercular sulcus, holding the tendon of the long head of the biceps brachii firmly in place

7 **Accessory features:**

Inside the articular capsule:
- 7.1 **Glenoid labrum** *(labrum glenoidale)* – a cartilaginous margin that enlarges the articular cavity
- 7.2 **Tendon of long head of biceps brachii** *(tendo capitis longi musculi bicipitis brachii)*
  – originates on the supraglenoid tubercle near the glenoid labrum and runs between the fibrous and synovial layers of the articular capsule

Outside the articular capsule:
- 7.3 **Subdeltoid bursa** *(bursa subdeltoidea)* – is located under the deltoid
- 7.4 **Subacromial bursa** *(bursa subacromialis)* – is located under the acromion
- 7.5 **Subtendinous bursa of subscapularis** *(bursa subtendinea musculi subscapularis)*

8 **Movements:** large range of joint motion in all three planes
- 8.1 **Ventral flexion:** 0–90°, with concomitant external rotation of the inferior angle of the scapula up to 180°
- 8.2 **Dorsiflexion (extension):** 0–50°
- 8.3 **Abduction**: 0–90°, with concomitant external rotation of the inferior angle of the scapula up to 180°
- 8.4 **Adduction** (hyperadduction): 0–75°
- 8.5 **External rotation:** 0–90°
- 8.6 **Internal rotation:** 0–90°

9 **Neutral position**: mild flexion and 45°of abduction

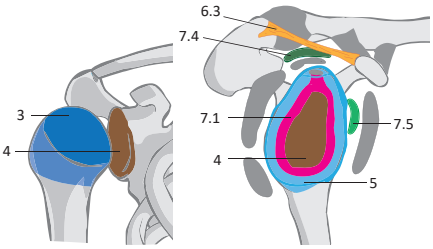

Anterior view of the right shoulder

Lateral view of the right shoulder

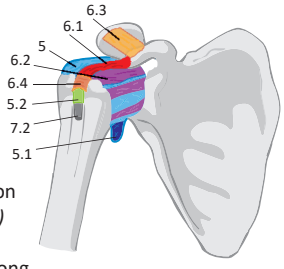

Anterior view of the right shoulder

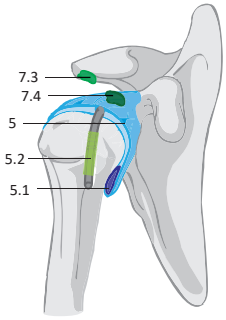

Left oblique view of the right shoulder with the joint capsule partialy opened

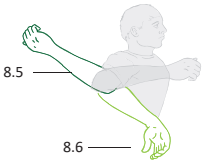

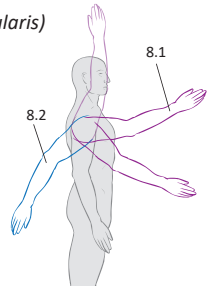

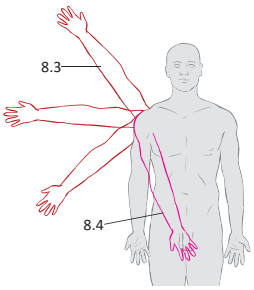

Rotator cuff

– the rotator cuff is a group of four muscles that attach to the greater and lesser tubercle of the humerus
– they stabilise the shoulder joint and aid in its rotation
- 1 **Supraspinatus** *(musculus supraspinatus)*
  – inserts on the superior facet of the greater tubercle
- 2 **Infraspinatus** *(musculus infraspinatus)*
  – inserts on the middle facet of the greater tubercle
- 3 **Teres minor** *(musculus teres minor)*
  – inserts on the inferior facet of the greater tubercle
- 4 **Subscapularis** *(musculus subscapularis)* – inserts on the lesser tubercle

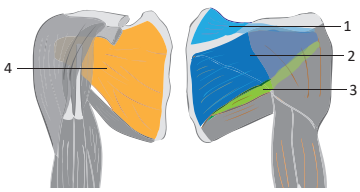

Anterior and posterior views of the muscles attaching to the scapula

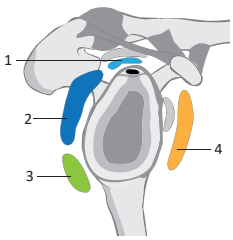

Lateral view of the right shoulder

This copy belongs to ali yaghoubi

The elbow joint is a compound synovial joint made up of **three bones articulating in three separate simple joints**. It is a **biaxial joint** that allows flexion and extension and, in cooperation with the distal radio-ulnar joint, pronation and supination.

Joints comprising the elbow joint

- 1 **Humero-ulnar joint** *(articulatio humeroulnaris)*
  - 1.1 **Shape:** trochlear
  - 1.2 **Articular head:** the trochlea of the humerus
  - 1.3 **Articular fossa:** the trochlear notch of the ulna
- 2 **Humeroradial joint** *(articulatio humeroradialis)*
  - 2.1 **Shape:** ball-and-socket
  - 2.2 **Articular head:** the capitullum of the humerus
  - 2.3 **Articular fossa:** the articular facet of the head of the radius
- 3 **Proximal radio-ulnar joint** *(articulatio radioulnaris proximalis)*
  - 3.1 **Shape:** pivot
  - 3.2 **Articular head:** the articular circumference of the head of the radius
  - 3.3 **Articular fossa:** the radial notch of the ulna

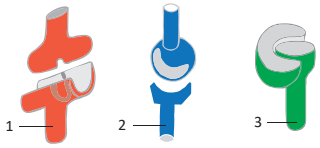

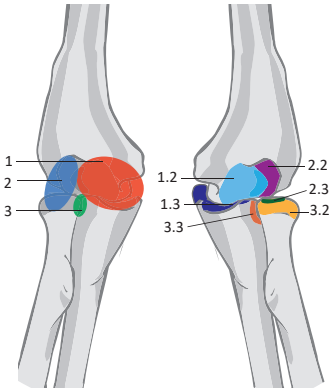

Anterior view of the right and left elbow

Common parts of the elbow joint

- 4 **Capsule:** attaches to the humerus inferior to the epicondyles, to the neck of the radius and to the ulna on the borders of its articular surface
  - 4.1 **Sacciform recess** *(recessus sacciformis)*
    - – a pouch within the articular capsule located over the neck of the radius

5 **Ligaments:**

- 5.1 **Ulnar collateral ligament** *(ligamentum collaterale ulnare)*
  - – a triangular ligament on the medial side of the elbow
- 5.2 **Radial collateral ligament** *(ligamentum collaterale radiale)*
  - – is located on the lateral side of the elbow
- 5.3 **Annular ligament of radius** *(ligamentum anulare radii)*
  - – attaches to the ulna
  - – encircles the head of the radius

6 **Accessory features:**

- 6.1 **Subtendinous bursa of triceps brachii** *(bursa subtendinea musculi tricipitis brachii)*
  - – in the place of the olecranon

7 **Movements:**

- 7.1 **Flexion**: 0–145°
- 7.2 **Extension:** 0–5° hyperextension up to 10° is physiological in females due to a smaller sized olecranon
- 7.3 **Pronation**: 0–90°
  - – the radius is crossed over the ulna
- 7.4 **Supination**: 0– 90°
  - – the radius and ulna are parallel

8 **Neutral position:** is in mild flexion and pronation

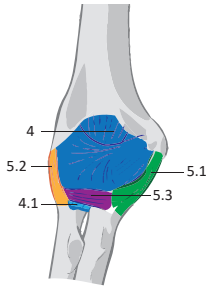

Anterior view of the right elbow

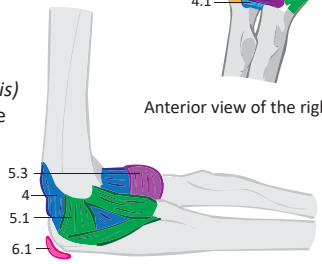

Medial side of the left elbow joint

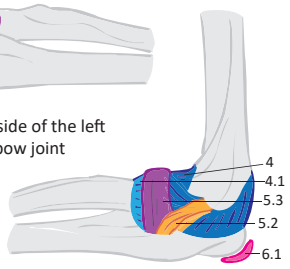

Lateral side of the left ulnar joint

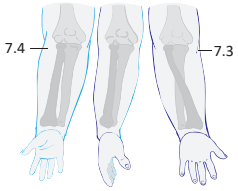

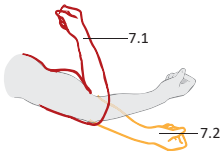

The triangular fibrocartilage complex (TFCC) is a clinical term used for the articular disc of the wrist joint and its associated ligaments, comprising the palmar and dorsal radioulnar ligaments and ulnocarpal ligaments (ulnolunate and ulnotriquetral ligaments). It separates the head of the ulna from the proximal row of the carpal bones. From the distal side, the disc looks like an isosceles triangle with the base adjacent to the ulnar notch of the radius and the apex at the styloid process of the ulna. The legs of the triangle grow together with the joint capsule of the distal radioulnar joint and form the palmar and dorsal radioulnar ligament, which help to stabilise the carpal bones.

The ulnar collateral ligament consists of three ligaments, which form a triangle:

- – the humerocoronoid ligament *(lig. humerocoronoideum)*
- – the olecranohumeral ligament *(lig. olecranohumerale)*
- – the oblique ligament *(lig. obliquum)*

The posterior interosseous vessels *(vasa interossea posteriora)* pass through an opening between fibres of the oblique cord and the interosseous membrane to enter the dorsal compartment of the forearm.

Clinical notes

The anular ligament of the radius is not fully developed in children until the age of 5 to 6. Under weight of the forearm, a subluxation of the humeroradial joint can occur. This condition is termed painful pronation *(pronatio dolorosa)*.

The proximal and distal radio-ulnar joints form a **functional unit** that **makes pronation and supination movements** of the forearm possible. The bones of the forearm are united by a **syndesmosis**, which has two components: the proximal narrow **oblique cord** and the distal widened **interosseous membrane of the forearm**.

Distal radio-ulnar joint *(articulatio radioulnaris distalis)*

1 **Type:** simple
2 **Shape:** pivot
3 **Articular head:** the articular circumference of the head of the ulna
4 **Articular fossa:** the ulnar notch of the radius
5 **Capsule:** attached to the circumference of articular surfaces
6 **Movements:** are combined with movements of the proximal radio-ulnar joint
- 6.1 **Pronation:** 0–90°
  the radius crosses over ulna
  the palm is turned to face dorsally
- 6.2 **Supination:** 0–90°
  the radius moves so that it lies parallel to the ulna
  the palm is turned to face ventrally

7 **Neutral position:** is mild pronation

Radio-ulnar syndesmosis *(syndesmosis radioulnaris)*

8 **Interosseous membrane of forearm** *(membrana interossea antebrachii)*
– is composed of fibers that run mediodistally from the radius to the ulna
9 **Oblique cord** *(chorda obliqua)*
– a narrow band of fibers running laterodistally from the ulna to the radius

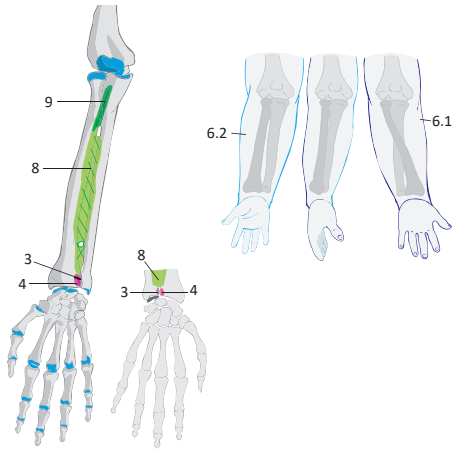

Anterior and posterior view of the right forearm and hand

5.6 Wrist joint – Articulatio radiocarpalis

Composed of **four articulating bones and containing an articular disc**, the **ellipsoid shaped wrist joint** is classified as being both **complex and compound**. Allows movements in two planes, both separately and simultaneously.

1 **Type:** both complex and compound
2 **Shape:** ellipsoid
3 **Articular head:**
- 3.1 **Scaphoid**
- 3.2 **Lunate**
- 3.3 **Triquetrum**

4 **Articular fossa:** the carpal articular surface of the radius and the articular disc
5 **Capsule:** is loose and allows a wide range of movements
6 **Accessory features:** an articular disc, which forms the medial part of the articular fossa and articulates with the ulna (the ulna does not directly articulate with the carpal bones)
7 **Ligaments:**
- 7.1 **Radiate carpal ligament** *(ligamentum carpi radiatum)*
- 7.2 **Palmar and dorsal radiocarpal ligament** *(ligamentum radiocarpale palmare et dorsale)*
- 7.3 **Palmar and dorsal ulnocarpal ligament** *(ligamentum ulnocarpale palmare et dorsale)*
- 7.4 **Ulnar and radial collateral ligament of the wrist joint** *(ligamentum collaterale carpi ulnare et radiale)* – are weak ligaments

8 **Movements:**
- 8.1 **Palmar flexion:** 0–80°
- 8.2 **Dorsiflexion:** 0–85°
- 8.3 **Ulnar duction:** 0–45°
- 8.4 **Radial duction:** 0–15°

9 **Neutral position** – is in the direction of the long axis of the forearm

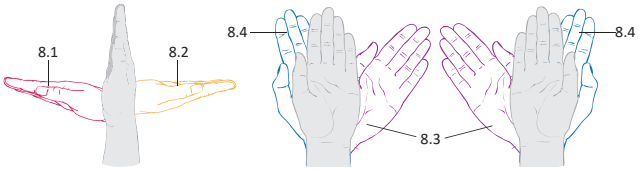

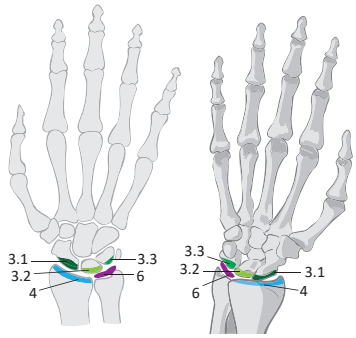

Anterior view of the left and right hand

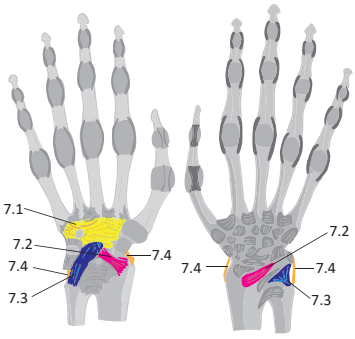

Anterior and posterior views of the right hand

This copy belongs to ali yaghoubi

The joints of the hand are a **group of joints** that work together to make complex hand movements possible.

Joints of the hand

- 1 **Wrist joint** *(articulatio radiocarpalis)*
- 2 **Midcarpal joint** *(articulatio mediocarpalis)*
- 3 **Intercarpal joints** *(articulationes intercarpales)*
- 4 **Carpometacarpal joints** *(articulationes carpometacarpales)*
- 5 **Carpometacarpal joint of thumb** *(articulatio carpometacarpalis pollicis)*
- 6 **Intermetacarpal joints** *(articulationes intermetacarpales)*
- 7 **Metacarpophalangeal joints** *(articulationes metacarpophalangeae)*
- 8 **Proximal interphalangeal joints** *(articulationes interphalangeae proximales)*
- 9 **Distal interphalangeal joints** *(articulationes interphalangeae distales)*

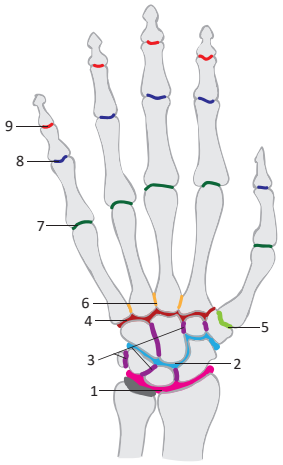

Anterior view of the right hand

Proximal joints of the hand

1 **Midcarpal joint** *(articulatio mediocarpalis)*
- 1.1 **Type:** compound
- 1.2 **Shape:** of the letter S
- 1.3 **Articular head:**
  medially: capitate and hamate
  laterally: scaphoid
- 1.4 **Articular fossa:**
  medially: scaphoid, lunate and triquetrum
  laterally: trapezium and trapezoid

2 **Intercarpal joints** *(articulationes intercarpales)*
– joints in between the individual carpal bones

3 **Carpometacarpal joints** *(articulationes carpometacarpales)*
- 3.1 **Type:** compound
- 3.2 **Shape:** plane
- 3.3 **Articular head:** the distal line of the carpal bones
- 3.4 **Articular fossa:** the base of the 2nd–5th metacarpal bones

4 **Carpometacarpal joint of thumb** *(articulatio carpometacarpalis pollicis)*
- 4.1 **Shape:** saddle
- 4.2 **Head:** the base of the 1st metacarpal bone
- 4.3 **Cavity:** trapezium
- 4.4 **Movements:**
  - 4.4.1 **Flexion**: 0–45°
  - 4.4.2 **Extension**: 0–15°
  - 4.4.3 **Abduction:** 70°
  - 4.4.4 **Adduction**
  - 4.4.5 **Opposition**
  - 4.4.6 **Reposition**

5 **Intermetacarpal joints** *(articulationes intermetacarpales)*
– joints between the adjacent surface of the bases of the 2nd–5th metacarpal bones

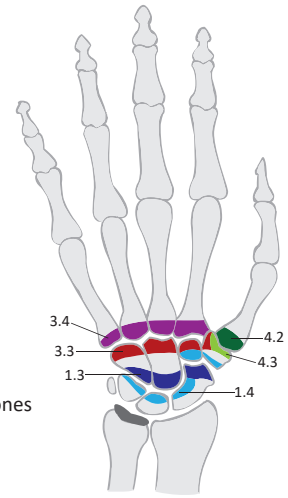

Anterior view of the right hand

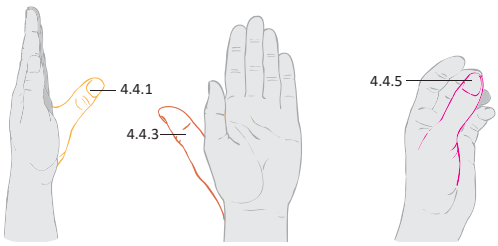

Some of the carpal ligaments on the palmar side of hand form bands in a shape of the letter V. Between them, there is a weak spot called the space of Poirier. The lunate bone can luxate through this space. The proximal part of the V band is formed by the radiotriquetral and ulnotriquetral ligament. The distal part of the V band is formed by the radiocapital and capitaltriquetral ligament.
Similar bands are found on the dorsum of the hand. These are the **radiotriquetral ligament**, which crosses the lunate bone and the smaller **triquetroscaphoid ligament.**

The transverse carpal ligament *(ligamentum carpi transversum)* is an obsolete term for flexor retinaculum.

The pisiform joint *(articulatio ossis pisiformis)* is a simple flat rigid joint. Its articular head is formed by the triquetrum and its socket by the pisiform. Ligaments stabilising the joint are the pisohamate and pisometacarpal ligament.

Palmar fibrocartilage *(fibrocartilago palmaris)* enlarges the articular fossa of metacarpophalangeal and interphalangeal joints. It is responsible for strenghtening the articular capsule from the palmar side. Palmar fibrocartilage is located inside the **palmar ligaments** *(ligamenta palmaria).*

Clinical notes

Bouchard's nodes are fusiform swellings of the metacarpophalangeal and proximal interphalangeal joints that occur in rheumatoid arthritis. The distal interphalangeal joints are not usually affected by this process. Larger joints are usually affected in the later phase of the disease

Heberden's nodes are thickenings of the distal interphalangeal joints caused by the development of bone spurs (osteophytes). These joint deformations are typical signs of osteoarthrosis.

Joints of the hand as a group

1 **Ligaments:** attach to all the bones that they pass
- 1.1 **Collateral ligaments of wrist joint** *(ligamenta collateralia carpi)*
  – weak ligaments that run on both sides of the wrist joint
- 1.2 **Palmar and dorsal ulnocarpal ligaments**
  (ligamentum ulnocarpale palmare et dorsale)
  – run from the ulna to the carpal bones
- 1.3 **Palmar and dorsal radiocarpal ligament**
  (ligamentum radiocarpale palmare et dorsale)
  – run from the radius to the carpal bones
- 1.4 **Radiate carpal ligament** *(ligamentum carpi radiatum)*
  – radiates outward from the palmar side of the capitate
- 1.5 **Interosseous intercarpal ligaments** *(ligamenta intercarpalia interossea)*
- 1.6 **Palmar and dorsal carpometacarpal ligaments**
  (ligamenta carpometacarpalia palmaria et dorsalia)
- 1.7 **Dorsal, palmar and interosseous metacarpal ligaments**
  (ligamenta metacarpalia palmaria, dorsalia et interossea)
  - 1.7.1 **Deep transverse metacarpal ligament**
    (ligamentum metacarpale transversum profundum)
  - 1.7.2 **Medial and lateral collateral ligament**
    (ligamentum collaterale mediale et laterale)
- 1.8 **Flexor retinaculum** *(retinaculum musculorum flexorum)*
  – a strong ligament stretched between the radial and ulnar carpal eminences
  – forms the roof of the carpal tunnel

2 **Movements:** very limited

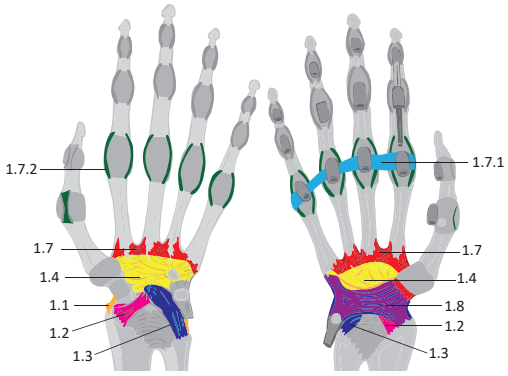

Anterior view of the left and right hands

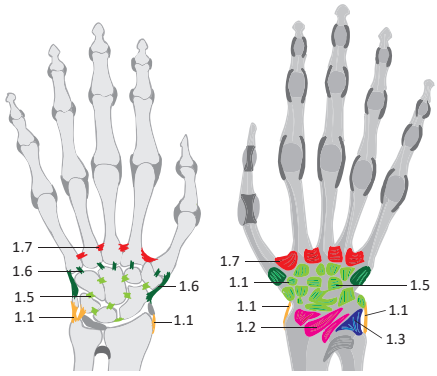

Right hand, viewed from the front and back

Joints of the fingers

1 **Metacarpophalangeal joint** *(articulatio metacarpophalangea)*
- 1.1 **Type:** simple
- 1.2 **Shape:** the palmar side of the joint is cylindrical-shaped but the dorsal side resembles a ball-and-socket joint (functionally ellipsoid joints)
- 1.3 **Articular head:** the head of the metacarpal
- 1.4 **Articular fossa:** the base of the proximal phalanx
- 1.5 **Ligaments:**
  - 1.5.1 **Medial and lateral collateral ligament**
    (ligamentum collaterale mediale et laterale)
  - 1.5.2 **Palmar ligaments** *(ligamenta palmaria)*
  - 1.5.3 **Deep transverse metacarpal ligament**
    (ligamentum metacarpale transversum profundum)
- 1.6 **Accessory features:**
  - 1.6.1 **Palmar fibrocartilage** *(fibrocartilago palmaris)*
- 1.7 **Movements:**
  - 1.7.1 **Flexion:** 90°
  - 1.7.2 **Extension:** 0–20°
  - 1.7.3 **Radial and ulnar duction** is possible only in extended joints
    – abduction away from the 3rd finger: 25–40°
    – adduction to wards the 3rd finger: 0–5°
  - 1.7.5 **Passive rotations:**
- 1.8 **Neutral position:** 45° of flexion of the fingers

2 **Proximal and distal interphalangeal joints**
(articulationes interphalangeae proximales et distales)
- 2.1 **Type**: simple, mobile
- 2.2 **Shape:** trochlear
- 2.3 **Head:** the head of the proximal and middle phalanges
- 2.4 **Cavity:** the base of the middle and distal phalanges
- 2.5 **Ligaments:**
  - 2.5.1 **Medial and lateral collateral ligament**
    (ligamentum collaterale mediale et laterale)
  - 2.5.2 **Palmar ligaments** *(ligamenta palmaria)*
- 2.6 **Accessories:**
  - 2.6.1 **Palmar fibrocartilage** *(fibrocartilago palmaris)*
- 2.7 **Movements:** flexion and extension from 70 to 100°
- 2.8 **Neutral position:** half the way to maximal flexion

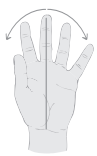
Opening of fingers
– abduction from the 3rd finger


Closing of fingers
– adduction to the 3rd finger


Extension in the metacarpophalangeal and interphalangeal joints


Flexion in the metacarpophalangeal joints and extension in the interphalangeal joints


Extension in the metacarpophalangeal joints and flexion in the proximal and distal interphalangeal joints


Flexion in the metacarpophalangeal and interphalangeal joints

This copy belongs to ali yaghoubi

The bones of the lower limb are connected predominantly by synovial joints. The bones of the leg, however, are connected to each other by an **interosseous membrane and the tibiofibular syndesmosis**.

- 1 **Sacro-iliac joint** *(articulatio sacroiliaca)*
- 2 **Synarthroses of pelvic girdle** *(synarthroses cinguli pelvici)*
- 3 **Hip joint** *(articulatio coxae)*
- 4 **Knee joint** *(articulatio genus)*
- 5 **Tibiofibular joint / superior tibiofibular joint** *(articulatio tibiofibularis)*
- 6 **Interosseous membrane of leg and tibiofibular syndesmosis / inferior tibiofibular joint** *(membrana interossea cruris et syndesmosis tibiofibularis)*
- 7 **Ankle joint** *(articulatio talocruralis)*
- 8 **Joints of foot** *(articulationes pedis)*

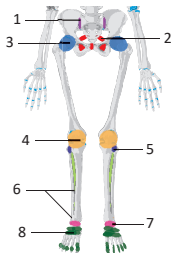

6.1 Sacro-iliac joint – Articulatio sacroiliaca

The sacroiliac joint is an amphiarthrosis between the sacrum and ilium that allows only very limited movements. It establishes the **angle of inclination of the pelvis** and transmits force between the pelvis and vertebral column.

1 **Type:** simple
2 **Shape:** plane
3 **Articular surfaces:**
- 3.1 **Auricular surface of sacrum** *(facies auricularis ossis sacri)*
- 3.2 **Auricular surface of ilium** *(facies auricularis ossis ilii)*

4 **Capsule:** short and firm
5 **Ligaments:**
- 5.1 **Anterior, posterior and interosseous sacro-iliac ligament** *(ligamentum sacroiliacum anterius, posterius et interosseum)*

6 **Movements:** limited translational movements

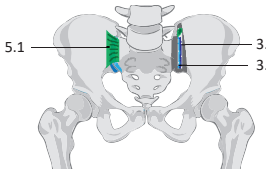

Pelvis, anterior view

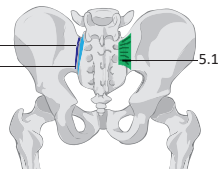

Pelvis, posterior view

6.2 Synarthroses of the pelvic girdle – Synarthroses cinguli pelvici

The pubic symphysis is an elastic cartilaginous joint uniting the two pubic bones in the midline. A fluid-filled sagittal fissure can develop within the cartilaginous disc, imparting a resemblance of a diarthrosis. The hormonal changes occurring during pregnancy loosen the cartilage, preparing the pelvis for parturition.

Pubic symphysis *(symphisis pubica)*

- 1 **Pubic symphysis**
  - 1.1 **Type of connection:** symphysis
  - 1.2 **Accessory features:** the symphysial surfaces of the pubic bones are covered by hyaline cartilage which is continous with a fibrocartilaginous articular disc
  - 1.3 **Ligaments:** the superior and inferior pubic ligaments *(ligamentum pubicum superius et inferius)*

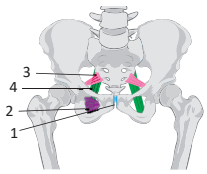

Pelvis, aterior view

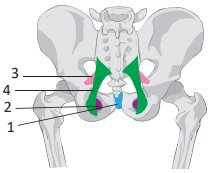

Pelvis, posterior view

Syndesmoses of the pelvic girdle *(syndesmoses cinguli pelvici)*

- 2 **Obturator membrane** *(memebrana obturatioria)*
  - covers the obturator foramen
  - contains a small opening, the obturator canal *(canlis obturatorius)*, for the obturator vessels and nerve
- 3 **Sacrospinous ligament** *(ligamentum sacrospinale)*
  - runs from the ischial spine to the sacrum and coccyx
  - closes the greater sciatic notch forming the greater sciatic foramen
- 4 **Sacrotuberous ligament** *(ligamentum sacrotuberale)*
  - runs from the ischial tuberosity to the sacrum and coccyx
  - closes the lesser sciatic notch forming the lesser sciatic foramen

The inferior pubic ligament *(ligamentum pubicum inferius)*, previously known as the arcuate ligament (*ligamentum arcuatum pubis*), is so strong that it can hold the two pubic bones together in the abscence of the pubic symphysis.

The trochanteric fossa is located outside of the joint capsule.

The iliofemoral ligament is short at birth but gains length during life. It is the strongest ligament in the human body. In newborns it keeps the thighs in a typical position (flexion, abduction and external rotation).

Clinical notes

Overloading of the sacroiliac joint causes local pain that radiates into the thigh. This pain is a consequence of muscular spasms that attempt to stabilise the overloaded joint. The most frequent causes of sacroiliac joint overload are certain sports, working in a forward bended position and osteoarthrotic changes.

Pain over the pubic symphysis can be caused by hypertonic hip joint adductors.

Dislocation of the hip joint may be caused by a high energy trauma. This typically occurs in car accidents when the knees are impacted on the car dashboard (the so called dashboard injury). 90 % of the cases are posterior dislocations, which occur through a weak spot between the ligaments strengthening the articular capsule.

Developmental dysplasia of the hip is a congenital deformity of the hip joint which, if not treated, causes orthopedic problems throughout life. It is charactsied by a misshapen acetabulum and/or head and neck of the femur. This causes a misalignment of the "bone-to-bone" contact between the articular head and fossa. All newborns are screened for DDH after birth with a specialised examination that includes ultrasound.

Total hip replacement (endoprosthesis) is an orthopeadic procedure that replaces the articular head and fossa of the hip joint with an artificial prosthesis. Severely damaged hips are indicated for this operation, such as occur in osteoarthrosis or after injuries.

Hemiarthropathy of the hip is a replacement of the articular head only. This is usually indicated in femoral neck fractures occuring in elderly people.

The hip joint is a **limited synovial ball-and-socket joint** (a cotyloid joint) which allows **limited movements in all three planes**. The deep articular fossa is formed by the **acetabulum of the pelvis** which articulates with the **head of the femur**. The articular surface of the acetabulum is called the **lunate articular facet** and is enlarged by a **cartilaginous labrum**. The articular capsule is thickened by **three strong ligaments** that run from the pubis, ilium and ischium to the femur.

1 **Type:** simple
2 **Shape:** limited ball-and-socket (cotyloid)
3 **Articular head:** the head of the femur
4 **Articular fossa:** acetabulum
- 4.1 **Lunate surface** *(facies lunata)* – the articular facet in the acetabulum

5 **Capsule:** attaches to the margins of the acetabulum and across the posterior aspect of the neck (1 cm above the intertrochanteric crest)
- 5.1 **Retinacula of Weitbrecht** – folds of a synovial membrane formed by impressions of the vessels supplying the neck and head of the femur

6 **Ligaments:**
- 6.1 **Iliofemoral ligament** *(ligamentum iliofemorale)* – prevents hyperextension of the hip joint
- 6.2 **Pubofemoral ligament** *(ligamentum pubofemorale)* – limits abduction and external rotation
- 6.3 **Ischiofemoral ligament** *(ligamentum ischiofemorale)* – limits adduction and internal rotation
  - 6.3.1 **Zona orbicularis** – a ligamentous ring encircling the neck of the femur formed by the pubofemoral and ischiofemoral ligaments
- 6.4 **Transverse acetabular ligament** *(ligamentum transversum acetabuli)* – bridges the acetabular notch
- 6.5 **Ligament of head of femur** *(ligamentum capitis femoris)* – a small ligament connecting the transverse acetabular ligament and fovea for the ligament of the head of the femur – contains the artery of the head of the femur

7 **Accessory features:**
- 7.1 **Acetabular labrum** *(labrum acetabuli)* – a fibrocartilaginous rim that enlarges the cavity of the acetabulum
- 7.2 **Acetabular fat pad** *(pulvinar acetabuli)* – a fat pad in the acetabular fossa

8 **Movements:**
- 8.1 **Flexion**: 0–130°
- 8.2 **Extension**: 0–30° – limited by tension of the iliofemoral ligament
- 8.3 **Abduction**: 0–45°
- 8.4 **Adduction** (hyperadduction): 0–30°
- 8.5 **External rotation:** to 45°
- 8.6 **Internal rotation:** to 35°

9 **Neutral position:** mild flexion, mild external rotation and mild abduction

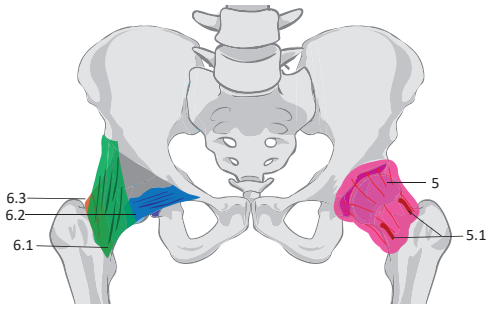

Anterior view of the pelvis and hip joints

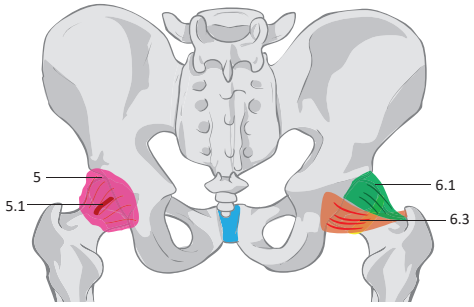

Posterior view of the pelvis and hip joints

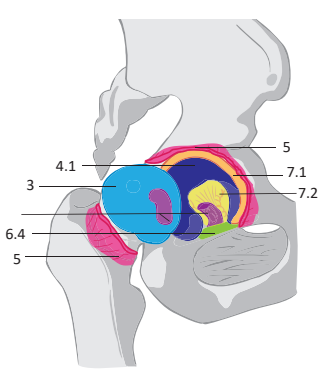

Open right hip joint viewed from the right

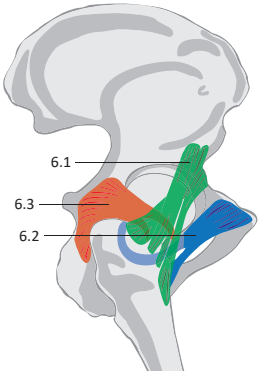

Right hip joint viewed from the right

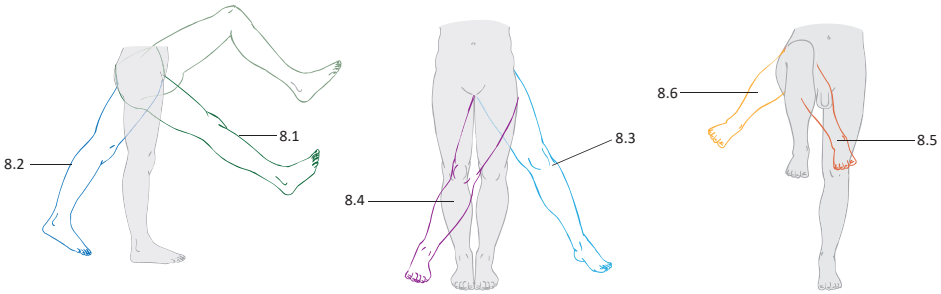

This copy belongs to ali yaghoubi

The knee joint is the most complicated synovial joint in the human body. It is a **complex and compound bicondylar joint** in which **three bones and two menisci** articulate. The knee joint has **12 articular ligaments** and many **associated bursae**. Movements are possible in **two axes**, but these movements are limited when the knee is in full flexion and full extension.

Type, shape and articular surfaces of the knee joint

Type: both complex and compound

1 **Femoropatellar joint** *(articulatio femoropatellaris)*
- 1.1 **Shape:** plane
- 1.2 **Articular head:** the patellar surface of the femur
- 1.3 **Articular fossa:** the articular surface of the patella

2 **Femorotibial joint** *(articulatio femorotibialis)*
- 2.1 **Shape:** a combination of the hinge and pivot joints
- 2.2 **Articular head:** the condyles of the femur
- 2.3 **Articular fossa:** the condyles of the tibia

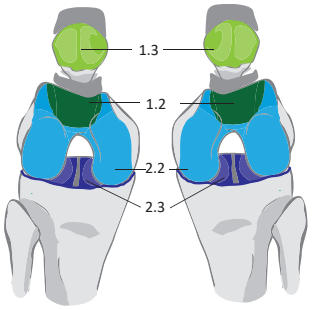

Open right and left knee joints

Articular capsule

- 1 **Fibrous capsule**
  - – originates below the epicondyles of the femur
  - – attaches to the circumference of the articular surfaces of the tibia and patella
- 2 **Synovial membrane**
  - – lines the internal surface of the fibrous layer
  - – does not cover the cruciate ligaments
  - 2.1 **Infrapatellar synovial fold** *(plica synovialis infrapatellaris)*
    - 2.1.1 **Alar folds** *(plicae alares)* – project dorsally from the ventral part of the joint
  - 2.2 **Infrapatellar fat pad** *(corpus adiposum infrapatellare)*
    - – a fat pad between the fibrous and synovial layers
- 3 **Synovial bursae and articular recesses**
  - – approximately 20 bursae and 2 recesses are located in the vicinity of the knee joint

Communicating with the knee joint:
- 3.1 **Suprapatellar recess** *(recessus suprapatellaris)*
- 3.2 **Suprapatellar bursa** *(bursa suprapatellaris)*
- 3.3 **Subpopliteal recess** *(becessus subpopliteus)*
- 3.4 **Gastrocnemiosemimembranosus bursa** *(bursa gastrocnemiosemimembranosa)*

Not communicating with the knee joint:
- 3.5 **Anserine bursa** *(bursa anserina)*
- 3.6 **Subcutaneous prepatellar bursa** *(bursa subcutanea prepatellaris)*
- 3.7 **Subcutaneous infrapatellar bursa** *(bursa subcutanea infrapatellaris)*

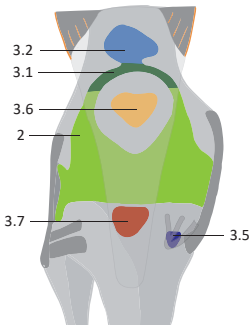

Anterior view of the right knee joint

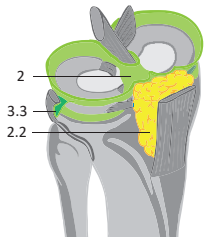

Right anterior superior view of the right knee joint

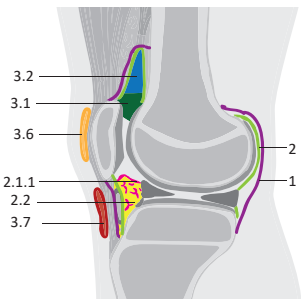

Sagittal section of the right knee joint viewed from the left

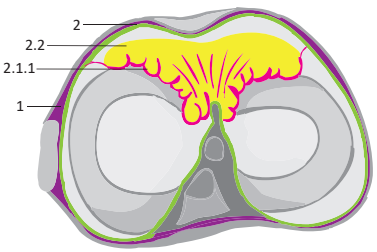

Superior view of a transverse section of the right knee joint

The valve mechanism of the knee is a system of connected pouches and synovial bursae of the knee joint through which synovial fluid flows. The ventral part is formed by the suprapatellar recess and bursa, the dorsomedial part is formed by the gastrocnemius-semimembranosus bursa and the dorsolateral part by the subpopliteal recess.

A mnemonics for remembering the positions of the cruciate ligaments: when the middle finger is crossed over the index finger and the hand placed on the ipsilateral knee, the middle finger shows the position of the anterior cruciate ligament and the index finger shows the position of the posterior cruciate ligament.

In clinical practice, the tibial and fibular collateral ligaments are inaccurately termed the medial and lateral collateral ligaments.

The middle position of the knee joint is 20–30°of flexion.

The articularis genus is a standalone muscle below the quadriceps femoris. It attaches to the joint capsule, which stretches up and prevents its incarceration.

Clinical notes

The unhappy triad is a term given to concomitant damage to the anterior cruciate ligament, medial meniscus and tibial collateral ligament.

The menisci, anterior cruciate ligament and collateral ligaments are the most predisposed structures of the knee to be injured. The anterior cruciate ligament is injured ten times more frequently than the posterior cruciate ligament.

Baker's cyst arises when the gastrocnemius-semimembranosus bursa becomes overfilled with synovial fluid. It is palpable in the subcutaneous tissue of the popliteal fossa.

Total knee replacement is a surgical procedure that replaces severely damaged femoral and tibial condyles with artificial prostheses. This is performed when conservative therapy with analgetics, injections, and rehabilitation is not sufficient in patients with severe arthrosis. Other indications include disease of the knee caused by systemic diseases such as rheumatoid arthritis, ankylosing spondylitis disease and psoriatic arthritis.

Ligaments

1 **Collateral ligaments:**
- 1.1 **Tibial collateral ligament** *(ligamentum collaterale tibiale)*
  - runs from the medial epicondyle of the femur to the tibia
  - is attached firmly to the medial meniscus
- 1.2 **Fibular collateral ligament** *(ligamentum collaterale fibulare)*
  - runs from the lateral epicondyle of the femur to the head of the fibula

2 **Ventral ligaments:**
- 2.1 **Medial and lateral patellar retinacula** *(retinaculum patellae mediale et laterale)*
  - attach the quadriceps femoris directly to the tibial tuberosity on either side of the patella
  - hold the patella in the shallow patellar surface of the femur
- 2.2 **Patellar ligament** *(ligamentum patellae)*
  - the insertion of the quadriceps femoris between the patella and the tibial tuberosity

3 **Dorsal ligaments:**
- 3.1 **Oblique popliteal ligament** *(ligamentum popliteum obliquum)*
  - one of the insertions of the semimembranosus
  - is also known as the pes anserinus profundus
- 3.2 **Arcuate popliteal ligament** *(ligamentum popliteum arcuatum)*
  - forms an arch above the tendon of the popliteus

4 **Intra-articular ligaments:**
- 4.1 **Anterior cruciate ligament** *(ligamentum cruciatum anterius)*
  - runs from the medial surface of the lateral condyle of the femur ventromedially to the anterior intercondylar area of the tibia
- 4.2 **Posterior cruciate ligament** *(ligamentum cruciatum posterius)*
  - runs from the lateral surface of medial condyle of the femur caudally to the posterior intercondylar area of the tibia
- 4.3 **Transverse ligament of knee** *(ligamentum transversum genus)*
  - connects both menisci ventrally; not covered by synovial membrane (the only true intra-articular ligament of the human body)
- 4.4 **Anterior and posterior meniscofemoral ligament** *(ligamentum meniscofemorale anterius et posterius)*
  - weak ligaments around the posterior cruciate ligament

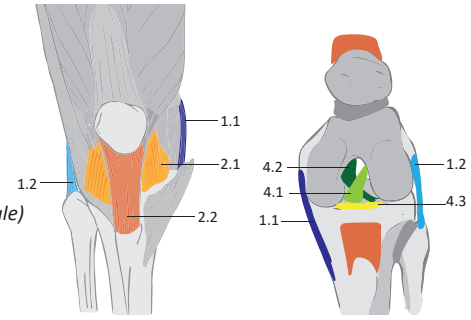

Posterior view of the right knee in extension and the left knee in flexion with the patella reflected

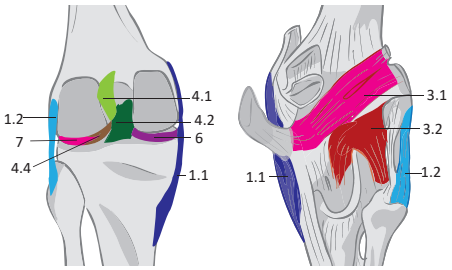

Posterior view of the left and right knee joints

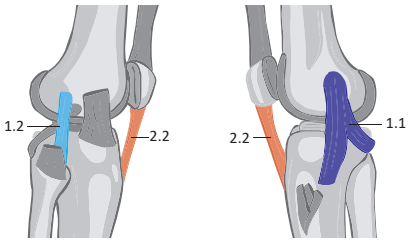

Medial and lateral sides of the right knee joint

Menisci

- 6 **Medial meniscus** *(meniscus medialis)* – a C-shape semicircle
  - attaches to the anterior and posterior intercondylar area
  - is firmly attached medially to the articular capsule and laterally to the tibial collateral ligament, which limits its mobility
  - the semimembranosus prevents displacement by pulling it at its dorsal end
- 7 **Lateral meniscus** *(meniscus lateralis)* – almost forms a complete circle
  - attaches to the anterior and posterior intercondylar area
  - is not attached to the capsule and so is more mobile than the medial meniscus
  - the popliteus prevents displacement by pulling its dorsal end

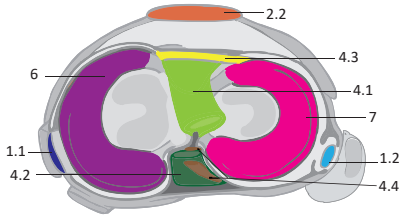

Superior view of the right knee joint

Movements

- 8 **Flexion:** 0–150°
- 9 **Extension:** 0°
- 10 **Rotations** – is possible only in flexed knees
  - 10.1 **Internal rotation:** 5–10°
  - 10.2 **External rotation:** approximately 40°

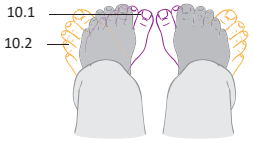

Flexion of the knee joint (3 phases):
– the patella slips distally during flexion and proximally during extension

1. **Initial rotation** (unlocking of knee joint): flexion to 5°
   - release of the cruciate ligaments and tibial collateral ligament
   - tibia rotates internally
   - lockout of the knee occurs in the reverse order
2. **Rolling movement:** flexion 10–20°
   - condyles of the femur roll over the condyles of the tibia and on the menisci
3. **Sliding movement:** from 20° flexion to approximately 160° the condyles of the femur and menisci slide on the tibia dorsally

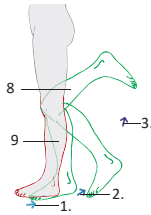

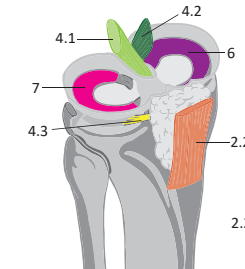

Right anterior superior view of the right knee joint

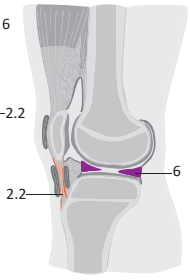

Sagittal section of the left knee joint, view from the right

This copy belongs to ali yaghoubi

6.5 Tibiofibular joint (superior tibiofibular joint) – Articulatio tibiofibularis

The tibiofibular joint is a plane synovial joint that allows only very limited movement. It is an amphiarthrosis.

1 **Type:** simple
2 **Shape:** plane
3 **Articular surfaces:**
- 3.1 **Articular facet of head of fibula** *(facies articularis capitis fibulae)*
- 3.2 **Fibular articular facet of tibia** *(facies articularis fibularis tibiae)*

4 **Capsule:** firm and small
5 **Ligaments:** the anterior and posterior ligaments of the head of the fibula *(ligamentum capitis fibulae anterius et posterius)*
6 **Movements:** passive movements due to the movements of the ankle joint

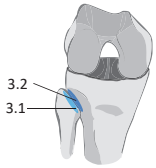

Anterior view of the right tibiofibular joint

6.6 Interosseous membrane of the leg and tibiofibular syndesmosis

The interosseous membrane of the leg runs from the tibia laterodistally and prevents the tibia and fibula moving away from each other. The muscles of the deep layer of the leg originate on this membrane. **The tibiofibular syndesmosis** connects the distal part of the tibia and fibula, which forms a fork shaped unit for articulation with the talus.

- 1 **Interosseous membrane of leg** *(membrana interossea cruris)*
  – attaches to the interosseous borders of the fibula and tibia
- 2 **Tibiofibular syndesmosis / inferior tibiofibular joint** *(syndesmosis tibiofibularis)*
  – a distal thickening of the interosseous membrane
- 3 **Anterior and posterior tibiofibular ligaments** *(ligamentum tibiofibulare anterius et posterius)*
  – ventral and dorsal strengthenings of the tibiofibular syndesmosis

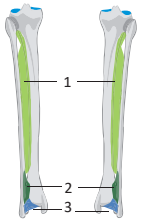

6.7 Joints of the foot – Articulationes pedis

The joints of the foot comprise a functional unit that produces foot movements necessary for ambulation.

Joints of the foot

- 1 **Ankle joint** *(articulatio talocruralis)*
- 2 **Subtalar/talocalcaneal joint** *(articulatio subtalaris/talocalcanea)*
- 3 **Talocalcaneonavicular joint** *(articulatio talocalcaneonavicularis)*
- 4 **Calcaneocuboid joint** *(articulatio calcaneocuboidea)*
- 5 **Cuneonavicular joint** *(articulatio cuneonavicularis)*
- 6 **Cuneocuboid joint** *(articulatio cuneocuboidea)*
- 7 **Intercuneiform joints** *(articulationes intercuneiformes)*
- 8 **Tarsometatarsal joints** *(articulationes tarsometatarsales)*
- 9 **Intermetatarsal joints** *(articulationes intermetatarsales)*
- 10 **Metatarsophalangeal joints** *(articulationes metatarsophalangeae)*
- 11 **Interphalangeal joints of foot** *(articulationes interphalangeae pedis)*

Functional joints
- 12 **Chopart's joint** – the transverse tarsal joint
- 13 **Lisfranc's joint** – the tarsometatarsal and intermetatarsal joints

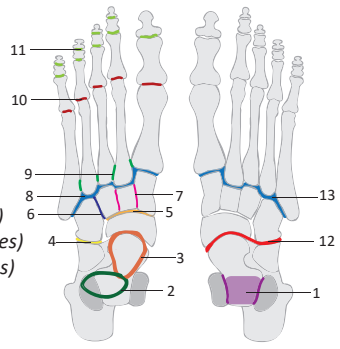

Superior view of the left and right feet

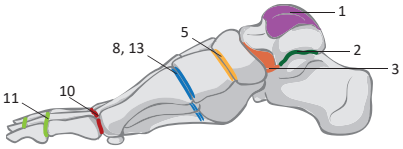

Medial view of the right foot

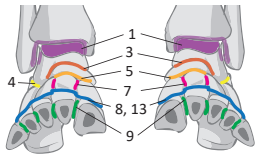

Anterior view of a section through the metatarsals of the right and left feet

All movements in the tarsus are associated with rotation of the fibula

The articular facet of the medial malleolus is lunate or tear-drop shaped.

The articular facet of the lateral malleolus has a triangular shape.

The opening for the anterior tibial vessels *(vasa tibialia anteriora)* is located at the proximal end of the interosseous membrane of the leg.

The bifurcate ligament is a strong ligament on the dorsum of the foot. Distal to its attachment on the calcaneus, it bifurcates into the calcaneocuboid and calcaneonavicular ligaments.

The spring ligament is another name for the plantar calcaneonavicular ligament.

The plantar calcaneocuboid ligament is also known as the short plantar ligament.

Talotarsal joint (subtalar/talocalcaneal and talocalcaneonavicular joints) are a functional unit for the inversion and eversion.

Clinical notes

The tibiofibular syndesmosis is a very firm synarthrosis. A trauma to the leg is much more likely to cause dislocation of the ankle than rupture of the tibiofibular syndesmosis.

Ankle fractures are classified preferably according to Weber into types A, B and C. This classification describes the fractures according to the location of fracture in relation to the tibiofibular syndesmosis.

Injuries of the collateral ligaments of the ankle represent some of the most frequent types of sport injuries. The medial collateral ligament is firmer than the lateral and so is injured less often. A sprained ankle, the most common type of ankle injury, is caused by a tear in the anterior inferior talofibular ligament.

Ankle joint *(articulatio talocruralis)*

1 **Type:** a compound joint of three articulating bones
2 **Shape:** trochlear
3 **Articular head:** the trochlea of the talus
- 3.1 **Superior facet** *(facies articularis superior)*
- 3.2 **Medial malleolar facet** *(facies articularis malleolaris medialis tali)*
- 3.3 **Lateral malleolar facet** *(facies articularis malleolaris lateralis tali)*

4 **Articular fossa:** the distal end of the tibia and fibula
- 4.1 **Inferior articular surface of tibia** *(facies articularis inferior tibiae)*
- 4.2 **Articular facet of medial malleolus of tibia** *(facies articularis malleoli medialis tibiae)*
- 4.3 **Articular facet of lateral malleolus of fibula** *(facies articularis malleoli lateralis fibulae)*

5 **Capsule:** is attached to the circumference of the articular surfaces
6 **Collateral ligaments:**
- 6.1 **Medial/deltoid ligament** *(ligamentum collaterale mediale / ligamentum deltoideum)* – a triangular ligament composed of four parts
  - 6.1.1 **Anterior tibiotalar part** *(pars tibiotalaris anterior)*
  - 6.1.2 **Posterior tibiotalar part** *(pars tibiotalaris posterior)*
  - 6.1.3 **Tibionavicular part** *(pars tibionavicularis)*
  - 6.1.4 **Tibiocalcaneal part** *(pars tibiocalcanea)*
- 6.2 **Lateral ligament** *(ligamentum collaterale laterale)* – a complex of three independent ligaments
  - 6.2.1 **Anterior talofibular ligament** *(ligamentum talofibulare anterius)*
  - 6.2.2 **Posterior talofibular ligament** *(ligamentum talofibulare posterius)*
  - 6.2.3 **Calcaneofibular ligament** *(ligamentum calcaneofibulare)*

7 **Movements:**
- 7.1 **Plantar flexion:** 0–50°
- 7.2 **Dorsiflexion:** 0–20°

8 **Middle position:** corresponds to the anatomical position

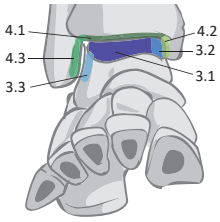

Anterior view of a section through the metarsal bones on the right foot

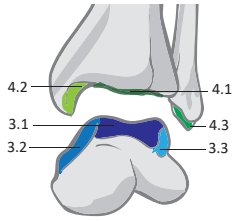

Posterior view of the bones of the ankle joint

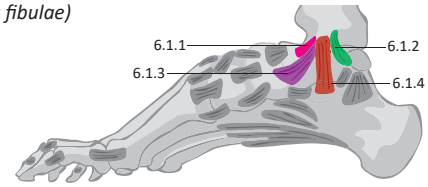

Medial view of the right foot

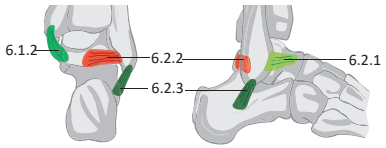

Posterior and lateral view of the right foot

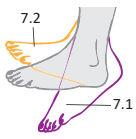

Subtalar/talocalcaneal joint *(articulatio subtalaris/talocalcanea)*

1.1 **Type:** simple
1.2 **Shape**: cylindrical
- 1.3 **Articular head:** the posterior articular talar surface of the calcaneus *(facies articularis talaris posterior calcanei)*
- 1.4 **Articular fossa:** the posterior calcaneal articular facet of the talus *(facies articularis calcanea posterior tali)*

1.5 **Ligaments:** the posterior, medial, lateral and interosseous talocalcaneal ligaments *(ligamentum talocalcaneum posterius, mediale, laterale et interosseum)*

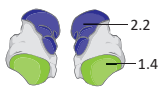

Posterior view of the right and left talus

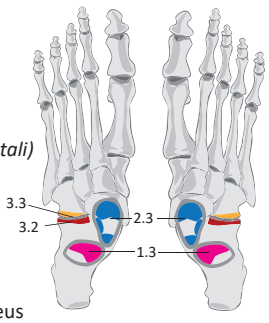

Superior view of the left and right foot after removal of the talus

Talocalcaneonavicular joint *(articulatio talocalcaneonavicularis)*

2.1 **Type:** a compound joint of three articulating bones
- 2.2 **Articular head:** the head of the talus and the anterior and middle articular talar surfaces of the calcaneus
- 2.3 **Articular fossa:** the navicular and the anterior and middle calcaneal articular facets of the talus and navicular fibrocartilage

2.4 **Ligaments:** the talonavicular ligament *(ligamentum talonaviculare)*, plantar calcaneonavicular ligament *(ligamentum calcaneonaviculare plantare)*, and dorsal calcaneonavicular ligament *(ligamentum calcaneonaviculare dorsale)*
2.5 **Accessory features:** the navicular fibrocartilage which enlarges the fossa for the head of the talus (within the plantar calcaneonavicular ligament)

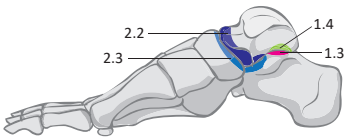

Medial view of the right foot

Calcaneocuboid joint *(articulatio calcaneocuboidea)*

3.1 **Type:** amphiarthroses
- 3.2 **Articular head:** the articular surface for the cuboid on the calcaneus
- 3.3 **Articular fossa:** cuboid

3.4 **Ligaments:** the plantar calcaneocuboid ligament *(ligamentum calcaneocuboideum plantare)* and dorsal calcaneocuboid ligament *(ligamentum calcaneocuboideum dorsale)*
3.5 **Movements:** very limited



Inversion and eversion of the feet

Movements of the foot

- 1 **Inversion**: 0–30°
- 2 **Eversion**: 0–15

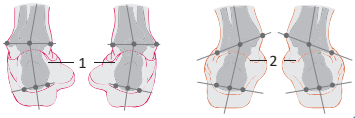

Inversion and eversion of the feet

This copy belongs to ali yaghoubi

Other foot joints

1 **Cuneonavicular joint** *(articulatio cuneonavicularis)*
– a compound plane joint between the cuneiform bones and navicular
- 1.1 **Ligaments:** the plantar and dorsal cuneonavicular ligament *(ligamentum cuneonaviculare plantare et dorsale)*

2 **Cuneocuboid joint** *(articulatio cuneocuboidea)*
– a plane joint between the lateral cuneiform and the cuboid
- 2.1 **Ligaments:** the plantar, dorsal and interosseous cuneocuboid ligaments *(ligamentum cuneocuboideum plantare, dorsale et interosseum)* and plantar and dorsal cuboideonavicular ligaments *(ligamentum cuboideonaviculare plantare et dorsale)*

3 **Intercuneiform joints** *(articulationes intercuneiformes)*
– plane joints between the cuneiform bones
- 3.1 **Ligaments:** the plantar, dorsal and interosseous intercuneiform ligament *(ligamentum intercuneiforme plantare, dorsale et interosseum)*

4 **Tarsometatarsal joints** *(articulationes tarsometatarsales)*
4.1 **Type:** simple
4.2 **Shape:** plane
4.3 **Articular surfaces:**
– the distal surfaces of the cuneiform bones articulate with the bases of the 1st–3rd metatarsals
– the distal surface of the cuboid articulates with the bases of the 4th–5th metatarsals
- 4.4 **Ligaments:** the plantar and dorsal tarsometatarsal ligaments *(ligamenta tarsometatarsalia plantaria et dorsalia)* and interosseous cuneometatarsal ligaments *(ligament cuneometatarsalia interossea)*

5 **Intermetatarsal joints** *(articulationes intermetatarsales)*
– connect the adjacent surfaces of the bases of the 1st–5th metatarsal bones
- 5.1 **Ligaments:** the plantar, dorsal and interosseous metatarsal ligaments *(ligamenta metatarsalia plantaria, dorsalia et interossea)*

6 **Metatarsophalangeal joints** *(articulationes metatarsophalangeae)*
6.1 **Articular head:** the head of the metatarsal bones
6.2 **Articular fossa: the** base of the adjacent proximal phalanges
6.3 **Ligaments:**
- 6.3.1 **Plantar and collateral ligaments** *(ligamenta plantaria et collateralia)*
- 6.3.2 **Deep transverse metatarsal ligament** *(ligamentum metatarsale transversum profundum)*
– connects the adjacent heads of the metatarsals

6.4 **Accessory features:** plantar fibrocartilage *(fibrocartilago plantaris)*
6.5 **Movements:** flexion, extension and mild adduction and abduction

7 **Proximal and distal interphalangeal joints of foot** *(articulationes interphalangeae pedis proximales et distales)*
7.1 **Head:** the head of the proximal and middle phalanx
7.2 **Cavity**: the base of the middle and distal phalanx
7.3 **Shape:** trochlear
- 7.4 **Ligaments:** the collateral and plantar ligaments *(ligamenta collateralia et plantaria)*

7.5 **Accessories:** plantar fibrocartilage
7.6 **Movements:** flexion and extension

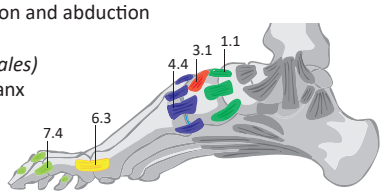

Medial view of the right foot

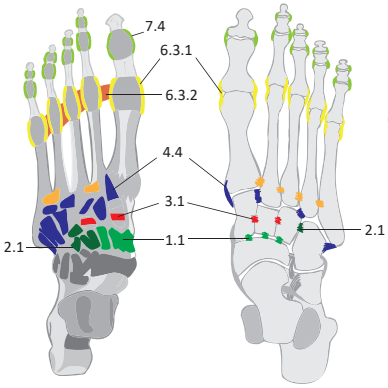

Superior view of the right and left feet

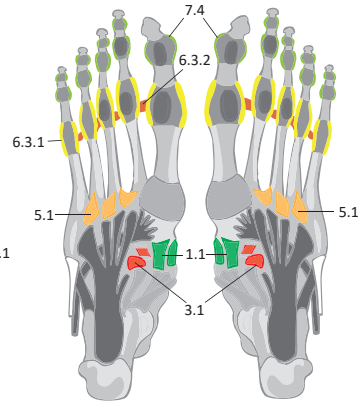

Posterior view of the right and left feet

The key to Chopart´s joint *(clavis articulationis tarsi transversae)* is a clinical term for the bifurcated ligament.

The tendinous stirrup is formed by the inserting tendons of tibialis anterior and fibularis longus at the medial cuneiform bone and supports the transverse arch of foot.

The plantar fibrocartilage *(fibrocartilago* plantaris) enlarges the articular heads of the metacarpophalangeal and interphalangeal joints, strengthening these joints. Plantar fibrocartilage is embedded within **the plantar ligaments** *(ligamenta plantaris).*

The navicular bone serves as a central keystone of the bony vault at the apex of the longitudinal arch of foot.

Clinical notes

Exarticulation of the distal part of the foot can be performed along the Chopart's or Lisfranc's joint lines.

Hallux valgus is a deformity of the big toe characterised by a lateral deviation of the big toe towards the other toes. It can occur secondarily due to a varus deformity of the 1st metarsal or to degenerative changes of the 1st metatarsophalangeal joint.

Pes transversoplanus is a type of flat foot caused by the collapse of the transverse arch of the foot.

Pes cavus is a foot deformity characterised by a high longitudinal arch of the foot.

Functional joints

- 1 **Chopart´s joint / transverse tarsal joint** *(articulatio tarsi transversa)*
  - – is composed of the talonavicular joint, which is a part of the talocalcaneonavicular joint and the calcaneocuboid joint
  - – a functionally and clinically important joint of the foot
  - – allows the pronation and supination and enlarges the movement of the ankle joint
  - 1.1 **Bifurcate ligament** *(ligamentum bifurcatum)*
    - – is located on the dorsal aspect of the foot and composed of two parts
    - 1.1.1 **Calcaneonavicular ligament** *(ligamentum calcaneonaviculare)*
    - 1.1.2 **Calcaneocuboid ligament** *(ligamentum calcaneocuboideum)*
- 2 **Lisfranc's joint**
  - – comprises the tarsometatarsal and intermetatarsal joints
  - – facilitates the spring movements of the foot
  - – the serrate line of articulation is formed by the insertion of the 2nd metatarsal into a shallow cavity formed by the intermediate cuneiform, which is shorter than other cuneiform bones

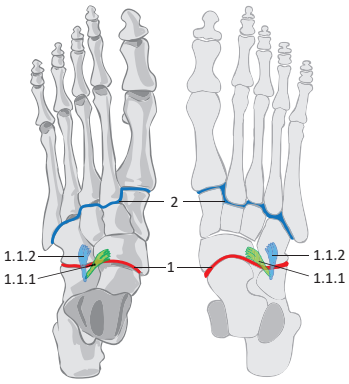

Superior view of the left and right feet

6.7.1 Arches of the foot

The human foot is shaped by two longitudinal and one transverse arch. These arches are formed and maintained by the architecture of the tarsus and metatarsal bones, **the long and short ligaments of the foot and the muscles of the foot and leg**. The arches are fully developed by the 3rd year of life, at which point the foot is in contact with the ground in three spots: **the calcaneal tuberosity, the head of the 1st metatarsal bone and the head of the 5th metatarsal bone**. The arches of the foot **protect the soft tissue of the foot** and function as **a spring, converting elastic energy into kinetic energy during gait**.

- 1 **Longitudinal arch** – two lines of bones which end on the navicular
  - **Medial**: the calcaneus, talus, navicular, three cuneiform bones and 1st metatarsal
    - – 15–18 mm above the ground at its highest point
  - **Lateral**: the calcaneus, cuboid and 5th metatarsal
    - – 3–5 mm above the ground at its highest point

  Maintained by:
  - 1.1 **Longitudinal plantar ligaments**
    - 1.1.1 **Long plantar ligament** *(ligamentum plantare longum)*
      - – a strong thick ligament that runs from the calcaneus to the bases of the metatarsals on the plantar aspect of the foot
      - – has some fibres which run to the cuboid
    - 1.1.2 short plantar and interosseous ligaments of the foot
  - 1.2 **Plantar aponeurosis** *(aponeurosis plantaris)*
  - 1.3 **Muscles:**
    - 1.3.1 **Tibialis anterior** *(musculus tibialis anterior)*
    - 1.3.2 **Tibialis posterior** *(musculus tibialis posterior)*
    - 1.3.3 **Flexor hallucis longus** *(musculus flexor hallucis longus)*
    - 1.3.4 **Flexor digitorum longus and brevis** *(musculus flexor digitorum longus et brevis)*
    - 1.3.5 **Intrinsic muscles of the foot**
- 2 **Transverse arch:**
  - – runs over the heads of all the metatarsals
  - – most developed in over the cuneiform bones and the cuboid
  - – held by the tendinous strirrup of the tibialis anterior and fibularis longus

  Maintained by:
  - 2.1 **Transverse ligaments of the foot:**
    - 2.1.1 **Plantar and interosseous intercuneiform ligaments** *(ligamenta intercuneiformia plantaria et interossea)*
    - 2.1.2 **Plantar cuneonavicular ligaments** *(ligamenta cuneonavicularia plantaria)*
    - 2.1.3 **Plantar tarsometatarsal ligaments** *(ligamenta tarsometatarsalia plantaria)*
  - 2.2 **Muscles:**
    - 2.2.1 **Tibialis anterior** *(musculus tibialis anterior)*
    - 2.2.2 **Fibularis longus** *(musculus fibularis longus)*
    - 2.2.3 **Adductor hallucis** *(musculus adductor hallucis)*
    - 2.2.4 **Intrinsic muscles of the foot**

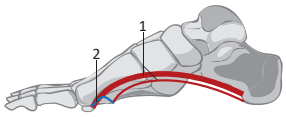

Medial view of the right foot

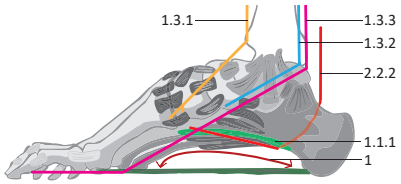

Medial view of the right foot

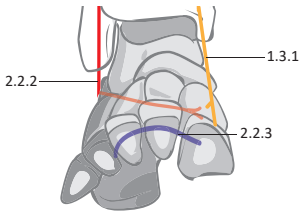

Anterior view of a section through the metatarsals in the right foot

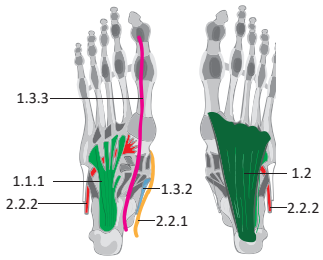

Inferior view of the right and left feet

This copy belongs to ali yaghoubi

Head and neck			
Flexion / Ventral flexion (bilateral contraction)	**Extension / Retroflexion / Dorsiflexion** (bilateral contraction)	**Lateral flexion / Lateroflexion / Inclination** (unilateral contraction)	**Rotation** (unilateral contraction)
Sternocleidomastoid	**Sternocleidomastoid**	**Sternocleidomastoid**	**Sternocleidomastoid**
Scalenus anterior	**Trapezius** (with a fixed shoulder girdle)	**Trapezius**	**Splenius capitis**
Scalenus medius	**Splenius capitis**	**Levator scapulae** (unilateral contraction with a fixed scapula)	**Splenius cervicis**
Scalenus posterior	**Splenius cervicis**	**Splenius capitis**	**Semispinalis capitis**
Longus capitis	**Longissimus capitis**	**Splenius cervicis**	**Semispinalis cervicis**
Longus colli	**Longissimus cervicis**	**Longissimus capitis**	**Longissimus capitis**
Rectus capitis anterior	**Semispinalis capitis**	**Longissimus cervicis**	**Longissimus cervicis**
Suprahyoid and infrahyoid muscles working together synergistically	**Semispinalis cervicis**	**Semispinalis capitis**	**Obliquus capitis inferior**
	Rectus capitis posterior major	**Semispinalis cervicis**	**Scalenus anterior**
	Rectus capitis posterior minor	**Rectus capitis posterior major**	**Scalenus medius**
	Obliquus capitis superior	**Rectus capitis posterior minor**	
		Obliquus capitis superior	
		Scalenus anterior	
		Scalenus medius	
		Scalenus posterior	
		Longus colli	
		Rectus capitis anterior	
		Rectus capitis lateralis	

Temporomandibular joint				
Protraction	**Retraction**	**Elevation**	**Depression**	**Lateropulsion**
Lateral pterygoid	**Temporalis (posterior fibres)**	**Temporalis (anterior fibers)**	**Mylohyoid**	**Medial pterygoid**
Masseter (superficial part)		**Masseter (superficial and deep part)**	**Digastricus**	**Lateral pterygoid**
		Medial pterygoid	**Geniohyoid**	

Body part / joint	Movement	Range of joint motion
Scapula Acromioclavicular joint + Sternoclavicular joint + „Scapulothoracic joint“	depression – elevation	0–55°
	retraction – protraction	0–25°
	internal rotation – external rotation	0–60°
Arm / shoulder joint	ventral flexion	0–90° (180°)
	dorsiflexion / extension	0–50°
	abduction	0–90 (180°)
	adduction (hyperadduction)	0–75°
	external rotation	0–90°
	internal rotation	0–90°
Forearm / elbow joint	flexion	0–145°
	extension	0–5°
Forearm / proximal and distal radioulnar joints	supination	90°
	pronation	90°
Hand / wrist joint	palmar flexion	0–80°
	dorsal flexion	0–85°
	radial duction	0–15°
	ulnar duction	0–45°
Fingers of the hand / metacarpophalangeal joints	flexion	0–90°
	extension	0–20°
	abduction – adduction (from/to 3rd finger)	0–45°
Thumb / carpometacarpal joint of first digit	flexion	0–45°
	extension	0–15°
	adduction – abduction	0–70°
Thigh / hip joint	flexion	0–130°
	extension	0–30°
	abduction	0–45°
	adduction (hyperadduction)	0–30°
	external rotation	0–45°
	internal rotation	0–35°
Leg / knee joint	extension– flexion	0–150°
	external rotation (in flexion only)	0–40°
	internal rotation (in flexion only)	0–10°
Food / ankle joint	plantar flexion	0–50°
	dorsiflexion / extension	0–20°
Whole foot	inversion	0–30°
	eversion	0–15°
Fingers of the foot / metatarsophalangeal joints	flexion	0–45°
	extension	0–70°
	abduction – adduction (from/to 2nd toe)	0–25°

Note 1: The range of joint motion is measured from 0° at the basic anatomical position to the maximal angle obtained for each particular movement. The exceptions are supination and pronation in which we describe the maximum range of motion to be 90° for both movements.
The anatomical position of the forearm is in supination and therefore the total range of joint motion for supination and pronation should be 0–180°.

Note 2: In this table, values from goniometrical and kinesiological publications were used. These values vary widely.
We tried to choose the most suitable compromise.

This copy belongs to ali yaghoubi

Glenohumeral joint					
Flexion	**Extension**	**Abduction**	**Adduction**	**Internal rotation**	**External roation**
Deltoid (clavicular part)	**Deltoid (spinal part)**	**Deltoid (acromial part)**	**Infraspinatus**	**Deltoid (clavicular part)**	**Deltoid (spinal part)**
Biceps brachii (short head)	**Teres major**	**Supraspinatus**	**Teres major**	**Teres major**	**Supraspinatus**
Coracobrachialis	**Triceps brachii (long head)**	**Biceps brachii (long head)**	**Teres minor**	**Subscapularis**	**Infraspinatus**
Pectoralis major	Latissimus dorsi		**Subscapularis**	Latissimus dorsi	**Teres minor**
			Biceps brachii (short head)	Pectoralis major	
			Coracobrachialis		
			Triceps brachii (long head)		
			Latissimus dorsi		
			Pectoralis major		

Elbow joint			
Flexion	**Extension**	**Pronation**	**Supination**
Brachialis	**Triceps brachii**	**Pronator teres**	**Supinator**
Biceps brachii (only with supinated forearm)	Anconeus	**Pronator quadratus**	**Biceps brachii** (only with pronated forearm)
Palmaris longus		Brachioradialis (only in flexed forearm from supinated position)	Brachioradialis (only in extended forearm from pronated position)
Pronator teres		Extensor carpi radialis longus (only in flexed forearm)	Extensor carpi radialis longus (only in extended forearm)
Flexor carpi radialis		Extensor carpi radialis brevis (only in flexed forearm)	Extensor carpi radialis brevis (only in extended forearm)
Flexor carpi ulnaris			
Flexor digitorum superficialis			
Brachioradialis			

Wrist joint (and associated joints of the hand)			
Flexion	**Extension**	**Radial duction**	**Ulnar duction**
Flexor carpi radialis	**Extensor carpi radialis longus**	**Flexor carpi radialis**	**Flexor carpi ulnaris**
Flexor carpi ulnaris	**Extensor carpi radialis brevis**	**Extensor carpi radialis longus**	**Extensor carpi ulnaris**
Flexor digitorum superficialis	**Extensor digitorum**	**Extensor carpi radialis brevis**	
Flexor digitorum profundus	**Extensor carpi ulnaris**	**Abductor pollicis longus**	
Palmaris longus	Extensor digiti minimi		
Flexor pollicis longus	Extensor indicis		

Hip joint					
Flexion	**Extension**	**Abduction**	**Adduction**	**Internal rotation**	**External rotation**
Iliopsoas	**Gluteus maximus**	**Iliopsoas**	**Gluteus maximus**	**Gluteus medius** (anterior fibers)	**Iliopsoas**
Gluteus medius (anterior fibers)	**Gluteus medius** (posterior fibers)	**Gluteus maximus**	**Gracilis**	**Gluteus minimus** (anterior fibers)	**Gluteus maximus**
Gluteus minimus (anterior fibers)	**Gluteus minimus** (posterior fibers)	**Gluteus medius** (middle part)	**Pectineus**	**Tensor fasciae latae**	**Gluteus medius** (posterior fibers)
Tensor fasciae latae	**Adductor magnus** (extensor part)	**Gluteus minimus** (middle part)	**Adductor brevis**	Semitendinosus	**Gluteus minimus** (posterior fibers)
Sartorius	**Biceps femoris**	**Tensor fasciae latae**	**Adductor longus**	Semimembranosus	**Piriformis** (in extended thigh)
Quadriceps femoris (rectus femoris)	**Semitendinosus**	**Piriformis** (in flexed thigh)	**Adductor magnus** (adductor part)	**Adductor magnus** (extensor part)	**Gemellus superior** (in extended thigh)
Pectineus	**Semimembranosus**	**Gemellus superior** (in flexed thigh)	Semitendinosus		**Obturatorius internus** (in extended thigh)
Adductor brevis		**Obturator internus** (in flexed thigh)	Semimembranosus		**Gemellus inferior** (in extended thigh)
Adductor longus		**Gemellus inferior** (in flexed thigh)			**Quadratus femoris**
Adductor magnus (adductor part)		**Sartorius**			**Sartorius**
					Pectineus
					Adductor brevis
					Adductor longus
					Biceps femoris

Knee joint			
Flexion	**Extension**	**Internal rotation** (only in flexed leg)	**External roation** (only in flexed leg)
Sartorius	**Quadriceps femoris**	**Sartorius**	**Biceps femoris**
Gracilis	Gluteus maximus	**Gracilis**	
Biceps femoris	Tensor fasciae latae	**Semitendinosus**	
Semitendinosus		**Semimembranosus**	
Semimembranosus		**Popliteus**	
Triceps surae (gastrocnemius)			
Popliteus			

Ankle joint (and the associated joints of the foot)			
Flexion (plantar flexion)	**Extension (dorsal flexion)**	**Inversion**	**Eversion**
Fibularis longus	**Tibialis anterior**	**Tibialis anterior**	**Fibularis longus**
Fibularis brevis	**Extensor digitorum longus**	**Tibialis posterior**	**Fibularis brevis**
Triceps surae	Extensor hallucis longus	**Flexor digitorum longus**	Extensor digitorum longus
Tibialis posterior		**Flexor hallucis longus**	
Flexor digitorum longus		Triceps surae	
Flexor hallucis longus			

This copy belongs to ali yaghoubi

I. General arthrology

1. Explain the term “neutral position of a joint”. (p. 68)
2. Explain the differences between synchondrosis and symphysis and give examples of both of these types of joints. (p. 68)
3. State what fills the articular cavity and what creates this substance. (p. 70)
4. Give the definitions of complex and compound joints. (p. 69)
5. Describe the differences between articular discs and menisci and give examples of where these structures can be found. (p. 71)
6. Explain the term “circumduction” and name some joints where this movement can be performed. (p. 71)

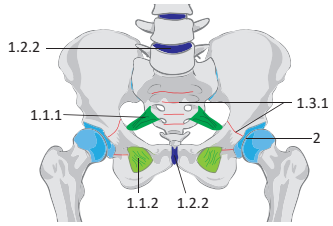

Describe the joints of the pelvis and hip

II. Joints of the skull

7. List all the types of joint found in the skull. (p. 72)
8. Describe the movements that can be performed in the temporomandibular joint. (p. 72)

III. Joints of the vertebral column

9. State the type of joint found between adjacent vertebral bodies and describe the structure of the intervertebral disc. (p. 73)
10. Name the two main long ligaments on the vertebral column and specify their location and their main function. (p. 73)
11. Name 5 ligaments of the median atlanto-axial joint. (p. 73)
12. Name the joint located between the adjacent superior and inferior articular processes of the vertebrae and state the accessory feature of this joint. (p. 73, 74)
13. Specify the part of the vertebral column that has the range of motion in rotation and specify the approximate range of this rotation. (p. 75)

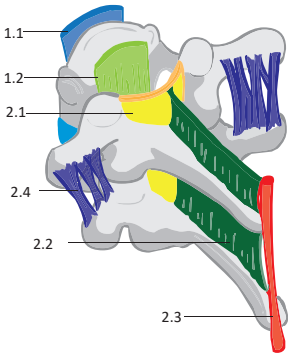

List the ligaments of the spine

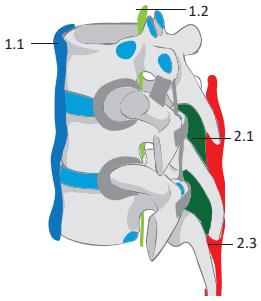

List the ligaments of the spine

IV. Thoracic joints

14. Name three main locations of connections of the true ribs to the rest of the skeleton. (p. 75)

V. Joints of the upper limb

15. Specify the type of the acromioclavicular joint. (p. 76)
16. Describe the articular cavity of the glenohumeral joint. (p. 77)
17. Describe the movements that can be performed at the shoulder joint. (p. 77)
18. Name the muscle whose tendon runs through the shoulder joint. (p. 77)
19. Name one synovial bursa in the vicinity of the shoulder joint. (p. 77)
20. Name three joints that comprise the elbow joint. (p. 78)
21. Specify the shape of the proximal radioulnar joint. (p. 78)
22. Describe the neutral position of the elbow joint. (p. 78)
23. Name the three main ligaments of the elbow joint. (p. 78)
24. Describe the course of interosseous membrane and explain the term “oblique cord”. (p. 79)
25. Describe the movements that can be performed in the proximal and distal radioulnar joint. (p. 79)
26. Specify the type and shape of the wrist joint and list the structures that articulate in it. (p. 79)
27. Name the articular head and fossa of the midcarpal joint. (p. 80)
28. Specify the shape of the metacarpophalangeal joints and describe the movements that can be performed in them. (p. 80)
29. Give an example of a saddle joint in the hand and describe the movements that can be performed in it. (p. 80)

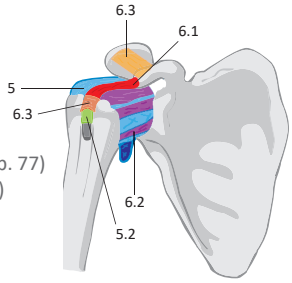

Describe the structures of the shoulder joint

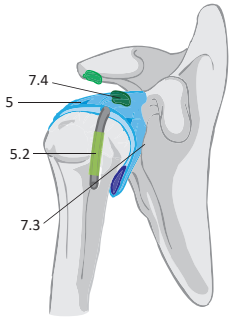

Describe the structures of the shoulder joint

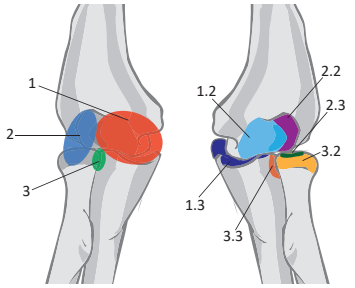

Describe the components of the elbow joint

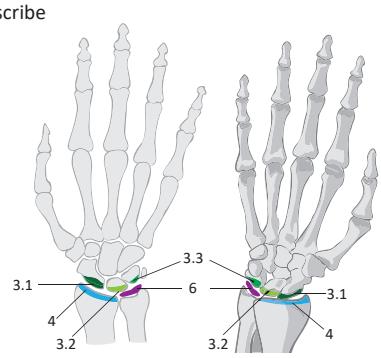

Describe the articular surfaces of the wrist joint

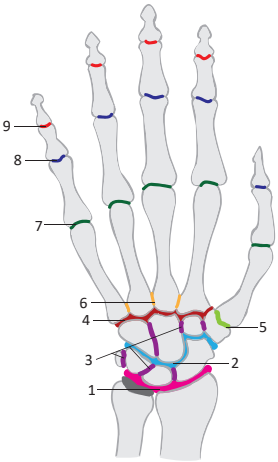

Describe the joints of the hand

VI. Joints of the lower limb

30. State the name of the articular fossa of the hip joint. (p. 83)
31. Name the structure that enlarges the acetabulum and state which tissue it is made of. (p. 83)
32. Name the ligament that limits extension of the hip joint and specify where this ligament attaches on the femur. (p. 83)
33. Explain what is the "zona orbicularis" of the hip joint. (p. 83)
34. Describe the movements (including their range) that can be performed in the hip joint. (p. 83)
35. Explain the term "retinacula of Weitbrecht". (p. 83)
36. Name three synovial bursae in the vicinity of knee joint. (p. 84)
37. Name 4 intra-articular ligaments of the knee joint. (p. 85)
38. State the structure that attaches to the medial meniscus and limits its movability. (p. 85)
39. Describe flexion of the knee joint and name its three phases. (p. 85)
40. Describe the neutral position of the knee joint. (p. 85)
41. Describe the difference between the proximal and distal articulations of the tibia and fibula. (p. 86)
42. Specify the type and shape of the ankle joint. (p. 87)
43. Name 4 ligaments that form the medial ligament of the ankle joint. (p. 87)
44. Describe the "Chopart's joint". (p. 89)
45. Describe the bifurcate ligament (p. 89)
46. List the two rows of bones that form the medial and lateral longitudinal arches of the foot. (p. 89)
47. Name 4 muscles that support the transverse arch of the foot. (p. 89)
48. Name three muscles that support the longitudinal arch of the foot. (p. 89)

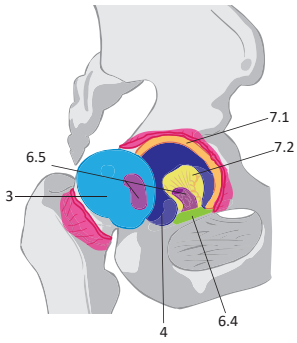

Name the components of the hip joint

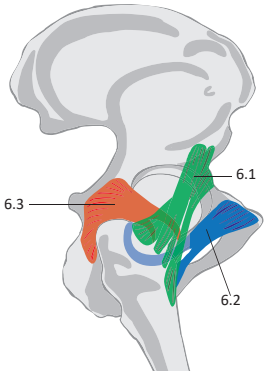

List the ligaments of the hip joint

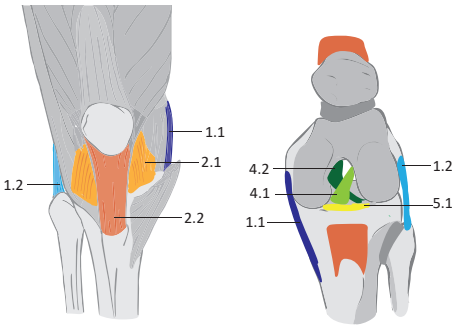

Name the ligaments of the knee joint

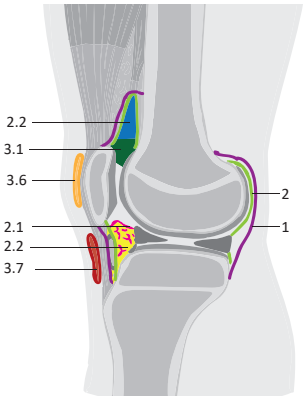

Describe the knee joint

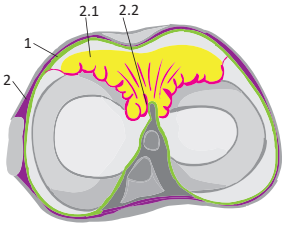

Describe the knee joint

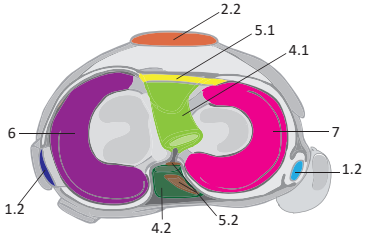

Describe the knee joint

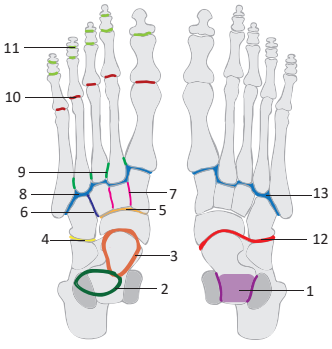

Describe the joints of the foot

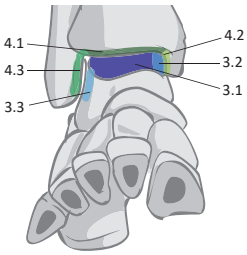

Describe the articular surfaces of the ankle joint

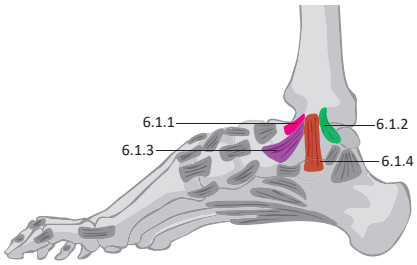

List the ligaments of the ankle joint

This copy belongs to ali yaghoubi

We would like to **thank the following anatomists, physicians and medical students** for their invaluable help, devotion and feedback in the preparation of this chapter.

Anatomists

Assoc. prof. Václav Báča, MD, PhD – Department of Anatomy, Third Faculty of Medicine, Prague, Czech Republic
Georg Feigl, Univ.-Ass. OA Priv.-Doz. Dr.med.univ. – Medical University of Graz, Institute of Anatomy, Austria
Trifon Totlis, MD PhD – Laboratory of Anatomy, Medical School, Aristotle University of Thessaloniki, Macedonia, Greece
Quentin Fogg, PhD – Centre for Human Anatomy Education, Monash University, Melbourne, Australia

Clinicians

Assoc. prof. Vojtěch Havlas, MD, PhD – Department of Orthopaedics, Second Faculty of Medicine, Charles University in Prague and Motol University Hospital, Czech Republic

Medical students

Lucie Mládenková
Eva Fürstová

10 References

1. AGUR, A. M. R. and A. F. DALLEY. Grant's Atlas of Anatomy. 13th Ed. Philadelphia: Lippincot Williams & Wilkins, 2012, 888 p. ISBN 978-1-60831-756-1.
2. BARTONÍČEK, J. and J. HEŘT. Základy klinické anatomie pohybového aparátu. 1st Ed. Praha: Jessenius Maxdorf, 2004, 256 p. ISBN 80-7345-017-8.
3. CHUNG, K. W.; CHUNG, H. M. and N. L. HALLIDAY. BRS Gross Anatomy. 8th Ed. Philadelphia: Lippincott Williams & Wilkins, 2015. 544 p. ISBN 978-1-4511-9307-7.
4. LANZ, T. and W. WACHSMUTH. Praktische Anatomie. 7 bands. Berlin: Springer, 2003, 3658 p. ISBN 978-3-540-40571-9.
5. MOORE, K. L.; DALLEY, A. F. and A. AGUR. Clinically oriented anatomy. 7th Ed. Philadelphia: Lippincot Williams & Wilkins, 2014. 1139 p. ISBN 978-1-4511-1945-3.
6. NETTER, F. H. Atlas of Human Anatomy. Professional Edition. 6th Ed. Oxford: Elsevier. 2014. 640 p. ISBN 978-1-455-75888-3.
7. SNELL, R. S. Clinical anatomy by regions. 9th Ed. Philadelphia: Lippincott Williams & Wilkins, 2012. 768 p. ISBN 978-1-60913-446-4.
8. WILLIAMS, P. L., ed. Gray´s Anatomy: the anatomical basis of medicine and surgery. 38th Ed. New York: Churchill Livingstone, 1995, 2092 p. ISBN 0-443-05717-6.

Memorix Anatomy



4 Muscles

Martin Čepelík
David Kachlík
Radovan Hudák
Adam Whitley

General overview 98
Muscles of the head 102
Muscles of the neck 110
Muscles of the back 116
Muscles of the thorax 124
Muscles of the abdomen 128
Pelvic floor muscles 131
Muscles of the upper limb 133
Muscles of the lower limb 148
Review questions and figures 166
Acknowledgements and references 168

This copy belongs to ali yaghoubi

Muscle tissue is one of the four principle tissues of the human body. It has the **ability to contract**, which generates force and enables movement. Muscle functions are enabled by **conversion of chemical energy stored in ATP into mechanical energy**. The elementary unit of muscle tissue is **the myofibril**, which contains **contractile proteins.**

Types of muscle tissue

1 **Smooth muscle** (*textus muscularis levis/nonstriatus*)
- is composed of elongated spindle-shaped cells with centrally positioned nuclei
- is derived from the splanchnic mesoderm
- forms the walls of hollow organs (such as the stomach, intestines, ureter and uterus) and blood vessels
- is found in the dermis of the skin
- maintains a degree of tension at rest, as it never completely relaxes
- contracts and relaxes slowly, so is not subjected to fatigue
- is innervated by autonomic nerves and so is not under voluntary control


Smooth muscle

2 **Skeletal muscle** (*textus muscularis striatus*)
- is composed of striated muscle fibres, which contain myofibrils
- is derived from the somites of the paraxial mesoderm
- the striated muscle fibre is a syncytium, made up of individual muscle cells that fuse during development
- contraction is mainly under voluntary control and is usually fast
- is fatigable
- is innervated by spinal and cranial nerves (somatomotor fibres)
- almost all striated muscles are attached to bones (except for some muscles of the tongue, the striated muscle of the oesophagus and the facial muscles)


Skeletal muscle

3 **Cardiac muscle** (*textus muscularis striatus cardiacus*)
- consists of individual muscle cells callled cardiomyocytes
- is under the control of the cardiac conduction system, which is influenced by autonomic nerves (not under voluntary control)
- is derived from the cardiogenic mesoderm of splanchnopleura

3.1 **Intercalated discs** (*disci intercalares*)
- connections between cardiomyocytes
- allow fast transmission of impulses

3.2 **Functional syncytium** – a functional network of cells that are connected by intercalated discs

3.3 **Conducting system of the heart** (*complexus stimulans cordis*)
- is formed by specialised cardiomyocytes capable of generating electrical impulses (cardiac automaticity)


Cardiac muscle

General structure of skeletal muscle

- 1 **Muscle** (*musculus*) – the structural unit of skeletal muscle
  - 1.1 **Fascia** – a layer of fibrous connective tissue surrounding the muscle
    - 1.1.1 **Epimysium** – a thinner layer of connective tissue between the muscle and fascia
- 2 **Bundles of muscle fibres**
  - 2.1 **Perimysium** – a layer of connective tissue that covers muscle bundles
    - consists of septa that arise from the epimysium, run through the muscle and contain vessels and nerves
    - the continuation of tendons inside the muscle, trainsmits tension through the muscle
- 3 **Muscle fibre** (*myofibra*) – the functional unit of skeletal muscle
  - several muscle fibres form a muscle bundle/fascicle
  - 3.1 **Endomysium** – a layer ensheathing individual muscle fibres
    - contains numerous capillaries

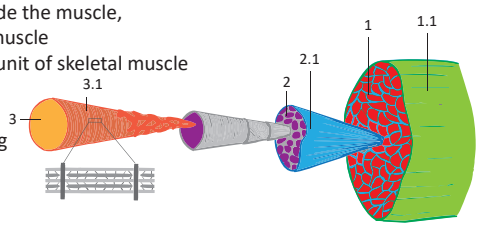

General structure of skeletal muscle

Muscles

With regard to uniformity of the description of the skeletal muscles, we have decided to use some universal abbreviations in this chapter.
O: Origin
I: Insertion
F: Function
N: Innervation

Musculus is the Latin term for muscle. Myos is the Greek term. Musculus literally means a mouse, as it was thought a muscle contraction resembles a mouse running under the skin.

Myology is the scientific study of muscle tissue.

Compartment (*compartimentum*) is a space containing a group of muscles firmly bounded by fascia.

Striated muscle is a term used for both skeletal and cardiac muscle (the myocardium) based on their histological structure.

Smooth muscle cell is 5–8 µm thick and its length ranges from 20 µm (in blood vessel wall) to 800 µm (myometrium in pregnancy).

Skeletal muscle cell is 40–80 µm thick and its length ranges form milimeters to centimetres.

Cardiac muscle cell is 15 µm thick and approximately 100 µm long.

Clinical notes

Hypertonia means increased muscle tone. It can have either an organic or a functional etiology. Hypertonic muscles are not able to fully relax.

Organic hypertonia includes rigidity (such as in Parkinsonian syndrome) and spasticity (caused by dysfunction of central motor neuron).

Functional hypertonia is caused by inner discoordination of muscle fibers (trigger points), by painful irritation or dysfunction at the level of spinal segment or limbic system.

Hypotonia and atonia may be caused by peripheral nerve damage.

Compartment syndrome is a pathological condition caused by increased intrafascial pressure, which can occur in a number of situations such as contusion causing soft tissue oedema or by compression from incorrectly applied plasters. It leads to impairment of the macrocirculation and microcirculation with subsequent development of irreversible ischemic changes and disintegration of muscle fibers (rhabdomyolysis).

Histology of skeletal muscle

1 **Polynuclear elements** – nuclei located closely to the cytoplasmic membrane (sarcolemma)
2 **Myofibrils** (*myofibrillae*) – the contractile part of the muscle fibre (are composed of myofilaments)
3 **Z-line** (*linea Z, telophragma*) – divides myofibrils into sarcomeres (sarcomera)
– responsible for the visible transverse striations of striated muscle tissue
4 **Main proteins of myofibrils**
4.1 **Actin** (*actinum*) – two chains of actin form a double helix that is anchored to the Z-line
4.2 **Tropomyosin** (*tropomyosinum*) – runs in a groove formed by actin subunits and serves as a binding site for troponin
4.3 **Troponin** (*complexus troponini*) – a complex of three subunits
4.3.1 **TnT** – binds to tropomyosin
4.3.2 **TnC** – binds calcium ions (Ca^{2+})
4.3.3 **TnI** – inhibits the bond between actin and myosin
4.4 **Myosin** (*myosinum*) – is composed of two heavy and two light chains
4.4.1 **Myosin head** – responsible for binding to actin and binding to and hydrolysing ATP
5 **Myofilaments** (*myofilamenta*) – composed of thick and thin filaments that partially overlap, even in a relaxed state
5.1 **Thick filaments** – the myosin complex in the centre of the sarcomere
5.2 **Thin filaments** – a complex of actin, tropomyosin and troponin, bound to the Z-line
6 **Sarcoplasmic reticulum** (*reticulum sarcoplasmicum*) – stores calcium ions, which are essential for muscle contraction

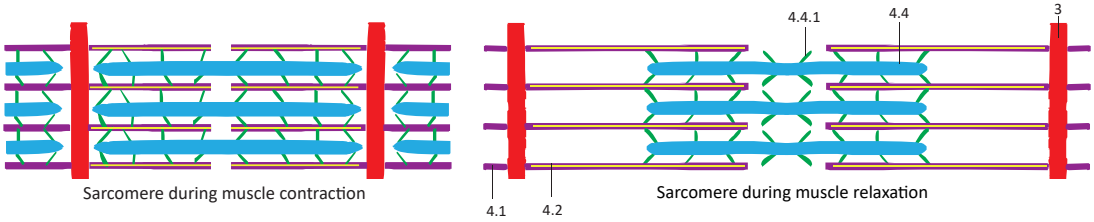

Sarcomere during muscle contraction
Sarcomere during muscle relaxation

Parts of skeletal muscle

1 **Origin** (*origo*) – the part of the muscle attached by a tendon to the bone that is closer to the axial skeleton than the insertion, this is often the least movable part
2 **Head** (*caput*) – the proximal part of a muscle, near its origin
3 **Belly** (*venter*) – the widest part of a muscle
4 **Tail** (*cauda*) – a narrow connection of a muscle belly to its insertion
5 **Insertion/attachment** (*insertio*) – part of the muscle that is attached by a tendon to a bone that is further from the axial skeleton than its origin

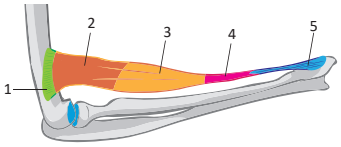

Parts of skeletal muscle

Auxiliary features of skeletal muscle

1 **Tendon** (*tendo*) – a tough fibrous collagen structure connected to muscular tissue
– attaches muscle to bone, cartilage, fibrous discs or skin
1.1 **Myotendinous junction** (*junctio myotendinea*)
– the junction between tendon and muscle
1.2 **Aponeurosis** – a flat tendon
– its architecture resembles a net of crossing fibres
2 **Fascia** – a tough fibrous tissue enveloping individual muscles or groups of muscles
2.1 **Osteofascial septum** – a fibrous (fascial) partition
– travels the superficial fascia to the periosteum
– forms particular compartments (units for individual group of muscles)
– serves as the entry and course of vessels and nerves
2.2 **Osteofibrous canal** – a fibrous (fascial) partition leading from the superficial fascia to the periosteum
– forms a space for the extensor tendons (e.g. on the dorsal side of the wrist)
2.3 **Retinaculum** – a fibrous loop
– retinacula in the wrist and ankle hold muscle tendons to the bone
– retinacula in the knee stabilise the patella

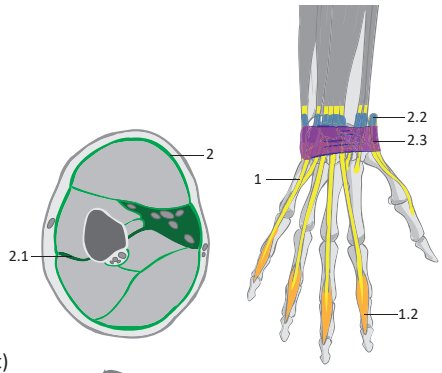

3 **Synovial bursae** (*bursa synovialis*)
– are located in regions of the highest pressure and friction from muscle tendons
– are commonly found between tendons, between tendons and bone and between tendons and skin
– decrease pressure and friction and improve the movements of tendons
4 **Tendon sheaths** (*vagina tendinis*) – envelope tendons in their passage through osteofibrous canals
4.1 **Synovial sheath** (*vagina synovialis*) – the inner layer of the sheath, made of a synovial membrane
4.2 **Fibrous sheath** (*vagina fibrosa*) – the outer layer of the sheath, provides mechanical support
4.3 **Vincula tendinum** – fibrous connections within the tendon sheath that provide nutrition

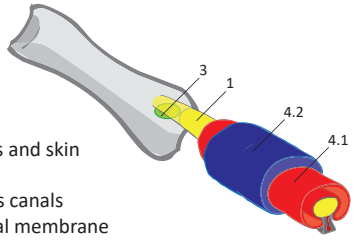

This copy belongs to ali yaghoubi

Mechanism of striated muscle contraction

1. **Depolarisation of the sarcoplasmic reticulum** – pumps Ca^{2+} ions into the sarcoplasm
2. **Binding of Ca^{2+} ions to the TnC subunit of troponin** – leads to a change in troponin configuration that allows binding of myosin to actin
3. **Hydrolysis of ATP to ADP** – energy stored in ATP bends the myosin head bound to actin – this process moves the actin filaments closer to the centre of the sarcomere
4. **ADP replaced with ATP on the myosin head** – as this occurs actin and myosin disconnect
5. **Termination of the contraction** – is completed by removal of Ca^{2+} ions from the sarcoplasm

Types of muscle fibres

Muscles contain two prinicple types of fibre: fast-twitch and slow-twitch muscle fibres.

1 Fast-twitch muscle fibres
- have a lighter color as they contain less myoglobin
- their contraction lasts less than 25 ms
- fatigue quickly
- are located in the periphery of the muscle

2 Slow-twitch muscle fibers
- are redder in color as they contain more myoglobin
- fatigue slowly
- are located in the centre of the muscle

Types of muscle contraction

1 **Isotonic contraction**
- causes the muscle length to change
- the muscle tone does not change
  - 1.1 **Concentric contraction**
    - causes the muscle to shorten
    - the force acting on the muscle is lower than the muscle strength
  - 1.2 **Eccentric contraction**
    - caues the muscle to lengthen
    - the force acting on the muscle is higher than the muscle strength

- 2 **Isometric contraction**
  - the muscle tone changes but the muscle length remains the same
  - the muscle fatigues quickly (due to limited blood supply)

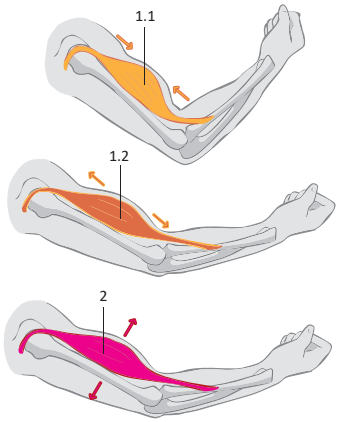

Development of skeletal muscle

Skeletal muscles are derived from the paraaxial (segmented) mesoderm. They develop from dermatomyotomes, which are parts of somites. Muscle fibres are formed from the fusion of multiple mononuclear myoblasts.

- 1 **Epaxial muscles**
  - are derived from the dorsal parts of myotomes
  - their segmentation is relatively preserved
  - are innervated by posterior branches of spinal nerves
  - the deep back muscle groups are the only epaxial muscles of the human body
- 2 **Hypaxial muscles**
  - are derived from the ventral parts of myotomes
  - include all skeletal muscles except for the deep back muscles
  - are innervated by anterior branches of spinal nerves
  - hypaxial muscle cells migrate to the limb buds to create the limb muscles

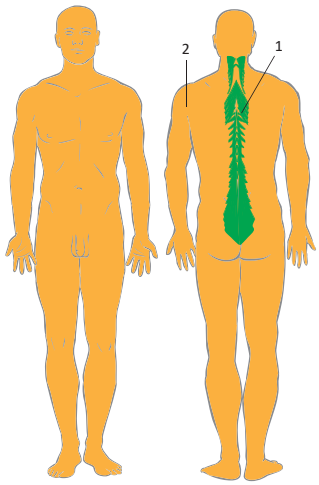

A diploneural muscle is a muscle innervated by two peripheral nerves. The pectineus is a diploneuronal muscle. It is innervated by both the obturator nerve and femoral nerve.

A plurineural muscle is a muscle innervated by more than two peripheral nerves. The rectus abdominis is a plurineural muscles. It is innervated by six intercostal nerves.

Myoglobin is a muscular protein containing heme, which binds oxygen oxygen (similar to hemoglobin). It serves as a reservoir of oxygen for muscle contraction.

Rudimentary muscle is a term used for atrophied muscle that has lost its original functions and significance (e.g. muscles of the auricle).

Somites (42–44 in number) are pairs of thickened paraxial mesoderm. They differentiate into the myotome, sclerotome and dermatome.

Fixed point (*punctum fixum*) is a part of muscle insertion which is reinforced (via influence of shortening activity of other muscles) so that the other insertion part of muscle – mobile point *(punctum mobile)* could perform movement in particular joint.

Clinical notes

Myofascial trigger points are pathological indurations inside a muscle. They are usually palpable and are characterised by increased irritability and pain. External pressure on the trigger point causes pain and twitching and even contraction of the surrounding muscles.

Post-isometric relaxation is a method used for deactivation of particular trigger points and reducing myoskeletal pain. It includes muscle extension and gentle isometric contraction followed by relaxation.

Muscle innervation

1 **Somatomotor fibres** – axons of motor neurons from the spinal cord and brainstem
– terminate at the neuromuscular junction (a type of synapse)
- 1.1 **Motor unit** – a group of muscles innervated by a single motor neuron
- 1.2 **Alpha motor neurons** (α motoneurons) – transmit impulses to individual motor units (extrafusal fibres)
- 1.3 **Gamma motor neurons** (γ motoneurons) – transmit impulses to muscle spindles (intrafusal fibres)

2 **Somatosensory innervation** – include fibres from muscle spindles and golgi tendon organs
3 **Visceromotor fibres** – autonomic motor fibres that innervate smooth muscle
– innervate blood vessels inside muscle
4 **Muscle spindle** (*fusus neuromuscularis*) – a group of intrafusal muscle fibres
– short thin fibers sheathed by a fibrous cover that is attached to tendon on one side while on the other side between muscle fibers
– provides proprioceptive sensation – control of muscle tone
– is innervated by gamma motor neurons
5 **Golgi tendon organ** / neurotendinous spindle (*organum sensorium tendinis*)
– positioned close to the border between the muscle and tendon
– consists of tendon bundles surrounded by a cover with higher excitability threshold than that of muscle spindles

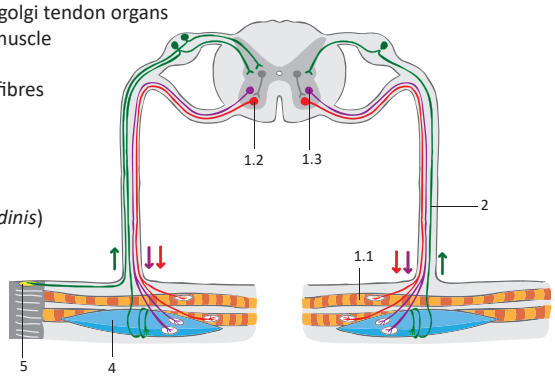

Classification of muscles

According to function

1 **Agonists** – act as the executors of movement (e.g. the deltoid)
2 **Synergists** (auxiliary) – cooperate with other muscles to produce the same movement (e.g. the supraspinatus)
3 **Antagonists** – provide movements in the opposite direction to the agonist (e.g. the latissimus dorsi)
4 **Neutralisers** – muscles that cancel unwanted movement (combined movements) of other muscles (e.g. the teres minor)
5 **Stabilisers** – muscles that stabilise certain parts of the body
– maintain the mobile segment in its optimal position for movement (e.g. the trapezius)
6 **Postural muscles** – tonic, antigravity muscles
– contain a larger proportion of slow twitch muscle fibres
– do not fatigue quickly
– maintain a stable muscle tone necessary for upright posture
– tend to shorten over time due to the chronic muscle tension
7 **Phasic muscles** – contain a larger proportion of fast twitch muscle fibres
– are able to develop great speed and power, but only for a short period of time
– tend to become flabby (hypotrophic) if they are not regularly used
8 **Main muscles** – usually one muscle from a group of agonists or synergists for a particular movement
9 **Auxiliary muscles** – muscles cooperating with the main muscle
10 **One-joint muscles** – perform movement just in one joint
11 **Multi-joint muscles** – perform movement in more than one joint
– they usually have more influence on the distal joint
– the function at the proximal joint (closer to the origin) is rather auxillary

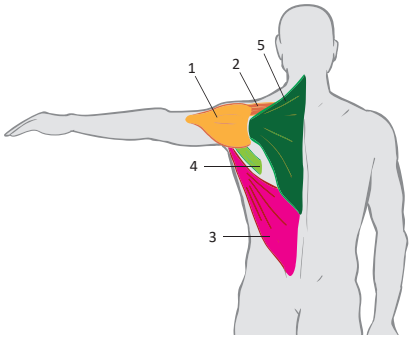

Example of a movement: abduction to the horizontal position

According to shape

1 **Fusiform** *(musculus fusiformis)* – the most common shape,
– are divided into one-headed and multi-headed muscles
– two, three and four headed muscles are termed biceps, triceps and quadriceps respectively
2 **Flat** (*musculus planus*) – are usually attached to bone by aponeurosis
3 **Orbicular** (*musculus orbicularis*) – encircle orifices of the body (e.g. orbicularis oris)
4 **Sphincter** (*musculus sphincter*) – circular muscle with the ability to close or constrict an orifice or lumen (e.g. the external sphincter of the anus)
5 **Others** – straight, triangular, pennate, semipennate and multipennate



Muscles according to shape

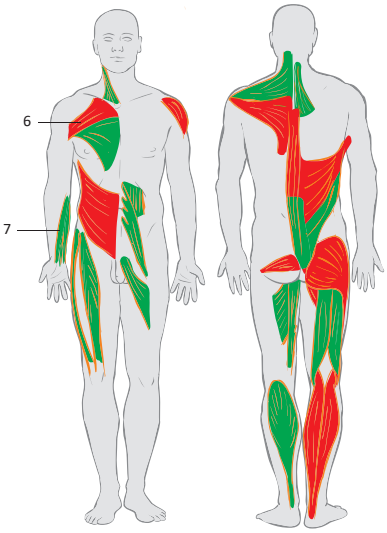

Postural and phasic muscles

This copy belongs to ali yaghoubi

According to their origin and function, **the muscles of the head** can be divided into the **facial muscles** and the **masticatory muscles**.

Facial muscles *(musculi faciei)*
– insert into the skin of the head
– are innervated by the facial nerve (n. VII)
– are not covered by fascia
(except for the buccinator)

Masticatory muscles *(musculi masticatorii)*
– insert on the mandible
– are innervated by the trigeminal nerve (n. V)
– are covered by fascia

2.1 Facial muscles – Musculi faciei

The facial muscles are derived from the second pharyngeal arch. They are **inserted into the skin of the head** and therefore form wrinkles and **control facial expression**. All facial muscles are **innervated by branches of the facial nerve (n. VII)**.

1 **Epicranial muscle group**
- 1.1 **Epicranius** *(musculus epicranius)*
  - 1.1.1 **Occipitofrontalis** *(musculus occipitofrontalis)*
  - 1.1.2 **Temporoparietalis** *(musculus temporoparietalis)*

2 **Circumorbital and palpebral muscle groups**
- 2.1 **Orbicularis oculi** *(musculus orbicularis oculi)*
- 2.2 **Procerus** *(musculus procerus)*
- 2.3 **Corrugator supercilii** *(musculus corrugator supercilii)*
- 2.4 **Depressor supercilii** *(musculus depressor supercilii)*

3 **Nasal muscle group**
- 3.1 **Nasalis** *(musculus nasalis)*
- 3.2 **Levator labii superioris alaeque nasi** *(musculus levator labii superioris alaeque nasi)*
- 3.3 **Depressor septi nasi** *(musculus depressor septi nasi)*

4 **Auricular muscle group**
- 4.1 **Auricularis anterior** *(musculus auricularis anterior)*
- 4.2 **Auricularis superior** *(musculus auricularis superior)*
- 4.3 **Auricularis posterior** *(musculus auricularis posterior)*

5 **Buccolabial muscle group**
- 5.1 **Orbicularis oris** *(musculus orbicularis oris)*
- 5.2 **Levator labii superioris** *(musculus levator labii superioris)*
- 5.3 **Zygomaticus minor** *(musculus zygomaticus minor)*
- 5.4 **Zygomaticus major** *(musculus zygomaticus major)*
- 5.5 **Levator anguli oris** *(musculus levator anguli oris)*
- 5.6 **Risorius** *(musculus risorius)*
- 5.7 **Depressor anguli oris** *(musculus depressor anguli oris)*
- 5.8 **Depressor labii inferioris** *(musculus depressor labii inferioris)*
- 5.9 **Mentalis** *(musculus mentalis)*
- 5.10 **Buccinator** *(musculus buccinator)*

6 **Modiulus** *(modiulus anguli oris)* – the "motor centre of the face"

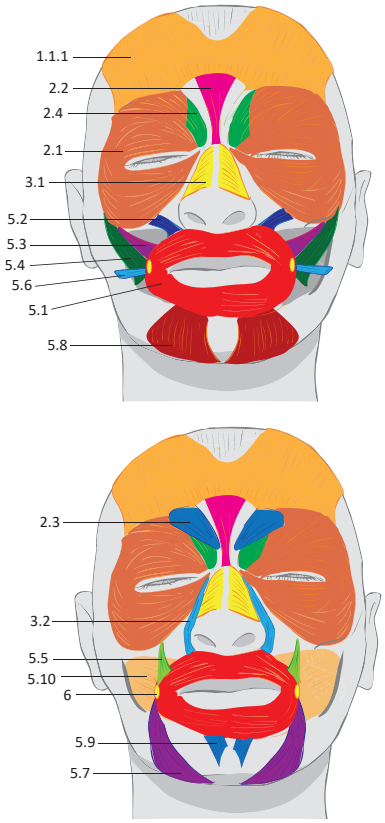

Muscles of the eye and orbit
see page 515.
Muscles of the soft palate
see page 179.
Muscles of the middle ear
see page 507.
Muscles of the tongue
see page 177.

The modiolus (*modiolus anguli oris*, "corner spindle") is a centre for the insertion of several facial muscles. It is known as the "motor centre of the human face". Muscle fibres of the buccinator, depressor anguli oris, levator anguli oris and zygomaticus major insert into the marginal part of the orbicularis oris at the modiolus.

SMAS is an abbreviation for the superficial muscular-aponeurotic system. It is a fibromuscular layer found on the head that covers the facial muscles. It is more developed over the calvaria as the epicranial aponeurosis (*galea aponeurotica*) and on the face.

The thin subgalear connective tissue is a low-resistance area that facilitates scalping (removing the scalp from the bone).

Clinical notes

The frontal belly of the occipitofrontalis may contain very painful myofascial trigger points. It is typically caused by overloading of the ipsilateral sternocleidomastoid. This trigger point may be released by traction of the occipitofrontalis.

Trigger points in the temporoparietalis may be activated by disorders of the temporomandibular joint and can occur in the cervico-cranial syndrome.

The epicranius is a **flat muscle of the cranial vault**. It consists of two main parts connected by a flat tendon called the **epicranial aponeurosis**.

Epicranius *(musculus epicranius)*

- 1 1 **Epicranial aponeurosis** *(galea aponeurotica)*
  - – forms the largest middle part of the muscle
  - – an aponeurotic tendinous structure
  - – is connected to the periosteum of the cranial vault by tenuous fibrous tissue, thus is freely movable over the skull
- 2 **Occipitofrontalis** *(musculus occipitofrontalis)*
  - 2.1 **Frontal belly** *(venter frontalis)*
    - **O:** epicranial aponeurosis – ventral margin
    - **I:** skin of the eyebrows and glabella
    - **F:** elevates the skin of the forehead, forms horizontal wrinkles of the forehead, contributes to elevation of the upper eyelid and creates expressions of attention and astonishment
    - **N:** facial nerve – temporal branches
  - 2.2 **Occipital belly** *(venter occipitalis)*
    - **O:** occipital bone – highest nuchal line (lateral 2/3)
    - **I:** epicranial aponeurosis – dorsal margin
    - **F:** pulls the epicranial aponeurosis dorsally, stabilises the epicranial aponeurosis and assists the frontal belly in the elevation of the upper eyelids
    - **N:** facial nerve – occipital branch of the posterior auricular nerve
- 3 **Temporoparietalis** *(musculus temporoparietalis)*
  - **O:** auricle – internal aspect
  - **I:** epicranial aponeurosis – at the height of the superior temporal line
  - **F:** movements of the auricle – cranially, ventrally and dorsally
  - **N:** facial nerve – occipital branch of the posterior auricular nerve

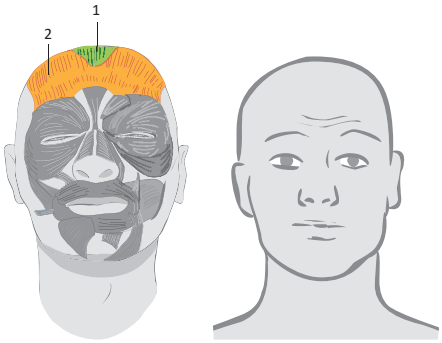



2.1 Facial muscles – auricular muscle group

The intrinsic muscles of the external ear are **rudimentary muscles** that originate and insert on the lateral surface of the auricle. **The extrinsic muscles of the external ear** insert on **the root of the auricle**. The extrinsic muscles consist of the anterior, superior and posterior auricularis as well as the temporoparietalis. Their common function is **movement of the auricle**. They have no practical importance in humans.

Extrinsic muscles of external ear

- 1 **Auricularis anterior** *(musculus auricularis anterior)*
  - **O:** temporal fascia
  - **I:** auricle – spine of helix
  - **F:** cranial and ventral movements of the auricle
  - **N:** facial nerve – temporal branches
- 2 **Auricularis superior** *(musculus auricularis superior)*
  - **O:** epicranial aponeurosis
  - **I:** auricle – eminence of triangular fossa
  - **F:** cranial movement of the auricle
  - **N:** facial nerve – temporal branches
- 3 **Auricularis posterior** *(musculus auricularis posterior)*
  - **O:** temporal bone – mastoid process
  - **I:** auricle – eminence of concha
  - **F:** dorsal movement of the auricle
  - **N:** facial nerve – posterior auricular branch

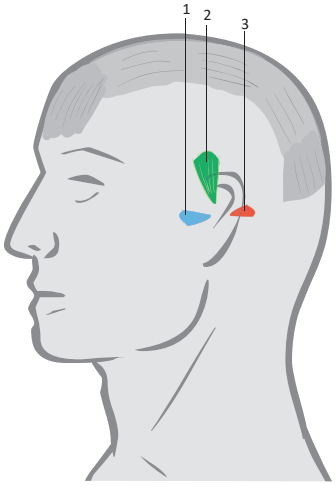

This copy belongs to ali yaghoubi

The nasal muscle group consists of three muscles that insert and act on the nose. **The nasalis** has two parts according to the course of its fibers: the transverse part (compressor naris) and the alar part (dilatator naris). The transverse part **constricts the nostrils** and the alar part **dilates** them.

Nasalis *(musculus nasalis)*

- 1 **Tranverse part** *(pars transversa)*
  - **O:** maxilla – anterior surface
  - **I:** dorsal aponeurosis of the nose
  - **F:** constricts the nostrils
  - **N:** facial nerve – buccal branches
- 2 **Alar part** *(pars alaris)*
  - **O:** maxilla – anterior surface
  - **I:** skin of the nasal wing, lateral crus of major alar cartilage
  - **F:** dilates the nostrils
  - **N:** facial nerve – buccal branches

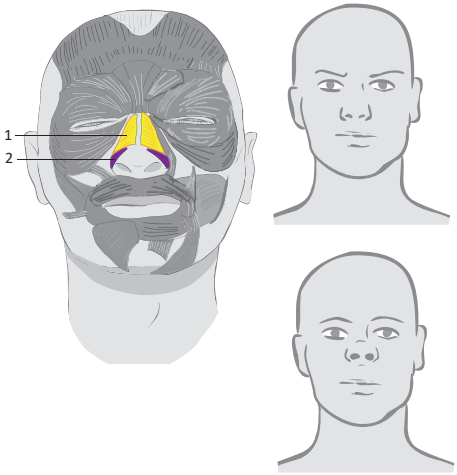

Levator labii superioris alaeque nasi *(musculus levator labii superioris alaeque nasi)*

O: maxilla – frontal process
I: skin of the nasal wing (major alar cartilage), lateral part of the upper lip
F: dilates the nostrils, elevates the upper lip, elevates and smooths out the nasolabial sulcus produces an expression of discontent
N: facial nerve – buccal branches

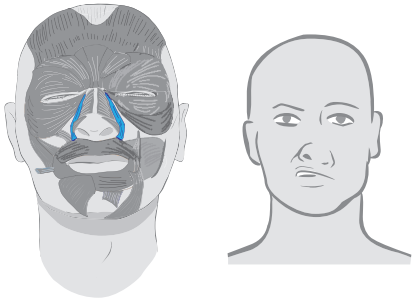

Depressor septi nasi *(musculus depressor septi nasi)*

O: incisive fossa on the anterior surface of the maxilla
I: nasal septum – mobile part nasalis – alar part (dorsal aspect)
F: depresses the nasal septum, dilates the nares, moves the apex of the nose during movements of the upper lip (e.g. during speech)
N: facial nerve – buccal branch and zygomatic branch

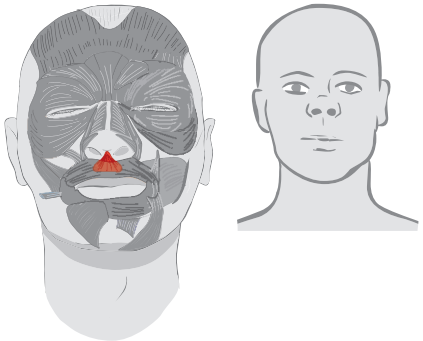

Compressor naris is an obsolete term for the transverse part of the nasalis.

Dilatator nasi is an obsolete term for the alar part of the nasalis.

The muscle of Elvis is a laic term used for the levator labii superioris alaeque nasi. Its contraction produces a facial expression famously associated with Elvis Presley.

The levator labii superioris alaeque nasi has the longest name of any muscle of the human body.

Clinical notes

The auxiliary muscle fibres of the frontal belly of the occipitofrontalis insert into the orbicularis oculi and contribute to the elevation of the upper eyelid. These fibres may help in eye opening in palsy of the oculomotor nerve (n. III).

The orbicularis oculi is an annular muscle located around the orbital opening. It is composed of two main parts: the orbital part and the palpebral part. **The orbital part** forms the peripheral part of the muscle and is located around the orbital opening. **The palpebral part** covers the eyelids. The main function of orbicularis oculi is to **close the eyelids and thus to narrow the palpebral fissure.**

Orbicularis oculi *(musculus orbicularis oculi)*

- 1 **Orbital part** *(pars orbitalis)*
  – the peripheral part of the muscle
  O: frontal bone – nasal part
  maxilla – frontal process
  medial palpebral ligament (a ligament that connects the medial angle of the eyelids to the frontal process of the maxilla)
  I: lateral palpebral ligament (a ligament that connects the lateral margin of the eyelids to the zygomatic bone
- 2 **Palpebral part** *(pars palpebralis)*
  – located in the upper and lower eyelids
  O: medial palpebral ligament
  I: lateral palpebral raphe
  2.1 **Deep part** *(pars profunda partis palpebralis)*
  O: lacrimal bone – posterior lacrimal crest and lacrimal fascia
  I: tarsal plates of the upper and lower eyelids
  F: dilates the lacrimal sac, which aids the drainage of tears

Function:
firm closure of the eye lids,
creates wrinkles extending outwards from the lateral angle of the eye (crow's feet)

Innervation:
facial nerve – temporal and zygomatic branches

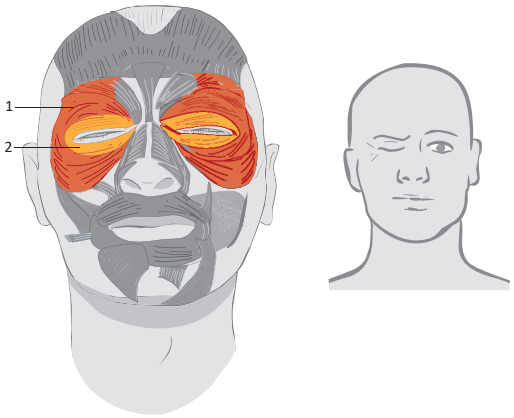

Procerus *(musculus procerus)*

O: fascia of the dorsum of the nose
I: skin of the inferior part of the forehead
F: forms a horizontal wrinkle on the root of the nose, located over the glabella
N: facial nerve – buccal branches

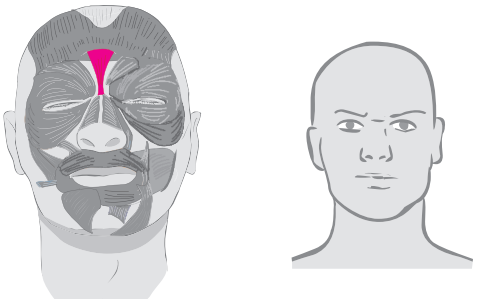

Corrugator supercilii *(musculus corrugator supercilii)*

O: frontal bone – above the frontonasal suture and on the medial end of the supercilliary arch of the frontal bone
I: skin of the middle part of the eyebrows
F: pulls the eyebrows mediocaudally and forms vertical wrinkles above the root of the nose, forming facial expressions of frowning and pain
N: facial nerve – temporal branches

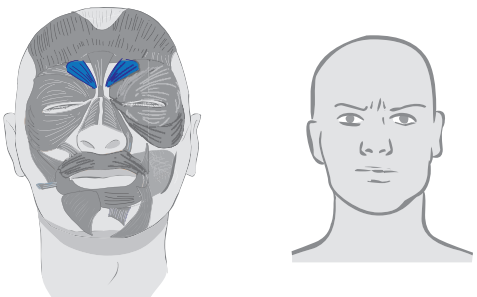

Depressor supercilii *(musculus depressor supercilii)*

O: orbicularis oculi – upper part of the orbital part
I: skin of the eyebrows
F: depresses the eyebrows
N: facial nerve – temporal branches

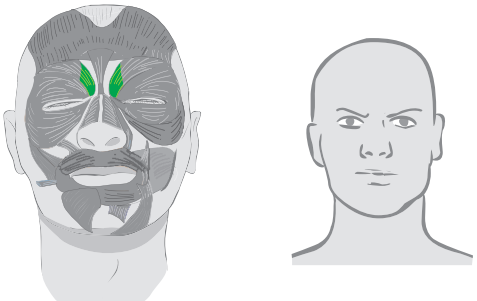

This copy belongs to ali yaghoubi

The orbicularis oris is a complex annular muscle located around the oral opening on **the upper and lower lips**. It consists of two parts: the marginal part and the labial part. **The marginal part** consists of the outer fibers and lies closer to the bone. The **labial part** lies within the lips. **The buccinator** is the deepest of the facial muscles and is located in **the cheek**.

Orbicularis oris *(musculus orbicularis oris)*

- 1 **Marginal part** *(pars marginalis)*
  – outer fibers, are located close to the bone
- 2 **Labial part** *(pars labialis)*
  – gives shape to the lips
- 3 **Modiolus** *(modiolus anguli oris)*
  – a chiasma (crossing of fibres) of the facial muscles located at the angle of the mouth

O: the fibres are arranged in a circle around the lips and can be divided into four segments corresponding to the four quadrants of the lips
I: labial part: fuses with the contralateral part, in the skin of the lips
F: closes the lips, presses the lips against the teeth, with stronger contraction of the marginal part it protrudes the lips (puckers the lips)
N: facial nerve – buccal branches

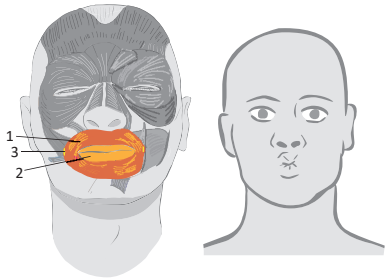

Levator labii superioris *(musculus levator labii superioris)*

O: maxilla – under the caudal border of the orbit, but above the infra-orbital foramen
I: upper lip and skin of the nasolabial sulcus
F: elevates the nasolabial sulcus, expressing happiness
N: facial nerve – buccal branches

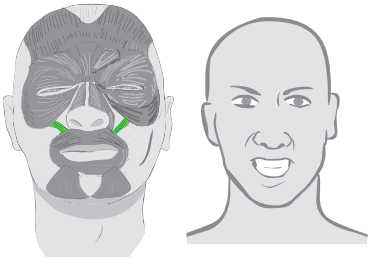

Zygomaticus minor *(musculus zygomaticus minor)*

O: zygomatic bone – medial to the zygomaticus major
I: upper lip
F: elevates the lateral third of the nasolabial sulcus, producing a smile and an expression of compassion
N: facial nerve – zygomatic branches

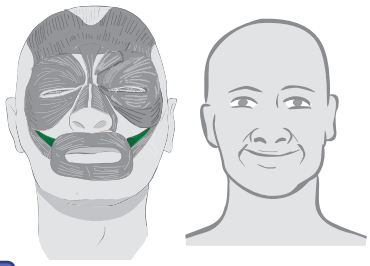

Zygomaticus major *(musculus zygomaticus major)*

O: zygomatic bone – temporal process (laterally to the zygomaticus minor)
I: modiolus
F: pulls the angle of the mouth laterocranially, producing an expression of an ironic smile
N: facial nerve – zygomatic branches

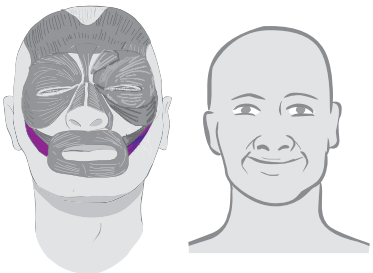

The mentalis is also known as the muscle of pride. Its contraction creates an expression of scorn.

The buccinator is also known as the trumpeter's muscle.

The levator labii superioris is divided according to its origins into:
1 **angular part** (*pars angularis*)
– originates on the frontal process of the maxilla
2 **infraorbital part** (*pars infraorbitalis*)
– originates above the infra-orbital foramen
3 **zygomatic part** (*pars zygomatica*)
– originates on the zygomatic bone, behind the zygomaticomaxillary suture

Clinical notes

Both central and peripheral palsies of the facial nerve (n. VII) cause impairment and weakness of the buccinator. This leads to an inability to puff out the cheeks and whistle.

Levator anguli oris *(musculus levator anguli oris)*

O: maxilla – anterior surface
(canine fossa – beneath infraorbital foramen)
I: modiolus
F: elevates the angle of the mouth, producing a smile
N: facial nerve – buccal branches

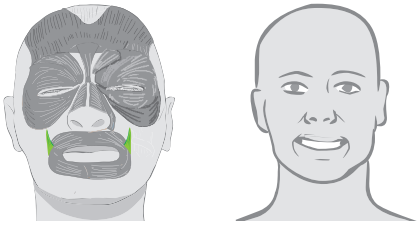

Risorius *(musculus risorius)*

O: masseteric fascia
I: modiolus
F: moves the angle of the mouth laterally,
stretches the oral opening, producing a smile
N: facial nerve – buccal branches

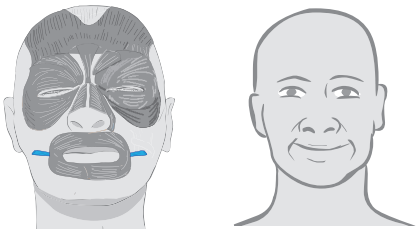

Depressor anguli oris *(musculus depressor anguli oris)*

O: mandible – inferior border
I: modiolus
F: depresses the angle of the mouth, producing
an expression of sadness
N: facial nerve – marginal mandibular branch

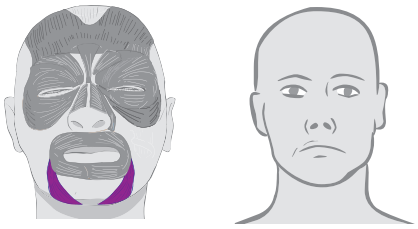

Depressor labii inferioris *(musculus depressor labii inferioris)*

O: mandible – inferior border (under the depressor anguli oris)
I: skin of the lower lip
F: depresses the lower lip and pulls the lower lip laterally,
producing an expression of contempt
N: facial nerve – marginal mandibular branch

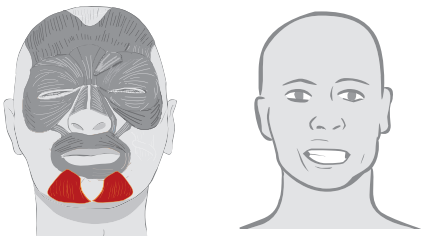

Mentalis *(musculus mentalis)*

O: mandible – alveolar yoke of the second incisor
I: skin of the chin (fibres run mediocaudally)
F: pulls the lower lip upwards and foward, producing
an expression of scorn
N: facial nerve – marginal mandibular branch

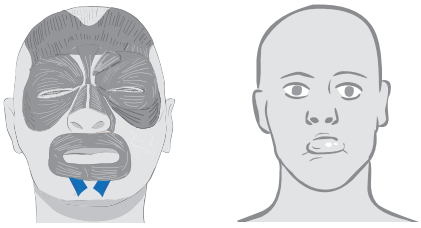

Buccinator *(musculus buccinator)*

O: maxilla and mandible – alveolar yokes of the molars,
pterygomandibular raphe (fibres running from the pterygoid
hamulus to the medial surface of the border
between the body and ramus of the mandible)
I: modiolus,
fibres of the orbicularis oris of both the upper and lower lips
F: presses the cheeks against the teeth and gums
(moves food between the molars),
squeezes air out of the oral cavity when the mouth is open,
prevents compression of the cheeks during mastication (chewing)
N: facial nerve – buccal branches

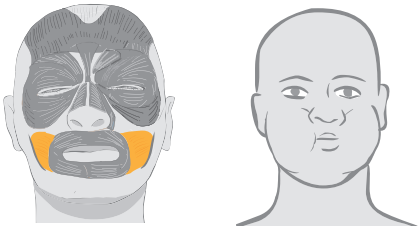

This copy belongs to ali yaghoubi

The masticatory muscles are derived from the first pharyngeal arch. They insert on the **mandible** and perform **masticatory (chewing) movements**. All masticatory muscles are **innervated by the mandibular nerve (n. V3)**.

Masticatory muscles

- 1 **Temporalis / temporal muscle** *(musculus temporalis)*
- 2 **Masseter** *(musculus masseter)*
- 3 **Medial pterygoid** *(musculus pterygoideus medialis)*
- 4 **Lateral pterygoid** *(musculus pterygoideus lateralis)*

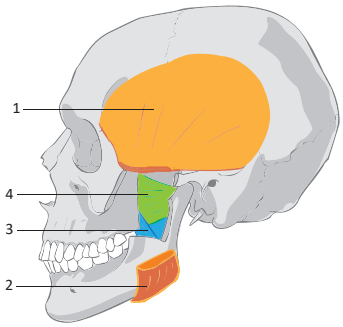

Temporalis / temporal muscle *(musculus temporalis)*

O: temporal fossa,
parietal bone – inferior temporal line
I: mandible – coronoid process and temporal crest
F: elevates the mandible (anterior fibers),
retracts the mandible (posterior fibers),
maintains the static position of
the mandible (closed mouth),
generates static tension in the masticatory muscles
N: mandibular nerve (n. V3) – deep temporal nerves

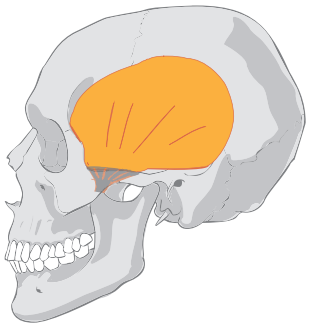

Masseter *(musculus masseter)*

Parts: superficial part and deep part
Innervation of the muscle:
mandibular nerve (n. V3) – masseteric nerve

- 1 **Superficial part** *(pars superficialis)*
  O: zygomatic process of maxilla,
  zygomatic arch (anterior part)
  Course of fibres: dorsocaudal
  I: mandible – masseteric tuberosity
  F: elevates the mandible,
  protracts the mandible (only the superficial part)

- 2 **Deep part** *(pars profunda)*
  O: zygomatic arch (posterior part)
  Course of fibers: caudal (ventrocaudal in newborns)
  I: mandible – ramus of mandible (deep part)
  and coronoid process
  F: elevates the mandible

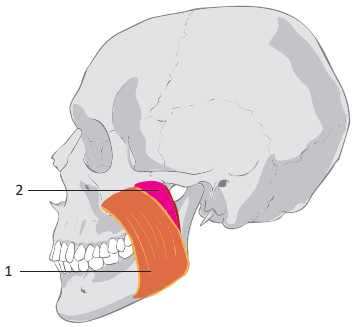

Newborns and suckling infants activate the deep part of the masseter, which protracts and retracts the mandible during breast-feeding

The temporalis maintains a degree of muscle tone during mastication. Thus, it typically atrophies in people without teeth.

The angular tract / mandibulostylohyoid ligament (*tractus angularis*) is a strengthened band of the parotideomasseteric fascia. It runs from the angle of the mandible to the stylohyoid ligament and hyoid bone and separates the parotideomasseteric region from the submandibular triangle (i.e. separates the parotid and submandibular glands).

Clinical notes

The temporalis is a wide muscle that has a predilection to develop trigger points. Pain from its anterior part typically radiates above the orbit and into the superior canines. Trigger points located in front of the auricle radiate into the superior molars.

Extensive chewing of a chewing gum in chronic stress conditions in predisposed persons can cause **overloading of the masseter**. Pain is not situated inside the muscle, contrarily the typical complaint is pain radiating into the superior and inferior molars, ear or above the orbit.

Trigger points in the medial and lateral pterygoids may lead to ear pain. Thus, it is important to consider this disorder when diagnosing a patient with ear pain. Trigger points may be released by the postisometric relaxation method described above. Both muscles and trigger points are palpable through the mouth.

Medial pterygoid *(musculus pterygoideus medialis)*

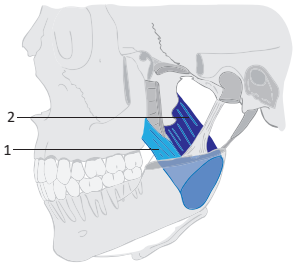

Origin:
- 1 **Superficial part** *(pars superficialis)*: maxilla – maxillary tuberosity
- 2 **Deep part** *(pars profunda)*: sphenoid bone (pterygoid process) – pterygoid fossa

I: mandible – pterygoid tuberosity
F: elevation of the mandible (bilateral contration),
lateropulsion of the mandible (unilateral contraction) – frictional masticatory movements
N: mandibular nerve (n. V3) – nerve to medial pterygoid

Lateral pterygoid *(musculus pterygoideus lateralis)*

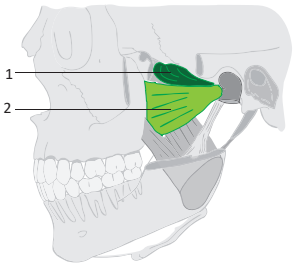

Origin:
- 1 **Upper/superior head** *(caput superius)*: sphenoidal bone (greater wing)
  – infratemporal surface and crest
- 2 **Lower/inferior head** *(caput inferius)*: sphenoidal bone (pterygoid process)
  – lateral plate

I: mandible (condylar process) – pterygoid fovea,
temporomandibular joint (articular capsule and its disc)
F: protraction of the mandible (bilateral contraction),
lateropulsion of the mandible (unilateral contraction) – frictional masticatory movements,
contributes to the opening of the oral fissure by pulling the condylar process
and articular disc of the temporomandibular joint ventrally
N: mandibular nerve (n. V3) – nerve to lateral pterygoid

2.3 Fasciae of the head

As the facial muscles insert into the skin they do not have a continuous fascial covering. Fasciae cover **the parotid gland, masticatory muscles and some of the buccinator**.

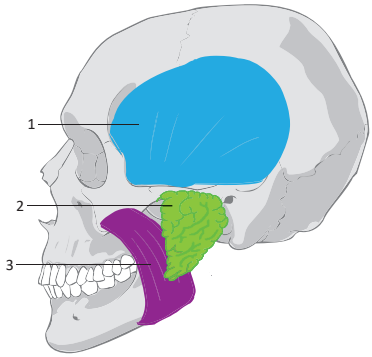

- 1 **Temporal fascia** *(fascia temporalis)*
  – 2 layers: a superficial layer and a deep layer
  – cranial attachment and border: superior temporal line
  – caudal attachment and border: zygomatic arch
- 2 **Parotid fascia** *(fascia parotidea)*
  – covers the parotid gland
  – partially fuses with the masseteric fascia
  forming the parotideomasseteric fascia
- 3 **Masseteric fascia** *(fascia masseterica)*
  – covers the masseter
  – cranial attachment and border: zygomatic arch
  – ventral attachment and border: ramus of mandible (ventral margin)
  – dorsal attachment and border: partially fuses with the parotid fascia
  forming the parotideomasseteric fascia
  – caudal attachment and border:
  continuous with the superficial layer of the cervical fascia
- 4 **Buccopharyngeal fascia** *(fascia buccopharyngea)*
  – covers the buccinator
  – dorsal attachment and border:
  connects to the pterygomandibular raphe,
  continues into the fibrous tissue of the pharynx

  5 **Interpterygoid plate** *(lamina interpterygoidea)*
  – a fibrous plate between the pterygoid muscles
  – cranial attachment and border: base of the skull
  – caudal attachment and border: mandible
- 6 **Buccal fat pad/ Bichat's fat pad** *(corpus adiposum buccae)*
  – is located in the infratemporal fossa
  – is divided into 3 lobes (anterior, intermediate and posterior lobes)
  – extends to four processes (buccal, temporal, pterygoid
  and pterygopalatine processes)

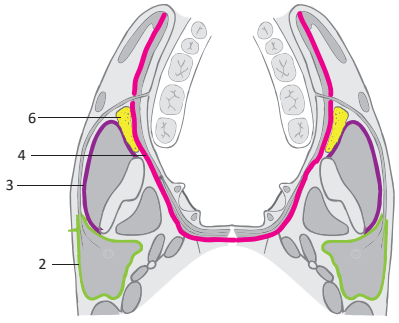

Transverse section at the level of C1

This copy belongs to ali yaghoubi

The muscles of the neck can be divided into **5 groups**: the superficial muscle group, the suprahyoid muscles, the infrahyoid muscles, the scaleni and the deep muscle group.

1 **Superficial muscle group**
(musculi colli superficiales)
- 1.1 **Platysma**
- 1.2 **Sternocleidomastoid**
  (musculus sternocleidomastoideus)

2 **Suprahyoid muscles** *(musculi suprahyoidei)*
- 2.1 **Digastric**
  (musculus digastricus)
- 2.2 **Stylohyoid**
  (musculus stylohyoideus)
- 2.3 **Mylohyoid**
  (musculus mylohyoideus)
- 2.4 **Geniohyoid**
  (musculus geniohyoideus)

3 **Infrahyoid muscles** *(musculi infrahyoidei)*
- 3.1 **Sternohyoid**
  (musculus sternohyoideus)
- 3.2 **Sternothyroid**
  (musculus sternothyroideus)
- 3.3 **Thyrohyoid**
  (musculus thyrohyoideus)
- 3.4 **Omohyoid**
  (Musculus omohyoideus)

4 **Scaleni** *(musculi scaleni)*
- 4.1 **Scalenus anterior / anterior scalene**
  (musculus scalenus anterior)
- 4.2 **Scalenus medius / middle scalene**
  (musculus scalenus medius)
- 4.3 **Scalenus posterior / posterior scalene**
  (musculus scalenus posterior)
- 4.4 **Scalenus minimus**
  (musculus scalenus minimus)

5 **Deep muscle group** *(musculi colli profundi)*
- 5.1 **Longus capitis**
  (musculus longus capitis)
- 5.2 **Longus colli**
  (musculus longus colli)
- 5.3 **Rectus capitis anterior**
  (musculus rectus capitis anterior)
- 5.4 **Rectus capitis lateralis**
  (musculus rectus capitis lateralis)

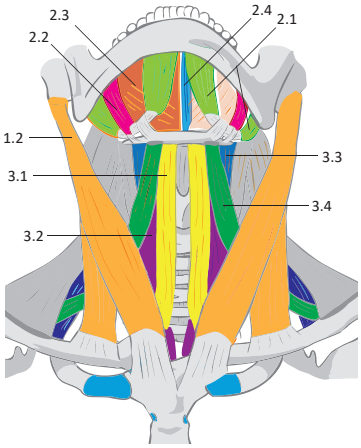

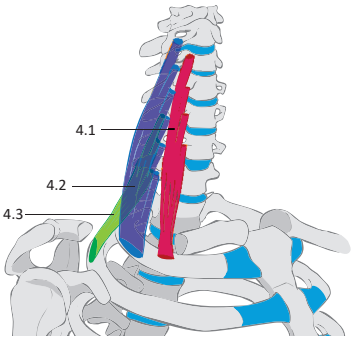

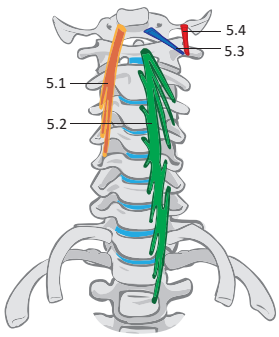

Pharyngeal muscles see page 184.

Laryngeal muscles see page 213.

Nuchal muscles see page 123.

Clinical notes

Trigger points in the platysma cause pain on the lateral side of the mandible. This pain is commonly described as prickling.

Pain in the sternocleidomastoid can radiate to various parts of the body, such as the forehead, eyes, ears and vertex.

Trigger points in the sternocleidomastoid may lead to postural instability and impairment in motion perception. A patient develops difficulties in perception of the initiation and termination of particular movements. This occurs most commonly during traveling in vehicles.

Trigger points in the sternocleidomastoid may be activated by the bird watching posture (a forward position of the head with retroflexion at the atlantooccipital joint)

Increased tone in the sternocleidomastoid may lead to impairment in swallowing. It has to be differentiated from other disorders leading to problems with swallowing by the following maneuver: the patient is in the supine position, the muscle is gripped by examiner's fingers as in pincers and the patient is requested to swallow. If pain does not occur, it is caused by the sternocleidomastoid.

Torticollis is a shortening (spasm or dystonia) of the sternocleidomastoid causing the head to tilt to the affected side and rotate towards the unaffected side.

The superficial muscles of the neck consist of two muscles: the platysma and the sternocleidomastoid. **The platysma** is located above to the cervical fascia and **the sternocleidomastoid** is embedded with it. These two muscles have a different origins, insertions and innervations. They are united only by their **superficial location in the neck**.

Platysma

O: pectoral and deltoid fascia (below the clavicle)
I: mandibular part: mandible – caudal margin,
labial part: lower lip – lateral part,
modiolar part: skin around the angle of the mouth (at the modiolus)
F: controls tension in the skin of the neck,
contributes to depression of the angle of the mouth and mandible
N: facial nerve – cervical branch

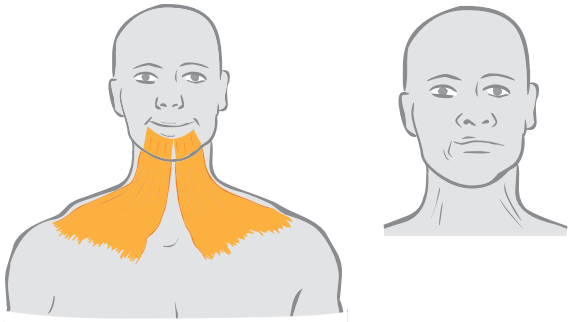

Sternocleidomastoid *(musculus sternocleidomastoideus)*

Origin:
- 1 **Sternal part** *(pars sternalis)*: sternum – manubrium of sternum
- 2 **Clavicular part** *(pars clavicularis)*: clavicle – sternal end

– the two origins form the lesser supraclavicular fossa which is located between them
– the jugular fossa is located between the sternal origins of the sternocleidomastoids of each side

I: temporal bone – mastoid process,
occipital bone – superior nuchal line (lateral margin)
F: ventral flexion of the head (anterior fibers),
dorsal flexion of the head (posterior fibers),
protraction of the head (bilateral contraction),
lateroflexion of the head to the side of the contracted muscle and rotation of the head to the opposite side (unilateral contraction)
N: accessory nerve (n. XI),
additional fibres from the anterior rami of the spinal nerves C2–C4

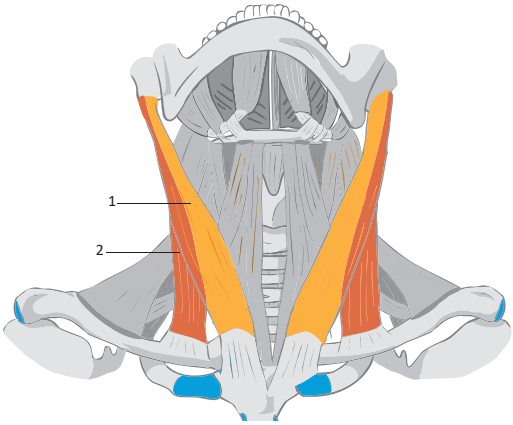

This copy belongs to ali yaghoubi

The suprahyoid muscles are located within the **superficial layer of the cervical fascia and cranially to the hyoid bone**. The common function of the suprahyoid muscles is **movement of the hyoid bone**. Additionally, some of the suprahyoid muscles **act on the mandible**.

Digastric *(musculus digastricus)*

– the digastric has two bellies that are connected in the middle by a tendon that is partially attached to the hyoid bone

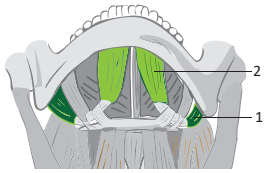

- 1 **Posterior belly** *(venter posterior)*
  - **O:** temporal bone (mastoid process) – mastoid notch
  - **I:** into the tendon that inserts on the hyoid bone
  - **F:** elevates the hyoid bone
  - **N:** facial nerve – digastric branch
- 2 **Anterior belly** *(venter anterior)*
  - **O:** continues from the posterior belly through the tendon that inserts on the hyoid bone
  - **I:** mandible – digastric fossa
  - **F:** depresses the mandible, elevates the hyoid bone
  - **N:** mandibular nerve (n. V3) – nerve to the mylohyoid

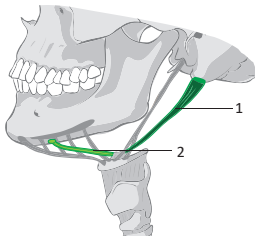

Stylohyoid *(musculus stylohyoideus)*

O: temporal bone – styloid process
I: hyoid bone (near the lesser horn)
F: fixation of the hyoid bone, pulls the hyoid bone dorsocranially
N: facial nerve – stylohyoid branch

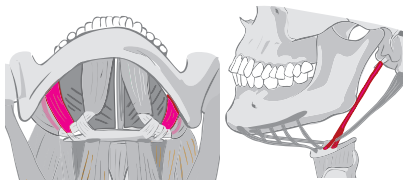

Mylohyoide muscle *(musculus mylohyoideus)*

O: mandible – mylohyoid line
I: hyoid bone – body, fuses with the contralateral muscle in the mylohyoid raphe
F: elevates the hyoid bone, depresses the mandible (when the hyoid bone is fixed), bulges the floor of the oral cavity during swallowing
N: mandibular nerve (n. V3) – nerve to mylohyoid

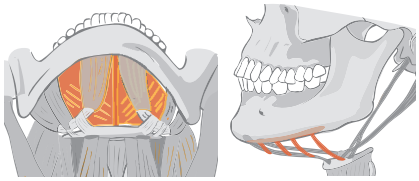

Geniohyoid *(musculus geniohyoideus)*

O: mandible – inferior mental spine
I: hyoid bone – body
F: elevation of the body of the hyoid, depression of the mandible (when the hyoid bone is fixed), bulges the floor of the oral cavity during swallowing
N: superior root of deep cervical ansa (anterior ramus of spinal nerve C1 via the hypoglossal nerve)

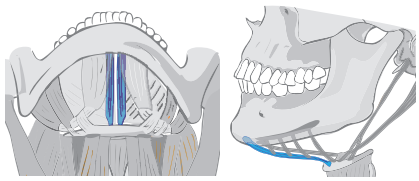

The sternohyoid tightens the pretracheal lamina of the cervical fascia.

The anterior belly of the digastric is one of the most variable muscles in the human body. The anatomical description of this muscle is seen in less than 50 % of dissections.

Clinical notes

Hypertonicity of the digastric leads to a pathological position of the hyoid bone protruding to the unaffected side.

The infrahyoid muscles are located **caudally to the hyoid bone**. Their **common innervation** comes from **the deep cervical ansa**. The infrahyoid muscles are located within the **pretracheal layer of the cervical fascia. The omohyoids form the lateral border of this fascia.** The infrahyoid muscles **help maintain the position of the hyoid bone**. Without this, depression of the mandible would not be possible. The infrahyoid muscles also **change the height of the larynx** and therefore change the frequency of produced tones in voice production.

Sternohyoid *(musculus sternohyoideus)*

O: clavicle – sternal end,
sternum – manubrium of sternum,
dorsal part of the sternoclavicular joint
(posterior sternoclavicular ligament)
Course of fibers: the paired muscles diverge caudally
I: hyoid bone – body (caudal margin)
F: depression of the hyoid bone,
stretches the pretracheal layer of the cervical fascia
N: deep cervical ansa
(branches of the spinal nerves C1–C3)

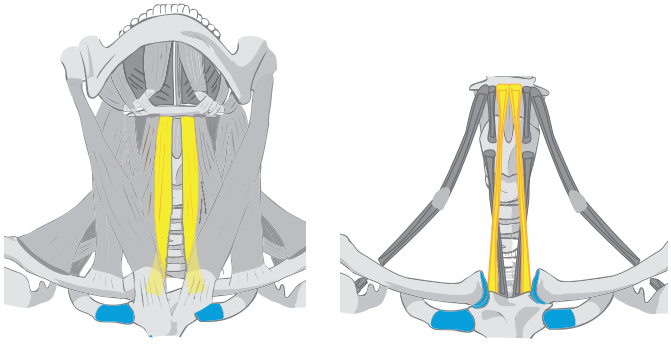

Sternothyroid *(musculus sternothyroideus)*

O: manubrium of sternum – posterior surface,
cartilage of the 1st rib (posterior margin)
Course of fibers: the paired muscles diverge cranially
I: thyroid cartilage – oblique line
F: depression of the larynx and thyroid cartilage
N: deep cervical ansa
(branches of the spinal nerves C1–C3)

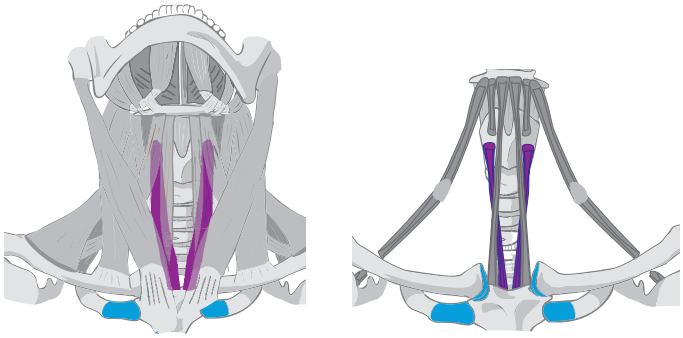

Thyrohyoid *(musculus thyrohyoideus)*

O: thyroid cartilage – oblique line
I: hyoid bone – greater horn
F: depression of the hyoid bone,
elevation of the larynx and thyroid cartilage
N: superior root of deep cervical ansa
(anterior ramus of spinal nerve C1
via the hypoglossal nerve)

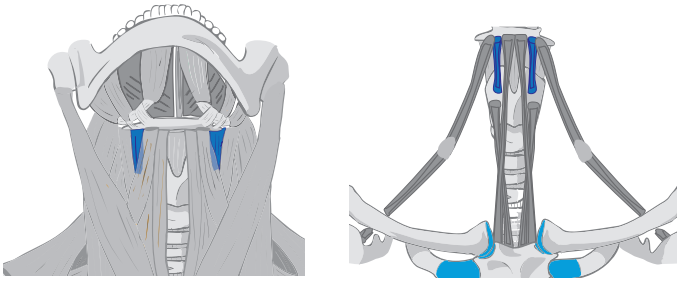

Omohyoid *(musculus omohyoideus)*

– a muscle that has two bellies, which are connected by a tendinous intersection
– this intermediate tendon is fused to the carotid sheath
- 1 **Superior belly** *(venter superior)*
- 2 **Inferior belly** *(venter inferior)*

O: scapula – suprascapular notch
and superior transverse scapular
ligament (inferior belly)
I: hyoid bone – body (superior belly)
F: depresses the hyoid bone, stretches the pretracheal layer of the cervical fascia
and pulls the carotid sheath, which dilates the internal jugular vein and increases the blood flow within it
N: deep cervical ansa
(branches of spinal nerves C1–C3)

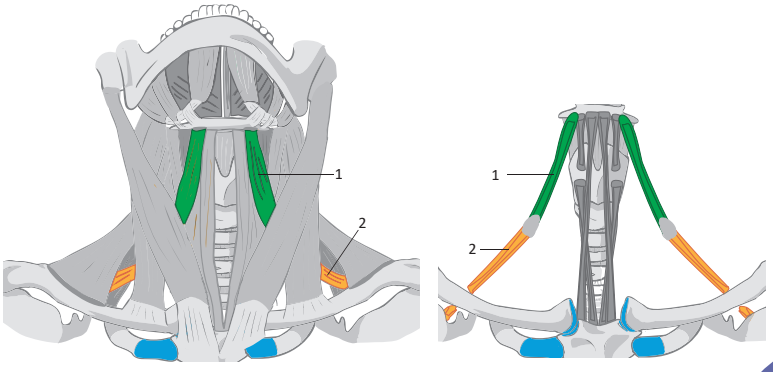

This copy belongs to ali yaghoubi

The scaleni are a group of muscles that run from the vertebral colum to the 1st and 2nd ribs. Their fibres course in a **laterocaudal direction**. They are **accessory muscles of inspiration** and are located within the **prevertebral layer of the cervical fascia**.

Scalenus anterior / anterior scalene *(musculus scalenus anterior)*

O: vertebrae C3–C6 – transverse processes
I: 1st rib – scalene tubercle
F: ventral flexion of the cervical vertebral column (bilateral contraction), lateroflexion of the cervical vertebral column to the side of the contracted muscle and rotation to the opposite side (unilateral contraction), elevation of the 1st rib (acts as an accessory muscle of inspiration when the vertebral column is fixed)
N: anterior rami of the spinal nerves C5–C7

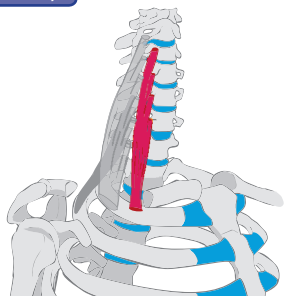

Scalenus medius / middle scalene *(musculus scalenus medius)*

O: vertebrae C2–C7 – transverse processes
I: 1st rib – dorsal to the subclavian artery
F: ventral flexion of the cervical vertebral column (bilateral contraction), lateroflexion of the cervical vertebral column to the side of the contracted muscle and rotation to the opposite side (unilateral contraction), elevation of the 1st rib (acts as an accessory muscle of inspiration when the vertebral column is fixed)
N: anterior rami of the spinal nerves C3–C8

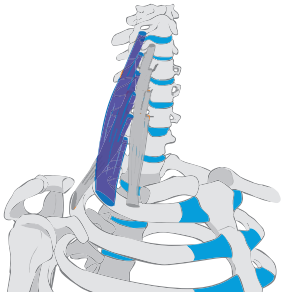

Scalenus posterior / posterior scalene *(musculus scalenus posterior)*

O: vertebrae C5–C7 – transverse processes
I: 2nd rib – dorsal to the tuberosity for the serratus anterior
F: ventral flexion of the cervical vertebral column (bilateral contraction), lateroflexion of the cervical vertebral column to the side of the contracted muscle and rotation to the opposite side (unilateral contraction), elevation of the 2nd rib (acts as an accessory muscle of inspiration when the vertebral column is fixed)
N: anterior rami of the spinal nerves C6–C8

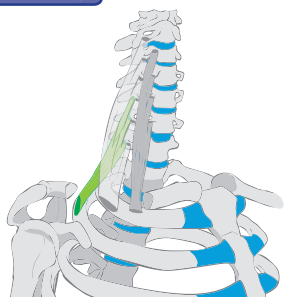

Scalenus minimus *(musculus scalenus minimus)*

– a variable muscle present in 50% of cases
O: vertebra C7 – transverse process
Course of fibers: in the scalene fissure (fissura scalenorum) and on part of the scalenopleural membrane
I: 1st rib (internal surface), cupula of pleura
F: stretches the cupula of the pleura
N: anterior ramus of the spinal nerve C7

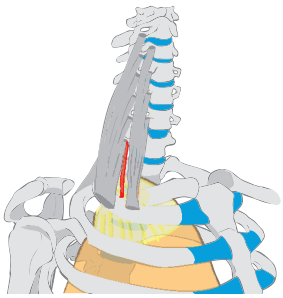

The main function of the scalene muscles is stabilisation of the cervical part of the vertebral column. The auxiliary inspiration function is activated only during deep breathing.

The scalenic fissure (*fissura scalenorum*) is a slit between the anterior and middle scaleni that contains the brachial plexus and subclavian artery (for details see page 545).

The rectus capitis anterior and lateralis are sometimes classified as nuchal muscles (according to TA 1998). From the developmental point of view, these muscles are derived from the hypaxial myotomes and thus their innervation differs from the nuchal muscles. On the other hand, their functional activity may be considered to be similar to the nuchal muscles.

The longus capitis is an antagonist of the rectus capitis posterior major and minor.

For a detailed description of the cervical fasciae see page 547.

Clinical notes

The scaleni and upper spaula fixators are often found to be simutaneously hypertonic on clinical examination. This leads to impairment in the moving the head backwards.

Some people activate the scalenic muscles during respiration, which typically leads to overloading of these muscles. This causes cervical pain and even atypical pain that radiates to the upper extremity. This pain is different from the cervical radicular syndromes, in which pain follows a radicular distribution (for details see the peripheral nervous system chapter). Overload of the scalenic muscles may cause the finger flexion test to be positive, as the patient is not able to touch his metacarpophalangeal joints with his fingertips due to the pain.

Thoracic outlet syndrome (scalenic syndrome) is caused by compression of the subclavian artery and/or brachial plexus within the scalenic fissure. Compression of the brachial artery typically leads to impairment in blood supply to the upper limb. This can be detected by a difference in blood pressure between the affected and unaffected arms. Compression of the brachial plexus leads to motor and sensory defects corresponding to the compressed nerves (for details see the brachial plexus in the peripheral nervous system chapter).

The deep group of the cervical muscles are located ventrally to the cervical vertebral column and are covered by the **prevertebral layer of the cervical fascia**. The common function of these muscles is **movement of the cervical vertebral column**.

Longus capitis *(musculus longus capitis)*

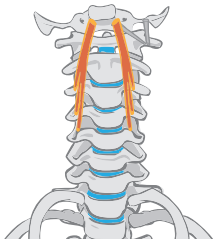

O: vertebrae C3–C6 – transverse processes
I: occipital bone (dorsolaterally to the pharyngeal tubercle)
F: ventral flexion of the vertebral column
N: anterior rami of spinal nerves C1–C3

Longus colli *(musculus longus colli)*

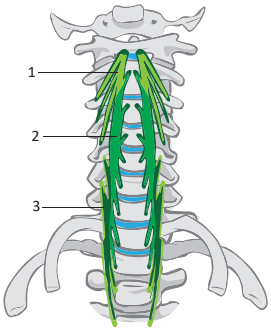

– longus colli is subdivided into three parts

- 1 **Cranial oblique part**
  O: vertebrae C3–C5 – transverse processes
  I: atlas (C1) – anterior tubercle
- 2 **Upright part**
  O: vertebrae C5–T3 – bodies
  I: vertebrae C2–C4 – bodies
- 3 **Caudal oblique part**
  O: vertebrae T1–T3 – bodies
  I: vertebrae C5–C6 – transverse processes

Function: ventral flexion of the cervical vertebral column (bilateral contraction),
lateroflexion of the vertebral column (unilateral contraction),
rotation of the vertebral column to the opposite side (unilateral contraction) – caudal oblique part,
rotation of the head to the same side (unilateral contraction) – cranial oblique part
Innervation: anterior rami of the spinal nerves C2–C6

Rectus capitis anterior *(musculus rectus capitis anterior)*



O: atlas (C1) – lateral mass and transverse process (anterior surface)
I: occipital bone (dorsocranially to the pharyngeal tubercle)
F: ventral flexion of the head (bilateral contraction),
lateroflexion of the head (unilateral contraction),
fine balancing movements of the head
N: anterior rami of the spinal nerves C1–C2

Rectus capitis lateralis *(musculus rectus capitis lateralis)*



O: atlas (C1) – transverse process (cranial surface)
I: occipital bone – jugular process
F: lateroflexion of the head
N: anterior rami of the spinal nerves C1–C2

3.6 **Cervical fascia** – Fascia cervicalis

The cervical fascia has three layers that embed and cover the cervical muscles. The fascia forms spaces, which contain organs nerves and vessels.

- 1 **Superficial layer** *(lamina superficialis fasciae cervicalis)*
  – covers the surface of the neck
  – the platysma is superficial to the fascia
  – envelops the trapezius (as the nuchal fascia) and the sternocleidomastoid
- 2 **Pretracheal layer** *(lamina pretrachealis fasciae cervicalis)*
  – envelops the infrahyoid muscles
  - 2.1 **Carotid sheath** *(vagina carotica)* – is derived from the pretracheal layer and invests the neurovascular bundle
- 3 **Prevertebral layer** *(lamina prevertebralis fasciae cervicalis)*
  – covers the deep cervical muscles
  3.1 **Scalene fascia** *(fascia scalenorum)* – part of the prevertebral layer that covers the scaleni
  – on the pleural cupula it continues into the suprapleural membrane and axillary fascia

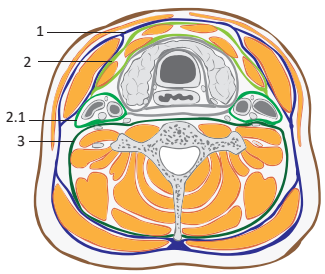

Transverse section at the level of C6

This copy belongs to ali yaghoubi

The muscles of the back can be **organised into four layers**. **The muscles of the 1st layer** insert on **the upper limb** and are therefore known as the **spinohumeral muscles**. The muscles of the **2nd layer** insert on the **scapula**, these muscles are thus known as **the spinoscapular muscles**. **The 3rd layer** of the back muscles inserts on the **ribs**, thus they are known as **the spinocostal muscles**. **The fourth layer** of the back muscles are **epaxial muscles** and are innervated by the posterior rami of spinal nerves.

1 **Muscles of the 1st layer**
– spinohumeral muscles
- 1.1 **Trapezius** *(musculus trapezius)*
- 1.2 **Latissimus dorsi** *(musculus latissimus dorsi)*

2 **Muscles of the 2nd layer**
– spinoscapular muscles
- 2.1 **Rhomboid major** *(musculus rhomboideus major)*
- 2.2 **Rhomboid minor** *(musculus rhomboideus minor)*
- 2.3 **Levator scapulae** *(musculus levator scapulae)*

3 **Muscles of the 3rd layer**
– spinocostal muscles
- 3.1 **Serratus posterior superior** *(musculus serratus posterior superior)*
- 3.2 **Serratus posterior inferior** *(musculus serratus posterior inferior)*

4 **Deep back muscles** *(musculi dorsi proprii)*
- 4.1 **Spinotransverse system**
- 4.2 **Spinospinal system**
- 4.3 **Transversospinal system**
- 4.4 **System of short muscles**
- 4.5 **Suboccipital muscles**
  – deep muscles of the neck

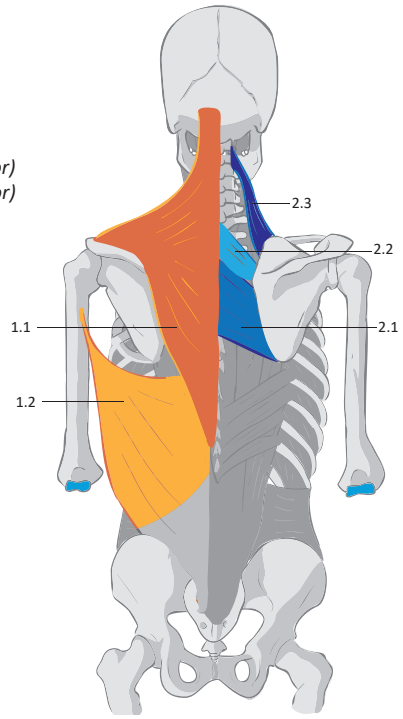

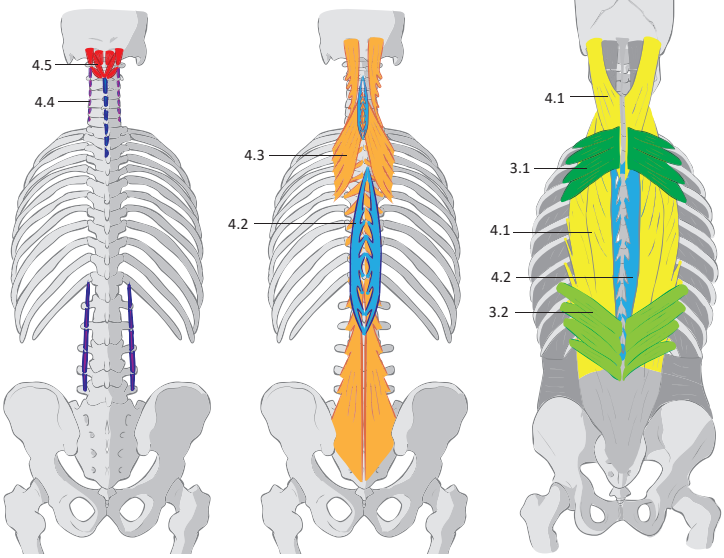

Muscles

The speculum rhomboideum is an aponeurotic field of the trapezius at the level of the vertebra C7.

The tendon of the latissimus dorsi is able to rotate through an angle of 180°. The more caudal fibres insert on the proximal portion of the crest of the lesser tubercle and the cranial fibres insert to the distal portion of the crest of the lesser tubercle.

The posterior axillary fold (*plica axillaris posterior*) is formed by the fused tendons of the latissimus dorsi and teres major.

The latissimus dorsi is innervated and supplied by the thoracodorsal nerve and vessels entering the muscle in its insertion. Thus, it is possible to cut this muscle at its origin, shift it and use in reconstructive surgery.

Clinical notes

The ascending part of the trapezius is typically weakened concurrently with the serratus anterior.

The descending part of the trapezius may be overloaded by carrying heavy luggage.

The descending part of the trapezius contains the so-called "key latent trigger point", which has a potential for chaining and pain accenting. This weak point of the trapezius is termed the key perpetuating factor and therapy must be targeted to the primary trigger point, otherwise it is not successful.

The transverse part of the trapezius usually contains so-called "hypertonic fibres", which are typically present when the antagonist (pectoralis major) shortens and serratus anterior weakens.

Chronic cough leads to overloading of the lateral portion of the latissimus dorsi.

A hypertonic latissimus dorsi may lead to a painful blockage at the thoracolumbal transition.

The 1st group of back muscles are the most superficial muscles of the back. They insert on the upper limb and are thus known as **the spinohumeral muscles**. This group of muscles consists of two muscles: **the trapezius and latissmimus dorsi.** Together these two muscles cover almost the entire surface of the back.

Trapezius *(musculus trapezius)*

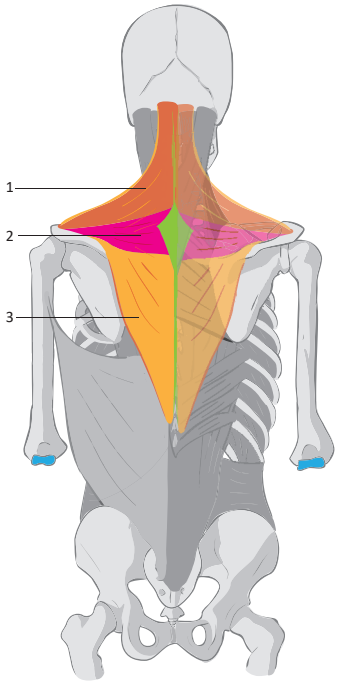

- 1 **Descending/superior part** *(pars descendens)*
  - **O:** occipital bone – superior nuchal line, occipital bone – external occipital protuberance, vertebrae C1–C6 – spinous processes (via the nuchal ligament)
  - **I:** clavicle – acromial end, scapula – acromion
  - **F:** elevation of the scapula, dorsal flexion of the head (when the scapula is fixed, bilateral contraction), lateroflexion of the head (when the scapula is fixed, unilateral contraction), fixates the scapula to the vertebral column
- 2 **Transverse / middle part** *(pars transversa)*
  - **O:** vertebrae C7–T3 – spinous processes
  - **I:** scapula – spine of scapula (lateral part – superior margin), scapula – acromion
  - **F:** retraction of the scapula and its fixation to the vertebral column
- 3 **Ascending / inferior part** *(pars ascendens)*
  - **O:** vertebrae T4–T12 – spinous processes
  - **I:** scapula – spine of scapula (medial part to the deltoid tubercle)
  - **F:** depression of the scapula and its fixation to the vertebral column

Innervation: accessory nerve (n. XI), anterior rami of the spinal nerves C3–C4

Function: external rotation of the scapula during simultaneous contraction of the ascending and descending part (inferior angle rotates laterally), which produces elevation of the arm above the horizontal line (synergist of the serratus anterior)

Latissimus dorsi *(musculus latissimus dorsi)*

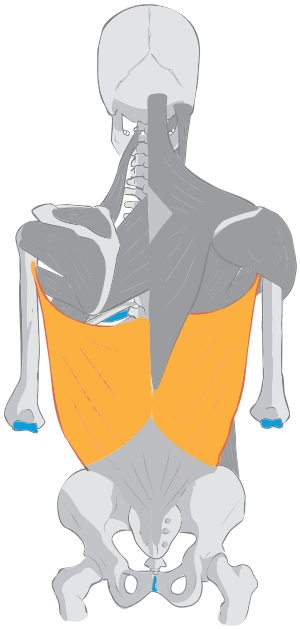

O: vertebrae T7–S5 – spinous processes and median sacral crest, thoracolumbar fascia – posterior layer, hip bone – posterior superior iliac spine and iliac crest (outer lip), 10th–12th rib, inferior angle of scapula

I: humerus – crest of lesser tubercle

F: internal rotation, adduction and dorsal flexion of the arm, auxiliary inspiration muscle when the upper limb is fixed (elevates the ribs), auxiliary expiration muscle – during strong expiration (cough) intensifies the curvature of the thoracic vertebral column and therefore reduces the volume of the thorax

N: thoracodorsal nerve

This copy belongs to ali yaghoubi

The muscles of the second layer insert on the scapula (spinoscapular muscles). **The rhomboids** belong to **the lower scapula fixators**, and **the levator scapulae** belongs to **the upper scapula fixators**.

Rhomboid major *(musculus rhomboideus major)*

O: vertebrae T1–T4 – spinous processes
I: scapula – caudal 2/3 of the medial border
F: elevation and retraction of the scapula, backdraw of elevated arm (180°)
N: dorsal scapular nerve

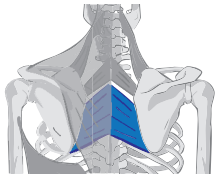

Rhomboid minor *(musculus rhomboideus minor)*

O: vertebrae C6–C7 – spinous processes
I: scapula – cranial 1/3 of the medial border (cranially to the rhomboid major)
F: elevation and retraction of the scapula
N: dorsal scapular nerve

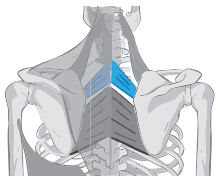

Levator scapulae *(musculus levator scapulae)*

O: vertebrae C1–C4 – transverse processes (posterior tubercle)
I: scapula – superior angle, upper margin of medial border of scapula
F: elevation of the scapula, lateroflexion of the vertebral column (when the scapula is fixed), internal rotation of the scapula (lateral rotation of the inferior angle), antagonist of the trapezius and serratus anterior
N: anterior rami of the spinal nerves C3–C4, dorsal scapular nerve (C5)

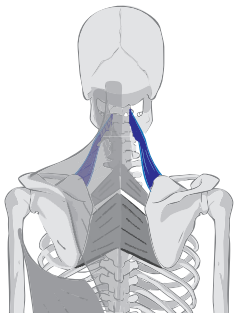

4.3 Muscles of the back – 3rd layer (spinocostal muscles)

The muscles of the 3rd layer **insert on the ribs** and are known as the spinocostal muscles. They are structurally **weak muscles** and function as **auxiliary respiratory muscles.**

Serratus posterior superior *(musculus serratus posterior superior)*

O: vertebrae C6–T2 – spinous processes
I: 2nd–5th rib – angle of rib
F: elevation of the ribs – auxiliary inspiration muscle
N: intercostal nerves I–IV

Serratus posterior inferior *(musculus serratus posterior inferior)*

O: vertebrae T11–L2 – spinous processes
I: 9th–12th rib
F: auxiliary inspiration muscle (fixates the caudal ribs and therefore aids the function of the diaphragm)
N: intercostal nerves IX–XI, subcostal nerve

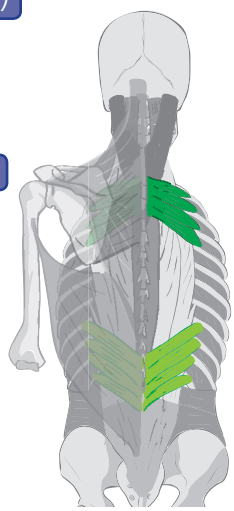

The scapula is fixed mainly by the surrounding muscles. The muscles of the scapula affect the position of the head, arms and cervical part of the vertebral column. The position of the scapula depends on the equilibrium between the superior and inferior scapular fixators and the serratus anterior.

Clinical notes

The rhomboid major and minor are responsible for stabilisation of the cervicothoracic transition. These muscles tend to weaken and it is important to stretch and exercise them together with the pectoral muscles. However, the weak rhomboid muscles often contain painful trigger points.

Upper crossed syndrome is caused by a muscular imbalance with the accentuated thoracic kyphosis and cervical lordosis (descending part of the trapezius, levator scapulae and sternocleidomastoid, and inferior part of the major pectoralis are shortened; the nuchal muscles, rhomboids and superior part of the major pectoralis are weakened).

The levator scapulae is typically overloaded by carrying of heavy luggage or by a constant arm elevation (computer working and long lasting use of a mouse). Similarly to the trapezius, this muscle is very sensitive to cold air conditions (leading to painful spasms).

The posterior superior serratus is palpable in the depth of the back in a maximal scapular abduction. This muscle is typically overloaded in constant forward position of the head and in paradoxical breathing. Its trigger point irradiation typically emits under the scapula, to the posterior part of the arm, into the triceps, elbow, ulnar part of the forearm, to the 5th finger. It is important to note this disorder and differentiate it from radicular syndromes of C8 and T1.

The splenius capitis and sternocleidomastoid may cause transferred pain in the vertex.

The deepest layer of back muscles, the fourth layer, differs from the other layers in both its structure and development. These muscles are known as **epaxial muscles**, a term which reflects their embryological origin from the dorsal part of the myotomes. They are innervated by the **posterior rami of spinal nerves**. Almost all the deep back muscles insert and originate on the vertebrae (hence their other name, the intrinsic back muscles). The deep back muscles are further divided into **5 muscle systems**. However, they all share a common function of **extension of the vertebral column**. The more superficial subgroups of the deep back muscles, which include the spinotransverse and spinospinous systems, have **sectional organisation**. They act over several vertebral levels, providing stability for particular sections of the vertebral column. The deeper muscles of the deep back muscles have **segmental organisation**. This means that they connect and provide stability to adjacent vertebrae.

1 **Spinotransverse system**
- 1.1 **Splenius** *(musculus splenius)*
- 1.2 **Longissimus** *(musculus longissimus)*
- 1.3 **Iliocostalis** *(musculus iliocostalis)*

2 **Spinospinal system**
- 2.1 **Spinalis** *(musculus spinalis)*

3 **Transversospinal system**
- 3.1 **Semispinalis** *(musculus semispinalis)*
- 3.2 **Multifidi** *(musculi multifidi)*
- 3.3 **Rotatores** *(musculi rotatores)*

4 **System of short muscles**
- 4.1 **Interspinales** *(musculi interspinales)*
- 4.2 **Intertransversarii** *(musculi intertrasversarii)*

5 **Suboccipital muscles** *(musculi suboccipitales)*
- 5.1 **Rectus capitis posterior major** *(musculus rectus capitis posterior major)*
- 5.2 **Rectus capitis posterior minor** *(musculus rectus capitis posterior minor)*
- 5.3 **Obliquus capitis superior** *(musculus obliquus capitis superior)*
- 5.4 **Obliquus capitis inferior** *(musculus obliquus capitis inferior)*

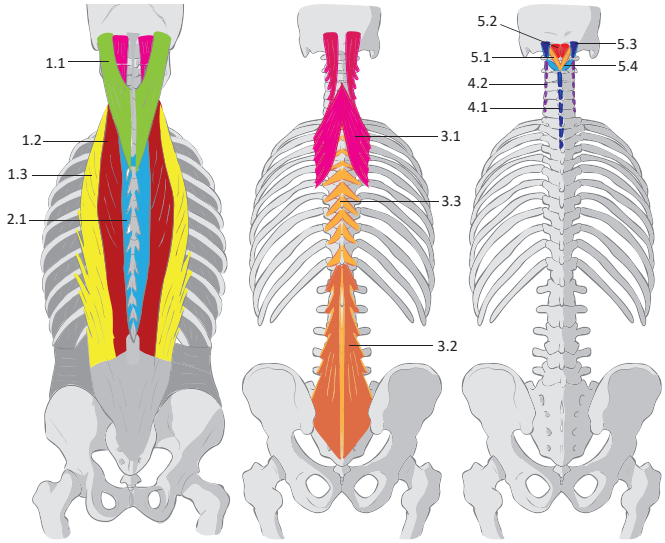

Spinotransverse system

– the spinotransverse system is a group of muscles whose fibres course from the spinous processes of the caudal vertebrae to the transverse processes of the cranial vertebrae
– these muscles have the shape of the letter V

1 **Splenius** *(musculus splenius)*
– 2 parts
- 1.1 **Splenius capitis** *(musculus splenius capitis)*
  - **O:** nuchal ligament (caudal part), vertebrae C7–T4 – spinous processes
  - **I:** temporal bone – mastoid process, occipital bone – occipital plane (below the lateral third of the superior nuchal line)
  - **F:** dorsal flexion of the head (bilateral contraction), lateroflexion and rotation of the head to the side of the contracted muscle (unilateral contraction)
  - **N:** posterior rami of spinal nerves (inferior cervical segments)
- 1.2 **Splenius cervicis** *(musculus splenius cervicis)*
  - **O:** vertebrae T3–T6 – spinous processes
  - **I:** vertebrae C1–C3 – transverse processes
  - **F:** dorsal flexion of the head (bilateral contraction), lateroflexion and rotation of the head to the side of the contracted muscle (unilateral contraction) – these are common functions for both parts of the splenius
  - **N:** posterior rami of spinal nerves (caudal cervical and cranial thoracic segments)

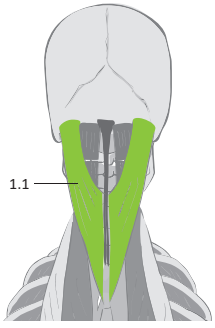

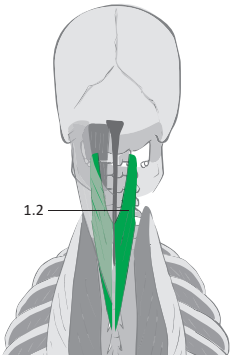

This copy belongs to ali yaghoubi

Spinotransverse system

2 **Longissimus** *(musculus longissimus)*
– forms the middle part of the erector spinae

- 2.1 **Longissimus thoracis** *(musculus longissimus thoracis)*
  O: erector spinae aponeurosis (large common tendon), spinous processes T11–L5, sacrum – median sacral crest
  I: vertebrae L1–L5 – costal processes, vertebrae T1–T12 – transverse processes, 3rd–12th rib, thoracolumbar fascia – middle layer
- 2.2 **Longissimus cervicis** *(musculus longissimus cervicis)*
  O: vertebrae T1–T5 – transverse processes
  I: vertebrae C2–C6 – transverse processes
- 2.3 **Longissimus capitis** *(musculus longissimus capitis)*
  O: vertebrae T1–T5 – transverse processes, vertebrae C2–C6 – articular processes
  I: occipital bone – mastoid process

Function: dorsal flexion of the vertebral column and head (bilateral contraction), lateroflexion and rotation of the vertebral column and head to the side of the contracted muscle (unilateral contraction)
Innervation: posterior rami of spinal nerves

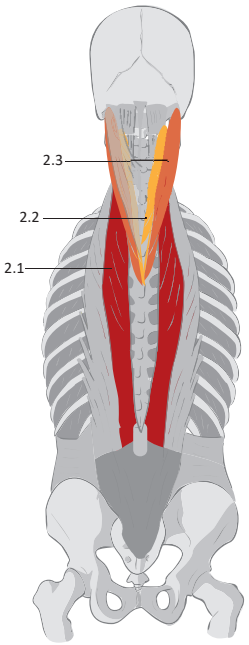

3 **Iliocostalis** *(musculus iliocostalis)*
– forms the lateral part of the erector spinae

- 3.1 **Iliocostalis lumborus** *(musculus iliocostalis lumborum)*
  - 3.1.1 **Lumbar part** *(pars lumbalis)*
    O: erector spinae aponeurosis (large common tendon), sacrum – lateral sacral crest, hip bone – outer lip of iliac crest
    I: 6th–12th rib – angle of rib
  - 3.1.2 **Thoracic part** *(pars thoracica)*
    O: 6th–12th rib – angle of rib (mediocranially to the insertion of the lumbar part)
    I: 1st–6th rib – angle of rib, vertebra C7 – transverse process
- 3.2 **Iliocostalis cervicis** *(musculus iliocostalis cervicis)*
  O: 3rd–6th rib – angle of rib (medial to the insertion of the thoracic part)
  I: vertebrae C4–C6 – transverse processes

Function of the whole muscle: dorsal flexion of the vertebral column (bilateral contraction), lateroflexion and rotation of the vertebral column to the side of the contracted muscle (unilateral contraction)
Innervation: posterior rami of spinal nerves

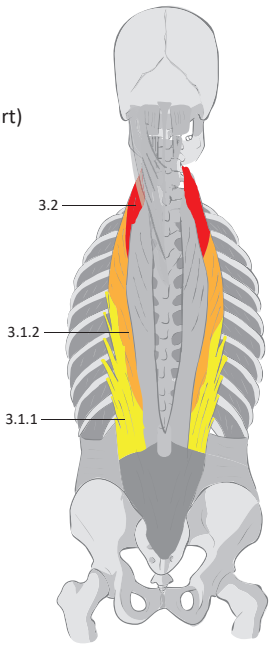

Muscles

The erector spinae is a muscular complex alongside the vertebral column which is formed by (in a lateromedial direction): iliocostalis, longissimus and spinalis.

The sacrospinal system is another term for the longissimus and iliocostalis regarding the origin and course of these muscles.

Clinical notes

The deep back muscles tend to weaken and atrophy. This is common for many people of modern society. The superficial muscles are hyperactive and the deep and stabilisation muscles become weakened.

The erector spinae is typically overloaded and hypertonic in the thoracolumbar and lumbosacral regions.

Spinospinal system

– the spinospinal system is characterised by the course of its fibres that run from the spinous processes of the caudal vertebrae to the spinous processes of the cranial vertebrae.

1 **Spinalis** *(musculus spinalis)*
– forms the medial part of the erector spinae.
- 1.1 **Spinalis thoracis** *(musculus spinalis thoracis)*
  – fuses with the longissimus thoracis (they are very difficult to differentiate)
  O: vertebrae T11–L2 – spinous processes
  I: 4–8 cranial thoracic vertebrae – spinous processes
- 1.2 **Spinalis cervicis** *(musculus spinalis cervicis)*
  – a variable muscle
  O: nuchal ligament, vertebrae C7-T2 – spinous processes
  I: axis (C2) – spinous process, vertebrae C3 and C4 – spinous processes (variable insertion))

1.3 **Spinalis capitis** *(musculus spinalis capitis)*
– usually fuses with the spinalis cervicis

Function of the whole muscle:
dorsal flexion of the vertebral column and head (bilateral contraction), lateroflexion of the vertebral column to the side of the contracted muscle (unilateral contraction)
Innervation: posterior rami of spinal nerves

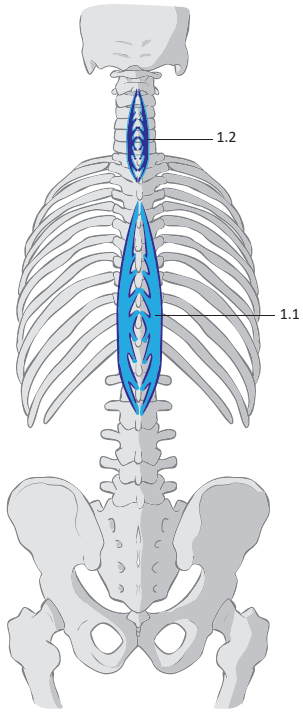

Transversospinal system

– the course of the fibres of the transversospinal system runs from the transverse processes of the caudal vertebrae to the spinous processes of the cranial vertebrae
– these muscle are shaped like the letter A

1 **Semispinalis** *(musculus semispinalis)*
- 1.1 **Semispinalis thoracis** *(musculus semispinalis thoracis)*
  O: vertebrae T6–T10 – transverse processes
  I: vertebrae C6–T4 – spinous processes
- 1.2 **Semispinalis cervicis** *(musculus semispinalis cervicis)*
  O: vertebrae T1–T6 – transverse processes
  I: vertebrae C2–C5 – spinous processes
- 1.3 **Semispinalis capitis** *(musculus semispinalis capitis)*
  O: vertebrae T6–C7 – transverse processes
  vertebrae C4–C6 – articular processes,
  vertebrae C7–T1 – spinous processes (variably)
  I: occipital bone – the inferior nuchal line

Function of the whole muscle:
dorsal flexion of the vertebral column and head (bilateral contraction), lateroflexion of the vertebral column and head to the side of the contracted muscle and rotation of the vertebral column and head to the opposite side (unilateral contraction)
Innervation: posterior rami of spinal nerves

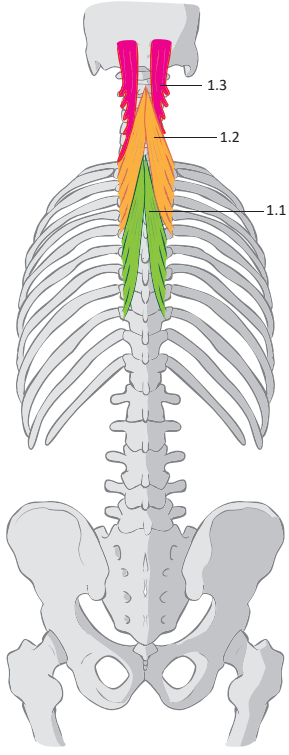

This copy belongs to ali yaghoubi

Transversospinal system

2 **Multifidi** *(musculi multifidi)*
– short muscles located very deeply in the back
– fill the space lateral to the spinous processes of the vertebrae
– are most distinct at the level of the lumbar vertebral column
O: sacrum – dorsal surface,
posterior sacro-iliac ligament,
hip bone – posterior superior iliac spine,
vertebrae L1–L5 – mammillary processes (costal processes),
vertebrae T1–T12 – transverse processes,
vertebrae C4–C7 – articular processes
I: spinous processes of vertebrae
– superficial multifidi 3–4 vertebrae above their origin,
the deepest multifidi to the adjacent vertebra of their origin
F: dorsal flexion of the vertebral column (bilateral contraction),
rotation of the vertebral column to the opposite side
of the contracted muscles (unilateral contraction)
N: posterior rami of spinal nerves

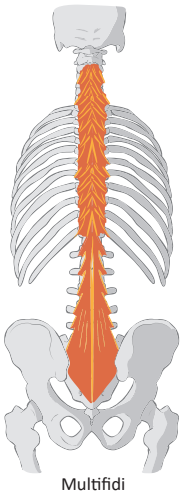

Multifidi

3 **Rotatores** *(musculi rotatores)*
– the deepest layer of muscles, are always present in the
thoracic part of the vertebral column (rotatores thoracis)
– variably present in the cervical and lumbar vertebral column
O: vertebrae – transverse processes
I: vertebrae – vertebral arches (next to spinous process)
of 1 (rotatores breves) or 2 (rotatores longi)
vertebrae above
F: dorsal flexion of the spine – neighbouring vertebrae
(bilateral contraction),
rotation of the vertebral column to the opposite side
of the contracted muscles (unilateral contraction)
N: posterior rami of spinal nerves

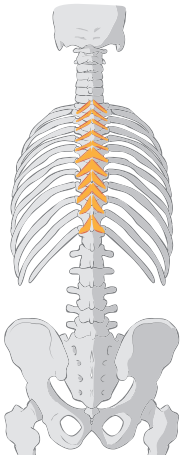

Rotatores

System of short muscles

– the system of short muscles connecting adjacent vertebrae

● 1 **Interspinales** *(musculi interspinales)*
– a paired system of muscles that are located between spinous
processes of neighbouring vertebrae
– are most developed in the cervical part of the vertebral column
– there are 7 pairs of interspinales cervicis (T1–C2)
F: dorsal flexion of the vertebral column,
maintain stability of the vertebral column (postural muscles)
N: posterior rami of spinal nerves

● 2 **Intertransversarii** *(musculi intertransversarii)*
– a system of muscles that are located between transverse
processes of adjacent vertebrae
– are most developed in the cervical part
of the vertebral column
– in other parts of the vertebral column
they are poorly developed
F: lateroflexion of the vertebral column
N: anterior and posterior rami of spinal nerves

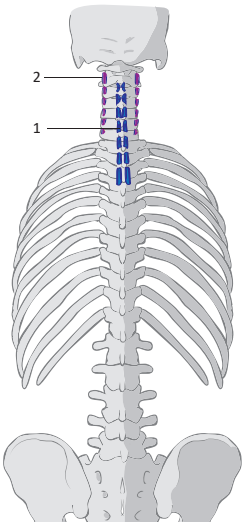

System of short muscles

Lumbosacral fascia is an obsolete term for the thoracolumbar fascia.

The nuchal fascia separates the trapezius and rhomboids from the deep back muscles. Laterally it continues to the superficial lamina of the cervical fascia and in the midline it is strengthened by the nuchal ligament. The nuchal fascia covers the trapezius. Its superficial part attaches to the highest nuchal line and is called the superficial fascia of the back (*fascia dorsi superficialis*).

The rhombus of Michaelis is a rhombus-shaped area in the lumbar region. Its superior corner is formed by the spinous processus of vertebra L4, the lateral corners are formed by the superior posterior iliac spines and the inferior corner is located in the region of the sacrococcygeal transition (at the superior margin of the intergluteal cleft). If symmetrical, it indicates physiological development of the pelvis.

Suboccipital triangle see page 569.

Clinical notes

The nuchal muscles are some of the most susceptible muscles to become hypertonic. This can be caused by a head posture characterised by chin protraction and head retroflexion. Hypertonia in the nuchal muscles can lead to a disturbance in proprioception of the entire locomotor system. It can also reduce perfusion of the brain, increase the lumbar kyphosis and is one of the main parts of the cervicocranial syndrome. It causes pain during sleep and is often associated with dysfunction of vision and a decrease in the effectiveness of lenses and glasses on visual acuity.

When the nuchal muscles are overloaded, the patient complains of pain in the occipital region. The patients report that they can eliminate this pain by themselves using finger pressure or a specific massage. Correction of head posture and improvement of the working environment is fundamental to bringing permanent relief.

The dorsal fasciae (both the superficial and deep fasciae) must be freely movable in all directions. Increased mobility by means of the melting phenomenon (or heating) **can be a potential method of treatment.**

A disorder of extensibility of the thoracolumbar fascia is one of the most frequent reflexive changes accompanying disorders of the lumbar part of the vertebral column.

Suboccipital muscles *(musculi suboccipitales)*

– suboccipital muscles are a system of deep muscles of the neck located between the first two vertebrae and the occipital bone
– these muscles form the suboccipital triangle

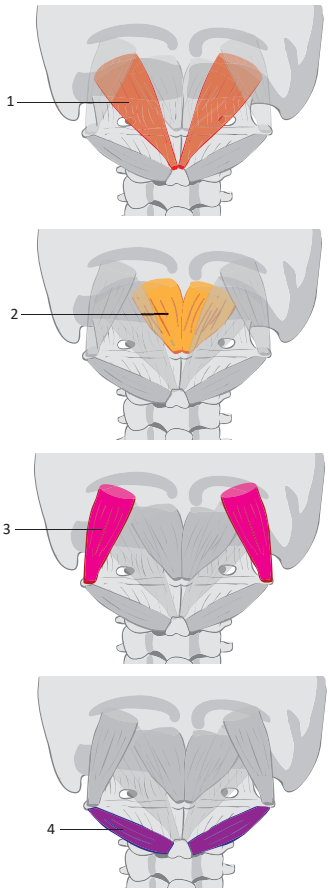

- 1 **Rectus capitis posterior major** *(musculus rectus capitis posterior major)*
  - **O:** axis (C2) – spinous process
  - **I:** occipital bone – occipital plane, inferior nuchal line
  - **F:** dorsal flexion of the head (bilateral contraction), lateroflexion and rotation of the head to the side of the contracted muscle (unilateral contraction)
  - **N:** suboccipital nerve (posterior ramus of the spinal nerve C1)

- 2 **Rectus capitis posterior minor** *(musculus rectus capitis posterior minor)*
  - **O:** atlas (C1) – posterior tubercle
  - **I:** occipital bone – occipital plane, inferior nuchal line (medially to the rectus capitis posterior major)
  - **F:** dorsal flexion of the head (bilateral contraction), lateroflexion and rotation of the head to the side of the contracted muscle (unilateral contraction)
  - **N:** suboccipital nerve (posterior ramus of the spinal nerve C1)

- 3 **Obliquus capitis superior** *(musculus obliquus capitis superior)*
  - **O:** atlas (C1) – transverse process
  - **I:** occipital bone – occipital plane, lateral part of inferior nuchal line
  - **F:** dorsal flexion of the head (bilateral contraction), rotation of the head to the opposite side of the contracted muscle (unilateral contraction)
  - **N:** suboccipital nerve (posterior ramus of the spinal nerve C1)

- 4 **Obliquus capitis inferior** *(musculus obliquus capitis inferior)*
  - **O:** axis (C2) – spinous process
  - **I:** atlas (C1) – transverse process
  - **F:** rotation of the atlas (and the head) to the side of the contracted muscle (unilateral contraction)
  - **N:** suboccipital nerve (posterior ramus of the spinal nerve C1)

4.5 Fasciae of the back

The superficial back muscles are covered by **the superficial fascia of the back**. **The thoracolumbar fascia** is located deeply in the caudal part of the back and forms the aponeurotic origin of the latissimus dorsi from which the lateral muscles of the abdominal wall originate. **The middle layer of the thoracolumbar fascia** develops from the horizontal myoseptum and forms the **borderline between the epaxial and hypaxial muscles**.

- 1 **Superficial fascia of back** *(fascia dorsi superficialis)* – covers the surface of the back
  – is formed by fusion of the fasciae of the muscles of the superficial layer (tenuous fibrous plates)
  – is continuous with the superficial layer of the cervical fascia and nuchal fascia
- 2 **Thoracolumbar fascia** *(fascia thoracolumbalis)*
  - 2.1 **Posterior layer** *(lamina posterior)*
    – the aponeurotic origin of the latissimus dorsi
    – covers the deep back muscles
  - 2.2 **Middle layer** *(lamina media)*
    – a firm aponeurotic membrane
    – separates the deep back muscles from the quadratus lumborum
    – develops from the horizontal myoseptum (which forms the border between the epaxial and hypaxial muscles)
  - 2.3 **Anterior layer** *(lamina anterior)*
    – covers the quadratus lumborum ventrally

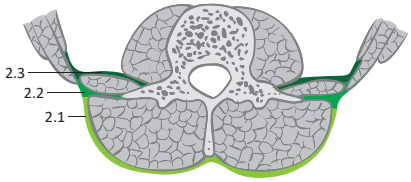

Transverse section at the level of the lumbar vertebra

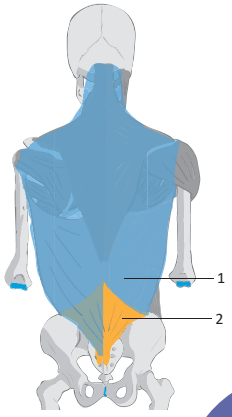

This copy belongs to ali yaghoubi

The muscles of the thorax are organised into three groups: **the thoracohumeral muscles,** which insert on the upper limb, **the proper muscles of the thorax,** which are the main muscles of respiration, and **the diaphragm**.

1 **Thoracohumeral muscles**
- 1.1 **Pectoralis major** *(musculus pectoralis major)*
- 1.2 **Pectoralis minor** *(musculus pectoralis minor)*
- 1.3 **Serratus anterior** *(musculus serratus anterior)*
- 1.4 **Subclavius** *(musculus subclavius)*

2 **Proper muscles of the thorax**
- 2.1 **Intercostal muscles** *(musculi intercostales)*
  - 2.1.1 **External intercostal muscles** *(musculi intercostales externi)*
  - 2.1.2 **Internal intercostal muscles** *(musculi intercostales interni)*
  - 2.1.3 **Innermost intercostal muscles** *(musculi intercostales intimi)*
- 2.2 **Transversus thoracis** *(musculus transversus thoracis)*
- 2.3 **Levatores costarum** *(musculi levatores costarum)*

3 **Diaphragm** *(diaphragma)*

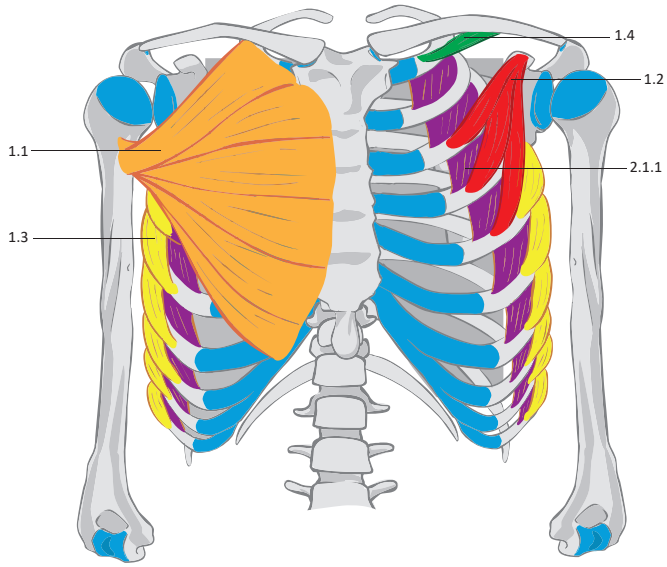

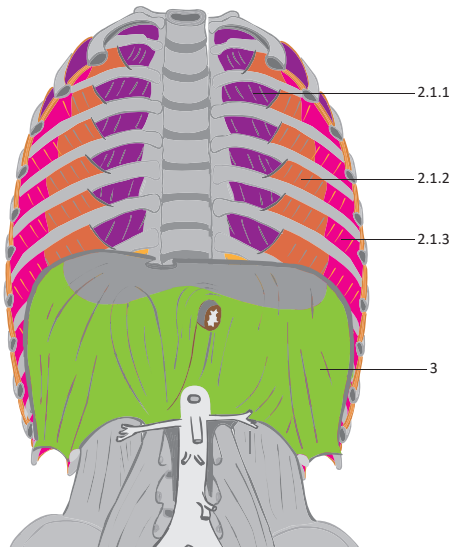

The anterior axillary fold (*plica axillaris anterior*) is formed by the tendon of the pectoralis major.

The subclavius is functionally considered to be part of the pectoralis major.

Clinical notes

The subclavius protects the vessels and nerves that run under the clavicle. This is important in fractures of the clavicle.

All three parts of the pectoralis major tend to shorten and must be evaluated and exercised separately.

Trigger points in the sternocostal part of the pectoralis major may cause hypersensitivity of the nipple and areola.

The trigger point of cardiac arrhythmia is a trigger point situated in the sternocostal part of the pectoralis major under the 5th rib 3–4 cm laterally from the midline. It may cause a sense of palpitations, but there is no underlying cardiac pathology.

The pectoralis minor may compress some branches of the axillary artery and distal parts of the brachial plexus. This muscle is usually examined in abduction and lateral rotation of the shoulder.

Shortening of the pectoralis minor leads to protraction of the arms. A hypertonic pectoralis minor is associated with pain in the infraclavicular region.

Trigger points in the serratus anterior may lead to problems with breathing. Such patient may suffer from a lack of air and may even complain of painful inspiration. The pain may radiate to the ulnar part of the arm, forearm and hand.

The thoracohumeral muscles are a group of the thoracic muscles with diverse functions. The thoracohumeral muscles **originate on the thorax and insert on the bones of the upper limb** (clavicle, scapula and humerus).

Pectoralis major *(musculus pectoralis major)*

– according to its origin the pectoralis major can be divided into three parts, which are capable of contracting independently

Origin:

- 1 **Clavicular part** *(pars clavicularis)* – clavicle – medial part
- 2 **Sternocostal part** *(pars sternocostalis)* – sternum to the attachment of the 7th rib, cartilage of the 1st–7th rib (1st and 7th rib variably)
- 3 **Abdominal part** *(pars abdominalis)* – aponeuroses of the lateral muscles of the abdomen

I: humerus – crest of greater tubercle (caudal part of the muscle inserts most cranially as the tendon makes a turn of 180°

F: adduction, flexion and internal rotation of the arm at the shoulder joint, an accessory muscle of inspiration (when the upper limb is fixed)

N: pectoral nerves (medial and lateral)

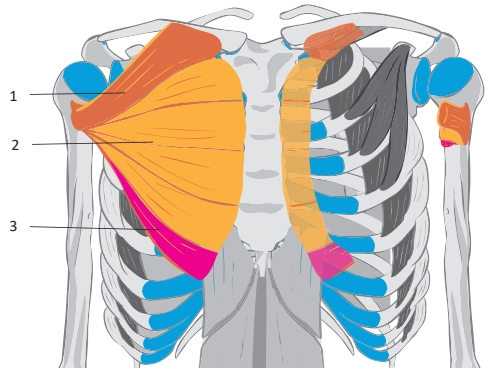

Pectoralis minor *(musculus pectoralis minor)*

O: 3rd–5th rib (lateral to the cartilage)

I: scapula – coracoid process

F: protraction and depression of the scapula, an accessory muscle of inspiration (when the upper limb is fixed)

N: medial pectoral nerve (and variably by the lateral pectoral nerve)

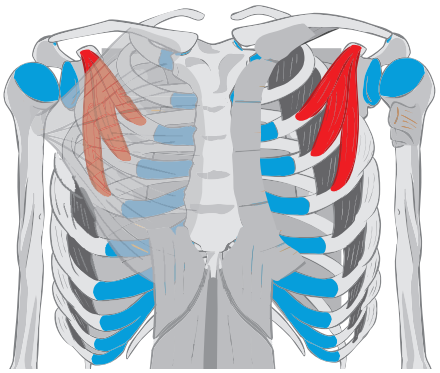

Serratus anterior *(musculus serratus anterior)*

O: as muscular slips on the 1st–9th rib (the 5 caudal slips interdigitate with the origins of the external oblique)

I: scapula – medial border

F: protraction of the scapula, holds the scapula on the thoracic wall, external rotation of the scapula (rotates the inferior angle laterally and elevates the arm above the horizontal plane, a synergist of the trapezius, an auxiliary inspiration muscle (when the upper limb is fixed)

N: long thoracic nerve

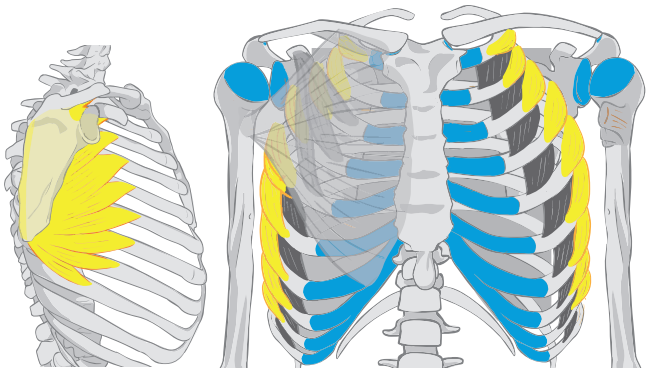

Subclavius *(musculus subclavius)*

O: 1st rib

I: clavicle – subclavian groove

F: depression of the clavicle, elevation of the 1st rib – fixation of the sternoclavicular joint

N: subclavian nerve

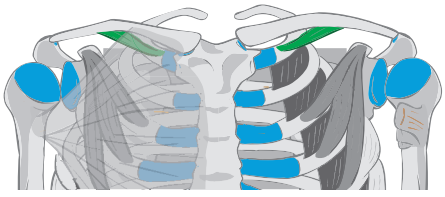

This copy belongs to ali yaghoubi

The proper muscles of the thorax **insert on the ribs**. They move the ribs, change the volume of the thoracic cavity and thus belong to the **main muscles of respiration**.

Intercostal muscles *(musculi intercostales)*

- 1 **External intercostal muscles** *(musculi intercostales externi)*
  - – the superficial layer of the intercostal muscles
  - – are located in the dorsal two thirds of the intercostal space, extending from the vertebral column to the transition between the bony rib and rib cartilage
  - – are absent in the region of the costal cartilages where they are substituted by the external intercostal membrane
  - **O:** ribs – caudal margin of the rib
  - **Course of fibres:** the fibres run in an oblique ventrocaudal direction
  - **I:** ribs – cranial margin of the rib below the origin
  - **F:** elevation of the ribs (main inspiration muscles)
- 2 **Internal intercostal muscles** *(musculi intercostales interni)*
  - – the middle layer of the intercostal muscles
  - – are located in the ventral two thirds of the intercostal space, extending from the angle of the rib to the sternum
  - – are absent from the vertebral column to the angle of the rib where they are substituted by the internal intercostal membrane
  - **O:** ribs – caudal margin of the rib
  - **Course of fibers:** oblique dorsocaudal
  - **I:** ribs – cranial margin on the rib below the origin
  - **F:** depression of the ribs (muscles of expiration), stabilisation of the ribs (aid the diaphragm)
- 3 **Innermost intercostal muscles** *(musculi intercostales intimi)*
  - – the internal layer of the intercostal muscles
  - – follow the course of the internal intercostal muscles
  - – weak and often with missing parts
  - – only in the ventral two thirds of the intercostal space extending from the angle of the rib to the sternum
  - **O:** ribs – caudal margin
  - **Course of fibers:** oblique dorsocaudal
  - **I:** ribs – cranial margin of the rib below the origin
  - **F:** depression of the ribs (muscles of expiration), stabilisation of the ribs (aid the diaphragm)

Innervation: intercostal nerves I–XI

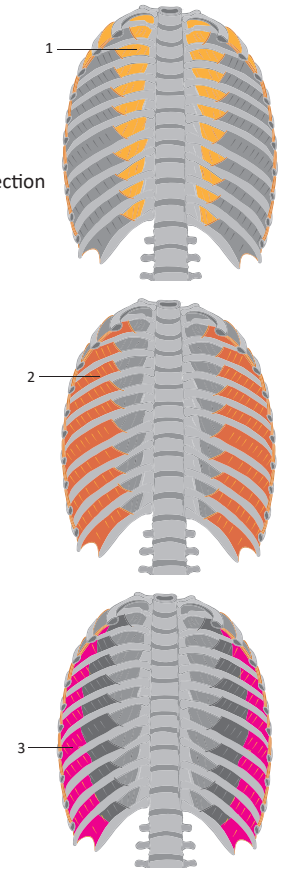

Transverse thoracis *(musculus transversus thoracis)*

– the transverse thoracis is a muscle whose fibres radiate outwards on the internal surface of the sternum

O: sternum (caudal third of the internal surface), cartilage of the 4th–7th rib

I: cartilage of the 2nd–6th ribs

F: depression of the ribs (an auxiliary muscle of expiration)

N: intercostal nerves I–VI



Levatores costarum *(musculi levatores costarum)*

- 1 **Levatores costarum breves** *(musculi levatores costarum breves)*
  - – are composed of 12 bundles of fibres
  - **O:** vertebrae C7–T11 – transverse processes
  - **I:** rib – between the tubercle and angle of the rib (one rib caudally)
- 2 **Levatores costarum longi** *(musculi levatores costarum longi)*
  - – 4 bundles
  - **O:** vertebrae T8–T11 – transverse processes
  - **I:** rib – in between the tubercle and angle of the rib (two ribs caudally)

Function: elevation of the ribs

Innervation: posterior rami of spinal nerves

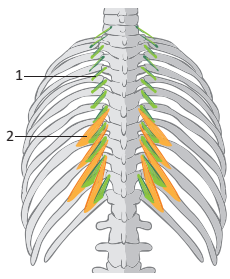

The subcostal muscles are rudimentary muscles underneath the innermost intercostal muscles. Their origins are situated on the inner surface of the ribs close to the angle of the rib and their attachments are situated caudally, usually skipping one or two ribs and again to the angle of the rib. Their function is mainly fixation of the ribs in cooperation with the internal intercostal muscles.

The levatores costarum, from the developmental point of view, are epaxial muscles and, together with the diaphragm, they have a phasic activity in inspiration.

The sternalis is an inconstant muscle (present in 1 % of the population) close to the sternocostal part of the pectoralis major. It runs near to the margin of the sternum.

The muscular fibres of the diaphragm may intermingle with the fibres of the psoas major.

The diaphragm has three different functions: respiratory, stabilization and (oesophageal) sfincter function. Equilibrium is important for its proper functions.

Intercostal space see page 549.

Openings in the diaphragm see page 553.

Clinical notes

Hiccups (*singultus*) are caused by reflexive contractions of the diaphragm. They can be stopped by post-isometric relaxation of the diaphragm. This can be achieved by elevating the arm while holding the breath in inspiration.

The thoracic fasciae are contracted in majority of the population. This is associated with hypertonic and even painful pectoral muscles.

The diagphragm is a flat muscle that forms a horizontal **septum between the thoracic and abdominal cavity**. It is comprised of **three muscular parts** (lumbar part, costal part and sternal part) that are connected to each other **in a central fibrous tendon**. The sternocostal and lumbocostal triangles are small fibrous triangles located between the individual parts of the diaphram. The diaphragm forms an arch with **two vaults: one at the level of the 4th intercostal space on the right side and one at the 5th intercostal space on the left side**. The vaults flatten during inspiration and the central tendon descends caudally which increases the volume of the thoracic cavity. The diaphragm is the **main muscle of inspiration**.

Origin:

- 1 **Lumbar part** *(pars lumbalis)*
  - 1.1 **Right crus** *(crus dextrum)*: bodies of the vertebrae L1–L4
  - 1.2 **Left crus** *(crus sinistrum)*: bodies of the vertebrae L1–L3
  - 1.3 **Median arcuate ligament** *(ligamentum arcuatum medianum)*
    - the aortic arcade
    - intersection of the right and left crus
    - encloses the aortic hiatus
  - 1.4 **Medial arcuate ligament** *(ligamentum arcuatum mediale)*
    - the psoatic arcade
    - from the body of the vertebrae L1–L2 to the costal process of L1
  - 1.5 **Lateral arcuate ligament** *(ligamentum arcuatum laterale)*
    - the quadratic arcade
    - from the costal process of L1 to the 12th rib
- 2 **Costal part** *(pars costalis)*
  - 2.1 **7th–12th rib** – alternate with the origins of the transversus abdominis
- 3 **Sternal part** *(pars sternalis)*
  - 3.1 **Sternum** – xiphoid process
  - 3.2 **Rectus sheath** *(vagina musculi recti abdominis)*

Insertion:

- 4 **Central tendon** *(centrum tendineum)*
  - is located in the middle of the diaphragm
  - the tendinous insertion of all three parts of the diaphragm

Function:

– the main muscle of inspiration and an important postural muscle
– contributes to stabilisation of the thoracolumbar transition of the vertebral column
– separates the thoracic cavity from the abdominal cavity
– organs, nerves and vessels run through openings in the diaphragm
– contributes to closure of the oesophagus at the cardia
(the phreno-oesophageal membrane of *Leimer*)
– fixates and stabilises the caudal ribs

Innervation: phrenic nerve (C4 and small connections from C3–C5)

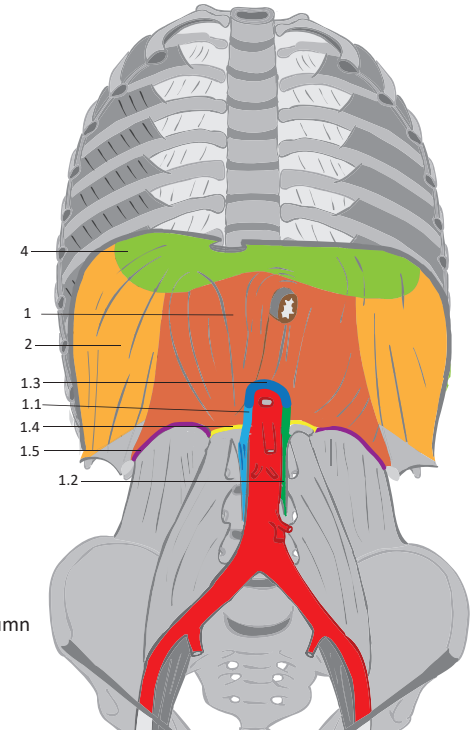

5.4 Fasciae of the thorax

The thoracohumeral muscles are covered by **the superficial fasciae of the thorax**. These fasciae are the **pectoral fascia** and **clavipectoral fascia**. The skeleton of the thorax and the **proper muscles of the thorax** are covered by fasciae on their internal and external surfaces by **the endothoracic and the thoracic fasciae**, respectively.

- 1 **Pectoral fascia** *(fascia pectoralis)* – covers the pectoralis major
- 2 **Clavipectoral fascia** *(fascia clavipectoralis)*
  - is located under the pectoralis major
  - is stretched between the clavicle, coracoid process, cartilaginous ends of the ribs and the caudal origin of the pectoralis minor
  - contains the infraclavicular oval fossa
  - covers the subclavius and pectoralis minor
- 3 **Thoracic fascia** *(fascia thoracica)*
  - a fascia over the surface of the ribs and intercostal spaces
- 4 **Endothoracic fascia / parietal fascia of thorax** *(fascia endothoracica / fascia parietalis thoracis)*
  - covers the internal surface of the thoracic cavity
  - 4.1 **Suprapleural membrane of Sibson** *(membrana suprapleuralis)*
    - a thickened part of the endothoracic fascia on the pleural cupula
  - 4.2 **Diaphragmatic fascia** *(fascia diaphragmatica)* – covers the diaphragm from above

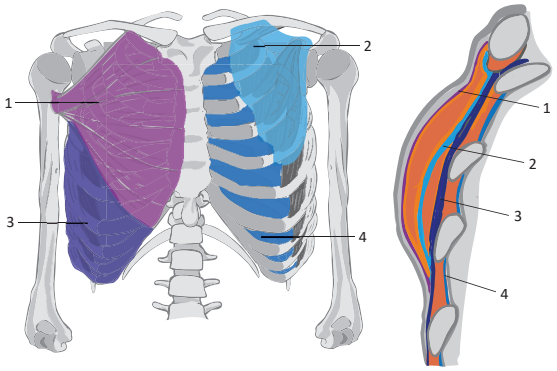

This copy belongs to ali yaghoubi

The muscles of the abdomen are organised into **three groups** (anterior, lateral and posterior) that form the **abdominal wall**. **All the muscles of the abdomen** significantly cooperate in their functions. Together with the diaphragm and the muscles of the pelvis, the abdominal muscles produce and **maintain intra-abdominal pressure**. Intra-abdominal pressure is important for stabilisation of the vertebral column, defecation, coughing, vomiting and partuition.

1 **Anterior group**
- 1.1 **Rectus abdominis** *(musculus rectus abdominis)*
- 1.2 **Pyramidalis** *(musculus pyramidalis)*

2 **Lateral group**
- 2.1 **External oblique** *(musculus obliquus externus abdominis)*
- 2.2 **Internal oblique** *(musculus obliquus internus abdominis)*
- 2.3 **Transversus abdominis / transverse abdominal** *(musculus transversus abdominis)*
- 2.4 **Cremaster** *(musculus cremaster)*

3 **Posterior group**
- 3.1 **Quadratus lumborum** *(musculus quadratus lumborum)*

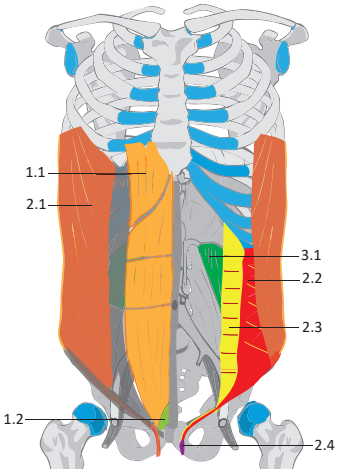

6.1 Muscles of the abdomen – anterior group

The main muscle of the anterior group is the **rectus abdominis.** The rectus abdominis is a paired muscle which connects to its contralateral muscle in the midline at **the linea alba**. **The pyramidalis** is a small rudimentary triangular muscle located ventrocaudally to the rectus abdominis and inside the rectus sheath. **The rectus sheath** is created from the **aponeuroses of the three muscles of the lateral group**.

Rectus abdominis *(musculus rectus abdominis)*

O: 5th–7th rib, sternum – xiphoid process
I: pubis – body of pubis between the pubic symphysis and pubic tubercle, tendinous intersections (transverse tendinous strips in the muscle, usually three with the lowest at the height of the umbilicus
F: ventral flexion of the vertebral column (when the pelvis is fixed), tilting of the pelvis (when the trunk is fixed), pulls the ribs caudally (an auxiliary expiration muscle), contributes to intra-abdominal pressure
N: intercostal nerves VII–XI, subcostal nerve

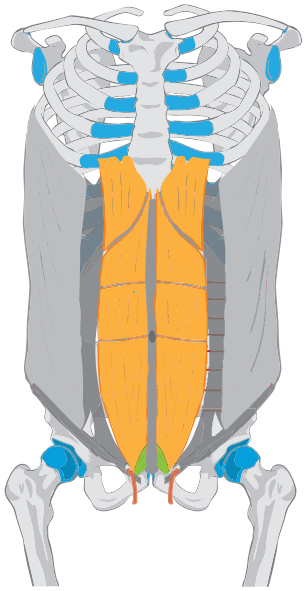

Pyramidalis *(musculus pyramidalis)*

O: pubis (body) – ventrally to the rectus abdominis
I: linea alba – caudal part between the pubic symphysis and the umbilical ring
F: strengthens the rectus sheath
N: subcostal nerve

The inguinal ligament is the strengthened caudal margin of the aponeurosis of the external oblique. It is stretched between the superior anterior iliac spine and pubic tubercle.

The inguinal falx or conjoint tendon (*falx inguinalis, tendo conjunctivus*) is formed by an adhesion between the internal oblique and transversus abdominis.

The rectus abdominis is an important muscle for bipedal locomotion (walking, running and jumping). It is a synergist and stabilisation muscle for the iliopsoas. Important is its eccentric function in deceleration of movement while walking downstairs or downhill. Exercising in the gym is usually focused more on concentric contractions.

The best exercise for the rectus abdominis is the first 20–30 degrees of sit-ups. After this, the iliopsoas is activated more than the rectus abdominis.

The transversus abdominis supports peristalsis and defecation.

The direction of the course of the fibres of the external oblique can be remembered as being the same as the direction of the fingers placed into the front trouser pockets.

Rectus sheath – see page 555
Inguinal canal – see page 556

Clinical notes

Trigger points in the rectus abdominis are situated just above the pubic symphysis. The rectus abdominis is typically overloaded in its upper part between the xiphoid process and umbilicus. It is usually weakened from the umbilicus to the pubic symphysis. The linea alba may be split in extremely obese patients and in a pregnancy. This is called diastasis.

The lateral group of the abdominal muscles is comprised of **three muscles**. Going from superficial to deep they are as follows: **external oblique, internal oblique** and **transversus abdominis**. The internal oblique and transversus abdominis are partially fused together, particularly at their caudal margin, which forms the **inguinal falx**. The **cremaster** is a muscle in males that covers the spermatic cord and scrotum. It originiates from the caudal fibres of the internal oblique and transversus abdominis.

External oblique *(musculus obliquus externus abdominis)*

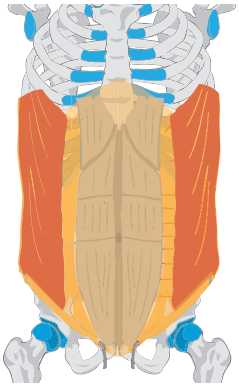

O: from the 5th–12th rib as eight slips (the cranial 5 slips interdigitate with the serratus anterior)
Course of fibers: run in a ventrocaudal direction
I: hip bone – iliac crest (outer lip), linea alba via its aponeurosis
F: ventral flexion of the trunk (bilateral contraction), lateroflexion of the vertebral column to the side of the contracted muscle and rotation to the opposite side (unilateral contraction), contributes to intra-abdominal pressure, an auxiliary muscle of inspiration
N: intercostal nerves V-XI, subcostal nerve

Internal oblique *(musculus obliquus internus abdominis)*

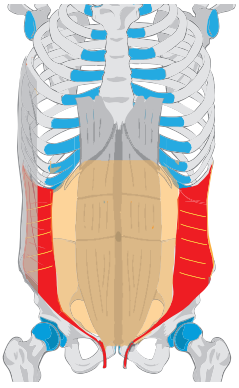

O: thoracolumbar fascia (anterior layer), hip bone – iliac crest (intermediate zone), inguinal ligament (lateral half)
Course of fibres: run in a ventrocranial direction
I: 10th–12th rib, linea alba via its aponeurosis, inguinal falx
F: ventral flexion of the vertebral column when the pelvis is fixed (bilateral contraction), tilting of the pelvis when the trunk is fixed (bilateral contraction), lateroflexion and rotation of the vertebral column to the side of the contracted muscle (unilateral contraction), contributes to intra-abdominal pressure, an auxiliary muscle of expiration
N: intercostal nerves VIII–XI, subcostal nerve, iliohypogastric nerve, ilioinguinal nerve

Transverse abdominal *(musculus transversus abdominis)*

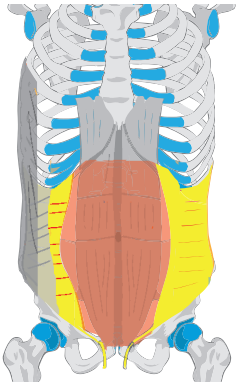

O: 7th–12th rib – internal surface (origins alternate with the origins of the diaphragm), thoracolumbar fascia – anterior layer, hip bone – iliac crest (inner lip), inguinal ligament – lateral part
I: linea alba via its aponeurosis, inguinal falx
F: rotation of the trunk to the side of the contracted muscle (unilateral contraction), stabilises the ribs for optimal function of the diaphragm, contributes to intra-abdominal pressure, an auxiliary muscle of expiration (flattens the abdominal wall)
N: intercostal nerves VII–XI, subcostal nerve, iliohypogastric nerve, ilio-inguinal nerve

Cremaster *(musculus cremaster)*

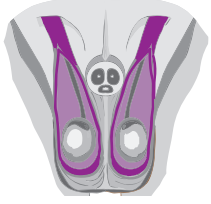

– is composed of fibres from the caudal part of the internal oblique and transversus abdominis
– covers the spermatic cord and scrotum
F: elevates the testis and scrotum towards the body
N: genital branch of genitofemoral nerve (L1 and L2)

This copy belongs to ali yaghoubi

The quadratus lumborum is the only muscle of the posterior group of the abdominal muscles. According to its function, it can be divided into a lateral and a medial part. **The lateral part** is a tonic muscle that has a **tendency to shorten**, and **the medial part** is part of **the deep stabilising system of the lumbar vertebral column**.

Quadratus lumborum *(musculus quadratus lumborum)*

O: 12th rib,
vertebrae L1–L4 – costal processes
I: hip bone – iliac crest,
iliolumbar ligament
F: extension of the vertebral column (bilateral contraction),
lateroflexion of the vertebral column when the pelvis is fixed
elevation of the iliac crest when the vertebral column is fixed (unilateral contraction),
stabilisation of the 12th rib and interaction with movements of the diaphragm (speech, singing),
strong expiration (coughing)
N: subcostal nerve,
anterior rami of L1–L3 (variably L4)

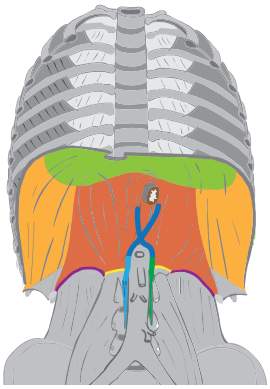

6.4 Fasciae of the abdomen

The fasciae of the abdomen **cover the muscles of the abdomen from both the external and internal side**. **The fascia of Scarpa** is also considered a fascia of the abdomen, although it is thickened subcutaneous connective tissue and not a true fascia.

- 1 **Subcutaneous abdominal fascia / fascia of Scarpa**
  (fascia abdominis subcutanea Scarpae)
  – a layer of thickened subcutaneous connective tissue
  (a membranous layer of the subcutaneous tissue of the abdomen)
  – comprises 2/3 of the width of the subcutaneous tissue,
  – separates the superficial and deep fatty layer
  – more distinct in slim individuals
  – fades away cranially at the level of the umbilicus
  – continues caudally in the lower limbs, perineum and scrotum
    – to the lower limb as the saphenous fascia
    – to the perineum as the superficial perineal fascia (of Colles)
    – to the scrotum as the dartos fascia

- 2 **Superficial abdominal fascia / superficial investing abdominal fascia**
  (fascia abdominis superficialis / fascia investiens abdominis superficialis)
  – the fascia of the external oblique
  – no particular attachments to bones
  – continuous with the pectoral fascia on the thorax
  – continuous with the fascia lata on the femur
  – continuous with the superficial fascia of the back
  – continuous with the perineal fascia (of Gallaudet)
  – continuous with the deep fascia of the penis (of Buck)
  – continuous with the external spermatic fascia of the scrotum

- 3 **Parietal abdominal fascia / endo-abdominal fascia**
  (fascia abdominis parietalis / fascia endoabdominalis)
  – covers all muscles of the abdominal cavity
  (including the diaphragm)
  – continuous with the anterior layer of the thoracolumbar fascia on the quadratus lumborum
  – continuous with the parietal pelvic fascia
  3.1 **Transversalis fascia** *(fascia transversalis)*
  – fascia of the transverse abdominis
  3.2 **Iliac fascia** *(fascia iliaca)* – fascia of the iliopsoas

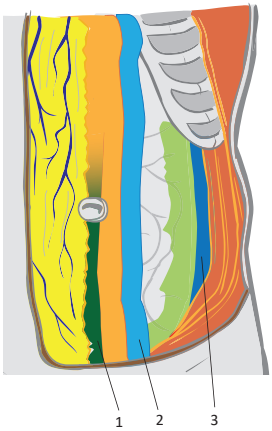

Both quadratus lumborum form a functional unit. They may work in a synergic or antagonist manner based on the particular movements.

The, quadratus lumborum works as an extensor from the neutral position but it is not able to generate extension power from anteflexion to the neutral position.

The pelvic floor muscles work as a one complex unit. They support and protect organs against herniation and work as antagonists of the diaphragm.

The femoral septum (*septum femorale*) is a subdivision of the transversalis fascia in caudal direction from the inguinal ligament. It encloses the vascular space. The transversalis fascia is strengthened in the area of the inguinal ligament and it is fixed to this ligament as the iliopubic tract of Thomson (tractus iliopubicus).

Clinical notes

The quadratus lumborum may be overloaded by carrying or lifting of heavy luggage.

Trigger point of the quadratus lumborum is very painful and may imitate the pain of disc herniation or pyelonephritis.

Exercise of the pelvic floor muscles is recommended before and after delivery as well as for elderly women. Proper exercise helps to minimize the risk of prolapse of organs (urinary bladder, vagina, uterus or rectum) and urine incontinence.

The muscles of the pelvic floor are organised into the **shape of a funnel**. They attach to **the walls of the lesser pelvis and contain passages for the rectum, vagina and urethra**. They contribute to the creation of intra-abdominal pressure and and are part of the deep stabilising system.

- 1 **Levator ani** *(musculus levator ani)*
- 2 **Ischiococcygeus/coccygeus** *(musculus ischococcygeus / coccygeus)*
- 3 **External anal sphincter** *(musculus sphincter ani externus)*

Levator ani *(musculus levator ani)*

- 1 **Iliococcygeus** *(musculus iliococcygeus)*
  - **O:** hip bone – ischial spine, tendinous arch of the levator ani (ligamentous band on the obturator fascia)
  - **I:** coccyx – lateral side, iliococcygeal raphe (connects to the anococcygeal ligament)
- 2 **Pubococcygeus** *(musculus pubococcygeus)*
  - – muscular bands between the coccyx and pubis
  - – encircles the organs of the lesser pelvis
  - – is divided into parts that are not macroscopically visible (puboperineal, puboprostatic, pubovaginal and puboanal parts)
- 3 **Puborectal** *(musculus puborectalis)*
  - – muscular bands below the pubococcygeus
  - **O:** pubis – superior ramus
  - **I:** encircles the rectum – connects to the contralateral muscle

Function
- – compresses the organs of the pelvic outlet
- – elevates the pelvic floor and anus
- – contributes to the support of the uterus
- – contributes to anorectal and urine continence (an accessory sphincter of the anus)
- – contributes to intra-abdominal pressure
- – belongs to the deep stabilising system (together with the deep back muscles, diaphragm and muscles of the abdomen maintains the stability of the vertebral column)

Innervation: pudendal nerve, anterior rami of the spinal nerves S2–S4

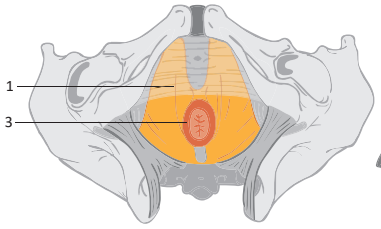

Inferior view to the levator ani

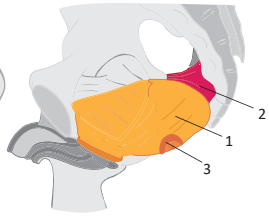

Sagittal section of the levator ani

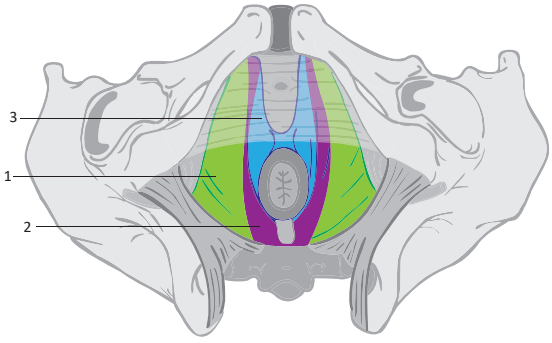

Inferior view to the levator ani

Ischiococcygeus/coccygeus *(musculus ischiococcygeus/coccygeus)*

– a thin muscle that merges with the sacrospinous ligament
O: hip bone – ischial spine, sacropinous ligament, wall of the pelvis
I: coccyx, vertebra L5
F: pulls the coccyx ventrally to its former position (during defecation or delivery)
N: anterior ramus of the spinal nerve S4

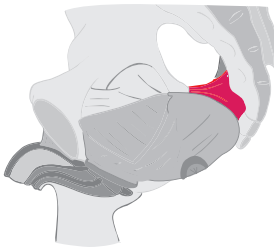
Sagittal section of the pelvis

External anal sphincter *(musculus sphincter ani externus)*

- 1 **Subcutaneous part** *(pars subcutanea)* – below the internal anal sphincter
- 2 **Superficial part** *(pars superficialis)* – encircles the caudal part of the internal anal sphincter
- 3 **Deep part** *(pars profunda)* – encircles the cranial part of the internal anal sphincter
  - – partially merges with the puborectalis

Function: compresses the anal canal and therefore maintains anorectal continence
Innervation: pudendal nerve, anterior rami of the spinal nerves S3–S4

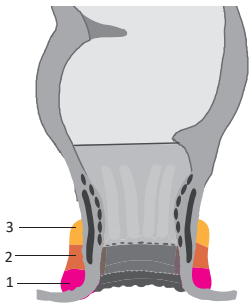

Frontal section of the rectum

This copy belongs to ali yaghoubi

The inner wall of the lesser pelvis is covered by **the parietal pelvic fascia**. The pelvic fasciae can be divided into **the fasciae of the pelvic floor muscles** and **the perineal fasciae**. **The superficial perineal fascia** is not a true fascia, but rather a thickening of subcutaneous connective tissue. It transits into the fascia of Scarpa on the abdomen and into the saphenous fascia on the thigh.

- 1 **Parietal pelvic fascia / endopelvic fascia** *(fascia pelvis parietalis / fascia endopelvina)*
  - – covers the internal surface of all muscles of the pelvic cavity and pelvic floor
  - – continues into the parietal abdominal fascia on the abdomen
  - 1.1 **Obturator fascia** *(fascia obturatoria)*
    - 1.1.1 **Tendinous arch of pelvic fascia** *(arcus tendineus fasciae pelvis)*
      - – the transition between the parietal and visceral pelvic fasciae
    - 1.2 **Piriformis fascia** *(fascia musculi piriformis)*
    - 1.3 **Presacral fascia of Waldeyer** *(fascia presacralis)*
      - – covers the sacrum
    - 1.4 **Retrosacral fascia** *(fascia retrosacralis)*
      - – runs from the caudal part of the rectum to the sacrum
  - 1.5 **Superior fascia of pelvic diaphragm** *(fascia superior diaphragmatis pelvis)*
    - – covers the mediocranial surface of the levator ani
- 2 **Inferior fascia of pelvic diaphragm** *(fascia inferior diaphragmatis pelvis)*
  - – covers the laterocaudal surface of the levator ani
- 3 **Perineal fascia of Gallaudet** *(fascia perinei / fascia investiens perinei superficialis)*
  - – covers the caudal surface of the urogenital floor (perineal membrane / deep transverses perineal muscle, ischiocavernosus, bulbospongiosus)
  - – separates the erectile bodies from the subcutaneous tissue of the perineum
  - – continues into the superficial abdominal fascia
  - – continues into the deep fascia of the penis (of Buck)
  - – continues into the external spermatic fascia of the scrotum
  - – continues into the fascia lata on the femur
  - – continues into the gluteal fascia
- 4 **Superficial perineal fascia of Colles** *(fascia perinei superficialis)*
  - – a thickened layer of subcutaneous tissue (the membranous layer of the subcutaneous tissue of the abdomen)
  - – continues into the subcutaneous abdominal fascia (of Scarpa)
  - – continues into the saphenous fascia on the femur
  - – continues into the superficial fascia of the penis
  - – continues into the dartos fascia on the scrotum



The level of the frontal section

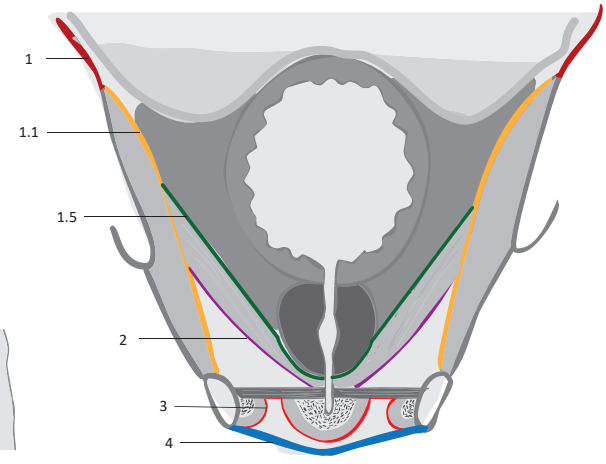

Frontal section of the male pelvis

Muscles

The obturator fascia represents a continuation of the inferior fascia of the pelvic diaphragm onto the obturator internus.

The perineal muscles are a specific group of muscles – they do not belong to the group of the pelvic floor muscles (for detail see page 256).

The superior and inferior fasciae of the urogenital diaphragm (*fascia diaphragmatis urogenitalis superior et inferior*) are obsolete terms for the deep and superficial investing fasciae of the perineum (*fascia investiens perinei profunda et superficialis*).

Particular parts of the deltoid have different functions: the spinal part and clavicular part are phasic muscles, in comparison to the acromial part which is more tonic. The acromial part of the deltoid and supraspinatus fix the head of the humerus in the glenoid cavity.

The infraspinatus and teres minor (external rotators of the arm) tend to weaken frequently in comparison to the internal rotators (pectoralis major, subscapularis, latissimus dorsi and teres major).

Mnemonics for the rotator cuff: SITS muscles (**s**upraspinatus, **i**nfraspinatus, **t**eres minor and **s**ubscapularis).

Clinical notes

Triggers point in the deltoid may be caused by injuries or may originate in other muscles (infraspinatus, pectoralis major and trapezius).

Pain from the deltoid is typically located in the area of the deltoid tuberosity. Weakening of the deltoid leads to disequilibrium of the deltoid and trapezius with a typical position of the arm in elevation and abduction.

The most common injured tendon of the external arm rotators is the tendon of the supraspinatus. Pain typically radiates to the acromial region and lateral humeral epicondyle.

The infraspinatus and supraspinatus are the most common triggers of pain in the region of the arm. Pain originating in the infraspinatus radiates to the lateral side of the arm and forearm and the ventral shoulder region. Trigger points of this muscle may lead to sleep disturbances that predominantly occur when sleeping in the supine position.

In addition to the muscles of the upper limb proper, **the thoracohumeral and spinohumeral muscles functionally belong to the group of muscles of the upper limb**. The muscles of the upper limb proper include: muscles of the shoulder joint, muscles of the arm, muscles of the forearm and hand muscles. **The hand muscles** allow p**recise and delicate movements of the hand and fingers.**

8.1 Muscles of the shoulder joint

The muscles of the shoulder joint surround the shoulder joint. The supraspinatus, infraspinatus, teres minor and subscapularis form **the rotator cuff**, which allows **rotation of the humerus** at the shoulder joint, provides **stability** to the shoulder and **prevents dislocation**.

- 1 **Deltoid** *(musculus deltoideus)*
- 2 **Supraspinatus** *(musculus supraspinatus)*
- 3 **Infraspinatus** *(musculus infraspinatus)*
- 4 **Teres major** *(musculus teres major)*
- 5 **Teres minor** *(musculus teres minor)*
- 6 **Subscapularis** *(musculus subscapularis)*

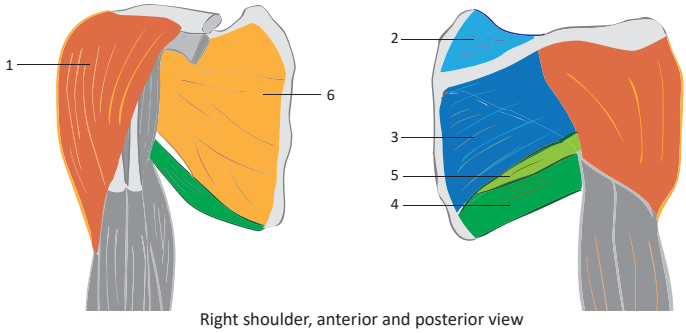

Right shoulder, anterior and posterior view

Deltoid *(musculus deltoideus)*

– multipennate muscle

Origin:
- 1 **Spinal part** *(pars spinalis)*: scapula – lateral 2/3 of the spine of the scapula
- 2 **Acromial part** *(pars acromialis)*: scapula – acromion
- 3 **Clavicular part** *(pars clavicularis)*: clavicle – lateral 1/3

Insertion: humerus – deltoid tuberosity

Function:

the muscle working as whole presses the head of the humerus into the articular fossa of the shoulder joint and therefore increases stability of the shoulder joint

1 **Spinal part** *(pars spinalis)*: dorsal flexion and external rotation of the arm
2 **Acromial part** *(pars acromialis)*: abduction of the arm
3 **Clavicular part** *(pars clavicularis)*: ventral flexion, abduction and internal rotation of the arm

Innervation: axillary nerve (C5 and C6)

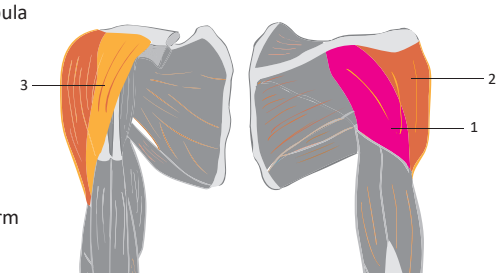

Supraspinatus *(musculus supraspinatus)*

O: scapula – supraspinous fossa
I: humerus – greater tubercle
F: initial abduction and external rotation of the arm, stabilisation of the head of the humerus in the articular fossa of the shoulder joint
N: suprascapular nerve (C5)

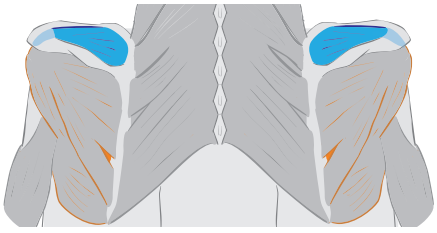

Infraspinatus *(musculus infraspinatus)*

O: scapula – infraspinous fossa
I: humerus – greater tubercle
F: adduction and external rotation of the arm
N: suprascapular nerve (C5 and C6)

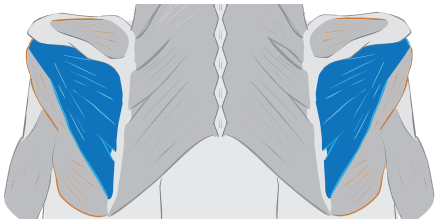

This copy belongs to ali yaghoubi

Teres minor *(musculus teres minor)*

O: scapula – cranial 2/3 of the lateral border
I: humerus – greater tubercle
F: adduction and external rotation of the arm
N: axillary nerve (V5, variably C4–C6)

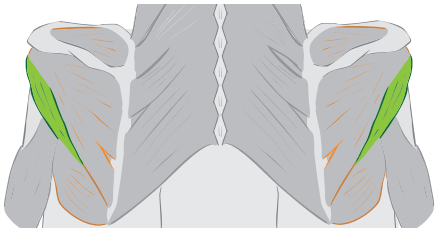

Teres major *(musculus teres major)*

O: scapula – caudal 1/3 of the lateral border
I: humerus – crest of the lesser tubercle
F: adduction, dorsal flexion and internal rotation of the arm
N: subscapular nerve (C6)

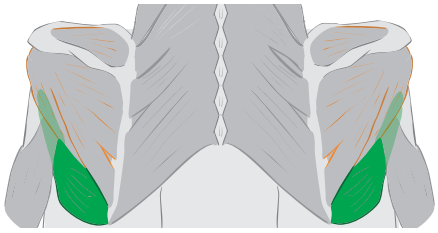

Subscapularis *(musculus subscapularis)*

O: scapula (costal surface) – muscular lines
I: humerus – lesser tubercle
F: adduction and internal rotation of the arm
N: subscapular nerve (C5 and C6)

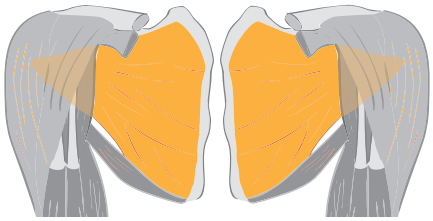

8.2 Muscles of the arm – Musculi brachii

The muscles around the humerus can be divided into an **anterior and a posterior group**. These muscles **act on the shoulder and elbow joints**. **The anterior group** consists of **flexors** of the shoulder and elbow joints and is innervated by the **musculocutaneous nerve**. **The posterior group** consists of **extensors** of the shoulder and elbow joints and is innervated by the **radial nerve**.

1 **Anterior (flexor) group**
- 1.1 **Biceps brachii** *(musculus biceps brachii)*
- 1.2 **Coracobrachialis** *(musculus coracobrachialis)*
- 1.3 **Brachialis** *(musculus brachialis)*

2 **Posterior (extensor) group**
- 2.1 **Triceps brachii** *(musculus triceps brachii)*
- 2.2 **Anconeus** *(musculus anconeus)*

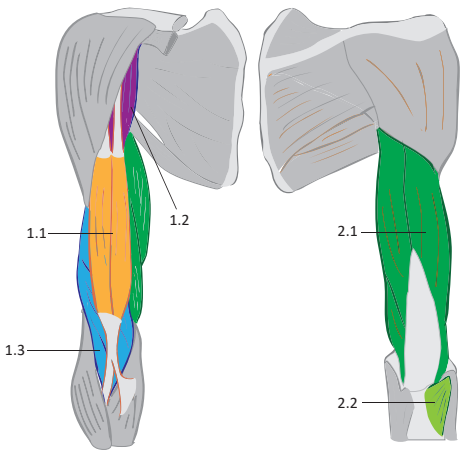

Anterior and posterior views of the right arm

Muscles

The tendon of the long head of the biceps brachii is the only tendon in the body which runs through the inside of a joint. The tendon is covered by a synovial membrane within the joint and by a synovial sheath when leaving the articular capsule in the intertubercular groove.

When the function of the anconeus is eliminated, extension of the elbow joint is decreased by 20 %.

Cubitus is a Latin term for elbow.
Ancon is a Greek term for elbow.
Lacerta is a Latin term for lizard.

Clinical notes

When performing chin-ups, an acute overload injury of the teres major may occur. This results in a slight reduction in ventral flexion.

A trigger point in the teres minor can cause a loss of sensation or a tingling sensation in the fourth and fifth fingers. This has to be distinguished from palsy of the ulnar nerve.

Trigger points in the subscapularis are often fundamental in diagnosing frozen shoulders and painful shoulders in hemiplegia. Pain projects to the scapular region, dorsal side of the arm and on a strip around the wrist. The most common complaint from the patient is a limitation of abduction. However, a significant limitation of external rotation also occurs, of which the patient is rarely aware.

Patients with trigger points in the biceps brachii complain of pain in the ventral part of the shoulder joint (but not inside the shoulder joint itself).

The coracobrachialis can compress the musculocutaneous nerve when overloaded or hyperthrophied causing entrapment syndrome. It is necessary to distinguish this from radiculopathy of C5/6 and from damage to the lateral cord of the brachial plexus. When the musculocutaneous nerve is compressed, the muscle still maintains its function because the motor branch is proximal to the compression.

When a trigger point in the long head of the triceps brachii is present, the patient cannot touch his ear with his hand (the triceps brachii test).

Pain originating from the lateral head of the triceps brachii is located over the lateral epicondyle of the humerus. Pain from the medial head is located over the medial epicondyle.

Biceps brachii *(musculus biceps brachii)*

– the biceps brachii is comprised of a long head and a short head

Origin:
- 1 **Long head** *(caput longum)*: scapula – supraglenoid tubercle
- 2 **Short head** *(caput breve)*: scapula – coracoid process

Insertion:
radius – radial tuberosity,
medial side of the forearm – antebrachial fascia
via the bicipital aponeurosis (*lacertus fibrosus*)

Function:
at the shoulder joint:
– abduction of the arm (long head)
– adduction and ventral flexion of the arm (short head)
at the elbow joint:
– supination of a pronated forearm
– flexion (only when the forearm is supinated)

Innervation: musculocutaneous nerve (C5 and C6)

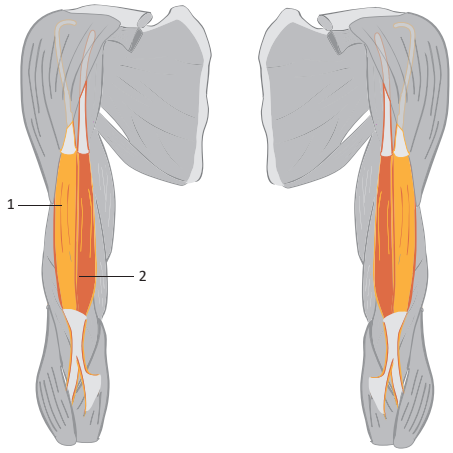

Anterior view of the right and left arms

Coracobrachialis *(musculus coracobrachialis)*

- 1 **Coracobrachialis** *(musculus coracobrachialis)*

O: scapula – coracoid process
I: humerus (anteromedial surface) – in the middle of the humerus
F: adduction and ventral flexion of the arm,
returns the arm to the middle (basic) position from both external and internal rotation
N: musculocutaneous nerve (C6 and C7)

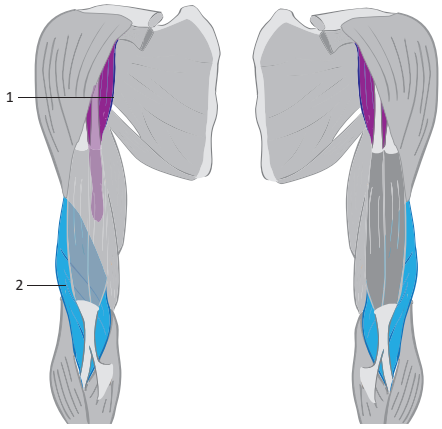

Anterior view of the right and left arms

Brachialis *(musculus brachialis)*

- 2 **Brachalis** *(musculus brachialis)*

O: humerus (anterior surface) – distal half
I: ulna – tuberosity of ulna
F: flexion of the forearm
N: musculocutaneous nerve (C5–C6)

Triceps brachii *(musculus triceps brachii)*

– the triceps brachii is comprised of a long head,
medial head and lateral head

Origin:
- 1 **Long head** *(caput longum)*: scapula – infraglenoid tubercle
- 2 **Lateral head** *(caput laterale)*: humerus – proximal to the radial groove
- 3 **Medial head** *(caput mediale)*: humerus – distal to the radial groove

Insertion: ulna – olecranon

Function:
whole muscle: extension of the forearm
only the long head: adduction of an extended arm

Innervation: radial nerve (C6–C8)

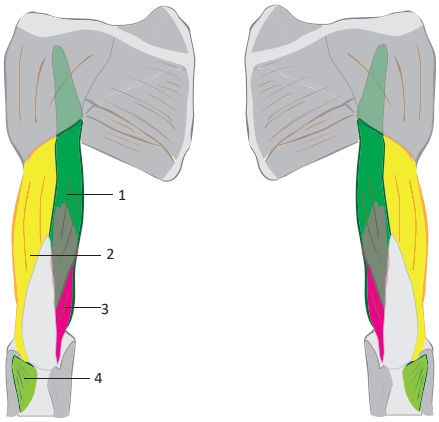

Posterior view of the right and left arms

Anconeus *(musculus anconeus)*

- 4 **Anconeus** *(musculus anconeus)*

O: humerus – lateral epicondyle, radial collateral ligament
I: ulna (posterior border) – proximally up to the olecranon
F: accessory extensor of the forearm,
stretches the articular capsule of the elbow joint and therefore prevents its constriction,
stabilises the elbow joint during supination and pronation
N: radial nerve (C7–C8)

This copy belongs to ali yaghoubi

The muscles of the forearm are divided into **3 groups**: anterior, lateral and posterior groups. They act on **the elbow joint, wrist joint and joints of the hand**.

1 Anterior (flexor) group

1st layer

- 1.1 **Palmaris longus** *(musculus palmaris longus)*
- 1.2 **Pronator teres** *(musculus pronator teres)*
- 1.3 **Flexor carpi radialis** *(musculus flexor carpi radialis)*
- 1.4 **Flexor carpi ulnaris** *(musculus flexor carpi ulnaris)*

2nd layer

- 1.5 **Flexor digitorum superficialis** *(musculus flexor digitorum superficialis)*

3rd layer

- 1.6 **Flexor digitorum profundus** *(musculus flexor digitorum profundus)*
- 1.7 **Flexor pollicis longus** *(musculus flexor pollicis longus)*

4th layer

- 1.8 **Pronator quadratus** *(musculus pronator quadratus)*

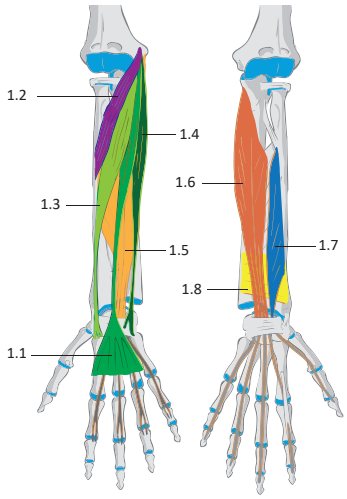

Anterior view of the right and left forearms

2 Lateral (radial) group

Superficial layer

- 2.1 **Brachioradialis** *(musculus brachioradialis)*
- 2.2 **Extensor carpi radialis longus** *(musculus extensor carpi radialis longus)*
- 2.3 **Extensor carpi radialis brevis** *(musculus extensor carpi radialis brevis)*

Deep layer

- 2.4 **Supinator** *(musculus supinator)*

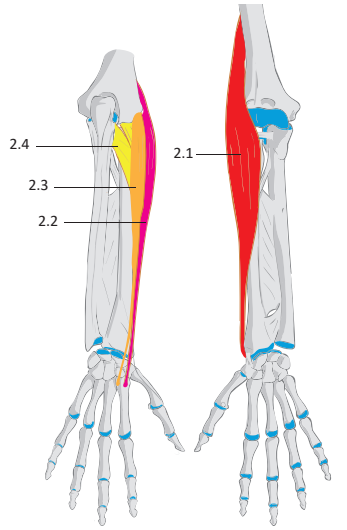

Anterior and posterior views of the right forearm

3 Posterior (extensor) group

Superficial layer

- 3.1 **Extensor digitorum** *(musculus extensor digitorum)*
- 3.2 **Extensor digiti minimi** *(musculus extensor digiti minimi)*
- 3.3 **Extensor carpi ulnaris** *(musculus extensor carpi ulnaris)*

Deep layer

- 3.4 **Abductor pollicis longus** *(musculus abductor pollicis longus)*
- 3.5 **Extensor pollicis brevis** *(musculus extensor pollicis brevis)*
- 3.6 **Extensor pollicis longus** *(musculus extensor pollicis longus)*
- 3.7 **Extensor indicis** *(musculus extensor indicis)*

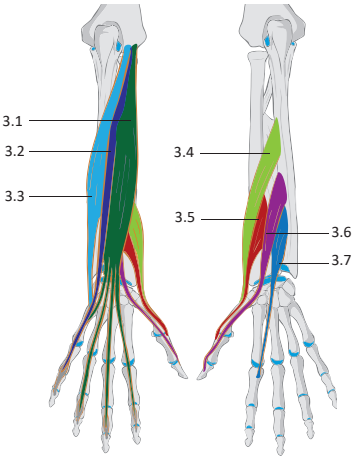

Posterior view of the right and left forearms

Muscles

The flexors and supinators of the forearm are more dominant than the extensors and pronators. The flexors and supinators may shorten during long periods of inactivity, as occurs in bedridden patients.

The palmaris longus is a functionally insignificant muscle and is absent in 10 % of cases. It can be used for tendon grafts.

The common ulnar head *(caput commune ulnare)* is the common origin of the first and the second layers of the ventral group of the forearm muscles.

The flexor carpi radialis courses through the carpal canal in its own separate section and then through a groove on the trapezium.

Pronator canal, supinator canal, cubital canal see page 575.

Clinical notes

Golfer's elbow is an overuse injury of the flexors that originate on the medial epicondyle. It can be caused by manual labor and is characterised by pain over the medial epicondyle.

Tennis elbow is an overuse injury of the extensors that originate on the lateral epicondyle. It can be caused by working on computers for long periods of time and is characterised by pain over the lateral epicondyle.

The palm and the palmar part of the wrist are painful when **the palmaris longus is overloaded**. The pain is described as "thousands of tiny needles" and it makes it difficult to work with tools.

Shortening of the pronator teres occurs from working on a computer while positioning the mouse in front of the body, rather than on the side. This position is characterised by internal rotation of the arm and flexion and pronation of the forearm. The shortened pronator teres limits the extent of flexion of the forearm and makes the extensors of the forearm disproportionally long.

The flexor carpi radialis brevis is a variable muscle, which, if present can compress the anterior interosseous nerve.

The pronator, supinator and cubital canals are narrow spaces between the muscles of the forearm through which the median nerve, deep branch of the radial nerve and ulnar nerve run, respectively. These nerves may be compressed in their canals, causing nerve entrapment syndromes.

The anterior muscles of the forearm are divided into **four layers**. They are **flexors and pronators of the forearm**. These muscles are innervated predominantly by the **median nerve,** although the flexor carpi ulnaris and part of the flexor digitorum profundus are innervated by the **ulnar nerve**. The pronator teres, flexor carpi ulnaris and flexor digitorum superficialis each have two heads, through which nerves from the upper arm pass to the forearm.

Pronator teres *(musculus pronator teres)*

– a muscle of the 1st layer
Origin:
- 1 **Humeral head** *(caput humerale)*: humerus – medial epicondyle
- 2 **Ulnar head** *(caput ulnare)*: ulna – coronoid process

I: radius – pronator tuberosity
F: flexion and pronation of the forearm
N: median nerve (C6–C7)

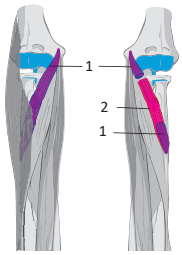

Anterior view of the right and left forearms

Flexor carpi radialis *(musculus flexor carpi radialis)*

– a muscle of the 1st layer
O: humerus – medial epicondyle and antebrachial fascia
I: base of the 2nd and 3rd metacarpal (anterior surface)
F: flexion of the forearm,
radial duction and flexion of the hand
N: median nerve (C6–C7)

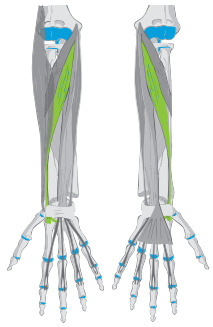
Anterior view of the right and left forearms

Palmaris longus *(musculus palmaris longus)*

– a muscle of the 1st layer
O: humerus – medial epicondyle and antebrachial fascia
I: palmar aponeurosis,
flexor retinaculum
F: an accessory flexor of the forearm and hand,
stretches the palmar aponeurosis
N: median nerve (C8, variably C7–T1)

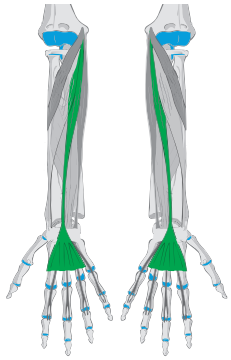
Anterior view of the right and left forearms

Flexor carpi ulnaris *(musculus flexor carpi ulnaris)*

– a muscle of the 1st layer
Origin:
- 1 **Humeral head** *(caput humerale)*: humerus – medial epicondyle
- 2 **Ulnar head** *(caput ulnare)*: ulna – olecranon and posterior border

I: pisiform,
hook of hamate (as the pisohamate ligament),
base of the 5th metacarpal (as the pisometacarpal ligament)
F: flexion of the forearm,
ulnar duction and flexion of the hand
N: ulnar nerve (C8–T1)

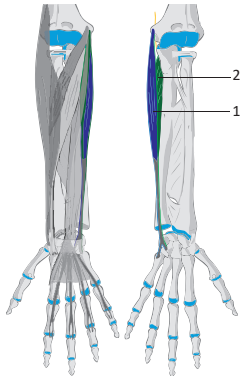

Anterior view of the right and left forearms

This copy belongs to ali yaghoubi

Flexor digitorum superficialis *(musculus flexor digitorum superficialis)*

– a muscle of the 2nd layer
Origin:
- 1 **Humero-ulnar head** *(caput humeroulnare)*:
  humerus – medial epicondyle,
  ulna – ulnar tuberosity,
  ulnar collateral ligament
- 2 **Radial head** *(caput radiale)*:
  radius – anterior surface from radial
  to pronator tuberosity

I: as four tendons to the 2nd–5th digits, which bifurcate to insert on both sides of the base of the middle phalanx
F: flexion of the 2nd–5th digits at the metacarpophalangeal and proximal interphalangeal joints, accessory flexion of the forearm and hand
N: median nerve (C7–T1)

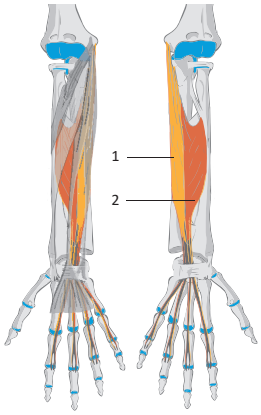

Anterior view of the right and left forearms

Flexor digitorum profundus *(musculus flexor digitorum profundus)*

– a muscle of the 3rd layer
O: ulna – anterior surface, interosseous membrane of forearm
I: as four tendons on the 2nd–5th finger that insert on the base of the distal phalanges
F: flexion of the 2nd–5th fingers at the metacarpophalangeal and interphalangeal joints, accessory flexion of the hand
N: median nerve (C7–T1) – for the 2nd and 3rd finger, ulnar nerve (C8–T1) – for the 4th and 5th finger

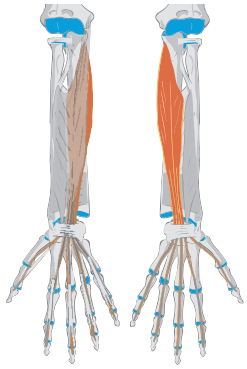
Anterior view of the right and left forearms

Flexor pollicis longus *(musculus flexor pollicis longus)*

– a muscle of the 3rd layer
O: radius – anterior surface, between the insertion of the pronator teres proximally and the insertion of the pronator quadratus distally, interosseous membrane of forearm
I: base of the distal phalanx of the thumb
F: flexion of the thumb at the metacarpophalangeal and interphalangeal joints, accessory flexion of the hand
N: median nerve (C6–C7)

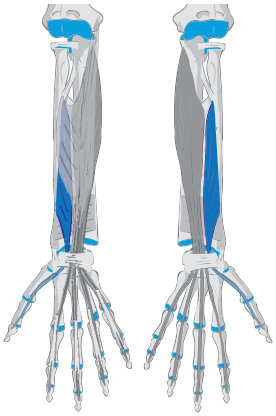
Anterior view of the right and left forearms

Pronator quadratus *(musculus pronator quadratus)*

– a muscle of the 4th layer
O: ulna – distal 1/4 of the anterior surface
I: radius – distal 1/4 of the anterior surface
F: pronation of the forearm
N: median nerve (C7–T1)

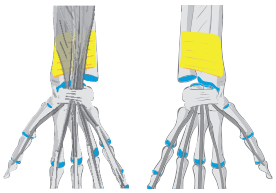
Anterior view of the right and left forearms

The tendons of the flexor carpi radialis, flexor digitorum superficialis and profundus and flexor pollicis longus are covered by synovial sheaths as they run through the carpal canal.

Contraction of the flexor digitorum profundus is not possible during passive extension of the fingers. This effect is diagnostically important when examining the hand and wrist when injury to the tendons is suspected.

Tendinous chiasm *(chiasma tendinum)* means crossing of tendons. This occurs at the middle phalanges as the tendons of the flexor digitorum profundus pass through the bifurcated tendons of the flexor digitorum superficialis to insert on the distal phalanges.

The common radial head *(caput commune radiale)* is the common origin of the lateral group and superficial layers of the dorsal group of the forearm muscles on the lateral epicondyle of the humerus.

The supinator canal *(canalis supinatorius)* is a space between the layers of the supinator where the deep branch of the radial nerve passes – see page 575.

The most important function of the extensor carpi radialis longus and brevis is prevention of ventral flexion of the wrist when grasping. The larger the object that is being grasped, the greater the load on these muscles.

Clinical notes

When a trigger point is present in the flexor digitorum profundus and flexor pollicis longus, the patient feels pain in the whole finger and even distally to the finger tips.

Pain from trigger points of the lateral group of the forearm muscles is located over the lateral epicondyle of the humerus.

The extensor carpi radialis brevis can compress the sensory branches of the radial nerve.

The lateral group of the forearm muscles consists of two layers of muscles that have a **common innervation by the radial nerve**. The superficial layer consists of three muscles, which have a common function of **pronation of the flexed forearm** and **supination of the extended forearm**. The deep layer consists of one muscle, the supinator, which is made up of two layers of fibres and acts as a **supinator of the forearm**.

Brachioradialis *(musculus brachioradialis)*

– a muscle of the superficial layer
O: humerus – lateral supraepicondylar ridge
I: radius – suprastyloid crest
F: supination of the extended forearm,
pronation of the flexed forearm,
flexion of the forearm,
stabilises the elbow joint to
prevent its overstretching
N: radial nerve (C5–C6)

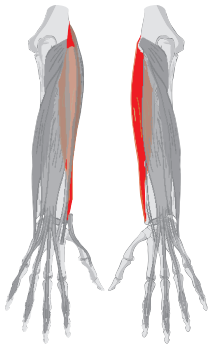

Posterior view of the right and left forearms

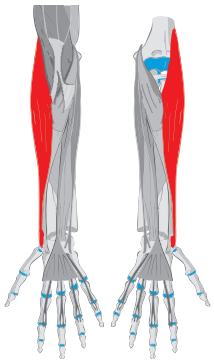

Posterior view of the right and left forearms

Extensor carpi radialis longus *(musculus extensor carpi radialis longus)*

– a muscle of the superficial layer
O: humerus – lateral supraepicondylar ridge
distally to the brachioradialis
I: base of the 2nd metacarpal – posterior surface
F: dorsal flexion and radial duction of the hand
supination of the extended forearm,
pronation of the flexed forearm,
accessory flexion of the forearm
N: radial nerve (C6–C7)

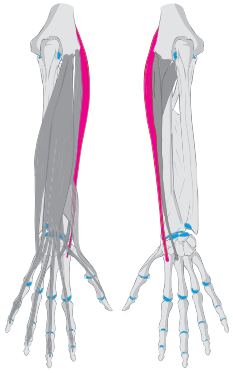

Posterior view of the right and left forearms

Extensor carpi radialis brevis *(musculus extensor carpi radialis brevis)*

– a muscle of the superficial layer
O: humerus – lateral epicondyle,
radial collateral ligament
I: base of the 3rd metacarpal – posterior surface
F: dorsal flexion and radial duction of the hand,
supination of the extended forearm,
pronation of the flexed forearm
N: radial nerve (C6–C7)

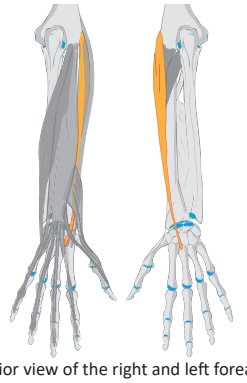

Posterior view of the right and left forearms

Supinator *(musculus supinator)*

– a muscle of the deep layer
– consists of 2 parts (layers)
Origin:
- 1 **Superficial layer:**
  humerus – lateral epicondyle,
  radial collateral ligament,
  anular ligament of radius
- 2 **Deep layer:**
  ulna – supinator crest

I: radius – laterally and proximally
to the pronator tuberosity
F: supination of the forearm
N: radial nerve (C5–C7)

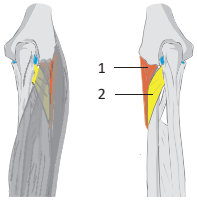

Posterior view of the proximal parts
of the right and left forearms

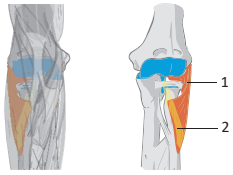

Anterior view of the proximal parts
of the right and left forearms

This copy belongs to ali yaghoubi

The posterior group of the forearm muscles is organised into two layers. These muscles are **extensors** and have a common innervation by **the radial nerve**. The tendons of all muscles of the posterior group are covered by tendinous sheaths as they run through osteofibrous canals under the extensor retinaculum to the dorsum of the hand. The extensor carpi ulnaris has two heads.

Extensor digitorum *(musculus extensor digitorum)*

– a muscle of the superficial layer
O: humerus – lateral epicondyle and antebrachial fascia
I: as four tendons to the 2nd–5th fingers, which insert on the dorsal aponeurosis on the base of the middle and distal phalanges
F: extension of the 2nd–5th fingers at the metacarpophalangeal and proximal and distal interphalangeal joints, dorsal flexion of the hand
N: radial nerve (C6–C8)

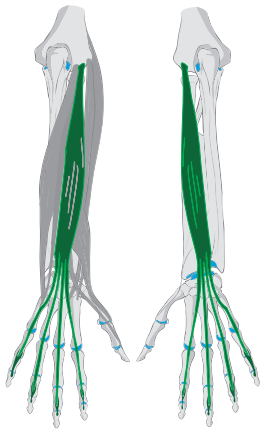

Posterior view of the right and left forearms

Extensor digiti minimi *(musculus extensor digiti minimi)*

– a muscle of the superficial layer
O: humerus – lateral epicondyle
I: dorsal aponeurosis of the 5th finger on the base of the middle and distal phalanges
F: extension of the 5th finger at the metacarpophalangeal joint and proximal and distal interphalangeal joints, flexion of the hand
N: radial nerve (C7–C8)

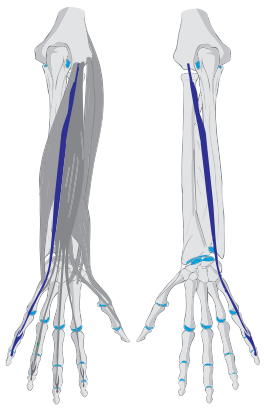

Posterior view of the right and left forearms

Extensor carpi ulnaris *(musculus extensor carpi ulnaris)*

– a muscle of the superficial layer
Origin:
- 1 **Humeral head** *(caput humerale)*: humerus – lateral epicondyle
- 2 **Ulnar head** *(caput ulnare)*: ulna – posterior border

I: base of the 5th metacarpal – medial side
F: ulnar duction and dorsal flexion of the hand
N: radial nerve (C7–C8, variably C6)

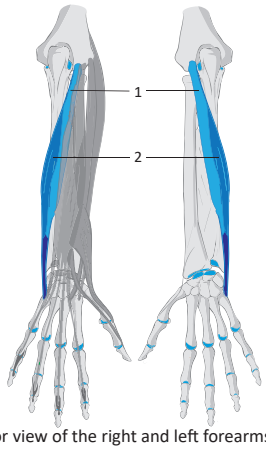

Posterior view of the right and left forearms

Intertendinous connections *(connexus intertendinei)* are connections between the tendons of the extensor digitorum.

The dorsal aponeurosis *(aponeurosis dorsalis)* is a fibrous structure on the back of the fingers, which attaches to the middle and distal phalanges. The extensor digitorum, extensor indicis, extensor digiti minimi, lumbricals and interossei insert on the phalanges through the dorsal aponeurosis.

Clinical notes

Trigger points often develop in the **extensor digitorum** due to overloading of the flexor digitorum superficialis and profundus.

Transposition of the tendons of the forearm muscles is a surgical procedure to regain hand function after injury to the tendons of the forearm muscles. If muscles important for hand function are irreversibly damaged, it is possible to transpose a tendon of another muscle which is not essential for hand function (for example the extensor pollicis brevis or flexor digitorum superficialis) on the stump of the original tendon. The result is a functional muscle that has the origin, belly and supply of the transposed muscle, but the insertion and similar function as the lost muscle.

Abductor pollicis longus *(musculus abductor pollicis longus)*

– a muscle of the deep layer
O: radius – middle 1/3 of the posterior surface
ulna – middle 1/3 of the posterior surface
interosseous membrane of forearm – middle 1/3 of the posterior surface
I: base of the 1st metacarpal – lateral side
trapezium
F: abduction of the thumb,
radial duction of the hand
N: radial nerve (C6–C7)

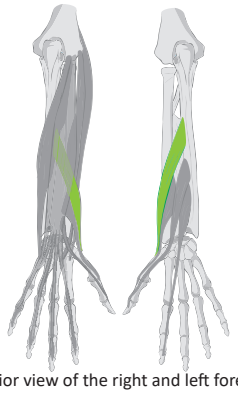

Posterior view of the right and left forearms

Extensor pollicis brevis *(musculus extensor pollicis brevis)*

– a muscle of the deep layer
O: radius – middle 1/3 of the posterior surface
interosseous membrane of forearm – middle 1/3 of the posterior surface
I: proximal phalanx of thumb – posterior surface
F: extension and abduction of the thumb
at the carpometacarpal and metacarpophalangeal joints
N: radial nerve (C6–C7)

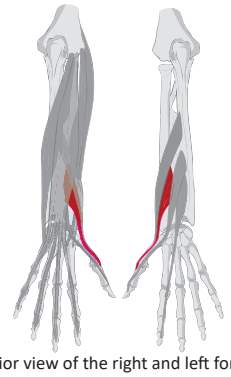

Posterior view of the right and left forearms

Extensor pollicis longus *(musculus extensor pollicis longus)*

– a muscle of the deep layer
O: ulna – middle 1/3 of the posterior surface
interosseous membrane of forearm – middle 1/3 of the posterior surface
I: proximal phalanx of thumb (posterior surface)
F: extension of the thumb (in the carpometacarpal,
metacarpophalangeal and interphalangeal joint),
accessory abductor of the thumb
N: radial nerve (C6–C7, variably C8)



Posterior view of the right and left forearms

Extensor indicis *(musculus extensor indicis)*

– a muscle of the deep layer
O: ulna – distal 1/3 of the posterior surface
interosseous membrane of forearm – distal 1/3 of the posterior surface
I: dorsal aponeurosis of the 2nd finger,
base of the middle and distal phalanges of the 2nd digit
F: extension of the 2nd digit at the metacarpophalangeal joint and
proximal and distal interphalangeal joints,
accessory flexion of the hand
N: radial nerve (C6–C7)

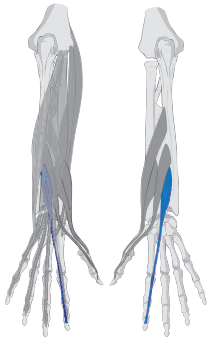

Posterior view of the right and left forearms

This copy belongs to ali yaghoubi

The intrinsic muscles of the hand can be divided into **4 groups: the muscles of the thenar eminence, the muscles of the hypothenar eminence, the interossei muscles and the lumbricals**. The superficial thenar muscles (abductor pollicis brevis, opponens pollicis and superficial head of the flexor pollicis brevis) and the two medial lumbricals are innervated by **the median nerve**. All other intrinsic hand muscles are innervated by **the ulnar nerve**.

1 **Muscles of the thenar eminence / thenar muscles** (thumb group)
- 1.1 **Abductor pollicis brevis** *(musculus abductor pollicis brevis)*
- 1.2 **Opponens pollicis** *(musculus opponens pollicis)*
- 1.3 **Flexor pollicis brevis** *(musculus flexor pollicis brevis)*
- 1.4 **Adductor pollicis** *(musculus adductor pollicis)*

2 **Muscles of the hypothenar eminence / hypothenar muscles** (little finger group)
- 2.1 **Palmaris brevis** *(musculus palmaris brevis)*
- 2.2 **Abductor digiti minimi** *(musculus abductor digiti minimi)*
- 2.3 **Flexor digiti minimi brevis** *(musculus flexor digiti minimi brevis)*
- 2.4 **Opponens digiti minimi** *(musculus opponens digiti minimi)*

3 **Interossei** *(musculi interossei)*
- 3.1 **Palmar interossei** *(musculi interossei palmares)*
- 3.2 **Dorsal interossei** *(musculi interossei dorsales)*

4 **Lumbricals** *(musculi lumbricales)*
- 4.1 **Lumbricals** *(musculi lumbricales)*

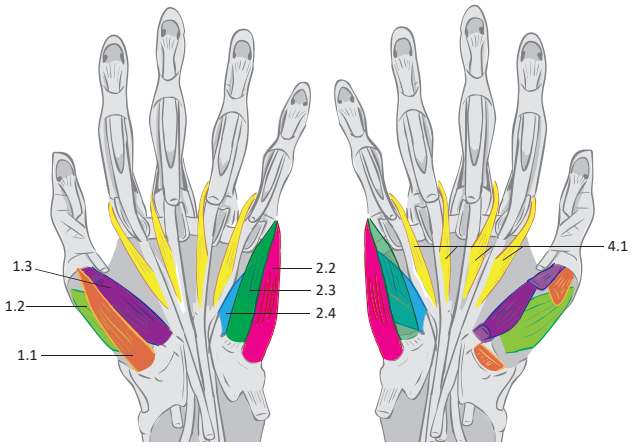

Anterior view of the left and right hands

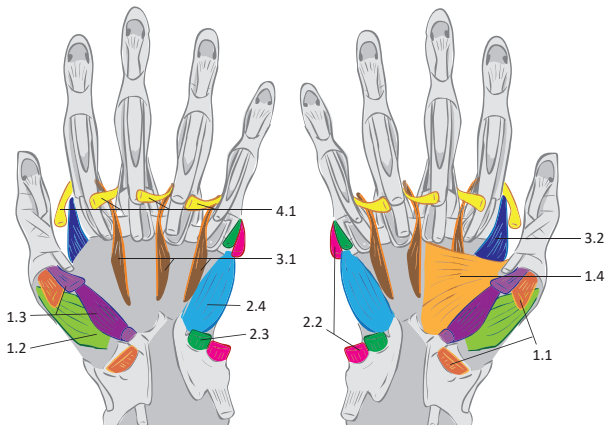

Anterior view of the left and right hands

The order of the thenar and hypothenar muscles (excluding the palmaris brevis) going from lateral to medial and superficial to deep can be remembered by the following mnemonic: :
PAFO And **MAFO**
P – Pollex (thumb)
A – Abductor pollicis brevis
F – Flexor pollicis brevis
O – Opponens pollicis
A – Adductor pollicis
M – Digitus Minimus (little finger)
A – Abductor digiti minimi
F – Flexor digiti minimi
O – Opponens digiti minimi

The opponens pollicis and adductor pollicis can be overloaded during activities such as gardening, writing and sewing. Load-relieving exercises such as shaking the arms, forearms and wrists with relaxed fingers should be performed regularly to prevent injury to these muscles.

Clinical notes

Trigger points in the adductor pollicis and opponens pollicis make the pincer grasp impossible due to intense pain. In the differential diagnosis, we distinguish disability of these two muscles from the carpal tunnel syndrome.

Hypertonus in the adductor pollicis often occurs with the spasmodic type of grasping or holding of a burden (e.g. texting on a mobile phone).

Overload of the adductor pollicis is probably related with the nodes of Heberden in the interphalangeal joint of the thumb.

The thenar group consists of **four muscles** that provide **movements of the thumb**. **The flexor pollicis brevis and adductor pollicis** have **two heads**. The thenar muscles are innervated by both the **median nerve** and the **ulnar nerve**. The borderline between the domains of these nerves is formed by the tendon of the flexor pollicis longus.

Abductor pollicis brevis *(musculus abductor pollicis brevis)*

O: radial carpal eminence,
flexor retinaculum
I: base of the proximal phalanx of the thumb (lateral side),
lateral sesamoid bone of the thumb
F: abduction of the thumb
N: median nerve (C6–C7)

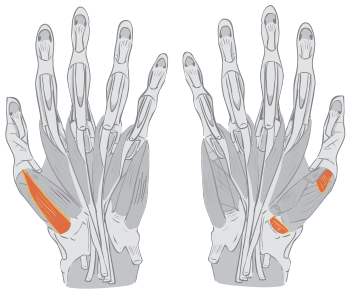

Anterior view of the left and right hands

Opponens pollicis *(musculus opponens pollicis)*

O: radial carpal eminence,
flexor retinaculum
I: 1st metacarpal – opponens crest
F: opposition and flexion of the thumb
at the carpometacarpal joint
N: median nerve (C6–C7)

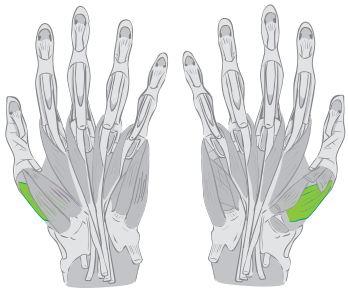

Anterior view of the left and right hands

Flexor pollicis brevis *(musculus flexor pollicis brevis)*

Origin:
- 1 **Superficial head** *(caput superficiale)*:
  radial carpal eminence,
  flexor retinaculum
- 2 **Deep head** *(caput profundum)*:
  trapezoid,
  capitate,
  palmar intercarpal ligaments

I: base of the proximal phalanx of the thumb (lateral side),
lateral sesamoid bone of the thumb
F: flexion of the thumb at the carpometacarpal
and metacarpophalangeal joints
Innervation:
1 **Superficial head** *(caput superficiale)*: median nerve (C6–C7)
2 **Deep head** *(caput profundum)*: ulnar nerve (C6–C7)

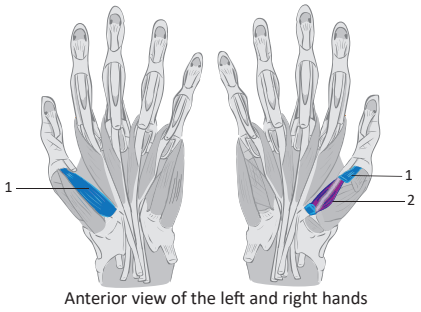

Anterior view of the left and right hands

Adductor pollicis *(musculus adductor pollicis)*

Origin:
- 1 **Oblique head** *(caput obliquum)*:
  capitate,
  trapezoid,
  base of the 2nd and 3rd metacarpal (anterior surface)
- 2 **Transverse head** *(caput transversum)*:
  3rd metacarpal (anterior surface)

I: base of the proximal phalanx of the thumb (medial side),
medial sesamoid bone of the thumb
F: adduction of the thumb
N: ulnar nerve (C6–C7)

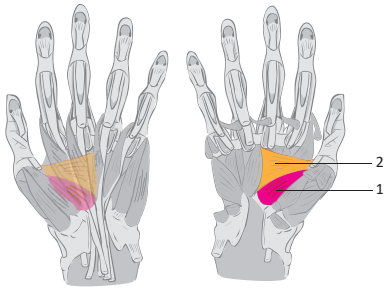

Anterior view of the left and right hands

This copy belongs to ali yaghoubi

The hypothenar muscles are a group of **four muscles**. Three of them (abductor digiti minimi, flexor digiti minimi brevis and opponens digiti minimi) provide **movements of the little finger**. The palmaris brevis is a rudimentary cutaneous muscle. All of the hypothenar muscles are innervated by the **ulnar nerve**.

Palmaris brevis *(musculus palmaris brevis)*

O: palmar aponeurosis (medial margin)
I: skin of the hypothenar eminence
F: pulls the skin of the hypothenar eminence
N: ulnar nerve (C8–T1)

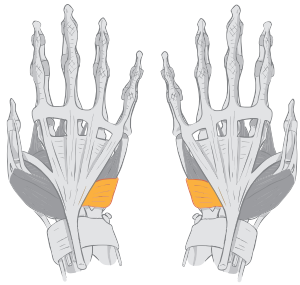

Anterior view of the left and right hands

Abductor digiti minimi *(musculus abductor digiti minimi)*

O: pisiform
I: base of the proximal phalanx of the little finger (ulnar side)
F: abduction of the little finger
N: ulnar nerve (C8–T1)

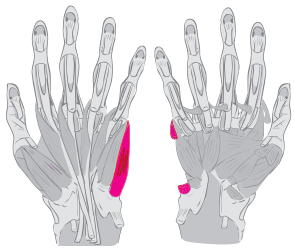

Anterior view of the left and right hands

Flexor digiti minimi brevis *(musculus flexor digiti minimi brevis)*

O: hook of hamate, flexor retinaculum
I: base of the proximal phalanx of the little finger (medial side)
F: flexion of the little finger at the metacarpophalangeal joint
N: ulnar nerve (C8–T1)

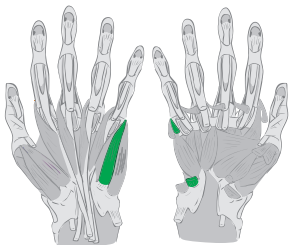

Anterior view of the left and right hands

Opponens digiti minimi *(musculus opponens digiti minimi)*

O: hook of hamate, flexor retinaculum
I: 5th metacarpal – medial margin and anterior surface
F: adduction and flexion of the little finger at the metacarpophalangeal joint
N: ulnar nerve (C8–T1)

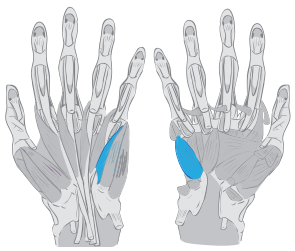

Anterior view of the left and right hands

Contemporary occupations lead more commonly to hypotonicity of the hypothenar muscles than of the thenar muscles.

The palmar and dorsal interossei and lumbricals generate the main force for extension of the middle and distal phalanges. The extensor digitorum performs especially extension of the proximal phallanx, however, it only has a weak effect on the other two phalanges. Extension of all phalanges is possible due to a common contraction of all these muscles.

The interossei and lumbricals are stretched by interweaving of both hands, fingers and pushing them against each other in front of the sternum.

The palmaris brevis is a cutaneous muscle and its innervation comes from the cutaneous branch (superficial branch of ulnar nerve).

Through the heads of the first dorsal interosseus the radial artery and veins pass to the palm.

Clinical notes

Interossei overload leads to interphalangeal joints arthrosis. And vice versa, interphalangeal joints arthrosis leads to the muscle overload.

Flexion and extension of the dorsal interossei need far less force than abduction and adduction. When these muscles are impaired, lateral movements are limited at first.

Projection of pain from the palmar or dorsal interosseus is located on the homolateral side of the finger where the muscle insertion is situated.

Pain from a trigger point in the first dorsal interosseus is located in the palm.

The palmar interossei are three muscles in the 2nd, 4th and 5th interosseous space in between the metacarpals. **The dorsal interossei** are four muscles in the 1st–4th interosseous space in between the metacarpals. Their function is adduction from (palmar interossei) and abduction from (dorsal interossei) a virtual axis that runs through the center of the 3rd finger. **The lumbricals** are four short muscles that originate on the tendons of the flexor digitorum profundus and insert on the 2nd–5th finger. The common function of the lumbricals is **flexion in the metacarpophalangeal joints** and **extension in the interphalangeal joints**.

Palmar interossei *(musculi interossei palmares)*

– the palmar interossei (PI) are three muscles located in the 2nd–4th interosseous spaces between the metacarpals
O: 2nd metacarpal – medial side (1st PI)
4th metacarpal – lateral side (2nd PI)
5th metacarpal – lateral side (3rd PI)
I: dorsal aponeurosis and base of proximal phalanges on the sides facing the 3rd digit
2nd digit, proximal phalanx – medial side (1st PI)
4th digit, proximal phalanx – lateral side (2nd PI)
5th digit, proximal phalanx – lateral side (3rd PI)
F: flexion of the fingers at the metacarpophalangeal joints, extension of the phalanges at the interphalangeal joints (by pulling the dorsal aponeurosis), duction of the fingers at the metacarpophalangeal joints to an axis that runs through the centre of the 3rd finger
N: ulnar nerve (C8–T1)

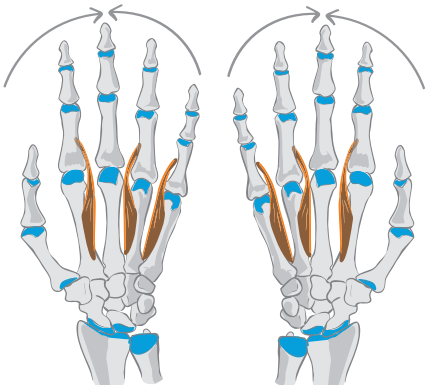

Anterior view of the left and right hands

Dorsal interossei *(musculi interossei dorsales)*

– the dorsal interossei (DI) are four muscles located in the 1st–4th interosseous spaces between the metacarpals
O: as two heads on adjacent metacarpals which meet in the interosseous space, resembling the shape of a tree
I: the dorsal aponeurosis of the digits 2–5 both sides of the proximal phalanx of the 3rd digit and on the sides facing away from the 3rd digit of the proximal phalanges of the 2nd and 4th digit
2nd digit, proximal phalanx – lateral side (1st DI),
3rd digit, proximal phalanx – lateral side (2nd DI) and medial side (3rd DI)
4th digit, proximal phalanx – medial side (4th DI)
F: flexion of the digits at the metacarpophalangeal joints, extension of the phalanges at the interphalangeal joints (by pulling the dorsal aponeurosis), duction of the fingers at metacarpophalangeal joints towards an axis that runs through the centre of the 3rd digit)
N: ulnar nerve (C8–T1)

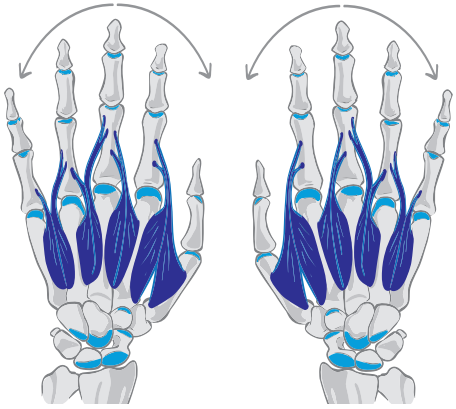

Posterior view of the left and right hands

Lumbricals *(musculi lumbricales)*

– four muscles corresponding to the 2nd–5th digits
O: on the tendons of the flexor digitorum profundus of the 2nd–5th finger
I: dorsal aponeuroses of the 2nd–5th digits, base of the proximal phalanges of the 2nd–5th finger (laterally)
F: flexion of the digits at the metacarpophalangeal joints, extension of the phalanges at the interphalangeal joints (by pulling the dorsal aponeurosis), radial duction of the fingers at the metacarpophalangeal joints (towards the thumb)
Innervation:
Lumbrical I and II: median nerve (C8–T1)
Lumbrical III and IV: ulnar nerve (C8–T1)

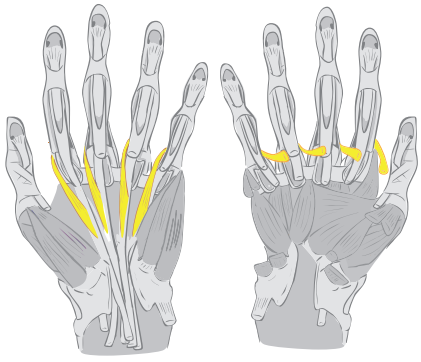

Anterior view of the left and right hands

This copy belongs to ali yaghoubi

Tendinous sheaths are filled with viscous fluid. **They coat tendons in places of high vulnerability during movement**, especially when tendons pass under the the flexor and extensor retinacula and on the fingers. Tendinous sheaths make **smooth sliding movements of tendons** possible.

Palmar tendinous sheaths

- 1 **Tendinous sheath of flexor carpi radialis**
  (vagina tendinis musculi flexoris carpi radialis)
- 2 **Tendinous sheath of flexor pollicis longus**
  (vagina tendinis musculi flexoris pollicis longi)
- 3 **Common flexor sheath**
  (vagina communis tendinum musculorum flexorum)
  – the common sheath for the flexor digitorum superficialis and flexor digitorum profundus
  – usually continues as the tendinous sheath of the little finger
  3.1 **Middle carpal sac** *(saccus carpi medius)*
  – the widened part of the common flexor sheath
- 4 **Synovial sheaths of digits of hand**
  (vaginae synoviales digitorum manus)
  – individual sheaths for the 2nd, 3rd and 4th fingers

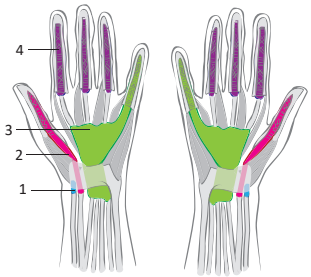

Anterior view of the left and right hands

Dorsal tendinous sheaths

- 1 **Tendinous sheath of abductor pollicis longus and extensor pollicis brevis**
  (vagina tendinum musculorum abductoris pollicis longi et extensoris pollicis brevis)
- 2 **Tendinous sheath of extensores carpi radiales**
  (vagina communis tendinum musculorum extensorum carpi radialium)
- 3 **Tendinous sheath of extensor pollicis longus**
  (vagina tendinis musculi extensoris pollicis longi)
- 4 **Tendinous sheath of extensor digitorum and extensor indicis**
  (vagina tendinum musculorum extensoris digitorum et extensoris indicis)
- 5 **Tendinous sheath of extensor digiti minimi**
  (vagina tendinis musculi extensoris digiti minimi)
- 6 **Tendinous sheath of extensor carpi ulnaris**
  (vagina tendinis musculi extensoris carpi ulnaris)

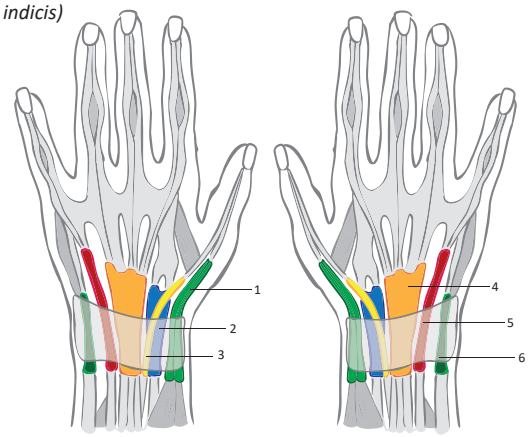

Posterior view of the left and right hands

Tendinous sheaths of the fingers

- 1 **Fibrous sheaths of digits of hand**
  (vaginae fibrosae digitorum manus)
  – osteofibrous canals of firm fibrous tissue coating the synovial sheaths of the tendons of the fingers
  – connected to the palmar fibrocartilage of the metacarpophalangeal and interphalangeal joints
  1.1 **Vincula tendinum**
  – fibrous connections inside the tendinous sheaths between the flexor digitorum superficialis and flexor digitorum profundus
  – provide nutrition to the tendons

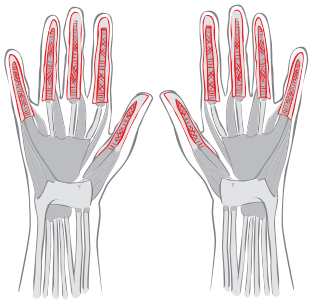

The anterior compartment of the forearm is divided into a superficial and deep part by a fibrous septum between the second and third layer of the ventral group of the forearm muscles. The median nerve runs through this septum.

The intertubercular tendon sheath *(vagina tendinis intertubercularis)* is a sheath for the long head of the biceps brachii. It arises from the shoulder joint capsule – see page 77.

Fibrous digital sheaths *(vaginae fibrosae digitorum manus)* are surrounded by a system of circular fibrous bands which prevent from the bowstring effect during flexion. The bands are ring-shaped (*pars anularis*; A1 – A5) and crossed (*pars cruciformis*; C1 – C3). They are attached to the middle and distal phalanges and to the interphalangeal joint capsules. The fingers have eight and the thumb has five bands.

The palmar aponeurosis is a significant protecting layer of the neurovascular bundle of the palm.

Vincula tendinum are always in pair in each tendon sheath. Vinculum breve is triangular and is located at the tendon insertion. Vinculum longum has a longer threadlike appearance (adaptation for tendon movement during contraction). It is located proximally to the vinculum breve on the same tendon.

Clinical notes

Tendosynovitis is inflammation inside the tendon sheath associated with pain, swelling and movement limitation. The condition can be caused by muscle overload.

Trigger finger *(digitus saltans)* is a finger disorder caused by swelling of the flexor tendons at the first circular fibrous band (pars anularis A1). A high amount of force is needed to "thread" the swollen tendon through the narrow bands. Treatment is surgical and based on cutting through the bands.

Contracture of Dupuytren is a pathological shortening of the palmar aponeurosis, which forms thick bands and limits the extent of extension of the fingers. It is a relapsing chronic disease that most typically occurs in men and alcohol consumers. The treatment options range from cutting through the bands to excision of the whole aponeurosis.

The fasciae of the upper limb form individual compartments (muscle groups) of the upper limb. The thickened distal parts of the fasciae of the forearm form **the flexor and extensor retinacula**.

- 1 **Axillary fascia** *(fascia axillaris)* – covers the axilla
  - – is perforated by sensory nerves and lymphatic vessels of the axilla
  - 1.1 **Suspensory ligament of axilla** *(ligamentum suspensorium axillae)*
    - – the continuation of the clavipectoral fascia to the axillary fascia
- 2 **Deltoid fascia** *(fascia deltoidea)* – covers the deltoid
- 3 **Brachial fascia** *(fascia brachii)* – covers the muscles of the arm
  - – is attached to the medial and lateral epicondyles of the humerus
  - 3.1 **Medial and lateral intermuscular septa of arm** *(septum intermusculare brachii mediale et laterale)*
    - – osteofascial septa between the muscles of the anterior and posterior group
    - – form two brachial compartments (osteofascial spaces): anterior and posterior
    - – form two skin grooves: medial and lateral bicipital grooves
- 4 **Antebrachial fascia** *(fascia antebrachii)*
  - – continues from the brachial fascia, attaches to the periosteum of the dorsal border of the ulna
  - 4.1 **Interosseous membrane of forearm** *(membrana interossea brachii)*
    - – separates the anterior compartment of the forearm from the posterior compartment
  - 4.2 **Anterior intermuscular septum of forearm** *(septum intermusculare antebrachii anterius)*
    - – separates the anterior compartment of the forearm from the lateral compartment
  - 4.3 **Posterior intermuscular septum of forearm** *(septum intermusculare antebrachii posterius)* – separates the posterior compartment of the forearm from the lateral compartment
- 5 **Flexor retinaculum** *(retinaculum musculorum flexorum)*
  - – a transverse band of thickened antebrachial fascia, located ventrally on the wrist
  - – ventrally borders the carpal canal
  - – fuses with the palmar carpal ligament
- 6 **Extensor retinaculum** *(retinaculum musculorum extensorum)*
  - – a transverse band of thickened antebrachial fascia, located dorsally on the wrist
- 7 **Fasciae of hand** *(fasciae manus)*
  - – reach the metacarpophalangeal joints
  - – do not continue to the fingers
  - 7.1 **Superficial dorsal fascia of hand** *(fascia dorsalis manus superficialis)*
  - 7.2 **Intertendinous dorsal fascia of hand** *(fascia dorsalis manus intertendinea)*
    - – connects the tendons on the dorsum of the hand
  - 7.3 **Interosseous dorsal fascia of hand** *(fascia dorsalis manus interossea)*
    - – covers the interossei muscles from the dorsal side
  - 7.4 **Superficial palmar fascia** *(fascia palmaris superficialis)*
    - – covers the muscles of both the thenar and hypothenar eminences and fuses with the palmar aponeurosis
    - – is separated from the interosseous palmar fascia by three compartments and is connected with it by two septa (thenar and hypothenar septa)
  - 7.5 **Interosseous palmar fascia** *(fascia palmaris interossea)*
    - – covers the interossei muscles from the ventral aspect
- 8 **Palmar aponeurosis** *(aponeurosis palmaris)*
  - – a fibrous triangle covering the palm
  - – fuses with the superficial palmar fascia
  - – disappears in bands on the fingers
- 9 **Superficial transverse metacarpal ligament** *(ligamentum metacarpale transversum superficiale)*
  - – the most distal transverse band of the palmar aponeurosis

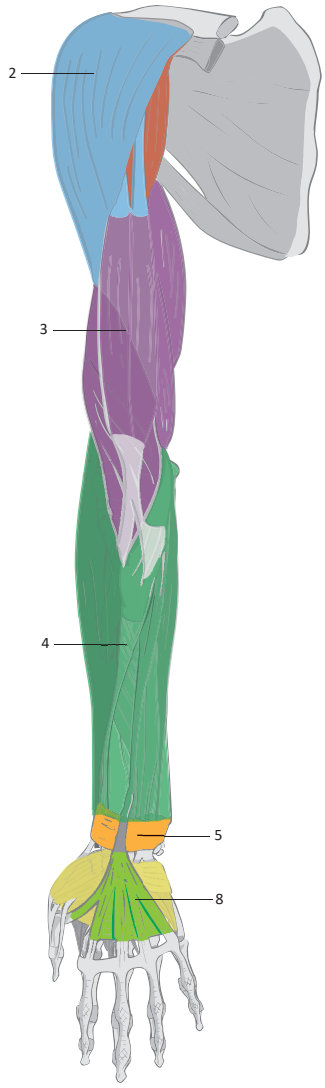

Anterior view of the right upper limb

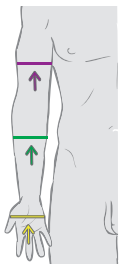

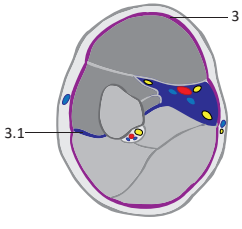

Transverse section of the arm

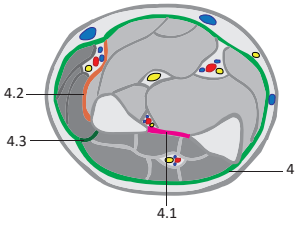

Transverse section of the forearm

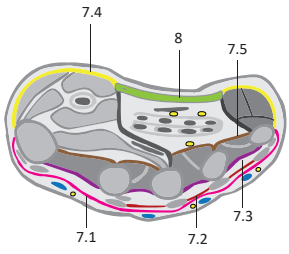

Transverse section of the hand

This copy belongs to ali yaghoubi

The muscles of the lower limb can be divided into **four groups,** according to their location: **the muscles of hip joint, the muscles of thigh, the muscles of leg and the muscles of foot**. The muscles of the lower limb enable **standing and walking**.

9.1 Muscles of the hip joint

The muscles of the hip joint can be divided into two groups: **anterior and posterior**. The posterior group is further divided into two layers: **superficial layer and deep or pelvitrochanteric layer**.

1 **Anterior group**
- 1.1 **Iliopsoas** *(musculus iliopsoas)*

2 **Posterior group**

Superficial layer
- 2.1 **Gluteus maximus** *(musculus gluteus maximus)*
- 2.2 **Gluteus medius** *(musculus gluteus medius)*
- 2.3 **Gluteus minimus** *(musculus gluteus minimus)*
- 2.4 **Tensor fasciae latae / tensor of fascia lata** *(musculus tensor fasciae latae)*

Deep layer – pelvitrochanteric muscles
- 2.5 **Piriformis** *(musculus piriformis)*
- 2.6 **Gemellus superior / superior gemellus** *(musculus gemellus superior)*
- 2.7 **Obturator internus** *(musculus obturatorius internus)*
- 2.8 **Gemellus inferior / inferior gemellus** *(musculus gemellus inferior)*
- 2.9 **Quadratus femoris** *(musculus quadratus femoris)*

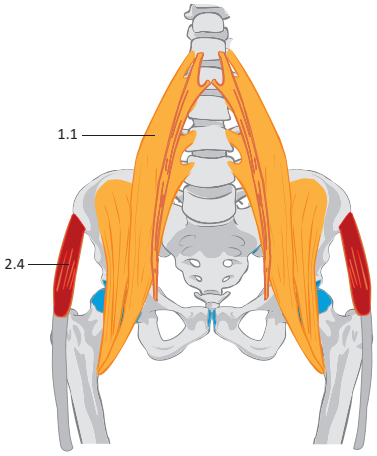

Anterior view

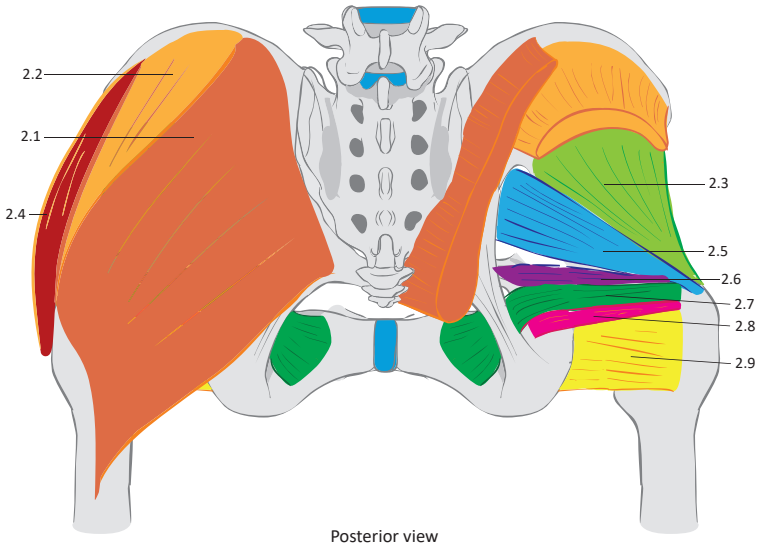

Posterior view

The iliopsoas is necessary for walking. The muscle also fixes the supporting limb. In a standing position the muscle prevents the torso from falling backwards and increases the lumbar lordosis. Permanent asymmetry can cause deviation of the vertebral column.

The psoas minor is a variable muscle which is bilaterally present in 40–50 % of the population.

Clinical notes

If a patient wants to indicate the location of pain caused by a trigger point in the iliopsoas, he will move his hand alongside the vertebral column in the vertical direction from the level of the vertebra T11 to the sacrum. Contrarily, if the patient moves his hand in the horizontal direction, it is probably the result of trigger points in the rectus abdominis.

The iliopsoas courses very close to the internal organs. Thus pathology of the iliopsoas may mimic a disease in the internal organs. When the right iliopsoas is injured, pain is felt in the right lower quadrant which can mimic appendicitis. Hypertrophy of the iliopsoas can make passage through the colon difficult.

Hypertrophy of the iliopsoas can compress the femoral nerve and lateral cutaneous nerve of the thigh at the muscular space *(lacuna musculorum)* and the genitofemoral nerve at the vascular space *(lacuna vasculorum)* under the inguinal ligament.

The anterior group of muscles of the hip joint consists of one muscle: **iliopsoas**. The iliopsoas consists of two parts: **iliacus and psoas major**. Both parts fuse when passing through **the muscular space under the inguinal ligament** and they **insert on the femur**. Occasionally, a third part, the psoas minor, is present. It originates with the psoas major on the lumbar vertebral column.

Iliopsoas *(musculus iliopsoas)*

Origin:
- 1 **Iliacus** *(musculus iliacus):*
  ilium – iliac fossa
- 2 **Psoas major** *(musculus psoas major)*:
  vertebral bodies of T12–L5,
  intervertebral discs (as 5 digitations),
  vertebrae L1–L5 – costal processes
- 3 **Psoas minor** *(musculus psoas minor)*
  – vertebral bodies of T12 and L1 and
  the intervertebral discs between them

Insertion:
1,2 **Iliacus and psoas major:**
femur – lesser trochanter
3 **Psoas minor:**
iliopubic ramus

Function:
1,2 **Iliacus and psoas major:**
flexion and external rotation of the thigh
2,3 **Psoas major and psoas minor:**
ventral flexion of the lumbar vertebral column
2 **Psoas major:**
lateroflexion of the trunk to the side of the contracted muscle and rotation to the opposite side (unilateral contraction)

Innervation (T12–L4): femoral nerve (iliacus),
lumbar plexus – branches of the spinal nerves L1–L3
(psoas major and psoas minor)

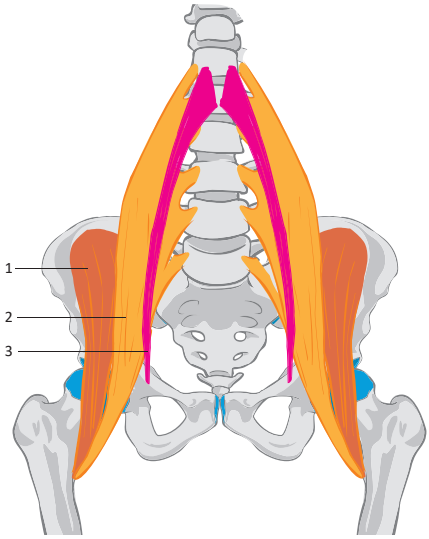

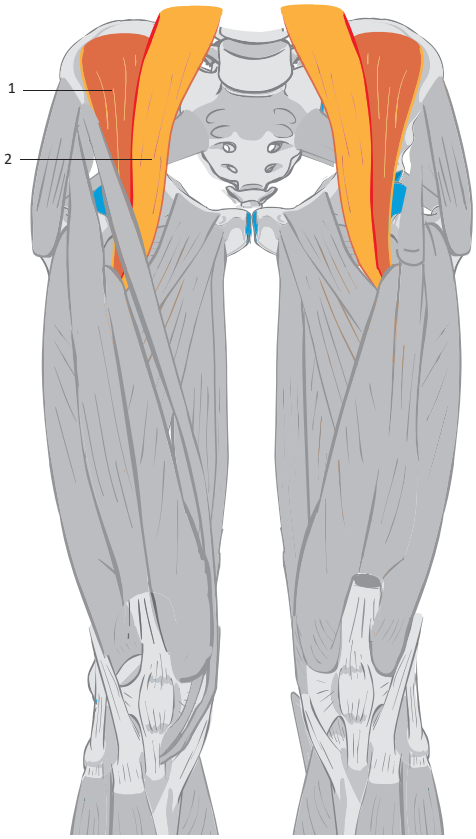

This copy belongs to ali yaghoubi

The superficial layer of the posterior group of muscles of the hip joint consists of **the gluteal muscles** and **the tensor fasciae latae**. These muscles facilitate **standing up from a sitting position and climbing stairs**, **keep the pelvis in retroversion** and **prevent the hip from deviating to one side**.

Gluteus maximus *(musculus gluteus maximus)*

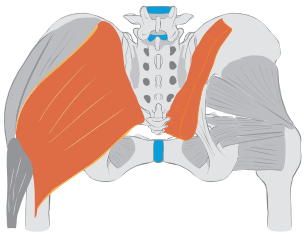

O: gluteal surface of the ilium – dorsal to the posterior gluteal line,
iliac crest – outer lip,
thoracolumbar fascia – posterior layer,
sacrum,
coccyx,
sacrotuberous ligament,
gluteal aponeurosis
I: femur – gluteal tuberosity,
tibia – lateral condyle (via the iliotibial tract)
F: abduction of the thigh (cranial fibers),
extension, external rotation and adduction of the thigh (caudal fibers),
maintains extension of the knee joint (by stretching the iliotibial tract),
keeps the pelvis in retroversion,
maintains the erect standing position
and provides lateral stability to the trunk (most important function)
N: inferior gluteal nerve (L5–S1, variably L4–S2)

Gluteus medius *(musculus gluteus medius)*

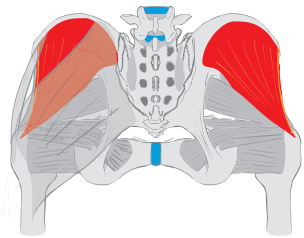

O: gluteal surface of the ilium – between the posterior and anterior gluteal lines,
iliac crest – outer lip
I: femur – greater trochanter
F: abduction of the thigh and tilting of the pelvis (middle fibers),
flexion and internal rotation of the thigh (anterior fibers),
extension and external rotation of the thigh (posterior fibers)
N: superior gluteal nerve (L4–S1)

Gluteus minimus *(musculus gluteus minimus)*

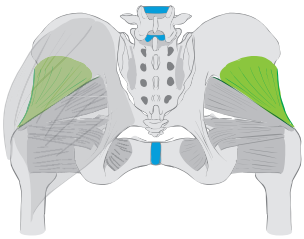

O: gluteal surface of the ilium – between the anterior and inferior gluteal lines,
iliac crest – outer lip
I: femur – greater trochanter
F: abduction of the thigh and tilting of the pelvis (middle fibers),
flexion and internal rotation of the thigh (anterior fibers),
extension and external rotation of the thigh (posterior fibers)
N: superior gluteal nerve (L4–S1)

Tensor fasciae latae / tensor of fascia lata *(musculus tensor fasciae latae)*

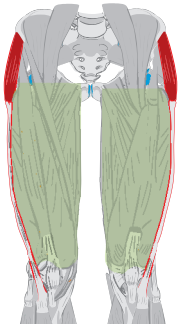

O: ilium – anterior superior iliac spine
I: tibia – tuberosity for the iliotibial (on the lateral condyle) tract of Gerdy (via the iliotibial tract)
F: extension of the knee joint (“locking of the knee joint”),
abduction, flexion and internal rotation of the thigh,
stabilisation of both knee joints and the hip joint during walking
N: superior gluteal nerve (L4–S1)

Muscles

The gluteus maximus is one of the biggest muscles in the human body. The muscle has role in maintaining an upright posutre. In the stance phase of the gait, the muscle prevents flexion at the hip joint.

Sleeping on the side, in the long term, can cause excessive stretching of the gluteus medius. Putting a pillow between the thighs is a suitable prevention. This is especially important for women with a wide pelvis.

The iliotibial tract is a reinforcement of the fascia lata on the lateral side.

The piriformis divides the greater sciatic foramen into the suprapiriform foramen and the infrapiriform foramen (see page 579).

The triceps coxae is an obsolete term for the superior gemellus, obturator internus and inferior gemellus, which insert via a common tendon on a small facet on the greater trochanter of the femur, located above the trochanteric fossa.

The gluteal aponeurosis *(aponeurosis glutea)* is a thick fibrous membrane, located in the superior gluteal region between the iliac crest and the superolateral border of the gluteus maximus. It is part of the gluteal fascia and forms part of the origin of the gluteus maximus and medius.

Clinical notes

Trigger points in muscles of the pelvic girdle never cause referred pain distal to the knee joint. Muscles of the pectoral girdle, however, often cause pain distal to the elbow joint.

Walking uphill, upstairs or jumping is not possible when the gluteus maximus is injured.

The piriformis has a tendency to become hypertonic and the gluteus maximus has a tendncy to become hypotonic. As a result, internal rotation of the thigh is limited and the muscles are painful on palpation.

The piriformis may cause entrapment syndromes of all the blood vessels and nerves passing through the suprapiriform and infrapiriform foramina. The piriformis may cause symptoms of sciatica, a condition known as the piriformis syndrome. The piriformis syndrome is also referred to as “wallet sciatica” or “fat wallet syndrome”, since this condition can be caused or aggravated by sitting with a large wallet in the back pocket on the affected side.

The muscles of the deep layer are called **the pelvitrochanteric muscles**. They are short muscles with **insertions around the greater trochanter**. They maintain **stability of the hip joint** and have important **postural functions**.

Piriformis *(musculus piriformis)*

O: sacrum (S2–S4) – pelvic surface
I: femur – greater trochanter
F: external rotation of the extended thigh,
abduction of the flexed thigh
N: nerve to the piriformis
and direct branches from the sacral plexus (L4–S2)

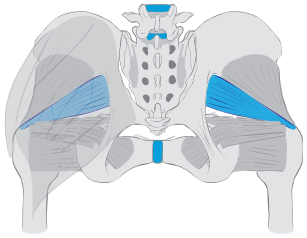

Gemellus superior / superior gemellus *(musculus gemellus superior)*

O: ischial spine
I: femur – greater trochanter
(on a small facet above the trochanteric fossa)
F: external rotation of the extended thigh,
abduction of the flexed thigh
N: nerve to the obturator internus
and direct branches from the sacral plexus (L4–S2)

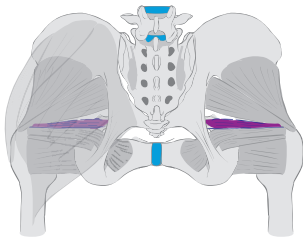

Obturator internus *(musculus obturatorius internus)*

O: internal surface of the obturator membrane,
hip bone – obturator foramen (bony margins)
Course of fibres: passes through the lesser sciatic foramen
I: femur – greater trochanter
(small facet above the trochanteric fossa)
F: external rotation of the extended thigh,
abduction of the flexed thigh
N: nerve to the obturator internus
and direct branches from the sacral plexus (L4–S2)

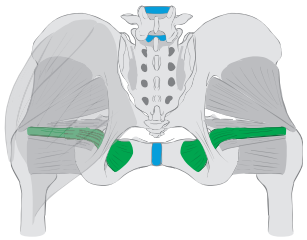

Gemellus inferior / inferior gemellus *(musculus gemellus inferior)*

O: ischial tuberosity
I: femur – greater trochanter
(on a small facet above the trochanteric fossa)
F: external rotation of the extended thigh,
abduction of the flexed thigh
N: nerve to the quadratus femoris
and direct branches from the sacral plexus (L4–S2)

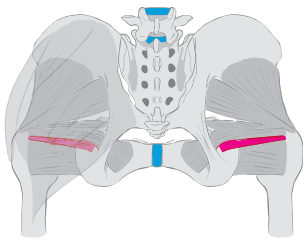

Quadratus femoris *(musculus quadratus femoris)*

O: ischial tuberosity
I: femur – intertrochanteric crest
(including the quadrate tubercle)
F: external rotation of the thigh
N: nerve to the quadratus femoris
and direct branches from the sacral plexus (L4–S2)

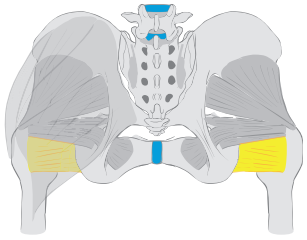

This copy belongs to ali yaghoubi

The muscles of the thigh are organised into **three groups**: anterior, medial and lateral groups. **The quadriceps femoris** forms the anterior group and is the **only extensor of the leg**.

1 **Anterior group**
- 1.1 **Sartorius** *(musculus sartorius)*
- 1.2 **Quadriceps femoris** *(musculus quadriceps femoris)*

2 **Medial group**
- 2.1 **Pectineus** *(musculus pectineus)*
- 2.2 **Adductor longus** *(musculus adductor longus)*
- 2.3 **Gracilis** *(musculus gracilis)*
- 2.4 **Adductor brevis** *(musculus adductor brevis)*
- 2.5 **Adductor magnus** *(musculus adductor magnus)*
- 2.6 **Obturator externus** *(musculus obturatorius externus)*

3 **Posterior group**
- 3.1 **Biceps femoris** *(musculus biceps femoris)*
- 3.2 **Semitendinosus** *(musculus semitendinosus)*
- 3.3 **Semimembranosus** *(musculus semimembranosus)*

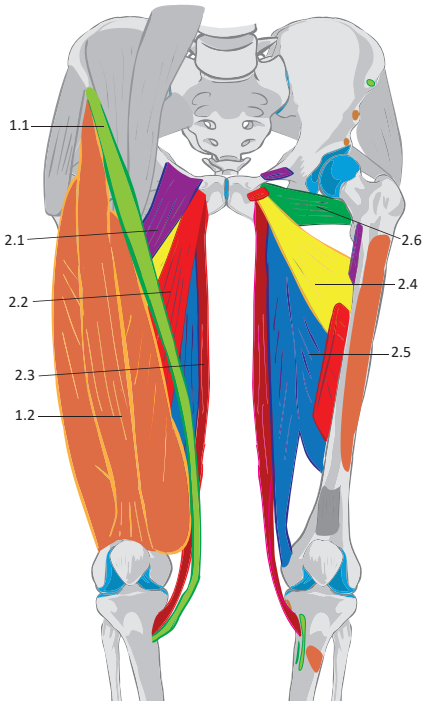

Anterior view of the right and left thighs

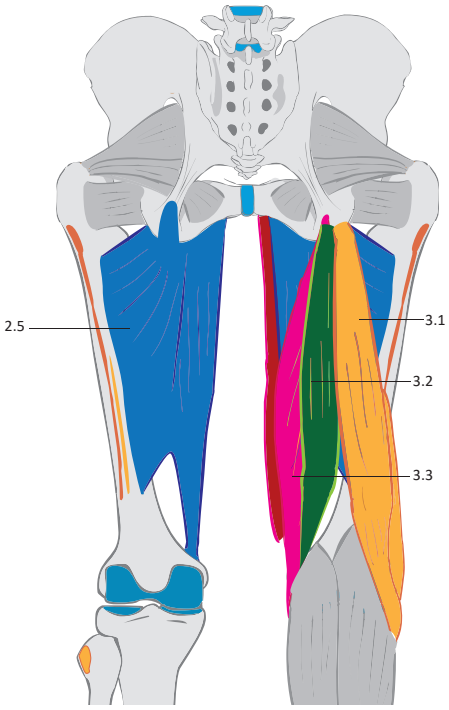

Posterior view of the right and left thighs

The articularis genus is a deep, cleaved portion of the vastus intermedius. The muscle tightens capsule of the knee joint.

The adductor minimus is a latero-proximal part of the adductor magnus. The passage of the first perforating artery (branch of the deep femoral artery) separates these two muscles. Its fibres cross the fibres of the adductor magnus.

Clinical notes

The sartorius can compress the lateral cutaneous nerve of the thigh below the anterior superior iliac spine.

Pain in the sartorius is usually not located as deeply as pain in most muscles. It is described as a sharp or tingling pain.

Trigger points in any part of the quadriceps femoris can cause a displacement in the position of the patella.

Pain in the ventral part of the knee can be caused by a variety of disorders or an imbalance in the rectus femoris or vastus medialis.

Presence of even a small amout of fluid (less than 10 ml is enough) in the cavity of the knee joint significantly weakens the vastus medialis. 20 ml of the fluid significantly weakens the vastus lateralis.

The anterior group of the thigh muscles covers the entire anterior surface of the thigh and have a common innervation from the **femoral nerve**. **The quadriceps femoris** is comprised of **four heads**: rectus femoris, vastus lateralis, vastus intermedius and vastus medialis. **The rectus femoris** can be further divided into two heads: **straight head and reflected head**. The rectus femoris is the only head of the quariceps femoris that acts not only at **the knee joint**, but also at **the hip joint**.

Sartorius *(musculus sartorius)*

O: ilium – anterior superior iliac spine
I: tibia – medial condyle
(via the pes anserinus major)
F: flexion, abduction and external rotation of the thigh,
flexion of the leg,
internal rotation of the flexed leg
N: femoral nerve (L2–L3)

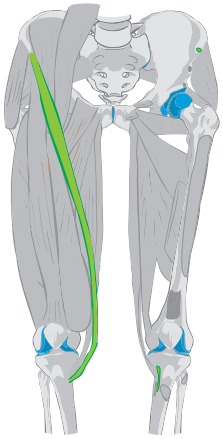

Quadriceps femoris *(musculus quadriceps femoris)*

Origin:
- 1 **Rectus femoris** *(musculus rectus femoris)*:
  - 1.1 **Straight head** *(caput rectum)*:
    ilium – anterior inferior iliac spine
  - 1.2 **Reflected head** *(caput reflexum)*:
    ilium – supra-acetabular groove
- 2 **Vastus lateralis** *(musculus vastus lateralis)*:
  femur – linea aspera (proximal half of the lateral lip),
  femur – intertrochanteric line (proximal part)
- 3 **Vastus intermedius** *(musculus vastus intermedius)*:
  femur – anterior and lateral surfaces
- 4 **Vastus medialis** *(musculus vastus medialis)*:
  femur – linea aspera (medial lip),
  femur – intertrochanteric line (distal part)

I: tibial tuberosity – via the patellar ligament
F: extension of the leg,
control of flexion of the leg
(the muscle often works in a state
of eccentric contraction),
flexion of the thigh (rectus femoris only)
N: femoral nerve (L2–L4)

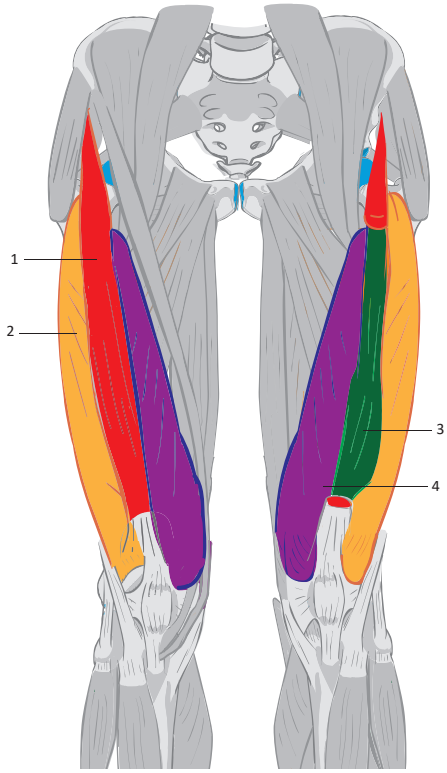

This copy belongs to ali yaghoubi

The muscles in the medial group are **adductors**. The common innervation of the medial group is from the **obturator nerve**. However, two diploneural muscles belong to this group: the pectineus and adductor magnus. The adductor magnus can be divided into two unnamed parts (adductor part and extensor part), each with its own innervation.

Pectineus *(musculus pectineus)*

O: pubis – pecten pubis
I: femur – pectineal line
F: adduction, flexion and external rotation of the thigh
N: femoral nerve (L2–L3),
obturator nerve (L2–L3)

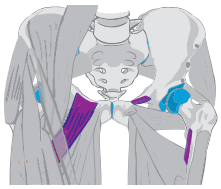

Adductor longus *(musculus adductor longus)*

O: pubis – in between the pubic tubercle and pubic symphysis
I: femur – linea aspera (middle 1/3 of the medial lip)
F: adduction, flexion and external rotation of the thigh
N: obturator nerve (L2–L3)

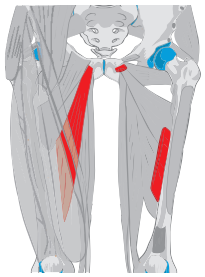

Gracilis *(musculus gracilis)*

O: pubis – body and inferior pubic ramus
I: tibia – medial condyle
(via the pes anserinus major)
F: adduction of the thigh,
flexion of the leg,
internal rotation of the flexed leg
N: obturator nerve (L2–L4)

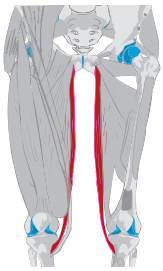

Adductor brevis *(musculus adductor brevis)*

O: pubis – inferior pubic ramus
I: femur – linea aspera
(proximal 1/3 of the medial lip)
F: adduction, flexion and external rotation of the thigh
N: obturator nerve (L2–L4)

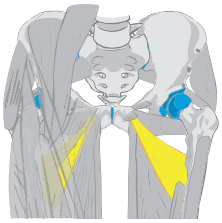

Adductor magnus *(musculus adductor magnus)*

- 1 **Adductor part**
  - **O:** pubis – inferior pubic ramus
  - **I:** femur – linea aspera (medial lip)
  - **F:** adduction and flexion of the thigh
  - **N:** obturator nerve (L2–L4)
- 2 **Extensor part**
  - **O:** ischium – ramus and ischial tuberosity
  - **I:** femur (medial condyle) – adductor tubercle
  - **F:** extension and internal rotation of the thigh
  - **N:** sciatic nerve (L2–L4), obturator nerve (L2–L4)

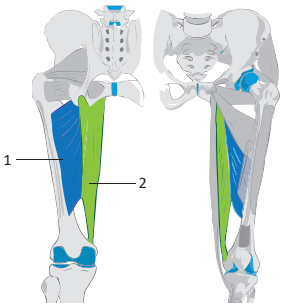

Left thigh, posterior and anterior view

The major pes anserinus („goose foot", *pes anserinus major*) is the insertion of the conjoined tendons of the sartorius, gracilis and semitendinosus on the medial condyle of the tibia.

The deep pes anserinus (*pes anserinus profundus*) consists of three insertions of the semimebranosus. Two insertions are on the medial condyle of the tibia and the third attaches to the lateral condyle of the femur via the oblique popliteal ligament.

Adductor overload may occur in women from sexual intercourse by pressing their partners tightly with their thighs. Treatment involves changing the position of sexual intercourse or a combined program of relaxing and fitness exercises for the adductors. Hypertonic adductors significantly limit the range of movements of abduction, often less than half that of physiological range, however patients are not usually aware of this limitation.

Hamstrings is a common term for the semitendinosus, semimebranosus and the long head of the biceps femoris.

The hamstrings and the gluteus maximus work together to prevent flexion strength (gravitation) and by eccentric contraction end the swing phase of gait.

Clinical notes

The medial group of the thigh muscles are often acutely overloaded when a patient slips or keeps balance in situations close to falling. The adductors hypertonus is often related to the pelvic floor muscles dysfunction or the hip joint pathologies.

Trigger points in the pectineus cause a persistent pain under the inguinal ligament, deep in the groin and in the area of the hip joint. Overload of this muscle is very common after total hip replacement.

Trigger points in the gracilis cause superficial burning and pungent pain, which does not decrease at rest in any position. On the contrary, walking causes pain release.

Trigger points in the proximal part of the adductor magnus cause pain, which is perceived in the area of the pubic symphysis or even in the vagina, rectum or urinary bladder.

The biceps femoris is often injured (stretched or torn) during sprinting disciplines and sports games.

Obturator externus *(musculus obturatorius externus)*

O: external surface of the obturator membrane, obturator foramen (bony margins)
Course of fibers: run dorsally to the neck of the femur
I: femur – trochanteric fossa
F: external rotation of the thigh, accessory flexion of the thigh
N: obturator nerve (L3–L4)

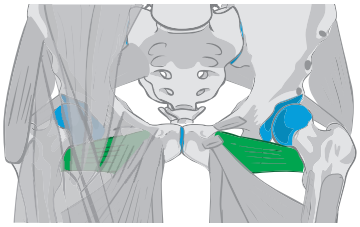

9.2.3 Muscles of the thigh – posterior group

The posterior group of the thigh muscles are **extensors of the hip joint and flexors of the knee joint**. This group consists of **three muscles that have a common innervation from the sciatic nerve**. **The biceps femoris** has a long and short head. If the sciatic nerve divides proximally (**a high division of the sciatic nerve**), the biceps femoris is a **diploneural muscle**, innervated by both the tibial and fibular nerves.

Biceps femoris *(musculus biceps femoris)*

Origin:
- 1 **Long head** *(caput longum)*: ischial tuberosity
- 2 **Short head** *(caput breve)*: femur – linea aspera (middle 1/3 of the lateral lip)

I: fibula – head of fibula
F: flexion of the leg, external rotation of the flexed leg, extension and accessory external rotation of the thigh (the long head only)
N: sciatic nerve (L5–S1, variably L4–S2)
1 **Long head** *(caput longum)*: tibial nerve
2 **Short head** *(caput breve)*: common fibular nerve

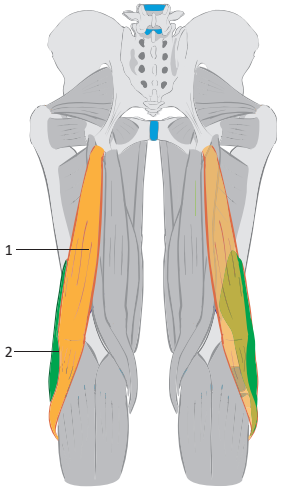

Semitendinosus *(musculus semitendinosus)*

O: ischial tuberosity
I: tibia – medial condyle (via the pes anserinus major)
F: flexion of the leg, internal rotation of the flexed leg, extension and internal rotation of the thigh,
N: sciatic nerve – tibial nerve (L4–S1)

Semimembranosus *(musculus semimembranosus)*

O: ischial tuberosity
I: tibia – medial condyle (2 insertions), femur – lateral condyle (via the oblique popliteal ligament)
F: flexion of the leg, internal rotation of the flexed leg, extension and internal rotation of the thigh
N: sciatic nerve – tibial nerve (L4–S1)

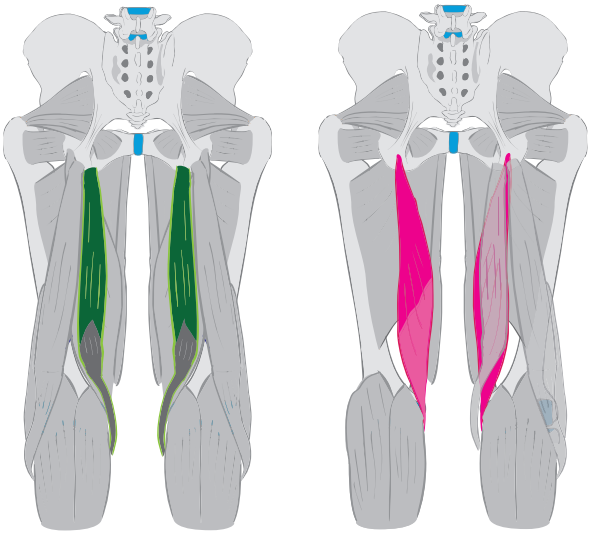

Semitendinosus Semimembranosus

This copy belongs to ali yaghoubi

The muscles of the leg are organised into **three groups**: the anterior, lateral and posterior groups. The anterior group is innervated by the **deep fibular nerve**, the lateral group is innervated by the **superficial fibular nerve**, and the posterior group is innervated by the **tibial nerve**.

1 Anterior group

- 1.1 **Tibialis anterior**
  (musculus tibialis anterior)
- 1.2 **Extensor digitorum longus**
  (musculus extensor digitorum longus)
- 1.3 **Extensor hallucis longus**
  (musculus extensor hallucis longus)

2 Lateral group

- 2.1 **Fibularis longus**
  (musculus fibularis longus)
- 2.2 **Fibularis brevis**
  (musculus fibularis brevis)

3 Posterior group

Superficial layer

- 3.1 **Triceps surae**
  (musculus triceps surae)
- 3.2 **Plantaris**
  (musculus plantaris)

Deep layer

- 3.3 **Popliteus**
  (musculus popliteus)
- 3.4 **Tibialis posterior**
  (musculus tibialis posterior)
- 3.5 **Flexor digitorum longus**
  (musculus flexor digitorum longus)
- 3.6 **Flexor hallucis longus**
  (musculus flexor hallucis longus)

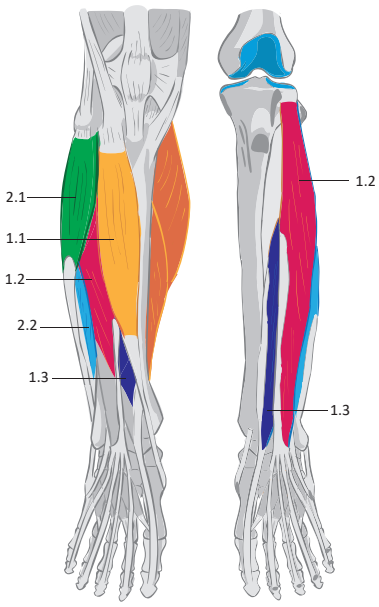

Anterior view of the right and left legs

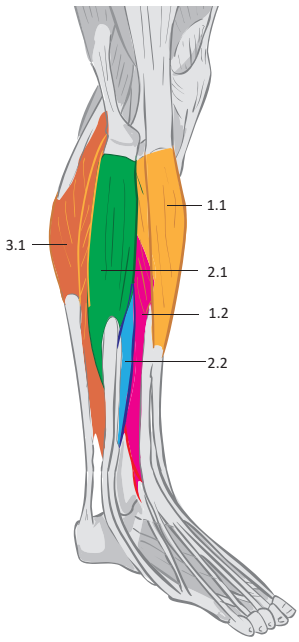

Lateral view of the right leg

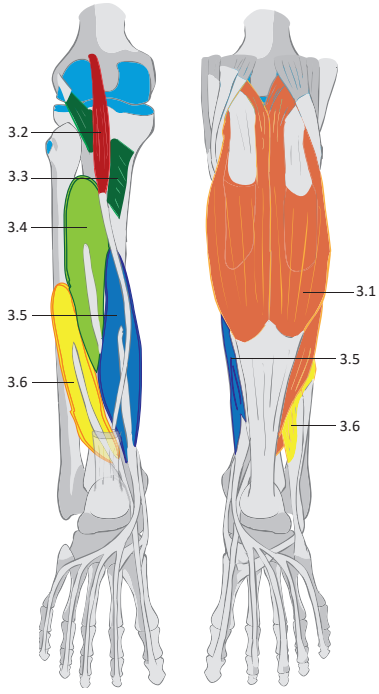

Posterior view of the right and left legs

Muscles

The fibularis tertius is part of the extensor digitorum longus, which inserts on the tuberosity of the fifth metatarsal bone by a slim and often doubled tendon. The muscle is present in 92 % of cases and is innervated by the deep fibular nerve. It helps the extensor digitorum longus in extension of the toes and pronation of the foot.

The tibialis anterior prevents plantar flexion of the foot at the beginning of the stance phase of gait. In addition, it helps prevent the toes from coming into contact with the ground during the swing phase of gait.

The dorsal aponeurosis *(aponeurosis dorsalis)* is a fibrous structure on the back of the toes which attaches to the middle and distal phalanges. The extensor digitorum longus and brevis, lumbricals and interossei are attached to the phalanges by means of the dorsal aponeurosis.

Clinical notes

Trigger points in the tibialis anterior cause pain on the ventromedial surface of the ankle and on the dorsal and medial surfaces of the big toe. The trigger points are usually situated in the proximal third of the muscle and they are very painful. They can be caused by driving for long periods of time with high-positioned pedals.

The extensor digitorum longus is called the "mallet toe muscle". The muscle is more effective during walking as a dorsal flexor of the foot when the metatarsophalangeal joints are fully extended. If the muscle is used for dorsal flexion of the foot instead of the tibialis anterior, a deformity called mallet toe may develop (see page 56).

A hypertonic extensor digitorum longus can compress the deep fibular nerve against the fibula.

Weakening of the fibular muscles predisposes to ankle instability syndrome and sprained ankles. A trigger point in the fibular muscles causes pain in the area of the lateral malleolus.

A hypertonic fibularis longus can compress the common fibular nerve against the fibula.

The fibularis brevis often develops trigger points following ankle sprains or immobilisation in plaster.

The anterior group of the leg muscles consists of three muscles that are located ventrally to the interosseous membrane of the leg. They have a common innervation from the **deep fibular nerve** and are **extensors of the leg**. Tendons of these muscles pass under the **superior and inferior extensor retinacula**. The tibialis anterior helps to maintain both **the longitudinal and transverse arches of the foot**.

Tibialis anterior *(musculus tibialis anterior)*

O: tibia – lateral condyle,
tibia – body (lateral surface – proximal 2/3),
interosseous membrane of leg
I: base of the 1st metatarsal,
medial cuneiform (plantar surface)
F: dorsal flexion and supination of the foot,
maintains the longitudinal and transverse arches of the foot
N: deep fibular nerve (L4)



Anterior view of the right and left legs



Lateral view of the right leg

Extensor digitorum longus *(musculus extensor digitorum longus)*

O: tibia – lateral condyle,
fibula – body (medial surface – proximal 3/4),
interosseous membrane of leg, anterior intermuscular septum of leg
I: four tendons to the 2nd–5th toes (into the dorsal aponeurosis of the toes),
distal phalanges of the toes
F: extension of the 2nd–5th toe,
dorsal flexion and accessory pronation of the foot
N: deep fibular nerve (L4–S1)





Extensor hallucis longus *(musculus extensor hallucis longus)*

O: fibula – medial surface (middle 2/4),
interosseous membrane of leg
I: dorsal aponeurosis of the big toe,
distal phalanx of the big toe
F: extension of the big toe, accessory dorsiflexion of the foot
N: deep fibular nerve (L4–L5, variably S1)



9.3.2 Muscles of the leg – lateral group

The lateral group of the leg muscles consits of two fibular muscles that originate on the **lateral surface of the fibula**. Both muscles run **behind the lateral malleolus in a common tendinous sheath under the superior and inferior fibular retinacula**. Muscles of the lateral group are innervated by the **superficial fibular nerve** and their common function is **eversion of the foot**. The fibularis longus maintains the longitudinal and transverse arches of the foot.

Fibularis longus *(musculus fibularis longus)*

O: fibula – head of fibula,
fibula – body (lateral surface – proximal 1/2)
Course of fibers: through the malleolar groove of the fibula
(in the common tendinous sheath with the fibularis brevis),
through a groove for the tendon on the plantar surface of the cuboid (in the tendinous sheath)
I: base of the 1st metatarsal,
medial cuneiform (plantar surface)
F: plantar flexion, pronation and abduction of the foot (eversion of the foot),
holds both the longitudinal and transverse arch of the foot
N: superficial fibular nerve (L5–S1)

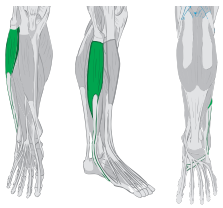

Anterior, lateral and posterior views of the right leg

Fibularis brevis *(musculus fibularis brevis)*

O: fibula – body (lateral surface – distal 1/2)
I: base of the 5th metatarsal – tuberosity of the 5th metatarsal
F: plantar flexion, pronation and abduction of the foot (eversion of the foot)
N: superficial fibular nerve (L5–S1)

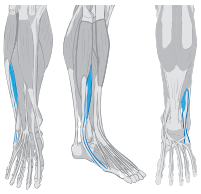

This copy belongs to ali yaghoubi

The posterior group of the muscles of the leg can be divided into **two layers**. The superficial layer consists of one muscle, **the triceps surae,** which is made up of **the soleus** and the two-headed **gastrocnemius**. Variably, a rudimentary muscle, **the plantaris**, can also be found in the superficial layer.

Triceps surae *(musculus triceps surae)*

Origin:

- 1 **Medial head of gastrocnemius** *(caput mediale musculi gastrocnemii)*: femur – medial epicondyle (internal supracondylar tubercle)
- 2 **Lateral head of gastrocnemius** *(caput laterale musculi gastrocnemii)*: femur – lateral epicondyle (external supracondylar tubercle)
- 3 **Soleus** *(Musculus soleus)*: fibula – head of fibula, tibia – soleal line, tibia – posterior surface (proximal 1/4), tendinous arch of soleus

I: calcaneus – calcaneal tuberosity (via the Achilles/calcaneal tendon)
F: plantar flexion of the foot, flexion of the leg (only gastrocnemius), stabilizes the knee joint
N: tibial nerve (L5–S3)

Plantaris *(musculus plantaris)*

- 4 **Plantaris** *(musculus plantaris)*

O: femur – lateral supracondylar line
I: calcaneus – calcaneal tuberosity (via the Achilles/calcaneal tendon)
F: accessory plantar flexion of the foot and leg
N: tibial nerve

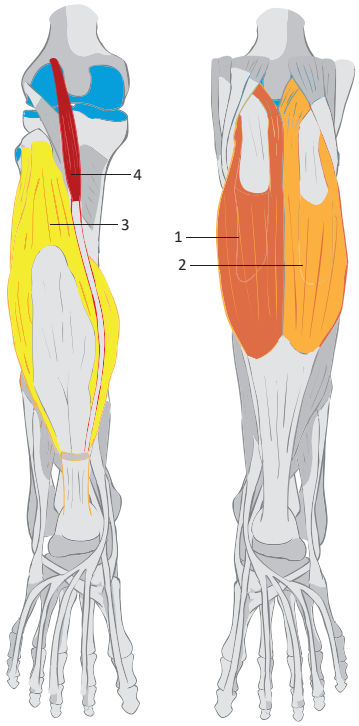

Posterior view of the right and left legs

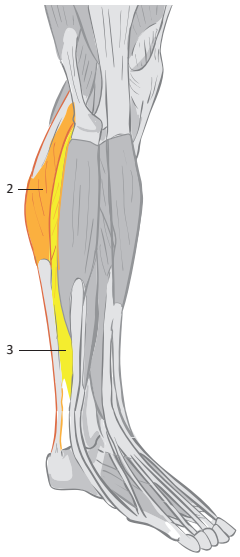

Lateral view of the right leg

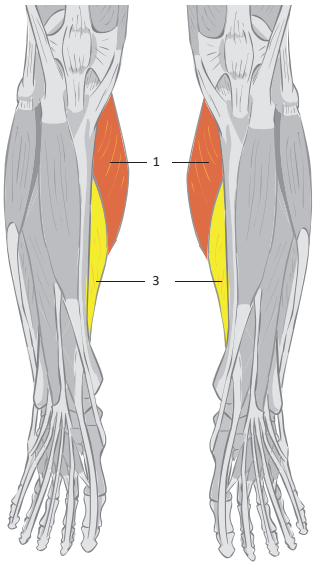

Anterior view of the right and left legs

The gastrocnemius and soleus are sometimes described as being separate individual muscles.

The fabella is a sesamoid bone present in 25 % of cases. The word fabella means "green bean". This bone can be found at the origin of the lateral head of the gastrocnemius at the level of the lateral condyle of the femur. It can cause pain during flexion of the leg.

The achilles tendon is a term for the calcaneal tendon.

The bursa of the calcaneal tendon is located near the insertion of the calcaneal tendon on the calcaneal tuberosity at the triangle of Kager.

The quadratus plantae stabilises the oblique course of the flexor digitorum longus tendons on the sole. It is sometimes called the accessory flexor of the foot.

For proper function of the gastrocnemius it is important to avoid positions in which the muscle is passively shortened such as occurs by wearing high-heeled footwear and sitting with support for only the distal part of the sole.

Clinical notes

Trigger points in the gastrocnemius can cause pain from the distal dorsal part of the thigh to the midpoint of the sole (but omitting the heel). They often cause muscle spasms in the night and can cause pain during walking (intermittent claudication).

Pain from the soleus is located in the whole area of the heel, the Achilles tendon and the ipsilateral sacroiliac joint. Such pain is quite common for recreational runners.

The flexor hallucis longus plays a significant role in the development of hallux valgus. Shoes which force the great toe inwards to the valgus deformity are not recommended, especially in puberty and in young adults.

The deep layer of the leg muscles consists of **four muscles**. The tendons of these muscles (except the popliteus) **run behind the medial malleolus through the malleolar canal under the flexor retinaculum in three separate tendon sheaths**. The muscles of the deep layer act as **flexors of the foot and toes** and have a common innervation from **the tibial nerve**.

Popliteus *(musculus popliteus)*

O: femur – lateral condyle (groove for the popliteus)
I: tibia – posterior surface (above the soleal line)
F: flexion of the leg ("unlocks" the knee joint),
internal rotation of the flexed leg,
influences the movements of
the lateral meniscus of the knee joint
N: tibial nerve (L4–S1)

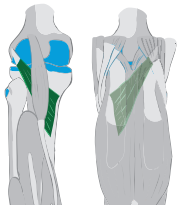

Posterior view of the right and left legs

Tibialis posterior *(musculus tibialis posterior)*

O: tibia and fibula – posterior surface (proximal 2/3),
interosseous membrane of leg
I: navicular – tuberosity of the navicular,
medial cuneiform – plantar surface (medial part of the tendon)
F: plantar flexion, supination and adduction
of the foot (inversion of the foot),
holds the longitudinal arch of the foot
N: tibial nerve (L5–S1, variably S2)

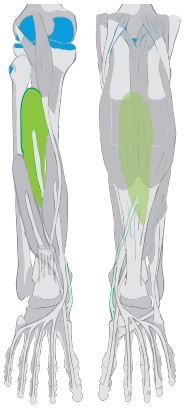

Posterior view of the right and left legs

Flexor digitorum longus *(musculus flexor digitorum longus)*

O: tibia – posterior surface (middle 2/4),
interosseous membrane of leg
I: four tendons for the 2nd–5th toes
(insertion on the bases of the distal phalanges)
F: flexion of the toes at the metatarsophalangeal joint
and proximal and distal interphalangeal joints,
plantar flexion, supination and adduction
of the foot (inversion of the foot),
helps to hold the longitudinal arch of the foot
N: tibial nerve (L5–S2)

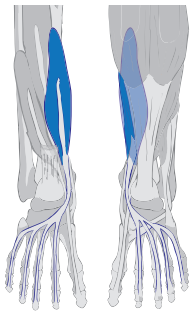

Posterior view of the right and left legs

Flexor hallucis longus *(musculus flexor hallucis longus)*

O: fibula – posterior surface (distal 2/3),
interosseous membrane of leg
I: base of the distal phalanx of the big toe
F: flexion of the big toe at metatarsophalangeal
and interphalangeal joints,
plantar flexion, supination and adduction
of the foot (inversion of the foot),
helps to hold the longitudinal arch of the foot
N: tibial nerve (L5–S2)

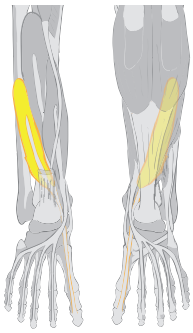

Posterior view of the right and left legs

This copy belongs to ali yaghoubi

The muscles of the foot are organised into six groups: **dorsal, medial** (group of the big toe), **lateral** (group of the little toe), **middle**, **interossei** and **lumbricals**.

1 **Dorsal group**
- 1.1 **Extensor digitorum brevis** *(musculus extensor digitorum brevis)*
- 1.2 **Extensor hallucis brevis** *(musculus extensor hallucis brevis)*

2 **Medial group** (group of the great toe)
- 2.1 **Abductor hallucis** *(musculus abductor hallucis)*
- 2.2 **Flexor hallucis brevis** *(musculus flexor hallucis brevis)*
- 2.3 **Adductor hallucis** *(musculus adductor hallucis)*

3 **Lateral group** (group of the little toe)
- 3.1 **Abductor digiti minimi** *(musculus abductor digiti minimi)*
- 3.2 **Flexor digiti minimi brevis** *(musculus flexor digiti minimi brevis)*
- 3.3 **Opponens digiti minimi** *(musculus opponens digiti minimi)*

4 **Middle group**
- 4.1 **Flexor digitorum brevis** *(musculus flexor digitorum brevis)*
- 4.2 **Quadratus plantae** *(musculus quadratus plantae)*

5 **Interossei** *(musculi interossei)*
- 5.1 **Plantar interossei** *(musculi interossei plantares)*
- 5.2 **Dorsal interossei** *(musculi interossei dorsales)*

6 **Lumbricals** *(musculi lumbricales)*
- 6.1 **Lumbricals** *(musculi lumbricales)*

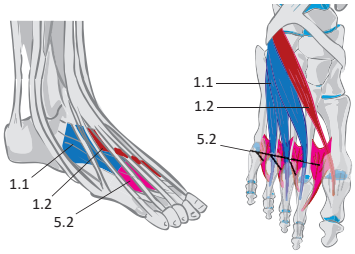

Lateral and superior view of the right foot

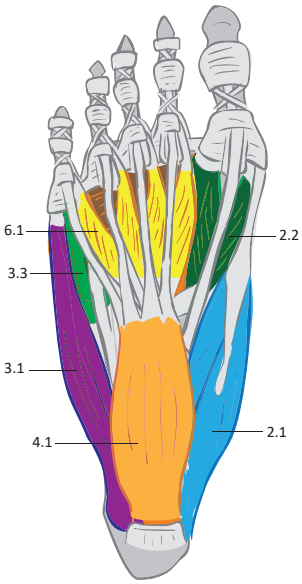

Inferior view of the right foot

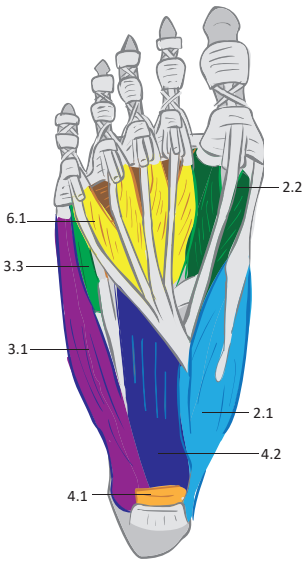

Inferior view of the right foot

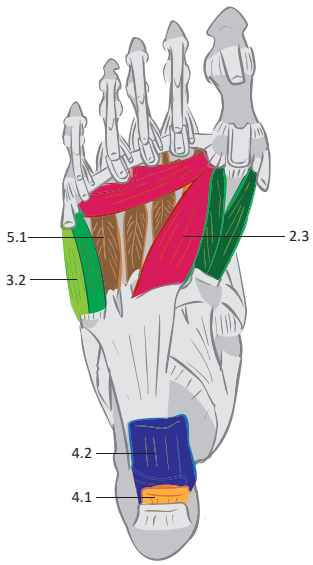

Inferior view of the right foot

A mnemonic for the muscle groups of the great and little toe is as follows:
HAFA MAFO
H – Hallux (big toe)
A – Abductor hallucis
F – Flexor hallucis brevis
A – Adductor hallucis
M – Digitus Minimus (little toe)
A – Abductor digiti minimi
F – Flexor digiti minimi
O – Opponens digiti minimi

During walking, the muscles of the foot enable flexibility for shock absorption. They are also tough when compressive strength is working in rebounding. They are physiologically inactive when standing on both lower limbs.

Despite its name, the main function of the abductor hallucis is flexion of the big toe. The muscle is able to produce abduction in only about 20 % of the population.

The adductor hallucis is responsible for stabilisation of the metatarsal bones in the transverse plane. It also participates in maintenance of the transverse foot arch.

The abductor hallucis is an important muscle for stabilisation of the medial longitudinal arch of the foot.

Clinical notes

The extensor digitorum brevis and extensor hallucis brevis are often shortened and overloaded. One of the causes of this is wearing heavy shoes (e.g. medical shoes).

The abductor hallucis can compress the tibial nerve and its branches (medial and lateral plantar nerves) as they leave the malleolar canal.

Trigger points in the abductor hallucis cause pain on the medial edge of the sole that is maximal on the heel which differs from trigger points in the soleus, where the heel pain is diffuse. The muscle is often overloaded in people with flat feet.

Traction of the lateral head of the flexor hallucis brevis and the abductor hallucis is the main cause of hallux valgus development.

When hallux valgus deformity is significantly developed, the abductor hallucis loses its ability to pull the great toe away and its traction can even enlarge the deformity.

Trigger point in the transverse head of the adductor hallucis causes numbness and swelling in the area of the heads of the metatarsal bones.

The dorsal group of the foot muscles consists of two short muscles on the dorsum of the foot. These muscles are **extensors of the toes** and have a common innervation from the **deep fibular nerve**.

Extensor digitorum brevis *(musculus extensor digitorum brevis)*

O: calcaneus – dorsal surface
I: 3–4 tendons for the 2nd–4th toe (variably the 5th toe), insertion into the dorsal aponeurosis of the toes
F: extension of the2nd–4th toe (variably the 5th toe)
N: deep fibular nerve (L4–S1)

Extensor hallucis brevis *(musculus extensor hallucis brevis)*

O: calcaneus – dorsal surface
I: dorsal aponeurosis of the big toe
F: extension of the big toe (only in the metatarsophalangeal joint)
N: deep fibular nerve (L4–S1)

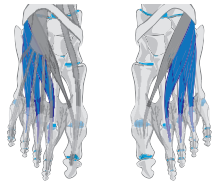

Superior view of the right and left feet

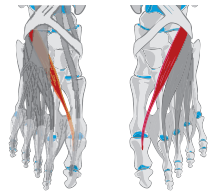

9.4.2 Muscles of the foot – medial group (group of the big toe)

The medial group (of the great toe) comprises of **three muscles**. Two of these muscles (flexor hallucis brevis and adductor hallucis) have two heads. All muscles of the medial group are innervated by the **tibial nerve** (via the medial and lateral plantar nerve).

Abductor hallucis *(musculus abductor hallucis)*

O: calcaneus – calcaneal tuberosity (medial process)
I: base of the proximal phalanx of the big toe, medial sesamoid bone of the big toe
F: abduction and flexion of the big toe at the metatarsophalangeal joint, helps to hold the longitudinal arch of the foot
N: tibial nerve – medial plantar nerve (L5–S1)

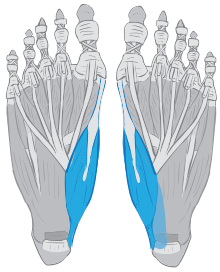

Inferior view of the right and left feet

Flexor hallucis brevis *(musculus flexor hallucis brevis)*

Origin:
- 1 **Medial head** *(caput mediale)*: intermediate cuneiform bone and base of the 2nd–4th metatarsals
- 2 **Lateral head** *(caput laterale)*: cuboid and lateral cuneiform – plantar surface

I: base of the proximal phalanx of the big toe, sesamoid bones of the big toe (both medial and lateral)
F: flexion of the big toe at the metatarsophalangeal joint
N: tibial nerve – medial plantar nerve (S1–S2)

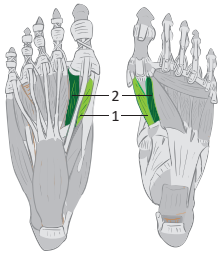

Inferior view of the right and left feet

Adductor hallucis *(musculus adductor hallucis)*

Origin:
- 1 **Oblique head** *(caput obliquum)*: base of the 2nd–4th metatarsal, cuboid – plantar surface, cuneiforms – plantar surface
- 2 **Transverse head** *(caput transversum)*: 3rd–5th metatarsophalangeal joints

I: base of the proximal phalanx of the big toe (plantar surface), lateral sesamoid bone of the big toe
F: adduction of the big toe accessory flexion of the toes at the metatarsophalangeal joints
N: tibial nerve – lateral plantar nerve (S1–S2)

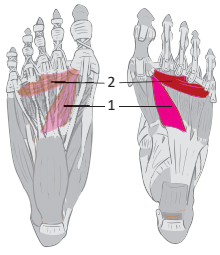

Inferior view of the right and left feet

This copy belongs to ali yaghoubi

9.4.3 Muscles of the foot – lateral group (group of the little toe)

The lateral group of the foot muscles consists of **three small muscles** that share **flexion of the little toe** as their main function. Their common innervation is from **the lateral plantar nerve** (a branch of the tibial nerve).

Abductor digiti minimi *(musculus abductor digiti minimi)*

O: calcaneus – calcaneal tuberosity, plantar aponeurosis
I: base of the proximal phalanx of the little toe, tuberosity of the 5th metatarsal
F: abduction and flexion of the little toe at the metatasophalangeal joint
N: tibial nerve – lateral plantar nerve (S1–S2)

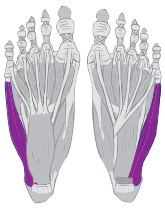

Inferior view of the right and left feet

Flexor digiti minimi brevis *(musculus flexor digiti minimi brevis)*

O: base of the 5th metatarsal
I: base of the proximal phalanx of the little toe
F: flexion of the little toe at the metatarsophalangeal joint
N: tibial nerve – lateral plantar nerve (S1–S2)

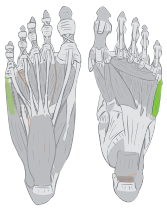

Opponens digiti minimi *(musculus opponens digiti minimi)*

O: base of the 5th metatarsal, long plantar ligament
I: metatarsophalangeal joint of the little toe
F: accessory adductor and flexor of the 5th metatarsal
N: tibial nerve – lateral plantar nerve (S1–S2)

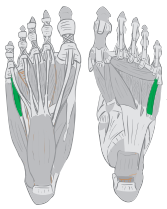

9.4.4 Muscles of the foot – middle group

The middle group of the foot muscles consists of **2 muscles** which **maintain the longitudinal arch of the foot**. Their common innervation is from the **lateral and medial plantar nerves**, which are branches of the tibial nerve.

Flexor digitorum brevis *(musculus flexor digitorum brevis)*

O: calcaneus – calcaneal tuberosity (medial process)
I: four tendons to the 2nd–5th toes (with bifuracated insertion on the bases of the middle phalages)
F: flexion of the 2nd–5th toes at the metatarsophalangeal and proximal interphalangeal joints
N: tibial nerve – medial plantar nerve (L5–S1)

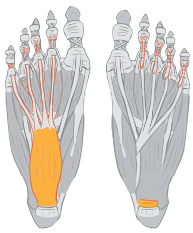

Inferior view of the right and left feet

Quadratus plantae *(musculus quadratus plantae)*

O: calcaneus – plantar surface, long plantar ligament
I: into the tendons of the flexor digitorum longus (before it divides into tendons for the inidividual toes)
F: straightens the oblique traction of the flexor digitorum longus (participates in flexion of the toes)
N: tibial nerve – lateral plantar nerve (S1–S2)

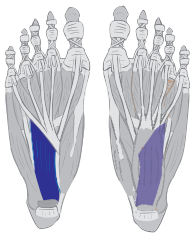

Muscles

The opponens digiti minimi is an inconstant muscle. It often merges with the flexor digiti minimi brevis.

The flexor digiti minimi brevis is developed from the opponens digiti minimi as we know it in monkeys. It corresponds to the opponens digiti minimi of the hand.

Tendinous chiasm *(chiasma tendinum)* is a crossing of tendons. The bifurcated tendons of the flexor digitorum brevis are crossed and insert on the middle phalanges. The tendons of the flexor digitorum longus pass through these bifurcations to insert on the distal phalanx. This is an example of a tendinous chiasm.

The quadratus plantae has two innominate heads which originate on the medial and lateral margin of the calcaneus. The space between them is filled with a triangular fascia. The muscle resembles the flag of the Czech Republic and the blue field is represented by the fascia.

The biggest interossei are at the fourth toe (2nd plantar and 4th dorsal) and their origins also cover the largest area.

The abductor digiti minimi is an important muscle for stabilisation of the lateral longitudinal arch of the foot.

Clinical notes

Trigger points in the abductor digiti minimi cause pain under the fifth metatarsophalangeal joint.

Trigger points in the abductor hallucis, abductor digiti minimi and flexor digitorum brevis cause intense pain that is present at rest and limits walking. The pain forces the patient to seek medical help.

Trigger points in the flexor digitorum brevis cause pain under the second, third and fourth metatarsophalangeal joint. The pain never spreads distally to the toes or proximally to the sole. Trigger point in the extensor digitorum brevis causes pain on the lateral part of the foot dorsum (instep).

Hypertonicity and trigger points in the quadratus plantae cause pain on the plantar side of the heel.

The organisation of the **interossei muscles of the foot** differs from the organisation of the interossei muscles of the hand. They act on a virtual **axis that runs through the 2nd toe** (on the hand this axis runs through the 3rd finger). The interossei muscles maintain the **transverse arch of the foot**. **The lumbricals** are **4 small muscles originating from the tendons of the flexor digitorum longus**. The common innervation of the interrossei and lumbicals is from the **lateral plantar nerve**, with the exception of the 2 medial lumbricals, which are innervated by **medial plantar nerve**.

Plantar interossei *(musculi interossei planteres)*

– the plantar interrossei are three muscles located in the 2nd–4th interosseous space of the metatarsals
O: 3rd–5th metatarsal (tibial side),
epimysium of the surrounding muscles,
tendon of fibularis longus,
long plantar ligament,
articular capsules of the tarsometatarsal joints
I: dorsal aponeurosis of the 3rd–5th toes,
base of the proximal phalanges of the 3rd–5th toes (medial side)
F: flexion of the toes at the metatarsophalangeal joints,
extension of the toes at the proximal and distal interphalangeal joints (by pulling the dorsal aponeurosis),
adduction of the toes (towards the axis that runs through the 2nd toe)
N: tibial nerve – lateral plantar nerve (S1–S2)

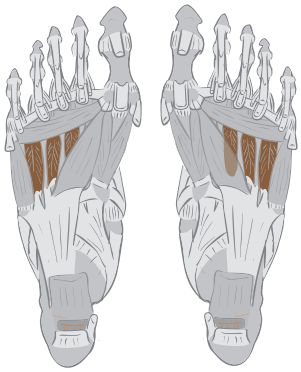

Inferior view of the right and left feet

Dorsal interossei *(musculi interossei dorsales)*

– the dorsal interossei (DI) are 4 muscles located in the 1st–4th interosseous spaces of the metatarsals
O: each dorsal interreous muscle originates as two heads on neighbouring surfaces of the metatarsals that join in the interosseous space, forming the shape of a tree
I: the dorsal aponeurosis and the bases of the proximal phalanges
2nd digit, proximal phalanx – on the medial surface (1st DI)
2nd digit, proximal phalanx – on the lateral surface (2nd DI)
3rd digit, proximal phalanx – on the lateral surface (3rd DI)
4th digit, proximal phalanx – on the lateral surface (4th DI)
F: flexion of the toes at the metatarsophalangeal joints,
extension of the toes at the proximal and distal interphalangeal joints (by pulling the dorsal aponeurosis),
abduction of the toes away from the axis running through the 2nd toe
N: tibial nerve – lateral plantar nerve

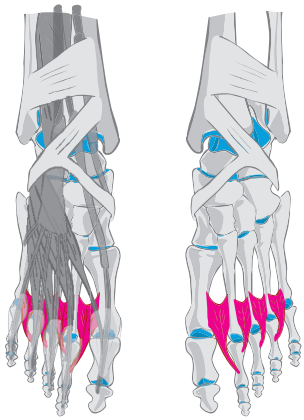

Superior view of the right and left feet

Lumbricals *(musculi lumbricales)*

The lumbricals are 4 muscles corresponding to the 2nd–5th toe.
O: the tendons of the flexor digitorum longus of the 2nd–5th toe
I: dorsal aponeurosis of the 2nd–5th toe,
the bases of the proximal phalanges
of the 2nd–5th toe (on their medial surfaces)
F: flexion of the toes at the metatarsophalangeal joints,
extension of the toes at the proximal and distal interphalangeal joints (by pulling the dosal aponeurosis),
medial duction of the toes towards the big toe
Innervation:
Lumbricals I and II: tibial nerve – medial plantar nerve (L5–S2)
Lumbricals III and IV: tibial nerve – lateral plantar nerve (L5–S2)

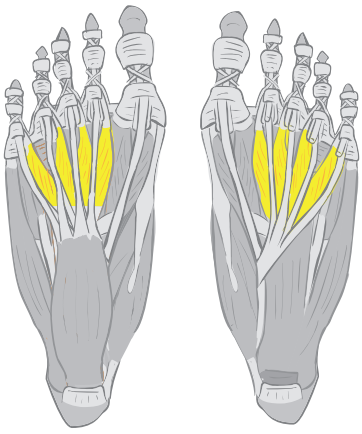

Inferior view of the right and left feet

This copy belongs to ali yaghoubi

Tendinous sheaths are filled with viscous fluid. **They coat tendons in places of high vulnerability during movement**. This occurs where tendons pass under the flexor retinaculum, the superior and inferior extensor retinacula, the superior and inferior fibular retinacula and on the toes. Tendinous sheaths make **smooth sliding movements of tendons** possible.

Tendinous sheaths behind the medial malleolus *(medial malleolus)*

1 **Tibial tarsal tendinous sheaths** *(vaginae tendinum tarsales tibiales)*
– is located under the flexor retinaculum
- 1.1 **Tendinous sheath of tibialis posterior** *(vagina tendinis musculi tibialis posterioris)*
- 1.2 **Tendinous sheath of flexor digitorum longus** *(vagina tendinis musculi flexoris digitorum longi)*
- 1.3 **Tendinous sheath of flexor hallucis longus** *(vagina tendinis musculi flexoris hallucis longi)*

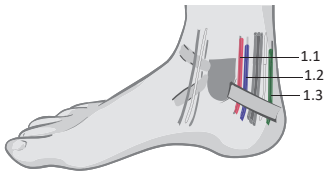

Medial view of the right foot

Tendinous sheaths on the dorsum of the foot

2 **Anterior tarsal tendinous sheaths** *(vaginae tendinum tarsales anteriores)*
– under the superior and inferior extensor retinacula
- 2.1 **Tendinous sheath of tibialis anterior** *(vagina tendinis musculi tibialis anterioris)*
- 2.2 **Tendinous sheath of extensor hallucis longus** *(vagina tendinis musculi extensoris hallucis longi)*
- 2.3 **Tendinous sheath of extensor digitorum longus** *(vagina tendinis musculi extensoris digitorum longi)*

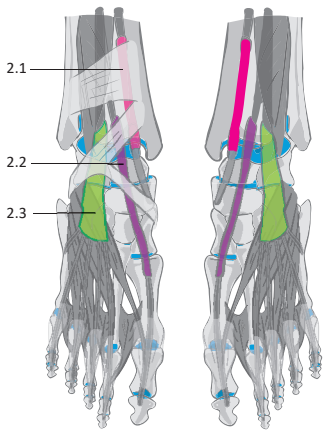

Superior view of the right and left feet

Tendinous sheaths behind the lateral malleolus *(lateral malleolus)*

3 **Fibular tarsal tendinous sheaths** *(vaginae tendinum tarsales fibulares)*
– under the superior and inferior fibular retinaculum
- 3.1 **Common tendinous sheath of fibulares** *(vagina communis tendinum musculorum fibularium)*



Lateral view of the right foot

Tendinous sheaths on the sole of the foot

- 4.1 **Plantar tendinous sheath of fibularis longus** *(vagina plantaris tendinis musculi fibularis longi)*
  – for the tendon of the fibularis longus in its groove on the plantar surface of the cuboid
- 4.2 **Fibrous sheaths of toes** *(vaginae fibrosae digitorum pedis)*
  – osteofibrous canals made of firm fibrous tissue coating synovial sheaths of the tendons of the toes
  – are connected to the plantar fibrocartilage of the metatarsophalangeal and interphalangeal joints

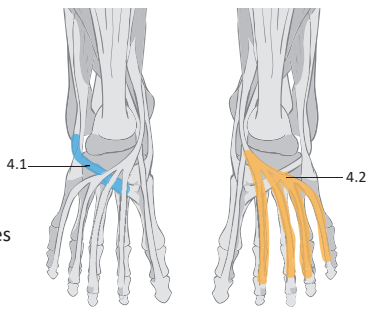

Inferior view of the right and left feet

Muscles

The cribriform fascia *(fascia cribrosa)* is part of the fascia lata in the area of the saphenous opening, containing openings for the passage of small blood and lymph vessels.

The plantar aponeurosis helps to maintain the longitudinal arch of the foot.

Vincula tendinum are fibrous connections of the flexor digitorum longus and brevis tendons inside the tendon sheaths. Their function is to provide nutrition of the tendons. Vincula tendinum always occur in pairs in each tendon sheath. Vinculum breve is triangular and is located at the tendon insertion. Vinculum longum has a longer thread-like appearance (serving as adaptation for tendon movement during contraction). It is located proximally to the vinculum breve of the same tendon.

Clinical notes

During lateral fasciotomy it is possible to open all four compartments of the leg from one incision.

Patients with plantar fasciitis complain of acute pain over the middle of the sole and/or on the heel. The pain is worse in the morning and when walking. During examination, the pain gets worse when the big toe is passively extended.

The fasciae of the lower limb cover the muscles and create the osteofascial spaces of the lower limb. Thickened fasciae in the tarsal region, where tendons run from the leg to the foot, form the **flexor retinaculum, superior and inferior extensor retinacula** and **superior and inferior fibular retinacula**.

1 **Gluteal fascia** *(fascia glutea)* – covers the gluteus maximus and gluteus medius
– attaches proximally to the iliac crest and medially to the sacrum, distally continues as the fascia lata

2 **Fascia lata** *(fascia lata femoris)*
– attaches proximally to the iliac crest and ingiunal ligament, continues dorsally as the gluteal fascia
– attaches distally to the epicondyles of the femur, base of the patella and head of the fibula
- 2.1 **Iliotibial tract** *(tractus iliotibialis)* – a thickened lateral band of the fascia lata
  – attaches to the tuberosity for the iliotibial tract (tubercle of Gerdy)
- 2.2 **Lateral, medial and anteromedial femoral intermuscular septa** *(septum intermusculare femoris laterale, mediale et vastoadductorium)*
  – create the 3 compartments of the thigh (anterior, posterior and medial)

3 **Popliteal fascia** *(fascia poplitea)* – covers the popliteal fossa
– the continuation of the fascia lata

4 **Deep fascia of leg** *(fascia cruris)* – the continuation of the fascia lata
– attaches into the periosteum of the anterior border and medial surface of the tibia and to the medial and lateral malleolus
– forms four compartments (osteofascial spaces)
- 4.1 **Interosseous membrane of the leg** *(membrana interossea cruris)*
  – separates the anterior compartment of the leg from the posterior compartment of the leg
- 4.2 **Anterior intermuscular septum of leg** *(septum intermusculare cruris anterius)*
  – separates the anterior compartment of the leg from the lateral compartment of the leg
- 4.3 **Posterior intermuscular septum of leg** *(septum intermusculare cruris posterius)*
  – separates the lateral compartment of the leg from the posterior compartment of the leg
- 4.4 **Deep plate of deep fascia of leg** *(lamina profunda fasciae cruris)*
  – divides the posterior compartment of the leg into a superficial and a deep layer

5 **Flexor retinaculum** *(retinaculum musculorum flexorum)* – a thickened fascia of the leg, stretched from the medial malleolus to the calcaneal tuberosity
– covers the tendons of the deep layer of the posterior group of muscles of the leg
– borders the malleolar canal medially

6 **Superior and inferior fibular retinaculum** *(retinaculum musculorum fibularium superius et inferius)*
– a thickening of the fascia of the leg
– stretches from the calcaneal tuberosity and lateral malleolus to the foot
– covers the tendons of the fibular muscles as they pass from the leg to the foot

7 **Superior and inferior extensor retinaculum** *(retinaculum musculorum extensorum superius et inferius)*
– a thickened ventral part of the fascia of the leg
– covers the tendons of the extensors where they pass from the leg to the foot

8 **Fascia of the foot** *(fascia pedis)*
– reaches the metatarsophalangeal joints, does not continue to the toes
- 8.1 **Superficial dorsal fascia of foot** *(fascia dorsalis pedis superficialis)*
  – covers the tendons of both the long and short extensors of the toes
- 8.2 **Interosseous dorsal fascia of foot** *(fascia dorsalis pedis interossea)*
  – covers the interossei dorsally
- 8.3 **Superficial plantar fascia** *(fascia plantaris superficialis)*
  – covers the lateral and medial group of the foot muscles
  – fuses with the plantar aponeurosis
  – communicates with the deep layer of the posterior compartment of the leg
  – is separated from the interosseous plantar fascia by the medial and lateral osteofascial septa
    - 8.3.1 **Medial plantar space** *(spatium plantare mediale)*
    - 8.3.2 **Lateral plantar space** *(spatium plantare laterale)*
    - 8.3.3 **Middle plantar space** *(spatium plantare medium)*
- 8.4 **Interosseous plantar fascia** *(fascia plantaris interossea)*
  – covers the interossei ventrally

9 **Plantar aponeurosis** *(aponeurosis plantaris)*
– fuses with the surface of the flexor digitorum brevis and covers it
– originates on the calcaneal tuberosity, disappears distally as bands on the toes

10 **Superficial transverse metatarsal ligament** *(ligamentum metatarsale transversum superficiale)*
– the most distal transverse band of the plantar aponeurosis

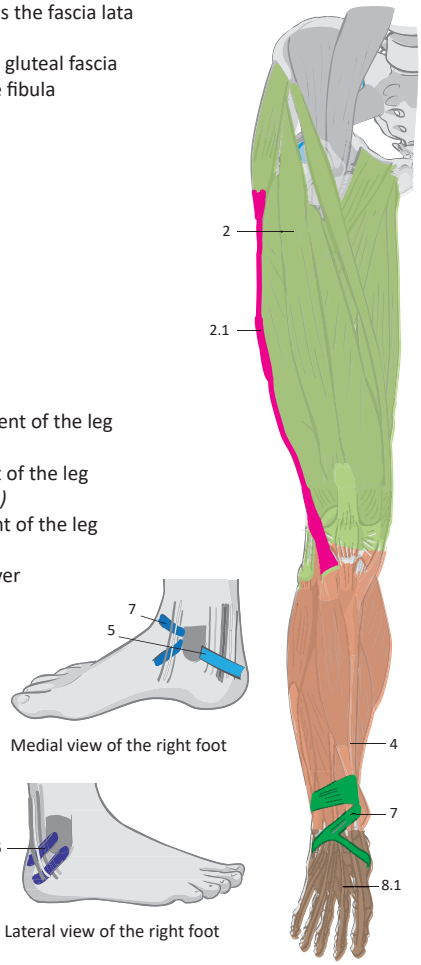

Anterior view of the right lower limb

Medial view of the right foot

Lateral view of the right foot

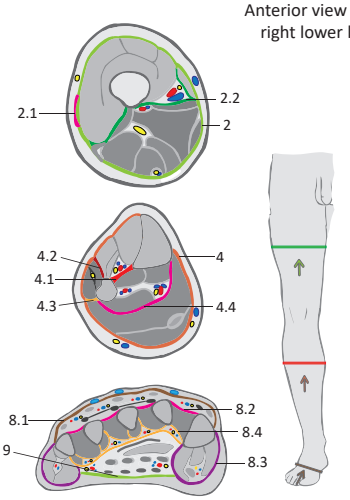

Section of the thigh, leg and foot

This copy belongs to ali yaghoubi

I. General myology

1. Explain the term “diploneural muscle”, and state at least three examples of such muscles. (p. 100)
2. Explain the term “antagonist” and give an example. (p. 101)
3. Explain the term “hypaxial muscles” and state an example (p. 100)

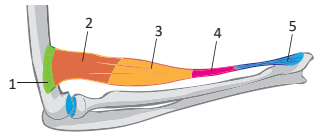

Describe the main parts of skeletal muscle

II. Muscles of the head

4. State which nerve innervates the facial muscles. (p. 102)
5. Explain the term epicranial aponeurosis. (p. 103)
6. Explain the term modiolus of the angle of the mouth and state at least three muscles that insert into it. (p. 102)
7. List 4 masticatory muscles and give their common innervation. (p. 108)

III. Muscles of the neck

8. Explain the movements performed by the sternocleidomastoid. (p. 111)
9. List 4 infrahyoid muscles and state their common innervation. (p. 113)
10. Name the two muscles of the neck which border the scalene fissure and state their insertions. (p. 113)
11. Explain the function of the longus colli. (p. 114)
12. State which layer of the cervical fascia surrounds the infrahyoid muscles and the cervical neuromuscular bundle. (p. 114)

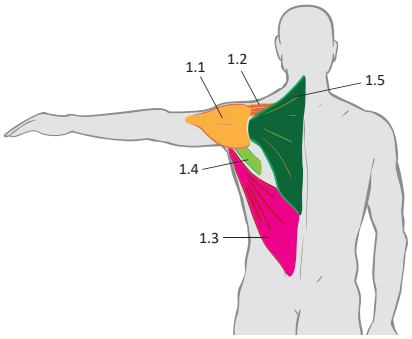

Describe the types of muscles providing abduction to the horizontal position

IV. Muscles of the back

13. Explain the movements performed by the latissimus dorsi and state its origin, insertion and innervation. (p. 116)
14. State three muscles from the 2nd layer of the muscles of the back. (p. 117)
15. Specify the function of the 3rd layer back muscles (serratus posterior superior and inferior). (p. 117)
16. State three long deep muscles of the back that insert on the skull. (p. 119)
17. Describe the course of the fascicles of the spinotransversal system and list three examples. (p. 118)
18. State three muscles which belong to the system of the erector spinae. (p. 119)
19. State three deep muscles of the neck and their common innervation. (p. 122)
20. Name the fascia which surrounds the deep muscles of the back and has a posterior layer that forms the aponeurotic origin of the latissimus dorsi. (p. 123)

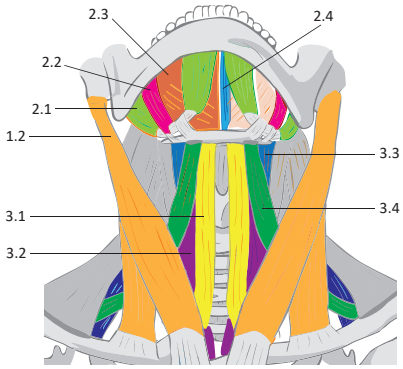

Describe the muscles of the neck

V. Muscles of the thorax

21. State 4 thoracohumeral muscles and describe their common features. (p. 124)
22. Describe the movements made by the serratus anterior and state the origin, insertion and innervation of this muscle. (p. 124)
23. Specify where the external intercostal muscles are replaced by a fibrous membrane. (p. 125)
24. State the common function of the internal and innermost intercostal muscles. (p. 125)
25. State the origin of the lumbar part of the diaphragm and list the muscles which are skipped by diaphragm insertion by means of its arcades. (p. 126)
26. State the location of the aortic hiatus of the diaphragm and two structures that run through it. (p. 126)
27. State 5 functions of the diaphragm. (p. 126)

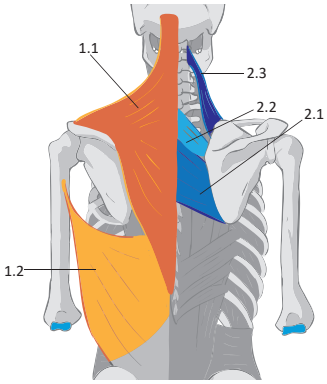

Describe the muscles of the back

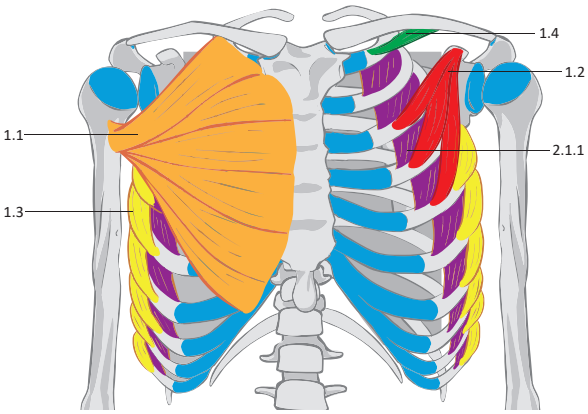

Describe the muscles of the thorax

VI. Muscles of the abdomen

28. State the origin and insertion of the rectus abdominis. (p. 127)
29. Explain the movements performed by the external oblique. (p. 128)
30. State the muscle which belongs to the posterior group of the abdominal muscles. (p. 129)
31. List the three layers of the abdominal fasciae and state which of them lies most superficially. (p. 129)

VII. Pelvic floor muscles

32. List three muscles of the pelvic diaphragm. (p. 130)

VIII. Muscles of the upper limb

33. Explain the movements performed by the deltoid and state the origin, insertion and innervation of this muscle. (p. 132)
34. Explain the term rotator cuff and list the 4 muscles it is formed of. (p. 132)
35. Identify the origin and insertion of the biceps brachii. (p. 134)
36. State the common innervation of the ventral group of muscles of the upper limb. (p. 133)
37. State three biheaded muscles of the ventral group of muscles of the upper limb. (p. 136)
38. State the insertion and inervation of the flexor digitorum profundus (p. 137)
39. List four thenar muscles and state their innervation. (p. 142)
40. Describe the movements performed by the dorsal interossei muscles of the hand. (p. 144)

IX. Muscles of the lower limb

41. State the origin, insertion, innervation and functions of the sartorius. (p. 152)
42. State the origins of the individual parts of the rectus femoris. (p. 152)
43. State the origin, insertion, innervation and functions of the adductor magnus. (p. 153)
44. Explain the term pes anserinus and state three muscles which insert into it. (p. 153)
45. Identify the muscle which inserts by means of the Achilles tendon to the calcaneus. (p. 157)
46. Describe the difference between the origins of the soleus and medial and lateral gastrocnemius. (p. 157)
47. Describe the function of the quadratus plantae. (p. 161)
48. State two short extensors of the foot and state their innervation. (p. 162)

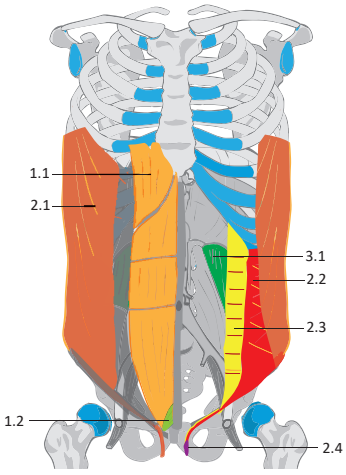

Describe the muscles of the abdomen

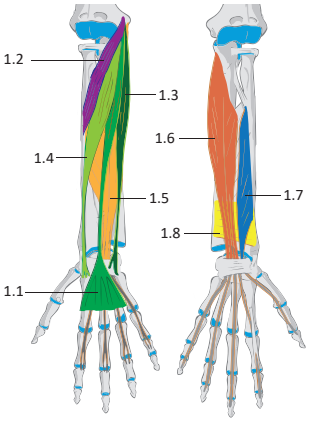

Describe the muscles of the forearm

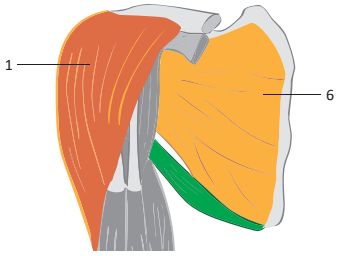

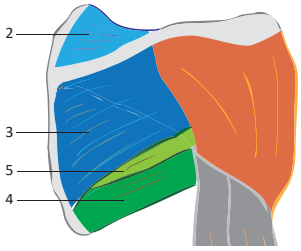

Describe the muscles of the shoulder

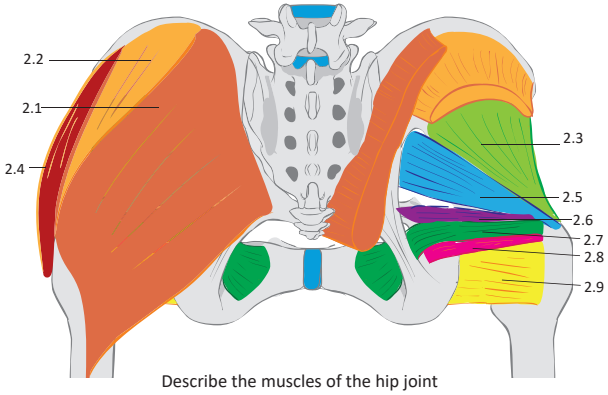

Describe the muscles of the hip joint

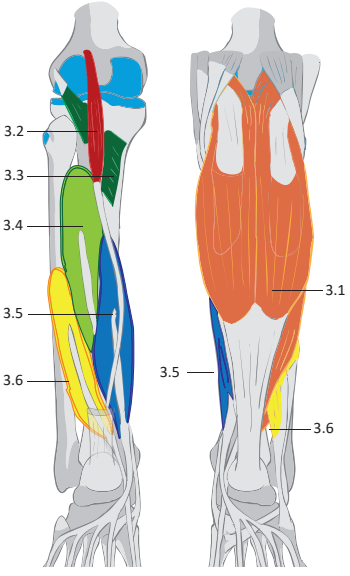

Describe the muscles of the leg

This copy belongs to ali yaghoubi

We would like to **thank the following anatomists, physicians and medical students** for their invaluable help, devotion and feedback in the preparation of this chapter.

Anatomists

Assoc. prof. Václav Báča, MD, PhD – Department of Anatomy, Third Faculty of Medicine, Prague, Czech Republic
Marcela Bezdíčková, DSc, PhD – Department of Anatomy, Faculty of Medicine and Dentistry, Palacký University Olomouc, Czech Republic
Georg Feigl, Univ.-Ass. OA Priv.-Doz. Dr.med.univ. – Medical University of Graz, Institute of Anatomy, Austria
Quentin Fogg, PhD – Centre for Human Anatomy Education, Monash University, Melbourne, Australia

Clinicians

Zdeněk Čech, MSc. – Department of Rehabilitation and Sports Medicine, Second Faculty of Medicine, Charles University in Prague and Motol University Hospital, Czech Republic

Medical students

Lucie Mládenková
Prokop Vodička
Michal Klíma
Kateřina Tomanová
Domenico Messina

11 References

1. AGUR, A. M. R. and A. F. DALLEY. Grant's Atlas of Anatomy. 13th Ed. Philadelphia: Lippincot Williams & Wilkins, 2012, 888 p. ISBN 978-1-60831-756-1.
2. CHUNG, K. W.; CHUNG, H. M. and N. L. HALLIDAY. BRS Gross Anatomy. 8th Ed. Philadelphia: Lippincott Williams & Wilkins, 2015. 544 p. ISBN 978-1-4511-9307-7.
3. LANZ, T. and W. WACHSMUTH. Praktische Anatomie. 7 bands. Berlin: Springer, 2003, 3658 p. ISBN 978-3-540-40571-9.
4. MOORE, K. L.; DALLEY, A. F. and A. AGUR. Clinically oriented anatomy. 7th Ed. Philadelphia: Lippincot Williams & Wilkins, 2014. 1139 p. ISBN 978-1-4511-1945-3.
5. NETTER, F. H. Atlas of Human Anatomy. Professional Edition. 6th Ed. Oxford: Elsevier. 2014. 640 p. ISBN 978-1-455-75888-3.
6. ROHEN, J. W. LUTJEN-DRECOLL, E. and C. YOKOCHI. Color Atlas of Anatomy: A Photographic Study of the Human Body. 7th Ed. Stuttgart: Lippincot Williams & Wilkins, 532 p. ISBN 978-1-58255-856-1.
7. SNELL, R. S. Clinical anatomy by regions. 9th Ed. Philadelphia: Lippincott Williams & Wilkins, 2012. 768 p. ISBN 978-1-60913-446-4.
8. WILLIAMS, P. L., ed. Gray´s Anatomy: the anatomical basis of medicine and surgery. 38th Ed. New York: Churchill Livingstone, 1995, 2092 p. ISBN 0-443-05717-6.

Memorix Anatomy

5 Digestive system

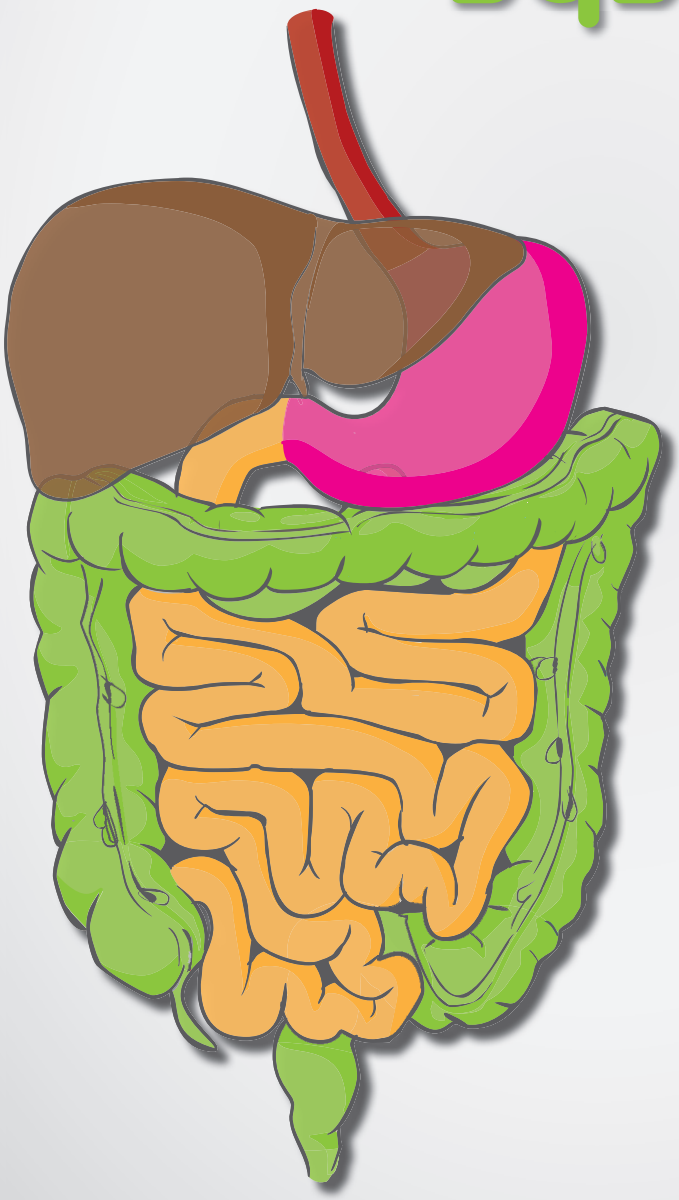

Ladislav Douda
David Kachlík
Radovan Hudák
Ondřej Volný
Adam Whitley

General overview	170
Oral cavity	172
Pharynx	182
Oesophagus	185
Stomach	186
Small intestine	188
Large intestine	191
Liver	196
Gallbladder	199
Pancreas	200
Peritoneum	201
Review questions and figures	202
Acknowledgements and references	204

This copy belongs to ali yaghoubi

The digestive system is comprised of the **digestive tract** extending from the mouth to the anus and of **glands** appended to the canal. Almost the entire digestive canal is built of **four layers**: mucosa, submucosa, a muscular layer and an outer layer that is either serosa or adventitia. The oral cavity, pharynx and oesophagus are described in their separate topographical spaces. The organs of the digestive system within the abdominal cavity are described by their relationship to the peritoneum as being either intraperitoneal, primary retroperitoneal or secondary retroperitoneal. They are supplied by three unpaired trunks from the abdominal aorta: the coeliac trunk and the superior and inferior mesenteric arteries. Blood drains from the abdominal organs via the hepatic portal vein to the liver. Autonomic innervation of the abdominal organs is provided by the **vagus nerve** (parasympathetic) and the **splanchnic nerves** (sympathetic).

Basic parts

- 1 **Oral cavity** *(cavitas oris)*
- 2 **Pharynx**
- 3 **Oesophagus**
- 4 **Stomach** *(gaster)*
- 5 **Small intestine** *(intestinum tenue)*
  - 5.1 **Duodenum**
  - 5.2 **Jejunum**
  - 5.3 **Ileum**
- 6 **Large intestine** *(intestinum crassum)*
  - 6.1 **Caecum**
  - 6.2 **Colon**
  - 6.3 **Rectum**
- 7 **Liver** *(hepar)*
- 8 **Gallbladder** *(vesica biliaris)*
- 9 **Pancreas**

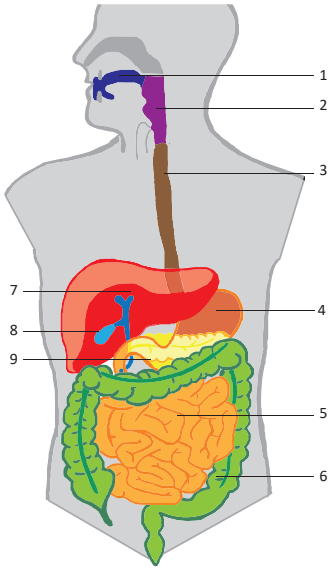

Basic parts of the digestive system

Position of individual parts

Organs in separate topographical spaces

- **The oral cavity** is a topographical space of the skull
- **The pharynx** is located in the cervical visceral space
- **The oesophagus** extends from the cervical visceral space through the superior and posterior inferior mediastinum to the supramesocolic part of the abdominal cavity
- **The aboral 2/3 of the rectum** are located infraperitoneally

Position of organs in relation to the peritoneum

- **Supramesocolic part of abdominal cavity** *(pars supramesocolica cavitatis peritonealis)*
  - Oesophagus (abdominal part)
  - Stomach
  - Liver and gallbladder
  - Pancreas (upper portion of the head, body and tail)
  - Duodenum (superior part and upper portion of the descending part)
- **Inframesocolic part of abdominal cavity** *(pars inframesocolica cavitatis peritonealis)*
  - Jejunum and ileum
  - Caecum
  - Transverse colon
  - Sigmoid colon
  - Rectum (oral 1/3)
  - Pancreas (lower portion of the head, body and tail)
  - Duodenum (the inferior and ascending parts and the lower portion of the descending part)
- **Secondarily retroperitoneal organs**
  - Ascending colon
  - Descending colon
  - Pancreas (head and body)
  - Duodenum (except the ampulla)

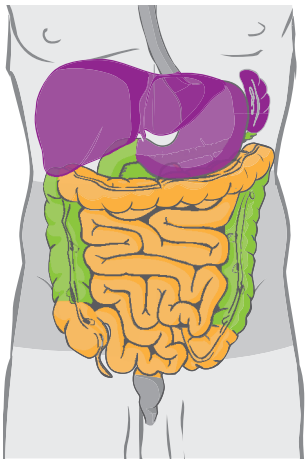
Position of individual parts of the digestive system

The abbreviation GIT for **G**astrointestinal **T**ract is often used for the digestive tract. The synonym alimentary tract is used less often.

For orientation in the digestive system, we use the tems oral *(oralis)*, which means towards the mouth, and aboral *(aboralis)*, which means away from the mouth (towards the anus).

Sphincters are made of thickened circular smooth muscle tissue. In some areas, such as the rectum, there are also skeletal muscle sphincters attached to the outer surface of the digestive canal.

The enteric nervous system is a special part of the autonomic nervous system that controls the digestive system. The submucous plexus of Meissner *(plexus submucosus)* and the myenteric plexus of Auerbach *(plexus myentericus)* work together. They are able to work independently of extrinsic signals, but both are influenced by the sympathetic and parasympathetic nervous systems.

The ileal diverticulum / Meckel's diverticulum is a rudimentary relic of the omphaloenteric duct, which connects the lumen of embryonic intestine to the yolk sac and is connected at a distance of 0 to 100 cm orally to the ileocaecal transition. The diverticulum occurs only in 2 % of cases. In more than one half of cases, the diverticulum contains ectopic tissue (e.g. gastric, duodenal or pancreatic tissue), which can be a source of irritation or haemorrhage.

Glands connected to the digestive canal secrete their products through a system of ducts to the lumen of the digestive canal (exocrine glands) or into capillaries surrounding the cells of the glands (endocrine glands). Glands are located either in the wall of the digestive canal (intramural glands) or outside the wall (extramural glands).

The ventral and dorsal mesogastrium *(mesogastrium ventrale et dorsale)* are developmental peritoneal duplicatures (folds of peritoneum), which fix the primitive intestine (destined to become the stomach) to the anterior and posterior wall of the peritoneal cavity, respectively. During the embryonic period, the developing organs rotate around their duplicatures to reach their final positions.

Histology

1 **Mucosa** *(tunica mucosa)* – also called mucous membrane
– can either be smooth or contains papillae, villi or folds
- 1.1 **Epithelium** – varies in character in different parts of the digestive canal
  – provides mechanical protection and resorbs and secretes substances
- 1.2 **Lamina propria** *(lamina propria mucosae)* – a thin layer of loose connective tissue
  – contains lymphoid tissue (either diffuse or aggregated into nodules), mucous glands and nerve endings
- 1.3 **Muscularis mucosae** *(lamina muscularis mucosae)*
  – a thin layer of smooth muscle that forms the border between the mucosa and submucosa
  – permits independent movement of the mucosa in relation to the other layers of the wall of the digestive canal

2 **Submucosa** *(tela submucosa)* – a layer of connective tissue located under the mucosa, which contains blood vessels, submucous glands, lymphoid tissue and a neural plexus
- 2.1 **Submucous plexus of Meissner** *(plexus submucosus)* – an autonomic nervous plexus with ganglia
  – plays an important role in controlling the secretion of substances into the lumen and in regulating perfusion of the intestinal wall
  – works predominantly via local reflexes

3 **Muscular layer** *(tunica muscularis)* – the muscular layer of the oral cavity, pharynx, oral half of the oesophagus and aboral part of the rectum is composed of striated muscle
– the muscular layer of all other parts of the digestive canal is composed of smooth muscle tissue
– consists of two layers where it is made of smooth muscle tissue
- 3.1 **Circular layer** *(stratum circulare)* – the inner layer
- 3.2 **Longitudinal layer** *(stratum longitudinale)* – the outer layer
- 3.3 **Myenteric plexus of Auerbach** *(plexus myentericus)*
  – an autonomic nervous plexus with ganglia located between the two layers of smooth muscle
  – is responsible for controlling intestinal peristalsis

4 **Outer surrounding connective tissue** *(tunica externa)* – the outermost layer
- 4.1 **Adventitia** *(tunica adventitia)*
  – a layer of loose connective tissue covering and holding organs to the surroundings outside the peritoneal cavity
- 4.2 **Serosa** *(tunica serosa)*
  – consists of subserous connective tissue covered by mesothelium
  – a glossy membrane covering the organs inside the peritoneal cavity
  – also called visceral peritoneum *(peritoneum viscerale)*

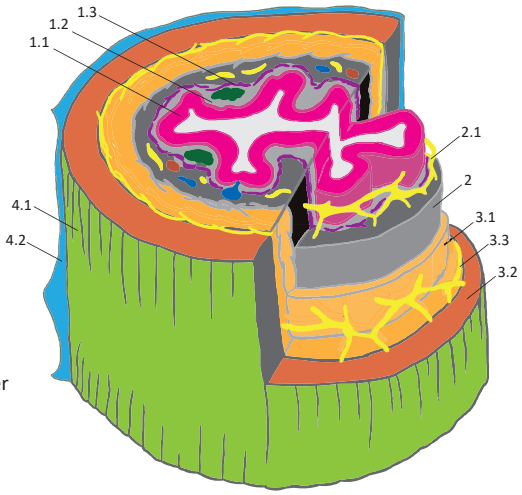

General structure of the wall of the digestive canal

Development of the digestive system

1 **Stomodeum** – the most anterior part of the developing digestive canal
– is derived from the ectoderm and develops into the oral cavity
- 1.1 **Oropharyngeal membrane** *(membrana oropharyngea)*
  – separates the stomodeum from the primitive intestine

2 **Proctodeum** – the most posterior part of the developing digestive canal
– is derived from the ectoderm and develops into the aboral part of the anal canal
- 2.1 **Cloacal membrane** *(membrana cloacalis)*
  – separates the proctodeum from the hindgut

3 **Primitive intestine** *(preenteron* – is derived from the endoderm
- 3.1 **Foregut** *(proenteron)* – extends from the oropharyngeal membrane to the liver bud
  – **develops into:** pharynx, oesophagus, stomach, duodenum (oral half), liver, gallbladder and pancreas
  – **supplied with blood by**: coeliac trunk
- 3.2 **Midgut** *(mesenteron)* – opens ventrally into the yolk sac
  – **develops into**: duodenum (aboral half), jejunum, ileum, caecum, ascending colon, transverse colon (oral 2/3)
  – **supplied with blood by:** superior mesenteric artery
- 3.3 **Hindgut** *(metenteron)* – extends from the end of the midgut to the cloacal membrane
  – **develops into**: transverse colon (aboral 1/3), descending colon, sigmoid colon, rectum (rectal ampulla and oral part of the anal canal)
  – **supplied with blood by**: inferior mesenteric artery

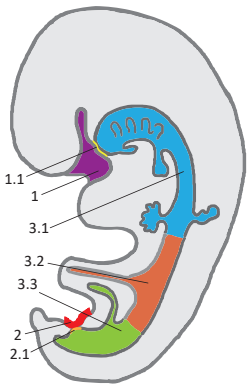

Embryonic digestive system

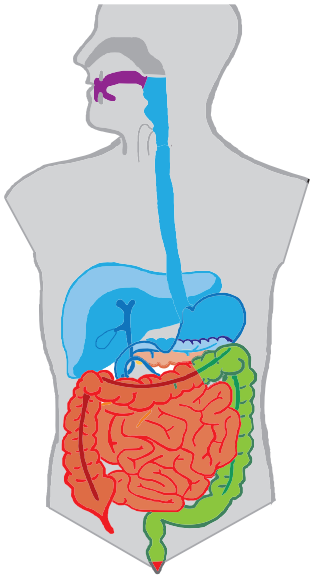
Adult digestive system

This copy belongs to ali yaghoubi

The **oral cavity** is bounded ventrally by the lips and laterally by the cheeks. The floor of the oral cavity is formed by the oral diaphragm and the roof by the palate. Dorsally, it is continuous through the isthmus of fauces with the pharynx. **The dental arches divide** the oral cavity into **the oral vestibule** ventral to the arches and **the oral cavity proper** dorsal to the arches.

Divisions and content

1 **Oral fissure** *(rima oris)* – the entrance to the oral cavity
2 **Isthmus of fauces / oropharyngeal isthmus** *(isthmus faucium)* – marks the transition from the oral cavity to the oral part of the pharynx

The dental arches divide the oral cavity into:

3 **Oral vestibule** *(vestibulum oris)* – ventral to the dental arches
- 3.1 **Cheek** *(bucca)* – contains the buccinator and the buccal fat pad
- 3.2 **Lips** *(labia oris)* – surround the oral fissure

4 **Oral cavity proper** *(cavitas oris propria)* – dorsal to the dental arches
- 4.1 **Teeth** *(dentes)*
- 4.2 **Gum** *(gingiva)*
- 4.3 **Tongue** *(lingua)*
- 4.4 **Hard palate** *(palatum durum)*
- 4.5 **Soft palate** *(palatum molle)*
- 4.6 **Palatine tonsil** *(tonsilla palatina)*
- 4.7 **Salivary glands** *(glandulae salivariae)*

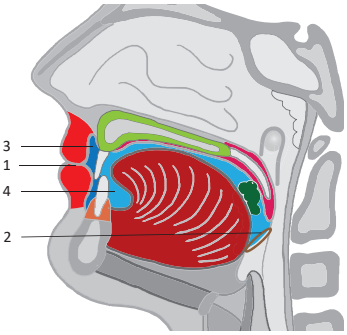

The sagittal section of the oral cavity

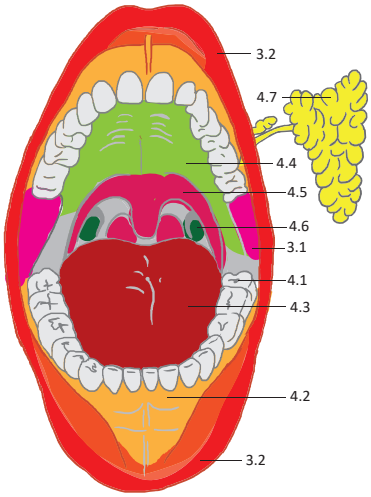

Open oral cavity

The oral diaphragm *(diaphragma oris)* is a muscular plate under the tongue, which caudally encloses the oral cavity. It consists of the mylohyoid, geniohyoid and anterior belly of the digastric.

The oral vestibule and oral cavity proper communicate between the posterior edge of the third molar and the anterior edge of the coronoid process of the mandible. It is possible to use this gap to place a feeding tube when the mandible is immobilised in the treatment of a fracture. Small gaps between the teeth *(tremata)* are other places where the oral cavity proper and oral vestibule communicate.

We distinguish on the lips:
Cutaneous part: keratinised stratified squamous epithelium.
Transitional part (vermilion zone): The skin here does not contain any pigment and so the capillaries in the papillae of the dermis shine through, imparting a red-colour.
Vermillion border: the border between the cutaneous and transitional parts.
Mucous part: non-keratinised stratified squamous epithelium.

Cheek layers page 531.

Clinical notes

Facial clefts are caused by incomplete fusion of the lips, maxilla and hard palate.
Cheiloschisis – cleft of the lip
Gnathoschisis – cleft of the maxilla
Palatoschisis – cleft of the hard palate
Cheilognathopalatoschisis – combined cleft of all the above mentioned structures.

Anaemia is a deficiency of haemoglobin in the blood. The transitional zone of the lips is pale in this condition.
Cyanosis is caused by lack of oxygen in the blood, which increases the concentration of reduced haemoglobin. The transitional zone of the lips becomes violet in this condition.

The danger triangle of the face *(trigonum mortis)* is an area richly supplied with blood, located between the angles of the mouth and root of the nose. Venous blood from this area drains into the intracranial venous sinuses, thus there is a risk of a pathological process spreading to the intracranial space from this area.

2.1 Cheek – Bucca

The shape of the cheek is formed by the **buccinator**. The **buccal fat pad** (Bichat's fat pad) is located under the subcutaneous connective tissue and together with the fat in the subcutaneous connective tissue gives the cheek its definitive appearance.

Borders

The cheeks are bordered by the zygomatic arch **cranially**,
the ramus of the mandible **caudally**,
the angle of the mouth and the nasolabial sulcus **ventrally**
and the posterior margin of the masseter **dorsally**.

Blood supply and innervation

Arterial supply: facial artery, transverse facial artery, buccal artery
Venous drainage: facial vein, transverse facial vein, deep facial vein
Lymphatic drainage: facial lymph nodes (on the outer surface of the buccinator), submandibular lymph nodes
Motor innervation: facial nerve (buccinator)
Sensory innervation: trigeminal nerve (skin)



The **lips** are two horizontal folds that surround the oral fissure and meet at the angle of the mouth. **The inner and outer sides of the lips are covered by different types epithelium**; there is a transitional zone between the two sides. The orbicularis oris forms the shape of the lips. The lower lip is attached to the paired mandibular processes. The upper lip is attached to the paired maxillary processes and the unpaired frontonasal process.

External structure

- 1 **Upper lip** (*labium superius*) – located between the oral fissure and lower margin of the nose, laterally bounded by the nasolabial sulcus
  - 1.1 **Frenulum of upper lip** *(frenulum labii superioris)* – attaches the upper lip to the gum from inside
  - 1.2 **Philtrum** – a sagitally oriented groove from the nasal septum to the upper lip
    – the margins of the philtrum are remnants of an adhesion of the three embryonic processes
  - 1.3 **Tubercle of upper lip** *(tuberculum labii superioris)* – tubercle on the lower end of the philtrum
- 2 **Lower lip** *(labium inferius)* – located between the oral fissure and the mentolabial sulcus
  - 2.1 **Frenulum of lower lip** *(frenulum labii inferioris)* – attaches the lower lip to the gum from inside
- 3 **Angle of mouth** *(angulus oris)* – a place of adhesion of the upper and lower lip
- 4 **Nasolabial sulcus** *(sulcus nasolabialis)* – a paired groove ongoing laterocaudally from the wing of the nose to the angle of the mouth
- 5 **Mentolabial sulcus** *(sulcus mentolabialis)* – an unpaired groove between the chin and lower lip

Blood supply

Arterial supply: superior and inferior labial artery (form anastomosis in the superior and inferior labial arch)
Venous drainage: facial vein
Lymphatic drainage: submandibular and submental lymph nodes

Innervation

Motor innervation: facial nerve (facial muscles of the lips)
Sensory innervation: maxillary nerve (upper lip), mandibular nerve (lower lip)

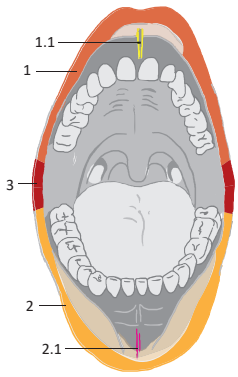

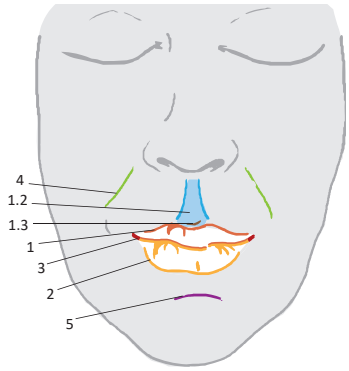

From the anatomical point of view, **the gum is a mucous membrane covering the alveolar processes of the maxilla and mandible**. From the clinical point of view the gum is divided into the **gum proper** and the **alveolar mucous membrane**. The gum proper is the mucosa located at the same level of the neck and crown of the tooth. It that does not contain any submucous connective tissue and is attached directly to the periosteum. It is thus known and as the mucoperisteum and is immobile. The alveolar mucosa covers the alveolar processes at the level of the root of the tooth. It contains submucosal connective tissue and is therefore mobile.

External structure

Alveolar gingiva / attached gum *(gingiva alveolaris)* – the gum attached to the alveolus (facing the oral cavity)
Marginal gingiva / free gingival margin *(gingiva marginalis)* – the gum attached to the tooth, facing the tooth and enclosing the entrance to the periodontal space

- 1 **Gingival margin** *(margo gingivalis)* – an elevated margin of the gum around the tooth
- 2 **Gingival sulcus** *(sulcus gingivalis)*
  – a groove between the margin of the gum and the tooth
  2.1 **Gingival recess** *(recessus gingivalis)* – a blind trunk of the gingival sulcus, which extends to the neck of the tooth
- 3 **Gingival papillae / interdental papillae** *(papillae gingivales)*
  – gingival projections between the necks of the teeth

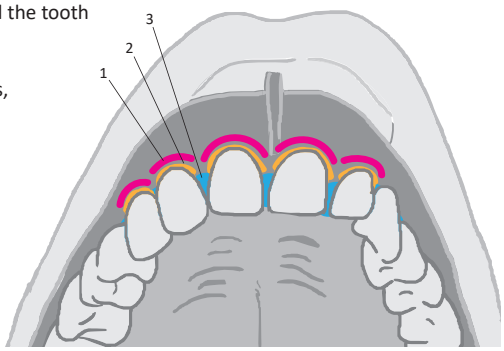

Blood supply and innervation

Arterial supply: superior alveolar arteries, inferior alveolar arteries
Venous drainage: pterygoid plexus, facial vein, lingual vein
Lymphatic drainage: submandibular lymph nodes
Mixed innervation: superior dental plexus (maxillary nerve), inferior dental plexus (mandibular nerve)

This copy belongs to ali yaghoubi

The **teeth** are held in the dental alveoli by a specific type of joint called a **gomphosis**. They are arranged in two arches: **the maxillary and mandibular arcades**. Eruption of **deciduous teeth** begins in the 6th month of life and ends in the 24th month. There are 20 deciduous teeth in total. Eruption of **permanent teeth** begins in the 6th year and is usually complete by the 30th year. There are 32 permanent teeth in total. The main function of the teeth is **mechanical digestion**. However they also take part in voice production and maintenance of the proper position of the temporomandibular joint.

External structures

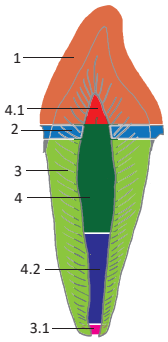

- 1 **Crown of tooth** *(corona dentis)*
  – the visible part of the tooth, covered by enamel
- 2 **Neck of tooth** *(cervix dentis)*
  – the transition between the crown and root, covered by the gum
- 3 **Root of tooth** *(radix dentis)* – is placed in the dental alveolus of the jaw
  - 3.1 **Root apex** *(apex radicis dentis)* – contains an opening (*foramen apicis radicis dentis*) where vessels and nerves enter the tooth
- 4 **Pulp cavity** *(cavitas dentis)* – contains the dental pulp *(pulpa dentis)*, which is connective tissue that has a rich neurovascular supply
  - 4.1 **Pulp cavity of crown** *(cavitas coronae)*
    – a widening of the pulp cavity within the crown of the tooth
  - 4.2 **Root canal** *(canalis radicis dentis)*
    – a narrowing of the pulp cavity within the root apex

Directions and surfaces on the dental crown

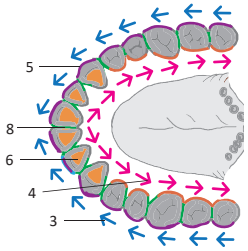

Directions

- 1 **Cervical** – towards the neck of the tooth
- 2 **Apical** – towards the root of the tooth
- 3 **Mesial** – towards the anterior midline of the dental arcade
- 4 **Distal** – towards the posterior teeth

Surfaces

- 5 **Vestibular surface** *(facies vestibularis)* – faces the oral vestibule
  - 5.1 **Labial surface** *(facies labialis)* – faces the lips (the anterior teeth)
  - 5.2 **Vestibular surface** *(facies vestibularis)* – faces the cheeks (the posterior teeth)
- 6 **Lingual surface** *(facies lingualis)* – faces the tongue (the lower teeth)
- 7 **Palatal surface** *(facies palatinalis)* – faces the palate (the upper teeth)
- 8 **Approximal surface** *(facies approximalis)* – faces the neighboring tooth
- 9 **Occlusal surface** *(facies occlusalis)*
  – the chewing surface at the top of the crown

Histology

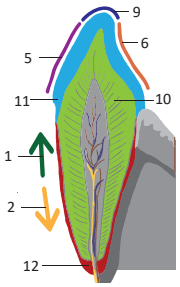

- 10 **Dentine** *(dentinum)* – makes up the basic substance of the tooth
- 11 **Enamel** *(enamelum)* – covers the dentin of the crown
- 12 **Cement** *(cementum)* – covers the neck and root of the tooth

Fixation of the teeth in the jaw

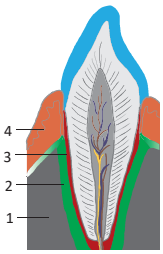

Parodontium – a complex of structures that supports the teeth

- 1 **Dental alveolus** (*alveolus dentalis*) – a fossa for the tooth that is made from compact bone
- 2 **Periodontium** – the dentoalveolar connection, continues cranially into the connective tissue of the gum
  - 2.1 **Gomphosis** (a type of syndesmosis) – a fibrous connection between the root of the tooth and the periosteum on the inner surface of the dental alveolus
- 3 **Cement** – a layer of fibrillar bone on the surface covering the root and neck of the tooth
- 4 **Gingiva / gum** – supports the teeth at the neck of the tooth

Dentogingival junction *(junctio dentogingivalis)*

– the gingiva covers the peridontium around the neck of the tooth
– a special junction between the gingival epithelium and the enamel and cement
– there is an infiltration of lymphocytes and plasmocytes in the connective tissue beneath the dentogingival junction, which forms an immunological barrier

Odus (genitive: odontos) is the greek term for tooth.

Dental articulation (gliding occlusion) is term for the mutual contact of the occlusal surfaces of the upper and lower teeth.

Neutrocclusion is a form of occlusion characterised by the upper teeth being located anterior to the lower teeth.
Crossbite is a form of occlusion when part of the lower dental arcade overlaps with the upper arcade.

The old system of the dental formula was based on the first letter of the Latin name of each tooth and its location in the dental arcade:
Deciduous teeth – i1, i2, m1, c, m2
Permanent teeth – M1, I1, I2, P1, C, P2, M2, M3.

A mnemonic for the sequence of permanent teeth eruption based on the old system of the dental formula is: "**M**ama **I**s **I**n **P**ain, **P**apa **C**an **M**ake **M**edicine".

The first molar (M1) is under the most pressure. **The third molars (M3)** erupt in adulthood and are also called wisdom teeth.

According to the knowledge of tooth eruption, it is possible to estimate the age of a child with a discrepancy of about half a year.

Contact surface of the tooth *(facies contactus)* is an obsolete term for the approximal surface of a tooth.

Clinical notes

The periodontal gap is a space richly innervated and supplied with blood, located between the tooth and alveolus where the periodontium is located.

The periapical space is a widening of the periodontal gap around the root apex. Inflammatory of teeth is most likely to occur here .

Occlusal abrasion is abrasion of the teeth caused by wearing out during life.

Gingival recession (receding gums) is a loss of gum tissue caudal to the crown of the tooth. It exposes the neck of the tooth.

A reduction of the alveolar processes is a decrease in height of the alveolar bones.

An orthopantomograph (OPG) is an X-ray image that clearly shows the facial part of the skull with the teeth in both dental arcades.

Dental arcades and types of teeth

- **Maxillary/upper dental arcade** *(arcus dentalis maxillaris/superior)* – is elliptical-shaped
  – is larger than the lower dental arcade, which it ventrally and laterally overlaps
- **Mandibular/lower dental arcade** *(arcus dentalis mandibularis/inferior)* – is parabolic-shaped
- **Articulation curve** – runs from the incisor through the molars to the temporomandibular joint
  – is produced by the masticatory muscles, which create a force directed towards the first molar
- 1, 2 **Incisor teeth** *(dentes incisivi)* **(I)** – contain one root and usually one root canal
  – there are two incisors in each quadrant, which are referred to by the numbers 1 and 2
- 3 **Canine teeth** *(dentes canini)* **(C)** – contain one root and usually one root canal
  – there is one canine in each quadrant, which is referred to by the number 3
- 4, 5 **Premolar teeth** *(dentes premolares)* **(P)** – contain one root and usually one root canal but the upper first premolar has two roots and two canals
  – there are two premolars in each quadrant, which are referred to by the numbers 4 and 5
- 6, 7, 8 **Molar teeth** *(dentes molares)* **(M)** – upper molars usually have three roots and four canals
  – lower molars usually have two roots and three canals
  – there are three molars in each quadrant, which are referred to by the numbers 6, 7, 8

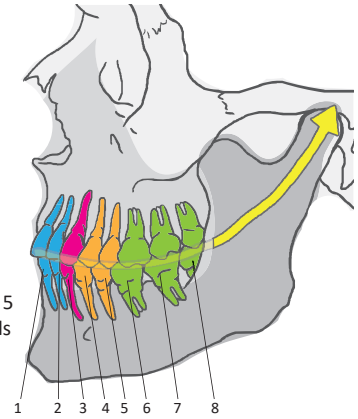

Dental formula

The teeth are divided into four quadrants seen in an open mouth.

- **Deciduous teeth** *(dentes decidui)*
  – 20 teeth divided into four quadrants, each containing 5 teeth
  (51–55, 61–65, 71–75, 81–85)
- **Permanent teeth** *(dentes permanentes)*
  – 32 teeth divided into four quadrants, each containing eight teeth
  (11–18, 21–28, 31–38, 41–48)

Quadrants are described in a clockwise direction from the right upper quadrant:
right upper quadrant → left upper quadrant
right lower quadrant ← left lower quadrant

55 54 53 52 51	**61 62 63 64 65**
85 84 83 82 81	**71 72 73 74 75**

Dental formula of the deciduous teeth

18 17 16 15 14 13 12 11	**21 22 23 24 25 26 27 28**
48 47 46 45 44 43 42 41	**31 32 33 34 35 36 37 38**

Dental formula of the permanent teeth

Tooth eruption

Eruption of the deciduous teeth

6th–8th month – **incisors** (i1), upper first, then lower
7th–12th month – **incisors** (i2), upper first, then lower
12th–16th month – **molars** (m1), lower first, then upper
15th–20th month – **canines** (c), lower first, then upper
20th–30th month – **molars** (m2), upper and lower together

Eruption of the permanent teeth

- 6th–8th year – **molars** (M1), usually lower first
- 6th–7th year – **incisors** (I1), usually lower first
- 7th–9th year – **incisors** (I2), usually lower first
- 9th–11th year – **premolars** (P1)
- 9th–14th year – **canines** (C)
- 11th–14th year – **premolars** (P2)
- 10th–15th year – **molars** (M2)
  17th–30th year – **molars** (M3)



Simplified panoramic dental X-ray image (OPG) of an 8.5-years-old boy

Blood supply and innervation

Artery supply:
– **the maxillary (upper) dental arcade**: dental branches *(rr. dentales)* from the posterior superior alveolar artery (maxillary artery) and from the anterior superior alveolar arteries (infraorbital artery from the maxillary artery)
– **the mandibular (lower) dental arcade**: dental braches *(rr. dentales)* from the inferior alveolar artery (maxillary artery)
Venous drainage: to the pterygoid plexus and further to the maxillary veins (to the retromandibular vein)
Lymphatic drainage: submandibular lymph nodes, deep cervical lymph nodes
Somatosensory:
– **the maxillary (upper) dental arcade**: dental branches *(rr. dentales)* from the superior dental plexus (anterior, middle and posterior superior alveolar branches from the infraorbital nerve from the maxillary nerve)
– **the mandibular (lower) arcade**: dental branches *(rr. dentales)* from the inferior dental plexus (inferior alveolar nerve from the mandibular nerve)

This copy belongs to ali yaghoubi

The tongue is a muscular organ, covered by mucosa and located in the oral cavity. The muscles of the tongue are divided into two groups: the intrinsic and extrinsic muscles. **The intrinsic muscles** are entirely located within the tongue itself and function to **change the shape of the tongue**. **The extrinsic muscles** attach to the tongue from the surrounding structures and function to **change the position of the tongue**. The tongue helps to **mechanically break down food**, participates in both **articulation** and **phonation** and, by means of its taste buds, in **taste perception**.

Parts and surfaces of the tongue

Parts

- 1 **Apex/tip of tongue** *(apex linguae)*
  – the most ventral part of the tongue
- 2 **Body of tongue** *(corpus linguae)*
  – the ventral 2/3 of the tongue
- 3 **Root of tongue** *(radix linguae)*
  – the dorsal 1/3 of the tongue

Surfaces

4 **Dorsum of tongue** *(dorsum linguae)*
– faces the roof of the oral cavity

- 5 **Margin of tongue** *(margo linguae)* – faces the teeth

6 **Inferior surface of tongue** *(facies inferior linguae)*
– faces the oral diaphragm

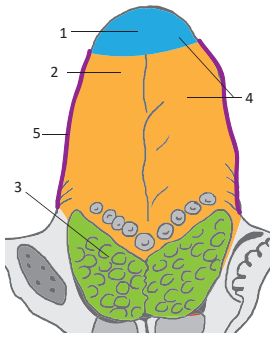

Structures on the dorsum and root of the tongue

Structures on the dorsum of the tongue

- 1 **Terminal sulcus of tongue** *(sulcus terminalis linguae)*
  – a "V" shaped groove with a dorsally pointing vertex
  – bordered ventrally by the 8–12 vallate papillae
  – forms the border between the body and the root of the tongue
- 2 **Foramen caecum of the tongue** *(foramen caecum linguae)*
  – a small depression at the vertex of the terminal sulcus
- 3 **Midline groove of tongue / median sulcus of tongue** *(sulcus medianus linguae)*
  – a groove in the median plane of the tongue
  – the superficial projection of the lingual septum

Structures on the root of the tongue

- 4 **Lingual tonsil** *(tonsilla lingualis)*
  – diffuse lymphoid tissue located in the submucosal connective tissue that forms bumps on the surface of the root of the tongue
- 5 **Median glosso-epiglottic fold** *(Plica glossoepiglottica mediana)*
  – a sagittal mucosal fold extending dorsally from the root of the tongue to the epiglottis
- 6 **Lateral glosso-epiglottic folds** *(plicae glossoepiglotticae laterales)*
  – two mucosal folds located lateral to the epiglottic valleculae
- 7 **Epiglottic valleculae** *(valleculae epiglotticae)*
  – two depressions between the lateral glosso-epiglottic folds and median glosso-epiglottic fold

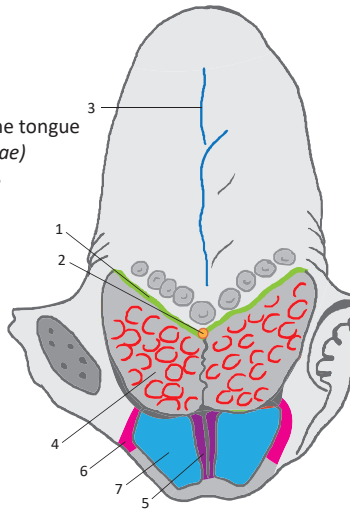

Structures on the inferior surface of the tongue

- 1 **Fimbriated fold** *(plica fimbriata)* – a paired dorsolateral fold
- 2 **Frenulum of tongue** *(frenulum linguae)*
  – a sagittal mucosal fold in the median plane connecting the inferior surface of the tongue with the floor of the oral cavity
- 3 **Sublingual caruncle** *(caruncula sublingualis)*
  – a paired tubercle lateral to the frenulum of the tongue where the submandibular and major sublingual ducts open
- 4 **Sublingual fold** *(plica sublingualis)* – a paired dorsolateral fold where the 8–30 minor sublingual ducts open

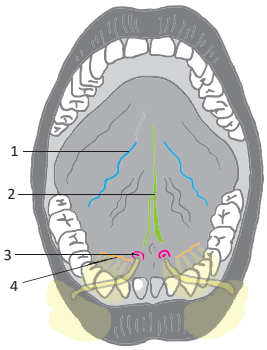

Glossa is the Greek term for tongue.

The mucosa of the tongue is covered by stratified squamous epithelium, which keratinises in some places and forms projections of various shapes called lingual papillae.

The vallate papillae *(papillae vallatae)* are the largest lingual papillae and are located ventral to the terminal sulcus of the tongue. Taste buds are located in the epithelium around the vallate papillae (as well as in various other parts of the oral cavity). Other lingual papillae include the filiform, fungiform and foliate papillae. The foliate papillae are rudimentary leaf-like papillae on the margin of the tongue.

The foramen caecum of the tongue is a remnant of the thyroglossal duct. The thyroglossal duct is a canal formed by the descent of the thyroid during development.

The lingual septum fades out basally and changes into a sagittally oriented space filled with loose connective tissue called the middle space of the tongue *(spatium medianum linguae)*, which extends caudally to the mylohyoids, ventrally to the mental spines of the mandible and dorsally to the hyoid bone.

The palatoglossus
– functionally belongs to the muscles of the tongue
– developmentally belongs to the muscles of the soft palate
– innervation: vagus nerve

The paralingual canal is a slit between the hyoglossus and genioglossus, where the lingual artery and vein pass.

Clinical notes

When performing first aid, the tongue must be prevented from falling backwards and blocking the airways. This is done by moving the mandible forward (as the tongue is attached to the mandible by the genioglossus). The same effect can be achieved by bending the head backwards, which causes the root of tongue to move out of the laryngeal part of the pharynx.

The manoeuvre of Esmarch is performed by simultaneously bending the head backwards, moving the mandible forwards and opening the mouth.

Ankyloglossia (tongue-tie) is a congenital abnormality of the tongue characterised by a short and tough frenulum. This condition impedes the ability to suckle and later to speak.

Muscles of the tongue *(musculi linguae)*

All muscles of the tongue (intrinsic and extrinsic tongue muscles) attach to the lingual aponeurosis or the lingual septum.

- 1 **Lingual aponeurosis** *(aponeurosis linguae)* – a fibrous disc beneath the mucosa of the dorsum of the tongue
- 2 **Lingual septum** *(septum linguae)* – an incomplete sagittal fibrous partition perpendicular to the lingual aponeurosis

Intrinsic (intraglossal) muscles

The intrinsic muscles of the tongue change the tongue's shape. The muscle fibres are interlaced and do not contain any fasciae.

- 3 **Superior longitudinal muscle** *(musculus longitudinalis superior)* – shortens the length of the tongue and arches the dorsum of tongue
  – runs sagitally beneath the lingual aponeurosis to which it is connected
- 4 **Inferior longitudinal muscle** *(musculus longitudinalis inferior)* – shortens the tongue
  – runs sagitally above the genioglossus
  – its fibres interlace with the genioglossus and hyoglossus
- 5 **Transverse muscle** *(musculus transversus)* – narrows and extends the tongue
  – runs across the tongue from the sides through the lingual septum
- 6 **Vertical muscle** *(musculus verticalis)* – flattens, broadens and extends the tongue
  – runs between the dorsal and inferior surfaces of the tongue

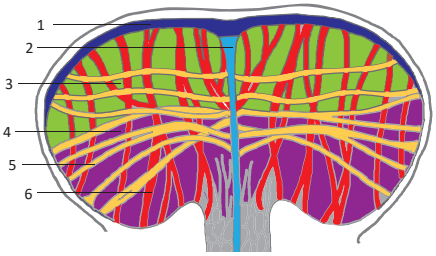

Frontal section of the tongue

Extrinsic (extraglossal) muscles

The extrinsic muscles of the tongue originate on the surrounding structures and insert on the fibrous lingual apparatus. They change the position of the tongue.

- 1 **Genioglossus** *(musculus genioglossus)*
  Origin: superior mental spine
  Insertion: lingual aponeurosis
  Function: protrusion and depression of the tongue and protects the tongue from falling backwards
- 2 **Hyoglossus** *(musculus hyoglossus)*
  Origin: the greater horn of the hyoid bone
  Insertion: lateral to the genioglossus
  Action: depression and retraction of the tongue
- 3 **Styloglossus** *(musculus styloglossus)*
  Origin: styloid process and stylomandibular ligament
  Insertion: the tip and sides of the tongue
  Function: retraction of the tongue and elevation of the body and apex of the tongue
- 4 **Palatoglossus** *(musculus palatoglossus)*
  Origin: the lateral margins of the palatine aponeurosis
  Course: within the palatoglossal arch (forms the anterior pillar of the fauces)
  Insertion: the root of the tongue
  Function: elevation of the root of the tongue and depression of the soft palate, thus the final action is to narrow the opening of the pharynx

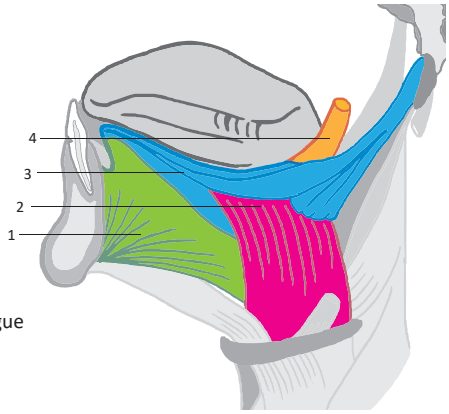

Sagittal section of the mandible and extrinsic muscles of the tongue, lateral view

Blood supply

Arterial supply: lingual artery (a branch of the external carotid artery)
Venous drainage: lingual vein, vena comitans of the hypoglossal nerve (to the internal jugular vein)
Lymphatic drainage: from the apex – submental lymph nodes, **from the margins** – submandibular lymph nodes, **from the body and root** – deep cervical lymph nodes, due to the incomplete septum of the tongue also to the contralateral nodes

Innervation

Motor innervation: hypoglossal nerve – all muscles except the palatoglossus (vagus nerve)
Somatosensory innervation:
lingual nerve (a branch of the mandibular nerve), glossopharyngeal nerve, vagus nerve
Sensory innervation – taste:

- **VII Chorda tympani** – provides taste on the apex and body of the tongue except the vallate papillae
  – a branch of the facial nerve, from the tongue fibers travel via the lingual nerve
- **IX Glossopharyngeal nerve** – provides taste on the root of the tongue and vallate papillae
- **X Vagus nerve** – provides taste on the epiglottic valleculae

Parasympathetic innervation (of the salivary glands):

- **VII Chorda tympani** – innervates the glands within the apex and body of the tongue
- **IX Glossopharyngeal nerve** – innervates the glands within the root of the tongue
- **X Vagus nerve** – innervates the glands within the epiglottic valleculae

Sympathetic innervation: via the periarterial plexus surrounding the lingual artery

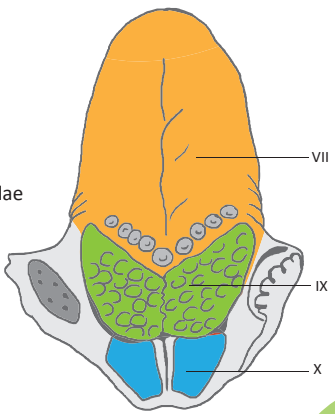

This copy belongs to ali yaghoubi

The palate is a horizontal partition separating the oral cavity from the nasal cavity. The ventral part is formed by the **bony hard palate**. The dorsal part is called the **soft palate** and formed by a fibromuscular plate. The palate is used during swallowing, phonation and articulation.

2.6.1 Hard palate – Palatum durum

The **hard palate** is a horizontal bony partition covered by mucosa and separating the oral cavity from the nasal cavity.

Components

1 **Incisive bone** *(premaxilla, os incisivum)* - unpaired
2 **Palatine process of maxilla** *(processus palatinus maxillae)*
3 **Horizontal plate of palatine bone** *(lamina horizontalis ossis palatini)*

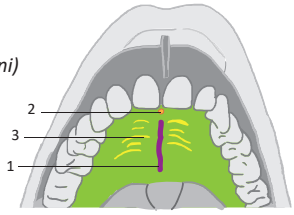

Structures

- 1 **Palatine raphe** *(raphe palati)*
  – a mucosal ridge running in the median plane
- 2 **Incisive papilla** *(papilla incisiva)* – elevated mucosa above the opening of the incisive canal on the ventral part of the palatine raphe
- 3 **Transverse palatine folds** *(palatine rugae, plicae palatinae transversae, rugae palatinae)*
  – low transverse mucous folds on the oral side of the palate

2.7 Palatine tonsil – Tonsilla palatina

The palatine tonsil is **an oval-shaped lymphoid organ** covered by mucosa and located in the tonsillar fossa/sinus (*fossa tonsillaris*) **between the palatoglossal and palatopharyngeal arches**. It is a part of the immunological barrier that prevents infection from spreading from the oral and nasal cavity. The surface of the tonsil is decorated by the tonsillar pits and crypts.

Syntopy

Medially: isthmus of fauces
Laterally (in layers):
1. Tonsillar capsule *(capsula tonsillae)* – a fibrous capsule that borders the lateral aspect of the tonsil
   – emits septa into the surrounding tissue
2. Peritonsillar space – a space filled with loose connective tissue
   – is continuous with the surrounding submucosal connective tissue
   – contains the venous tonsillar plexus and the external palatine vein
3. Superior constrictor of the pharynx *(musculus constrictor pharyngis superior)*
4. Parapharyngeal space *(spatium parapharyngeum)*

Cranially (structures):
1 Supratonsillar fossa *(fossa supratonsillaris)*
2 Semilunar fold (*plica semilunaris*)
3 Triangular fold (*plica triangularis*)

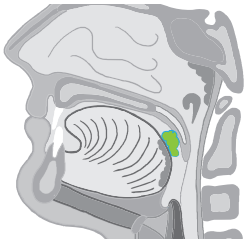

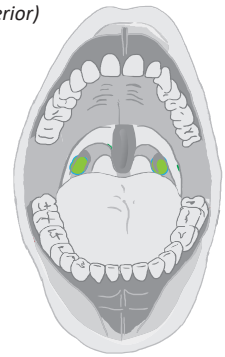

Blood supply and innervation

Arterial supply: ascending palatine artery, lesser palatine arteries, lingual artery ascending pharyngeal artery
Venous drainage: external palatine vein
Lymphatic drainage: into the deep cervical lymph nodes but mostly to the tonsillar lymph node (node of Wood) located behind the angle of the mandible
Sensory innervation: maxillary nerve, glossopharyngeal nerve

Velum is an obsolete term for the soft palate.

A mnemonic for the palatine muscles:
2 muscles are attached directly to the palate:
– tensor veli palatini and levator veli palatini
– complicated position, course and innervation
1 muscle is simple:
– musculus uvulae
2 muscles are in arches:
– palatoglossus and palatopharyngeus
– both run within the homonymous arches
– developmentally are classified as muscles of the pharynx
– functionally are classified as muscles of the tongue and pharynx
– both are elevators
– both are innervated by the vagus nerve

Clinical notes

During acute tonsillitis dead bacteria and denuded epithelial cells accumulate in the pits and crypts of the tonsil and a white exudate emerges on the surface. Swollen tonsils can narrow or even completely close the lumen of the pharynx, impairing swallowing or even causing asphyxiation. Inflammation of the palatine tonsils is also called angina tonsillaris.

Tonsillectomy is a surgical procedure to remove the tonsils from the peritonsillar space. In the loose connective tissue of this space, inflammation can arise and spread to the surrounding tissue. This condition can deteriorate to the point of a life-threatening cervical phlegmon and spread to the mediastinum.

A peritonsillar abscess is a bordered inflammatory focus in the peritonsillar space. It is a frequent complication of a bacterial inflammation of the palatine tonsil.

A paratonsillar abscess is a type peritonsillar abscesses. It is located in the peritonsillar space lateral to the tonsil and can extend into the parapharyngeal space.

The internal carotid artery runs close to the palatine tonsil in the parapharyngeal space. It can be damaged during a careless tonsillectomy as runs about 25 mm dorsal to the tonsil. Nevertheless, the most common structure prone to bleed during and after tonsillectomy is the paratonsillar vein (from the external palatine vein).

The soft palate is a fibromuscular plate that consists of the the palatine aponeurosis and the muscles that insert and originate on it. Two palatine arches extend laterocaudally from the soft palate: the palatoglossal arch and palatopharyngeal arch. They are formed by two homonymous muscles. The uvula protrudes caudally from the posterior part of the soft palate. The soft palate **participates in swallowing and prevents food from passing into the nasopharynx**.

Structures

- 1 **Uvula** (*uvula palatina*) – a caudally protruding part of the soft palate
- 2 **Palatoglossal arch / anterior pillar of fauces** (*arcus palatoglossus*)
  – an arched elevation between the palate and tongue, formed by the palatoglossus
- 3 **Palatopharyngeal arch / posterior pillar of fauces** (*arcus palatopharyngeus*)
  – an arched elevation between the palate and pharynx, formed by the palatopharyngeus

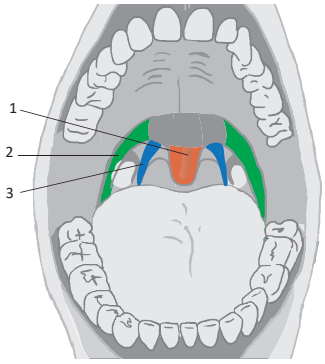

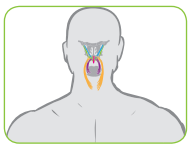

Position of the muscles of soft palate and fauces, posterior view

Muscles

- 1 **Tensor veli palatini** *(musculus tensor veli palatini)* – tenses the soft palate
  Origin: spine of sphenoid bone, scaphoid fossa of sphenoid bone, lateral side of the cartilaginous part of the auditory tube
  Course: descends laterally from the medial lamina of the pterygoid process of sphenoid bone, its inserting tendon turns medially around the pterygoid hamulus
  Insertion: palatine aponeurosis
  Innervation: mandibular nerve (branch of the trigeminal nerve)
  Function: tenses the soft palate and narrows the auditory tube by pressing its tendon on the wall of the auditory tube
- 2 **Levator veli palatini** *(musculus levator veli palatini)* – the levator of the soft palate
  Origin: apex of petrous part of temporal bone, medial wall of the cartilaginous part of auditory tube
  Course: descends medially from the medial lamina of the pterygoid process of the sphenoid bone
  Insertion: palatine aponeurosis
  Innervation: vagus nerve
  Function: elevates the soft palate
- 3 **Musculus uvulae**
  Origin: posterior nasal spine of palatine bone and palatine aponeurosis
  Insertion: connective tissue of the uvula, it protrudes into the pharynx (the fauces)
  Innervation: vagus nerve
  Action: shortens and elevates the uvula
- 4 **Palatoglossus** *(musculus palatoglossus)*
  Origin: the lateral margins of the palatine aponeurosis
  Course: within the palatoglossal arch
  Insertion: the root of the tongue
  Innervation: vagus nerve
  Function: elevation of the root of the tongue and depression of the soft palate, thus the final action is narrowing of the opening of the pharynx
- 5 **Palatopharyngeus** *(musculus palatopharyngeus)*
  Origin: palatine aponeurosis and medial lamina of pterygoid process of sphenoid bone, pterygoid hamulus and the inferior part of the auditory tube
  Course: within the palatopharyngeal arch
  Insertion: posterior margin of the thyroid cartilage and he wall of the pharynx
  Innervation: vagus nerve
  Action: elevation of the pharynx and depression of the soft palate, thus the final action is narrowing of the opening of the pharynx (the fauces)

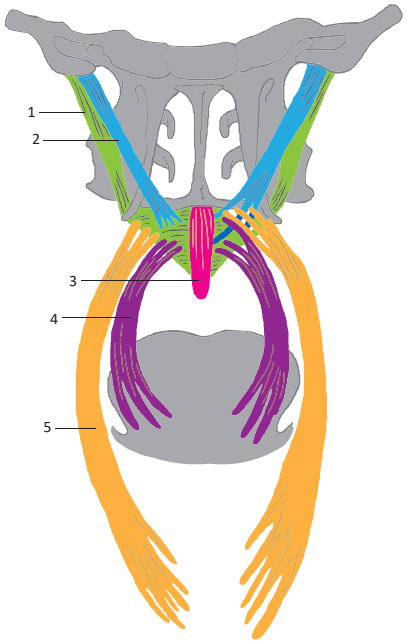

Posterior view of the muscles of the soft palate and fauces

Blood supply and innervation

Arterial supply: descending palatine artery, ascending palatine artery, ascending pharyngeal artery, lingual artery
Venous drainage: pterygoid plexus, pharyngeal veins

Motor innervation: vagus nerve, except for the tensor veli palatini muscle, which is innervated by the mandibular nerve
Somatosensory and parasympathetic innervation: greater palatine nerve, lesser palatine nerves, nasopalatine nerve (maxillary nerve – somatosensory, facial nerve – parasympathetic and taste)
Sympathetic innervation: pharyngeal plexus (glossopharyngeal nerve, vagus nerve)

This copy belongs to ali yaghoubi

The **salivary glands** are connected by their ducts to the oral cavity. They produce **saliva**, which has a serous and a mucous component. **The serous component** contains enzymes, which participate in the initial breakdown of food. **The mucous component** lubricates the ingested food and prepares it for swallowing. Saliva secretion is regulated by reflexes and **controlled directly by the autonomic nervous system**. The autonomic nervous system processes stimuli that lead to salivation, such as: smell, taste, visual stimuli and somatosensory stimuli, made by contact between food and the mucosa of the oral cavity.

Types of glands according to the type of saliva they produce

1 **Serous glands:** the parotid gland and the gustatory glands (von Ebner 's glands)
2 **Mucous glands:** glands of the root of the tongue (Weber's glands), the posterior part of the sublingual gland and the palatine glands
3 **Seromucous glands:** the submandibular gland, the anterior part of the sublingual gland, labial glands, buccal glands, molar glands and the anterior lingual glands

Types of glands according to their size

1 **Minor salivary glands** *(glandulae salivariae minores)* – the lesser glands
– scattered throughout the oral cavity, embedded in mucosa, submucosa and sometimes even in the muscular layer
– produce saliva continuously without neuronal stimuli
1.1 **Labial glands** *(glandulae labiales)* – glands of the lip
1.2 **Buccal glands** *(glandulae buccales)* – glands of the cheek
1.3 **Molar glands** *(glandulae molares)* – glands of the molar area
1.4 **Palatine glands** *(glandulae palatinae)* – glands of the palate
1.5 **Lingual glands** *(glandulae linguales)* – glands of the tongue

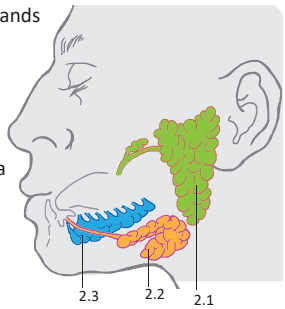

2 **Major salivary glands** *(glandulae salivariae majores)*
– open via ducts into the oral cavity
– produce saliva in response to neuronal stimuli
- 2.1 **Parotid gland** *(glandula parotidea)* – is located around the ramus of the mandible
- 2.2 **Submandibular gland** *(glandula submandibularis)* – is located beneath the mandible
- 2.3 **Sublingual gland** *(glandula sublingualis)*
– is located beneath the tongue and above the mylohyoid

Sublingual gland *(glandula sublingualis)*

The sublingual gland is located in the sublingual space.
The anterior part of the gland is seromucous. The posterior part is purely mucous.

Syntopy

Caudally: in contact with the upper surface of the mylohyoid
Cranially: forms a prominence in the oral cavity called the sublingual fold
Laterally: in contact with the sublingual fovea of the mandible
Medially: in contact with the hyoglossus, geniohyoid, submandibular duct and lingual nerve

Ducts

- 1 **Major sublingual duct / duct of Bartholin** *(ductus sublingualis major)*
– leaves the anterior seromucous part of the gland
– its opening is located on the sublingual caruncle with the opening of the submandibular duct
- 2 **Minor sublingual ducts** *(ductus sublinguales minores)*
– 8–20 ducts that leave from the posterior part of the gland
– are located on each side of the gland and open on the sublingual fold

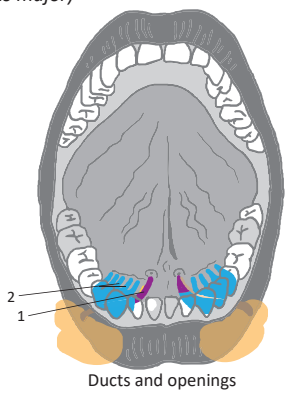

Ducts and openings of the sublingual glands

Blood supply and innervation:

Arterial supply: facial artery, lingual artery
Venous drainage: facial vein, lingual vein
Lymphatic drainage: submandibular lymph nodes
Parasympathetic innervation: glandular branches from the submandibular ganglion (fibres from the facial nerve via the chorda tympani)
Sympathetic innervation: periarterial plexus
Viscerosensory innervation: lingual nerve (from the mandibular nerve)

Von Ebner's glands (gustatory glands) are serous glands that wash out the grooves around the vallate papillae where taste buds are located.

Weber's glands (glands of the root of the tongue) are mucous glands. They protect the root of the tongue.

The retromandibular fossa is located between the lateral margin of the ramus of the mandible, external acoustic meatus, posterior belly of the digastric, styloid process, styloid septum and pterygoids.

Relation of the parotid gland to nerves in its proximity:
The facial nerve enters the gland after passing through the stylomastoid foramen. Within the gland it ramifies forming the intraparotid plexus, which divides the gland into superficial and deep parts.

The auriculotemporal nerve passes behind the parotid gland to reach the temporal region.

Division of the parotid gland by the intraparotid plexus (branches of the facial nerve) into the superficial and deep part does not match exactly the morphological division into the pars superficialis and pars profunda.

Parasympathetic fibres that supply the parotid gland originate in the inferior salivary nucleus. They travel in the tympanic branch of the glossopharyngeal nerve to the middle ear before leaving the skull as the lesser petrosal nerve. They synapse in the otic ganglion and reach the parotid gland through the parotid branches of the auriculotemporal nerve.

The salivary glands produce 1 to 1,5 liters of saliva daily. Saliva is important for hygiene of the oral cavity, lubricating food and in preventing the formation of dental calculus.

Clinical notes

Sialolithiasis refers to the presence of stones in the salivary ducts. This occurs most frequently in the submandibular duct due to its upward course.

Sialoadenitis is inflammation of the salivary gland. This can occur as a consequence of sialolithiasis.

Epidemic parotitis (mumps) is an acute viral inflammation of the parotid gland. Its clinical symptoms are swelling and pain. The disease can be accompanied by inflammation of other glands such as the pancreas and gonads. Infection of the male gonads may result in sterility.

Submandibular gland *(glandula submandibularis)*

The submandibular gland is a seromucous gland in the submandibular space. It secretes predominantly serous saliva.

Syntopy

Dorsally: is separated from the parotid gland by the stylomandibular ligament
Laterally: faces the submandibular fovea of the mandible
Turns around the posterior margin of the mylohyoid and follows its duct to the sublingual space.
The surface of the gland is covered by the superficial layer of the cervical fascia.
Relationship to the surrounding structures:

1 **Superficial cervical ansa** – in contact with the gland through the superficial layer of the cervical fascia
2 **Hypoglossal nerve** – in contact with the gland in the inferior pole of the submandibular triangle
3 **Facial artery and vein** – cross the gland vertically
– the facial vein is on the outer surface of the gland and the facial artery runs medially to the gland

Course of the submandibular/Wharton's duct *(ductus submandibularis)*

- 1 **emerges from the posterior part of the gland**
- 2 **curves over the posterior margin of the mylohyoid** and runs between the mylohyoid and hyoglossus
- 3 continues **in the sublingual space** on the inner side of the sublingual gland, where it crosses the lingual nerve
- 4 opens on the sublingual caruncle with the major sublingual duct

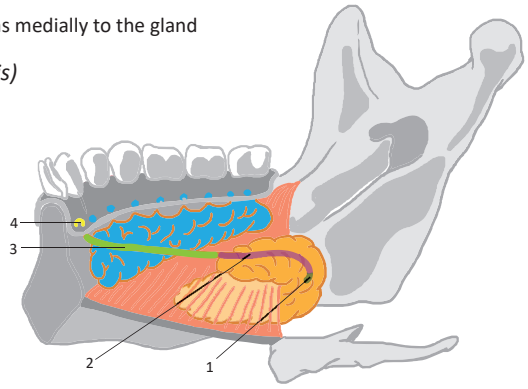

Sagittal section of the mandible with the sublingual and submandibular gland, viewed from the left

Blood supply and innervation:

Arterial supply: facial artery and lingual artery
Venous drainage: facial vein and lingual vein
Lymphatic drainage: submandibular lymph nodes
Parasympathetic innervation: lingual nerve via the submandibular ganglion (fibres from the facial nerve via the chorda tympani)
Sympathetic innervation: periarterial plexus
Viscerosensory innervation: lingual nerve (from the mandibular nerve)

Parotid gland *(glandula parotidea)*

The purely serous parotid gland is the largest salivary gland. It is located on the lateral surface of the head, ventral to the auricle.

Structure and syntopy

- 1 **Superficial part** *(pars superficialis)* – is medially in contact with the masseter
- 2 **Deep part** *(pars profunda)* – is located in the retromandibular fossa
- 3 **Isthmus** – the connection between the superficial and deep part – is located behind the ramus of the mandible
- 4 **Accessory parotid gland** *(glandula parotidea accessoria)* – a small accessory gland located above the parotid duct

Parotid duct / Stensen duct *(ductus parotideus)*

- 5 **Masseteric part** *(pars masseterica)* – runs ventrally on the surface of the masseter, about 1cm beneath the zygomatic arch
- 6 **Premasseteric part** *(pars premasseterica)* – courses on the anterior margin of the masseter and enters and the buccal fat pad
- 7 **Buccinatoric part** *(pars buccinatoria)* – opens into the oral vestibule on the parotid papilla just above the second upper molar

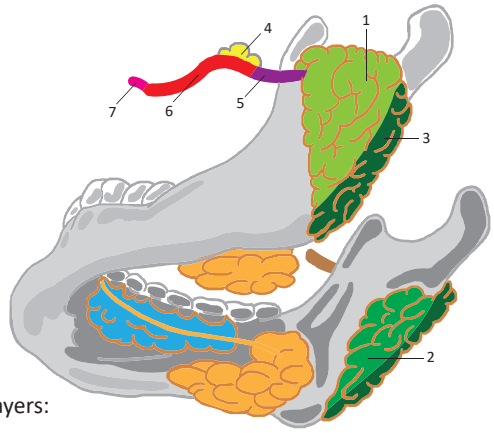

Mandible and major salivary glands, oblique left posterior view

Parotid fascia *(fascia parotidea)* – covers the gland and consists of three layers:

1 **Superficial layer** – part of the parotideomasseteric fascia, covers the masseter
2 **Deep layer** – separates the gland from the styloid septum and pterygoids
3 **Angular tract** *(tractus angularis)* – an oblique band at the angle of the mandible continues into the superficial layer of cervical fascia
– separates the gland from the submandibular space

Blood supply and innervation:

Arterial supply: superficial temporal artery, maxillary artery, posterior auricular artery, transverse facial artery
Venous drainage: parotid veins (retromandibular vein)
Lymphatic drainage: superficial and deep cervical lymph nodes and parotid lymph nodes
Parasympathetic innervation: auriculotemporal nerve (a branch of the mandibular nerve), carries parasympathetic fibres from the glossopharyngeal nerve
Sympathetic innervation: periarterial plexus
Viscerosensory innervation: auriculotemporal nerve (from the mandibular nerve)

This copy belongs to ali yaghoubi

The pharynx is a funnel-shaped muscular organ **located under the base of the skull**. It gets narrow in the craniocaudal direction and is continuous with the oesophagus at the level of vertebra C6. It **communicates ventrally with the nasal, oral and laryngeal cavity**. The oropharynx and laryngopharynx are **part of the digestive and respiratory systems**. The function of the pharynx is provided by two kinds of muscles: **constrictors and levators**. The pharynx plays a role in **swallowing, talking and breathing**.

Parts

- 1 **Nasopharynx** *(pars nasalis pharyngis)* – opens into the nasal cavity through the choanae
- 2 **Oropharynx** (*pars oralis pharyngis*) – opens into the oral cavity through the isthmus of fauces
- 3 **Laryngopharynx** *(pars laryngea pharyngis)* – opens into the larynx through the laryngeal inlet

Syntopy

- 4 **Cranially:** cranial base
- 5 **Caudally:** continues as the oesophagus at the level of vertebra C6
- 6 **Ventrally:** opens into the oral, nasal and laryngeal cavities
- 7 **Dorsally:** the cervical part of the vertebral column
- 8 **Laterally:** cervical neurovascular bundle and the lobes of the thyroid gland

Topographical spaces

The space around the pharynx is limited by connective tissue membranes attached to the pharyngeal adventitia.

- 1 **Parapharyngeal space** *(spatium parapharyngeum)*
  - 1.1 **Prestyloid space** *(spatium prestyloideum)*
  - 1.2 **Retrostyloid space** *(spatium retrostyloideum)*
- 2 **Retropharyngeal space** *(spatium retropharyngeum)*

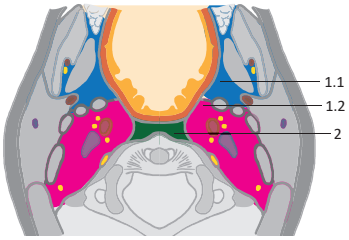

Transverse section of the neck at the level of C1

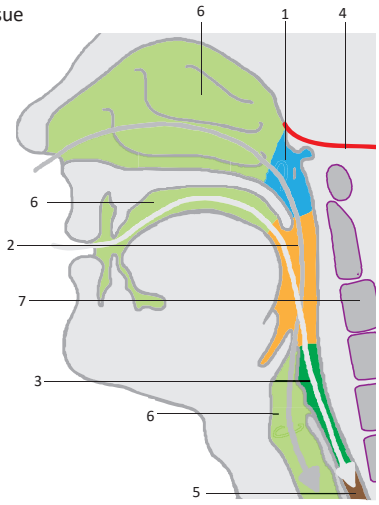

Sagittal section of the head and neck

Blood supply

Arterial supply: superior thyroid artery, lingual artery and ascending pharyngeal artery (from the external carotid artery), ascending palatine artery (from the facial artery), descending palatine artery and the artery of the pterygoid canal (from maxillary artery)

Venous drainage: pharyngeal venous plexus to the pharyngeal veins (to the internal jugular vein)

Lymphatic drainage: retropharyngeal lymph nodes (to the deep cervical lymph nodes)

Innervation

Pharyngeal plexus – a mixed network of fibres from the glossopharyngeal and vagus nerves and fibres from the superior cervical ganglion of the sympathetic trunk

Visceromotor nerves: vagus nerve
(except the stylopharyngeus, which is innervated by the glossopharyngeal nerve)

Viscerosensory nerves:
Nasopharynx – ventrally: maxillary nerve (from trigeminal nerve), dorsally: glossopharyngeal nerve
Oropharynx – glossopharyngeal nerve and vagus nerve
Laryngopharynx – vagus nerve

Sympathetic system: laryngopharyngeal nerves (from the sympathetic trunk)

Parasympathetic system: facial nerve (nasopharynx) and vagus nerve (oropharynx and laryngopharynx)

The auditory tube / pharyngotympanic tube / Eustachian tube *(tuba auditiva, tuba pharyngotympanica, salpinx)* is a tube connecting the nasopharynx to the middle ear. It serves to equilibrate air pressure in the middle ear.

The pharyngeal tonsil is also called the adenoid.

The pharyngeal bursa *(bursa pharyngealis)* is an inconstantly present small pit located dorsal to the pharyngeal tonsil. It a remnant of the embryonic notochord, which becomes enclosed within the pharyngeal wall. This is the first place for lymphatic tissue of the pharynx to appear and can be a place of inflammation.

The pharyngeal hypophysis *(hypophysis pharyngealis)* is a variably present mass of cells located ventral to the pharyngeal bursa. It is a remnant of the embryonic precursor of the adenohypophysis (the pouch of Rathke).

The space of Luschka is a semilunar space around the pharyngobasilar fascia where the pharyngeal wall lacks a muscular layer.

In newborn and infants, the larynx is located more cranially so that the epiglottis overlies the uvula and totally separates the digestive and respiratory systems, enabling concomitant swallowing and breathing.

Lateral bands are regions of lymphoid tissue in the lateral walls of the pharynx.

The pharyngeal recess / fossa of Rosenmüller *(recessus pharyngeus)* is a recess behind the torus tubarius.

Rouviere's lymph node is the most superior retropharyngeal lymph node located below the base of the skull.

Clinical notes

Adenotomy is a surgical removal of the pharyngeal tonsil (adenoid).

A retropharyngeal abscess is a deep circumscribed infection in the neck. This usualy results from ascending lymphadenitis after an infection of the upper airways.

The sinus of Morgagni is a weakening in the pharyngeal wall where the auditory tube opens into the pharyngeal cavity. Pathologic processes can spread to the parapharyngeal space and to the base of the skull.

Nasopharynx *(epipharynx, pars nasalis pharyngis)*

Borders

Cranially: cranial base
Caudally: posterior margin of the soft palate
Ventrally: nasal cavity (through choanae)

Insertion of the pharynx on the base of the skull

– the pharynx is inserted on the base of the skull by the pharyngobasilar fascia *(fascia pharyngobasilaris)*, a thickening of the submucous connective tissue
– at the level of the pharyngeal insertion on the base of the skull, the pharyngeal wall consists only of connective tissue (pharyngobasilar fascia) without a muscular layer

- **Detail of the insertion:**
- 1. from the **pharyngeal tubercle of the occipital bone**
- 2. further laterally and ventrally to the insertions of the **longus capitis** and **rectus capitis anterior**
- 3. crosses over the **petro-occipital fissure**
- 4. ventrally to the **external opening of the carotid canal**
- 5. directs towards the **medial plate of the pterygoid process of the sphenoidal bone** crossing over on its way the sphenopetrosal fissure

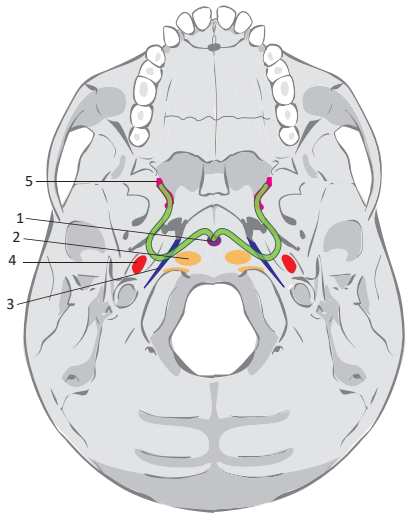

Insertion of the pharynx on the base of the skull

Structures

- 1 **Pharyngeal fornix** *(fornix pharyngis)*
  – a ventrally opened concave arch that is inserted on the base of the skull
- 2 **Pharyngeal tonsil** / nasopharyngeal tonsil (*tonsilla pharyngealis*)
  – a mass of lymphoid tissue in the roof of the nasopharynx
- 3 **Pharyngeal orifice of auditory tube** *(ostium pharyngeum tubae auditivae)*
  – the opening of the auditory tube on the lateral wall of the nasopharynx
- 4 **Torus tubarius** – a mucosal elevation located dorsal to the pharyngeal orifice of the auditory tube, formed by the medial plate of the cartilaginous part of the auditory tube
- 5 **Salpingopharyngeal fold** *(plica salpingopharyngea)* – a mucosal fold descending caudally from the torus tubarius, formed by the salpingopharyngeus
- 6 **Salpingopalatine fold** *(plica salpingopalatina)* – a mucous fold descending ventrocaudally to the soft palate, elevated by homonymous muscle fibres

7 **Torus levatorius** – a mucosal bulge between the salpingopharyngeal and salpingopalatine folds under the pharyngeal orifice of the auditory tube, formed by the levator veli palatini

8 **Tubal tonsil** *(tonsilla tubaria)* – an accumulation of mucosal lymphoid tissue around the pharyngeal orifice of the auditory tube

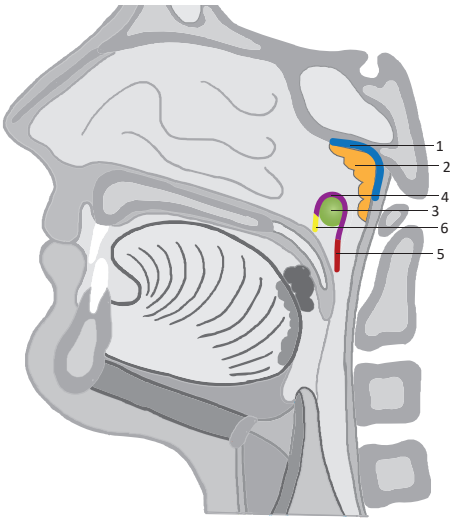

Sagittal section of the head and neck

Oropharynx *(pars oralis pharyngis)*

Cranially: the level of the posterior margin of the soft palate (C2 level)
Caudally: the superior margin of the epiglottis (C4 level)
Ventrally: oral cavity (through isthmus of the fauces)

Laryngopharynx (*hypopharynx, pars laryngea pharyngis*)

Cranially: the superior margin of the epiglottis (C4 level)
Caudally: continuous with the oesophagus (C6 level), through the pharyngo-oesophageal constriction
Ventrally: laryngeal cavity (through the laryngeal inlet)

Pharyngeal lymphoid ring (*anulus lymphoideus pharyngis*)

Pharyngeal lymphoid ring / Waldeyer's ring of lymphoid tissue:
The interconnected lymphoid tissue of the pharyngeal mucosa plays an important role in the early recognition of microorganisms entering the upper parts of the digestive and respiratory systems and in the initiation of an immune response. The lymphoid ring is connected caudally to the laryngeal lymphoid tissue. Bands of lymphoid tissue connect neighboring tonsils. Components of the lymphoid ring:

- 1 **Pharyngeal tonsil** – single
- 2 **Tubar tonsil** – paired
- 3 **Palatine tonsil** – paired
- 4 **Lingual tonsil** – single

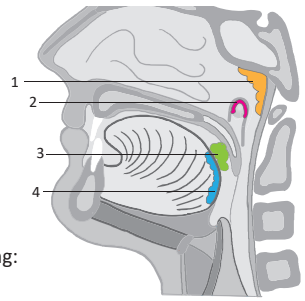

Sagittal section of the head and neck

This copy belongs to ali yaghoubi

Pharyngeal constrictors *(musculi constrictores pharyngis)*

The fibres of the pharyneal constrictors have a **circular course** and **overlap each other in a craniocaudal direction**.
They originate on the base of the skull and its neighboring structures and insert into the pharyngeal raphe.

- 7 **Pharyngeal raphe** (*raphe pharyngis*) – a band of connective tissue in the posterior wall of the pharynx, where the pharyngeal constrictors are inserted

- 1 **Superior constrictor** *(musculus constrictor pharyngis superior)*
  – originates on the base of the skull and its neighboring structures
  - 1.1 **Pterygopharyngeal part** *(pars pterygopharyngea)*
    – originates on the medial lamina of the pterygoid process of the sphenoid
  - 1.2 **Buccopharyngeal part** *(pars buccopharyngea)*
    – originates on the pterygomandibular raphe
  - 1.3 **Mylopharyngeal part** *(pars mylopharyngea)*
    – originates on the mylohyoid line of the mandible
  - 1.4 **Glossopharyngeal part** *(pars glossopharyngea)*
    – originates on the transverse muscle of the tongue

- 2 **Middle constrictor** *(musculus constrictor pharyngis medius)*
  – originates on the hyoid bone
  - 2.1 **Chondropharyngeal part** *(pars chondropharyngea)*
    – originates on the lesser horn of the hyoid bone
  - 2.2 **Ceratopharyngeal part** *(pars ceratopharyngea)*
    – originates on the greater horn of the hyoid bone

- 3 **Inferior constrictor** *(musculus constrictor pharyngis inferior)*
  – originates on the laryngeal cartilage
  - 3.1 **Thyropharyngeal part** *(pars thyropharyngea)*
    – originates on the thyroid cartilage
  - 3.2 **Cricopharyngeal part** *(pars cricopharyngea)*
    – originates on the cricoid cartilage

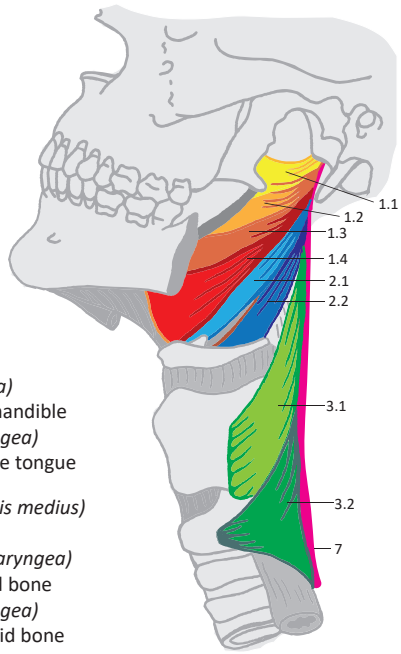

Pharyngeal constrictors, viewed from the left

Pharyngeal levators *(musculi levatores pharyngis)*

The levators have a longitudinal course and descend to the pharyngeal wall from either the outside or the inside of the pharynx. They originate on the base of the skull and its neighboring structures and insert into the pharyngeal muscular wall made by the pharyngeal constrictors.

- 4 **Stylopharyngeus** *(musculus stylopharyngeus)*
  – originates on the styloid process and inserts on the outer wall of the pharynx
  – runs through a cleft between the superior and middle constrictors
  – innervation: pharyngeal plexus (n. IX)

- 5 **Salpingopharyngeus** *(musculus salpingopharyngeus)*
  – originates on the medial margin of the cartilaginous part of the auditory tube and inserts on the inner wall of the pharynx
  – innervation: pharyngeal plexus

6 **Palatopharyngeus** *(musculus palatopharyngeus)*
– originates on the margin of the soft palate, runs in the palatopharyngeal arch and inserts on the inner wall of the pharynx
– innervation: pharyngeal plexus

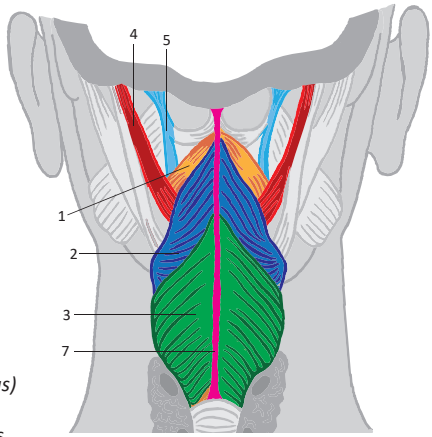

Pharyngeal constrictors and levators, posterior view

Oesophagus (or esophagus) is derived from Greek words for carrying *(oesein)* and eating *(phagein)*.

The gastro-oesophageal junction / ora serrata / Z-line is the junction between the oesophageal non-keratinised stratified squamous epithelium and the gastric simple columnar epithelium. During endoscopy, this junction is usually well visible.

The interstitial connective tissue between the oesophagus and the deep layer of cervical fascia continues cranially to the retropharyngeal space and caudally to the superior mediastinum. It allows movements of the oesophagus against the vertebral column. However, it also allows pathological processes (mainly infections) to spread towards the base of the skull (in the retropharyngeal space) and to the mediastinum.

Closure of the aboral oesophageal and cardiac orifice relies on the following anatomical structures:

1. **Lower oesophageal sphincter (LES)** – a thickened region of the smooth circular muscle layer between the thoracic and abdominal parts of the oesophagus
2. **Phreno-oesophageal membrane of Leimer**
3. **Crura of diaphragm**
4. **High pressure zone in the muscular layer in the cardia** (approximately 4 mm wide)
5. **Loop of Willis / collar of Helvitius**
6. **Angle of His and valve of Gubaroff**

Clinical notes

Oesophageal varices are a severe consequence of portal hypertension. The elevated portal vein pressure is transmitted to the veins in the submucosa of the cardia and lower part of the oesophagus. Blood stagnates in these veins, resulting in a dilated venous submucousal plexus in cardia and lower third of the oesophagus. There is a risk of the rupture and life threatening bleeding from oesophageal varices.

Metaplasia is a transformation of one type of epithelium to another.

Barrett's oesophagus refers to metaplasia of the normal non-keratinised stratified squamous epithelium lining the lower part of the oesophagus into simple columnar epithelium of the intestinal type. Barrett's oesophagus is caused by gastro-oesophageal reflux and can progress to dysplasia and eventually to oesophageal carcinoma (adenocarcinoma).

The oesophagus is an approximately 25 cm long muscular tube that connects the pharynx to the stomach. Several **curvatures** and **constrictions** are located along **its course through the neck and thorax to the abdominal cavity**. The muscular layer of the upper third of the oesophagus is composed of striated muscle fibres. The middle third is composed of both striated and smooth muscle fibres and the lower third is composed of smooth muscle fibres. Due to the long course of the oesophagus through several topographical regions, the blood supply is provided by multiple sources. The venous system of the oesophagus contains an important **portocaval anastomosis**, which can form varices in portal hypertension.

Parts of the oesophagus and its syntopy

- 1 **Cervical part** *(pars cervicalis)* – runs in the cervical visceral space from C6 to T2
  - **ventrally:** trachea
  - **dorsally:** the prevertebral layer of the cervical fascia and spinal cord
  - **laterally:** cervical neuro-vascular bundle
- 2 **Thoracic part** *(pars thoracica)* – passes through the posterior mediastinum from T2 to T10
  - **ventrally:** trachea, main left bronchus, and the heart (left atrium) enclosed in the pericardium
  - **laterally:** the vagus nerves run on the sides of the oesophagus
  - – running caudally, the right vagus nerve moves to its dorsal surface and the left vagus moves to its anterior surface
  - **on the right side:** the azygos vein crosses the right main bronchus and then opens into the superior vena cava
  - **on the left side:** the descending part of the aortic arch
  - **dorsally:** thoracic aorta and thoracic duct
- 3 **Abdominal part** (*pars abdominalis*) – runs within the peritoneal cavity from T10 to T11
  - – a 1–2 cm long portion located in the abdominal cavity after passing through the oesophageal hiatus of the diaphragm
  - **ventrally:** the oesophagus is in contact with the liver and creates the oesophageal impression on its dorsal surface
  - **dorsally:** diaphragm

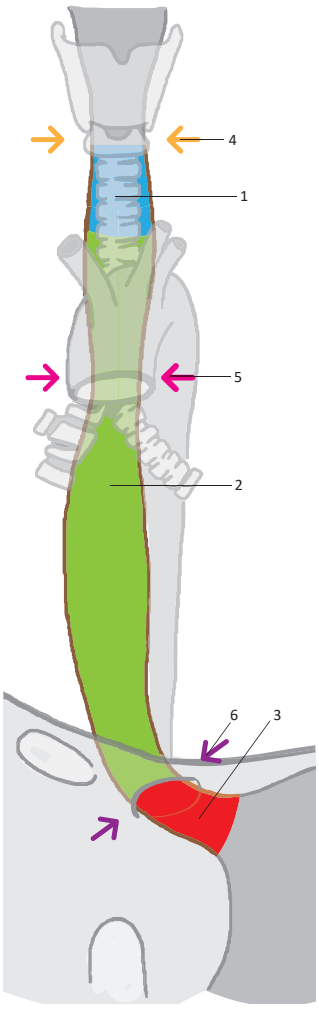

Parts and constrictions of the oesophagus

Curvatures

In the frontal plane
- – **the cervical part** is curved in the median plane
- – **the superior thoracic part** is curved to the left
- – **the middle thoracic part** is curved to the right
- – **the inferior thoracic part** is curved to the left and directs towards the oesophageal hiatus

In the sagittal plane
- – the oesophagus is **ventrally concave** in accordance with the kyphosis of the vertebral column

Constrictions

- 4 **Pharyngo-oesophageal constriction of Killian** *(constrictio pharyngooesophagealis)*
  - – the border between the pharynx and oesophagus at the level of C6
  - – is located between the cricoid cartilage and vertebral column
  - – during an endoscopic procedure, this point is about 15 cm from the patient's incisors
- 5 **Thoracic constriction** *(constrictio partis thoracicae, constrictio bronchoaortica)*
  - – is in contact with the aortic arch and the main left bronchus at the level of T4–5
  - – during an endoscopic procedure, this point is about 25 cm from the patient's incisors
- 6 **Diaphragmatic constriction** *(constrictio phrenica)*
  - – is located within the oesophageal hiatus at the level of T10–11
  - – during an endoscopic procedure, this point is about 40 cm from the patient's incisors

Blood supply and innervation

Arterial supply is segmental. The individual parts of the oesophagus are supplied from the nearest blood vessels: inferior thyroid artery, oesophageal branches of the aortic arch and thoracic aorta, posterior intercostal arteries, left gastric artery and left inferior phrenic artery.

Venous drainage occurs through two venous plexues located in the wall of the oesophagus: the deep (in the submucosa) and superficial (within the adventitia) plexuses. These plexuses anastomose with each other and form a connection between the riverbeds of the superior vena cava and the portal vein. Thus, they create a portocaval anastomosis. Blood from the oesophagus drains into:
- – **superior vena cava:** via the oesophageal veins into the azygos and hemi-azygos veins and also via the inferior thyroid veins
- – **portal vein:** the aboral part of the oesophagus via the gastric veins

Lymphatic drainage:
- – **cervical part:** deep cervical lymph nodes, **thoracic part:** tracheobronchial lymph nodes and posterior mediastinal lymph nodes, **abdominal part:** left gastric lymph nodes

Mixed innervation: oesophageal plexus (fibres of both vagus nerves and the cervical part of the sympathetic trunk)

This copy belongs to ali yaghoubi

The stomach is the widest part of the digestive tract. It is located in the **supramesocolic part of the peritoneal cavity** under the left vault of the diaphragm. It extends on the right to the epigastric region. The average volume is approximately one litre, but the capacity may be two to three litres. The shape of the stomach varies according to its content and the activity of its muscular wall. The arterial supply is provided by the **coeliac trunk**.

External structure

Parts of the stomach

- 1 **Fundus** – the cranial portion under the diaphragm
  - 1.1 **Cardial notch** *(incisura cardialis)* – a notch between the fundus and cardia
- 2 **Body of stomach** *(corpus gastricum)* – the largest part of the stomach
  - 2.1 **Cardia / cardial part** *(cardia / pars cardica)* – an area around the opening of the oesophagus
  - 2.2 **Cardial orifice** *(ostium cardiacum)* – the opening of the oesophagus into the stomach (at the level of T11)
  - 2.3 **Gastric canal** *(canalis gastricus)* – a cavity within the body of the stomach
- 3 **Pyloric part** *(pars pylorica)* – a horizontal or slightly ascending part of the stomach between the body and duodenum
  - 3.1 **Pyloric antrum** *(antrum pyloricum)* – is located between the gastric and pyloric canals at the level of the angular notch
  - 3.2 **Pyloric canal** *(canalis pyloricus)* – a 2–3 cm long part heading towards the pylorus
  - 3.3 **Pylorus** – the transition between the stomach and duodenum
  - 3.4 **Pyloric orifice** *(ostium pyloricum)* – a closable outlet of the stomach into the duodenum

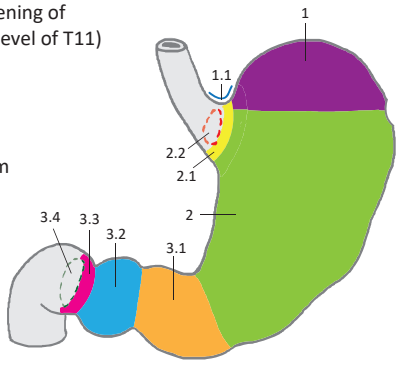

Parts of the stomach

Surfaces

- 4 **Anterior wall** *(paries anterior)* – faces the anterior abdominal wall, diaphragm and liver
- 5 **Posterior wall** *(paries posterior)* – faces the omental bursa

Curvatures

- 6 **Greater curvature** *(curvatura major)* – the left, long and convex curvature of the stomach
  - 6.1 **Great notch** *(incisura major)* – a notch within the greater curvature between the fundus and body of the stomach
- 7 **Lesser curvature** *(curvatura minor)* – the right, short and concave curvature of the stomach
  - 7.1 **Angular notch** *(incisura angularis)* – a small notch within the lesser curvature between the body of the stomach and the pyloric part

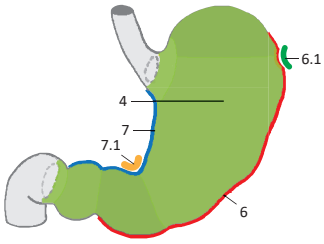

Surfaces and curvatures of the stomach

Syntopy

The anterior wall of the stomach is in contact with:

- 1 **Diaphragm** – diaphragmatic surface *(facies diaphragmatica)*
- 2 **Liver** – hepatic surface *(facies hepatica)*
- 3 **Anterior abdominal wall** – free surface *(facies libera)*

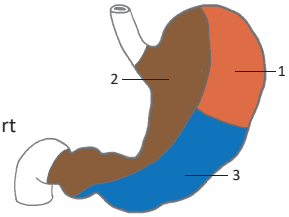

Syntopy of the anterior wall of the stomach

Posterior wall of the stomach faces the omental bursa and is in contact with the following structures listed belowm, through the parietal peritoneum:

- 1 **Diaphragm**
- 2 **Left kidney**
- 3 **Left suprarenal gland**
- 4 **Pancreas**
- 5 **Spleen**
- 6 **Transverse colon and mesocolon**

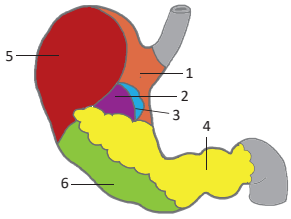

Syntopy of the posterior wall of the stomach

Stomachus is the Greek term for the stomach. **Ventriculus** is the obsolete Latin term for the stomach.

Functional division of the stomach:
Digestive part *(pars digestoria)* – includes the fundus and body of the stomach.
Evacuating part *(pars egestoria)* – includes the pyloric part of the stomach.

Gastric peristola is a resting phase of the stomach after being filled with food.
Peristaltic waves enable mixing and moving of the gastric content and creation of chyme.
Pyloric pump: peristaltic waves in the pyloric part enable the passage of chyme into the duodenum while the pyloric sphincter is relaxed.

Pepsin, gastrin, intrinsic factor of Castle (necessary for absorption of vitamin B12) and **hydrochloric acid** (HCl) are secreted in the stomach.

The parasympathetic nervous system facilitates peristalsis and secretion of HCl.
The sympathetic nervous system inhibits peristalsis and secretion of HCl. However, the pyloric sphincter contracts under influence of the sympathetic system.

Mnemonics:
Arteries with a short name (gastric arteries) course along the **lesser** curvature.
Arteries with a long name (gastroomental arteries) course along the **greater** curvature.

Clinical notes

Pyloric stenosis *(pylorostenosis)* is a congential hypertrophic stenosis of the pyloric sphincter that may clinically manifest as projectile vomiting.

Achalasia is a pathological motility disorder of the aboral part of the oesophagus. A lack of the myenteric ganglionic cells lead to absence of peristalsis and inability to relax the distal oesophageal sphincter.

The nodes of Virchow-Troisier are the left supraclavicular lymph nodes. Enlargement of these nodes can be one of the first symptoms of stomach cancer due to its connection with the thoracic duct.

Gastric ulcers are more likely to occur in areas of the stomach that have poor blood supply, such as where the anastomotic arterial arches are attached to the lesser and greater curvatures of the stomach.

Fixation

Peritoneal duplicatures (ligaments) extend from the serous coat of the stomach and course towards both curvatures.
Blood and lymph vessels, nerves and lymph nodes are positioned in the loose fibrous tissue between the sheets of peritoneum.

1 **Hepatogastric ligament** *(ligamentum hepatogastricum)* – extends from the lesser curvature to the liver
– part of the lesser omentum
2 **Gastrosplenic ligament** *(ligamentum gastrosplenicum)* – extends from the greater curvature to the spleen
3 **Gastrophrenic ligament** *(ligamentum gastrophrenicum)* – extends from the greater curvature to the diaphragm
4 **Gastrocolic ligament** *(ligamentum gastrocolicum)* – extends from the greater curvature to the transverse colon
– part of the greater omentum

Histology

1 **Mucosa** – contains simple columnar epithelium
- 1.1 **Gastric folds** *(plicae gastricae)* – predominantly longitudinally oriented mucosal folds
  – are mainly located along the curvatures
- 1.2 **Salivary sulcus of Waldeyer** *(sulcus salivarius)*
  – longitudinal folds along the lesser curvature
  – liquid food may pass through them on their way from the cardia to the pylorus
- 1.3 **Gastric pits** *(foveolae gastricae)* – gastric glands are located within the lamina propria and open into the gastric pits
- 1.4 **Gastric areas** *(areae gastricae)*
  – areas of mucosa between the gastric pits

2 **Submucosa** *(tela submucosa)*
3 **Muscular layer** *(tunica muscularis)*
– in addition to the usual circular and longitudinal layers, there is a third innermost obliquely oriented layer
- 3.1 **Oblique fibres** *(fibrae obliquae)* – the innermost layer
  – extend from the circular layer
  – course from the cardia to the greater curvature
  – their contraction assists in closure of the cardia
- 3.2 **Circular layer** *(stratum circulare)* – the widest middle circular layer
  - 3.2.1 **Pyloric sphincter** *(musculus sphincter pylori)*
    – smooth circular muscle enclosing the pylorus
- 3.3 **Longitudinal layer** *(stratum longitudinale)* – the outer longitudinal layer
  – continuation of closing process of the cardia oesophageal longitudinal muscle layer

4 **Serosa** *(tunica serosa)* – visceral peritoneum

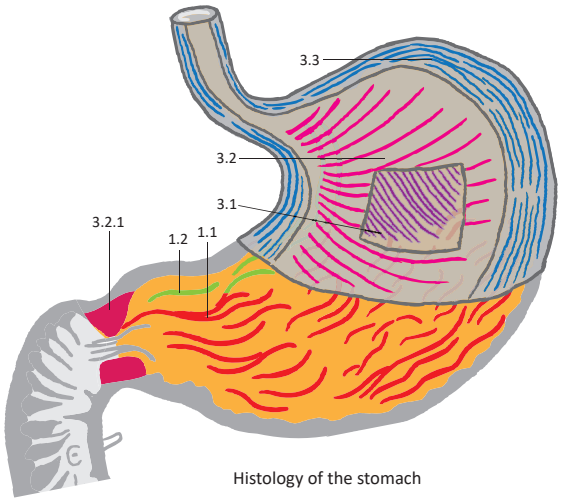

Histology of the stomach

Blood supply

Arterial supply: coeliac trunk
Anastomosis along the lesser curvature:
- 1 **Left gastric artery** (from the coeliac trunk)
- 2 **Right gastric artery** (usually from the hepatic artery proper)

Anastomosis along the greater curvature:
- 3 **Left gastro-omental** (gastro-epiploic) **artery** (from the splenic artery)
- 4 **Right gastro-omental** (gastro-epiploic) **artery** (from the gastroduodenal artery)

Other branches:
- 5 **Short gastric arteries** (from the splenic artery) – to the part of the fundus and body of the stomach
  6 **Pyloric artery** (from the hepatic artery proper) – to the anterior surface of the pylorus

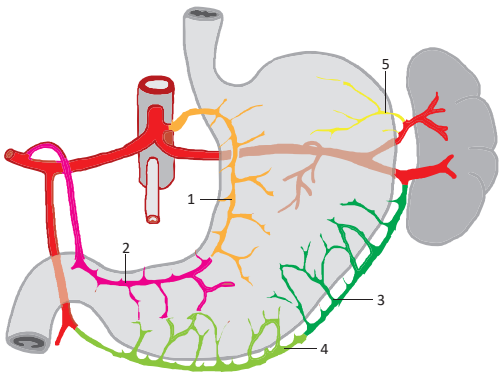

Blood supply of the stomach

Venous drainage: portal vein – left and right gastric vein, right and left gastro-omental (gastro-epiploic) vein, short gastric veins
– an important portocaval anastomosis is formed by connections with the oesophageal veins within the area of the cardia
– the ventral surface of the pylorus is drained by the prepyloric vein (either via the right gastric vein or directly to the portal vein)

Lymphatic drainage: coeliac lymph nodes (subsequently to the thoracic duct) and into the left supraclavicular lymph nodes (lymph nodes of Virchow-Troisier)
– **body of the stomach**: right and left gastric lymph nodes, right and left gastro-omental lymph nodes
– **fundus:** pancreaticosplenic lymph nodes, **pylorus:** pyloric lymph nodes

Innervation

Parasympathetic system: vagus nerves (anterior and posterior vagal trunk, anterior and posterior gastric branches)
Sympathetic system: splanchnic nerves (fibres of the coeliac plexus and via the periarterial plexuses enter the stomach wall)
Viscerosensory innervation: via the parasympathetic nerves (pressure, cold, heat) and sympathetic nerves (pain)

This copy belongs to ali yaghoubi

The small intestine is the longest part of the digestive system. It is approximately **3–5 m long** and its width is 2–4 cm. It is composed of **intestinal loops that fill the majority of the abdominal cavity**. The loops face the peritoneum of the anterior abdominal wall and are in contact with parts of the large intestine and other abdominal organs.

Parts

- 1 **Duodenum**
- 2 **Jejunum**
- 3 **Ileum**

Fixation

- 4 **Mesentery** *(mesenterium)*
  - a peritoneal duplicature suspending the jejunum and ileum
- 5 **Root of mesentery** (*radix mesenterii*)
  - the attachement of the mesentery to the posterior abdominal wall
  - extends from the duodenojejunal flexure to the right iliac fossa

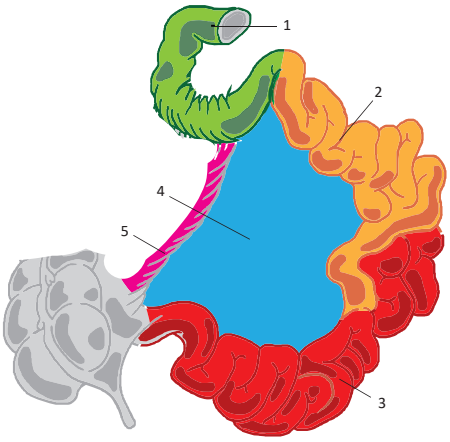

Histology

Mucosa is covered by simple columnar epithelium and together with the submucosa forms the macroscopically visible transverse circular folds of Kerckring (plicae circulares).
The muscular layer is composed of a longitudinal and a circular layer. The majority of the intestinal wall is covered by visceral peritoneum, excluding the duodenum, which is mainly retroperitoneal (except its ampulla), with its anterior surface covered by parietal peritoneum.

6.1 **Duodenum** – Duodenum

The duodenum originates at the pyloric orifice of the stomach and continues into the jejunum at the duodenojejunal flexure. It has the shape of a horseshoe. It is located at the level of L1–L3 and its length is about 25–30cm. The duodenum encircles vertebra L2 from the right side and **forms a space for the head of the pancreas**. The duodenum has four **main parts**, the majority of which are **secondarily retroperitoneal**. The bile duct and both pancreatic ducts open into the duodenum. The duodenal arterial supply is provided by two large trunks from the abdominal aorta: the coeliac trunk and the superior mesenteric artery.

Parts

- 1 **Superior part / D1** (*pars superior*) – is about 4–5 cm long
  - connects to the stomach and is located at the level of vertebra L1
- 2 **Descending part** / D2 *(pars descendens)*
  - is about 6–10 cm long
  - is vertically oriented and situated behind the peritoneum between the hilum of the right kidney and the right margin of L2
  - is secondarily retroperitoneal
- 3 **Inferior part / D3** *(pars inferior)*
  - is about 7–8 cm long
  - is horizontally oriented, in front of vertebra L3
  - in secondarily retroperitoneal
- 4 **Ascending part / D4** *(pars ascendens)*
  - is secondarily retroperitoneal
  - runs obliquely up to the left margin of the body of vertebra L2, then continues into the jejunum at the level of the duodenojejunal flexure

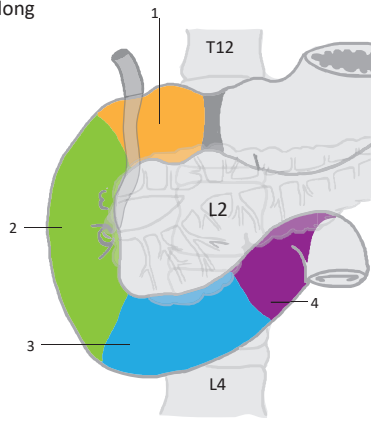

The term "duodenum" refers to its length of 12 inches.

The jejunum and ileum are intraperitoneal organs. They are suspended by the mesentery and, in comparison to the duodenum, which is not suspended by the mesentery, are mobile.

The muscular layer of the small intestine performs 3 types of motions. Segmental motions are focal contractions of circular muscle that create segments. Oscillating motions within the segments shorten and lengthen the intestinal loops, mixing the intestinal content. Peristaltic motions move the intestinal content in an aboral direction.

The intestinal villi *(villi intestinales)* are prominences of epithelium and lamina propria.

The intestinal glands / crypts of Lieberkühn *(glandulae intestinales)* are depressions between bases of the intestinal villi.

Peyer's patches *(noduli lymphoidei aggregati)* are located in the submucosa of the ileum.

The intestinal villi of the duodenal wall are shaped like sheets.

Duodenal glands / Brunner's glands *(glandulae duodenales)* are submucosal serous tuboalveolar glands that produce and secrete an alkaline liquid, which neutralises the acidic content from the stomach.

The developmental border zone between the foregut and midgut is situated just below the major duodenal papilla.

The suspensory muscle of duodenum / Ligament of Treitz *(musculus suspensorius duodeni)* is a musculoligamentous fascicle extending from the left crus of the diaphragm. It suspends the duodenojejunal flexure.

Clinical notes

Bulbar ulcer is a duodenal ulcer which occurs in the ampulla (duodenal cap). Ulcers are less likely to occur in other parts of the duodenum as chyme gets neutralized by the liquid of the duodenal glands

Oesophagogastroduodenoscopy is an endoscopic examination of the upper parts of the gastrointestinal tract: oesophagus, stomach and duodenum. In the clinical practice, this is often termed gastroscopy.

Structure

Superior part *(pars superior)*

- 1 **Ampulla / duodenal cap** *(ampulla duodeni)* – an intraperitoneal part connecting the duodenum to the stomach
  – no folds on its mucosa
- 2 **Superior duodenal flexure** *(flexura duodeni superior)* – a flexure between the superior and descending part

Syntopy:
ventrally: gallbladder and the visceral surface of the liver (forms the duodenal impression on the liver)
dorsally: bile duct, portal vein, inferior vena cava, gastroduodenal artery
cranially: hepatoduodenal ligament and its content
caudally: the head of the pancreas

Descending part *(pars descendens)*

- 3 **Longitudinal duodenal fold** *(plica longitudinalis duodeni)*
  – a longitudinal mucosal fold on the medial wall, which is formed by the course of the bile duct
- 4 **Major duodenal papilla of Vater** *(papilla duodeni major)* – an elevated area on the lower end of the longitudinal duodenal fold within the inferior half of the descending part, approximately 10cm from the pylorus
  – the opening of the bile duct and major pancreatic duct
- 5 **Minor duodenal papilla of Santorini** *(papilla duodeni minor)*
  – an elevated spot positioned 2cm above the major duodenal papilla
  – the opening of the accessory pancreatic duct
- 6 **Inferior duodenal flexure** *(flexura duodeni inferior)*
  – a flexure situated between the descending and inferior part

Syntopy:
ventrally: the root of the transverse mesocolon, transverse mesocolon, gallbladder and visceral surface of the liver
dorsally: the bile duct and pancreaticoduodenal arteries in a groove between the duodenum and the head of the pancreas
left: the head of the pancreas and blood vessels (anterior and posterior pancreatic arches)
right: the hilum of the right kidney, right renal pelvis, the initial part of the right ureter and the right renal blood vessels

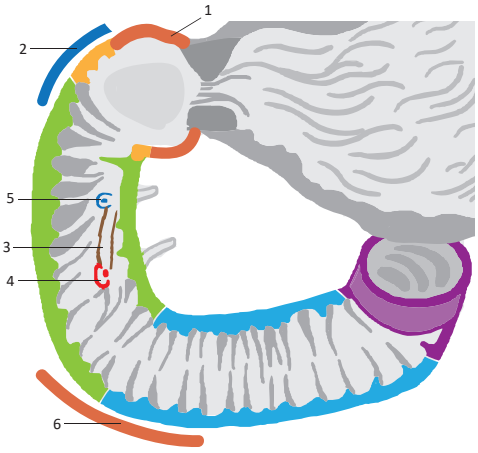

Frontal section of the duodenum

Inferior (horizontal) part *(pars inferior)*

Syntopy:
ventrally: the root of the mesentery with the superior mesenteric artery and vein (the vein is situated on the right side from the artery), and intestinal loops
dorsally: the right ureter, which crosses the inferior part in its direction from the right to the left, right psoas major, right testicular/ovarian blood vessels, inferior vena cava and abdominal aorta
cranially: the head of the pancreas

Ascending part *(pars ascendens)*

Syntopy:
ventrally: intestinal loops, transverse mesocolon, stomach
dorsally: the abdominal aorta, left sympathetic trunk, left psoas major, left testicular/ovarian blood vessels, left renal artery and vein
right: pancreas

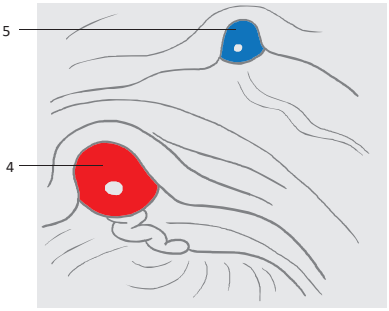

Major and minor duodenal papilla, endoscopic inferior view

Blood supply

Arterial blood supply: coeliac trunk and branches form the anterior and posterior pancreatic arches

- 1 **Superior anterior pancreaticoduodenal artery** (from the gastroduodenal artery)
- 2 **Superior posterior pancreaticoduodenal artery** (from the gastroduodenal artery)
- 3 **Inferior pancreaticoduodenal artery** (from the superior mesenteric artery)

Venous drainage: into the hepatic portal vein

Lymphatic drainage: pyloric, hepatic and superior mesenteric lymph nodes (into the coeliac lymph nodes)

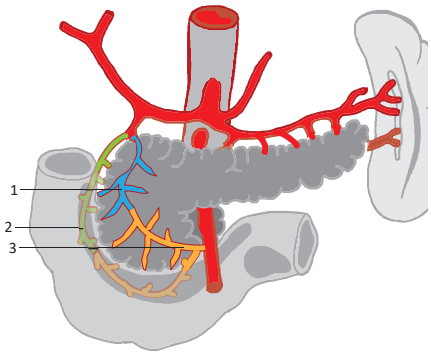

Innervation

Parasympathetic system: vagus nerve (via the coeliac plexus and superior mesenteric periarterial plexuses)
Sympathetic system: splanchnic nerves (via the coeliac plexus and superior mesenteric periarterial plexuses)
Viscerosensory innervation: fibres accompanying the vagus and splanchnic nerves

This copy belongs to ali yaghoubi

The duodenum becomes the jejunum at the duodenojejunal flexure. However, there is **no macroscopically visible border** between the jejunum and ileum. The jejunum and ileum form loops and together measure about **3 to 5 meters**. Only initial part of the jejunum and the terminal ileum are held firmly in place; the rest of the jejunum and ileum is freely mobile in the abdominal cavity.

Jejunum

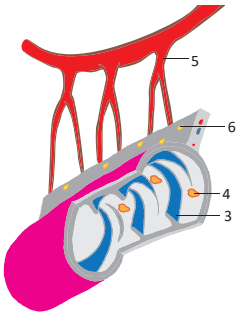

1 **Diameter:** about 3 cm
2 **Length:** two-fifths of the jejuno-ileal length
3 **Mucous folds:** tall and numerous
4 **Lymphoid nodules:** solitary
5 **Arterial supply:** rich (color: rosier in vivo),
1 or 2 series of arcades from the jejunal arteries and long straight arterioles (5 cm)
6 **Mesentery:** longer with less fat infiltration
7 **Location:** superior and left
8 **Autopsy:** no intestinal content

Ileum

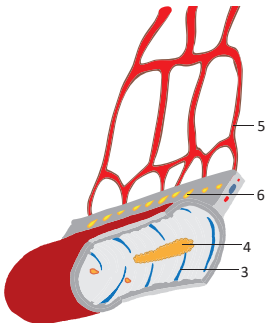

1 **Diameter:** about 2.5 cm
2 **Length:** three-fifths of the total jejuno-ileal length
3 **Mucous folds:** short and scarce
4 **Lymphoid nodules:** aggregated and solitary
5 **Arterial supply:** poor, 2–3 series of arcades from the ileal arteries and short straight arterioles (2 cm)
6 **Mesentery:** shorter and with richer fat infiltration
7 **Location:** inferior and right
8 **Autopsy:** usually presents with some intestinal content

Syntopy

1 **Ventrally:**
the greater omentum and anterior abdominal wall
2 **Dorsally:**
the retroperitoneal organs (duodenum, kidneys, ureters, abdominal aorta and inferior vena cava)
– the sigmoid colon and rectal ampulla in the pelvic part of the peritoneal cavity,
3 **Cranially:** transverse colon
4 **Caudally:** organs of the small pelvis
5 **Left:** descending and sigmoid colon
6 **Right:** caecum and ascending colon

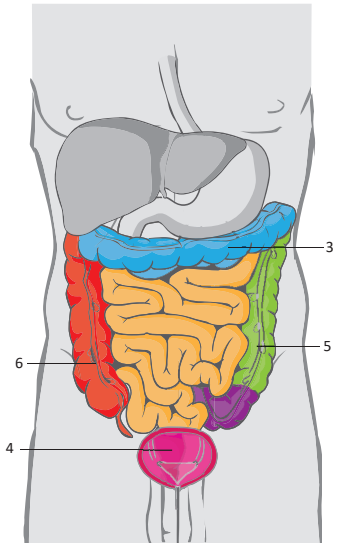

Syntopy of the jejunum and ileum

Blood supply

Arterial supply: superior mesenteric artery
– jejunal arteries, ileal arteries and ileocolic artery form the mesenteric arterial arches (terminated arcades)
– direct branches to the intestinal wall arise from arcades (straight arterioles)
Venous drainage: superior mesenteric vein (into the hepatic portal vein)
Lymphatic drainage: superior mesenteric lymph nodes (into the coeliac and lumbar lymph nodes and subsequently into the thoracic duct)

Innervation

Parasympathetic and sympathetic system: vagus and splanchnic nerves
Viscerosensory innervation: fibers accompanying the vagus and splanchnic nerves

In the clinical practice the jejunum and ileum are called the jejunoileum or mesenterial intestine.

The terminal ileum is a clinical term for the aboral part of ileum, which continues into the caecum. Inflammatory bowel diseases such as Crohn's disease may affect this part of small intestine.

The enterohepatic circulation refers to the circulation of bile acids that are absorbed in the terminal ileum and then transported by the hepatic portal vein back to the liver to be reused in bile acid synthesis.

The developmental border zone between the midgut and hindgut is situated between the middle and left thirds of transverse colon (the Cannon-Böhm point). This also represents the border between parasympathetic innervation from the vagus nerve and from the sacral spinal segments.

Gastrocolic ligament (*ligamentum gastrocolicum*) is a part of the greater omentum originating from the greater curvature of the stomach.It is attached to the omental taenia of the transverse colon.

Phrenicocolic ligament (*ligamentum phrenicocolicum*) is a peritoneal fold passing from the left diaphragmatic vault to the left colic flexure.

Clinical notes

Enteroscopy is an endoscopic examination of the small intestine.

The large intestine is **the last part of the digestive tract**. Its main functions are **absorption of water** and creation of faeces. The large intestine is about **1.5 m long** and 6–8 cm wide. Along its course, it is either located secondarily retroperitoneally on the posterior abdominal wall or is suspended in the abdominal cavity by the mesocolon. The large intestine froms a perimeter around the small intestine.

Parts

- 1 **Caecum**
  - 1.1 **Vermiform appendix** *(appendix vermiformis)*
- 2 **Colon**
  - 2.1 **Ascending colon** *(colon ascendens)*
  - 2.2 **Transverse colon** *(colon transversum)*
  - 2.3 **Descending colon** *(colon descendens)*
  - 2.4 **Sigmoid colon** *(colon sigmoideum)*
- 3 **Rectum**
  - 3.1 **Anus**

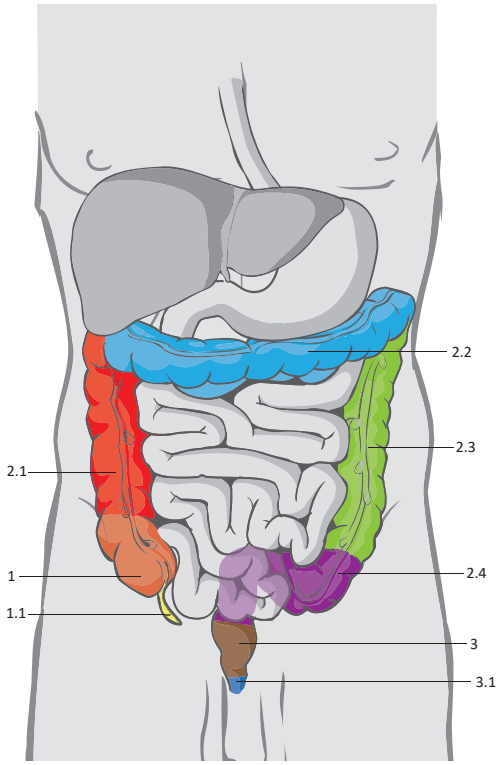

Parts of the large intestine

Histology

Mucosa (and submucosa)
– contains a single layer of columnar epithelium, there are no villi
Muscular layer – has a circular and a longitudinal layer of smooth muscle
– there are several regions along the course of the large intestine with highly developed circular muscle that form functional sphincters
Superficial layer – is covered by the visceral peritoneum except on the posterior wall of the ascending and descending colon and the aboral part of the rectum, which are connected to the surrounding tissue by adventitia

Appearance

- 1 **Haustra of colon** *(haustra coli)* – saccular pouches of the colon wall are formed by contractions of the layer of circular smooth muscle and bulging of the longitudinal muscles
  – notches between the pouches correlate with the internal semilunar folds
- 2 **Taeniae coli** – three longitudinal muscular bands that are visible on the external surface of the colon
  – are classified according to the position on the transverse colon:
  - 2.1 **Mesocolic taenia** *(taenia mecocolica)*
    – at the attachment of the transverse mesocolon
  - 2.2 **Omental taenia** *(taenia omentalis)* – at the fusion with the greater omentum (gastrocolic ligament)
  - 2.3 **Free taenia** *(taenia libera)*
    – faces the anterior abdominal wall
  – the taeniae coli form a continuous muscular layer on the **vermiform appendix** and the **rectum** (at the recto-sigmoid transition)
- 3 **Omental appendices / fatty appendices of colon** *(appendices omentales / adiposae coli / appendices epiploicae)*
  – small pouches of visceral peritoneum filled with adipose tissue
- 4 **Semilunar folds of colon** *(plicae semilunares coli)*
  – transverse semilunar-shaped folds of mucosa

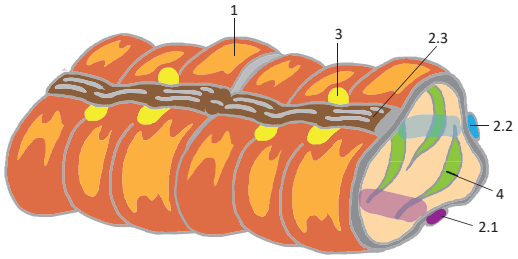

Structure of the wall of the colon

Innervation

Mixed periaterial plexus – extends from the coeliac and superior and inferior mesenteric ganglia
– contains sympathetic, parasympathetic and viscerosensory nerve fibres
Parasympathetic system: increases peristalsis and contractions of the large intestine and reduces its glandular activity
– **vagus nerve:** innervates the colon until the last third of the transverse colon at the Cannon-Böhm point
– **sacral parasympathetic fibres:** innervate the colon distal to the Cannon-Böhm point and travel in the sacral splanchnic nerves and the inferior mesenteric plexus
Sympathetic system: reduces peristaltic movements and contractions of the large intestine and increase its glandular activity
Viscerosensory nerves: travel in the vagus nerve and the sacral parasympathetic fibres

This copy belongs to ali yaghoubi

Blood supply

Arterial supply: superior mesenteric artery, inferior mesenteric artery, internal iliac artery

- 1 **Great anastomosis of Haller** – an anastomosis between the left colic and middle colic arteries

Superior mesenteric artery

- 2 **Ileocolic artery** – supplies the terminal ileum and caecum
  - 2.1 **Appendicular artery** – supplies the vermiform appendix
- 3 **Right colic artery** – supplies the ascending colon
- 4 **Middle colic artery**
  – supplies the right part of the transverse colon

Inferior mesenteric artery

- 5 **Left colic artery** – supplies the left part of the transverse colon and the descending colon
  - 5.1 **Superior branch** – an ascending branch supplying the left part of the transverse colon
  - 5.2 **Inferior branch** – a descending branch that makes an anastomosis with the first sigmoid artery
- 6 **Sigmoid arteries** – 2–4 branches to the sigmoid colon
- 7 **Superior rectal artery** – the terminal branch
  – supplies the rectal ampulla and anastomoses with the most distal of the sigmoid arteries

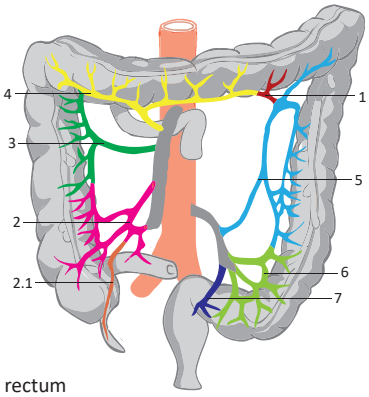

Internal iliac artery

- 8 **Middle rectal artery** – supplies the outer layers of the rectum
- 9 **Inferior rectal artery** – supplies the anal canal and anus
  – a branch of the internal pudendal artery

Venous drainage: superior rectal vein (to the inferior mesenteric vein and then to the portal vein), middle rectal veins and inferior rectal veins (to the internal iliac vein)

Lymphatic drainage:

- **terminal ileum, caecum, vermiform appendix and beginning of the ascending colon:** ileocolic nodes, precaecal and retrocaecal nodes, appendicular nodes and paracolic nodes
- **ascending colon:** right colic nodes
- **right 2/3 of the transverse colon:** middle colic nodes
- **left 1/3 of the transverse colon, descending colon and sigmoid colon:** left colic nodes
- **rectum:** inferior mesenteric nodes, internal and external iliac nodes, superficial inguinal nodes, pararectal and sacral nodes

7.1 Caecum – Caecum

The caecum is the first part of the large intestine. It is **situated in the right iliac fossa** and it is about 7 cm long. The ileum opens into the left side of the caecum. The caecum is covered by peritoneum, except on the cranial aspect of its dorsal wall. The caudal part of the caecum is free and movable, a peritoneal fold arises here forming the retrocaecal recess. The **vermiform appendix** arises from the caudal apex of the caecum.

External morphology

- 1 **Ileocolic transition** – the junction between the ileum and caecum
  - 1.1 **Ileal papilla** *(papilla ilealis)*
    - 1.1.1 **Ileal orifice** / orifice of the ileal papilla (*ostium ileale caeci*)
    - 1.1.2 **Ileocolic lip** / superior lip (*labrum ileocolicum / labium superius*)
    - 1.1.3 **Ileocaecal lip** / Inferior lip (*labrum ileocaecale / labium inferius*)
    - 1.1.4 **Frenulum of ileal orifice** *(frenulum ostii ilealis)*
      – a small fold of tissue that connects the ileocolic and ileocaecal lips

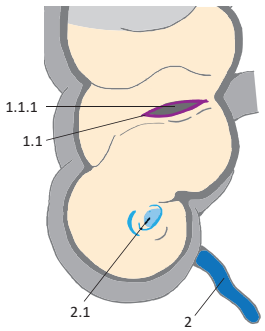

- 2 **Vermiform appendix** *(appendix vermiformis)*
  – a worm-shaped blind-ended tube
  - 2.1 **Orifice of vermiform appendix** *(ostium appendicis vermiformis)*
    – the opening of the vermiform appendix at the posterior wall of the caecum
    – is located around 3 cm below the ileal orifice

Mobile caecum is a term for a caecum, which is fully mobile due to the presence of a fold of peritoneum called the mesocaecum.

Syntopy of the caecum
Ventrally: the greater omentum and ileum
Dorsally: the iliacus, psoas major and lateral cutaneous nerve of the thigh

The appendicular tonsil is a term for the vermiform appendix based on the extensive amount of lymphoid tissue in its wall.

The appendiculo-ovarian ligament of Clado is a variable peritoneal duplicature connecting the vermiform appendix to the right ovary. It contains lymphatic vessels and may allow infection to spread between the vermiform appendix and ovary.

It can be sometimes difficult to determine the position of the vermiform appendix, particularly when it is in atypical positions or during inflammation of the abdominal cavity. In such cases, orientation by the taeniae coli can help as they converge on the vermiform appendix to form a continuous muscular layer.

The right and left paracolic spaces are spaces on the lateral border of the ascending and descending colons. The colon touches the posterior abdominal wall here through the parietal peritoneum.

Clinical notes

Acute appendicitis is an acute inflammation of the appendix. The classical presentation of appendicitis is pain in the right area under the umbilicus, but it can imitate an inflammation of other organs according to the variability of a position. It is a severe health condition, classified as acute abdomen. Retrocaecal appendices have the worst prognosis.

Atypical positions of the appendix, such as the subhepatic position and cranial displacement during pregnancy, can cause appendicitis to mimic inflammations of other organs, such as the gall bladder and kidneys.

Ulcerative colitis and Crohn's disease belong to a group of diseases called idiopathic inflammatory bowel disease (IBD).

Hirschsprung's disease is a rare congenital disorder. It is characterised by the absence of ganglia in the enteric nervous system in the aboral part of the large intestine.

The vermiform appendix is a 5–7 cm long, narrow blind-ended tube. It is held in its location by a **fold of peritoneum called the meso-appendix**. **An abundance of lymphoid tissue** is found throughout its mucosa and submucosa. The taeniae coli converge to form a continuous muscular layer on the vermiform appendix.

Positions of the appendix

- 1 **Retrocaecal position** – the most common position (about 2/3 cases)
  – located behind the caecum, the free part directs cranially
- 2 **Pelvic position** – the second most common position (about 25 % cases)
  – medial to the caecum, crossing the linea terminalis and pointing towards the lesser pelvis
- 3 **Ileocaecal position** – medial to the caecum and parallel to the terminal part of the ileum
- 4 **Laterocaecal position** – laterally to the caecum, between the caecal wall and abdominal wall, the free part points cranially
- 5 **Subcaecal position** – ventrocaudally to the caecum,
  – points towards the inguinal ligament
  – does not cross the linea terminalis
- 6 **Precaecal position** – ventral to the caecum, between the anterior wall of the caecum and abdominal wall

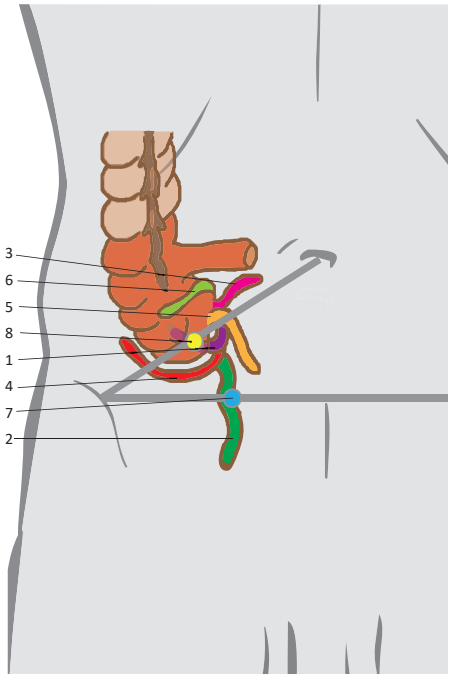

Projections on the anterior abdominal wall

- 7 **Point of Lanz**
  – is located at the border of the right and middle thirds of the interspinous line (a line connecting the superior anterior iliac spine on the right and left sides)
  – corresponds to the pelvic position of the vermiform appendix
- 8 **McBurney's point**
  – about 6 cm from the right superior anterior iliac spine on a line connecting the right superior anterior iliac spine to the umbilicus
  – corresponds to the orifice of the vermiform appendix or to part of its course

The ascending colon is about 15 cm long and is the second part of the large intestine. It is the aboral continuation of the caecum passing on the right side of the abdominal cavity up to the liver. At the liver, it bends to the left, forming the right colic flexure, and continues as the transverse colon. The ascending colon **lacks its peritoneal mesocolon**, because it remains in contact with the posterior abdominal wall and is covered by peritoneum on its ventral aspect. It is a **secondary retroperitoneal organ.**

Syntopy

- 1 **Ascending colon** *(colon ascendens)*
  dorsally: quadratus lumborum, iliacus, transversus abdominis, inferior pole of the right kidney, iliohypogastric nerve, ilioinguinal nerve, genitofemoral nerve, lateral cutaneous nerve of the thigh
  medially: small intestine
  laterally: abdominal wall

- 2 **Right colic flexure / hepatic flexure** (*flexura coli dextra/hepatica*)
  ventrally: hepatocolic ligament, cystocolic ligament
  ventromedially: gallbladder
  dorsally: right kidney
  medially: descending part of the duodenum
  cranially: liver

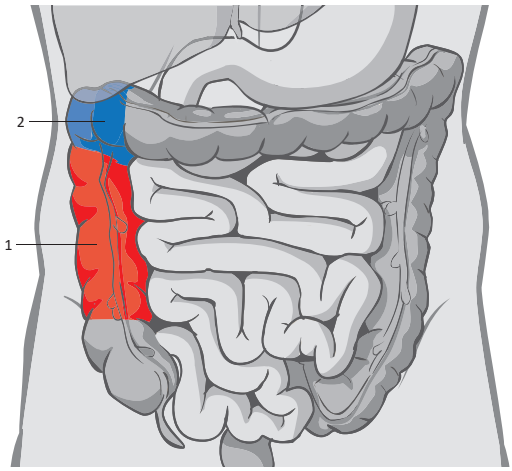

This copy belongs to ali yaghoubi

The transverse colon is the continuation of the ascending colon from **the right colic flexure** up to and including **the left colic flexure** at the spleen. At the left colic flexure it turns downwards and continues as the descending colon. The transverse colon is an **intraperitoneal organ**. **The transverse mesocolon** divides the peritoneal cavity into a (upper) **supramesocolic part** and a (lower) **inframesocolic part**.

Syntopy

- 1 **Transverse colon** *(colon transversum)*
  - **dorsally:** right kidney, duodenum, pancreas, left kidney, spleen
  - **ventrally:** greater omentum, anterior abdominal wall
  - **cranially:** liver, gallbladder, stomach, spleen
  - **caudally:** small intestine
- 2 **Left colic / splenic flexure** (*flexura coli sinistra/splenica*)
  - **dorsally:** left kidney
  - **ventromedially:** stomach
  - **cranially:** spleen

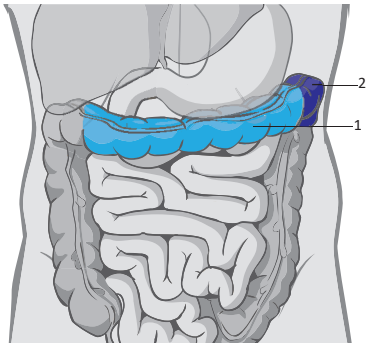

Transverse mesocolon (*mesocolon transversum*)

- **Root of transverse mesocolon** *(radix mesocoli transversi)*
  – the origin of the transverse mesocolon on the parietal peritoneum
  – the root of the transverse mesocolon crosses:
  - 1 **Right kidney**
  - 2 **Descending part of duodenum**
  - 3 **Head and body of pancreas**
  - 4 **Left kidney**

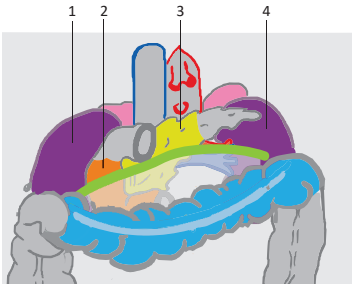

7.2.3 Descending and sigmoid colon – Colon descendens and sigmoideum

The **descending colon** is 22–30 cm long and passes on the left side of the peritoneal cavity distally from the left colic flexure to the left iliac fossa where it continues as the sigmoid colon. Similarly to the ascending colon, the descending colon **lacks its own peritoneal mesocolon**. It remains in contact with the posterior abdominal wall and is covered by peritoneum only on its ventral aspect. It is a **secondary retroperitoneal organ**. The **sigmoid colon** is 30–40 cm long. It courses from the level of the iliac crest to the level of the vertebral disc S2/S3. It is a primary **intraperitoneal organ** and its **peritoneal duplicature** is called the **sigmoid mesocolon**. It continues as the rectum on the pelvic surface of the sacrum.

Syntopy

- 1 **Descending colon** *(colon descendens)*
  - **dorsally:** iliacus, quadratus lumborum, transversus abdominis, left kidney, iliohypogastric nerve, ilioinguinal nerve, genitofemoral nerve, lateral cutaneous nerve of the thigh
  - **medially:** small intestine
  - **laterally:** abdominal wall
- 2 **Sigmoid colon** *(colon sigmoideum)*
  - **in its course it crosses:**
  – left testicular/ovarian vessels
  – left ureter
  – left external iliac vessels

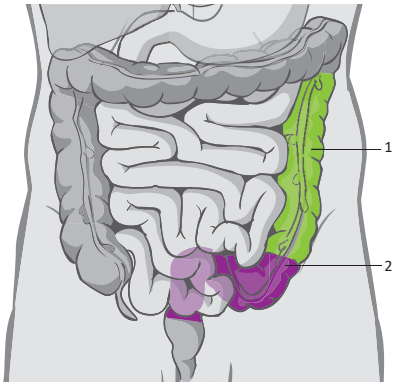

The root of the mesentery divides the inframesocolic part of the peritoneal cavity into the left and right paracolic spaces. The superior mesenteric artery supplies the right paracolic space and the inferior mesenteric artery supplies the left paracolic space.

The haemorrhoidal plexus (internal rectal venous plexus) is located in the submucosa of the oral part of the anal canal. It elevates the submucosa and contributes to the closure mechanism of the rectum. The superior rectal vein supplies blood to this area and it plays a key role in the pathogenesis of haemorrhoids.

The connection between the hepatic portal vein and internal iliac vein is a portocaval anastomosis and can participate in pathogenesis of haemorrhoids.

The mechanism of defecation starts with expansion of the rectal ampulla caused by accumulation of stool. This eventually leads to reflex relaxation of the internal anal sphincter. The next step is voluntary relaxation of the external anal sphincter and puborectalis. This triggers contractions of the muscular layer of the rectum that lead to defecation.

The colorectal zone reaches aborally down to the supratransitional line.

The surgical anal canal (described in the text and depicted in the figure) extends from the anorectal junction to the anocutaneous line. The anatomical anal canal extends from the pectinate line to the anocutaneous line.

Clinical notes

Structures palpated in the digital rectal examination:
Dorsally: coccyx, pelvic surface of the sacrum
Laterally: ischiadic spines, sometimes also the ovaries in female
Ventrally in a male: prostate (sometimes also the urinary bladder)
Ventrally in a female: the perineal wedge , posterior wall of the vagina and, through the vagina, the cervix of the uterus.

Colonoscopy is an endoscopic examination of the large intestine.

Colorectal carcinoma is one of the most common malignant tumors of the adult population. The common way for metastatic dissemination is hematogenous spread through the hepatic portal vein to the liver and lymphatic spread to the regional lymph nodes.

The rectum is the terminal part of the digestive canal. **It begins at the distal end of the sigmoid colon at the level of the vertebral disc S2/S3 and terminates as the anal canal**. The rectum is about 12–15 cm long, 4 cm wide and is located in the lesser pelvis. In comparison to the other parts of the large intestine, it lacks haustra, taeniae coli and omental appendices. Its shorter oral part has a **peritoneal attachment** called **the mesorectum**. Its longer aboral part is fixed to the surrounding sutures in the lesser pelvis by connective tissue known as **the paraproctium**.

Parts

- 1 **Rectal ampulla** *(ampulla recti)* – the dilated and longer part forming the sacral flexure
  - its mucosa features simple columnar epithelium as so is known as the colorectal zone
  - 1.1 **Anorectal junction** *(junctio anorectalis)* – the transition from the rectal ampulla to the anal canal at the level of pelvic diaphragm
- 2 **Anal canal** *(canalis analis)* – the narrow and shorter part forming the anorectal flexure
  - 2.1 **Supratransitional line** *(linea supratransitionalis)* – a histological border between the colorectal zone and anal transitional zone
  - 2.2 **Anal transition zone ATZ / haemorrhoidal zone** (*zona transitionalis analis*) – the main part of the anal canal
    - the epithelial cells get shorter when going in an aboral direction (from columnar to cuboid and finally squamous)
    - contains the internal rectal venous plexus (haemorrhoidal plexus) in the submucosa
    - 2.2.1 **Anal columns of Morgagni** *(columnae anales)* – 6 to 12 longitudinal folds connected aborally by the anal valves, which form the anal sinuses/crypts, into which the anal glands open
  - 2.3 **Pectinate line / dentate line** (*linea pectinata / linea dentata*) – a border at the level of the anal valves
  - 2.4 **Anal pecten / anoderm** (*zona squamosa analis*) – non-keratinised stratified squamous epithelium without skin adnexa
  - 2.5 **Anocutaneous line / white line of Hilton** *(linea anocutanea*) – the border between the anal pecten and anus
- 3 **Anus** – hole covered by the skin with skin adnexa

Flexures

In the sagittal plane

- 5 **Sacral flexure** *(flexura sacralis)* – the ventrodorsal bend of the rectal ampulla, a dorsal convexity over the sacrum and coccyx
- 6 **Anorectal flexure / perineal flexure** *(flexura anorectalis / flexura perinealis*) – after passing through the pelvic diaphragm, the rectum bends along the coccyx and then courses dorsocaudally

In the frontal plane

– flexures correlate with the mucous folds of the rectum – the superior, middle and inferior transverse folds of Houston *(plica transversa recti superior, media et inferior)*

- 7 **Superodextral lateral flexure** *(flexura superolateralis dextra)* – its convexity directs to the right side
- 8 **Intermediosinistral lateral flexure / Intermediate lateral flexure** *(flexura intermediolateralis sinistra*) – its convexity directs to the left side
  - 8.1 **Middle transverse rectal fold of Kohlrausch** *(plica transversa recti sinistra)* – the biggest fold, about 7 cm from the anal canal
- 9 **Inferodextral lateral fold** / inferior lateral flexure *(flexura inferolateralis dextra*) – its convexity directs to the right

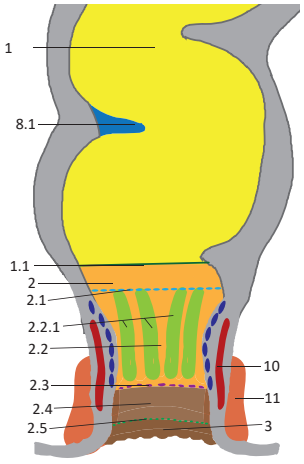

Frontal section of the rectum

Muscles

- 10 **Internal anal sphincter** *(musculus sphincter ani internus)* – a smooth muscle located in the oral part of the anal canal
- 11 **External anal sphincter** *(musculus sphincter ani externus)* – a skeletal muscle – attached externally to the internal anal sphincter and from below to the levator ani
- 12 **Puborectalis** *(musculus puborectalis)* – a skeletal muscle, the most medial part of the levator ani – forms a sling around the rectum at the level of the anorectal flexure

Syntopy

Dorsally, in both sexes: sacral vertebrae III–V, coccyx
Laterally, in both sexes: pararectal fossae, levator ani
Ventrally, in male:
– **oral part:** urinary bladder, seminal glands, rectovesical excavation of Proust
– **aboral part:** urinary bladder, seminal glands, ductus deferens, prostate
Ventrally, in female:
– **oral part**: uterus, vagina, rectouterine excavation of Douglas
– **aboral part:** vagina, perineal muscles

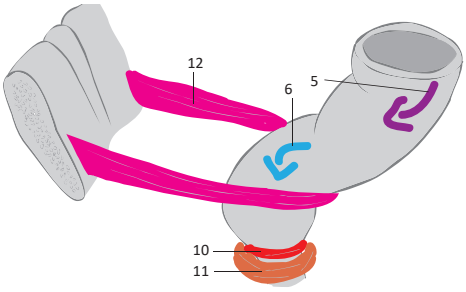

Muscles and flexures of the rectum

Innervation

Sympathetic: from the lumbar part of the sympathetic trunk via the superior hypogastric plexus (contracts the internal anal sphincter)
Parasympathetic: sacral splanchnic nerves (relaxes the internal anal sphincter and stimulates of the smooth muscles of the rectum)
Somatomotor and somatosensory: pudendal nerves (somatomotor innervation of the external anal sphincter and sensory innervation of the tissue surrounding the anus)

This copy belongs to ali yaghoubi

The liver is the largest gland in the human body. It has both the exocrine and endocrine functions. The liver **produces bile**, which travels through the biliary tree and is stored in the gallbladder before being excreted by the bile duct into the duodenum. Other important functions of the liver are detoxification and haematopoesis during foetal development. The liver is **situated in the supramesocolic part of the peritoneal cavity** in the **the right hypochondrium**. A minor part of the liver extends to the left hypochondrium.

Segmentation

Lobes *(lobi)*

– are marked by grooves on the visceral surface

- 1 **Right lobe** *(lobus dexter)* – on the right side of the left sagittal fissure
- 2 **Left lobe** *(lobus sinister)* – on the left side of the left sagittal fissure
- 3 **Quadrate lobe** *(lobus quadratus)* – below the porta hepatis
- 4 **Caudate lobe** *(lobus caudatus)* – above the porta hepatis

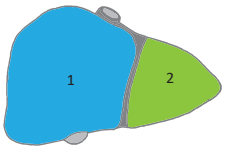

Anterior view

Segments *(segmenta)*

– are divided by the branching pattern of the blood vessels and biliary tree
– the inner segmentation does not correlate with the pattern of lobes as seen from the surface

- I **Posterior segment** – caudate lobe *(segmentum posterius)*
- II **Left posterior lateral segment** *(segmentum posterius laterale sinistrum)*
- III **Left anterior lateral segment** *(segmentum anterius laterale sinistrum)*
- IV **Left medial segment** *(segmentum mediale sinistrum)*
- V **Right anterior medial segment** *(segmentum anterius mediale dextrum)*
- VI **Right anterior lateral segment** *(segmentum anterius laterale dextrum)*
- VII **Right posterior lateral segment** *(segmentum posterius laterale dextrum)*
- VIII **Right posterior medial segment** *(segmentum posterius mediale dextrum)*

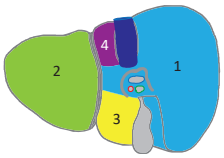

Inferior view

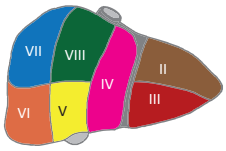

Anterior view

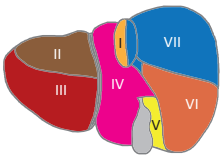

Inferior view

Histology

1 **Portal triad of Glisson** *(trias hepatica)*
– consists of the following structures, running between the lobules:
- 1.1 **Interlobular artery** *(arteria interlobularis)*
  – a branch of the hepatic artery proper
- 1.2 **Interlobular vein** *(vena interlobularis)* – a branch of the hepatic portal vein
- 1.3 **Interlobular bile duct** *(ductus bilifer interlobularis)* – a branch of the biliary tree

Hepatic parenchyma / hepatic muralium *(muralium hepaticum)* – tissue made of hepatocytes

- 2 **Hepatocyte** – a hepatic cell, the main cell of the liver parenchyma
- 3 **Hepatocyte lamina/plate/trabecula** – a radiating column made of hepatocytes
- 4 **Classical/polygonal hepatic lobule** – the basic anatomical unit
  – a hexagonal shape, the hepatocyte laminae radiating outward from the central vein
- 5 **Portobiliary space** – the point of the contact of three hepatic lobules, contains the portal triad
- 6 **Portal lobule of Mall** – the principal unit of circulation, a triangular shape, vertices are represented by three central veins, the portobiliary space is located in the centre
  – a part of the hepatic parenchyma supplied by the interlobular vessels located in its centre
- 7 **Hepatic/liver acinus** – the primary functional unit
  – made of hepatic laminae supplied by one particular circumlobular vessels (artery and vein)
  – quadrilateral (two triangles), the circumlobular artery and vein are situated in its center, vertices are represented by two central veins and two portobiliary spaces

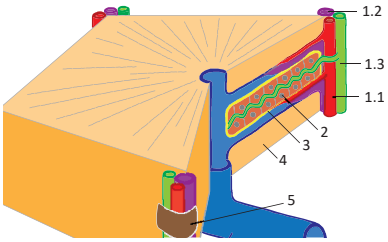

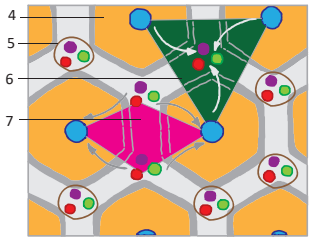

The basic structural unit of the liver: hepatocytes
The basic morphologic unit: the classical hepatic lobule
The basic circulation unit: the portal lobule
The basic functional unit: the hepatic acinus

The fibrous capsule of the liver (capsule of Glisson) is a fibrous cover of the liver. It projects septa into the liver parenchyma. These septa delimit individual hepatic lobules and house the blood vessels and bile ducts (perivascular fibrous capsule).

The sinusoid is a type of a blood capillary which does not have a continuous basal lamina. Sinusoids have irregularly shaped lumens and walls, which contain fenestrations and pores. Sinusoids are located between the anastomosing laminae of the hepatic parenchyma. Their structure facilitates exchange of substances between blood and hepatocytes. The portal blood and arterial blood are mixed in the sinusoids (and also in the circumlobular veins and precapillary veins).

The round ligament of the liver is a ligamentous remnant of the umbilical vein.

The ligamentum venosum is a ligamentous remnant of the venous duct.

The hepatorenal ligament is a transition between the dorsal part of the right coronary ligament and the parietal peritoneum covering the right kidney.

The fibrous appendix of the liver (*appendix fibrosa hepatis*) is the end of the left coronary ligament attached to the diaphragm.

Portal vein page 298.

Clinical notes

Liver cirrhosis is conversion of the hepatic parenchyma into nodules. Portal venous blood pressure may rise due to cirrhosis. This is called portal hypertension and can lead to an expansion of the portocaval anastomosis between the stomach and oesophagus, which results in oesophageal varices. Bleeding of ruptured varices is a life-threatening condition.

Division of the liver parenchyma into segments allows surgical removal of particular segments according to their blood supply.

External structure

Surfaces

- 1 **Diaphragmatic surface** *(facies diaphragmatica)* – faces the diaphragm
  - 1.1 **Bare area** *(area nuda)* – a trianglular area devoid of peritoneum – adheres to the diaphragm
- 2 **Visceral surface** *(facies visceralis)* – in contact with abdominal organs
- 3 **Inferior border** *(margo inferior)* – the border of the diaphragmatic and visceral surfaces

Grooves – divide the visceral surface into lobes

4 **Left sagittal fissure** *(fissura sagittalis sinistra)* – is divided into a ventral and dorsal part

4.1 **Fissure for round ligament** *(fissura ligamenti teretis)* – the ventral part of the left sagittal fissure, contains the round ligament of the liver

4.2 **Fissure for ligamentum venosum** *(fissura ligamenti venosi)* – the dorsal part of left sagittal fissure, contains the ligamentum venosum

5 **Right sagittal fissure** *(fissura sagittalis dextra)*

5.1 **Fossa for gallbladder** *(fossa vesicae biliaris/felleae)* – a groove for the gallbladder

- 5.1.1 **Gallbladder** *(vesica biliaris/fellea)*

5.2 **Groove for vena cava** *(sulcus venae cavae)* – the dorsal part of the right sagittal fissure – contains the inferior vena cava, at the entrance of the hepatic veins

- 5.2.1 **Ligament of vena cava** *(ligamentum venae cavae)* – a ligament holding the inferior vena cava to the liver

6 **Porta hepatis** *(porta hepatis)* – a transverse groove, where the hepatic ducts emerge from the liver and vessels and nerves enter the liver

- 6.1 **Right and left branch of the hepatic artery proper**
- 6.2 **Right and left branch of the hepatic portal vein**
- 6.3 **Right and left hepatic duct**

6.4 **Lymphatic vessels**

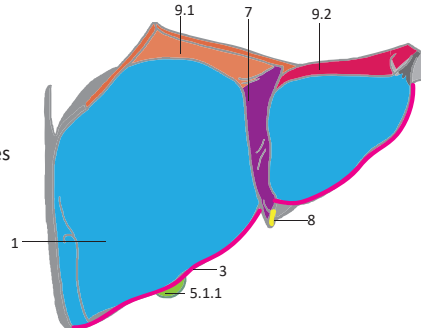

Anterior view of the diaphragmatic surface

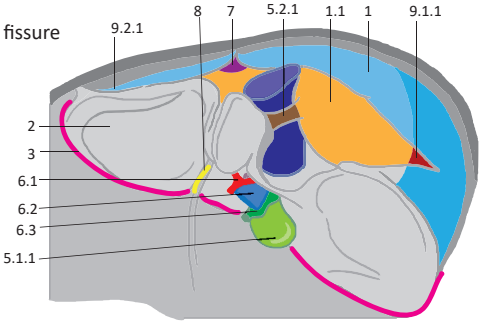

Posterior view of the visceral surface

Fixation

The liver is held to the surrounding structures by peritoneal duplicatures and, in some places, by single sheets of peritoneum.

- 7 **Falciform ligament** *(ligamentum falciforme hepatis)* – a peritoneal duplicature
  - is located in front of the liver between the right and left lobes
  - attaches the liver to the anterior abdominal wall
  - splits into two separate sheets on the bare area, the anterior sheet continues as the coronary ligament on both sides
- 8 **Round ligament of liver** *(ligamentum teres hepatis)*
  - a remnant of the fetal umbilical vein in the free edge of the falciform ligament extending from the umbilicus to the liver

9 **Coronary ligament** *(ligamentum coronarium hepatis)* – a single sheet of peritoneum

- borders the superior and posterior parts of the diaphragmatic surface
  - 9.1 **Right coronary ligament** *(ligamentum coronarium dextrum)*
    - borders the bare area on the right side (both ventrally and dorsally)
      - 9.1.1 **Right triangular ligament** *(ligamentum triangulare dextrum)*
        - a continuation to the right side as a peritoneal duplicature
  - 9.2 **Left coronary ligament** *(ligamentum coronarium sinistrum)*
    - borders the bare area on the left side (both ventrally and dorsally)
      - 9.2.1 **Left triangular ligament** *(ligamentum triangulare sinistrum)*
        - a continuation to the left side as a peritoneal duplicature

10 **Lesser omentum** *(omentum minus)* – a peritoneal duplicature between the oesophagus, stomach, duodenum and liver

11 **Hepato-oesophageal, hepatogastric and hepatoduodenal ligament**

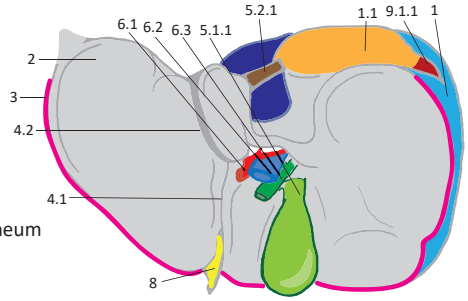

Inferior view of the visceral surface

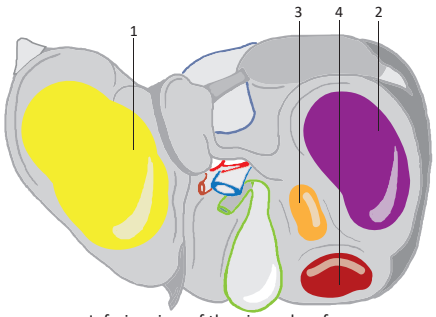

Inferior view of the visceral surface

Syntopy

Impressions on the visceral surface

- 1 **Gastric impression** *(impressio gastrica)* – an impression of the anterior wall of the stomach
- 2 **Renal and suprarenal impressions** *(impressio renalis et suprarenalis)* – impressions of the right kidney and right suprarenal gland
- 3 **Duodenal impression** *(impressio duodenalis)* – an impression of the ampulla of the duodenum
- 4 **Colic impression** *(impressio colica)* – an impression of the right colic flexure

5 **Oesophageal impression** *(impressio oesophagealis)* – an impression of the abdominal part of the oesophagus

Impressions on the diaphragmatic surface

6 **Cardiac impression** *(impressio cardiaca)* – an impression of the heart in the middle of the diaphragmatic surface – the heart exerts pressure on left hepatic lobe, between the heart and left hepatic lobe is the pericardium and diaphragm

This copy belongs to ali yaghoubi

Intrahepatic bile ducts

Intrahepatic bile ducts – the ducts collecting bile inside the liver

1. **Bile canaliculi / bile capillaries** (*canaliculi biliferi*) – hepatocytes produce bile and form the walls of the bile canaliculi, which flow into intralobular bile ducts
2. **Intralobular bile ducts** *(canales biliferi)* – at the periphery of the hepatic lobule the bile canaliculi transform into the short cholangiocyte-lined intralobular bile ducts
3. **Interlobular bile ducts** *(ductus biliferi interlobulares)* – are located in the portobiliary space, empty into the segmental ducts, which empty into the lobar ducts
4. **Right and left hepatic ducts** (*ductus hepaticus dexter et sinister*) – emerge from the liver at the porta hepatis

Blood supply

Functional circulation *(vasa publica)*

1. blood from the abdominal organs enters the liver via the hepatic portal vein
2. to the interlobular veins, which, at right angles, give off the circumlobular veins (venae circumlobulares) that surround the hepatic lobule and empty into the hepatic sinusoids via the precapillary veins
3. blood in the sinusoids supplies hepatocytes with oxygen and nutrients
4. and flows to the central vein, sublobular veins (venae sublobulares), hepatic veins and finally to the inferior vena cava

Nutritive circulation *(vasa privata)*

1. blood flows from the hepatic artery proper
2. to the interlobular arteries, which give of the circumlobulares arteries at right angles that flows via arterioles to the terminal parts of the hepatic portal system
3. the nutritive system oxygenates the wall of the veins and interstitial connective tissue and partially oxygenate hepatocytes (hepatocytes are mainly supplied by the portal venous blood)

Arterial supply: from the coeliac trunk
– proper hepatic artery (branch from the common hepatic artery)

Portal venous supply: from the hepatic portal vein
– the hepatic portal vein is formed by the superior mesenteric vein and splenic vein

Venous drainage: to the inferior vena cava
– right, left and intermediate hepatic veins
– usually two venous roots from the right side and one from the left side

Lymphatic drainage:
– to the hepatic and coeliac nodes
– also through the diaphragm to:
– anterior and posterior mediastinal nodes, anterior and posterior phrenic nodes, parasternal nodes

Innervation

Viscerosensory: right phrenic nerve

Parasympathetic: vagus nerve
– decreases glycogen and protein catabolism and increases production of bile

Sympathetic: thoracic splanchnic nerves
– decreases production of bile and increases glycogen and protein catabolism

Autonomic nerve fibers: supply the liver and gallbladder in a mixed hepatic plexus, passing via the coeliac ganglia and winding around the proper hepatic artery

Functions

1. **Bile production**
2. **Metabolism** of sacharides, lipids and amino acids
3. **Detoxification** of ammonia, alcohol and drugs
4. **Degradation** of hormones, heme and cholesterol
5. **Storage** of vitamins and glycogen
6. **Haematopoiesis** during fetal development

Cholékystis is the Greek term for gallbladder.

The mucosa of the gallbladder has columnar epithelium and displays macroscopic folding.

The spiral fold is a mucosal fold in the cystic duct, which allows bile to flow in both directions.

Hartmann's pouch is an out-pocketing of the gallbladder wall situated at the border between the neck of the gallbladder and first part of the cystic duct.

The sphincter of the ampulla is closed during the resting phase of digestion. This causes bile to accumulate in the bile duct and, after it reaches the level of the cystic duct, passively flow into the gallbladder.

The cystohepatic triangle of Calot is a topographical space bordered by the liver, common hepatic and cystic duct. It is a site for ligation of the cystic artery during cholecystectomy.

The liver is held in its position by the inferior vena cava, its adhesion to the diaphragm (bare area), support of the abdominal organs, the round ligament of the liver and other attachments.

The gallbladder projects on the anterior abdominal wall at Murphy's point, which is located at the intersection of the midclavicular line and costal margin.

The major duodenal papilla projects on the anterior abdominal wall at Desjardin's pancreatic point, which is located 6 cm from the umbilicus on a line connecting the umbilicus to the right axilla.

Clinical notes

Murphy's point may be sensitive on palpation (Murphy's sign). This indicates pathology of the gallbladder.

Cholelithiasis is the presence of bile stones in the gallbladder (cholecystolithiasis) or in the bile ducts (choledocholithiasis). This can cause inflammation of the gallbladder (cholecystitis), bile ducts (choledocholithitis) or pain, caused by the stone moving through the bile ducts (biliary colic).

Endoscopic retrograde cholangiopancreatography (ERCP) is an endoscopic technique that allows visualisation of the biliary tree and pancreas. It allows contrast material can be injected into the bile duct and pancreatic duct.

The gallbladder is an about 10 cm long blind sac with a volume of about 15 ml. It is located **in the fossa for the gallbladder on the visceral (inferior) surface of the liver**. **Bile is collected and concentrated** in the gallbladder. Almost the whole gallbladder is covered by the visceral peritoneum except part of its anterior wall, which is attached to the liver by connective tissue (there can be sometimes a short peritoneal duplication). The bile duct leads bile to the duodenum and to the gallbladder. Two types of the bile ducts exist: intrahepatic (inside the liver) and extrahepatic (outside the liver) bile ducts.

Structure

- 1 **Fundus** – located beyond the level of the inferior margin of the liver
- 2 **Body** *(corpus)* – located in the fossa for the gallbladder
- 3 **Infundibulum** – the part where the body continues to the neck
- 4 **Neck** *(collum)* – continues to the cystic duct

Syntopy

ventrally: the visceral surface of the liver
– the fundus is in contact with the anterior abdominal wall
dorsally: right colic flexure, transverse colon

Extrahepatic bile ducts

– course from the porta hepatis to the duodenum within the hepatoduodenal ligament

- 5 **Right hepatic duct** *(ductus hepaticus dexter)*
  – located on the right side of the porta hepatis
- 6 **Left hepatic duct** *(ductus hepaticus sinister)*
  – located on the left side of the porta hepatis
- 7 **Common hepatic duct** *(ductus hepaticus communis)*
  – formed by communion of the right and left hepatic ducts
- 8 **Cystic duct** *(ductus cysticus)* – connects the gallbladder to the common hepatic duct on the right side at a distance of about 4 cm from the porta hepatis
- 9 **Bile duct** *(ductus choledochus)* – formed by the common hepatic duct and cystic duct
  – is about 6–8 cm long and is divided into 4 parts:
  - 9.1 **Supraduodenal part** *(pars supraduodenalis)*
    – above the superior part of the duodenum
  - 9.2 **Retroduodenal part** *(pars retroduodenalis)*
    – behind the superior part of the duodenum
  - 9.3 **Pancreatic part** *(pars pancreatica)*
    – located in a groove between the descending part of the duodenum and head of the pancreas
    – elevates the longitudinal fold of the duodenum *(plica longitudinalis duodeni)*
  - 9.4 **Intramural part** *(pars intramuralis)*
    – passes inside the medial wall of the descending part of the duodenum

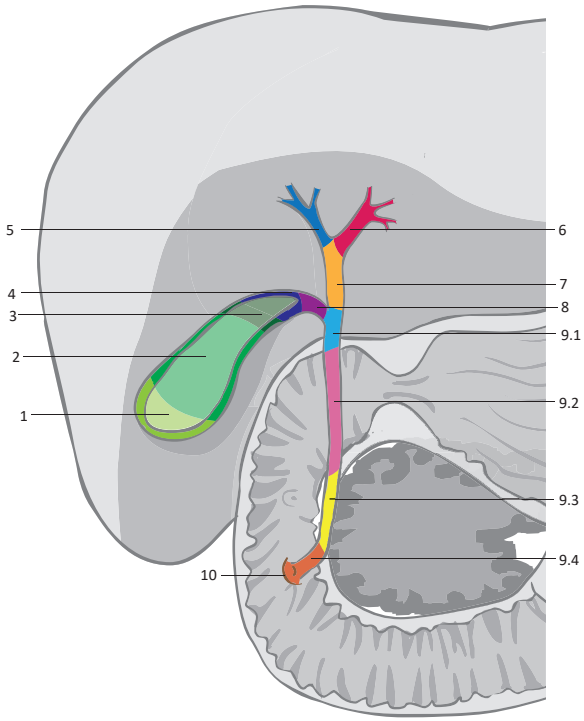

Gallbladder and bile ducts

Bile ducts termination

- 10 **Major duodenal papilla of Vater** *(papilla duodeni major)* – a mucous elevation located at the inferior border of the longitudinal fold of the duodenum in the lower half of the descending part of the duodenum, about 10 cm aboral to the pylorus
  – drains the bile duct and pancreatic duct
- 11 **Hepatopancreatic ampulla** *(ampulla hepatopancreatica)* – an enlargement at the union of the bile duct and pancreatic duct
- 12 **Sphincter of ampulla** *(musculus sphincter ampullae hepatopancreaticae)* – a sphincter surrounding the hepatopancreatic ampulla
- 13 **Sphincter of the bile duct / Sphincter of Oddi** *(musculus sphincter ductus choledochi)* – a sphincter at the distal end of the bile duct

Blood supply and innervation

Arterial supply: cystic artery (a branch of the right branch of the hepatic artery proper)
Venous drainage: cystic vein (to the portal vein)
Parasympathetic: vagus nerve (stimulates contractions of the gallbladder and relaxes the sphincter of the bile duct)
Sympathetic: thoracic splanchnic nerves (decrease contractions of the gallbladder and stimulate contraction of the sphincter of bile duct)
Viscerosensory: right phrenic nerve

This copy belongs to ali yaghoubi

The pancreas is a **secondary retroperitoneal** glandular organ located behind the stomach and in front of the inferior vena cava and abdominal aorta. It has both exocrine and endocrine functions. **The exocrine part** produces pancreatic juice that contains a variety of enzymes. Pancreatic juice flows into the duodenum. **The endocrine part** releases hormones into the blood. One of the important hormones it releases is **insulin**.

Structures

- 1 **Head of pancreas** *(caput pancreatis)* – the large and rounded part of the pancreas
  - is located in front of the body of vertebra L2 within the concavity of the duodenum
  - 1.1 **Pancreatic notch** *(incisura pancreatis)*
    - an notch on the inferior aspect of the pancreas between its head and body
  - 1.2 **Uncinate process** *(processus uncinatus)* – a extension of the head of the pancreas
    - passes behind the superior mesenteric vessels
- 2 **Body of pancreas** *(corpus pancreatis)* – the narrower and longer part of the pancreas
  - courses horizontally to the left side over the large vessels
  - 2.1 **Omental eminence** *(tuber omentale)*
    - a ventral prominence elevated by the abdominal aorta
- 3 **Tail of pancreas** *(cauda pancreatis)* – points towards the spleen, located intraperitoneally

Ducts

- 4 **Pancreatic duct / duct of Wirsung** *(ductus pancreaticus)*
  - about 10–12 cm long, runns along the whole length of the pancreas
  - runs dorsocaudally inside the head of the pancreas and emerges usually together with the bile duct (the hepatopancreatic ampulla) into the descending part of the duodenum on the major duodenal papilla
  - 4.1 **Sphincter of pancreatic duct** *(musculus sphincter ductus pancreatici)*
    - a sphincter at the distal end of the pancreatic duct
- 5 **Accessory pancreatic duct / duct of Santorini** *(ductus pancreaticus accessorius)*
  - is usually connected to the pancreatic duct but drains independently into the minor duodenal papilla

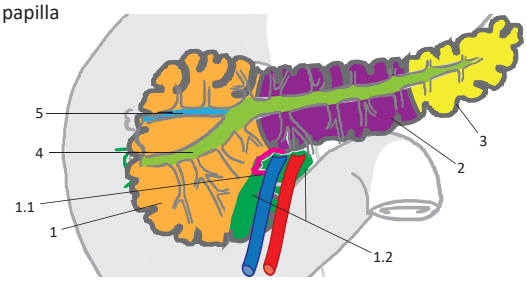

Pancreas located in the duodenal concavity

Syntopy

Head of pancreas

dorsally: bile duct, hepatic portal vein, inferior vena cava
ventrally: the root of the transverse mesocolon (via the omental bursa)

Body of pancreas

dorsally: abdominal aorta, superior mesenteric vessels, left renal vessels, left suprarenal gland
ventrally: stomach (via omental bursa)
cranially: on the upper border courses tortuous splenic artery (splenic vein runs behind the pancreas)
caudally: transverse colon, duodenojejunal flexure, jejunum

Blood supply and innervation

Arterial supply: coeliac trunk and superior mesenteric artery
- branches form anastomoses with each other
- the anterior and posterior superior pancreaticoduodenal artery (branches of the gastroduodenal artery) and the inferior pancreaticoduodenal artery (a branch of the superior mesenteric artery) supply the head of the pancreas
- pancreatic branches of the splenic artery (dorsal pancreatic artery, greater pancreatic artery, caudal pancreatic artery, inferior pancreatic artery) supply the body and tail of the pancreas

Venous drainage: to the splenic vein, superior mesenteric vein and then to the portal vein
Lymphatic drainage: hepatic, coeliac and pancreaticosplenic nodes
Sympathetic, parasympathetic and viscerosensory: pancreatic plexus (from the coeliac plexus)

The exocrine part of the pancreas is composed of the pancreatic acini which are made up by the serous cells. It is the major part of the pancreas.

The endocrine part of the pancreas is composed of about one million pancreatic islets of Langerhans. It represents only 1.5 % of the total pancreatic mass.

The duodenal window is a radiological term for the position of the head of the pancreas in the concavity of the duodenum at the level of L2.

The pancreas originates as two buds which merge during prenatal development. The ventral bud forms the inferior part of the head of the pancreas and its uncinate process and the dorsal bud form the superior part of the head, the body and the tail of the pancreas.

Divided pancreas (*pancreas divisum*) is a developmental defect presenting with a missing connection between the pancreatic duct and the ducts draining the body and tail. In this condition, most of the pancreatic juice is drained via the accessory pancreatic duct.

Anular pancreas (*pancreas anulare*) is a developmental defect characterised by a pancreas circumferentially surrounding the descending part of the duodenum. It can lead to constriction of the duodenal lumen.

Peritoneum consists the mesothelium supported by subserous connective tissue, which attaches the peritoneum to the surrounding structures. It contains blood and lymphatic vessels.

Mesothelium is a layer of simple squamous epithelium that produces peritoneal fluid. Mesothelial cells have the ability to absorb fluid.

The total area of the peritoneum is approximately 2 m^2.

Clinical notes

Tumors of the head of the pancreas can compress the bile duct leading to icterus (jaundice), compress the portal vein leading to portal hypertension and compress the pylorus or duodenum leading to obstruction of the passage of chyme.

Peritoneum is a **serous membrane** lining the abdominal cavity and part of the pelvic cavity. **The peritoneal cavity** is a space between the parietal and visceral peritoneum. **The parietal peritoneum** covers the abdominal walls and **the visceral peritoneum** covers organs. **Peritoneal duplicatures** are folds of peritoneum connecting the visceral to the parietal peritoneum. They **hold organs in their correct positions** and allow **blood vessels and nerves to pass to the organs**.

Principal parts

- 1 **Parietal peritoneum** *(peritoneum parietale)*
- 2 **Visceral peritoneum** *(peritoneum viscerale)*
- 3 **Peritoneal cavity** *(cavitas peritonealis)*
- 4 **Mesentery** *(mesenterium)* – a peritoneal duplicature
- 5 **Root of mesentery** *(radix mesenterii)*
  – the attachment of the duplicature to the posterior abdominal wall

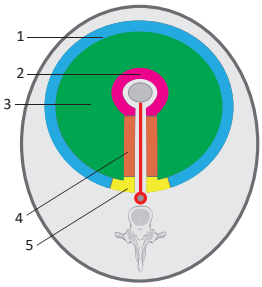

Scheme of peritoneum

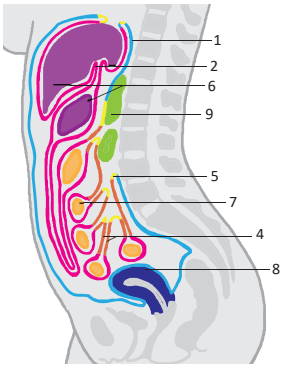

Sagittal section of the female body

Intraperitoneal organs and their duplicatures

- 6 **Supramesocolic part of peritoneal cavity**
  (pars supramesocolica cavitatis peritonealis)
  - 6.1 **Stomach** – gastrophrenic ligament, gastrosplenic ligament gastrocolic ligament, hepatogastric ligament
  - 6.2 **Oesophagus** – hepato-oesophageal ligament
  - 6.3 **Spleen** – phrenicosplenic ligament
  - 6.4 **Liver and gallbladder** – falciform ligament, coronary and triangular ligament, hepatorenal lig.
  - 6.5 **Pancreas** (tail only)
  - 6.6 **Duodenum** (ampulla only) – hepatoduodenal ligament, duodenorenal ligament
- 7 **Inframesocolic part of peritoneal cavity** *(pars inframesocolica cavitatis peritonealis)*
  - 7.1 **Jejunum and Ileum** – mesentery *(mesenterium)*
  - 7.2 **Caecum and vermiform appendix** – mesocaecum and mesoappendix
  - 7.3 **Transverse colon** – transverse mesocolon
  - 7.4 **Sigmoid colon** – sigmoid mesocolon
  - 7.5 **Rectum** (oral part only) – mesorectum
- 8 **Pelvic peritoneal cavity** *(cavitas peritonealis pelvis)*
  - 8.1 **Uterus and uterine tube** – mesometrium and mesosalpinx
  - 8.2 **Ovary** – mesovarium

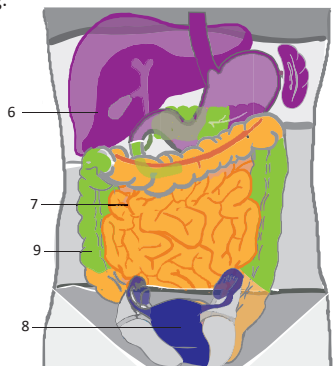

Abdominal and pelvic cavity of female

Secondary retroperitoneal organs and their origin

- 9 **Secondary retroperitoneal organs** – organs primary formed intraperitoneally but lose their peritoneal duplicature during development as they move to the retroperitoneal space
  - 9.1 **Ascending and descending colon** – only their anterior wall is covered by the visceral peritoneum
  - 9.2 **Pancreas** – except the tail
  - 9.3 **Duodenum** – except the ampulla

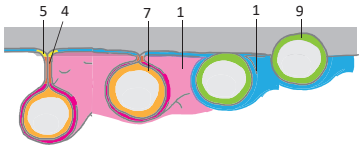

Origin of the secondary retroperitoneal organs

Principal structures and parts of the peritoneal cavity

- 1 **Greater omentum** *(omentum majus)* – a peritoneal duplicature extended from the greater curvature of the stomach to the transverse colon, it hangs in front of the small intestine
- 2 **Lesser omentum** *(omentum minus)* – a peritoneal duplicature extended between the liver and the oesophagus, stomach (lesser curvature) and duodenum
- 3 **Hepatoduodenal ligament** *(ligamentum hepatoduodenale)* – the right margin of the lesser omentum containing the following structures: portal vein, proper hepatic artery, bile duct
- 4 **Omental bursa / lesser sac** *(bursa omentalis)* – the space behind the stomach in the supramesocolic part of the peritoneal cavity
- 5 **Root of transverse mesocolon** *(radix mesocoli transversi)*
  – an attachment ofthe transverse mesocolon which divides the peritoneal cavity into two parts – supramesocolic and inframesocolic part
- 6 **Root of mesentery** *(radix mesenterii)* – attachment of the peritoneal duplicature for the jejunum and ileum (mesentery)
- 7 **Right paracolic space** – the right part of the inframesocolic part
- 8 **Left paracolic space** – the left part of the inframesocolic part, communicates with the pelvic peritoneal cavity
- 9 **Rectouterine pouch of Douglas** *(excavatio rectouterina)* **/ Rectovesical pouch of Proust** *(excavatio rectovesicalis)*
  – the lowest part of the peritoneal cavity in female/male

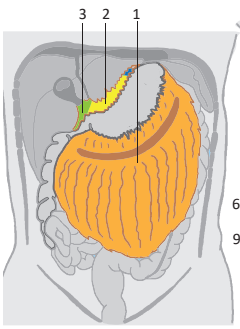

Greater omentum, anterior view

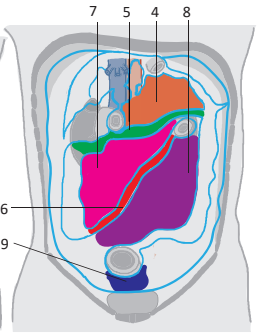

Parietal peritoneum on the posterior abdominal wall, anterior view

This copy belongs to ali yaghoubi

I. General overview of the digestive system

1. State the four principal parts of the digestive tract. (p. 171)

II. Mouth

2. State and explain the deciduous and permanent dental formulae. (p. 175)
3. Explain the innervation of the tongue. (p. 177)
4. State the topographic structures and spaces located lateral to the palatine tonsil. (p. 178)
5. List the 5 muscles of the soft palate and fauces and give their innervation. (p. 179)
6. List the three major salivary glands and describe the topography of their ducts. (p. 180–181)

III. Pharynx

7. Describe the insertion of the pharynx on the skull. (p. 183)
8. List the three sinuses which communicate with the lumen of the pharynx. (p. 182)
9. List the constrictors and levators of the pharynx and their innervation. (p. 184)

IV. Oesophagus

10. Explain the three main narrowings of the oesophagus. (p. 185)
11. Explain the term "oesophageal varices". (p. 184)
12. Describe the relationship between the oesophagus and trachea, and the oesophagus and pericardium. (p. 185)
13. State the venous plexuses located the oesophagus. (p. 185)

V. Stomach

14. State the organs, which are in contact with the posterior wall of the stomach. (p. 186)
15. List the 4 arteries, which form anastomotic arches on the curvatures of the stomach. (p. 187)
16. Explain the anatomical principle of the closure of the sphincters between the stomach and oesophagus and between the stomach and duodenum. (p. 184, p. 186)
17. Describe the arterial supply of the stomach. (p. 187)

VI. Small intestine

18. List 4 structures located dorsal to the superior part of the duodenum. (p. 189)
19. Describe the topography and content of the root of the mesentery. (p. 188)
20. Define the principal morphological differences between the jejunum and ileum. (p. 190)
21. State the principal arteries that supply the duodenum. (p. 189)

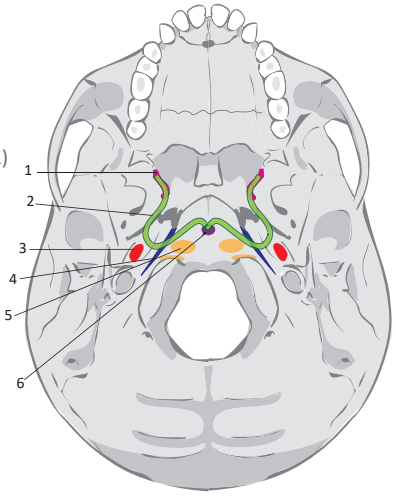

Describe the insertion of the pharynx on the cranial base

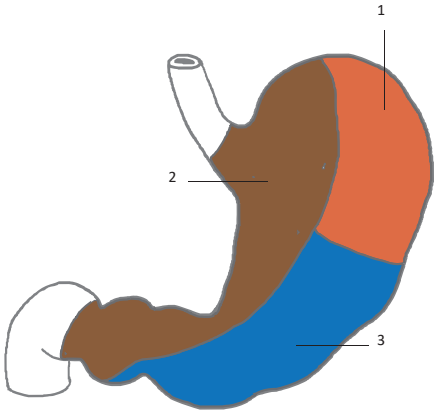

Describe the syntopy of the anterior wall of the stomach

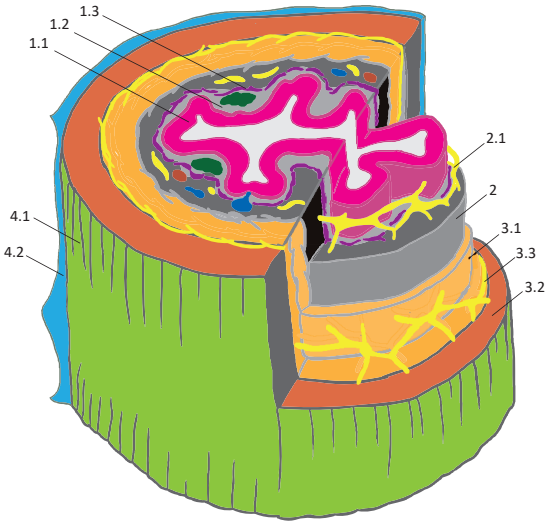

Describe the histology of the digestive tract

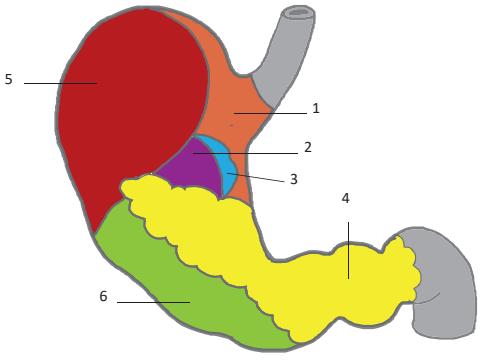

Describe the syntopy of the posterior wall of the stomach

VII. Large intestine

22. Describe the course of the root of the transverse mesolocon. (p. 194)
23. State 2 structures, which are located dorsal to the rectum. (p. 195)
24. List the structures and spaces that are located ventral to the rectum in the male. (p. 195)
25. Name the structures and spaces which are located ventral to the rectum in the female. (p. 195)
26. Define the most common positions of the vermiform appendix. (p. 193)
27. Describe the points of projection of the vermiform appendix on the anterior abdominal wall. (p. 193)
28. State the branches of the superior mesenteric artery supplying the large intestine. (p. 192)
29. State the branches of the inferior mesenteric artery supplying the large intestine. (p. 192)
30. State the principal arterial branches supplying the rectum. (p. 192)

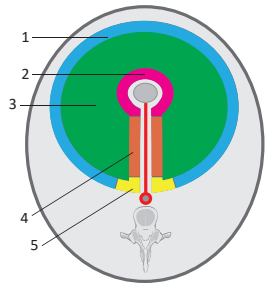

Describe the scheme of the peritoneum

VIII. Liver

31. State 5 impressions of organs on the visceral surface of the liver. (p. 197)
32. Explain the term "portal triad". (p. 196)
33. Explain the difference between the coronary and triangular ligaments. (p. 197)
34. Describe the two types of blood circulation in the liver. (p. 198)

IX. Gallbladder

35. List the 5 parts of the extrahepatic bile ducts. (p. 199)
36. List the 4 parts of the bile duct. (p. 199)
37. Explain the abbreviation „ERCP". (p. 198)

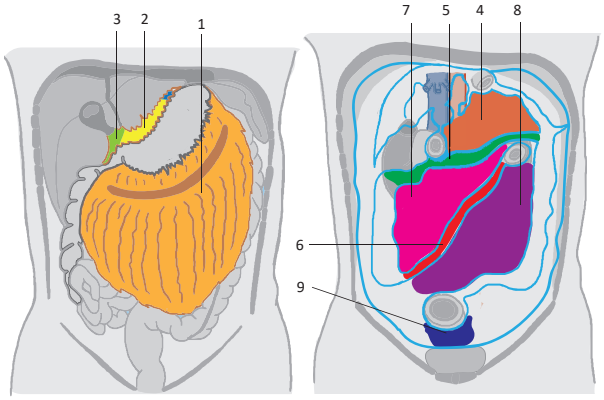

Describe the principal structures and parts of the peritoneal cavity

X. Pancreas

38. Explain the topographic relationship between the pancreas and duodenum. (p. 188, 200)
39. Name the ducts of the pancreas and describe how and where they open. (p. 200)
40. List the branches of the coeliac trunk that supply the pancreas. (p. 200)
41. List the branches of the superior mesenteric artery that supply the pancreas. (p. 200)
42. List the branches of the splenic artery that supply the pancreas. (p. 200)

XI. Peritoneum

43. Explain the terms "intraperitoneal", "primary retroperitoneal" and "secondary retroperitoneal" (p. 201)
44. State 4 secondary retroperitoneal organs. (p. 201)
45. Describe the histology of the peritoneum. (p. 200)

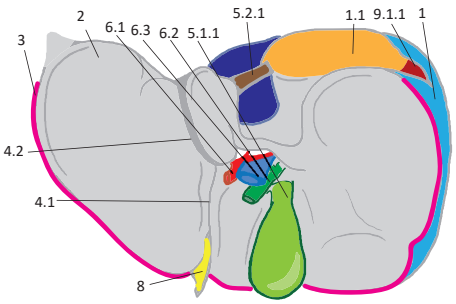

Describe the visceral surface of the liver

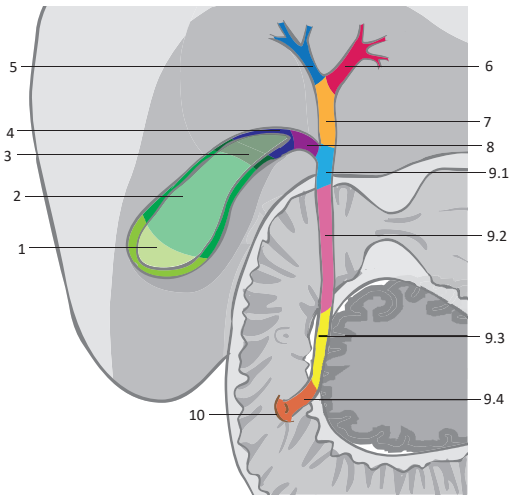

Describe the parts of the gallbladder and the extrahepatic bile ducts

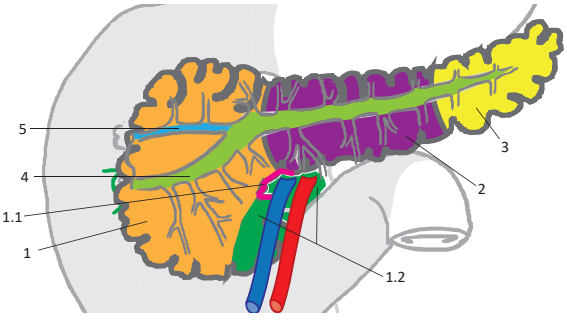

Describe the principal parts of the pancreas and its relationship to the duodenum

This copy belongs to ali yaghoubi

We would like to **thank the following anatomists, physicians and medical students** for their invaluable help, devotion and feedback in the preparation of this chapter.

Anatomists

Assoc. prof. Václav Báča, MD, PhD – Department of Anatomy, Third Faculty of Medicine, Prague, Czech Republic
Marcela Bezdíčková, DSc, PhD – Department of Anatomy, Faculty of Medicine and Dentistry, Palacký University Olomouc, Czech Republic
Assoc. prof. Dr. Med. Dzintra Kažoka – Institute of Anatomy and Anthropology, Riga Stradiņš University, Latvia
Assoc. prof. Ayhan Cömert, MD – Ankara Üniversitesi Tıp Fakültesi Anatomi Anabilim Dalı, Turkey
Assoc. prof. Nihal Apaydın, MD – Ankara Üniversitesi Tıp Fakültesi Anatomi Anabilim Dalı, Turkey
Lada Eberlová, MD, PhD – Department of Anatomy, Charles University, Pilsen, Czech Republic

Clinicians

Markéta Ječmenová, MD – Hepatogastroenterology Clinic, University Hospital Brno, Czech Republic

Medical students

Adéla Kuklová
Prokop Vodička
Lucia Mládenková
Linda Kašičková
Danil Yershov
René Novysedlák

13 References

1. AGUR, A. M. R. and A. F. DALLEY. Grant's Atlas of Anatomy. 13th Ed. Philadelphia: Lippincot Williams & Wilkins, 2012, 888 p. ISBN 978-1-60831-756-1.
2. CHUNG, K. W.; CHUNG, H. M. and N. L. HALLIDAY. BRS Gross Anatomy. 8th Ed. Philadelphia: Lippincott Williams & Wilkins, 2015. 544 p. ISBN 978-1-4511-9307-7.
3. LANZ, T. and W. WACHSMUTH. Praktische Anatomie. 7 bands. Berlin: Springer, 2003, 3658 p. ISBN 978-3-540-40571-9.
4. MILLS, S. E. Histology for pathologists. 4th Ed. Philadelphia: Lippincot Williams & Wilkins, 2012. 1328 p. ISBN-13: 978-1-4511-1303-7.
5. NETTER, F. H. Atlas of Human Anatomy. Professional Edition. 6th Ed. Oxford: Elsevier. 2014. 640 p. ISBN 978-1-455-75888-3.
6. ROHEN, J. W. LUTJEN-DRECOLL, E. and C. YOKOCHI. Color Atlas of Anatomy: A Photographic Study of the Human Body. 7th Ed. Stuttgart: Lippincot Williams & Wilkins, 532 p. ISBN 978-1-58255-856-1.
7. SNELL, R. S. Clinical anatomy by regions. 9th Ed. Philadelphia: Lippincott Williams & Wilkins, 2012. 768 p. ISBN 978-1-60913-446-4.
8. WILLIAMS, P. L., ed. Gray´s Anatomy: the anatomical basis of medicine and surgery. 38th Ed. New York: Churchill Livingstone, 1995, 2092 p. ISBN 0-443-05717-6.

Memorix Anatomy

6 Respiratory system

Ladislav Douda
David Kachlík
Radovan Hudák
Ondřej Volný
Vojtěch Kunc
Adam Whitley

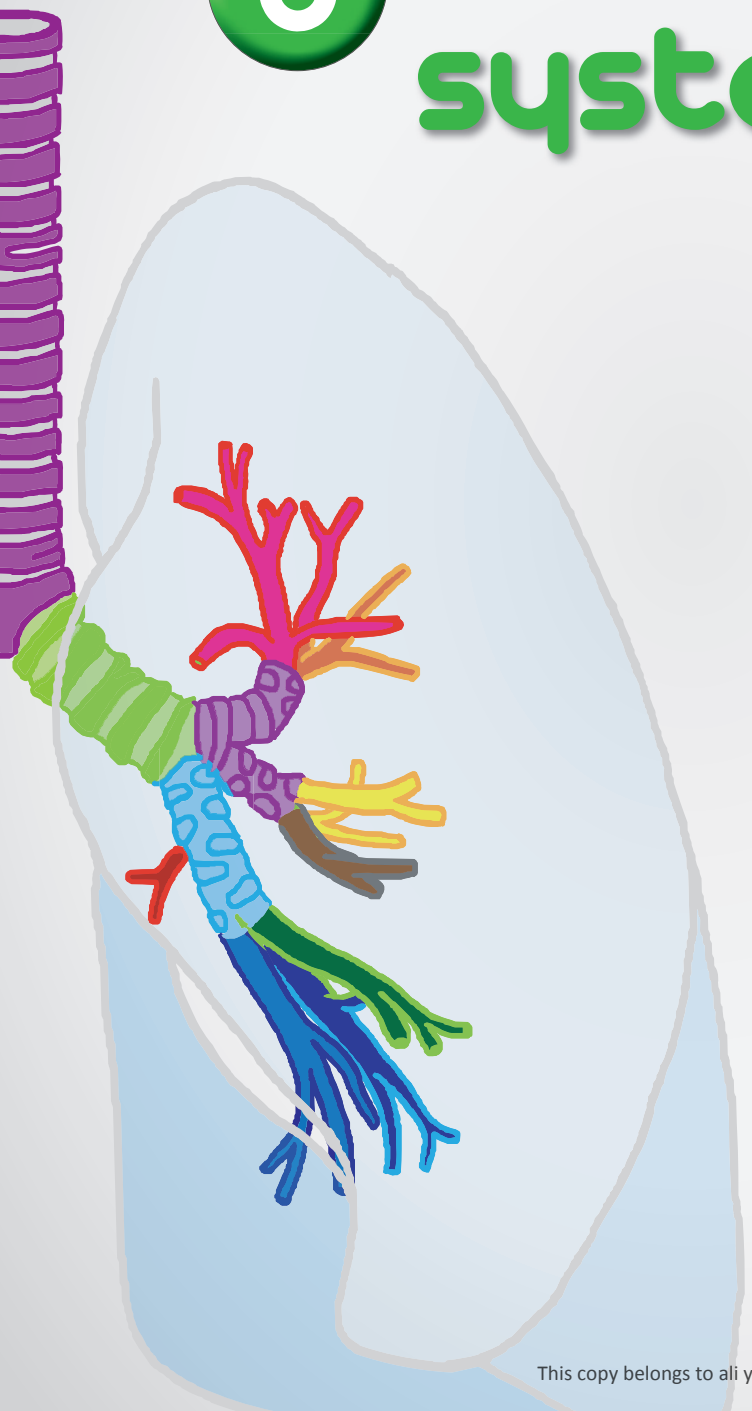

General overview	206
Nose	206
Nasal cavity	207
Paranasal sinuses	208
Pharynx	209
Larynx	210
Trachea	214
Bronchi	215
Lungs	216
Pleura	220
Mechanics of breathing	221
Table	222
Review questions and figures	222
Acknowledgements	224

This copy belongs to ali yaghoubi

The respiratory tract is a tree of ducts, which is divided into the **upper and lower airways**. Anatomically, the upper respiratory tract ends with the laryngopharynx; clinically, it includes the larynx and the cervical part of the trachea. The wall of the airways is strengthened by cartilage and elastic fibres, which protect the airway from collapse and provide elasticity. The respiratory system is responsible for the **exchange of gases** between the **air and blood, voice production, maintenance of acid-base balance** and **elimination of substances**.

Basic parts

Upper respiratory tract

- 1 **Nasal cavity** *(cavitas nasi)*
  - 1.1 **Paranasal sinuses** *(sinus paranasales)*
- 2 **Pharynx**
  - 2.1 **Nasopharynx** *(pars nasalis pharyngis)*
  - 2.2 **Oropharynx** *(pars oralis pharyngis)*
  - 2.3 **Laryngopharynx or hypopharynx** *(pars laryngea pharyngis)*

Lower respiratory tract

- 3 **Larynx**
- 4 **Trachea**
- 5 **Bronchi**
- 6 **Lungs** *(pulmones)*

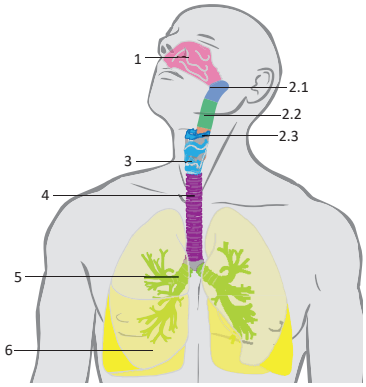

Rhinos is the Greek term for nose.

During ontogenetic development, the ventral aspect of the foregut forms the laryngotracheal groove, which gives rise to the larynx, trachea, bronchi and lungs.

The airways are almost entirely lined by mucosa with pseudostratified ciliated columnar epithelium. Coordinated ciliary movements ("mucociliary escalator") beat a layer of secreted mucus towards the pharynx, cleaning the airways.

The olfactory region *(regio olfactoria)* comprises the mucosa of the ceiling of the nasal cavity and the upper third of the nasal septum. It is lined with olfactory epithelium, which is specialised sensory pseudostratified ciliated columnar epithelium. The supporting cells contain lipofuscin granules, imparting a yellowish colour to the mucosa.

The respiratory region *(regio respiratoria)* constitutes all the mucosa of the nasal cavity excluding the olfactory region. It is lined by pseudostratified ciliated columnar epithelium.

The nasal vestibule contains thick hairs (*vibrissae*), which mechanically prevent particles from entering the nasal cavity.

The vomeronasal cartilage (*cartilago vomeronasalis*) is a minor paired cartilage, which is fixed to the septal nasal cartilage. It is rudimentary and insignificant in humans.

In plastic surgery, the columella is described as the skin that overlies the outer margin of the nasal septum.

2 Nose – Nasus

The nose has **a bony and cartilaginous base** of a triangular shape. The skin of the nose is **rich in sebaceous glands**. The skin overlying the bony part is movable, while the skin overlying cartilaginous part is firmly fixed. The muscles of facial expression inserting into the nose constrict and flare the nostrils.

Basic parts

- 1 **Root of nose** *(radix nasi)*
- 2 **Dorsum of nose / bridge of nose** *(dorsum nasi)*
- 3 **Apex of nose / tip of nose** *(apex nasi)*
- 4 **Ala of nose / wing of nose** (*ala nasi*)
- 5 **Nostrils** *(nares)*
- 6 **Nasal septum** *(septum nasi)*

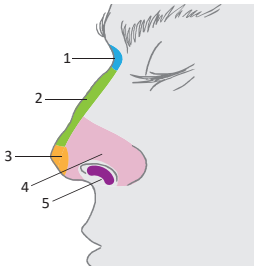

Structure

- 1 **Nasal bone** *(os nasale dextrum et sinistrum)*
- 2 **Nasal cartilages** *(cartilagines nasi)*
  - 2.1 **Lateral nasal cartilage** *(cartilago nasi lateralis)*
  - 2.2 **Major alar cartilage with medial and lateral crus** *(cartilago alaris major – crus mediale et laterale)*
  - 2.3 **Minor alar cartilages** *(cartilagines alares minores)*
  - 2.4 **Septal nasal cartilage** *(cartilago septi nasi)*
  - 2.5 **Accessory nasal cartilages** *(cartilagines nasales accessoriae)*

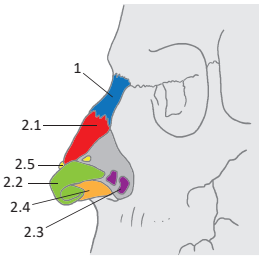

Vascular supply and innervation

Arterial supply: angular artery (facial artery), infraorbital artery (maxillary artery), supratrochlear and infratrochlear arteries (ophtalmic artery)
Venous drainage: facial vein, inferior ophthalmic vein, pterygoid plexus
Lymphatic drainage: submandibular nodes
Somatomotor (branchiomotor): nasal muscles of facial expression (facial nerve)
Somatosensory: ophthalmic nerve, maxillary nerve (trigeminal nerve)

Clinical notes

The nasal cavity can be surgically approached externally (the classic approach) or endoscopically and microscopically (functional endoscopic sinus surgery).

The pituitary gland may be surgically approached through the nasal cavity and sphenoidal sinus.

A deviated nasal septum may, during inflammation or oedema, obstruct half of the nasal cavity or block the openings of the paranasal sinuses.

Liquorrhoea is leakage of cerebrospinal fluid from the subarachnoid space. In fractures or surgeries affecting the anterior cranial fossa, cerebrospinal fluid may leak from the nose (nasal liquorrhoea).

The nasal cavity is open through the nostrils to the external environment. Dorsally, it communicates with the **nasopharynx** through the posterior nasal **apertures.** It is divided sagittally by the **nasal septum**, which is composed of cartilage ventrally and bone dorsally. The floor of the nasal cavity is formed by the palate. The three **conchae** (inferior, medial and superior) protrude from the lateral wall and divide the cavity into four groove-like air passages, the inferior, middle, superior and common meatuses, which communicate with the **paranasal sinuses and the nasolacrimal duct**. The roof is formed by the base of the anterior cranial fossa and is involved in **olfaction**. The nasal cavity serves to **heat and humidify inspired air**, and mechanically blocks particles from entering.

Basic parts

- 1 **Nasal vestibule** *(vestibulum nasi)* – from the nostrils to the upper edge of the major alar cartilage
  - 1.1 **Limen nasi** – the border between the nasal vestibule and the nasal cavity proper – a ridge formed by the upper edge of the major alar cartilage
  - 1.2 **Apical recess** *(recessus apicis nasi)* – a ventral projection (cul-de-sac) of the vestibule into the nasal apex
- 2 **Nasal cavity proper** *(cavitas nasi propria)*
  - 2.1 **Piriform aperture** *(apertura piriformis)* – the bony entrance of the nasal cavity proper
  - 2.2 **Nasal conchae/turbinates** *(conchae nasales)*
  - 2.3 **Posterior nasal apertures / choanae** – communicate with the nasopharynx
  - 2.4 **Olfactory region** *(regio olfactoria)* – olfactory epithelium with the olfactory receptors

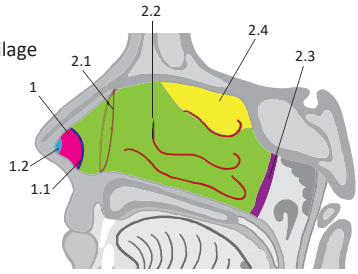

Sagittal section of the nasal cavity

Syntopy

1 **Cranially:** anterior cranial fossa (via cribriform plate of ethmoidal bone)
2 **Caudally:** oral cavity (via hard palate)
3 **Laterocranially:** orbit (via ethmoidal bone)
4 **Laterocaudally:** maxillary sinus
5 **Ventrally:** nose
6 **Dorsally:** nasopharynx (via choanae)

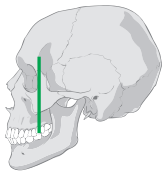

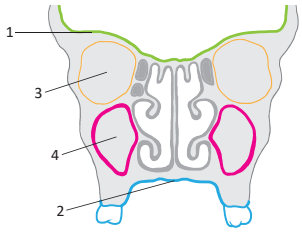

Frontal section of the nasal cavity

Borders

1 **Roof**
- 1.1 **Lateral nasal cartilage** *(cartilago nasi lateralis)*
- 1.2 **Nasal bone** *(os nasale)*
- 1.3 **Nasal part of frontal bone** *(pars nasalis ossis frontalis)*
- 1.4 **Cribriform plate of ethmoidal bone** *(lamina cribrosa ossis ethmoidalis)*
- 1.5 **Body of sphenoid** *(corpus ossis sphenoidalis)*

2 **Floor**
- 2.1 **Incisive bone** *(premaxilla / os incisivum)*
- 2.2 **Palatine process of maxilla** *(processus palatinus maxillae)*
- 2.3 **Horizontal plate of palatine bone** *(lamina horizontalis ossis palatini)*

3 **Lateral wall**
- 3.1 **Cartilaginous nasal wall**
- 3.2 **Frontal process of maxilla** *(processus frontalis maxillae)*
- 3.3 **Body of maxilla** *(corpus maxillae)*
- 3.4 **Inferior nasal concha** *(concha nasalis inferior)* – fixed to the maxilla
- 3.5 **Lacrimal bone** *(os lacrimale)*
- 3.6 **Ethmoidal labyrinth** *(labyrinthus ethmoidalis)*
- 3.7 **Perpendicular plate of palatine bone** *(lamina perpendicularis ossis palatini)*
- 3.8 **Medial plate of pterygoid process of sphenoid** *(lamina medialis processus pterygoidei ossis sphenoidalis)*

4 **Medial wall** – nasal septum *(septum nasi)*
- 4.1 **Bony part** *(pars ossea)*
  - 4.1.1 **Vomer**
  - 4.1.2 **Perpendicular plate of ethmoid** *(lamina perpendicularis ossis ethmoidalis)*
- 4.2 **Cartilaginous part** *(pars cartilaginea)*
  - 4.2.1 **Septal nasal cartilage** *(cartilago septi nasi)*
- 4.3 **Membranous part** *(pars membranacea)* – fibrous part between the nostrils
- 4.4 **Cutaneous part** *(pars cutanea)* – outer part between the nostrils

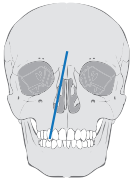

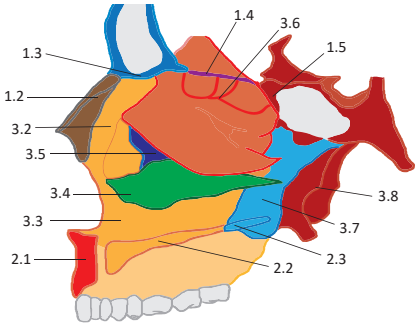

Oblique section of the nasal cavity

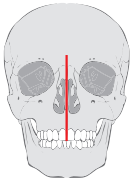

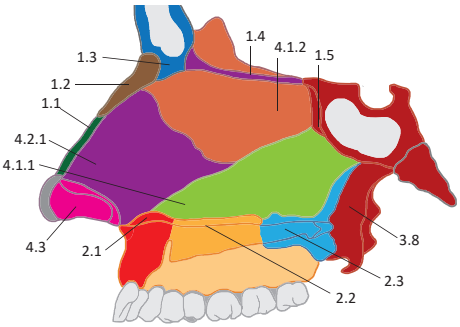

Sagittal view of the nasal septum

This copy belongs to ali yaghoubi

Nasal conchae or turbinates *(conchae nasales)*

- 1 **Superior nasal concha** *(concha nasalis superior)* – the smallest concha,
  – a part of the ethmoidal bone
- 2 **Middle nasal concha** *(concha nasalis media)* – a part of the ethmoidal bone
- 3 **Inferior nasal concha** *(concha nasalis inferior)* – a separate bone joined to the maxilla

Nasal meatus *(meatus nasi)*

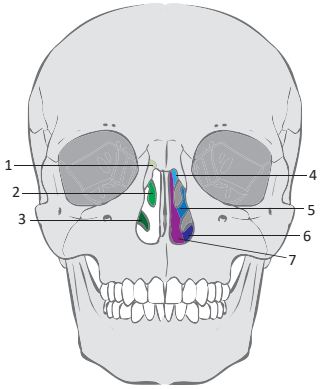

- 4 **Superior nasal meatus** *(meatus nasi superior)*
  – is located between the roof of the nasal cavity and the middle nasal concha
  – contains the openings of the sphenoid sinus and posterior ethmoidal air cells
- 5 **Middle nasal meatus** *(meatus nasi medius)*
  – is located between the middle and inferior nasal conchae
  – contains the openings of the frontal sinus, maxillary sinus and anterior and middle ethmoidal air cells
- 6 **Inferior nasal meatus** *(meatus nasi inferior)*
  – is located between the inferior nasal concha and the floor of the nasal cavity
  – contains the opening of the nasolacrimal duct
- 7 **Common nasal meatus** *(meatus nasi communis)* –is located between the medial ends of the conchae and the nasal septum

8 **Nasopharyngeal meatus** *(meatus nasopharyngeus)*
– a space between the dorsal ends of the conchae and the choanae

Vascular supply

Arterial supply: anterior and posterior ethmoidal arteries (ophthalmic artery), descending palatine artery (maxillary artery), sphenopalatine artery (maxillary artery), facial artery
Venous drainage: facial vein, ethmoidal veins, pterygoid plexus, pharyngeal plexus
Lymphatic drainage: retropharyngeal nodes and deep anterior cervical nodes

Innervation

Somatosensory: anterior ethmoidal nerve (ophthalmic nerve), posterior nasal branches and infraorbital nerve (maxillary nerve)
Visceromotor sympathetic: periarterial plexuses and deep petrosal nerve
Visceromotor parasympathetic: facial nerve
Special sensory: olfactory nerve

The semilunar hiatus is the opening of the maxillary sinus, frontal sinus and anterior and middle ethmoidal air cells into the middle nasal meatus.

The sphenoethmoidal recess is the dorsocranial projection of the nasal cavity towards the upper end of the anterior aspect of the sphenoid bone. The sphenoidal sinus opens here through the superior nasal meatus.

The cavernous plexuses of the conchae are vascular plexuses on the conchae.
Kiesselbach's plexus is located on the cartilaginous septum near the anterior end of the inferior nasal concha. It is a frequent source of nasal bleeding (epistaxis). It is supplied by 5 arteries: superior labial, anterior and posterior ethmoidal, sphenopalatine and greater palatine.
Woodruff's plexus is a venous plexus on the dorsal end of the inferior nasal concha, which may be a source of venous bleeding.

The paranasal sinuses arise as outgrowths of the nasal mucosa into the neighbouring bones. They are therefore covered by mucosa with respiratory epithelium. They develop mostly after birth; the newborn has only very rudimentary ethmoidal air cells and maxillary sinuses.

Clinical notes

During inflammation of the paranasal sinuses (sinusitis), percussion over the sinus becomes painful. The inflammation may erode the thin bone and enter the cranial cavity or the orbit. An X-ray may show opacity of the sinus.

During inflammation of the frontal sinus (frontal sinusitis), palpation of the ophthalmic nerve (N. V_1) may produce pain
During inflammation of the maxillary sinus (maxillary sinusitis), palpation of the maxillary nerve (N. V_2) may produce pain.
During inflammation of the ethmoidal air cells, the nasal root may be tender to palpation.

The maxillary sinus is closely related to the roots of the upper teeth, especially the canine, which has the longest root.

The ethmoidal air cells are separated from the orbit by the very thin orbital plate of the ethmoid (*lamina orbitalis ossis ethmoidalis* or, the obsolete term, *lamina papyracea*). Infection may, especially in young children, erode the thin bone and spread into the orbit and cause orbital cellulitis.

4 Paranasal sinuses – Sinus paranasales

The paranasal sinuses are air filled cavities within the bones of the skull. They **increase the resonance of voice** and **decrease the weight of the skull.**

Paranasal sinuses

- 1 **Frontal sinus** *(sinus frontalis)*
  - opens into the middle nasal meatus
- 2 **Maxillary sinus** *(sinus maxillaris)*
  - opens into the middle nasal meatus

3 **Ethmoidal air cells** *(cellulae ethmoidales)*
- 3.1 **Anterior and middle ethmoidal air cells** *(cellulae ethmoidales anteriores et mediae)*
  - open into the middle nasal meatus
- 3.2 **Posterior ethmoidal air cells** *(cellulae ethmoidales posteriores)*
  - open into the superior nasal meatus

- 4 **Sphenoid sinus** *(sinus sphenoidalis)*
  - opens into the superior nasal meatus

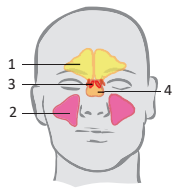

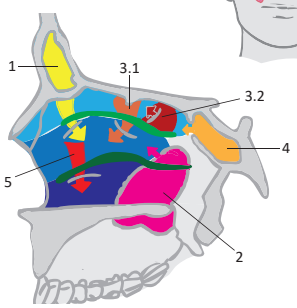

Lacrimal drainage

- 5 **Nasolacrimal duct** *(ductus nasolacrimalis)*
  - drains into the inferior nasal meatus

The pharynx is a muscular funnel-shaped organ attached to the base of the skull. Caudally it **continues as the oesophagus.** Ventrally it communicates with the nasal, oral and laryngeal cavities. The oral and laryngeal parts of the pharynx are components of both the gastrointestinal and respiratory tracts. The function of the pharynx is based on **two types of paired muscles**: **levators and constrictors**. The pharynx has an important role in **swallowing, speaking and breathing.**

Division and communications

- 1 **Nasopharynx** *(pars nasalis pharyngis)*
  – communicates with the nasal cavity through the choanae
- 2 **Oropharynx** *(pars oralis pharyngis)*
  – communicates with the oral cavity through the isthmus of fauces
- 3 **Laryngopharynx** *(pars laryngea pharyngis)*
  – communicates with the laryngeal cavity through the laryngeal inlet

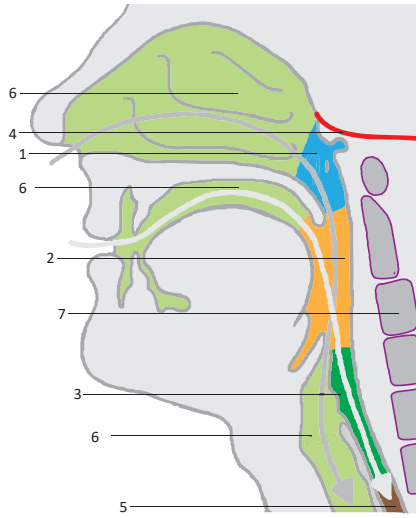

Sagittal section of the head and neck

Syntopy

- 4 **Cranially:** cranial base
- 5 **Caudally:** at the level of the vertebra C6 continues as the oesophagus
- 6 **Ventrally:** opens into the nasal, oral and laryngeal cavities
- 7 **Dorsally:** vertebral column

Nasopharynx *(epipharynx / pars nasalis pharyngis)*

Borders

Cranially: attached to the cranial base
Caudally: extends to the dorsal part of the soft palate
Ventrally: communicates with the nasal cavity through the choanae

Structures

- 1 **Vault of pharynx** *(fornix pharyngis)*
  – is attached to the cranial base
  – has a ventrally opened concavity
- 2 **Pharyngeal tonsil** *(tonsilla pharyngea)*
  – an unpaired tonsil in the mucosa of the dorsocranial part of the vault of the pharynx
- 3 **Pharyngeal opening of auditory tuba** *(ostium pharyngeum tubae auditivae)*
  – the opening of the auditory tube on the lateral side of the nasopharynx
- 4 **Torus tubarius** – an elevation of mucosa behind the opening of the auditory tube formed by the medial lamina of the cartilaginous part of the auditory tube
- 5 **Salpingopharyngeal fold** *(plica salpingopharyngea)*
  – a fold formed by the salpingopharyngeus muscle, extending caudally from the torus tubarius
- 6 **Salpingopalatine fold** *(plica salpingopalatina)*
  – a fold extending from the pharyngeal opening of the auditory tube to the soft palate
- 7 **Torus levatorius** – a ridge between the salpingopalatine and salpingopharyngeal folds beneath the opening of the auditory tube, formed by the levator veli palatini
- 8 **Tubal tonsil** *(tonsilla tubaria)*
  – a paired tonsil around the opening of the auditory tube

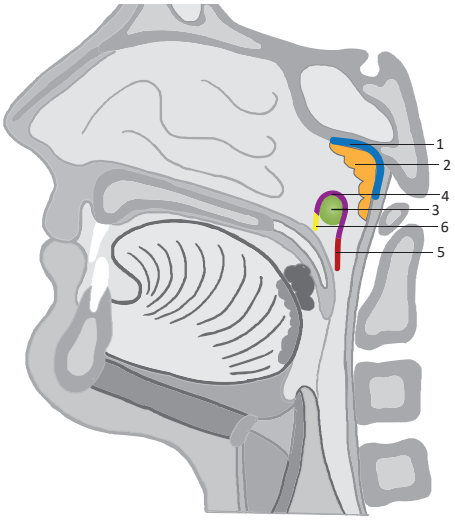

Sagittal section of the head and neck

Oropharynx *(pars oralis pharyngis)*

Cranially: the dorsal end of the soft palate (at the level of the vertebra C2)
Caudally: the upper edge of the epiglottis (at the level of the vertebra C4)
Ventrally: opens into the oral cavity through the isthmus of fauces

Laryngopharynx *(hypopharynx / pars laryngea pharyngis)*

Cranially: the upper edge of the epiglottis
Caudally: ends at the level of the vertebra C6, where it continues as the esophagus
Ventrally: opens into the laryngeal cavity through the laryngeal inlet

This copy belongs to ali yaghoubi

The larynx is **a hollow organ attached to the hyoid bone**. It **communicates cranially with the laryngopharynx and caudally it continues as the trachea**. The laryngeal skeleton **consists of a system of cartilages** connected by ligaments and joints. The movement of the cartilages is provided by skeletal muscles. The larynx has two surfaces: an inner surface covered by mucosa and an outer surface covered by adventitia. The larynx plays a role in **breathing** and is the main organ of **phonation.**

Laryngeal cavity (*cavitas laryngis*)

- 1 **Laryngeal inlet** (*aditus laryngis*) – an opening in the ventral wall of the laryngopharynx that connects the pharynx to the larynx
- 2 **Laryngeal vestibule** (*vestibulum laryngis*) – a space between the laryngeal inlet and the rima vestibuli
- 3**Vestibular folds** (*plicae vestibulares*)
  – paired mucosal folds
  - 3.1 **Vestibular ligaments / false vocal cords** (*ligamenta vestibularia*)
    – ligaments forming the vestibular folds
  - 3.2 **Rima vestibuli** (*rima vestibuli*)
    – a space between the vestibular folds
- 4 **Glottis** – a space between the vestibular folds cranially and the vocal folds caudally
  - 4.1 **Laryngeal ventricle** (*ventriculus laryngis*)
    – the lateral recess of the glottis
- 5 **Vocal folds / true vocal cords** *(plicae vocales)*
  – paired mucous folds between the thyroid and arytenoid cartilages
  - 5.1 **Vocal ligaments** (*ligamenta vocalia*)
    – form the base of the vocal folds
  - 5.2 **Rima glottidis** – a space between the vocal folds
- 6 **Infraglottic cavity** (*cavitas infraglottica*)
  – a space below the rima glottidis

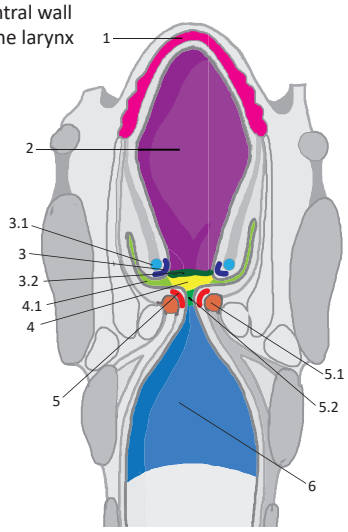

Frontal section of the larynx, posterior view

Laryngoscopic view of the glottis

Borders of the laryngeal inlet

- 1 **Epiglottis** – ventrocranially
- 2 **Aryepiglottic fold** (*plica aryepiglottica*) – laterally
- 3 **Cuneiform tubercle** (*tuberculum cuneiforme*) – laterally
- 4 **Corniculate tubercle** (*tuberculum corniculatum*) – laterally
- 5 **Interarytenoid notch** (*incisura interarytenoidea*)
  – dorsocaudally

Ligaments of the rima glottidis

- 6 **Vestibular folds** (*plicae vestibulares*)
- 7 **Vocal folds** (*plicae vocales*)
- 8 **Rima glottidis**

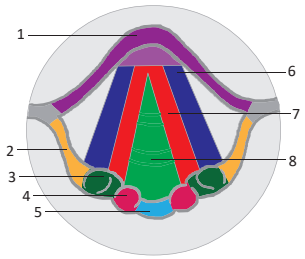

Laryngoscopic view of the glottis

Syntopy

- 1 **Ventrolaterally:** lobes of the thyroid gland
- 2 **Laterally:** common carotid arteries, internal jugular veins
- 3 **Cranially:** hyoid bone
- 4 **Caudally:** trachea
- 5 **Ventrally:** pretracheal layer of the cervical fascia
- 6 **Dorsally:** pharynx

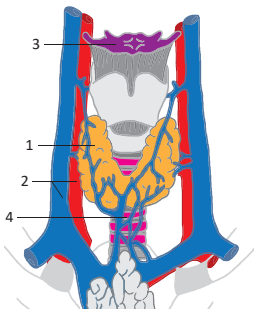

Syntopy of the larynx

Histological structure of the mucosa

1 **Respiratory epithelium** – pseudostratified ciliated columnar epithelium – pink mucosa in almost all parts of the larynx

2 **Non-keratinized stratified squamous epithelium** – whitish mucosa on the vocal folds, ary-epiglottic folds, ventral side and cranial half of the dorsal side of the epiglottis

3 **Zone of stratified columnar epithelium** – between the cranial and caudal halves of the dorsal side of the epiglottis

The cricoid cartilage (*cartilago cricoidea* from the Greek word "krikoeides", meaning "ring-shaped") was named after its resemblance to a signet ring.

The triticeal cartilage (*cartilagines triticae*) is a sesamoid cartilage within the thyrohyoid ligament.

Taste receptors are located in the mucosa of the dorsal side of the epiglottis and the aryepiglottic fold.

The anastomosis of Galen is an anastomosis between the sensory branches of the superior laryngeal nerve and recurrent laryngeal nerve. It is located on the dorsal side of the cricoid cartilage.

The rima glottidis is the narrowest part of the laryngeal cavity in adults. In children, the width is almost equal to the infraglottic cavity.

The rima glottidis has three parts:
Intermembranous part
– between the vocal ligaments
Intercartilaginous part
– between the vocal processes
Interarytenoid part
– between the arytenoid cartilages

Voice change (voice mutation) in males is caused by increased production of testosterone resulting in rapid growth of the vocal folds and a decrease of the pitch of voice.

Clinical notes

The laryngeal inlet and rima glottidis are narrow sections where foreign bodies may get stuck resulting in coughing and/or choking.

Laryngospasm is a spasmodic muscular contraction caused by irritation of the laryngeal mucosa closing the rima glottidis. This can result from trauma, foreign object aspiration, inflammation or allergy.

Laryngoscopy is an examination of the laryngeal cavity. It can be performed directly with a laryngoscope or indirectly using a mirror.

Cricothyrotomy (coniopuncture or coniotomy) is performed by a transverse incision through the middle cricothyroid ligament and the conus elasticus.
Needle cricothyrotomy (coniotomy) is performed by inserting a needle into the laryngeal cavity through the cricothyroid ligament and the conus elasticus.
Both cricothyrotomy and needle cricothyrotomy are life-saving procedures.

Blood supply

Arterial supply:
- 1 **Superior laryngeal artery** – superior thyroid artery (external carotid artery)
- 2 **Inferior laryngeal artery** – inferior thyroid artery (subclavian artery)

Venous drainage:
- 3 **Superior and middle thyroid veins** – internal jugular vein
- 4 **Inferior thyroid vein** – unpaired thyroid plexus (left brachiocephalic vein)

Lymphatic drainage:
– deep cervical lymph nodes and paratracheal lymph nodes

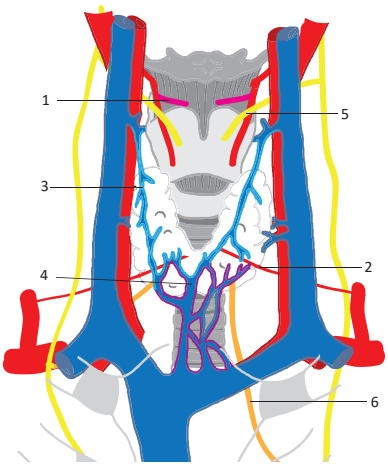

Blood supply and innervation of the larynx

Innervation

Viscerosensory innervation (innervating the mucosa)**:** vagus nerve
- 5 **Superior laryngeal nerve** – the internal branch innervates the mucosa above the vocal folds
- 6 **Recurrent laryngeal nerve** – the mucosa below the vocal folds

Somatomotor innervation (innervating the muscles of the larynx)**:** vagus nerve
- 5 **Superior laryngeal nerve** – the external branch innervates the cricothyroid
- 6 **Recurrent laryngeal nerve** – innervates all the other laryngeal muscles

Parasympathetic innervation: vagus nerve

Sympathetic innervation: laryngopharyngeal branches from the superior cervical ganglion

Cartilages

- 1 **Thyroid cartilage** (*cartilago thyroidea*)
  – hyaline, unpaired
  - 1.1 **Left and right lamina** (*lamina dextra et sinistra*)
  - 1.2 **Oblique line** (*linea obliqua*)
  - 1.3 **Laryngeal prominence** (*prominentia laryngea*)
  - 1.4 **Superior and inferior thyroid notch** (*incisura thyroidea superior et inferior*)
  - 1.5 **Superior and inferior horns** (*cornua superiora et inferiora*)
    - 1.5.1 **Cricoid articular surface** (*facies articularis cricoidea*) – on the inferior horn
- 2 **Cricoid cartilage** (*cartilago cricoidea*) – hyaline, unpaired
  – the only completely closed cartilage around the larynx
  - 2.1 **Lamina** – the posterior part
    - 2.1.1 **Thyroid articular surface** (*facies articularis thyroidea*) – on the lateral border of the lamina and arch
    - 2.1.2 **Arytenoid articular surface** (*facies articularis arytenoidea*) – on the cranial margin of the lamina
  - 2.2 **Arch** (*arcus*) – the ventral part of the cricoid cartilage
- 3 **Arytenoid cartilage** (*cartilago arytenoidea*) – hyaline, paired
  - 3.1 **Apex** – the cranial elastic narrower part
  - 3.2 **Base** (*basis*) – the caudal hyaline wider part
    - 3.2.1 **Vocal process** (*processus vocalis*) – points ventromedially
    - 3.2.2 **Muscular process** (*processus muscularis*) – points dorsolaterally
    - 3.2.3 **Cricoid articular surface** (*facies articularis cricoidea*) – concave
- 4 **Epiglottic cartilage** (*cartilago epiglottica*) – cartilage of the epiglottis
  – elastic, unpaired
  - 4.1 **Lamina** – protrudes dorsocranially into the pharynx
  - 4.2 **Stalk of epiglottis** (*petiolus*) – is caudally attached to the internal side of the thyroid cartilage
- 5 **Corniculate cartilage** (*cartilago corniculata*) – elastic, paired
  – attaches to the apex of the arytenoid cartilage
  – forms the corniculate tubercle
- 6 **Cuneiform cartilage** (*cartilago cuneiformis*) – elastic, paired
  – is located laterocranially to the corniculate cartilage
  – is embedded in the ary-epiglottic fold
  – forms the cuneiform tubercle

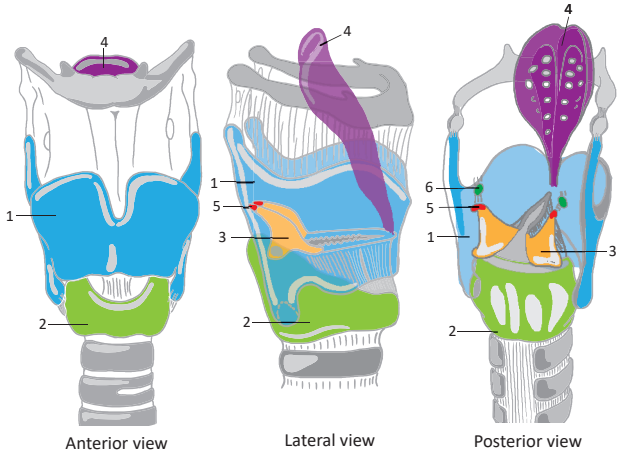

Anterior view · Lateral view · Posterior view

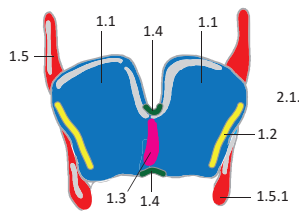

Thyroid cartilage

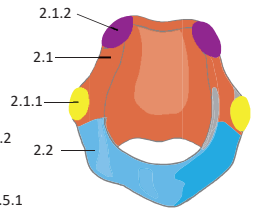

Cricoid cartilage

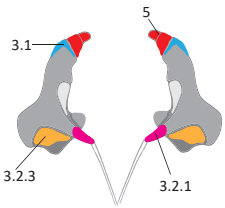

Arytenoid cartilage, anterior view

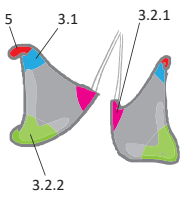

Arytenoid cartilage, oblique posterior view

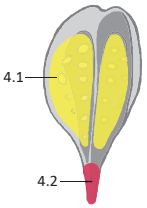

Epiglottic cartilage

This copy belongs to ali yaghoubi

Ligaments

Extrinsic membranes (true ligaments)
– connect the laryngeal cartilages together and the larynx to the surrounding structures

- 1 **Thyrohyoid membrane** *(membrana thyrohyoidea)*
  - 1.1 **Median thyrohyoid ligament** *(ligamentum thyrohyoideum medianum)*
  - 1.2 **Lateral thyrohyoid ligament** *(ligamentum thyrohyoideum laterale)*
- 2 **Cricothyroid ligament** *(elastic membrane / ligamentum cricothyroideum)*
  – extends from the caudal margin of the thyroid cartilage to the cranial margin of the cricoid cartilage
  – keeps the conus elasticus in the midline, located ventrally to it
- 3 **Cricotracheal ligament** *(ligamentum cricotracheale)*
  4 **Thyro-epiglottic ligament** *(ligamentum thyroepiglotticum)*
  – connects the stalk of the epiglottis to the internal surface of the thyroid cartilage
- 5 **Hyo-epiglottic ligament** *(ligamentum hyoepiglotticum)*

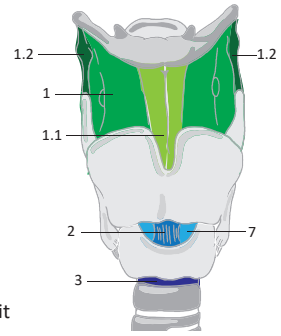

Frontal view

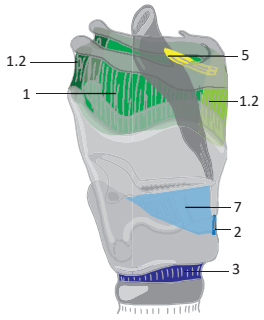

Lateral view

Intrinsic membranes – fibro-elastic laryngeal membranes *(membrana fibroelastica laryngis)*
– form a thickened fibrous layer under the submucosa

- 6 **Quadrangular membrane** *(membrana quadrangularis)*
  – extends from the vestibular fold up to the lateral margin of the epiglottic cartilage
  – its cranial margin underlies the ary-epiglottic fold
  - 6.1 **Vestibular ligament** *(ligamentum vestibulare)*
    – the thickened caudal margin of the quadrangular membrane extending from the dorsal surface of the thyroid cartilage to the ventrolateral surface of the arytenoid cartilage
    – the false ligament underlying the vestibular fold
- 7 **Conus elasticus**
  – extends from the vocal folds to the internal circumference of the cricoid cartilage
  – is weakened in the midline
  – is continuously connected to the cricothyroid ligament
  - 7.1 **Vocal ligament** *(ligamentum vocale)*
    – an elastic ligament forming the cranial margin of the conus elasticus
    – extends from the middle and dorsal parts of the thyroid cartilage to the dorsal part of the vocal process

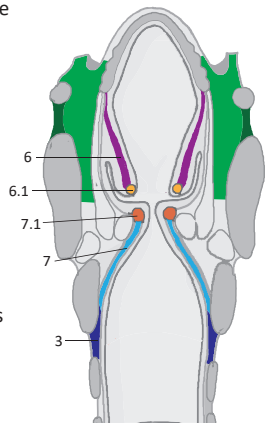

Frontal section of the larynx, posterior view

Joints

- 1 **Cricothyroid joint** *(articulatio cricothyroidea)*
  Type: simple
  Shape: cylindrical
  Articular head: cricoid articular surface on the inferior horn of thyroid cartilage
  Articular fossa: thyroid articular surface of cricoid cartilage
  Movement: ventrodorsal swaying movements

- 2 **Crico-arytenoid joint** *(articulatio cricoarytenoidea)*
  Type: simple
  Shape: flattened elliptical
  Articular head: arytenoid articular surface of cricoid cartilage
  Articular fossa: cricoid articular surface of arytenoid cartilage
  Movement: shifts and rotations, which are fundamental for abduction and adduction of the vocal ligaments

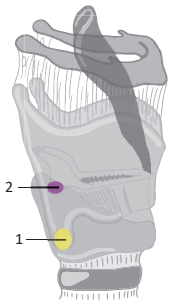

Lateral view

Phonation (voice production) is made possible by tensing the vocal folds and narrowing the rima glottidis.

Ventilation can only occur when the vocal folds are relaxed and the rima glottidis is open.

A cough (*tussis*) is an expiratory reflex to clean the lower airways of phlegm, sputum and foreign bodies irritating or blocking the airways. A cough begins with a deep breath, followed by strong contraction of the abdominal and expiratory muscles against a closed rima glottidis. The rima glottidis suddenly opens and air is forced out.

The tussigenic zones consist of areas innervated by the vagus nerve that may induce coughing when irritated. They include the larynx, trachea, main bronchi, parietal pleura, diaphragm, pericardium, oesophagus and external acoustic meatus.

The mechanism of sneezing is very similar to coughing. The difference is that during a sneeze, the uvula is depressed and most of the air is forced out through the nose. The fifth cranial nerve innervating the nasal mucosa provides the afferent limb of the sneeze reflex.

During swallowing the airways are closed by elevation of the pharynx by the suprahyoid muscles and the thyrohyoid with subsequent closure of the laryngeal inlet by the epiglottis.

Closure of the laryngeal inlet is caused by contraction of the ary-epiglottic part of the oblique arytenoid, the thyro-epiglottic part of the thyro-arytenoid and by descent of the root of the tongue.
Closure of the rima glottidis is caused by contraction of the lateral crico-arytenoid and the oblique and transverse arytenoids.

Clinical notes

Injury of the recurrent laryngeal nerve occurs as a complication of thyroid surgery due to its close topographical relation to the thyroid gland. Unilateral injury may result in a quiet voice. Bilateral injury causes difficulty in breathing as a result of paralysis of the posterior cricoarytenoid.

Palsy of the posterior cricoarytenoid prevents patency through the rima glottidis during inspiration.

Laryngeal oedema (*oedema glottidis/laryngis*) is inflammation located under the mucosa of the laryngeal cavity.

Intrinsic laryngeal muscles

Ventral group

1 **Cricothyroid** *(musculus cricothyroideus)*
parts:
- **straight part** *(pars recta)*
- **oblique part** *(pars obliqua)*

course: from the ventral side of the cricoid cartilage laterocranially to the caudal margin of the thyroid cartilage
function: moves the thyroid cartilage ventrocaudally while concurrently moving the arch of the cricoid cartilage cranially, tightening the vocal folds

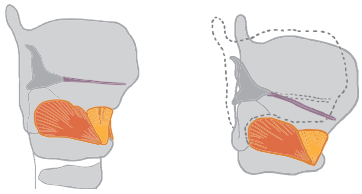
Cricothyroid

Lateral group

2 **Lateral cricoarytenoid** *(musculus cricoarytenoideus lateralis)*
course: from the cranial part of the lateral margin of the cricoid cartilage to the muscular process of the arytenoid cartilage
function: moves the muscular process ventrolaterally, adducting the vocal cords and closing the intermembranous part of the rima glottidis

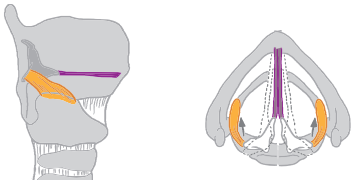
Lateral cricoarytenoid

3 **Thyroarytenoid** *(musculus thyroarytenoideus)*
course: from the internal side of the thyroid cartilage along the external side of the vocal ligament to the vocal process of the arytenoid cartilage
function: internal rotation and ventral shift of the arytenoid cartilage
– adduction and shortening of the vocal ligament (narrows the rima glottidis)

3.1 **Vocalis** *(musculus vocalis)*
– the medial part of the thyroarytenoid adjacent to the vocal ligament
– shortens and relaxes the vocal ligament
– the main muscle regulating strain on the vocal ligaments
– contains many motor units

3.2 **Thyro-epiglottic part** *(pars thyroepiglottica)*
course: fascicles of the thyroarytenoid from the thyroid cartilage extending to the lateral margin of the epiglottis
function: moves the margins of the epiglottis ventrally enlarging the rima glottidis

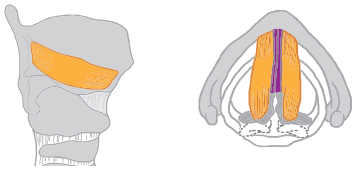
Thyroarytenoid

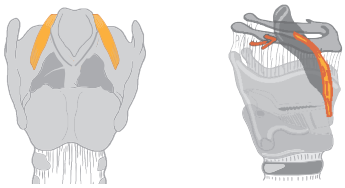
Thyro-epiglottic part of the thyroarytenoid

Dorsal group

4 **Posterior cricoarytenoid** *(musculus cricoarytenoideus posterior)*
course: begins on the dorsal side of the cricoid cartilage and runs craniolaterally to the muscular process of the arytenoid cartilage
function: external rotation and abduction of the arytenoid cartilage
– abducts and lenghtens the vocal ligament, enlarging the laryngeal inlet

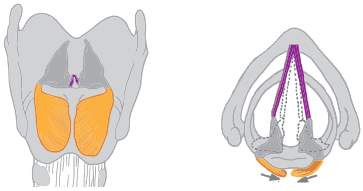
Posterior cricoarytenoid

5 **Transverse arytenoid** *(musculus arytenoideus transversus)*
course: transversally connects both arytenoid cartilages on their dorsal sides
function: adduction of the arytenoid cartilages
– adducts the vocal ligaments, narrowing the rima glottidis (both the intercartilaginous and interarytenoid parts)

6 **Oblique arytenoid** *(musculus arytenoideus obliquus)*
course: obliquely connects both arytenoid cartilages on their dorsal sides
function: adduction of the arytenoid cartilages
– adducts the vocal ligaments, narrowing the rima glottidis (both the intercartilaginous and interarytenoid parts)
– with the transverse arytenoid forms the strongest vocal ligament adductor

6.1 **Ary-epiglottic part** *(pars aryepiglottica)*
course: fascicles of the oblique arytenoid extending to the lateral margin of the epiglottic cartilage
– forms the ary-epiglottic fold
function: moves the margins of the epiglottis dorsocaudally, and thus depresses the epiglottis, closing the laryngeal inlet

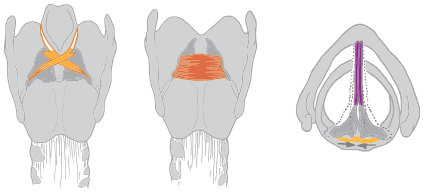
Transverse and oblique arytenoid

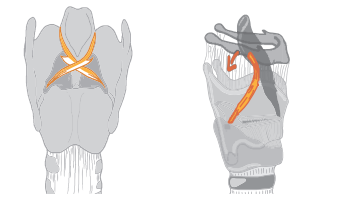
Ary-epiglottic part of the oblique arytenoid

This copy belongs to ali yaghoubi

The trachea is **connected to the larynx at the level of the vertebra C6**. It passes through the superior mediastinum and **bifurcates into the two main bronchi** at the **level of the vertebra T4**. It is **composed of 15–20 hyaline**, **C-shaped** dorsally opened **cartilages**, which are interconnected by a fibromuscular membrane.

Internal structure

- 1 **Mucosa and submucosa**
  - 1.1 **Pseudostratified ciliated columnar epithelium**
  - 1.2 **Tracheal glands** *(glandulae tracheales)*
    - – seromucous glands
  - 1.3 **Lymphoid tissue**
- 2 **Fibromusculocartilaginous layer** *(tunica fibromusculocartilaginea)*
  - 2.1 **Tracheal cartilage** *(cartilago trachealis)*
  - 2.2 **Membranous wall** *(paries membranaceus)*
    - – a fibromuscular membrane connecting the tracheal cartilages together at their dorsal edges
- 3 **Adventitia** *(tunica adventitia)*

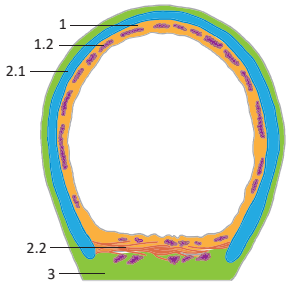

Transverse section of the trachea

External structure

- 1 **Tracheal cartilages** *(cartilagines tracheales)*
  - – 15–20 hyaline cartilages
  - – the last cartilage is triangular with a caudally pointing vertex
  - 1.1 **Carina of trachea** *(carina tracheae)*
    - – the ridge of the last cartilage protruding into the lumen of the trachea
- 2 **Annular ligaments** *(ligamenta anularia)*
  - – connect adjacent cartilages to each another

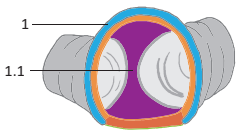

Superior view of the bifurcation of trachea

Syntopy

Cervical part *(pars cervicalis)*
– the continuation of the larynx at the level of the vertebra C6
– is located within the visceral space of the neck
ventrally: isthmus of the thyroid gland
laterally: thyroid gland, carotid sheath and recurrent laryngeal nerve (dorsolaterally)
dorsally: oesophagus

Thoracic part *(pars thoracica)*
– begins at the level of the cranial margin of the manubrium of the sternum
– passes through the superior mediastinum
– splits into the two main bronchi at the level of the T4 vertebra
– near the bifurcation, its left side touches the arch of the aorta

- 3 **dorsally:** oesophagus
- 4 **ventrally:** arch of aorta and its branches
- 5 **left:** left recurrent laryngeal nerve, arch of aorta
- 6 **right**: right recurrent laryngeal nerve, superior vena cava and azygos vein

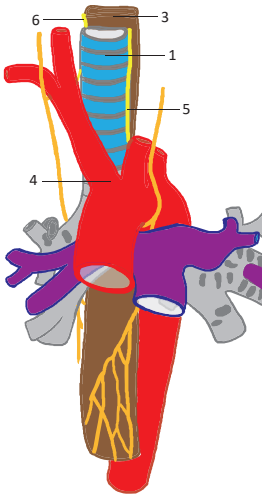

Syntopy of the trachea, anterior view

Blood supply

Arterial supply: tracheal branches (inferior thyroid artery), bronchial branches (descending aorta)
Venous drainage: tracheal veins (to the veins of the thyroid gland and oesophagus)
Lymphatic drainage: paratracheal nodes, tracheobronchial nodes

Innervation

Sympathetic innervation: parietal plexuses from the stellate ganglion
Parasympathetic innervation: recurrent laryngeal nerve, tracheal branches (vagus nerve)
Viscerosensory innervation: recurrent laryngeal nerve, tracheal branches (vagus nerve)

The bronchopericardial membrane extends between the main bronchi, oesophagus and the dorsal side of the pericardium, and forms the borderline between the anterior and posterior mediastinum.

Proportions of the trachea:
length 10–11 cm,
diameter 14–18 mm.

Length of the main bronchi:
The right main bronchus is about 3 cm, while the left main bronchus is 4–5 cm.

The ventral surface of the oesophagus is in contact with the flexible membranous wall of the trachea *(paries membranaceus tracheae)*. This allows ventral extension of the oesophageal wall during swallowing.

Clinical notes

Tracheotomy is a surgical procedure in which a horizontal or longitudinal incision through the ventral side of the trachea is performed. An upper tracheotomy *(tracheotomia superior)* is performed below the cricoid cartilage and above the isthmus of the thyroid gland. A lower tracheotomy (tracheotomia inferior) is performed below the isthmus of the thyroid gland at the level of the third tracheal cartilage. The resulting hole (stoma) of tracheotomy is called a tracheostomy.

A congenital tracheo-oesophageal fistula is a persisting communication between the respiratory and digestive tracts caused by incomplete separation of the oesophagus and the trachea.

Endotracheal intubation is the placement of a tube into the trachea through the oral cavity (orotracheal intubation) or the nasal cavity (nasotracheal intubation) to allow ventilation.

Postintubation tracheal stenosis occurs in 1 % of intubated patients. It usually becomes symptomatic after 3 months of intubation. Patients usually present with emphysema and inspiratory stridor. The stenosis can be treated by interventional bronchoscopy or by surgical resection of the trachea.

75 % of aspirated foreign bodies enter the right main bronchus due to its wider diameter and its direct continuity with the trachea.

The bronchi **arise from the tracheal bifurcation** at the level of the sternal angle and **successively divide to form the bronchial tree**. **The main bronchi** run in the mediastinum and **divide into the lobar bronchi** in the hilum of the lung. Peripheral parts of the bronchial tree are located within the lung tissue itself. Cartilaginous rings are incomplete, dorsally opened C-shaped rings in the primary bronchi. They become irregular and infrequent towards the periphery of the bronchial tree.

Basic bronchial tree

1. **Main/primary bronchi** *(bronchi principales)* – for the right and left lung
2. **Lobar/secondary bronchi** *(bronchi lobares)* – for the three lobes of the right lung and the two lobes of the left lung
3. **Segmental/tertiary bronchi** *(bronchi segmentales)* – for the 10 segments of the right lung and the (usually) 8 segments of the left lung

Bronchial tree *(arbor bronchialis)*

- 1 **Right main (primary) bronchus** *(bronchus principalis dexter)* – shorter, wider, more vertical and less deviated from the tracheal axis
  - 1.1 **Right superior lobar bronchus** *(bronchus lobaris superior dexter)*
    - B I **Apical segmental bronchus** *(bronchus segmentalis apicalis)*
    - B II **Posterior segmental bronchus** *(bronchus segmentalis posterior)*
    - B III **Anterior segmental bronchus** *(bronchus segmentalis anterior)*
  - 1.2 **Middle lobar bronchus** *(bronchus lobaris medius)*
    - B IV **Lateral segmental bronchus** *(bronchus segmentalis lateralis)*
    - B V **Medial segmental bronchus** *(bronchus segmentalis medialis)*
  - 1.3 **Right inferior lobar bronchus** *(bronchus lobaris inferior dexter)*
    - B VI **Superior segmental bronchus** *(bronchus segmentalis superior)*
    - B VII **Medial basal segmental bronchus** *(bronchus segmentalis basalis medialis or cardiacus)*
    - B VIII **Anterior basal segmental bronchus** *(bronchus segmentalis basalis anterior)*
    - B IX **Lateral basal segmental bronchus** *(bronchus segmentalis basalis lateralis)*
    - B X **Posterior basal segmental bronchus** *(bronchus segmentalis basalis posterior)*
- 2 **Left main (primary) bronchus** (*bronchus principalis sinister*) – longer, narrower, laterocranially concave and more deviated from the tracheal axis
  - 2.1 **Left superior lobar bronchus** *(bronchus lobaris superior sinister)*
    - B I + II **Apicoposterior segmental bronchus** *(bronchus segmentalis apicoposterior)*
    - B III **Anterior segmental bronchus** *(bronchus segmentalis anterior)*
    - B IV **Superior lingular bronchus** *(bronchus lingularis superior)*
    - B V **Inferior lingular bronchus** *(bronchus lingularis inferior)*
  - 2.2 **Left inferior lobar bronchus** *(bronchus lobaris inferior sinister)*
    - B VI **Superior segmental bronchus** *(bronchus segmentalis superior)*
    - B VII **Medial basal segmental bronchus** – missing in 90 % of cases *(bronchus segmentalis basalis medialis or cardiacus)*
    - B VIII **Anterior basal segmental bronchus** *(bronchus segmentalis basalis anterior)*
    - B IX **Lateral basal segmental bronchus** *(bronchus segmentalis basalis lateralis)*
    - B X **Posterior basal segmental bronchus** *(bronchus segmentalis basalis posterior)*

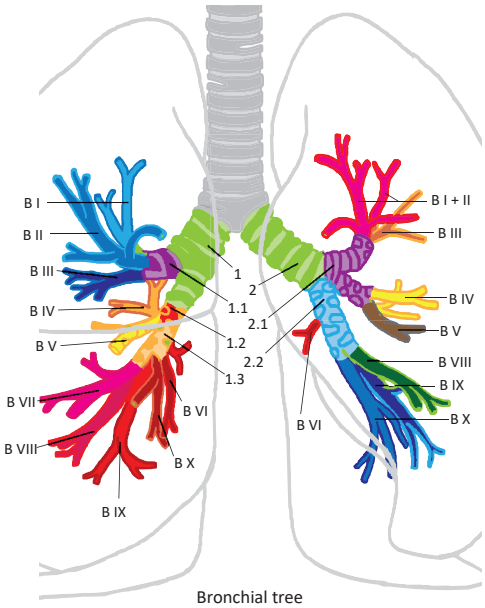

Bronchial tree

Syntopy

- 1 **Pulmonary arteries** *(arteriae pulmonales)* – ventrocaudal to the main right bronchus and cranial to the main left bronchus
- 2 **Pulmonary veins** *(venae pulmonales)* – ventrocaudal to the main bronchi
- 3 **Aortic arch** *(arcus aortae)* – superiorly convex, starts anteriorly to the left main bronchus, as it curves it becomes superior, and finally posterior to the left main bronchus
- 4 **Azygos vein** *(vena azygos)* – ascends ventrally to the right main bronchus, arches over it and opens into the superior vena cava
- 5 **Vagus nerves** *(nervus vagus)* – dorsal to the main bronchi
- 6 **Oesophagus** – dorsal to the left main bronchus

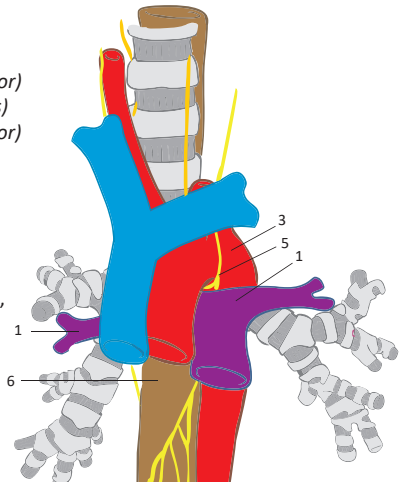

Syntopy of the bronchi, anterior view

Blood supply and innervation

Arterial supply: bronchial branches (thoracic aorta, posterior intercostal arteries)
Venous drainage: bronchial veins (azygos vein, accessory hemiazygos vein, posterior intercostal veins)
Lymphatic drainage: intrapulmonary nodes (further to the bronchopulmonary nodes and then to the tracheobronchial nodes)
Mixed innervation: peribronchial plexus (viscerosensory; visceromotor: sympathetic, parasympathetic – vagus nerve)

This copy belongs to ali yaghoubi

The lung is a **paired organ covered with the pleura** and located in the **pleural cavity**. Pulmonary tissue consists of the bronchial tree, connective tissue (the pulmonary interstitium), vessels, nerves and lymphatic nodes. The lungs are divided into **lobes each with its own lobar bronchus**. The lobes are further divided into segments, defined as the area ventilated by a segmental bronchus and perfused by a branch of the pulmonary artery. The **right lung has 3 lobes** and 10 segments; the left lung has **2 lobes** and usually 8 segments.

Basic parts

- 1 **Base of lung** (*basis pulmonis*) – the concave base resting on the diaphragm
- 2 **Apex of lung** (*apex pulmonis*) – projects towards the cervical pleura
- 3 **Hilum of lung** (*hilum pulmonis*)
  – a place where the structures of the root of the lung enter the lung
- 4 **Root of lung** (*radix pulmonis*)
  – the vessels, lymphatics, nerves, and bronchi passing through the hilum
- 5 **Pulmonary ligament** (*ligamentum pulmonale*) – a caudally extending pleural fold
  – a transition between the parietal and visceral pleura
- 6 **Lingula of left lung** (*lingula pulmonis sinistri*)
  – a thin slip of pulmonary tissue extending from the upper lobe of the left lung
  – the analogue of the middle lobe on the right lung

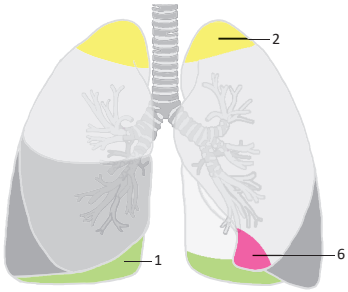

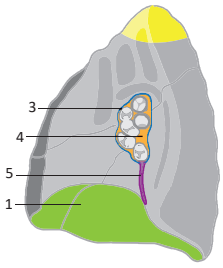

Mediastinal aspect of the right lung

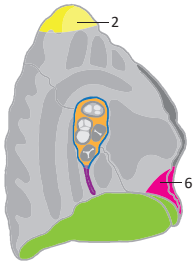

Mediastinal aspect of the left lung

Surfaces and borders

Surfaces

- 1 **Costal surface** (*facies costalis*) – faces the ribs
- 2 **Diaphragmatic surface** (*facies diaphragmatica*) – faces the diaphragm
- 3 **Medial surface** (*facies medialis*)
  – faces the mediastinum (mediastinal part) and the vertebral column (vertebral part)
- 4 **Interlobar surfaces** (*facies interlobares*) – formed by grooves between the lobes
  – face neighbouring lobes and are covered by the visceral pleura

Borders

- 5 **Anterior border** (*margo anterior*) – a sharp edge between the costal and medial surfaces
  - 5.1 **Cardiac notch of left lung** (*incisura cardiaca*)
    – a deep indentation on the anterior border of the left lung for the heart
- 6 **Inferior border** (*margo inferior*) – runs between the diaphragmatic and costal surfaces
- 7 **Vertebral border** (*margo vertebralis*)
  – the dorsal transistion between the costal and medial surfaces

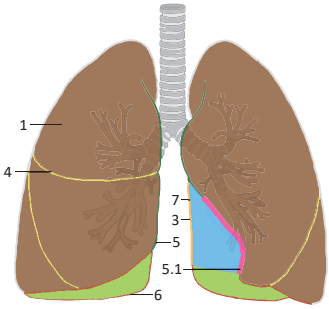

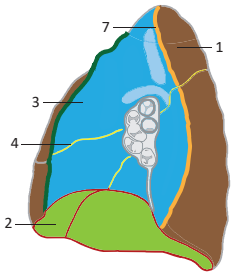

Mediastinal aspect of the right lung

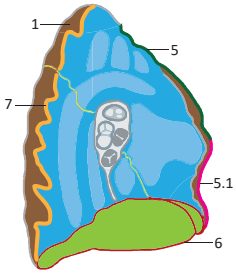

Mediastinal aspect of the left lung

The pulmonary interstitium is the connective tissue supporting the alveoli. It can be divided into:
1. peribronchial and perihilar fibrous tissue
2. interalveolar (or more simply alveolar), interlobular and intersegmental septa.

Surfactant is a superficial layer of proteins and phospholipids lining the alveoli. It reduces surface tension, which prevents the alveoli from collapsing. It is an acronym from **SURF**ace **ACT**ive **A**ge**NT**.

The airways of the lungs ramify as the brochial tree (first 14 levels), which serves for the air conduction, and then as the alveolar tree (other 9 levels) which serves for the air conduction and respiration.

The medial basal segment S VII (*segmentum basale mediale*) of the left lung is present in approximately 10 % of cases. In the other cases, it is incorporated into S VIII.

Pulmonary lobes (*lobi pulmonis*)

1 **Right lung** (*pulmo dexter*)
- 1.1 **Superior lobe** (*lobus superior*)
- 1.2 **Middle lobe** (*lobus medius*)
- 1.3 **Inferior lobe** (*lobus inferior*)
- 1.4 **Oblique fissure** (*fissura obliqua*)
- 1.5 **Horizontal fissure** (*fissura horizontalis*)

2 **Left lung** (*pulmo sinister*)
- 2.1 **Superior lobe** (*lobus superior*)
- 2.2 **Inferior lobe** (*lobus inferior*)
- 2.3 **Oblique fissure** (*fissura obliqua*)

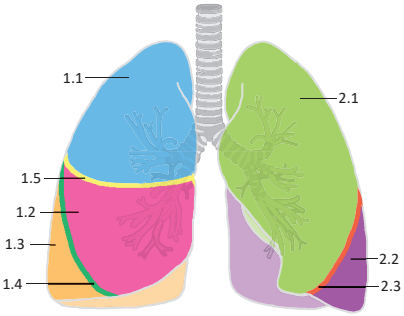

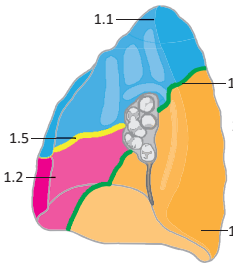

Mediastinal aspect of the right lung



Mediastinal aspect of the left lung

Bronchopulmonary segments (*segmenta bronchopulmonalia*)

Right lung (*pulmo dexter*)

Superior lobe (*lobus superior*)
- S I **Apical segment** (*segmentum apicale*)
- S II **Posterior segment** (*segmentum posterius*)
- S III **Anterior segment** (*segmentum anterius*)

Middle lobe (lobus medius)
- S IV **Lateral segment** (*segmentum laterale*)
- S V **Medial segment** (*segmentum mediale*)

Inferior lobe (lobus inferior)
- S VI **Superior segment** (*segmentum superius*)
- S VII **Medial basal segment** (*segmentum basale mediale / segmentum cardiacum*)
- S VIII **Anterior basal segment** (*segmentum basale anterius*)
- S IX **Lateral basal segment** (*segmentum basale laterale*)
- S X **Posterior basal segment** (*segmentum basale posterius*)

Left lung (*pulmo sinister*)

Superior lobe (*lobus superior*)
- S I + II **Apicoposterior segment** (*segmentum apicoposterius*)
- S III **Anterior segment** (*segmentum anterius*)
- S IV **Superior lingular segment** (*segmentum lingulare superius*)
- S V **Inferior lingular segment** (*segmentum lingulare inferius*)

Inferior lobe (*lobus inferior*)
- S VI **Superior segment** (*segmentum superius*)
- S VIII **Anterior basal segment** (*segmentum basale anterius*)
- S IX **Lateral basal segment** (*segmentum basale laterale*)
- S X **Posterior basal segment** (*segmentum basale posterius*)

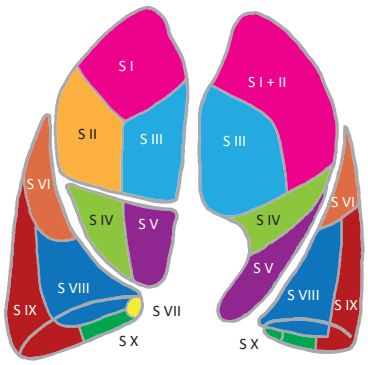

Right and left lung, anterior view

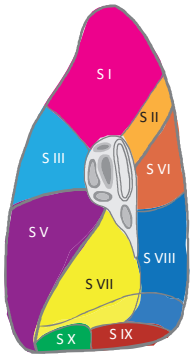

Mediastinal aspect of the right lung

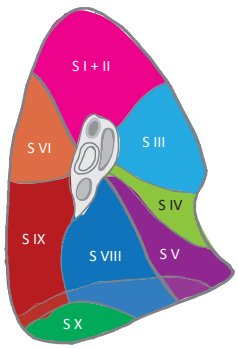

Mediastinal aspect of the left lung

Subsegments of lung parenchyma

1 **Bronchioles** (*bronchioli*) – contain neither cartilage nor glands

2 **Terminal bronchioles** (*bronchioli terminales*)
– the epithelium changes to simple columnar epithelium with exocrine bronchiolar cells (Clara cells)

3 **Alveolar tree** (*arbor alveolaris*) – the peripheral respiratory part of the bronchial segmentation
- 3.1 **Respiratory bronchioles** (*bronchioli respiratorii*) – first alveoli occur
- 3.2 **Alveolar ducts** (*ductus alveolares*) – contain many alveoli
- 3.3 **Alveolar atria** (*atria alveolaria*) – the widened terminal parts of the alveolar ducts
- 3.4 **Alveolar saccules / alveolar sacs** (*sacculi alveolares*) – the end of the bronchial tree
- 3.5 **Pulmonary alveoli** (*alveoli pulmonis*) – blind ends (cul-de-sacs) of the bronchial tree proceeding from the respiratory bronchioles, alveolar ducts and alveolar saccules

4 **Primary pulmonary lobule** (*lobulus pulmonis primarius*)
– is ventilated by one respiratory bronchiole

5 **Secondary pulmonary lobule** (*lobulus pulmonis secundarius*)
– the basic structural and functional unit of pulmonary tissue
– is ventilated by one terminal bronchiole

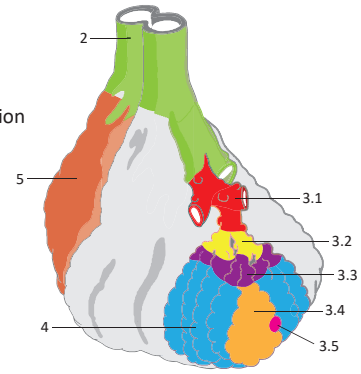

Subsegments of the lung parenchyma

This copy belongs to ali yaghoubi

Syntopy

1 **Mediastinal surface** *(facies mediastinalis)*
On both lungs
- 1.1 **Groove for first rib** *(sulcus costae primae)*
- 1.2 **Groove for subclavian artery** *(sulcus arteriae subclaviae)*
- 1.3 **Cardiac impression** *(impressio cardiaca)*

On the right lung
- 1.4 **Groove for superior vena cava** *(sulcus venae cavae superioris)*
- 1.5 **Groove for oesophagus** *(sulcus oesophageus)*
- 1.6 **Groove for azygos vein** *(sulcus venae azygos)*

On the left lung
- 1.7 **Groove for brachiocephalic vein** *(sulcus venae brachiocephalicae sinistrae)*
- 1.8 **Groove for aorta** *(sulcus aorticus)*
- 1.9 **Oesophageal impression** *(impressio oesophagea)*

2 **Costal surface** *(facies costalis)*
- 2.1 **Costal impressions** *(impressiones costarum)*

3 **Diaphragmatic surface** (*facies diaphragmatica*)
– is in direct contact with the diaphragm
– the following three organs are in contact with the lungs through the diaphragm (but do not form impressions):
3.1 **Liver** – in contact with the right lung
3.2 **Stomach** – in contact with the left lung
3.3 **Spleen** – in contact with the left lung

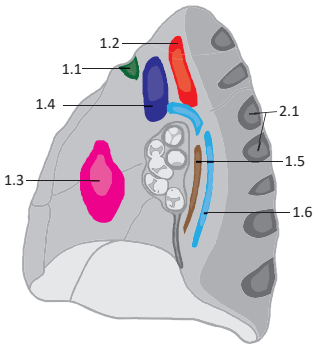

Mediastinal aspect of the right lung

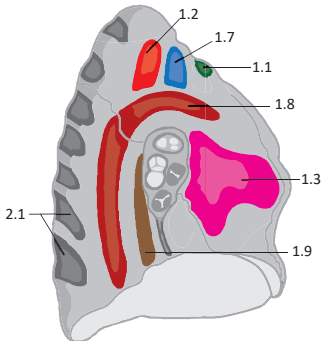

Mediastinal aspect of the left lung

Borders and projection of the lungs

- 1 **Apex of lung** *(apex pulmonis)*
  – is covered by the pleural cupula in the lesser supraclavicular fossa
- 2 **Anterior border** *(margo anterior)*
  – retrosternally between the anterior median line and the sternum
  – cranially recedes from the anterior median line to the lung apex
  – caudally recedes from the anterior median line
  - 2.1 **Cardiac notch** *(incisura cardiaca)*
    – the curved margin around the pericardium on the left lung
    – extends from the 4th sternocostal joint to the 6th rib in the midclavicular line
- 3 **Oblique fissure** *(fissura obliqua)* – extends from the spinous process T3 along the 6th rib to the navel
- 4 **Horizontal fissure** *(fissura horizontalis)* – on the right side from the oblique fissure in the midaxillary line along the 4th rib to the sternum
- 5 **Inferior border** *(margo inferior)*
  – at the level of the 6th rib in the midclavicular line
  – at the level of the 8th rib in the midaxillary line
  – at the level of the 10th rib in the scapular line

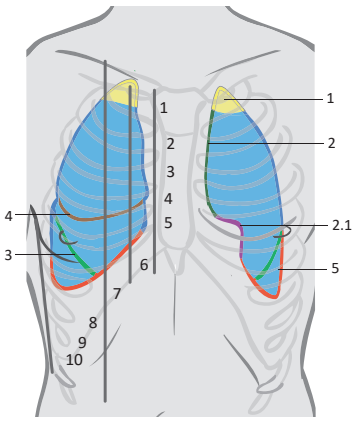

Anterior view

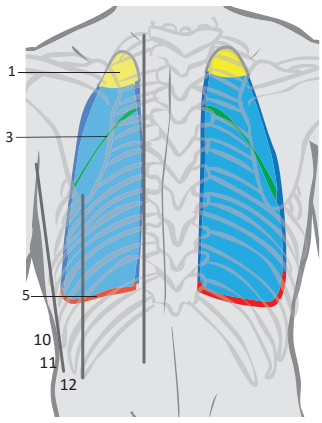

Posterior view

A mnemonic for remembering the arrangement of the structures in the hilum of the lung (**B**ronchus, **A**rtery, **V**ein in a craniocaudal direction):
BRIGHT IS RIGHT – bronchus on the right is cranial – but not on the left side

A mnemonic for remembering the position of the vagus and phrenic nerves in relation to the hilum:
Vagus nerve – behind the hilum of the lung ("vagus stays in the back")
Phrenic nerve – in front of the hilum of the lung ("**phr**enic is in the **fr**ont")

There are many **anastomoses** between the pulmonary and bronchial vascular beds (arterio-arterial and veno-venous) as well as between the arteries and veins in the pulmonary bed (arterio-venous). These connections may function as right-left shunts.

Nociceptive neurons (neurons perceiving the pain) are present in small numbers in the lungs and visceral pleura (lungs and visceral pleura do not have pain sensation). The only exception is the area around the hilum of the lung supplied by the vagus nerve.

Intrapulmonary lymph nodes are located around the branching points of the segmental bronchi in the lungs.

Bronchopulmonary lymph nodes are located around the lobar bronchi in the hilum of the lung.

Tracheobronchial lymph nodes are located around the tracheal bifurcation

Clinical notes

Pulmonary embolism is a life-threatening condition, which occurs due to obstruction of the pulmonary artery or any of its branches. In most cases it is due to a thromboembolism originating in the pelvic veins or the deep veins of the leg. Infrequently other types of embolism may occur, such as fat embolism (from fractures), amniotic fluid embolism (during delivery), air embolism (during injury) and tumour cell embolism.

Structures in the hilum of the lung

1 **Hilum of right lung** *(hilum pulmonis dextrum)*
- 1.1 **Right superior lobar bronchus** *(bronchus lobaris superior dexter)*
- 1.2 **Right pulmonary arteries** *(arteria pulmonalis dextra)*
- 1.3 **Right pulmonary veins** *(venae pulmonales dextrae)*
- 1.4 **Middle and inferior lobar bronchi** *(bronchus lobaris medius et inferior dexter)*
- 1.5 **Right bronchopulmonary lymph nodes** *(nodi lymphoidei bronchopulmonales dextri)*
- 1.6 **Pulmonary ligament** *(ligamentum pulmonale)*

2 **Hilum of left lung** *(hilum pulmonis sinistrum)*
- 2.1 **Left pulmonary artery** *(arteria pulmonalis sinistra)*
- 2.2 **Left superior lobar bronchus** *(bronchus lobaris superior sinister)*
- 2.3 **Left pulmonary veins** *(venae pulmonales sinistrae)*
- 2.4 **Left inferior lobar bronchus** *(bronchus lobaris inferior sinister)*
- 2.5 **Left bronchopulmonary lymph nodes** *(nodi lymphoidei bronchopulmonales sinistri)*
- 2.6 **Pulmonary ligament** *(ligamentum pulmonale)*

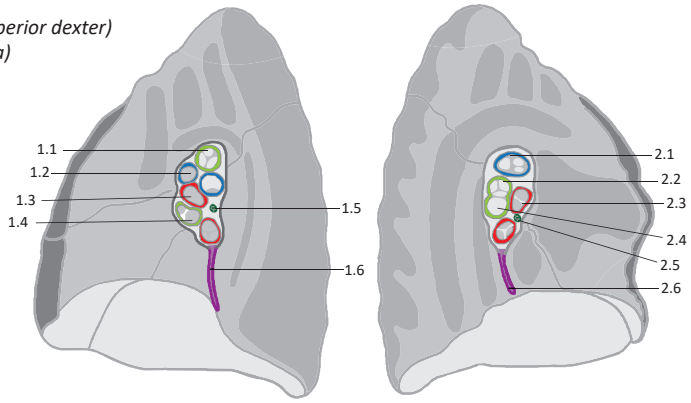

Mediastinal aspect of the right lung — Mediastinal aspect of the left lung

Blood supply

Functional circulation *(vasa publica)* – branches of the pulmonary artery and tributaries of the pulmonary veins
1. **Pulmonary trunk** *(truncus pulmonalis)* – begins at the right ventricle of the heart (contains deoxygenated blood)
2. **Right and left pulmonary arteries** *(arteria pulmonalis dextra et sinistra)* – branch along the bronchial tree
3. **Veins** – begin in the interstitial connective tissue and travel independently of the bronchial tree (the larger veins travel with the bronchi)
4. **Pulmonary veins** *(benae pulmonales)* – two from the right lung and two from the left lung
   – empty into the left atrium of the heart (contain oxygenated blood)

Nutritive circulation *(vasa privata)*
1. **Bronchial branches** *(rami bronchiales)* – contain oxygenated blood and course along the bronchial tree
   – usually two on the left from the thoracic aorta and one on the right from the third intercostal artery
   – form anastomoses with the bed of the pulmonary artery from the respiratory bronchioles onwards
2. **Bronchial veins** *(venae bronchiales)* – travel along the bronchial tree from the middle-calibre bronchi onwards
3. **To azygos vein, accessory hemi-azygos vein and intercostal veins**

Lymphatic drainage

– the superficial and deep lymphatic systems drain lymph to the hilar nodes
– from the hilar nodes lymph is drained through the bronchomediastinal trunks into the main lymphatic ducts

Superficial system
1. plexuses within the subpleural connective tissue
2. along the pulmonary veins (perivenous location)
3. there are no interposed lymph nodes before entering the bronchopulmonary nodes

Deep system
1. plexuses in the peribronchial connective tissue beginning at the level of the respiratory bronchioles
2. along the bronchi (peribronchial location)
3. intrapulmonary nodes are interposed before entering the bronchopulmonary nodes

Lymph nodes and lymphatic trunks
- 1 **Bronchopulmonary nodes** *(nodi lymphoidei bronchopulmonales)* – hilar nodes
- 2 **Right and left superior and inferior tracheobronchial nodes** *(nodi lymphoidei tracheobronchiales superiores et inferiores dextri et sinistri)*
- 3 **Right bronchomediastinal trunk** *(truncus bronchomediastinalis dexter)* – lymphatic collector
  - 3.1 to the right lymphatic duct *(ductus lymphaticus dexter)*
  - 3.2 **drainage area:** whole right lung, inferior lobe of left lung and both lingular segments of left lung superior lobe (S IV and S V)
- 4 **Left bronchomediastinal trunk** *(truncus bronchomediastinalis sinister)* – lymphatic collector
  - 4.1 to the thoracic duct *(ductus thoracicus)*
  - 4.2 **drainage area:** superior lobe of left lung (S I – III) excluding both lingular segments

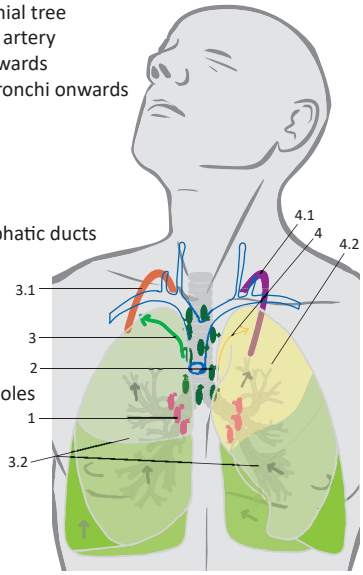

Lymphatic drainage of the lungs

Innervation

Sympathetic innervation: thoracic pulmonary branches – in the pulmonary plexus and the periarterial and peribronchial plexuses
Parasympathetic innervation: vagus nerve – in the pulmonary plexus and also in the periarterial and peribronchial plexuses
Viscerosensory innervation: by both sympathetic and parasympathetic nerves

This copy belongs to ali yaghoubi

The pleura is a **smooth glossy membrane** lining the thoracic cavity. It **consists of a layer of loose subserous tissue** covered by the **mesothelium**. It is divided into the **visceral pleura**, which is firmly **attached to the surface of the lungs** and extends into the interlobar fissures, and the **parietal pleura**, which **covers the inner surface of the thoracic cavity**. The **pleural cavity is located between these two layers; it** contains a small amount of **pleural fluid** (approximately 15 ml). This permits **smooth movements** of the lungs and pleura **during breathing** and **ensures negative pressure** in the thoracic cavity, keeping the lungs under tension.

Basic parts

- 1 **Visceral pleura** *(pleura visceralis)*
- 2 **Mesopneumonium** – the transition between the visceral and parietal pleura in the hilum of the lung
- 3 **Pleural cavity** *(cavitas pleuralis)*
- 4 **Parietal pleura** *(pleura parietalis)*
  - 4.1 **Pleural cupula** (*cupula pleurae*) – is located cranially between the scaleni
  - 4.2 **Costal part** *(pars costalis)* – faces the ribs
  - 4.3 **Mediastinal part** *(pars mediastinalis)* – faces mediastinum
  - 4.4 **Diaphragmatic part** *(pars diaphragmatica)* – faces the diaphragm

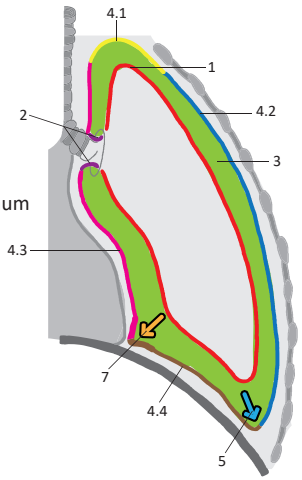

The schematic frontal section of the left pleural cavity

Pleural recesses *(recessus pleurales)*

- 5 **Costodiaphragmatic recess** *(recessus costodiaphragmaticus)* – between the ribs and the diaphragm – the deepest part of the pleural cavity
- 6 **Costomediastinal recess** *(recessus costomediastinalis)* – the anterior border of the mediastinal pleura between the ribs and the anterior mediastinum
- 7 **Phrenicomediastinal recess** *(recessus phrenicomediastinalis)* – between the diaphragm and the inferior mediastinum
- 8 **Vertebromediastinal recess** *(recessus vertebromediastinalis)* – between the vertebrae and the mediastinum

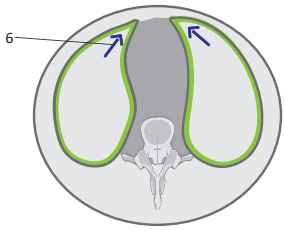

The schematic transversal section of the thorax

Pleural cupula / dome of pleura *(cupula pleurae)*

- 1 **Suprapleural membrane** – fascia of Sibson *(membrana suprapleuralis)* – the continuation of the endothoracic fascia
- 2 **Vertebropleural ligament** *(ligamentum vertebropleurale)* – from the deep layer of the cervical fascia
- 3 **Transversopleural ligament** *(ligamentum transversopleurale)* – from the transverse processes of the C6 and C7 vertebrae
- 4 **Costopleural ligament** (*ligamentum costopleurale*) – from the 1st rib
- 5 **Scalenopleural ligament** *(ligamentum scalenopleurale)* – from the inner surface of the scalenus anterior muscle

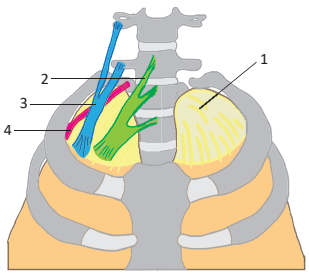

The components of the pleural cupula

Blood supply

Arterial supply and venous drainage:
- **parietal pleura** – internal thoracic artery and veins, posterior intercostal veins and arteries
- **visceral pleura** – veins and arteries of the lungs

Innervation

Viscerosensory innervation (visceral pleura)**:** vagus nerve (only in the hilum of the lung)

Somatosensory innervation (parietal pleura):
- **costal part, margins of the diaphragmatic part:** intercostal nerves
- **middle of the diaphragmatic part, mediastinal part:** phrenic nerve
- **pleural cupula:** brachial plexus

Pleural villi are appendages on the visceral pleura around the margins of the pulmonary lobes. The lungs expand into the **recesses of the parietal pleura** during maximal inspiration.

The parietal and visceral pleura are attached to the surrounding structures by several interconnected layers:
– the fibrous layer of the pleura (subserosa, subserous layer)
– a layer of loose connective tissue under the pleura (subpleural layer)
– interstitium of the lung, endothoracic fascia and the interstitial connective tissue of the mediastinum

The phrenicopleural fascia is a solid adhesion of the endothoracic fascia on the upper surface of the diaphragm to a layer of the subpleural connective tissue and a fibrous layer of the diaphragmatic part of the parietal pleura. Due to this solid adhesion, this diaphragmatic part of the parietal pleura is inseparable from the diaphragm.

The fascia of Sibson is a continuation of the endothoracic fascia covering the pleural cupula. It extends from the transverse processes of the 6th and 7th cervical vertebrae to the 1st rib.

The parietal pleura contains many nocireceptors ("parietal pleura hurts"). In contrast, the visceral pleura contains many mechanoreceptors ("visceral pleura and lungs do not hurt").

Clinical notesv

Pneumothorax is an accumulation of gas in the pleural cavity. The cause may be: injury to the thorax, rupture of a subpleural bulla, or iatrogenic (e.g. cannulation of the subclavian vein or puncture of the pleural cavity)

Fluidothorax is a collection of fluid in the pleural cavity. It may be classified as haemothorax (blood), chylothorax (lymph) or pyothorax (pus and bacteria). If the fluid contains a high content of protein, it is called an exudate. If it is poor in protein, it is called a transudate.

Thoracentesis (pleural tap) is a procedure to remove fluid or air from the pleural cavity. A tube is inserted through the 2nd or 3rd intercostal space in the midclavicular line (half-sitting position) for pneumothorax, or through the 6th intercostal space in the anterior or middle axillary line (sitting position) for fluidothorax. It is frequently performed under ultrasound guidance.

Borders and projections of the pleura

Upper border:

- **Lesser supraclavicular fossa** *(fossa supraclavicularis minor)*
  – the location of the cervical pleura

Anterior borders:

– the superior interpleural area *(area interpleuralis superior/thymica)* is bounded by the sternoclavicular joint cranially and the 2nd sternocostal joints caudally
– from the 2nd to the 4th ribs dorsally and parallel with the sternum
– from the 4th rib the borders diverge
– then form the inferior interpleural area *(area interpleuralis inferior or pericardiaca)*
– on the right, the border descends vertically along the sternum to the level of the 6th rib
– on the left, the border turns laterally towards the cartilage of the 6th rib

Inferior borders:

– from the level of the 6th rib the borders diverge and cross the anatomical lines

- 7th rib – midclavicular line
- 8th rib – anterior axillary line
  9th rib – middle axillary line

Dorsal border:

- 10th rib – posterior axillary line
- 11th rib – scapular line
- 12th rib (reaches also 2 cm below its level) – paravertebral line
  – the lowest and narrowest part of the pleural cavity

Parietal pleura Visceral pleura

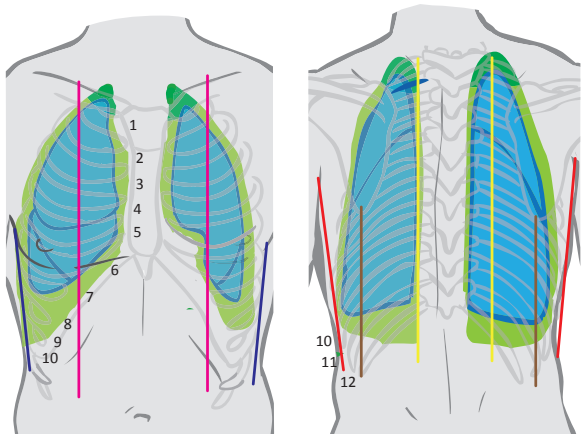

Anterior and posterior views of the parietal and visceral pleura

Inspiration is an **active process** in which the respiratory muscles elevate the thoracic cage ventrally and laterally. **Expiration** is a **passive process** in which the lung volume decreases due to the elastic recoil of the lungs. Forced expiration requires contraction of the expiratory muscles. **The inspiratory muscles insert on the superior parts of the ribs** and **elevate** them. **The expiratory muscles** insert on the inferior parts of the ribs and **depress** them. **The lungs are passive organs**; during breathing their volume adapts to the changes in volume and pressure in the thoracic cavity. Both the visceral and parietal pleura are fixed to the lungs and the chest wall and diaphragm, respectively. The pleural cavity does not communicate with any other nearby space.

Inspiratory muscles

- **Dominant inspiratory muscle:**
  Diaphragm
- **Auxilliary inspiratory muscles:**
  Neck muscles:
  scaleni, sternocleidomastoid, suprahyoid and infrahyoid
  Thoracic muscles:
  pectoralis major and minor, external intercostal, subclavius, serratus anterior, levatores costarum
  Back muscles:
  latissimus dorsi, trapezius (ascending part), levator scapulae, serratus posterior superior and inferior

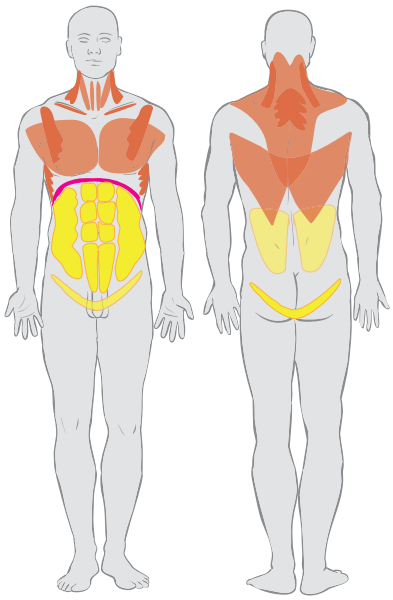

Expiratory muscles

- **Expiratory muscles involved in forced expiration:**
  Thoracic muscles:
  internal and innermost intercostals, subcostales, transversus thoracis
  "Abdominal press" muscles:
  abdominal wall muscles and pelvic-floor muscles

This copy belongs to ali yaghoubi

Muscles controlling the vocal ligaments				
Movements of the crico-arytenoid joint		**Movements of the cricothyroid joint**		
Abduction of the vocal ligaments (widening of the rima glottidis) – respiration position)	**Adduction of the vocal ligaments** (narrowing of the rima glottidis) – phonation position	**Tightening of the vocal ligaments**	**Relaxation of the vocal ligaments**	**Regulation of length and tension of the vocal ligaments**
posterior crico-arytenoid	lateral crico-arytenoid	cricothyroid	thyro-arytenoid	vocalis
	thyro-arytenoid			
	transverse and oblique arytenoid			

Muscles controlling the epiglottis	
Ventrocranial movement of the epiglottis (drags the epiglottis to the root of the tongue, opening the laryngeal inlet)	**Dorsocaudal movement of the epiglottis** (pulls the epiglottis down, closing the laryngeal inlet)
thyro-epiglottic part of thyro-arytenoid	ary-epiglottic part of oblique arytenoid

I. Nose

1. Name the cartilages forming the cartilaginous base of the nose. (p. 206)
2. Name the bony and the cartilaginous structures forming the nasal septum. (p. 207)

II. Nasal cavity

3. List the bones forming the lateral wall of the nasal cavity. (p. 207)
4. Define the term “common nasal meatus”. (p. 208)

III. Pharynx

5. State into which part of the pharynx the auditory (Eustachian) tube opens. (p. 209)
6. State into which part of the pharynx the laryngeal inlet opens. (p. 209)

IV. Larynx

7. List the 5 structures forming the borders of the laryngeal inlet. (p. 210)
8. State the three components of the rima glottidis. (p. 210)
9. State the colour of the vocal fold mucosa during laryngoscopic examination. (p. 210)
10. State the two arteries suppling the larynx. (p. 211)
11. Name the cranial nerve responsible for the viscerosensory, somatomotor and parasympathetic innervation of the larynx. (p. 211)
12. State the direction in which the vocal process of the arytenoid cartilage points. (p. 211)
13. State the direction in which the muscular process of the arytenoid cartilage points. (p. 211)
14. Define the term “quadrangular membrane”. (p. 212)
15. Define the term “conus elasticus”. (p. 212)
16. Explain the function of the posterior crico-arytenoid. (p. 213)

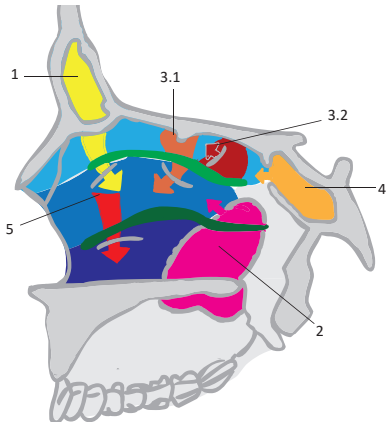

Describe the paranasal sinuses and the nasal meatuses

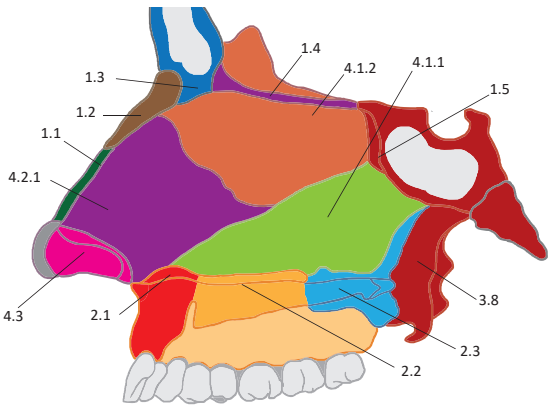

Describe the structure of the nasal septum

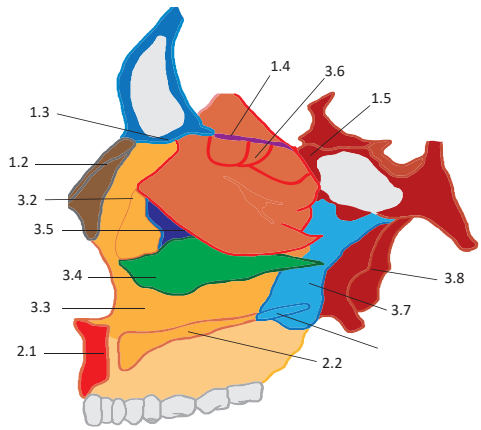

Describe the walls of the nasal cavity

V. Trachea

17. Define the term “carina of trachea”. (p. 214)
18. State at which level the tracheal bifurcation is located. (p. 214)
19. Define the term “bronchopericardial membrane”. (p. 214)
20. Name the organ that is located dorsally to the trachea. (p. 214)

VI. Lungs

21. Name the part of the airways that ventilates the secondary pulmonary lobule. (p. 217)
22. Describe the topographic relationship between the vagus nerve and the hilum of the lung. (p. 218)
23. Describe the topographic relationship between the phrenic nerve and the hilum of the lung. (p. 218)
24. State the location of the intrapulmonary lymph nodes. (p. 218)
25. State the location of the bronchopulmonary lymph nodes. (p. 218)
26. State the location of the tracheobronchial lymph nodes. (p. 218)
27. Name the 4 parts of the lungs from which lymph is drained into the right lymphatic duct. (p. 219)
28. Name the part of the lung from which lymph is drained into the thoracic duct. (p. 219)

VII. Parietal and visceral pleura

29. List the 4 parts of the parietal pleura. (p. 220)
30. State the deepest part of the pleural cavity. (p. 220)
31. State the approximate physiological amount of pleural fluid in the pleural cavity. (str. 220)

VIII. Mechanism of respiratory muscles

32. Name the main inspiratory muscles. (p. 221)

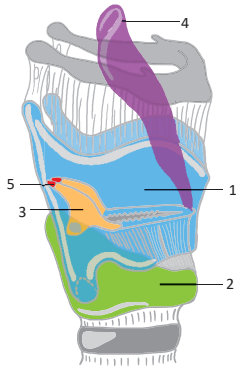

Describe the cartilagines of the larynx

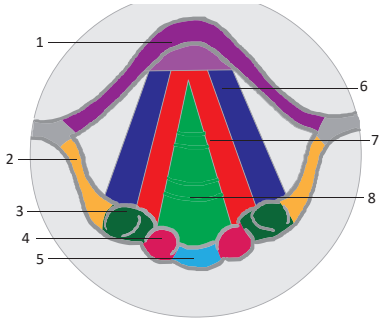

Describe the borders of the laryngeal inlet

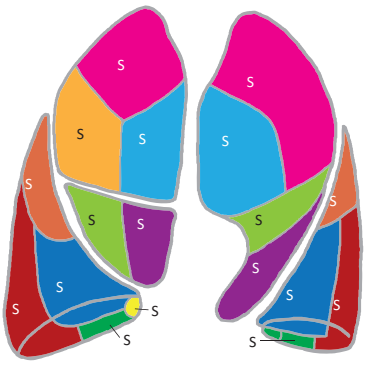

Describe the bronchopulmonary segments

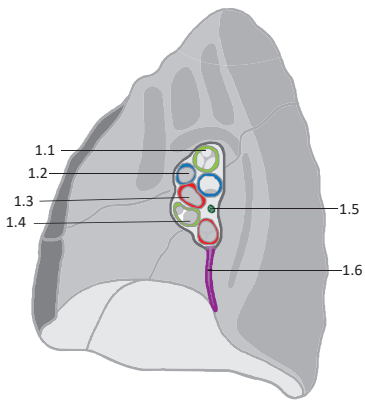

Describe the hilar structures of the right lung

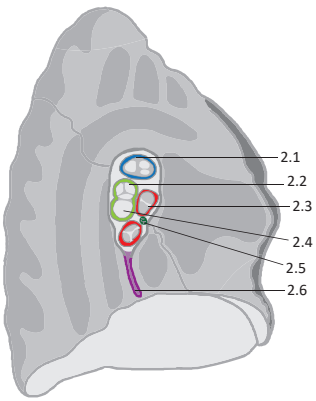

Describe the hilar structures of the left lung

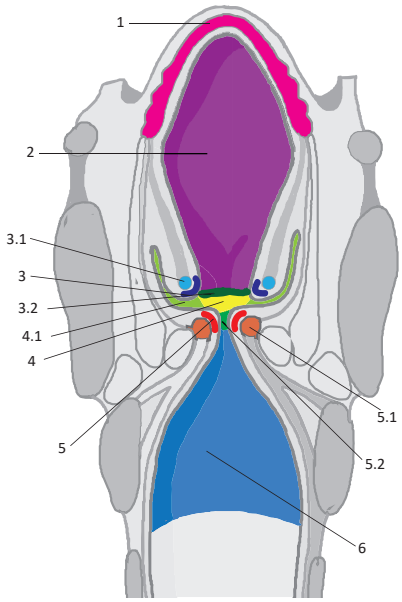

Describe the frontal section of the larynx

This copy belongs to ali yaghoubi

We would like to **thank the following physicians, anatomists and medical students** for their invaluable help, devotion and feedback in the preparation of this chapter.

Anatomists

Assoc. prof. Václav Báča, MD, PhD – Department of Anatomy, Third Faculty of Medicine, Prague, Czech Republic

Clinicians

Aravind Ganesh, MD – Department of Neurology, Foothills Medical Centre and University of Calgary, Calgary, Canada

Medical students

Marek Čierný
Vojtěch Kunc
Antonio Franca
Danil Yershov
Eva Fürstová

14 References

1. AGUR, A. M. R. and A. F. DALLEY. Grant's Atlas of Anatomy. 13th Ed. Philadelphia: Lippincot Williams & Wilkins, 2012, 888 p. ISBN 978-1-60831-756-1.
2. CHUNG, K. W.; CHUNG, H. M. and N. L. HALLIDAY. BRS Gross Anatomy. 8th Ed. Philadelphia: Lippincott Williams & Wilkins, 2015. 544 p. ISBN 978-1-4511-9307-7.
3. LANZ, T. and W. WACHSMUTH. Praktische Anatomie. 7 bands. Berlin: Springer, 2003, 3658 p. ISBN 978-3-540-40571-9.
4. MILLS, S. E. Histology for pathologists. 4th Ed. Philadelphia: Lippincot Williams & Wilkins, 2012. 1328 p. ISBN-13: 978-1-4511-1303-7.
5. NETTER, F. H. Atlas of Human Anatomy. Professional Edition. 6th Ed. Oxford: Elsevier. 2014. 640 p. ISBN 978-1-455-75888-3.
6. SNELL, R. S. Clinical anatomy by regions. 9th Ed. Philadelphia: Lippincott Williams & Wilkins, 2012. 768 p. ISBN 978-1-60913-446-4.
7. WILLIAMS, P. L., ed. Gray´s Anatomy: the anatomical basis of medicine and surgery. 38th Ed. New York: Churchill Livingstone, 1995, 2092 p. ISBN 0-443-05717-6.

Memorix Anatomy

7 Urinary system

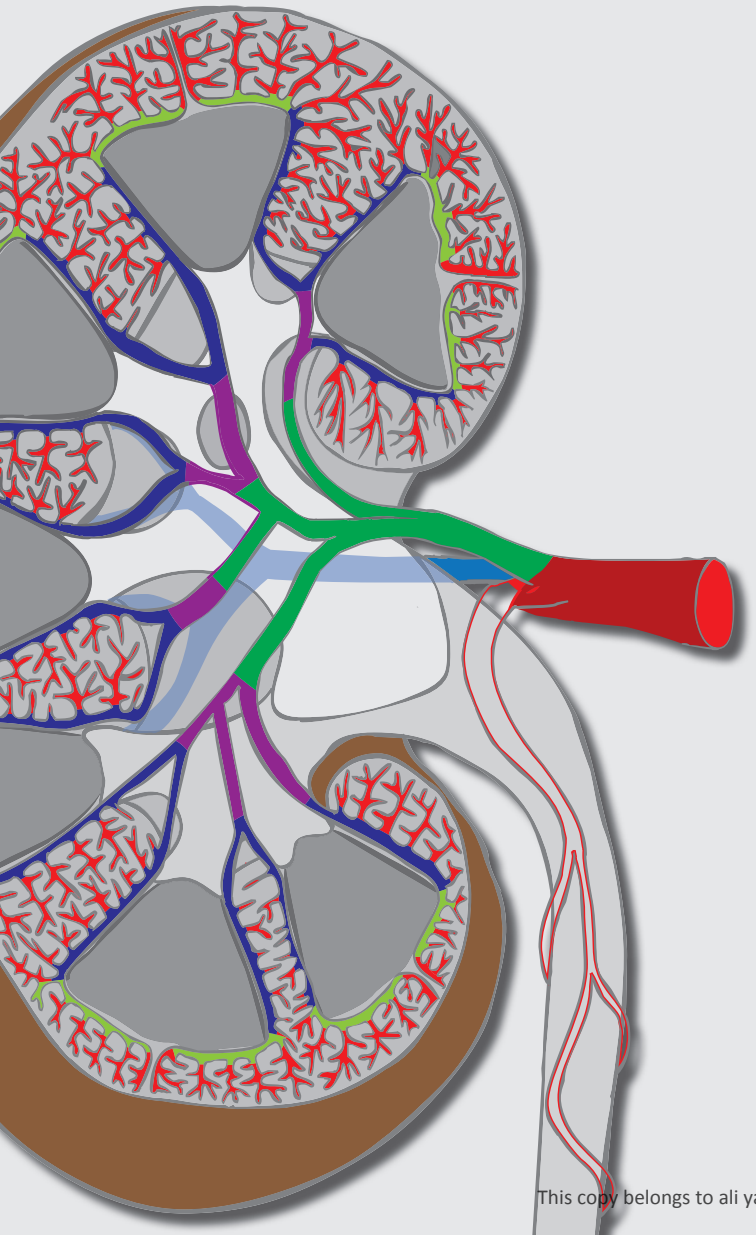

Barbora Beňová
David Kachlík
Radovan Hudák
Ondřej Volný
Adam Whitley

General overview 226
Kidneys 227
Renal pelvis and renal calices 230
Ureter 230
Urinary bladder 231
Female urethra 233
Dynamics of micturition 233
Review questions and figures 234
Acknowledgements and references 236

This copy belongs to ali yaghoubi

The urinary system is comprised of **two kidneys, two renal pelves, two ureters, the urinary bladder and the urethra**. The kidney is the main organ of the urinary system. Its roles include **plasma filtration, excretion of the waste products of metabolism, acid-base homeostasis**, **regulation of blood pressure and blood volume** (via renin), **hormone secretion** (erythropoetin) and **metabolism of vitamin D**. Urine is transported via the renal pelves and ureters to the urinary bladder before being excreted through the urethra.

External structure

- 1 **Kidneys** (*renes*)
  – filter plasma to create urine
- 2 **Minor and major renal calices** (*calices renales majores et minores*)
  – direct urine from the renal pyramids to the renal pelvis
- 3 **Renal pelvis** (*pelvis renalis*)
  – collects urine and is continuous with the ureter
- 4 **Ureter**
  – the longest segment of the urinary system
  – located between the renal pelvis and urinary bladder
- 5 **Urinary bladder** (*vesica urinaria*)
  – a hollow organ lying behind the pubic symphysis
- 6 **Urethra**
  – the terminal segment of the urinary system
  – **female urethra** (*urethra feminina*)
  – **male urethra** (*urethra masculina*)

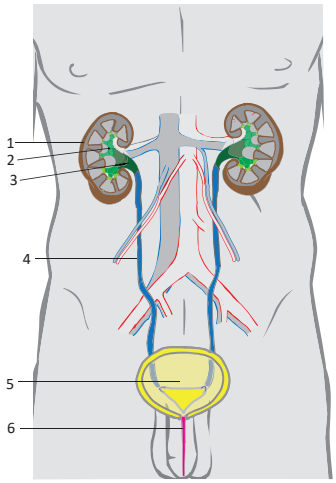

Internal structure

Mucosa (*tunica mucosa*) – is lined with transitional epithelium (urothelium), except for at the terminal part of the urethra, which is lined with stratified squamous epithelium

Muscular coat (t*unica muscularis*)
– is organised in two layers: an external circular layer and an internal longitudinal layer
– the muscular coat of the urinary bladder has three layers

Serosa (*tunica serosa*) – peritoneum covers the cranial surface of the urinary bladder and forms a pouch between the posterior wall of the urinary bladder and uterus in the female and between the urinary bladder and rectum in the male

Adventitia (*tunica adventitia*) – loose connective tissue surrounding parts of the urinary system not covered by the peritoneum

Development

Kidney
– originates from the intermediate mesoderm in the pelvic region
– during prenatal development, the caudal half of the body grows faster than the cranial half, which causes the kidneys to appear to ascend relative to their surroundings
– proceeds through three developmental stages

1. **Pronephros** – the first developmental stage
   – disappears completely by the 4th week of prenatal life
   – the mesonephric duct of Wolff / Wolffian duct (*ductus mesonephricus Wolffi*) arises from the caudal part of the pronephric duct
2. **Mesonephros** – arises from the mesonephric duct
   – in males, begins to disappear during the 9th week of prenatal life and consequently transforms into the rete testis and efferent ductules *(ductuli efferentes testis)*
   – in females, disappears along with the mesonephric duct
3. **Metanephros** – the definite kidney, distinguished from the previous stages by the presence of the loop of Henle and the renal medulla, which are capable creating concentrated urine

Renal calices, renal pelvis and ureters
– **the ureteric diverticulum** (*diverticulum ureteris*) arises from the mesonephric duct and develops into the ureter, renal pelvis, calices, papillary and collecting ducts

Urinary bladder and urethra
– the anterior part of **the urogenital sinus** (*sinus urogenitalis*) transforms into the urinary bladder and several parts of the urethra (intramural, prostatic and intermediate parts)

The excretory system is a synonymous term the urinary system. However, as other organ systems take part in the excretion of waste products, this term is less accurate.

Nephros *(pl. nephroi)* is the Greek term for kidney.

The urogenital sinus is the anterior half of the cloaca. The cloaca is the common end of the urinary, digestive and genital systems in the developing human. It divides into the urogenital sinus and anal canal.

Primary urine is plasma ultrafiltrate. 150–180 l of primary urine are produced per day.

There are approximately 1 to 1.5 million nephrons in a single kidney.

Clinical notes

Developmental variations in the shape and size of the kidney (that may or may not result in malfunction):
– **horseshoe kidney** *(ren arcuatus/unguliformis)*
– **supernumerary kidney** *(ren supernumerarius)*
– **sigmoid kidney** *(ren sigmoideus)*
– **cake (lump/fused pelvic) kidney** *(ren fungiformis)*

Dissection of the renal fibrous capsule is a procedure that is infrequently performed after the resection of benign tumors to cover the resulting defect.

Tapottement is part of the physical examination of the kidney. The examiner strikes the patient's lumbar area with the ulnar side of his/her palm. Pain is a positive result and may be a sign of kidney inflammation (pyelonephritis).

The kidneys are located **in the retroperitoneal space** on both sides of the vertebral column. The left kidney extends from vertebra T12 to L2 and the right kidney extends from vertebra T12 to L3. There are **five renal segments**, defined according to their vascular supply. Ventrally, the kidneys are covered by parietal peritoneum. Their dorsal surfaces lie close to the muscles of the posterior abdominal wall. **The hilum of the left kidney lies against vertebra L1**. The hilum of the right kidney lies slightly more caudal than this, as it is pushed by the mass of the liver. At birth, the kidney is composed of 6 renal pyramids. This number increases to 7–18 in adulthood.

Coverings of the kidney

- 1 **Paranephric fat** (*corpus adiposum pararenale*) – a body of fat surrounding the kidney, located between the retrorenal lamina of the renal fascia and the transversalis fascia
  – extends caudally to the upper margins of the iliac fossa
- 2 **Renal fascia / Gerota's fascia** (*fascia renalis*) – is composed of an anterior and a posterior layer that fuse at the lateral margin and superior pole of the kidney
  – the layers remain separated caudally, creating a space that the kidney can move into (*ren migrans*)
  – contains the capsuloadipose vessels
  – represents a condensed extension of the transversal fascia, the internal lining of the abdominal cavity
  - 2.1 **Prerenal layer of Toldt** (*lamina prerenalis*) – the anterior layer
  - 2.2 **Retrorenal layer of Zuckerkandl** (*lamina retrorenalis*) – the posterior layer
- 3 **Perinephric fat** (*capsula adiposa*) – the fat capsule of the kidney, surrounded by the renal fascia
- 4 **Fibrous capsule** (*capsula fibrosa*) – loosely covers the kidney
  – is attached firmly only to the vessels and the renal pelvis at the hilum of the kidney

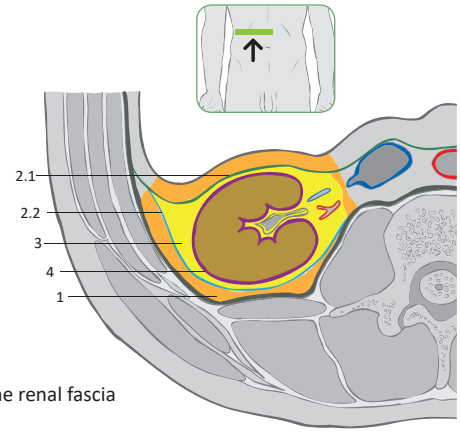

Transversal section of the right kidney at the level of L1 (vertebra)

External structures and segments

- 1 **Superior pole** (*extremitas superior*) – is covered by the suprarenal gland
- 2 **Inferior pole** (*extremitas inferior*)
- 3 **Medial border** (*margo medialis*) – the location of the hilum of the kidney
- 4 **Lateral border** (*margo lateralis*)
- 5 **Hilum of kidney** (*hilum renale*) – a vertical slit on the medial border where the renal vessels enter and leave the kidney and the location of the renal pelvis
- 6 **Anterior surface** (*facies anterior*)
- 7 **Posterior surface** (*facies posterior*)

Segments

- 1 **Superior segment** (*segmentum superius*) – is supplied by the superior segmental artery *(a. segmenti superioris)*
- 2 **Inferior segment** (*segmentum inferius*) – is supplied by the inferior segmental artery (*a. segmenti inferioris*)
- 3 **Anterior superior segment** (*segmentum anterius superius*) – is supplied by the anterior superior segmental artery (*a. segmenti anterioris superioris*)
- 4 **Anterior inferior segment** (*segmentum anterius inferius*) – is supplied by the anterior inferior segmental artery (*a. segmenti anterioris inferioris*)
- 5 **Posterior segment** (*segmentum posterius*) – is supplied by the posterior segmental artery (*a. segmenti posterioris*)

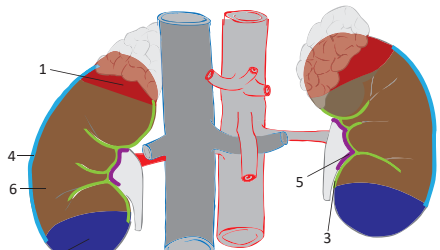

Anterior view of the kidneys and great vessels

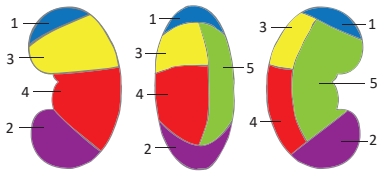

Anterior, lateral, and posterior view of the left kidney

Internal structures

- 1 **Renal cortex** (*cortex renalis*) – is composed of the glomeruli and the proximal and distal tubules
  - 1.1 **Renal columns** (*columnae renales*) – extensions of the cortex into the renal medulla
- 2 **Renal medulla** (*medulla renalis*) – is composed of the intermediate tubules, tubules of the juxtamedullary nephrons and collecting ducts in renal pyramids
  - 2.1 **Renal pyramids** (*pyramides renales*) – their bases projecting outwards to the renal cortex
    – there are 7–18 renal pyraminds in the adult kidney
  - 2.2 **Renal medullary rays** (*radii medullares*)
    – slender strips of renal medulla extending into the cortex
- 3 **Renal papillae** (*papillae renales*) – round tips of the pyramids projecting into the hilum of the kidney
  - 3.1 **Cribriform area** (*area cribrosa*) – the perforated surface of the papilla
  - 3.2 **Openings of papillary ducts** (*foramina papillaria*)
    – through these openings, the collecting ducts empty in the minor calix
- 4 **Kidney lobes** (*lobi renales*) – are composed of the renal pyramids and contiguous cortex
  – macroscopically visible in the early periods of development (lobulated kidney)

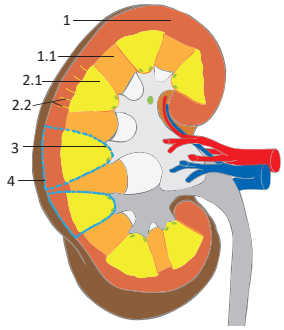

Frontal section of the right kidney, anterior view

This copy belongs to ali yaghoubi

Histology

Nephron

– the single functional unit of renal tissue
– **the cortical nephron** is located in the renal cortex
– **the juxtamedullary nephron** is located in the cortex in close proximity to the renal medulla

1 **Renal corpuscle** (*corpusculum renale Malpighi*)
– the initial part of the nephron
– consists of the glomerulus and Bowman's capsule
- 1.1 **Glomerulus** – a cluster of capillary loops
  - 1.1.1 **Afferent arteriole**
    – the larger vessel entering the glomerulus
  - 1.1.2 **Efferent arteriole**
    – the smaller vessel leaving the glomerulus
- 1.2 **Bowman's capsule** (*capsula glomeruli Bowmani*)
  – a double layer of epithelium surrounding the glomerulus
  – part of the renal filtration barrier

2 **Renal tubule** (*tubulus renalis*) – is divided into three segments
- 2.1 **Proximal tubule** (*tubulus proximalis*)
  - 2.1.1 **Proximal convoluted tubule** (*pars convoluta*)
  - 2.1.2 **Proximal straight tubule** (*pars recta*)
- 2.2 **Intermediate tubule** (*tubulus intermedius*)
  - 2.2.1 **Descending thin limb** (*crus descendens*)
  - 2.2.2 **Ascending thin limb** (*crus ascendens*)
    – the thick ascending limb is a part of the distal tubule
- 2.3 **Distal tubule** (*tubulus distalis*)
  – joins the collecting duct via the connecting tubule (*tubulus reuniens*)
  - 2.3.1 **Straight part** (*pars recta*)
  - 2.3.2 **Distal convoluted tubule** (*pars convoluta*)

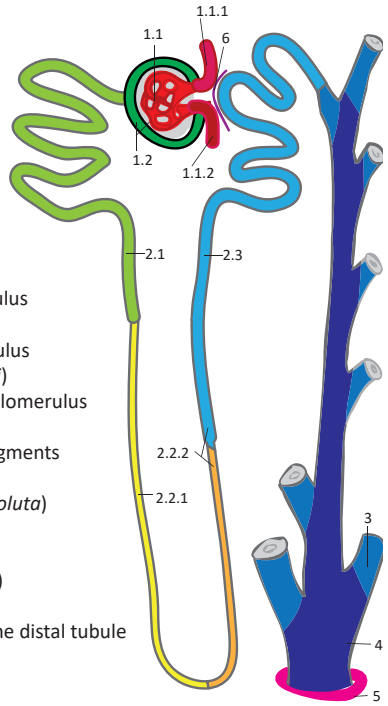

Juxtamedullary nephron and intrarenal ducts

Intrarenal ducts

- 3 **Collecting ducts** (*ductus colligentes*) – originate close to the renal cortex
- 4 **Papillary ducts** (*ductus papillares*) – begin by a confluence of several collecting ducts
- 5 **Openings of papillary ducts** (*foramina papillaria*) – on the tips of the renal papillae through which urine flows into the minor calix

Special structure

- 6 **Juxtaglomerular complex** (*complexus juxtaglomerularis*) – an apparatus consisting of the juxtaglomerular cells (modified smooth muscle cells of the afferent and efferent arterioles), extraglomerular mesangium, macula densa of the distal tubule, and granular epithelial peripolar cells
  – maintains stable blood pressure and intravascular volume and regulates sodium and water homeostasis by releasing the hormone (enzyme) renin

Development

Ureteric bud (*diverticulum ureteris*) – originates from the mesonephric duct (*ductus mesonephricus Wolffi*)
– releases the signal for differentiation of surrounding mesodermal cells into nephrons
– without this stimulating structure, kidney tissue does not develop at all (renal aplasia)
– partial failure results in renal cystic diseases (cysts compress the healthy kidney tissue which leads to renal atrophy or even renal failure)

Function

1. **Plasma filtration** through the renal filtration barrier
2. **Secretion and resorption** of water, ions and other substances
3. **Antidiuretic hormone activity** in the collecting tubules
4. **Aldosterone activity** in the distal tubule
5. **Erythropoietin, renin and urodilatin production**
6. **Vascular portal system:** plasma filtration through the glomerular membrane (1st capillary system), absorption and secretion of water, ions and other substances in the peritubular capillary plexus (2nd capillary system)
7. **Hydroxylation of vitamin D**

The loop of Henle *(ansa nephroni)* is composed of the straight part of the proximal tubule, all of the intermediate tubule and the straight part of the distal tubule. The juxtamedullary nephrons have longer loops of Henle, whereas the cortical nephrons have shorter loops.

Clinical notes

Renal artery stenosis is a narrowing of the renal artery. Decreased blood flow in the renal vascular bed disrupts the regulation of blood pressure and can result in hypertension.

Brodel's bloodless line is a watershed area between areas supplied by the anterior and posterior branches of the renal artery. It carries a lower risk of bleeding when being cut during nephrotomy or lithotomy (surgical removal of kidney stones). Due to its low perfusion, it is an optimal place for insertion of a renal catheter.

The accessory renal artery (hilar artery) enters the hilum of the kidney along with the main renal artery. An aberrant accessory renal artery (polar artery) enters the kidney outside the hilum. It pierces the renal capsule at the inferior pole or superior pole. It more frequently enters the kidney at the inferior pole, where it may compress the transition zone between the renal pelvis and ureter and lead to hydronephrosis. Accessory renal arteries occur in 30 % of patients. During transplantation or nephrectomy, they may be a source of unexpected bleeding or ischemia due to the absence of arterio-arterial anastomosis within the kidney.

A floating kidney *(ren migrans / nephroptosis)* describes a situation in which the renal capsule is weakened due to an excessive loss of perinephric fat (extreme weight loss), and the kidney descends within the retroperitoneal space to the pelvic cavity. Although the renal vessels descend along the kidney, their origin remains at the level of vertebra L2.

An ectopic kidney is a kidney located in an abnormal position. It results from failure of the kidney to reach its normal position during development and is usually located more caudal than the normal position. Its arteries arise from the aorta at the corresponding level.

A transplanted kidney is usually positioned in the right iliac fossa. It is more common than an ectopic or floating kidney in the same location.

Regional anatomy

Anterior surface – right kidney
- 1 Suprarenal (adrenal) gland
- 2 Liver
- 3 Duodenum
- 4 Jejunum
- 5 Right colic flexure
- 6 Attachment of the transverse mesocolon

Anterior surface – left kidney
- 1 Suprarenal (adrenal) gland
- 2 Stomach
- 3 Pancreas
- 4 Jejunum
- 5 Spleen
- 6 Left colic flexure
- 7 Attachment of the transverse mesocolon

Posterior surface – same in both kidneys
- 1 Diaphragm
- 2 Psoas major
- 3 Quadratus lumborum
- 4 Transverse abdominal

Structures related to the posterior surface of both kidneys:
– 11th and 12th rib
– subcostal nerve
– iliohypogastric nerve
– ilioinguinal nerve

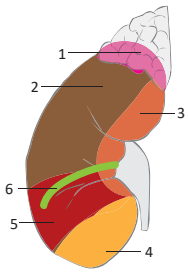

Right kidney

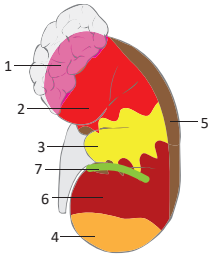

Left kidney

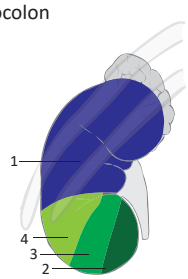

Left kidney

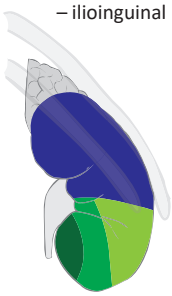
Right kidney

Vascular supply

Renal artery and its branches:
1 **Abdominal aorta** (*aorta abdominalis*)
2 **Right/left renal artery** (*arteria renalis dextra/sinistra*)
- 2.1 **Anterior branch** (*ramus anterior*) – has 4 branches that supply the anterior segments
  – superior segmental artery (*a. segmenti superioris*)
  – inferior segmental artery (*a. segmenti inferioris*)
  – anterior superior segmental artery (*a. segmenti anterioris superioris*)
  – anterior inferior segmental artery (*a. segmenti anterioris inferioris*)
- 2.2 **Posterior branch** (*ramus posterior*) – a single branch for the posterior segment
  – posterior segmental artery (*a. segmenti posterioris*)

3 **Lobar arteries** (*arteriae lobares*) – 15–20 arteries, one for each lobe
4 **Interlobar arteries** (*arteriae interlobares*)
– pass through the renal cortex between the renal pyramids
5 **Arcuate arteries** (*arteriae arcuatae*) – always two
– run between the border between the cortex and medulla
6 **Interlobular arteries, cortical radiate arteries** (*aa. corticales radiatae, aa. interlobulares*)
7 **Afferent glomerular arteriole** (*arteriola glomerularis afferens*)
8 **Glomerular capillary plexus** (*rete capillare glomerulare*)
9 **Efferent glomerular arteriole** (*arteriola glomerularis efferens*)
10 **Peritubular capillary plexus** – around proximal and distal tubules
11 **Vasa recta** (*arteriolae rectae*) – supply the medulla (juxtamedullary nephrons)

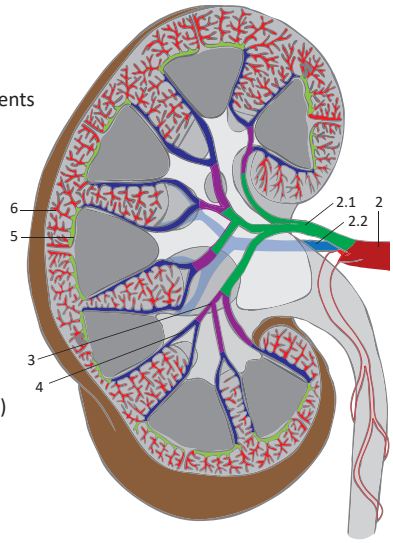

Coronal section of the right kidney, anterior view

Vascular portal system:
– **glomerular capillaries** continuing to the **peritubular capillary plexus or vasa recta**

Renal veins:
1. **Stellate veins** (*venulae stellatae*)
2. **Peritubular capillary plexus**
3. **Interlobular veins** (*venae interlobulares*)
4. **Arcuate veins** (*venae arcuatae*)
5. **Interlobar veins** (*venae interlobares*)
6. **Right/left renal vein** (*vena renalis dextra/sinistra*)
7. **Inferior vena cava** (*vena cava inferior*)

Lymphatic drainage: lateral aortic nodes, where three lymphatic plexuses terminate (one from the parenchyma, one from the fibrous capsule and one from the fat capsule)

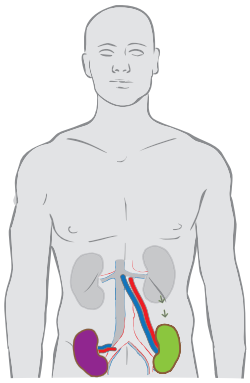

- Ectopic kidney
- Floating kidney

Innervation

Sympathetic, parasympathetic and visceral sensory innervation: renal plexus
Sympathetic supply: lesser splanchnic nerve (*n. splanchnicus minor*), coeliac ganglion (*ggl. coealiacum*)
Parasympathetic supply: vagus nerve (*n. vagus*)

This copy belongs to ali yaghoubi

3 Renal pelvis and renal calices – Pelvis renalis et calices renales

The renal pelvis and renal calices are parts of the upper urinary tract. They **collect urine** from the kidney **and direct it into the ureters**. They have the same innervation, vascular supply and lymphatic drainage as the kidneys.

Structure

- 1 **Minor calices** (*calices minores*) – small calices encircling the renal papillae (7–18)
- 2 **Major calices** (*calices majores*) – formed by the fusion of 2–3 minor calices
- 3 **Renal pelvis** (*pelvis renalis*)

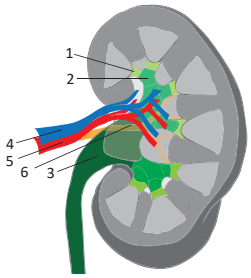

Anterior view of a coronal section of the left kidney

Regional anatomy of the hilum of the kidney

In ventrodorsal direction:

- 4 **Renal vein**
- 5 **Renal artery** – four anterior segmental branches
- **Renal pelvis**
- 6 **Renal artery** – posterior segmental branch

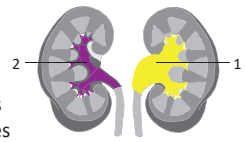

Types of the renal calices

- 1 **Ampullary type** – is distinguished by a wide pelvis and short calices
- 2 **Branching type** – is distinguished by a narrow pelvis and long calices

A mneumonic for the structures at the hilum of the kidney, in a ventrodorsal direction:
VAPA – vein, artery (renal), pelvis, artery (posterior segmental).

The ureter is 25–30 cm long and 4–7 mm wide.

The muscular layer (*tunica muscularis*) of the ureteric wall is composed of two layers: the internal longitudinal and external circular layer. The intramural part of the ureter has a ''third collar-like'' layer, called Waldeyer´s sheath.

The urachus is a remnant of the allantoenteric diverticulum. It is found within the median umbilical ligament (*ligamentum umbilicale medianum*) on the posterior side of the anterior abdominal wall.

The uretero-vesical junction region is described as the intramural part of the ureter, adjacent wall of the urinary bladder and ureteric orifice.

4 Ureter

The ureter is a muscular tube that transports urine from the renal pelvis to the urinary bladder. Its **peristaltic movements** pass urine in waves to the urinary bladder. Therefore, urine flow is not continuous.

Parts and orifices

- 1 **Abdominal part** (*pars abdominalis*) – courses in the retroperitoneal space
- 2 **Pelvic part** (*pars pelvica*) – courses in the lesser pelvis
- 3 **Intramural part** (*pars intramuralis*) – passing through the wall of the urinary bladder
- 4 **Ureteric orifice** (*ostium ureteris*) – a slit-like orifice opened only during the flow of urine

Constrictions

- 5 **Junction with the renal pelvis**
- 6 **Crossing the iliac vessels**
  - the right ureter runs ventrally to the external iliac artery and vein
  - the left ureter runs ventrally to the common iliac artery and vein
- 7 **Intramural part** in the wall of the urinary bladder

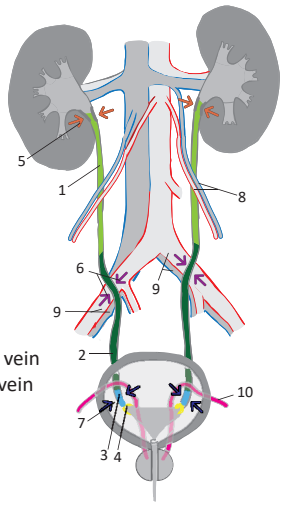

Regional anatomy

The ureter courses:

- 8 Dorsally to the testicular/ovarian artery and veins
- 9 Ventrally to the common and external iliac artery and vein and the genitofemoral nerve
- 10 Dorsally to the ductus deferens / uterine artery

Vascular supply and innervation

Arterial supply
in both sexes: renal artery, internal iliac artery, superior vesicular artery and middle rectal artery
in males: plus the testicular artery and artery to the ductus deferens
in female: plus the ovarian and uterine arteries
Innervation: sympathetic, parasympathetic and visceral sensory nerve fibres from the ureteric plexus (*plexus uretericus*), which originate in the abdominal aortic and renal plexuses (*plexus aorticus abdominalis, plexus renalis*)

Clinical notes

In the endoscopic percutaneous approach to the renal calices, a needle is inserted in a direction parallel to the course of the calyx and directed towards the papilla. In this location the vasculature is most scarce, which eliminate the risk of bleeding.

Hydronephrosis describes a situation where the renal pelvis is dilated due to either obstruction in the flow of urine or upstream flow of urine from the urinary bladder to the ureters and renal pelves and calices.

Vesicoureteral reflux occurs when the uretero-vesical junction is insufficient, allowing urine to flow upstream, back into the ureters and renal pelvis.

Developmental anomalies of the ureter:
Ureter fissus – a ureter divided in two in its proximal part with a single opening into the urinary bladder.
Ureter duplex – a double ureter with two separate openings into the urinary bladder.

Ureterocele is a dilation of the distal part of the ureter curved inwards to the cavity of the urinary bladder.

The retropubic space of Retzius *(spatium retropubicum)* is used as an extraperitoneal surgical approach to the urinary bladder or prostate. It avoids entering the peritoneal cavity.

The urinary bladder is a subperitoneally located hollow organ. It **collects urine**, which it releases by contractions of the **detrusor muscle** *(m. detrusor vesicae)* into the urethra. As the amount of urine in the bladder increases, the tension in the walls of the bladder increases, which eventually leads to the activation of the sacral parasympathetic system via visceral sensory nerves. This triggers contractions of the detrusor muscle, leading to an urgent need to micturate.

External structures

- 1 **Body of bladder** (*corpus vesicae*) – is covered by peritoneum
- 2 **Fundus of bladder** (*fundus vesicae*) – the bottom part of the bladder
  - – in males, it is in close proximity to the prostate and rectum
  - – in female, it is close to the vagina
- 3 **Neck of bladder** (*cervix vesicae*)
  - – is located on the inferior surface of the bladder and is continuous with the urethra
  - – in males, it prevents semen from flowing into the bladder during ejaculation
- 4 **Apex of bladder** (*apex vesicae*) – directed towards the pubic symphysis
  - – in the empty bladder, it is located right behind the pubic symphysis
  - – in the full bladder, it usually extends above the pubic symphysis
- 5 **Median umbilical ligament** (*ligamentum umbilicale medianum*)
  - – a ligament extendingfrom the apex of the bladder to the umbilicus on the anterior abdominal wall between the transversal fascia and parietal peritoneum

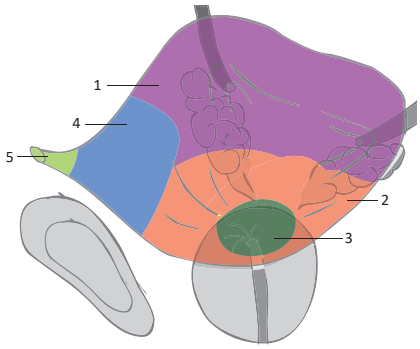

Superior oblique lateral view of the urinary bladder

Internal structures

- 1 **Ureteric orifices** (*ostia ureterum*) – slit-like openings for the ureters in the bladder wall
  - – there are no sphincter muscles around these orifices
- 2 **Trigone of bladder** (trigonum vesicae)
  - – a triangle-like area in the infero-posterior part of the bladder
  - – the ureteric orifices and the internal urethral orifice form the three corners of the trigone
  - – its mucosa is not folded
  - – in female, it projects on the anterior wall of the vagina as the trigonal area of Pawlik (*area trigonalis Pawliki*)
- 3 **Interureteric crest** (*plica interureterica*) – a fold in the bladder wall between the ureteric orifices
- 4 **Retrotrigonal fossa** (*fossa retrotrigonalis*) – a hollow space behind the interureteric crest
- 5 **Internal urethral orifice** (*ostium urethrae internum*) – an internal opening of the urethra
  - 5.1 **Uvula of bladder** (*uvula vesicae*)
    - – a mucous fold in the posterior part of the internal urethral orifice
    - – in males, it is located close to the middle lobe of the prostate

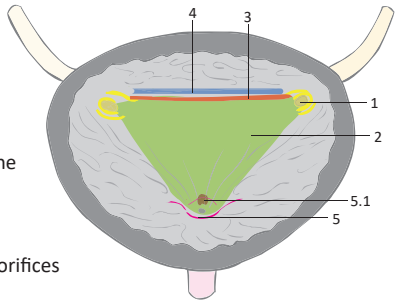

Oblique section of the urinary bladder, seen from the anterior superior view

Regional anatomy

Structures

- 1 **Anterior:** pubic symphysis
- 2 **Posterior:** rectum in males, vagina in female
- 3 **Superior:** small intestine in the peritoneal cavity, uterus in female
- 4 **Inferior:** prostate in males, urogenital diaphragm in females

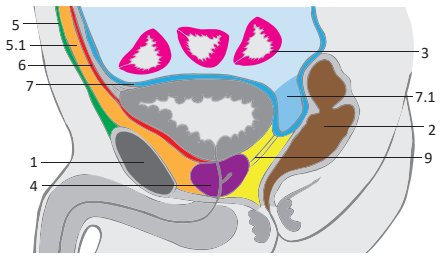

Sagittal section of the male pelvis

Spaces, fasciae, septa

- 5 **Transversal fascia** (*fascia transversalis*) – anterior to the apex of the urinary bladder
  - 5.1 **Retropubic space / space of Retzius** (*spatium retropubicum Retzii*)
    - – a space between the urinary bladder and pubic symphysis
- 6 **Vesicoumbilical fascia of Delbet** (*fascia vesicoumbilicalis Delbeti*) – a fascia located between the medial umbilical ligaments and median umbilical ligament in the shape of a triangle
  - – extends to the umbilicus and may contain the urinary bladder in its full state
- 7 **Parietal peritoneum** *(peritoneum parietale)* – covers the superior surface of the bladder
  - 7.1 **Recto-vesical pouch of Proust** (*excavatio rectovesicalis Prousti*)
    - – the space between the rectum and urinary bladder (only in males)
  - 7.2 **Vesico-uterine pouch** (*excavatio vesicouterina*)
    - – the space between the uterus and urinary bladder (only in females)
  - 7.3 **Paravesical fossae** (*fossae paravesicales*)
    - – peritoneum-lined spaces on both sides of the urinary bladder
- 8 **Paravesical space** (*spatium paravesicale*) – a space surrounding the urinary bladder inside the pelvic cavity between the urinary bladder and pelvic walls
- 9 **Rectovesical septum of Denonvilliers** (*septum rectovesicale Denonvilliersi*)
  - – a plate of connective tissue between the urinary bladder and the rectum (only in males)
  - 9.1 **Vesico-vaginal septum** (*septum vesicovaginale*) – an plate of connective tissue between the urinary bladder and the vagina with the adjacent cervix of the uterus

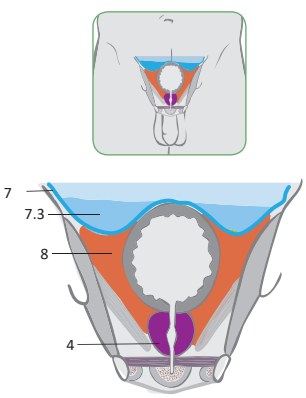

Frontal section of the male pelvis in the plane of the urinary bladder

This copy belongs to ali yaghoubi

Fixation of the bladder

Smoooth muscles

- 1 **Rectovesicalis** (*musculus rectovesicalis*) – extends from the rectum to the anterior wall of the neck of the urinary bladder
- 2 **Pubovesicalis** (*musculus pubovesicalis*) – extends from the pubic rami to the posterior wall of the neck of the urinary bladder
- 3 **Rectourethralis** (*musculus rectourethralis*) – extends from the rectum to the urethra (only in males)
- 4 **Puboprostaticus** (*musculus puboprostaticus*) – extends from the pubic rami to the prostate

Ligaments

- 5 **Rectovesical ligaments** (*ligamenta rectovesicalia*) – extends from the rectum to the posterior wall of the urinary bladder
- 6 **Pubovesical ligaments** (*ligamenta pubovesicalia*) – extends from the pubic symphysis to the anterior wall of the urinary bladder
- 7 **Vesicouterine ligaments** (*ligamenta vesicouterina*) – extends from the urinary bladder to the uterus (only in females)
- 8 **Puboprostatic ligaments** (*ligamenta puboprostatica*) – extends from the pubic rami to the prostate (only in males)

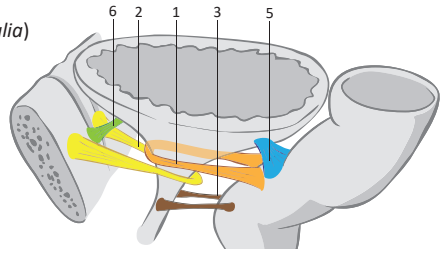

Pubic symphysis, urinary bladder and rectum seen from the superior oblique left view

Muscles involved in micturition and continence

Urinary bladder muscles

- 1 **Detrusor (muscle)** (*musculus detrusor vesicae*) – three layers of smooth muscle (inner plexiform, middle circular and external longitudinal layer) innervated by the parasympathetic system
- 2 **Sphincter vesicae (muscle)** (*musculus sphincter vesicae*)
  - a single layer of circular smooth muscle extending around the neck of the bladder innervated by the sympathetic system
  - in male, prevents semen from flowing into the bladder during ejaculation
- 3 **Trigonal muscles** (*musculi trigoni vesicae*)
  - bundles of smooth muscle located in the trigone of bladder, organised in a loop-like fashion
  - this enables them to control the opening and closure of the internal urethral orifice and ureteral orifices

Muscles surrounding the urethra

- 4 **Internal urethral sphincter** (*musculus sphincter urethrae internus*)
  - the internal sphincter is composed of smooth muscle tissue
- 5 **External urethral sphincter** (*musculus sphincter urethrae externus*)
  - the external sphincter is composed of striated muscle tissue

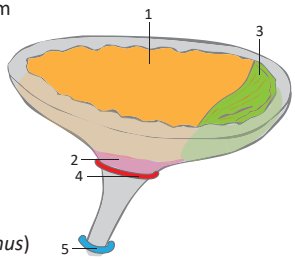

Superior left oblique view of the urinary bladder and urethra

Vascular supply

Arteries:

- superior vesical arteries (*aa. vesicales superiores*) from the umbilical artery
- inferior vesical artery (*a. vesicalis inferior*) from the internal iliac artery
- vesical branches (*rr. vesicales*) from the surrounding arteries (obturator, inferior gluteal, uterine and vaginal arteries)

Veins:

- vesical venous plexus (*plexus venosus vesicalis*) via the vesical veins into the internal iliac vein
- connections with the prostatic/vaginal venous plexus and pudendal plexus of Santorini

Lymphatic drainage:

- paravesical nodes (*nodi lymphoidei paravesicales*), which drain to the common iliac, external and internal iliac nodes

Innervation

Sympathetic system: vesical plexus (from inferior hypogastric/pelvic plexus)

Parasympathetic system, visceral sensory and visceral motor nerves: sacral nerves (L2–S2)

Urokystis is the Greek term for urinary bladder.

The vertex is the highest point of a full urinary bladder.

Bell's muscular fascicles are a pair of muscular fascicles between the ureteric orifice and the internal urethral orifice.

The spongy layer of the female urethra becomes thinner with age and may contribute to incontinence.
Micturition *(micturitio)* is the Latin term for urination.

Pawlik´s triangle *(area trigonalis vaginae)* is an area on the anterior wall of the vagina that is directly opposed to the trigone of the bladder. Vaginal rugae are absent here.

The external urethral sphincter is predominantly composed of slow-twitch muscle fibres that are capable of long-lasting contraction, maintaining closure of the urethra.

The mucosa and submucosa of the urethra are estrogen-dependent. They atrophy after menopause, which contributes to stress incontinence.

When the amount of urine in the urinary bladder reaches approximately 400 ml, the detrusor begins to contract, which creates the feeling of urgency. Volumes of urine over 500 ml can cause pain that projects to the hypogastrium, perineum and penis.

Clinical notes

The female urethra is short and in close proximity to the rectum. Females thus have an increased incidence of urinary tract infections caused by enteric pathogens.

The female urethra is short, wide and straight. Therefore, the insertion of a urinary catheter is not complicated.

The external iliac nodes need to be removed during radical cystectomy as they drain the urinary bladder.

The external urethral sphincter in males is the main mechanism for providing continence. During prostate and urinary bladder operations, it may be damaged and can cause urinary incontinence.

Epicystostomy *(sectio alta)* is a method to directly drain urine from the bladder by a inserting urine catheter through the anterior abdominal wall (extraperitoneal approach).

The female urethra is a 4 cm long, 6–8 cm wide muscular tube connecting the bladder to the external environment, thus forming the **terminal portion of the urinary tract in the female**. Voluntary contraction of the external urethral sphincter prevents urine from leaking out during reflex contraction of the detrusor muscle.

Parts

- 1 **Internal urethral orifice** (*ostium urethrae internum*) – is located inside the urinary bladder
- 2 **Intramural part** (*pars intramuralis*) – runs through the urinary bladder wall
- 3 **Pelvic part** (*pars pelvica*) – the longest section, located between the urinary bladder wall and the pelvic floor
- 4 **Perineal part** (*pars perinealis*) – passes through the perineal muscles and the urogenital hiatus (*hiatus urogenitalis*) of the levator ani
- 5 **External urethral orifice** (*ostium urethrae externum*)
  – protrudes as the urethral papilla (*papilla urethralis*) in the vestibule (*vestibulum vaginae*)

Internal structure

Mucosa (*tunica mucosa*) – lined by stratified squamous nonkeratinized epithelium
Spongy layer (*tunica spongiosa*) – part of the mucosa
– contains a venous plexus, which is essential for maintenance of urinary continence
Muscular layer (*tunica muscularis*)
– contains two layers of muscle: an inner longitudinal layer and an outer circular layer
– contains two spincters:

- 6 **Internal urethral sphincter** (*musculus sphincter urethrae internus*)
  – a weak layer of smooth muscle
- 7 **External urethral sphincter** (*musculus sphincter urethrae externus*)
  – a layer of striated muscle

Regional anatomy

- 8 **Vagina** – the urethra lies on the anterior wall of vagina, on which it forms a crest called the urethral carina of the vagina (*carina urethralis vaginae*), which is an extention of the trigonal area of Pawlik
- 9 **Bulb of vestibule** (*bulbus vestibuli*) – in front of and on both sides of the urethra

Vascular supply and innervation

Arteries:
– **intramural part:** inferior vesical artery (from the internal iliac artery)
– **pelvic part:** uterine and vaginal arteries (from the internal iliac artery)
– **perineal part:** internal pudendal artery (from the internal iliac artery)
Veins:
– **intramural part:** vesical venous plexus (via the vesical veins to the internal iliac vein)
– **pelvic part:** vaginal venous plexus (via the vaginal veins to the internal iliac vein)
– **perineal part:** internal pudendal veins (to the internal iliac vein)
Lymphatic drainage: paravesical nodes (to the common, internal and external iliac nodes)
Sympathetic and parasympathetic, visceral sensory and (somatic) motor nerve fibers: vesical plexus

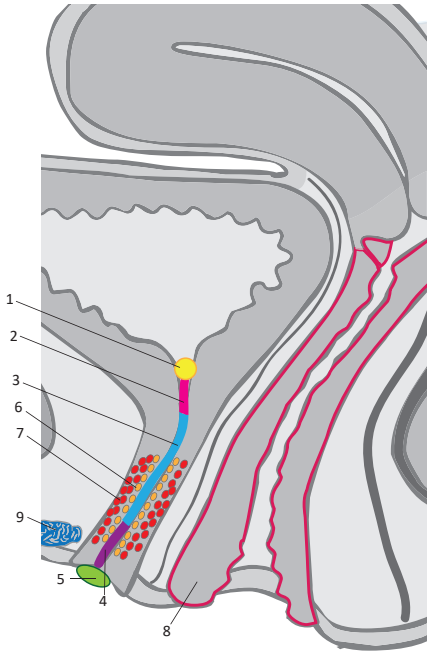

Left sagittal view of the female pelvis with the female urethra enlarged

7 Dynamics of micturition

Urinary continence is the ability to keep urine in the bladder and excrete it in a controlled fashion. **Urinary incontinence** is the lack of this ability. The two main aspects of urinary continence are the position of the urethra and neck of the bladder and the proper function of the urethral sphincters. In females, the sphincter compresses the urethra against the vagina and thus closes it. **Stress incontinence** is defined as involuntary leakage of urine when the pressure inside the peritoneal cavity rises (e.g. during coughing or laughing). Increased intra-abdominal pressure is able to push the urethra and the adjacent neck of the bladder downwards (a condition termed urethral hypermobility). Pressure is thus distributed unevenly; it is higher inside the urinary bladder than in the urethra, which results in urine leakage. **A different kind of stress incontinence** occurs when the urethra and neck of the bladder are permanently descended into the lesser pelvis, even at rest. Consequently, the internal urethral sphincter becomes unable to keep urine from escaping the urinary bladder.

Urinary continence in male is provided by:
– urethral mucosa and submucosa
– smooth muscle of the urethra
– external urethral sphincter
– levator ani (pubourethralis)

Urinary continence in female is provided by:
– urethral mucosa and submucosa
– smooth and striated muscle of the urethra
– external urethral sphincter, compressor urethrae
– sphincter urethrovaginalis, levator ani (pubovaginalis)

This copy belongs to ali yaghoubi

I. General overview and development of the urinary system

1. Name three structures that develop from the ureteric diverticulum. (p. 226)
2. Name the longest segment of the urinary tract. (p. 226)
3. Describe the structure of the three layers of the wall of tubular organs of the urinary system. (p. 226)
4. Specify which layer of the urinary bladder forms the fold between the urinary bladder and uterus. (p. 226)
5. Identify the difference between the mesonephros and metanephros. (p. 226)
6. Specify the definitive structure the mesonephric duct develops into (in the male). (p. 226)
7. Name the common structure from which the urinary bladder, prostatic and membranous parts of the urethra develop. (p. 226)

II. Kidneys

8. Name the 4 layers of the renal capsule. (p. 227)
9. Identify the 2 layers of the renal fascia of Gerota. (p. 227)
10. Explain the definition of a renal segment. (p. 227)
11. Draw the anterior and posterior views of renal segments. (p. 227)
12. Define a renal lobe. (p. 227)
13. Explain under which circumstances a lobulated kidney is physiologically present. (p. 227)
14. Describe the strucutre of the renal columns. (p. 227)
15. Explain the function of the juxtaglomerular complex. (p. 228)
16. Name the 3 segments of the intrarenal excretory system. (p. 228)
17. Name the parts of the nephron. (p. 228)
18. Explain the difference between the cortical and juxtaglomerular nephron. (p. 228)
19. State the 6 main functions of the kidney. (p. 228)
20. Draw and explain the regional anatomy of the kidney's anterior and posterior surfaces. (p. 229)
21. Describe a scheme of the vasculature of the kidney. (p. 229)
22. Explain the lymphatic drainage of the kidney. (p. 229)
23. State the structure that is continuous with the renal collecting ducts on one side and renal pelvis on the other. (p. 229)

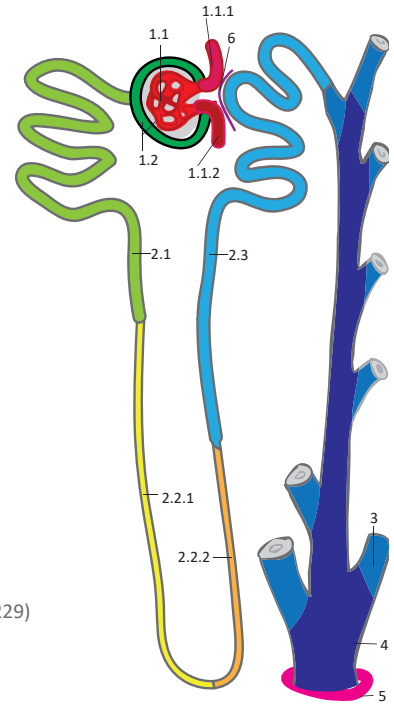

Describe the structure of the nephron and intrarenal ducts

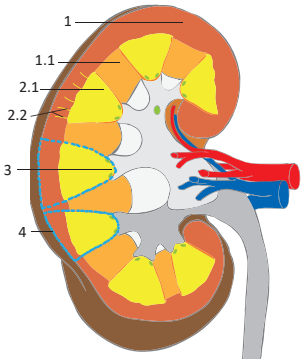

Describe the internal structure of the kidney

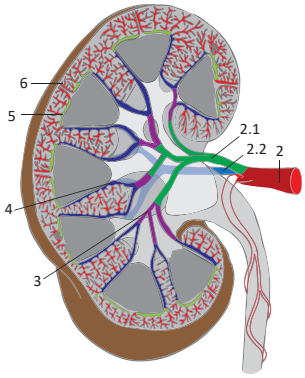

Describe the vasculature of the kidney

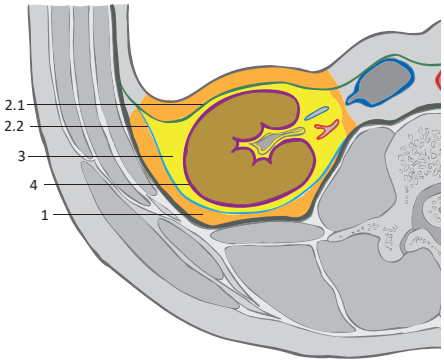

Describe the renal fasciae

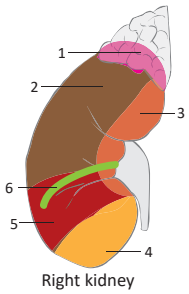

Right kidney

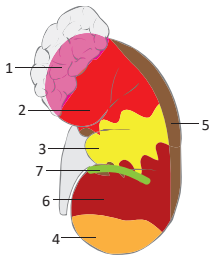

Left kidney

Describe the regional anatomy of the kidneys from its anterior aspect

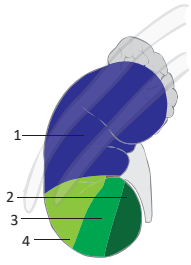

Left kidney

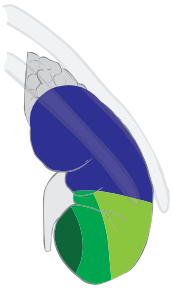

Right kidney

Describe the regional anatomy of the kidneys from its posterior aspect

III. Renal calices and the renal pelvis

24. Identify the 2 main types of renal calices and explain the difference between them. (p. 230)
25. Name the 4 structures of the hilum of the kidney. (p. 230)
26. Identify the structure that is posterior to the renal pelvis in the hilum of the kidney. (p. 230)
27. Identify the most anterior structure in the hilum of the kidney. (p. 230)

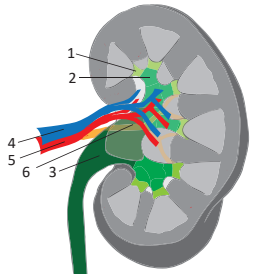

Describe the renal calyces, renal pelvis and structures in the hilum of the kidney

IV. Ureter

28. Define the segments of the ureter and orifice of the ureter. (p. 230)
29. Define the segments or the ureter that are the most vulnerable to obstruction (i.e. by kidney stones) due to their anatomical constriction. (p. 230)
30. Identify the 2 structures coursing anterior to the ureter. (p. 230)
31. Identify the structure coursing dorsally from the ureter. (p. 230)
32. Name the 3 vessels that supply the ureter via their ureteric branches. (p. 230)

V. Urinary bladder

33. Name the 5 parts of the urinary bladder. (p. 231)
34. Describe the borders of the trigone of the bladder. (p. 231)
35. Define the location where urine may stagnate due to an enlarged prostate. (p. 231)
36. Draw the sagittal view of the male pelvis and describe the regional anatomy of the urinary bladder. (p. 231)
37. Identify the ligaments that contribute to the fixation of the urinary bladder. (p. 232)
38. Distinguish the structures that contribute to fixation of the urinary bladder specific for male/female. (p. 232)
39. Name the muscles of the urinary bladder and the muscles in close proximity to the urethra that contribute to urinary continence in both males and females. (p. 232)

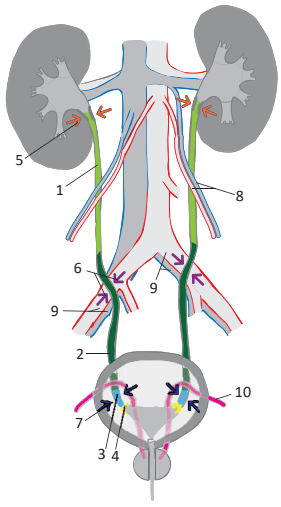

Describe the course of the ureter

VI. Female urethra

40. Define the 5 segments of the female urethra. (p. 233)
41. Explain the reason why females are more vulnerable to urinary infections. (p. 233)

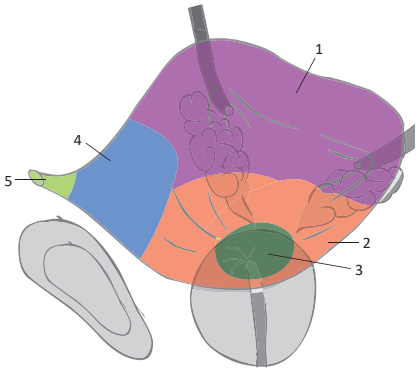

Describe the external structure of the urinary bladder

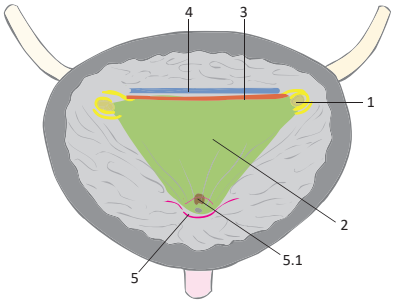

Describe the internal structure of the urinary bladder

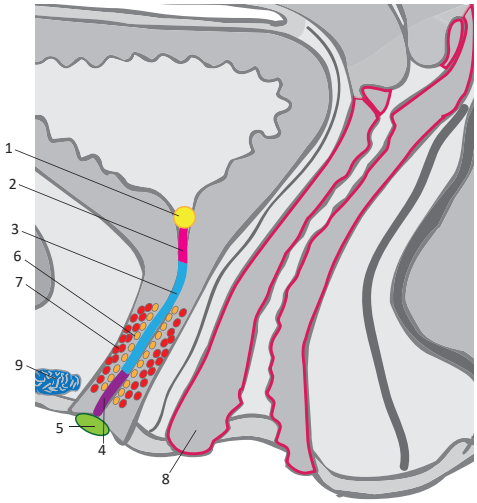

Describe the structure of the female urethra

This copy belongs to ali yaghoubi

We would like to **thank the following anatomists, clinicians and medical students** for their invaluable help, devotion and feedback in the preparation of this chapter.

Anatomists

Assoc. prof. Václav Báča, MD, PhD – Department of Anatomy, Third Faculty of Medicine, Prague, Czech Republic
Assoc. prof. Adriana Boleková, MD, PhD – Department of Anatomy, Pavol Jozef Šafárik University, Košice, Slovakia
Assoc. prof. Veronica Macchi, MD PhD – Institute of Human Anatomy, University of Padova, Italy

Clinicians

Dale Kalina, MD – Department of Internal Medicine, University of Saskatchewan, Canada

Medical students

Klára Macháčková
Danil Yershov
Eva Fürstová
Petr Urban

9 References

1. AGUR, A. M. R. and A. F. DALLEY. Grant's Atlas of Anatomy. 13th Ed. Philadelphia: Lippincot Williams & Wilkins, 2012, 888 p. ISBN 978-1-60831-756-1.
2. HALL, J. E. Guyton and Hall Textbook of Medical Physiology. 12th Ed. Philadelphia: Saunders/Elsevier, 2011, 1120 p. ISBN 978-1-4160-4574-8.
3. CHUNG, K. W.; CHUNG, H. M. and N. L. HALLIDAY. BRS Gross Anatomy. 8th Ed. Philadelphia: Lippincott Williams & Wilkins, 2015. 544 p. ISBN 978-1-4511-9307-7.
4. LANZ, T. and W. WACHSMUTH. Praktische Anatomie. 7 bands. Berlin: Springer, 2003, 3658 p. ISBN 978-3-540-40571-9.
5. MILLS, S. E. Histology for pathologists. 4th Ed. Philadelphia: Lippincot Williams & Wilkins, 2012. 1328 p. ISBN-13: 978-1-4511-1303-7.
6. NETTER, F. H. Atlas of Human Anatomy. Professional Edition. 6th Ed. Oxford: Elsevier. 2014. 640 p. ISBN 978-1-455-75888-3.
7. OVALLE, W. K. and P. C. NAHIRNEY. Netter's Essential Histology: with Student Consult Access. 2nd Ed. Philadelphia: Saunders/Elsevier, 2013. 493 p. ISBN-13: 978-1-4557-0631-0.
8. SNELL, R. S. Clinical anatomy by regions. 9th Ed. Philadelphia: Lippincott Williams & Wilkins, 2012. 768 p. ISBN 978-1-60913-446-4.
9. WILLIAMS, P. L., ed. Gray´s Anatomy: the anatomical basis of medicine and surgery. 38th Ed. New York: Churchill Livingstone, 1995, 2092 p. ISBN 0-443-05717-6.

Memorix Anatomy

8 Genital system

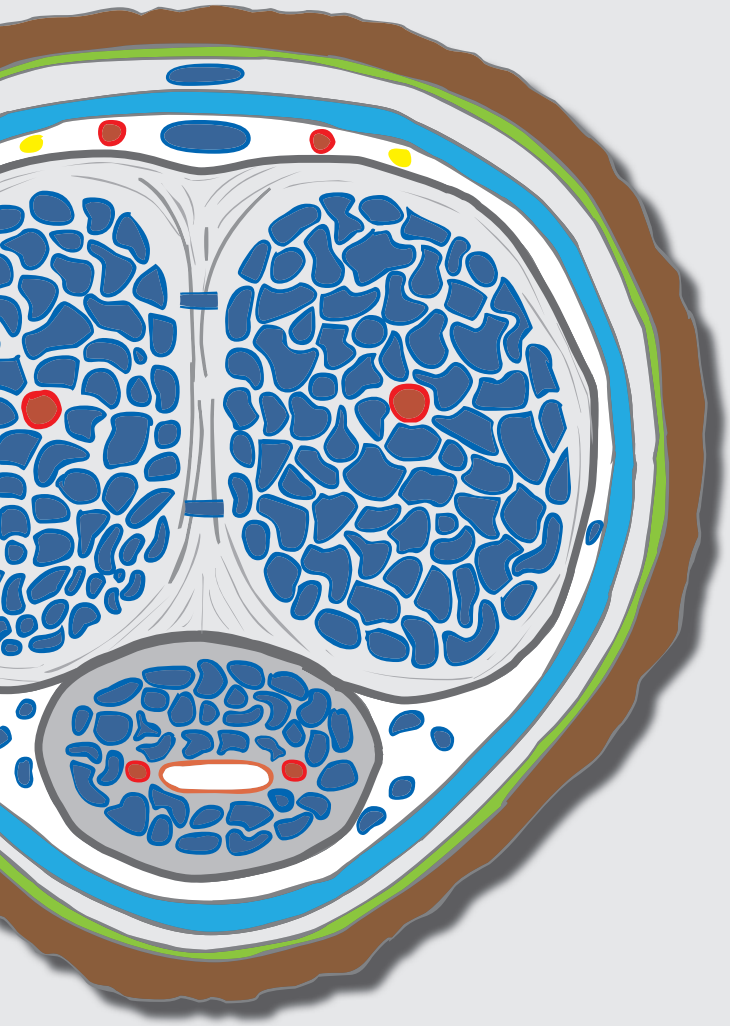

Barbora Beňová
David Kachlík
Radovan Hudák
Ondřej Volný
Adam Whitley

Development of the genital system 238
Male genital system 239
Female genital system 249
Perineum and its muscles 256
Anatomy in pregnancy 257
Fetal membranes, placenta and umbilical cord 258
Fetal anatomy and anatomy of labour 259
Review questions and figures 260
Acknowledgements and references 262

This copy belongs to ali yaghoubi

The sex of the foetus is **genetically determined at the moment of conception**. However, it is not until the **7th prenatal week that it is morphologically discernable**. The **process of differentiation** takes place until the 12th prenatal week, when the two sexes become fully differentiated. The organs of both the male and female genital systems can be divided into the gonads, excretory ducts and external genital organs.

Development of male sex organs	Development of female sex organs
1 Mesonephric duct of Wolff	**2 Paramesonephric duct of Müller**
Epididymis	Uterine tube
Ductus deferens	Uterus
Seminal glands	Cranial portion of vagina
3 Gonadal ridge	
Testis	Ovary
4 Primordia of prostatic buds but also urogenital sinus	
Prostate	Paraurethral glands
5 Urogenital sinus	
Prostatic and membranous urethra	Female urethra and vaginal vestibule
6 Bulbo-urethral gland primordium and greater vestibular gland primordium	
Bulbo-urethral gland	Greater vestibular gland
7 Phallic/genital tubercle	
Body of penis, glans penis and prepuce	Clitoris and prepuce of clitoris
8 Secondary urethral folds	
Root and raphe of penis	
Spongy urethra	Labia minora and bulb of vestibule
9 Labioscrotal/genital swellings	
Scrotum	Labia majora
10 Gubernaculum	
Gubernaculum testis → Scrotal ligament	Round ligament of uterus Proper ligament of ovary

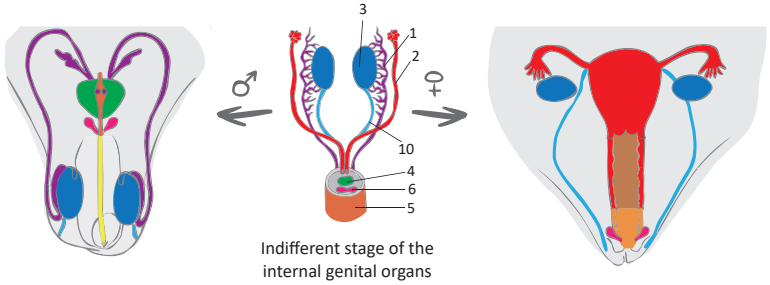

Indifferent stage of the internal genital organs

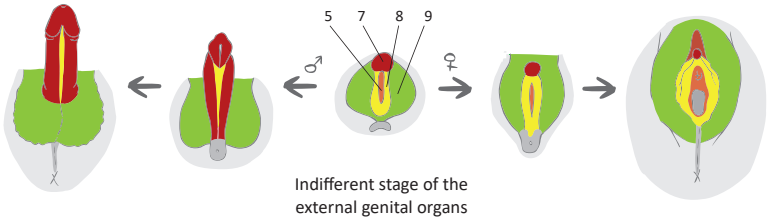

Indifferent stage of the external genital organs

The functional tissue of the ovary is its cortex *(cortex ovarii)*. The functional tissue of the testis is its medulla with the seminiferous tubuli *(tubuli seminiferi)*.

Remnants of the mesonephric tubules (*tubuli mesonephrici*)
in the female: the ductulus transversus epoophori and paroophoron Kobelti
in the male: the superior and inferior aberrant ductule of Haller *(ductulus aberrans superior et inferior Halleri)* in the epididymis and the paradidymis of Giraldes *(paradidymis Giraldesi)*.

Remnants of the mesonephric duct
in the female: the longitudinal duct of Gartner and Malpighi *(ductus longitudinalis epoophori Gartneri-Malpighi)* and the vestige of the ductus deferens *(ductus deferens vestigialis)*
in male: the appendix of the epididymis *(appendix epididymidis)*.

Remnants of the paramesonephric duct
in the female: vesicular appendices of Morgagni *(appendices vesiculosae Morgagni)*
in the male: the appendix of the testis of Morgagni *(appendix testis Morgagni)*

The paramesonephric duct disappears under the influence of anti-paramesonephric hormone (AMH/MIS, *factor antiparamesonephricus*).

Clinical notes

During the indifferent stage of development of the genital system, hormonal imbalance and other insults may lead to disorders of sex development, where phenotype does not correspond to sex genotype.

Embryological remnants of the genital system may give rise to cysts.

The appendix testis (hydatid of Morgagni) is a vestigial remnant of the paramesonaphric duct, present at the upper pole of the testis. It can undergo a torsion, causing acute one-sided testicular pain.

The male genital organs are divided into the external and internal male genitalia according to the developmental origin from the urogenital sinus or urogenital ridge, respectively. **The testes, epididymides, ductus deferentes, seminal glands and prostate** belong to the internal male genital organs. **The scrotum and penis** constitute the external male genital organs. **The male urethra** is both an internal and external genital organ. Its cranial part is internal and its caudal part within the penis is external. As the testes are located **outside the peritoneal cavity**, they are kept at a slightly lower temperature of 32–34 °C, which is optimal for spermatogenesis.

Internal genital organs

- 1 **Testis**
  - a paired gland located inside the scrotum
  - produces spermatozoa and testosterone
- 2 **Epididymis**
  - a paired organ serving as a place for maturation and storage of spermatozoa
- 3 **Ductus deferens**
  - a paired duct that connects the epididymis to the urethra
- 4 **Seminal gland** (*glandula vesiculosa*)
  - a paired organ lying on the posterior surface of the urinary bladder
  - produces most of the volume of the ejaculate
- 5 **Ejaculatory duct** (*ductus ejaculatorius*)
  - a paired common duct formed by the ductus deferens and excretory duct of the seminal gland, terminates in the urethra
- 6 **Prostate** (*prostata*)
  - an unpaired organ located under the urinary bladder
  - produces only a minor part of the ejaculate
  - the ejaculatory ducts terminate in the prostatic urethra
- 7 **Male urethra** (*urethra masculina*)
  - the common terminal part of both the male genital and urinary systems
  - the internal part of the male urethra passes through the prostate and urogenital diaphragm
- 8 **Bulbo-urethral glands** (*glandulae bulbourethrales*)
  - a pair of glands that empty into the urethra below the pelvic floor

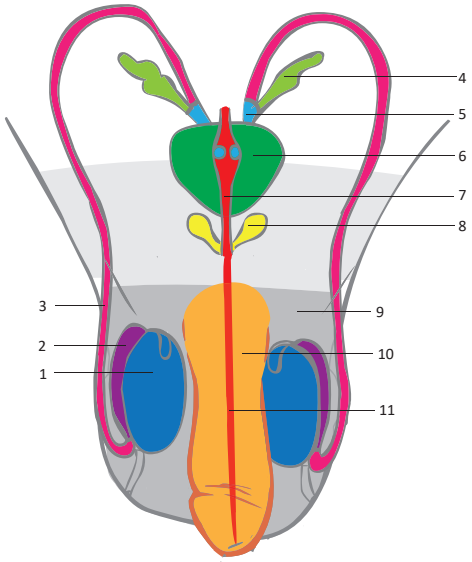

External genital organs

- 9 **Scrotum**
  - a space outside the abdominopelvic cavity where the testis, epididymis and central part of the ductus deferens are located
- 10 **Penis**
  - an unpaired organ that contains the terminal segments of both the urinary and genital systems
  - functions as an organ of micturition and copulation
- 11 **Male urethra** (*urethra masculina*)
  - the common terminal part of both the male genital and urinary systems
  - the external part of the male urethra passes through the corpus spongiosum of the penis

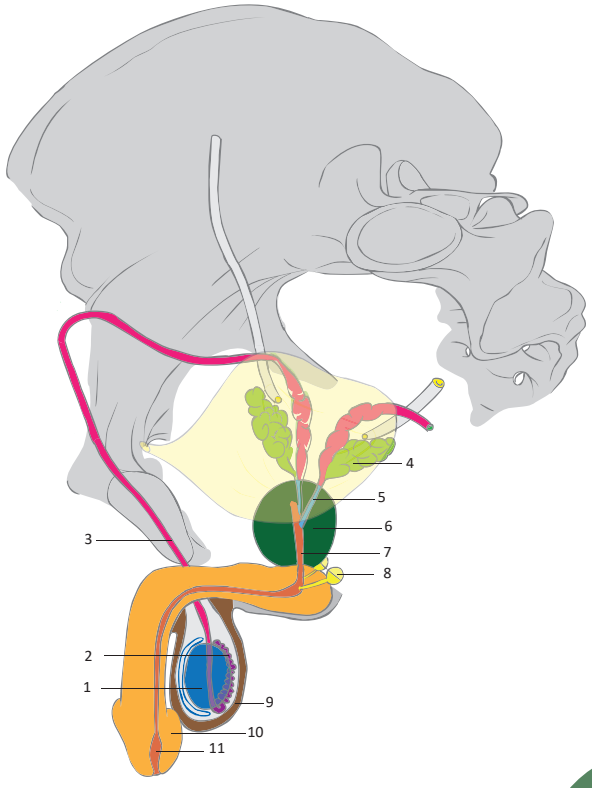

This copy belongs to ali yaghoubi

The testes are a pair of genital glands located outside the abdominopelvic cavity **in the scrotum**. During prenatal development, they originate **in the lumbar region** and **descend through the retroperitoneal space and inguinal canal to reach the scrotum**. The layers of the abdominal wall form the layers of scrotum as the testes passes through them. **The testicular vessels** descend with the testes, hence **the origin of these arteries in lumbar region** of the abdomen. **Lymphatic drainage** is similarly directed to the **lumbar nodes**. Testosterone and spermatozoa are produced in the testes.

External structure

- 1 **Upper pole** (*extremitas superior*)
- 2 **Lower pole** (*extremitas inferior*) – the attachment of the scrotal ligament to the testis
  - 2.1 **Scrotal ligament** (*ligamentum scrotale*) – a ligament attaching the lower pole of the testis and epididymis to the scrotum
- 3 **Anterior border** (*margo anterior*) – the anterior margin facing the tunica vaginalis
- 4 **Posterior border** (*margo posterior*) – the posterior margin facing the epididymis
- 5 **Medial surface** (*facies medialis*) – the medial surface facing the septum of the scrotum
- 6 **Lateral surface** (*facies lateralis*)
- 7 **Tunica vaginalis** (*tunica vaginalis testis*) – originally a part of peritoneum (*processus vaginalis peritonei*) that became one of the layers of the scrotum during the descent of the testis
  – is composed of two layers with a slender slit between them
  - 7.1 **Parietal layer** (*lamina parietalis / periorchium*)
  - 7.2 **Visceral layer** (*lamina visceralis / epiorchium*)
  - 7.3 **Cavum serosum scroti** – a slender cavity between the parietal and visceral layers of the tunica vaginalis

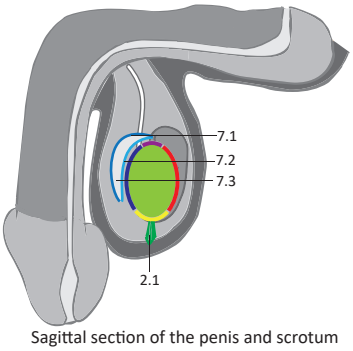

Sagittal section of the penis and scrotum

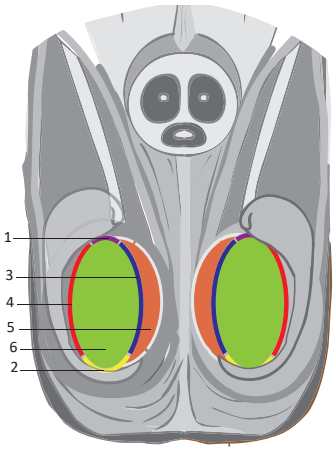

Frontal section of the penis and scrotum

Internal structure

Capsule

- 1 **Tunica albuginea** – a dense membrane of connective tissue covering the testis
  - 1.1 **Vascular layer** (*tunica vasculosa*) – is located under the tunica albuginea

Lobules

- 2 **Lobules of testis** (*lobuli testis*) – each contains a single tubule
  - 2.1 **Convoluted seminiferous tubules** (*tubuli seminiferi contorti*)
    – are lined with complex seminiferous epithelium that contains spermatogenic cells
  - 2.2 **Straight tubules** (*tubuli seminiferi recti*)
    – are continuous with the rete testis
- 3 **Septa of testis** (*septula testis*) – separates the lobules
  – dense plates of connective tissue derived from the tunica albuginea

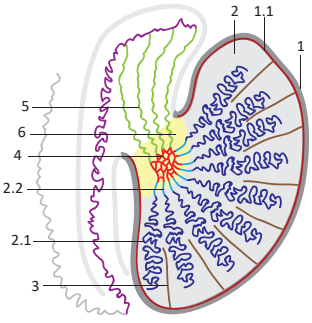

Ducts

- 4 **Rete testis** – a network of tubules in the mediastinum testis
- 5 **Efferent ductules** (*ductuli efferentes testis*)
  – connect the retes testis to the epididymis
  – are located in the head of the epididymis
- 6 **Mediastinum of the testis** (*mediastinum testis*)
  – an area close to the hilum of the testis filled with connective tissue where the rete testis and efferent ductules coalesce

Orchis is the Greek term for testis.

The gubernaculum testis is a thick band of connective tissue that originates from the caudal part of the urogenital fold *(plica urogenitalis)*. It is attached to the mesenchyme of the genital swellings on both sides of the urogenital membrane. Due to its firm attachment to the scrotum, it directs the testis during its descent.

The tunica albuginea is thickened on the posterior surface of the testis where it pierces the parenchyma of the testis and forms the mediastinum testis.

The hilum of the testis is a slit-like area on the posterior surface of the testis where the testicular vessels enter and the efferent ductules leave the testis.

There are 200–300 lobules in the testis.

Layers of the scrotum – page 246.

Clinical notes

Due to the origin of the testis in the retroperitoneal space, it is necessary to check the retroperitoneal lymph nodes for potential metastases as a part of surgical treatment of testicular tumors.

Palpation of the testes in the scrotum is an important part of the physical examination in paediatrics. The absence of the testes in situ, enlargement, pain or other physical abnormalities may be a sign of a potentially serious illness.

Testicular torsion describes an acute situation when the testis twists around the vessels passing in the spermatic cord. The symptoms are swelling of the scrotum, intense pain projecting to the inguinal region and nausea. It usually occurs in adolescent males and requires urgent surgical treatment to prevent complete necrosis of the testis. After 12 hours, the testis is usually irreversibly damaged and it is necessary to remove it.

Orchidectomy is a surgical removal of the testis.

Orchidopexy describes a surgical treatment of cryptorchism. It is a procedure to move an undescended testis to its proper place in the scrotum. Orchidopexy should be performed within the first six years of life, otherwise the risk of infertility and testicular tumors increases.

Descent of the testis

Descent of the testis from their place of their origin in the lumbar region to the scrotum takes place during intrauterine development:

3rd month – unequal growth of the trunk and the pulling force of the gubernaculum begins to move the testis caudally from their position at L1–L2
– the testicular artery (from the aorta), testicular vein (to the inferior vena cava) and lymphatic vessels follow the testis during its descent
– the testis is located in the iliac fossa by the end of the 3rd month
4th month – the testis is located in the deep inguinal ring
6th month – the testis passes through the inguinal canal and pulls the peritoneum (which becomes the vaginal process) fasciae of the abdominal muscles and muscle bundles of the transversus abdominis and internal oblique along with it
– these structures become the layers of the scrotum and the cremaster muscle
– vessels, nerves and the ductus deferens form the contents of the spermatic cord
8th month – the testis should be fully descended
– the arrangement of the scrotal layers are fully formed
– the vaginal process of the peritoneum separates completely from the abdominal peritoneum and closes to form the tunica vaginalis

Descended testes (testes in situ) is an important sign of maturity of the newborn.
Spermatogenesis is only possible in testes positioned inside the scrotum.
Descent of the testes should be complete by the end of **the 3rd postnatal month.**

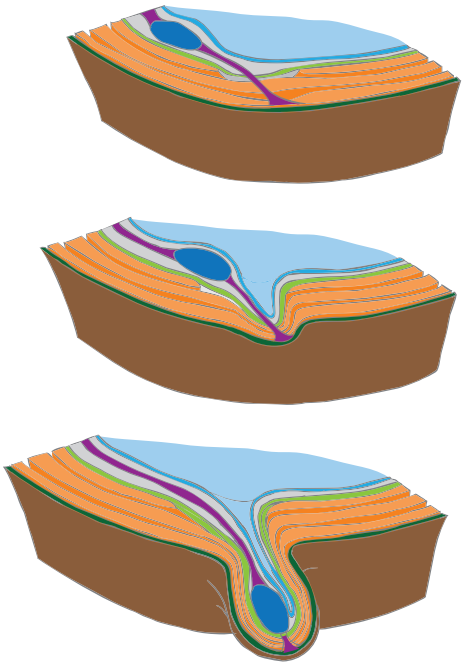

Descent of the testis in the 3rd, 4th and 8th month of development

Innervation

Sympathetic system: the testicular plexus (located around the testicular artery)
Parasympathetic system: the vagus nerve
Visceral sensory system: thoracic nerves (that run to spinal cord segment T10)

Vascular supply

Arterial supply:
- 1 **Testicular artery** (from the abdominal aorta), partially: artery to ductus deferens (from the internal iliac artery) and cremasteric artery (from the inferior epigastric artery)

Venous drainage:
- 2 **Pampiniform plexus and then testicular veins**
  2.1 **Right testicular vein** – to the inferior vena cava
  2.2 **Left testicular vein** – to the left renal vein

Lymphatic drainage:
- 3 **Lumbar nodes**

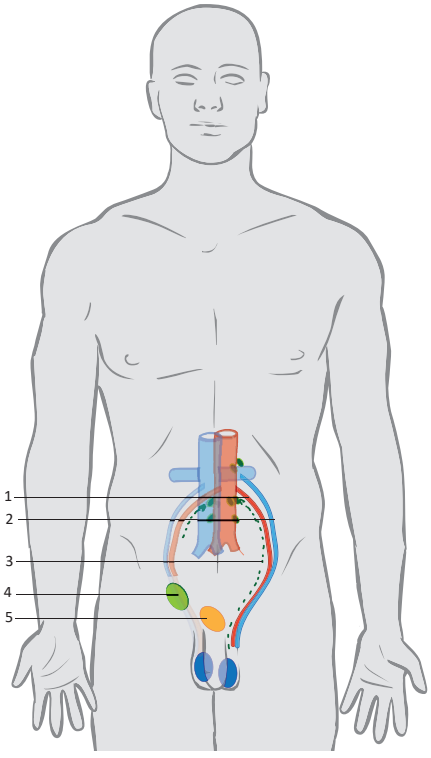

Function

Spermatozoa production occurs in the seminiferous epithelium.
Sertoli cells support, isolate and supply spermatozoa precursor cells (spermatogonia, spermatocytes and spermatids) with nutrients.
They also maintain high levels of testosterone in the seminiferous epithelium, which is necessary for the proper development of spermatozoa.
Testosterone production takes place in Leydig cells, located in the interstitium of the seminiferous tubules. Testosterone is the main male sex hormone (androgen).
It is responsible for male primary and secondary sex characteristics.

Clinical notes

Cryptorchism (undescended testis, retention of the testis)
– failure of descent of the testis and its subsequent absence in the scrotum
- 4 **Dystopic testis** – retention of the testis anywhere on its course from the abdomen at level of L1–2 to the scrotum
  – is most commonly located within the inguinal canal
- 5 **Ectopic testis** – a testis located in a position outside of the course of its physiological descent to the scrotum (e.g. lesser pelvis, perineum, above the pubic symphysis)

This copy belongs to ali yaghoubi

The epididymis is a **highly convoluted duct**. It is attached to the posterior margin of the testis and inferiorly to the scrotum. The tail of the epididymis **continues as the ductus deferens**. Spermatozoa spend 10–12 of their total 72 days of maturation within the epididymis. The epididymis serves as **a reservoir of spermatozoa**, where they mature **and gain the capacity to move and fertilise the ovum**. It also provides nutrition for the spermatozoa.

External structure

- 1 **Head of epididymis** (*caput epididymidis*)
  - the cranial part of the head of the epididymis is formed by the efferent ductules
- 2 **Body of epididymis** (*corpus epididymidis*)
  - is formed by the convoluted duct of the epididymis
- 3 **Tail of epididymis** (*cauda epididymidis*)
  - the caudal part of the epididymis
  - connects to the ductus deferens
- 4 **Sinus of epididymis** (*sinus epididymidis*)
  - a peritoneal fold
  - the visceral layer of the tunica vaginalis (*tunica vaginalis testis*) between the testis and epididymis

Supporting ligaments

- 5 **Superior ligament of epididymis** (*ligamentum epididymidis superius*)
  - connects the upper pole of the testis to the epididymis
- 6 **Inferior ligament of epididymis** (*ligamentum epididymidis inferius*)
  - connects the lower pole of the testis to the epididymis
- 7 **Scrotal ligament** (*ligamentum scrotale*)
  - connects the epididymis and testis to the caudal aspect of the scrotum
  - a remnant of the gubernaculum testis

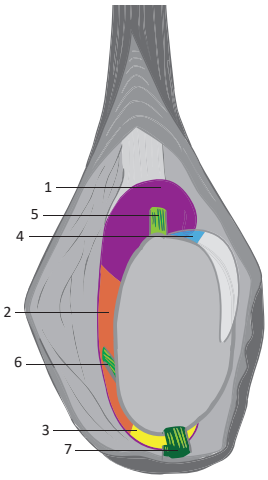

Sagittal view of a dissected scrotum

Ducts and lobules

- 1 **Efferent ductules** (*ductuli eferentes*)
  - 8–12 ductules that pass from the testis to the duct of the epididymis
- 2 **Lobules of epididymis** (*lobuli epididymidis*)
  - each lobule is formed by a single highly convoluted efferent ductule
- 3 **Duct of epididymis** (*ductus epididymidis*)
  - a highly convoluted duct of the epididymis, where spermatozoa definitively mature
- 4 **Ductus deferens** – a duct connecting the duct of the epididymis with the prostate and urethra

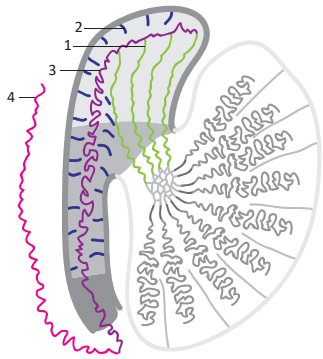

Vascular supply

Arterial supply: the testicular artery (from the abdominal aorta)
Venous drainage: the pampiniform plexus (to the testicular veins, which drain to the inferior vena cava on the right side and to the left renal vein on the left side)
Lymphatic drainage: the lumbar nodes

Innervation

Sympathetic system: the testicular plexus (along the testicular artery)
Parasympathetic system: the vagus nerve
Visceral sensory: spinal nerves from the segments T11–T12

If uncoiled, the ductules of the epididymis would reach a length of six meters.

The vas efferens is an obsolete synonym for the ductus deferens.

The pampiniform plexus and the testicular veins work as a countercurrent blood cooling system.

The epithelium of the efferent ductules is simple cuboidal with variable cell height. It contains kinocilia.

The epithelium of the duct of the epididymis is pseudostratified columnar with stereocilia.

Clinical notes

Varicocele is a term describing dilation of the pampiniform plexus inside the spermatic cord. In young males, the cause remains unknown. In older men, varicocele may arise as a result of impeded blood flow caused by various renal diseases and tumors. It is one of the most common causes of male infertility, as the impeded blood flow results in an increase in temperature inside the testis. Varicocele occurs more commonly on the left side, since the left testicular vein drains into the left renal vein perpendicularly.

The appendix of the epididymis (pedunculated hydatid) is a small stalked sac on the head of the epididymis. It is derived from the mesonephric duct.

The ductus deferens is a tubular organ **that transports spermatozoa from the epididymis to the prostatic urethra** by peristaltic contractions. It passes **from the scrotum through the spermatic cord and inguinal canal** into the lesser pelvis, where it **crosses the ureter** and **enters the prostate**.

Parts

- 1 **Scrotal part** (*pars scrotalis*) – is located in the scrotum,
  – is continuous with the duct of the epididymis
- 2 **Funicular part** (*pars funicularis*)
  – is located in the spermatic cord (*funiculus spermaticus*)
- 3 **Inguinal part** (*pars inguinalis*)
  – is located in the inguinal canal (*canalis inguinalis*)
  - the ductus deferens enters the inguinal canal through the superficial inguinal ring, courses through the canal ventral to the inferior epigastric vessels and enters the pelvis through the deep inguinal ring
- 4 **Pelvic part** (*pars pelvica*)
  – courses through the lesser pelvis, close to the urinary bladder and fuses with the excretory duct of the seminal vesicle
  - **External iliac vessels** – pass posteriorly to the ductus deferens
  - **Ureter** – runs beneath the ductus deferens in close proximity to the fundus of the urinary bladder
- 5 **Ampulla of ductus deferens** (*ampulla ductus deferentis*)
  – the dilated, most distal segment of the ductus deferens
- 6 **Ejaculatory duct** (*ductus ejaculatorius*)
  – a common duct formed by the union of the ductus deferens with the excretory duct of the seminal vesicle
  – enters the prostate and joins the prostatic urethra at the seminal colliculus

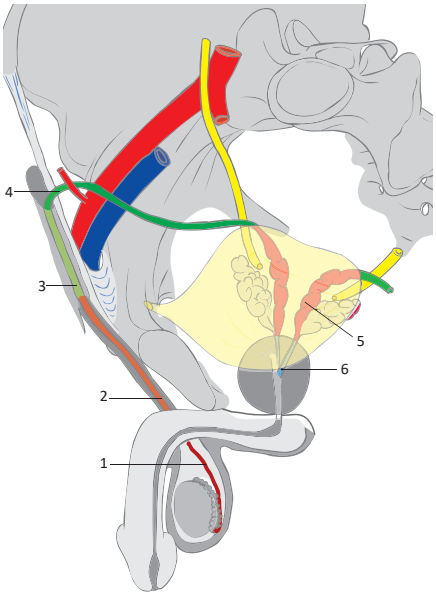

Left superior-oblique view of the male pelvis

The spermatic cord is a **tough rope-like structure that contains the ductus deferens and several vessels and nerves**. It courses from **the scrotum to the inguinal canal**. The venous pampiniform plexus lowers the temperature inside the spermatic cord, which is necessary for the proper maturation of spermatozoa. The layers of the abdominal wall continue over the spermatic cord and the scrotum, forming their coverings.

Contents

- 1 **Ductus deferens** – runs from the epididymis to the prostate
  - 1.1 **Artery to ductus deferens** (*arteria ductus deferentis*)
    – a branch of the internal iliac artery that supplies the ductus deferens
- 2 **Testicular artery** – a branch of the abdominal aorta supplying the testis and the epididymis
- 3 **Pampiniform plexus** (*plexus pampiniformis*) – a venous plexus conveying blood from the testis and epididymis to the inferior vena cava on the right and to the left renal vein on the left
- 4 **Testicular plexus** (*plexus testicularis*) – the nervous plexus of the testis
- 5 **Deferential plexus** (*plexus deferentialis*)
  – a visceral sensory nervous plexus of the ductus deferens

6 **Lymph vessels** – lymph from the testis and epididymis flows to the lumbar lymph nodes

7 **Vestige of processus vaginalis** (*vestigium processus vaginalis testis*)
– a remnant of the peritoneal fold

Coverings

- 8 **External spermatic fascia** (*fascia spermatica externa*)
  – a continuation of the superficial abdominal fascia
- 9 **Cremaster** – a skeletal muscle that pulls the scrotum towards the abdominal wall
  – consists of muscle bundles from the internal oblique and transversus abdominis muscles
  – the cremasteric fascia (*fascia cremasterica*) covers the cremaster and its muscle bundles
- 10 **Internal spermatic fascia** (*fascia spermatica interna*) – a continuation of the transversalis fascia of the ventrolateral abdominal wall

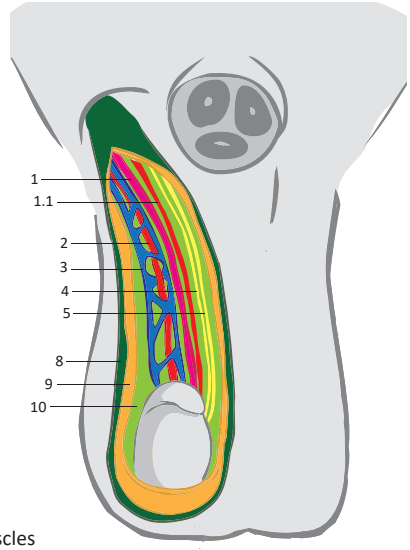

Frontal section of the penis and scrotum

This copy belongs to ali yaghoubi

The seminal glands are **located behind the urinary bladder above the prostate**. Each seminal gland is a simple tubular gland, **composed of a single duct that has multiple convolutions**. The seminal glands produce **50–80 % of the ejaculate**. The excretory duct of the seminal gland joins the ductus deferens to form **the ejaculatory duct** that empties into the urethra.

Regional anatomy and ducts

Seminal gland and its ducts

- 1 **Seminal gland** (*glandula vesiculosa*)
- 2 **Excretory duct** (*ductus excretorius*) – a duct of the seminal gland joining the ductus deferens
- 3 **Ejaculatory duct** (*ductus ejaculatorius*) – a common duct formed by the union of the excretory duct and ductus deferens

Regional anatomy

- 4 The posterior wall of the urinary bladder lies **anteriorly**
- 5 The rectovesical pouch of the peritoneal cavity is located **posteriorly**
- 6 The ampulla of the ductus deferens is situated **medially**
- 7 The prostate is found **caudally**

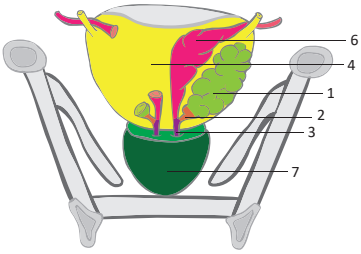

Posterior view of the seminal glands

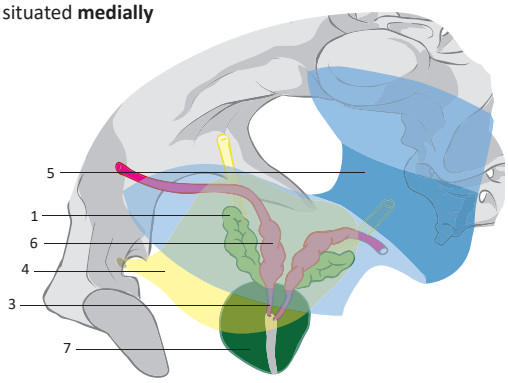

Left upper oblique view of the male pelvis

Vascular supply

Arterial supply: artery to ductus deferens, inferior vesical artery, middle rectal artery
Venous drainage: prostatic venous plexus, vesical venous plexus
Lymphatic drainage: internal and external iliac lymph nodes

Innervation

Sympathetic system: prostatic plexus derived from the inferior hypogastric plexus
Parasympathetic system: prostatic plexus derived from the inferior hypogastric plexus
Viscerosensory fibres: are located in the prostatic plexus

2.6 Bulbo-urethral glands – Glandulae bulbourethrales

The bulbourethral glands are a pair of **accessory genital glands that empty into the ampulla urethrae**. These pea-sized glands are located on the inferior surface of the deep transverse perineal muscle. They produce a viscous liquid that lubricates the internal surface of the urethra during ejaculation.

The gland and its regional anatomy

- 1 **Bulbo-urethral gland** (*glandula bulbourethralis*)
- 2 **Superiorly:** the gland lies on the inferior surface of the deep transverse perineal muscle
- 3 **Anteriorly:** the duct enters the ampulla urethrae
- 4 **Inferiorly:** the bulb of the penis is located under the glands

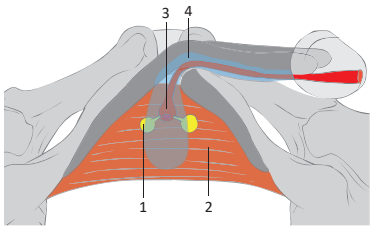

Glandulae seminales, vesiculae seminales, seminal vesicles and vesicular glands are alternative terms for the seminal glands.

Verumontanum is an obsolete term for the seminal colliculus.

Seminal glands produce an alkaline substance that contains fructose (a nutrient for spermatozoa), globulin proteins and prostaglandines (hormone-like compounds that stimulate the smooth muscle of the female genital organs).

The seminal glands develop from the ductus deferens. They are 4–5 cm long, 17–20 mm wide and 6–9 mm thick. When uncoiled, the length of the simple tubular gland is 10–15 cm.

The seminal glands are lined with pseudostratified columnar epithelium.

The prostatic glands are lined with cuboidal to pseudostratified columnar epithelium (depending on the secretion activity of the gland).

Proportion of gland tissue in the different histological zones of the prostate: Peripheral zone 75 %
Central and transitional zone 20 %
Aglandular zone (isthmus) and periurethral zone 5 %.

Clinical notes

Per rectum palpation of the prostate is a standard part of the clinical examination, performed by palpating the prostate through the anterior wall of the rectum.

The zones of the prostate vary in shape, in proportion of fibromuscular stroma and in their tendency to develop disease. The different zones of the prostate can be visualised by transrectal ultrasound and distinguish in the magnetic resonance imaging.

Benign prostate hyperplasia is characterised by an increase in number of the submucosal prostate glands. This leads to the enlargement of transistional zone, which can lead to obstruction of urinary flow. The enlarged transitional zone compresses the fibromuscular stroma of the peipheral zone, eventually transforming it into the "surgical" capsule of the prostate. This allows surgical enucleation of transistional zone, sparing the peripheral part.

Carcinoma of the prostate is a malignant neoplasia arising in the glandular epithelium of the peripheral zone or, less commonly, in the central or transistional zones.

The prostate is the **largest male genital gland**. It produces **30 % of ejaculate fluid**. It is located **subperitoneally, inferior to the urinary bladder**. **The urethra courses through the prostate** along with the paired ejaculatory ducts, the common duct for the epididymis and the seminal glands.

External structure

- 1 **Base of prostate** (*basis prostatae*) – the broad cranial part of the prostate – is located around the neck of the urinary bladder
- 2 **Apex of prostate** (*apex prostatae*) – the tip of prostate, points towards the pelvic floor
- 3 **Prostatic urethra** (*pars prostatica urethrae*) – a segment of the urethra coursing through the prostate
- 4 **Anterior surface** (*facies anterior*) – faces the pubic symphysis, is attached to the pubic symphsis by the puboprostaticus muscle and puboprostatic ligaments
- 5 **Posterior surface** (*facies posterior*) – the posterior surface facing the rectum
- 6 **Right and left inferolateral surfaces** (*facies inferolateralis dextra et sinistra*) – the lateral surfaces facing the pelvic floor
- 7 **Right, left and middle lobes of the prostate** (*lobus dexter, sinister et medius*) – the three lobes of the prostate

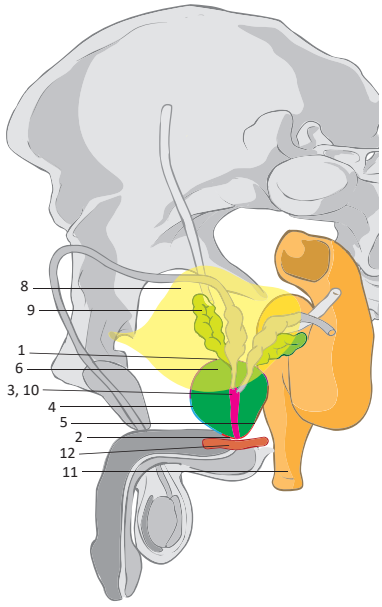

Left superior-oblique view of the male pelvis

Regional anatomy

- 8 **Cranially** – the neck of the urinary bladder, embedded in the base of the prostate
- 9 **Dorso-cranially** – the seminal glands laterally and the ductus deferens medially
- 10 **Centrally** – the urethra
- 11 **Dorsally** – the rectum, behind the rectovesical septum
- 12 **Caudally** – the apex of the prostate is embedded in the pelvic floor

Internal structure

1 **Prostatic capsule** – formed by three layers
- 1.1 **Capsule of prostate** (*capsula prostatica*) – a fibromuscular double-layered capsule, tightly attached to the surface of the prostate
- 1.2 **Prostatic venous plexus** (*plexus venosus prostaticus*)
- 1.3 **Periprostatic capsule** (*capsula periprostatica*) – the visceral pelvic fascia

2 **Division of the prostate into histological zones** (according to McNeal)
- 2.1 **Peripheral/inferoposterolateral zone** (*zona inferoposterolateralis/peripheralis*) – the outer part of the prostate, rich in glands
- 2.2 **Central/superomedial zone** (*zona superomedialis/centralis*) – the internal wedge-shaped area around the openings of the ejaculatory ducts and the prostatic utricle
- 2.3 **Peri-urethral gland zone** (*zona glandularum periurethralium*) – a slender strip of mucous glands in the wall of the urethra, the innermost zone
- 2.4 **Transitional/anteromedial zone** (*zona anteromedialis/transitionis*) – is located between the peripheral and peri-urethral zones around the proximal part of the urethra
- 2.5 **Anteriormedian zone / commisura** (*isthmus of prostate/zona anteromediana*) – a non-glandular zone composed of fibromuscular stroma

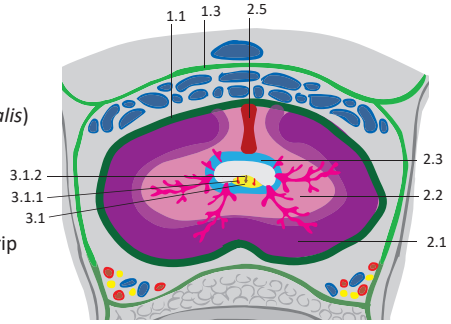

Transversal section of the prostate

- 3 **Urethral crest** (*crista urethralis*) – an elevated crest on the posterior surface of the urethra
  - 3.1 **Seminal colliculus** (*colliculus seminalis*) – an elevated area on the urethral crest
    - 3.1.1 **Openings of the ejaculatory ducts** – on both sides of the seminal colliculus
    - 3.1.2 **Prostatic utricle** (*utriculus prostaticus*) – an unpaired blind remnant of the paramesonephric duct
- 4 **Prostatic sinus** (*sinus prostaticus*) – a pair of pits on both sides of the urethral crest where the prostatic ductules (ducts of prostatic glands) open

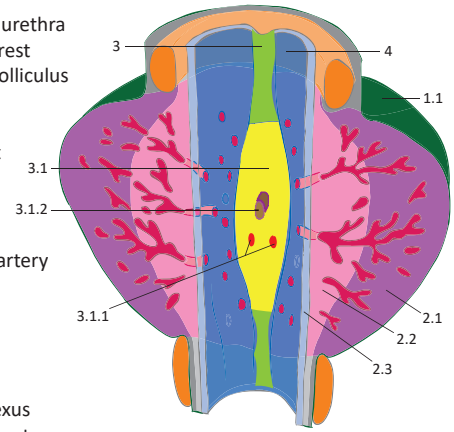

Frontal section of the prostate, posterior view

Vascular supply

Arterial supply: the prostatic branches of the inferior vesical artery and middle rectal artery
Venous drainage: the prostatic venous plexus and vesical venous plexus
Lymphatic drainage: the internal and external iliac nodes and the sacral nodes

Innervation

Sympathetic system: the prostatic plexus originating from the inferior hypogastric plexus
Parasympathetic plexus: the prostatic plexus originating from the inferior hypogastric plexus
Viscerosensory system: nerve fibers in the parasympathetic and sympathetic prostatic plexus

This copy belongs to ali yaghoubi

The scrotum is a sac **located on the outside of the body**, which contains the testis and epididymis. The temperature inside the scrotum is **2–4 degrees lower than core body temperature**. This ensures optimal spermatogenesis. **Contraction of the cremaster muscle pulls the scrotum upwards, towards the perineum**.

External structure

Septum of scrotum (*septum scroti*) – a septum composed of connective tissue that separates the scrotum into two independent cavities, each containing one testis

Raphe of scrotum (*raphe scroti*) – a seam-like line in the place where the genital (labioscrotal) swellings merged during development, right over the septum of the scrotum,
– continues ventrally as the raphe of the penis and dorsally as the perineal raphe

Scrotal ligament (*ligamentum scrotale*) – a remnant of the gubernaculum, a cord of connective tissue attaching the lower pole of the testis and tail of the epididymis to the floor of the scrotum

Layers of the scrotum

Layer of the scrotum	Corresponding layer of the abdominal wall
1 Skin	Skin
2 Dartos fascia (*tunica dartos*)	Fatty layer of superficial fascia
3 External spermatic fascia (*fascia spermatica externa*)	Membranous layer of superficial fascia
4 Cremaster and cremasteric fascia (*musculus cremaster, fascia cremasterica*)	Internal oblique Transversus abdominis
5 Internal spermatic fascia (*fascia spermatica interna*)	Transversalis fascia
6 Parietal layer of the tunica vaginalis *(periorchium)*	Parietal peritoneum
7 Visceral layer of the tunica vaginalis *(epiorchium)*	Visceral peritoneum

8 **Vaginal cavity of testis** (*cavitas vaginalis testis*)
– a serous cavity between the two layers of the tunica vaginalis

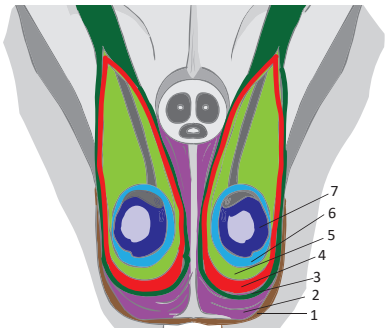

Anterior view of the layers of the scrotum

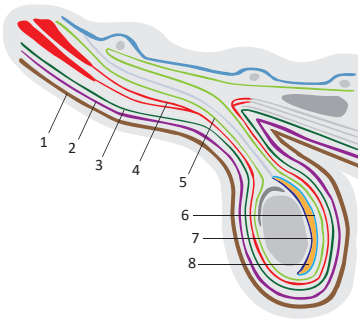

Schematic section through the layers of the scrotum and abdominal wall

Vascular supply

Arterial supply:
– **anterior half of the scrotum**: the anterior scrotal branches from the external pudendal arteries
– **posterior half of the scrotum**: the posterior scrotal branches from the internal pudendal artery
– **scrotal layers**: the cremasteric artery from the inferior epigastric artery

Venous drainage:
– the anterior scrotal veins, which drain into the great saphenous vein
– the posterior scrotal veins, which drain into the internal pudendal vein

Lymphatic drainage: the superficial inguinal nodes

Innervation

Motor system: the genital branch of the genitofemoral nerve

Somatosensory system:
– **anterior 1/3 of the scrotum:** the ilioinguinal nerve, genital branch of the genitofemoral nerve
– **posterior 2/3 of the scrotum**: the pudendal nerve, posterior cutaneous nerve of the thigh

The cremasteric reflex is triggered by tactile stimulation of the internal surface of the thigh, which leads to contraction of the cremaster. The afferent limb is formed by the somatosensory fibres of the femoral branch of the genitofemoral nerve. The efferent limb is formed by the motor fibres of the genital branch of the genitofemoral nerve.

Cavum serosum scroti is an obsolete term for the vaginal cavity of the testis.

The helicine arteries (*arteriae helicinae*) are convoluted in a flaccid penis and straighten during erection.

The tunica albuginea of the corpora cavernosa is denser than the tunica albuginea of the corpus spongiosum.

The bulbospongiosus is attached to the corpus spongiosum in the area of the bulb of the penis. It aids in emptying of the urethra and its rhythmical contractions contribute to the process of ejaculation.

Balanos is the Greek term for the bulb of penis. **Posthe** is the Greek term for foreskin.

Clinical notes

A hydrocele is an enlargement of the scotum caused by accumulation of fluid inside the vaginal cavity of the testis. **A congenital hydrocele** results from a persistent communication between the peritoneal cavity and the layers of the scrotum via a patent vaginal process of peritoneum. **An acquired hydrocele** can occur as result of inflammation of the testis or epididymis or from a tumour. However, in the majority of cases, its origin remains unknown.

A scrotal hernia arises due to a persistent communication between the peritoneal cavity and vaginal cavity of the testis (or the vaginal process of the peritoneum). An intestinal loop enter the scrotum.

Cabanas' lymph node (*nodus lymphoideus inguinalis superficialis superomedialis*) is the sentinel node of the skin of the penis.

In a suspected testicular tumor, a diagnostic biopsy is contraindicated due to the risk of dissemination of tumour cells in the layers of the scrotum.

Balanoposthitis is inflammation of the mucosa of the bulb of the penis and the internal layer of the foreskin.

The penis is an external genital male organ with **both excretory and copulative functions**. It is formed from 3 erectile bodies and the urethra, which courses throughout its entire length.

External structure

1 **Root of penis** (*radix penis*) – composed of two crura
2 **Crura of penis** (*crura penis*) – a paired internal part of the corpora cavernosa
– attaches to the phalic crest of the inferior pubic ramus and to the pubic symphysis
3 **Bulb of penis** (*bulbus penis*) – an unpaired dilated part of the corpus spongiosum underneath the perineum
4 **Body of penis** (*corpus penis*) – the external part of the penis, composed of three erectile bodies
- 4.1 **Dorsum of penis** (*dorsum penis*, *facies dorsalis*) – the „anterior" surface in a flaccid penis in the anatomical position, the upper to posterior surface in an erect penis
- 4.2 **Urethral surface** (*facies urethralis*) – the „posterior" surface in a flaccid penis facing the scrotum – the urethra courses the penis right beneath the urethral surface
- 4.3 **Raphe of penis** (*raphe penis*) – a longitudinal seam-like line on the urethral surface – a developmental remnant of the genital/labioscrotal swellings
- 4.4 **Fundiform ligament of penis** (*ligamentum fundiforme penis*) – originates at the linea alba – a loop-like ligament attaching the penis to the pubic symphysis
- 4.5 **Suspensory ligament of penis** (*ligamentum suspensorium penis*) – attaches the dorsum of the penis to the anterior surface of the pubic symphysis

5 **Glans penis** – the most distal segment of the corpus spongiosum, the location of the external urethral orifice
- 5.1 **Corona of glans** (*corona glandis*) – a dilated rim of the glans facing the body of the penis
- 5.2 **Neck of glans** (*collum glandis*) – a groove separating the glans from the body of the penis
- 5.3 **External urethral orifice** (*ostium urethrae externum*) – the most distal part at the tip of the glans
- 5.4 **Foreskin / prepuce** (*preputium*) – a skin fold of the body of the penis that can be pulled over the glans to a variable extent
- 5.5 **Frenulum** (*frenulum preputii*) – a ventrally located skin crease – a transition between the skin of the glans and the skin of the prepuce
- 5.6 **Preputial glands / Tyson's glands** (*glandulae preputiales*) – small smegma-producing glands at the inner margin of the foreskin

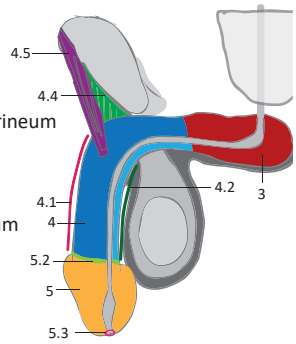

Sagittal section of the penis

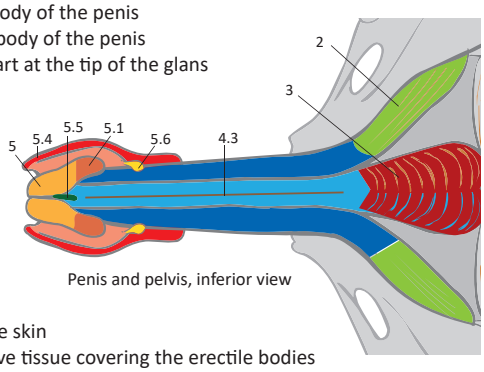

Penis and pelvis, inferior view

Internal structure

1 **Skin**
2 **Superficial fascia of penis** (*fascia penis superficialis*) – enables free sliding of the skin
3 **Deep fascia of penis / Buck' fascia** (*fascia penis profunda*) – a layer of connective tissue covering the erectile bodies
4 **Tunica albuginea** (*tunica albuginea*) – a dense layer of connective tissue covering the erectile bodies
5 **Corpora cavernosa penis** – erectile bodies that erect the penis when engorged with blood
– the ischiocavernosus attaches to them, contributing to the process of ejaculation
- 5.1 **Cavernous spaces and trabeculae of corpora cavernosa** – spaces that fill with venous blod during erection – little cavities inside the erectile bodies lined with endothelium, fenestrated by trabeculae
- 5.2 **Septum penis** – the incomplete fibrous plate separating the two corpora cavernosa

6 **Corpus spongiosum penis** – the unpaired erectile body beneath the urethral surface encompassing the spongy part of the male urethra; it constitutes the bulb and glans of the penis, and the body of the penis along with the corpora cavernosa

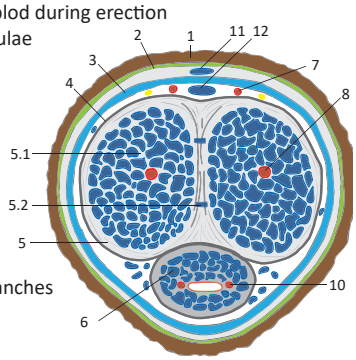

Transverse section of the penis

Vascular supply

Arterial supply: the internal pudendal artery
7 **Dorsal artery of penis** – supplies the skin and glans of the penis and the foreskin
8 **Deep artery of penis** – inside the corpus cavernosum, gives off the helicine arteries as its branches
9 **Artery of bulb of penis** – inside the bulb of the penis
10 **Urethral artery** – inside the corpus spongiosum

Venous drainage:
11 **Superficial dorsal vein of penis** – an unpaired vein that drains through the external pudendal veins into the common femoral vein
12 **Deep dorsal vein of penis** – an unpaired vein that bifuractes into the pudendal plexus of Santorini (and further to the prostatic venous plexus), and into the internal pudendal vein which converges into the internal iliac vein

Lymphatic drainage: the superficial inguinal nodes; **glans of penis:** the deep inguinal nodes, external iliac nodes; **corpora cavernosa, corpus spongiosum, urethra:** the internal iliac nodes

Innervation

Somatosensory system: the ilioinguinal nerve (the skin of the root of the penis), dorsal nerve of the penis from the pudendal nerve
Sympathetic system: the cavernous nerves of the penis from the inferior hypogastric plexus
Parasympathetic system: the cavernous nerves of the penis from the sacral splanchnic nerves via the inferior hypogastric plexus

This copy belongs to ali yaghoubi

The male urethra is **the final segment of the male excretory and reproductive systems**. The sphincter vesicae prevents **retrograde flow of semen into the urinary bladder** and prevents the release of urine during ejaculation. Along its course, the male urethra contains **constrictions and dilations** and **two curvatures**.

External structure

Segments

- 1 **Internal urethral orifice** (*ostium urethrae internum*)
  – the internal orifice inside the urinary bladder
- 2 **Intramural part** (*pars intramuralis, preprostatic part*) – a constricted part in the wall of the urinary bladder encircled by the smooth sphincter vesicae (*musculus sphincter vesicae*), which continues caudally as the smaller internal urethral sphincter
- 3 **Prostatic urethra** (*pars prostatica urethrae*) – a dilated part inside the prostate
  – two ejaculatory ducts open at the seminal collicle, transporting semen into the urethra
- 4 **Membranous urethra / intermediate part of urethra** (*pars intermedia/membranacea*)
  – a constricted part passing through the pelvic floor
  – is surrounded by the striated external urethral sphincter
- 5 **Spongy urethra** (*pars spongiosa*) – passes within the corpus spongiosum of the penis
  5.1 **Ampulla urethrae** – the dilated initial segment, where the bulbo-urethral glands open
  5.2 **Navicular fossa** (*fossa navicularis*) – the dilated final segment of the urethra
- 6 **External urethral orifice** (*ostium urethrae externum*)

Curvatures

- 7 **Subpubic curvature** – a superior-facing concavity at the transition of the membranous and spongy urethra, impossible to straighten
- 8 **Prepubic curvature** – a inferior-facing concavity of the spongy urethra, straightens during erection

Sphincters

- 9 **Internal urethral sphincter**
  – a weak smooth muscle sphincter innervated by visceromotor fibres of the sympathetic system
- 10 **External urethral sphincter** – a strong striated muscle innervated by somatomotor nerve fibres originating in the S2–S4 spinal cord segments

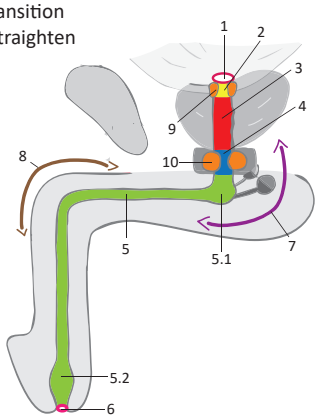

Sagittal section of the male urethra

Constricted and dilated segments

Constricted segments

- 1 **Intramural part**
- 2 **Membranous urethra**
- 3 **Spongy urethra**
- 4 **External urethral orifice**

Dilated segments

- 5 **Prostatic urethra**
- 6 **Ampulla urethrae**
- 7 **Navicular fossa**

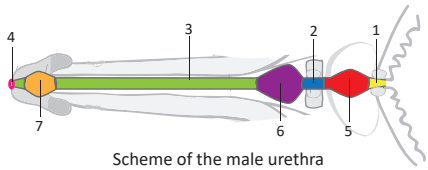

Scheme of the male urethra

Mechanism of erection and ejaculation

Erection is triggered by the parasympathetic system and **ejaculation by the sympathetic system**.

1. **Sexual stimuli are processed by the hypothalamic nuclei** and the limbic system.
2. **The stimuli** are transferred **to spinal cord segment S3,** where the **parasympathetic sacral splanchnic nerves** originate and, as the cavernous nerves of the penis, innervate erectile bodies.
3. Under the influence of the parasympathetic system, **the intimal thickenings within the helicine arteries diminish**, which **increases blood flow to the cavernous spaces**.
4. **The erectile bodies enlarge** and **compress the cavernous vein of penis, preventing blood outflow**.
5. **The prepubic curvature straightens** and the **penis enlarges**.
6. Stimulation of sensory nerve endings in the penis leads to **activation of the ejaculation center in the spinal cord segments T11–L2** under the influence **of the sympathetic system**.
7. The sympathetic system **contracts the ductus deferens**, which transports spermatozoa from the epididymis to the prostatic urethra, where they mix with fluid from prostate and seminal glands.
8. Concurrently, under the influence of the sympathetic system, **the spincter vesicae** and internal urethral sphincter contract, **preventing retrodrade flow of semen into the urinary bladder**.
9. **Contractions of the bulbospongiosus** and ischiocavernosus **eject semen out of the urethra**.

The 20 cm long male urethra is about 5 times longer than the 4 cm long female urethra. However, it is narrower and curved.

The epithelium of the male urethra varies along it course:
The intramural part and prostatic urethra above the opening for the ejaculatory ducts are lined with transitional epithelium.
The caudal part of the prostatic urethra and membranous and spongy urethrae are lined with stratified columnar epithelium.
The navicular fossa is lined with non-keratinised stratified squamous epithelium.
The external urethral orifice is lined with keratinised stratified squamous epithelium.

According to the WHO 2010 data, normal values for physiological spermiogram are as follows:
Semen volume > 1.5 ml
Spermatozoa concentration > 15 million spermatozoa/ml
Spermatozoa motility > 40 %
Spermatozoa morphology > 4 %.

Clinical notes

Clinically, the urethra can be divided in two parts: the anterior and posterior parts. From the anatomical point of view, the posterior urethra consists of the intramural part, prostatic urethra and membranous urethra. The anterior urethra consists of the spongy urethra.

Compared to the female urethra, the male urethra is longer and narrower and therefore less prone to infections. However, due to its course, these infections tend to have a worse clinical manifestation.

After transurethral resection of the prostate (TURP) for benign hyperplasia of the prostate, the neck of the urinary bladder remains open during ejaculation. This results in retrograde flow of semen into the urinary bladder, causing the so called “dry ejaculation”.

Epispadias is a rare atypical location of the external urethral orifice on the dorsum of the penis (1:30 000)

Hypospadias is a more common atypical location of the external urethral orifice on the ventral (urethral) surface of the penis (1:300).

Nitric oxide (NO) relaxes vascular smooth muscle. Drugs for erectile dysfunction, such as sildenafil-Viagra, increase the concentration of NO in the vascular beds of the erectile bodies.

The internal female genital organs include the genital glands **(ovaries)**, **uterine tubes, uterus and vagina**. **The vestibule, labia, female erectile bodies (clitoris and bulb of the vestibule) and mons pubis** constitute the **external female genital organs**.

Internal genital organs

- 1 **Ovary** (*ovarium*) – an intraperitoneally located pair of glands that contain maturing oocytes
- 2 **Uterine tube** (*tuba uterina*) – a paired tubular organ attached to the uterine horn
  - – partially covers the ovary
  - – the most common location of fertilisation of an oocyte
- 3 **Uterus** (*uterus*) – an unpaired hollow organ
  - – houses the developing embryo and foetus
- 4 **Vagina** (*vagina*) – the terminal segment of the female genital system
  - – the female organ of copulation and part of the birth canal

External genital organs

- 5 **Vestibule** (*vestibulum vaginae*)
  - – an area containing the external openings of the vagina, urethra, and paired accessory glands
- 6 **Greater vestibular gland / Bartholin's gland** (*glandula vestibularis major Bartholini*)
  - – a paired gland emptying into the vestibule
- 7 **Lesser vestibular glands** (*glandulae vestibulares minores*)
  - – small glands emptying into the vestible
- 8 **Labia majora** (*labia majora pudendi*)
  - – cover the labia minora
- 9 **Labia minora** (*labia minora pudendi*)
  - – cover the vestibule
- 10 **Clitoris** (*clitoris*) – the unpaired female erectile body
- 11 **Bulb of vestibule** (*bulbus vestibuli*)
  - – a pair of female erectile bodies located around the vestibule

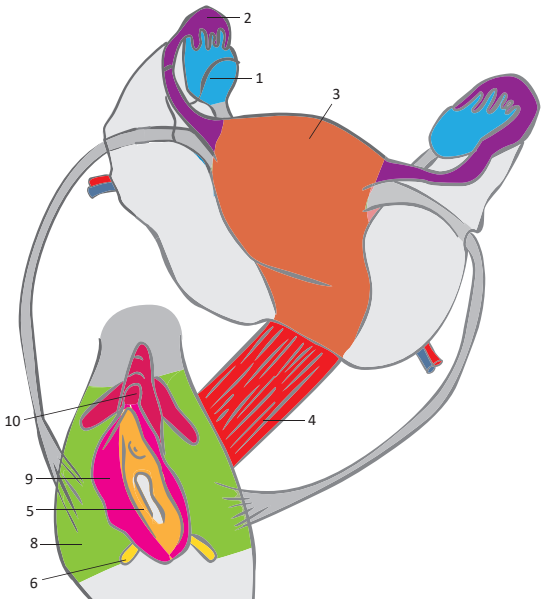

Left upper oblique view of the female genital system

Growth and maturation of follicle

Ovarian cycle – a 28 day cycle during which a single follicle reaches maturity
– during the cycle, the ovarian cortex cells differentiate and form the layers of the ovarian follicle
Ovulation – a secondary oocyte is released from a mature follicle into the uterine tube where fertilisation takes place

- 1 **Maturation of the follicle**
  - – several distinct stages of follicle maturation are distinguished:
  - 1.1 **Primordial follicle**
  - 1.2 **Primary follicle**
  - 1.3 **Secondary follicle**
  - 1.4 **Tertiary follicle**
  - 1.5 **Mature/Graafian follicle**
- 2 **Corpus rubrum/haemorrhagicum** (haemorhagic body)
  - – the immediate residue of a ruptured follicle after ovulation
- 3 **Corpus luteum**
  - – develops from the corpus rubrum
  - – secretes progesterone, estrogen, androgens, relaxin and inhibin
  - 3.1 **Corpus luteum of menstruation** (*corpus luteum menstruationis*)
    - – is present during the second half of the menstrual cycle
  - 3.2 **Corpus luteum of pregnancy** (*corpus luteum graviditatis*)
    - – produces progesterone until the 4th month of pregnancy
    - – produces the polypeptide hormone relaxin, which loosens the soft tissue of the pubic symphysis and the sacro-iliac and sacrococcygeal joints, thus facilitating labour
- 4 **Corpus albicans**
  - – a scar left after an obliterated corpus luteum of pregnancy

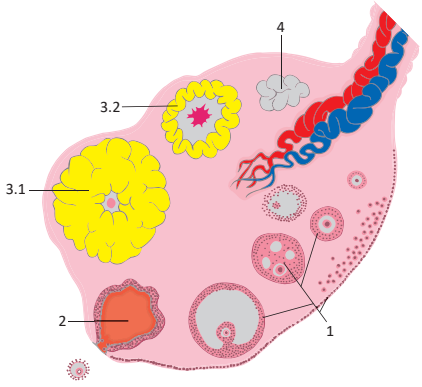

Stages of follicle maturation in the ovary

This copy belongs to ali yaghoubi

The ovary is the female genital gland (gonad). It is a paired intraperitoneal organ located **in the pelvis**. The ovary contains **oocytes within follicles, undergoing the process of maturation**. The ovary produces **various steroids and polypeptide hormones**.

External structure

1 **Medial surface** (*facies medialis*) – faces the pelvic viscera
2 **Lateral surface** (*facies lateralis*) – lies on the lateral wall of the lesser pelvis
3 **Mesovarian border** (*margo mesovaricus*)
– the anterior margin facing the peritoneal fold of the ovary
3.1 **Hilum of ovary** (*hilum ovarii*) – a slit through which the ovarian vessels and nerves enter the ovarian parenchyma
4 **Free border** (*margo liber*) – the posterior free margin
5 **Tubal extremity** (*extremitas tubaria*)
– the upper pole facing the abdominal opening of the uterine tube
6 **Uterine extremity** (*extremitas uterina*) – the lower pole facing the uterine horn

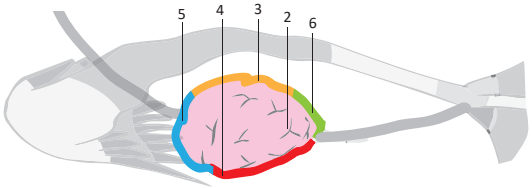

Anterior view of the right ovary

Peritoneal folds and their corresponding arterial supply

1 **Mesovarium** – a peritoneal fold of the ovary
– attaches to the posterior aspect of the broad ligament of the uterus
2 **Suspensory ligament of ovary** (*ligamentum suspensorium ovarii*)
– attaches the tubal extremity of the ovary to the lateral pelvic wall
– contains the ovarian artery and veins, ovarian nervous plexus and lymphatic vessels
3 **Ligament of ovary** (*ligamentum ovarii proprium*)
– attaches the uterine extremity of the ovary to the uterine horns
– contains the ovarian branch of the uterine artery and its corresponding veins and lymphatic vessels
4 **Ovarian arcade** – an anastomosis of the ovarian branch of the uterine artery with the ovarian artery

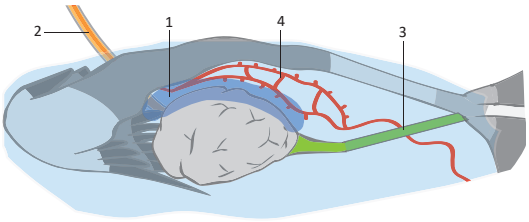

Internal structure

Surface – simple cuboidal epithelium
Tunica albuginea (*tunica albuginea ovarii*) – a thick layer of connective tissue under the epithelium
Ovarian stroma (*stroma ovarii*) – the connective tissue of the ovarian parenchyma
– forms the ovarian cortex and medulla
Ovarian cortex (*cortex ovarii*) – the functional tissue of the ovary
– contains the follicles in their various stages of maturation
Ovarian medulla (*medulla ovarii*) – contains the ovarian nerves and vessels and connective tissue

Vascular supply

Arterial supply: ovarian artery and ovarian branch of the uterine artery
Venous drainage: left ovarian vein (to left renal vein) and right ovarian vein (to inferior vena cava)
Lymphatic drainage: lumbar nodes

Innervation

Sympathetic system: ovarian, renal and aortic plexuses
Parasympathetic system: ovarian plexus (from the vagus nerve with accesory fibres from the superior and inferior hypogastric plexuses)
Viscerosensory system: sensory fibres travel in the sympathetic and parasymathetic plexuses

Oophoron is the Greek term for ovary.
Salpinx is the Greek term for uterine tube.

Ligamentum uteroovaricum and chorda uteroovarica are obsolete terms for the ligament of the ovary.

Ligamentum infundibulopelvicum is an obsolete term for the suspensory ligament of the ovary.

The adnexa of the uterus is a collective term for the ovary, uterine tube and their peritoneal folds.

Clinical notes

Oophorectomy is the surgical removal of the ovary. Salpingectomy is the surgical removal of the uterine tube.
Salpingo-oophorectomy / adnexectomy is the surgical removal of both the ovary and the uterine tube.

Adnexitis / pelvic inflammatory disease is inflammation of both the uterine tube and ovary. It may be caused by spread of infection from the appendix.

Salpingitis is inflammation of the uterine tube. It can spread to the peritoneum via the abdominal ostium and thus cause peritonitis.

An ovarian cyst is a collection of fluid covered by a thin membrane located in the ovary. In majority of cases, they are of no clinical significance. However, sometimes they can lead to infertility. In diagnostic ultrasound, small cysts less than 40mm may cause diagnostic confusion due to their resemblance of normal follicles.

Tubal obstruction may result from recurrent inflammation of the uterine tube mucosa and consequent scarring, causing adhesions and subsequent loss of tubal patency. This is a common cause of female infertility and ectopic pregnancy.

Ectopic pregnancy *(graviditas extrauterina / GEU)* occurs when a zygote (a fertilised ovum) implants in a different location than its normal implantation site within the uterus. This occurs most commonly within the uterine tube. However, other locations, such as the cervical canal, ovary or peritoneal cavity are possible. In the majority of cases the embryo does not survive. Howver sometimes its development may continue and rupture the uterine tube causing life threatening bleeding and sepsis.

The uterine tube (Fallopian tube) is a paired muscular tube uniting the uterine horn with the ovary. Its abdominal ostium is **freely open to the peritoneal cavity,** where it **captures released oocytes**, which are transported along the tube by peristaltic contractions to the uterine cavity. **Fertilisations of an oocyte by a spermatozoon** usually happens within the uterine tube.

External strucure

- 1 **Abdominal ostium** (*ostium abdominale*) – faces the ovary
  - directly communicates with the peritoneal cavity
  - the inlet of the uterine tube
- 2 **Infundibulum** (*infundibulum tubae uterinae*) – a dilated part adjacent to the abdominal ostium
  - contains the fimbriae
    - 2.1 **Fimbriae** (*fimbriae tubae uterinae*) – mucosal appendages projecting from the abdominal ostium
    - 2.2 **Ovarian fimbria** (*fimbria ovarica*) – the most distinct and longest fimbria, reaches the ovary
- 3 **Ampulla** (*ampulla tubae uterinae*) – the wider lateral 2/3 of the uterine tube, decorated by many mucosal folds
- 4 **Isthmus** (*isthmus tubae uterinae*) – the narrower medial 1/3 of the uterine tube, contains scant mucosal folds
- 5 **Uterine part** (*pars uterina*) – the intramural segment of the uterine tube, located inside the wall of the uterus
- 6 **Uterine ostium** (*ostium uterinum*) – is located within the uterine horn
- 7 **Mesosalpinx** (*mesosalpinx*) – the peritoneal fold of the uterine tube
  - 7.1 the cranial part of the broad ligament of the uterus
  - 7.2 contains an arterial anastomosis between the ovarian artery and the ovarian branch of the uterine artery (called the ovarian arcade) and its branches

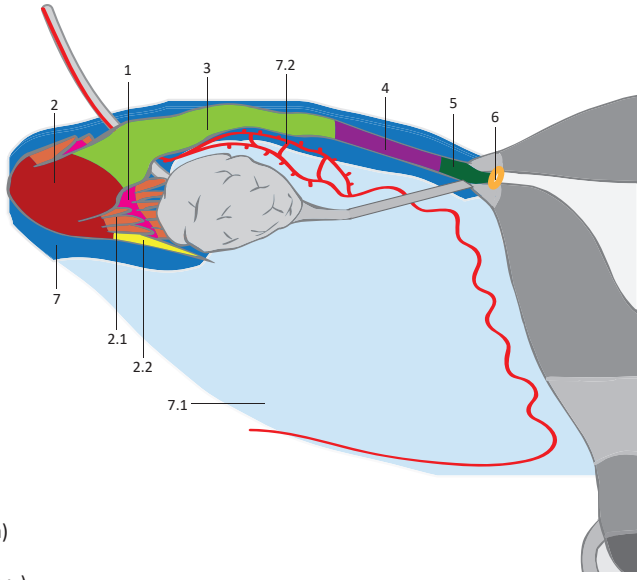

Internal structure

Mucosa (*tunica mucosa*)
– simple columnar ciliated epithelium
– is organised in multiple folds, which decrease in number and thickness from the ampulla to the isthmus
– the epithelium contains ciliated cells, peg cells and basal cells
– the mucosal folds form the "mucosal labyrinth", which is formed by primary, secondary and tertiary folds
Muscular layer (*tunica muscularis*)
– smooth muscle tissue organised into an external longitudinal layer and an internal circular layer
Serosa (*tunica serosa*)
– the external surface covered by peritoneum

Vascular supply

Arterial supply:
– **the lateral 1/3 of the uterine tube:** the tubal branch of the ovarian artery (from the abdominal aorta)
– **the medial 2/3 of the uterine tube:** the tubal branch of the uterine artery (from the internal iliac artery)
Venous drainage:
– theleft ovarian artery (to the left renal vein)
– the right ovarian artery (to the inferior vena cava)
– the uterine venous plexus (to the uterine vein, internal iliac vein)
Lymphatic drainage:
– the major part of the uterine tube: the lumbar nodes
– the isthmus: the superficial inguinal nodes

Innervation

Sympathetic system: the ovarian plexus (from the renal and aortic plexus)
Parasympathetic system:
– the lateral 1/3 of the uterine tube from the ovarian plexus (from vagus nerve)
– the medial 2/3 of the uterine tube from the inferior hypogastric plexus (from the sacral splanchnic nerves)
Viscerosensory system: sensory nerve fibres in the sympathetic and parasympathetics plexuses

This copy belongs to ali yaghoubi

The uterus is a **pear-shaped organ** located in the lesser pelvis between the urinary bladder and rectum. Its mucosa undergoes cyclic transformation, synchronised with the ovarian cycle. This ensures that the uterus is ready for implantation and the subsequent development of the fertilised ovum. It is positioned in **anteversion and anteflexion** and is almost completely covered by peritoneum. Due to its position, spermatozoa can easily reach the uterine cavity and it provides sufficient space for a growing embryo/foetus.

External structure

- 1 **Body of uterus** (*corpus uteri*) – the middle and largest part of the uterus
  - 1.1 **Fundus of uterus** (*fundus uteri*) – the ventro-cranial part of the body of the uterus
  - 1.2 **Uterine horn** (*cornu uteri*) – a paired structure through which the uterine tubes enter the uterus
  - 1.3 **Border of uterus** (*margo uteri*) – the attachment of the broad ligament of the uterus – the uterine artery ascends to the uterine horns from the isthmus of uterus
  - 1.4 **Uterine cavity** (*cavitas uteri*) – houses the developing embryo and foetus
- 2 **Isthmus of uterus** (*isthmus uteri*) – the narrow transitional area between the body and cervix
  - 2.1 **Canalis isthmi** – the cavity of the isthmus, its upper border forms the internal os
  - 2.2 **Anatomical os** (*ostium anatomicum uteri internum*) – the internal os

3 **Cervix of uterus** (*cervix uteri*)
- 3.1 **Supravaginal part** (*portio supravaginalis cervicis*)
  – the cranial part of the cervix above the attachment of the vagina
  – contains mucosal folds called the palmate folds (*plicae palmatae*)
- 3.2 **Vaginal part** (*portio vaginalis cervicis*)
  – the caudal part of the cervix protruding into the vagina
- 3.3 **Cervical canal** (*canalis cervicis*)
  – the continuation of the uterine cavity inside the cervix
- 3.4 **External os of uterus** (*ostium uteri*)
  – the opening of the cervical canal to the vagina

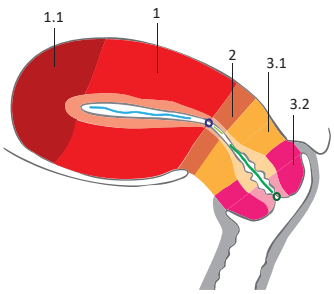

Sagittal section of the uterus and cranial part of the vagina

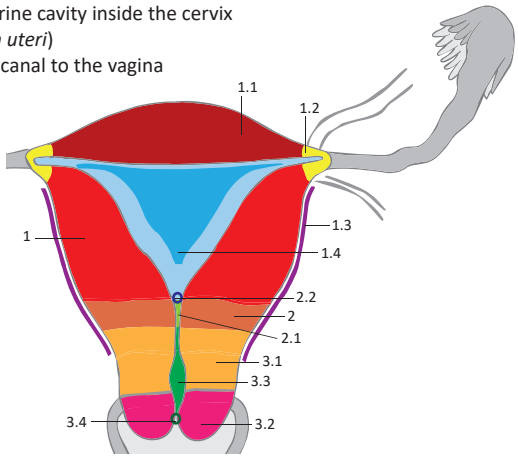

Frontal section of the uterus with the left uterine tube

Internal structure

1 **Endometrium** – the uterine mucosa, consists of simple columnar epithelium, connective tissue and simple tubular glands, contains more goblet cells than ciliated cells
- 1.1 **Basal layer** (*stratum basale*) – the deepest layer of the endometrium
  – doesnt change during the menstrual cycle,
  – contains the basal parts of the endometrial glands
- 1.2 **Functional layer** (*stratum functionale*) – the widest layer
  – undergoes cyclic changes
  – is composed mainly of uterine glands

1.3 **Compact/superficial layer** (*stratum compactum/superficiale*)
- the most superficial layer
- contains the duct of the uterine glands

- 2 **Myometrium** – smooth muscle of the uterus arranged in four layers
- 3 **Perimetrium** – a serous coat of the uterus, continuous with the peritoneum of the broad ligament of the uterus
- 4 **Parametrium**
  – loose connective tissue surrounding the caudal part of the uterus
  – extends between two layers of the broad ligament of the uterus and
  – below the broad ligament condenses to form the parametrial ligaments

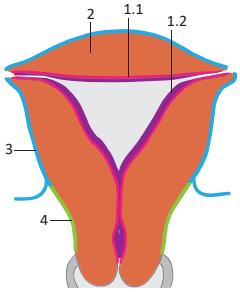

Frontal section of the uterus

Metra and hystera are Greek terms for uterus.

The round ligament of the uterus extends from the uterine horn laterally towards the pelvic wall. It passes ventrally through the inguinal canal and inserts into the fibrous tissue of the labia majora. The ligament contains a few fascicles of smooth muscle and some vessels.

Menstruation is the phase of uterine bleeding that occurs at the end of the menstrual cycle. After menstruation, the uterine mucosa regenerates during the proliferative phase while an oocyte matures in the ovary. After the proliferative phase, the oocyte is released from a Graafian follicle into the uterine tube. This is followed by the secretory phase, which prepares the mucosa for implantation of a fertilized ovum. If fertilisation doesn't occur, menstruation occurs and the cycle repeats.

Clinical notes

Metrorrhagia is uterine bleeding that differs in timing or intensity to normal menstrual bleeding.
Metralgia is the Latin term for "pain of the uterus".

Hysterectomy is the surgical removal of the uterus.

The epithelium of the cervix changes during puberty. The epithelium becomes more vulnerable to infection with HPV (human papilloma virus) during this transformation. Infection with HPV can cause cervical carcinoma.

The vesicouterine fold *(plica vesicouterina)* is located at the bottom of the vesicouterine pouch. It is an important structure for surgeries such as hysterectomies and caesarean sections. An incision has to made in the fold to release and descend the urinary bladder preventing possible surgical injury.

A myoma / leiomyoma is a benign tumor of the myometrium. It is the most common tumour of the body of the uterus. Its symptoms include long heavy bleeding that occurs independently from menstrual bleeding.

Uterine surfaces and position

Surfaces

- 1 **Intestinal surface** (*facies intestinalis*) – the dorso-cranial surface facing the intestinal loops
- 2 **Vesical surface** (*facies vesicalis*) – the ventro-caudal surface facing the urinary bladder

Position

- 3 **Anteflexion** – the longitudinal axis of the body of the uterus and the longitudinal cervical axis form an obtuse angle of 160°–170° open ventrally with the vertex at the isthmus of the uterus
- 4 **Anteversion** – the longitudinal axis of the body of the uterus and the longitudinal axis of the vagina form an angle of 70°–100° open ventrally with the vertex at the external os of the uterus
- 5 **Dextroversion** – the uterus is often slightly turned to the right with its left border lying closer to the midline and pushed forward

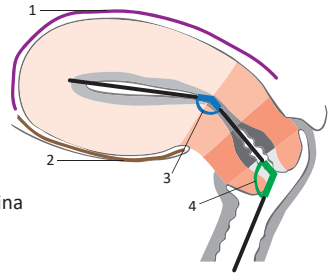

Sagittal section of the uterus and cranial part of vagina

Supporting apparatus of the uterus

The supporting apparatus of the uterus consists of the muscles of the pelvic floor. These are more important than the parametral ligaments.

1 **Levator ani/pubovaginalis**
2 **Ischiococcygeus**
3 **Perineal muscles**

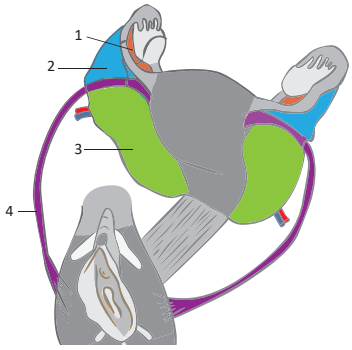

Female genitalia, oblique view

Peritoneal folds

Broad ligament of uterus (*ligamentum latum uteri*) – is a double peritoneal fold located in the frontal plane of the lesser pelvis, consists of the three parts
– it is attached to the uterine border medially and is laterally continuous with the parietal peritoneum of the pelvic wall

- 1 **Mesovarium** (dorsally) – a peritoneal fold of the ovary
- 2 **Mesosalpinx** (cranially) – a peritoneal fold of the uterine tube
- 3 **Mesometrium** (caudally) – a peritoneal fold of the uterus

Parametrial ligaments

The parametrial ligaments hold the uterus in its proper position in the pelvis.

- 4 **Round ligament of uterus** (*ligamentum teres uteri*) – keeps the uterus in anteversion during pregnancy
- 5 **Cardinal ligament / Mackenrodt's ligament / transverse cervical ligament** (*ligamentum cardinale Mackenrodti / ligamentum transversum cervicis*) – a paired fibrous band extending laterally from the cervix and isthmus to the pelvic wall – enables antero-posterior movements of the uterus
- 6 **Pubocervical ligament** (*ligamentum pubocervicale*) – extends from the pubic symphysis to the cervix
- 7 **Vesico-uterine ligament** (*ligamentum vesicouterinum*)– extends from the uterus to the urinary bladder
  - 7.1 **Pubovesical ligament** (*ligamentum pubovesicale*) – the continuation of the vesicouterine ligament to the pubis
- 8 **Recto-uterine ligament** (*ligamentum rectouterinum*) – extends from the rectum to the uterus
- 9 **Uterosacral ligaments** (*ligamenta sacrouterina*) – the continuation of the recto-uterine ligament to the sacrum, contain the inferior hypogastric plexus

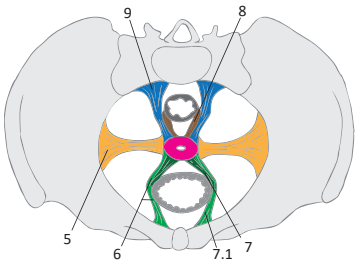

Parametral ligaments inside the pelvis

Blood supply

Arterial supply: the internal iliac artery

- 1 **Uterine artery** – approaches the isthmus from the side and ascends tortuously along the uterine border

Venous drainage: the uterine venous plexus (into the uterine vein and internal iliac vein)

Lymphatic drainage:

- 2 **Body of uterus:** the internal iliac nodes
- 3 **Fundus of uterus:** the lumbar nodes
- 4 **Border of uterus:** the superficial inguinal nodes along the round ligament of the uterus
- 5 **Ventral aspect of cervix:** the internal iliac nodes
- 6 **Dorsal aspect of cervix:** the sacral nodes

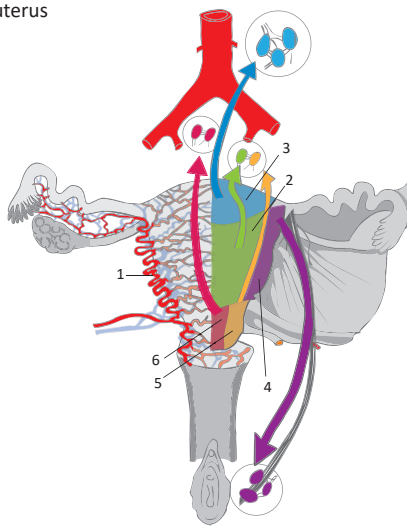

Blood supply of the female genitalia

Innervation

Sympathetic system: the uterovaginal plexus from the inferior hypogastric plexus
Parasympathetic system: the uterovaginal plexus from the inferior hypogastric plexus
Viscerosensory system: nerve fibers in both plexuses

This copy belongs to ali yaghoubi

The vagina is a **hollow muscular tube** that serves as the **terminal part of the female genital tract**. It facilitates **copulation and partuition**.

External structure

- 1 **Vaginal orifice** (*ostium vaginae*) – the external opening of the vagina in the vestibule
- 2 **Vestibule** (*vestibulum vaginae*) – a space borderd by the labia minora
- 3 **Vaginal canal** (*canalis vaginalis*) – the cavity of the vagina
  - 3.1 **Anterior wall** (*paries anterior*)
    - 3.1.1 **Pawlik's triangle** (*area trigonalis vaginae*) – an area on the anterior wall absent in rugae under the overlying trigone of the bladder
  - 3.2 **Paries posterior** (*paries posterior*)
  - 3.3 **Vaginal rugae** (*rugae vaginales*) – transverse mucosal folds on the vaginal walls – disappear during labour
    - 3.3.1 **Anterior and posterior vaginal columns** (*columna rugarum anterior et posterior*) – longitudinal elevations on the anterior and posterior walls of the vagina
- 4 **Vaginal fornix** (*fornix vaginae*) – encloses the vaginal part of the cervix uteri
  - 4.1 **Anterior part** (*pars anterior*) – the shallow anterior part of the fornix
  - 4.2 **Posterior part** (*pars posterior*) – the deeper posterior part of the fornix
  - 4.3 **Lateral parts** (*partes laterales*) – lateral parts of the fornix

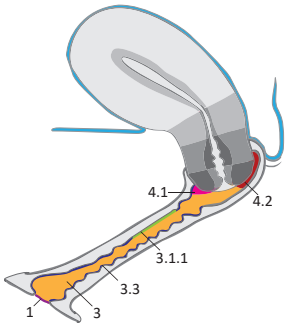

Sagittal section of the vagina

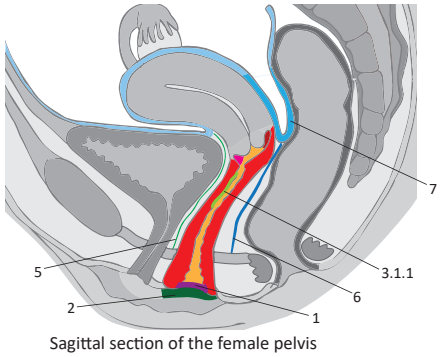

Sagittal section of the female pelvis

Regional anatomy

- 5 **Urethrovaginal septum** (*septum urethrovaginale*) – a plate of connective tissue between the urethra and vagina
- 6 **Rectovaginal septum** (*septum rectovaginale*) – a plate of connective tissue between the vagina and rectum – the cranial extention of the perineal body (*corpus perineale*)
- 7 **Recto-uterine pouch / pouch of Douglas** (*excavatio rectouterina Douglasi*) – the most caudal recess of the peritoneal cavity in females, extends to the posterior fornix

Vascular supply

Arterial supply:
– the vaginal artery, which arises either directly from the internal iliac or from the uterine artery
– vaginal branches from the uterine artery, middle rectal artery and internal pudendal artery

Venous drainage: the internal iliac vein via the uterine venous plexus (into the uterine and vaginal veins), middle rectal and internal pudendal veins

Lymphatic drainage: internal and external iliac nodes, sacral nodes
– caudally below the hymen: the superficial inguinal nodes

Innervation

Sympathetic system: the vaginal nerves, the uterovaginal plexus from the inferior hypogastric plexus

Parasympathetic system: the vaginal nerves, the uterovaginal plexus from the sacral splanchnic nerves (S2–S4)

Viscerosensory and somatosensory system: the vaginal nerves
– caudally below the hymen: the pudendal nerve and its branches, inferior rectal nerves, perineal nerves, posterior labial nerves

Kolpos is the Greek term for vagina. **Introitus** is an obsolete term for the vaginal orifice.

The hymen is a mucous membrane separating the vestibule from the cavity of the vagina.

Mons pubis / mons Venus is a fat pad located above the pubic symphysis. It is covered with pubic hair, which grows under the influence of the female sex hormones.

The urethral carina of the vagina *(carina urethralis vaginae)* is a ridge on the anterior wall of the vagina formed by the underlying urethra.

The fascia of the clitoris *(fascia clitoridis)* covers the clitoris and attaches it to the anterior surface of the pubic symphysis.

The pubovaginalis (part of the levator ani) circles the vagina at the urogenital hiatus and creates the promontorium vaginae of Thomas.

Receptaculum seminis is an obsolete term for the posterior part of the vaginal fornix that serves to collect semen after coitus.

Clinical notes

Colpitis is inflammation of the vagina.

The recto-uterine pouch/pouch of Douglas is a clinically important place for palpation and evacuation of fluid that has accumulated inside the peritoneal cavity.

Colposcopy is an endoscopic examination of the cervix through the vagina.

Culdoscopy is an endoscopic examination of the recto-uterine pouch. The endoscope is inserted through the posterior fornix of the vagina.

Vaginal (exfoliative) cytology is a repeated cytological examination of the vaginal epithelium over the course of the menstrual cycle.

A recto-vaginal fistula is a pathological communication between the vagina and rectum that carries a very high risk of infection.

Local anesthetics can be applied in the area of the pudendal nerve during or shortly before labour.

The greater vestibular gland/Bartholin's gland can be a site of a painful abscess.

The **vulva** is a term for the female external genitalia. It includes the **labia majora, labia minora, clitoris, erectile bodies and the vestibule** (with it's associated glands). The vestibule is an area bordered by the labia minora. The labia majora are covered with skin and pubic hair. The round ligament of the uterus inserts into the fat tissue of the labia majora. The labia minora do not contain fat tissue and are lined with mucosa on their medial surfaces. They divide ventrally into two folds, forming the prepuce and frenulum of the clitoris. The clitoris is an erectile organ connected to the two erectile bodies of the bulb of the vestibule.

External structure

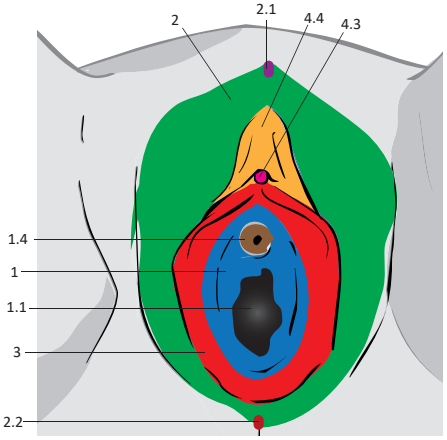

- 1 **Vestibule** (*vestibulum vaginae*)
  - 1.1 **Vaginal orifice** (*ostium vaginae*) – the external opening of the vagina
  - 1.2 **Greater vestibular gland / Bartholin's gland** (*glandula vestibularis major Bartholini*)
    – a paired mucous gland embedded in the perineal membrane
    – opens into the posterior part of the vestibule
  - 1.3 **Lesser vestibular glands** (*glandulae vestibulares minores*)
  - 1.4 **External urethral orifice** (*ostium urethrae externum*)
    – the external opening of the female urethra
- 2 **Labia majora** (*labia majora pudendi*)
  - 2.1 **Anterior commissure** (*commissura labiorum anterior*)
    – the anterior connection of the two labia majora
    – is located ventral to the prepuce of the clitoris
  - 2.2 **Posterior commissure** (*commissura labiorum posterior*)
    – the posterior connection of the two labia majora, behind the vestibule
- 3 **Labia minora** (*labia minora pudendi*)

4 **Clitoris** – the female erectile organ
- 4.1 **Crura of clitoris** (*crura clitoridis*)
  – paired bodies of erectile tissue attached to the phallic crest of the inferior pubic ramus
  – meet in the midline at the body of the clitoris
- 4.2 **Body of clitoris** (*corpus clitoridis*) – is formed by fusion of the crura of the clitoris
- 4.3 **Glans of clitoris** (*glans clitoridis*) – the terminal part of the clitoris
- 4.4 **Prepuce of clitoris** (*preputium clitoridis*) – is located on the ventral aspect of the clitoris
- 4.5 **Frenulum of clitoris** (*frenulum clitoridis*)

- 5 **Bulb of vestibule** (*bulbus vestibuli*) – a pair of erectile bodies encircling the vestibule
  – ventrally connected at the commissure of the bulbs (*commissura bulborum*)

Vascular supply

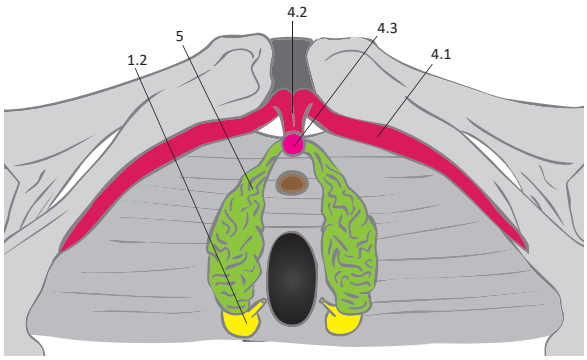

Arterial supply:
– the anterior labial branches (from external pudendal artery, which is from the femoral artery)
– the posterior labial branches (from internal pudendal artery, which is from the from internal iliac artery)
– the deep artery of clitoris, dorsal artery of clitoris and artery of bulb of vestibule (from are from the internal pudendal artery, which is from the internal iliac artery)

Venous drainage:
– the superficial dorsal vein of the clitoris and anterior labial veins (drain into the external pudendal veins, which drain into the common femoral vein)
– the deep dorsal vein of the clitoris (drains into the pudendal and vesical venous plexuses, which drain into the internal iliac vein)
– the posterior labial veins and vein of the bulb of the vestibule (drain into the internal pudendal vein, which drains into the internal iliac vein)

Lymphatic drainage:
– superficial inguinal nodes (bilaterally)
– deep inguinal nodes

Innervation

Somatosensory innervation of the labia: the ilioinguinal nerve and the genitofemoral nerve (from the lumbar plexus)
Somatosensory innervation of the labia, clitoris and perineum: the pudendal nerve (from the sacral plexus)
Somatosensory innervation of the perineum: the posterior cutaneous nerve of thigh (from the sacral plexus)
Visceromotor system of the clitoris: the cavernous nerves of the clitoris (from the inferior hypogastric plexus)

This copy belongs to ali yaghoubi

The perineum is the **region between the external genitalia and the anus**. The striated perineal muscles are arranged in two layers. They form the triangular fibromuscular **urogenital floor** (*diaphragma urogenitale*) spread between the ischial tuberosities and the inferior pubic rami. The urogenital floor contains a hiatus for the terminal segment of the urogenital tract. The perineal muscles **act as sphincters and contribute to erection and ejaculation**. They are **innervated by the pudendal nerve** (from spinal cord segments S2–S4).

Perineum

1 **In males:** the region between the posterior aspect of the scrotum and the anal canal

2 **In females:** the region between the posterior commissure of the labia and the anal canal

3 **Perineal raphe** (*raphe perinei*)
– a skin ridge along the midline of the perineum

Pelvic outlet (*apertura pelvis inferior*)

4 **Urogenital triangle** (*trigonum urogenitale*)
– the anterior triangle between the ischial tuberosities and pubic symphysis
– contains the pelvic floor and perineal muscles

5 **Anal triangle** (*trigonum anale*)
– the posterior triangle between the ischial tuberosities and coccyx
– the perineal muscles are missing here and the pelvic outlet is closed by the pelvic floor muscles

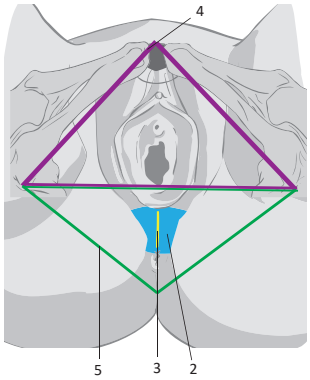

Urogenital floor in male

1 **Perineal membrane** (*membrana perinei*)
– a fibrous sheet covering the inferior aspect of the deep transverse perineal muscle

2 **Deep transverse perineal muscle** (*musculus transversus perinei profundus*)
– the deep muscular part of the urogenital floor

3 **Superficial transverse perineal muscle** (*musculus transversus perinei superficialis*)
– forms the posterior border of the urogenital floor

Muscles located superficial to the perineal membrane

4 **Ischiocavernosus** (*musculus ischiocavernosus*)
– compresses the crus of the penis, contributing to erection

5 **Bulbospongiosus** (*musculus bulbospongiosus*)
– evacuates the urethra during micturition and ejaculation

Muscles located deep to the perineal membrane

6 **External urethral sphincter** (*musculus sphincter urethrae externus*)

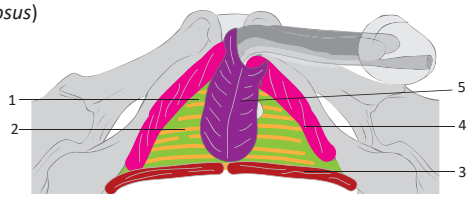

Inferior view of the urogenital triangle in male

Urogenital floor in female

1 **Perineal membrane** – a fibrous sheet containing disperse muscle fibers

2 **Superficial transverse perineal muscle** (*musculus transversus perinei superficialis*)
– adjacent to the posterior edge of urogenital floor, weak or often absent

Muscles located superficial to the perineal membrane

3 **Ischiocavernosus** – compresses the crus of the clitoris

4 **Bulbospongiosus** – compresses the vestibule, evacuating the vestibular glands

Muscles located deep to the perineal membrane

5 **External urethral sphincter**

6 **Compressor urethrae** (*musculus compressor urethrae*)
– compresses and extends the urethra

7 **Sphincter urethrovaginalis** (*musculus sphincter urethrovaginalis*)
– compresses and extends the urethra

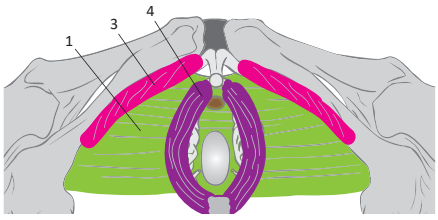

Inferior view of the urogenital triangle in female

The perineal body *(corpus perineale)* (formerly known as *centrum tendineum perinei*) is a pyramidal fibromuscular structure located in the midline of the perineum between the urogenital and anal triangles. Cranially, the rectoprostatic septum / rectovaginal septum *(septum rectoprostaticum/rectovaginale)* continues from the perineal body. It is the central insertion of the perineal and pelvic floor muscles.

The urogenital floor *(diaphragma urogenitale)* is an obsolete term for the fibromuscular plate formed by the perineal membrane, transverse perinei muscles, ischiocavernosus and bulbospongiosus. In modern anatomy, this term is no longer used, however, it is frequently applied in clinical terminology, which is why we mention it in this text.

The bulbo-clitoridal organ is a clinical term for the continuous erectile tissue of cavernous bodies of clitoris, of bulb of vestibule including its commissure and of the intermediate part between these two.

The pelvic floor and its muscles page 131.
Lesser pelvis topography page 564.

Clinical notes

Episiotomy is a surgical incision of the perineum during labour to prevent uncontrolled injury of the vagina, perineum and the baby. Midline episiotomy crosses the perineal body, medio-lateral episiotomy (30° from the midline) cuts through the bulbospongiosus and the superficial transverse perineal muscle. Left medio-lateral episiotomy is easily sutured, heals faster and therefore is performed more often.

Cervical shortening, diagnosed by transvaginal ultrasound, is a sign of progressing labour. Obstetricians use it in women at risk of preterm labor. The cervix is of a rather conical shape in primigravida (a woman pregnant for the first time) and of a cylindrical shape in multigravida.

Pre-eclampsia is a clinical condition associated with maternal hypertension, proteinuria (presence of protein in urine) and oedema. This occurs most commonly due to histological changes in the uterine spiral arteries causing them to have higher blood pressure. Eventually, convulsions (eclampsia) may develop.

Pregnancy *(graviditas)* is the period of time from fertilisation to the extraction of the foetus/embryo from the uterus. Pregnancy terminates by either delivery or abortion. Giving birth to a child is defined as a **delivery** *(partus)*. **Delivery of a live-born child** is defined if the neonate breathes and/or shows at least one vital sign. It is independent on the duration of pregnancy. **A stillborn child** is a foetus expelled or taken out of the uterus weighing over 500 grams and showing no signs of life. **A miscarriage** *(abortus)* is defined as the spontaneous expulsion of a foetus/embryo weighing less than 500 grams and showing no vital signs. An induced abortion is performed in accordance with local legislation.

Organ changes in pregnancy

1 **Uterus**
- the total weight of the uterus increases during pregnancy from 70 g to 1100 g (at term), due to increased blood flow (from 50 ml to 500–700 ml) and increased vasculature and fluid retention in the myometrium
- the total uterine volume increases from 10 ml to 5 litres (a 500 fold increase)

1.1 **Cervix**
- the dense fibro-muscular cervix acts as a firm plug for the uterus during pregnancy
- the cervix softens during labour; its collagen fibres break down and it retains fluid
- the cervix enables smooth passage of the foetus through the birth canal

1.2 **Isthmus**

1st trimester: the length of the ishthmus increases three-times and moves towards the body of the uterus
- the isthmus contributes to the formation of the lower uterine segment

2nd trimester: the isthmus and body of the uterus become continuous
- the isthmus transforms into the lower uterine segment

1.3 **Fundus** – is palpable from the 12th week onwards

12th week – palpable over the pubic symphysis

20th week – palpable at the level of the umbillicus

36th week – palpable under the xiphoid process

2 **Vagina**
- increased blood flow and fluid retention lead to enlargement and elongation of the vagina

3 **External genitalia**
- blood flow of the external genitalia increases
- pigmentation becomes more apparent
- submucosal veins dilate, sometimes forming varicosities
- the labia minora and the area around the external urethral orifice change color from pink to blue-like (livid); this is called Labhardt's sign

4 **Round ligament of uterus and broad ligament of uterus**
- both enlarge
- the broad ligament of the uterus enlarges due to an increase in number of the ovarian and uterine vessels and serves as a blood reservoir

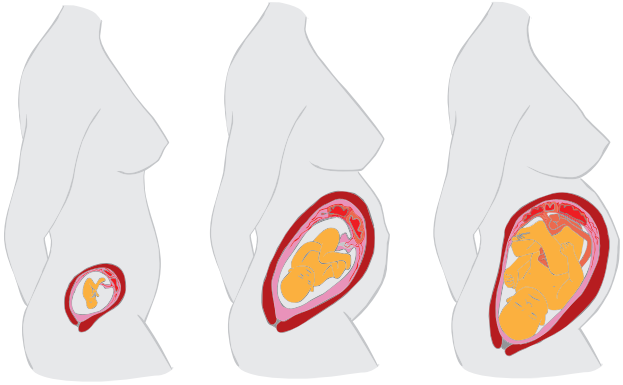

1st trimester 2nd trimester 3rd trimester

5 **Abdominal wall**
- pigmented spots appear on the skin (*striae gravidarum*)
- particularily in multiparous women, the rectus abdominis muscles may separate (diastasis), forming a slit through which the fundus may slip

6 **Abdominal aorta and inferior vena cava**
- in the supine position, the great vessels may be compressed by the growing uterus in the later stages of pregnancy
- compression of the more compliant inferior vena cava may result in the inferior vena cava syndrome
- inferior vena cava syndromes presents with hypotension (due to decreased venous return), nausea, fainting and foetal bradycardia on CTG (cardiotocogram)
- pregnant women are therefore positioned on their left side

7 **Vertebral column** – the cervical lordosis and the thoracic kyphosis equalise and the lumbar lordosis enhances

8 **Joints** – the hormone relaxin causes joints to loosen, particularly the sacro-iliac and sacrococcygeal joints and the pubic symphysis

Regional anatomy in pregnancy

– due to uterine enlargement, the abdominal organs are shifted to areas of minimal resistance

Cranially: jejunum, transverse colon

Cranio-laterally: ovary, uterine tubes

Vertical course: round ligament of uterus

Dorsally and to the right: the caecum, appendix

Laterally: ureter

This copy belongs to ali yaghoubi

The foetal membranes protect the developing human from external factors and **form a stable environment** inside the uterine cavity. **The placenta** provides a **connection between the mother and the developing embryo/foetus**. There are two main components of the placenta: the transformed uterine mucosa (*pars materna placentae*) and the extra-embryonic tissues and membranes of the developing embryo/fetus (*pars fetalis placentae*). **The umbilical cord** is an unpaired mobile connection between the foetus and the placenta.

Fetal membranes (*membranae fetales*)

1 **Chorion**
– originates from extra-embryonic mesodermal cells, is covered by trophoblasts
– differentiates into two functionally and morphologically distinct components:
1.1 **Chorion frondosum / villous chorion**
– is located at the insertion site of the placenta
– adjacent to the decidua basalis of the uterine mucosa
– is composed of chorionic villi that anchor the foetal part of the placenta into the uterine mucosa, the so called anchoring villi *(villi ancorantes)*
– the chorionic villi are rinsed with maternal blood providing exchange of oxygen, nutrients and waste products between the foetal and maternal circulation
1.2 **Chorion laeve / smooth chorion**
– a smooth larger part of the chorion lining the chorionic cavity underneath the amnion at the extra-placental sites
– adjacent to the parietal decidua (*decidua parietalis*) of the uterine mucosa of pregnancy
2 **Amnion**
– a single layer of cells differentiated from embryoblast
– the original amniotic cavity (*cavitas amniotica*) emerges as a slit in embryoblast, enlarges and eventually encloses the entire embryo (foetus), which swims inside this cavity filled with amniotic fluid

Placenta

1 **Maternal part of the placenta** (*pars materna placentae*)
– transformed stromal cells of the functional layer of the endometrium (decidual transformation); after fertilisation, under the influence of progesterone, they enlarge and fill with glycogen and lipids
– is separated into 15–20 lobules (cotyledons) by the placental septa growing from the basal (maternal) plate
1.1 **Basal decidua** (*decidua basalis*) – part of the decidual mucosa between the embryo and uterine wall
2 **Foetal part of the placenta** (*pars fetalis placentae*)
– forms the primary, secondary and tertiary villi
2.1 **Amnion**
2.2 **Fetal mesenchyme with branches of umbilical vessels**
2.3 **Cytotrophoblast and syncytiotrophoblast**
3 **Placental layers** (faces the uterine wall)
3.1 **Amnion**
3.2 **Foetal mesenchyme and umbilical vessels**
3.3 **Cytotrophoblast**
3.4 **Syncytiotrophoblast**
3.5 **Intervillous space** (*spatium intervillosum*)
3.6 **Basalis decidua**
3.6.1 **Spiral arteries**

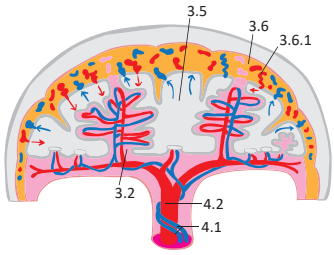

Cross-section of the placenta

Umbilical cord (*funiculus umbilicalis*) contents

4.1 **Umbilical arteries** (*arteriae umbilicales*) – two arteries
4.2 **Umbilical vein** (*vena umbilicalis impar*) – a single vein
4.3 **Wharton's jelly** (*textus mucoideus connectivus, mucoid connective tissue*)
4.4 **Remnants of allantois and omphaloenteric ducts** (*ductus omphaloentericus*)
4.5 **Amnion** – on the outer surface

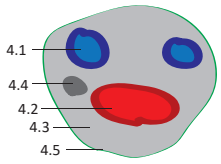

Cross-section of the umbilical cord

According to the position of the embryo/foetus, we distinguish three parts of the uterine mucosa. The basal decidua is located right under the embryo on the future site of the placenta. The capsular decidua *(decidua capsularis)* surrounds the embryo. The rest of the uterine mucosa is the parietal decidua.

Vascular supply of the placenta: Maternal blood from the spiral arteries fills the intervillous space and rinses the blood from the umbilical arteries in the chorionic villi. Functionally, the placenta is divided into small lobules (cotyledons) separated from each other by placental septa. A single terminal branch of the uterine artery supplies each cotyledon. The chorionic villi capillaries are in indirect contact through the wall of the villi with the maternal blood in the intervillous spaces. The umbilical vein drains foetal blood from the chorionic villi capillaries into the inferior vena cava of the foetus.

The gestational age of a child is calculated from the first day of the mother's last menstrual period (40 weeks at term). The fertilisation age is calculated from the day of fertilisation (38 weeks at term).

Embryology page 5.

Clinical notes

Caesarean section / C-section *(sectio caesarea, S.C.)* is the surgical removal of a baby through the abdominal wall and uterus. It varies according the surgical incision:
– lower uterine segment section
– cervico-corporal section in the body of the uterus and the lower uterine segment
– corporal section in the body of the uterus

Corporal section carries the highest risk of uterine rupture. Any following pregnancy must be terminated by C-section.

Placenta praevia a placenta located directly over the anatomical (internal) os of the uterus. Delivery must be performed by C-section as the placenta obstructs the birth canal.

Placenta accreta is a placenta growing to margin of the myometrium.

Placenta increta is a placenta invading the myometrium.

Placenta percreta is a placenta invading the entire layer of the myometrium or all three layers of the uterine wall.

Pregnancy (graviditas) is the **period of time from fertilisation to the end of labour**. Pregnancy lasts for 40 weeks. **Intrauterine** life of an individual is **divided into three periods** called trimesters. During labour, contractions of the uterine muscle and of the muscles of the abdominal wall lead to the expulsion of the fetus through the birth canal to the external world.

Clinically important anatomical markers of the foetus

- 1 **CRL:** crown-rump length
- 2 **GL:** global length
- 3 **NT:** nuchal translucency
- 4 **IT:** intracranial translucency
- 5 **NB:** (presence of) nasal bone

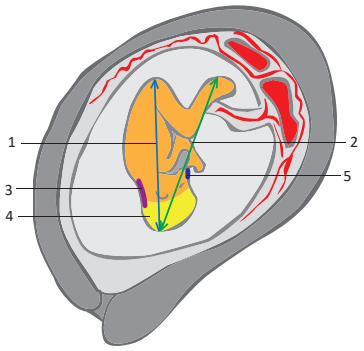

1st trimester

Important milestones of intra-uterine development

1st trimester (1st–14th week of pregnancy)
– all the organ systems are formed
week 2: implantation of the embryo, formation of the amniotic cavity, fluid and of the primary yolk sac
week 3: formation of three primary germ layers
week 4 (day 20–22): first beats of the foetal heart
week 4 (day 25–27): neural tube closure (anterior and posterior neuropore)
end of week 8: the end of the embryonal period, and the beginning of the foetal period

2nd trimester (14th–24th week of pregnancy)
– the foetus grows in length

3rd trimester (28th week till term)
– the foetus gains weight

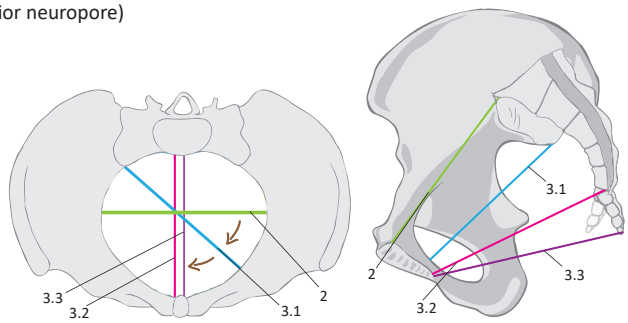

Internal pelvic dimensions in its specific planes

Anatomy of labour

The mechanism of labour is a series of movements of the foetus as it progressing through the birth canal. These movements are caused by uterine contractions that force the foetus against the soft and hard tissues of the birth canal

1 **Progression of the head** (*progressio capitis*)
– after the cervix dilates, the head descends further into the pelvic floor, distends the perineum and passes out through the vulval ring
– after the head, the shoulders are delivered followed by the rest of the body
- 1.1 **Small fontanele** (*fonticulus posterior*)
  – the leading point of head progression
- 2 **Initial head flexion** (*flexio capitis*)
  – the head rotates so that its smallest diameter is in line with the transverse diameter (*diameter transversa*) of the pelvic inlet (*apertura pelvis superior*)
- 3 **Inner rotation** (*rotatio capitis interna*)
  - 3.1 **to the oblique diameter** (*diameter obliqua*)
    – in the midpelvis (*amplitudo pelvis*)
  - 3.2 **to the anteroposterior diameter** (*diameter recta*)
    – in the midpelvis (*angustia pelvis*)
  - 3.3 **to the anteroposterior diameter** (*diameter recta*)
    – in the pelvic outlet (*apertura pelvis inferior*)
- 4 **Head extension** (*deflexio, extensio capitis*) as soon as the suboccipital part of the head reaches the symphysis, the head bends backwards (retroflexion)
- 5 **External head rotation** (*rotatio capitis externa, restitutio*) the delivered head rotates so that it is in the same position as it was in the uterus

6 **Delivery of the shoulders** (*expulsio brachiorum*) follows after head delivery
- 6.1 **anterior shoulder** to half the length of the deltoid muscle
- 6.2 **posterior shoulder** fully delivered

6.3 the rest of the anterior shoulder is delivered

7 **Delivery of the trunk and lower limbs** does not follow a regular mechanism

8 **Delivery of the placenta** is commonly called the third stage of labour

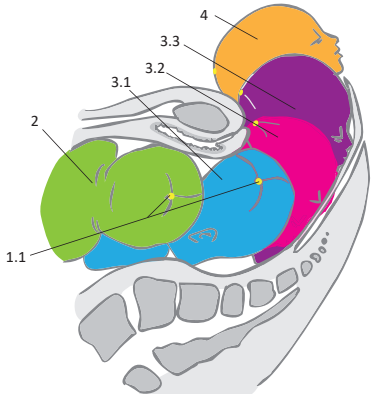

Progression of the head during labour

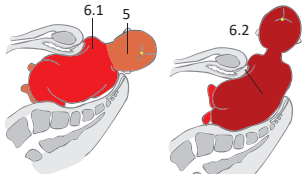

External head rotation and delivery of the shoulders

This copy belongs to ali yaghoubi

I. Development of the genital system

1. State 3 structures originating from the mesonephric duct. (p 238)
2. State 3 structures originating from the paramesonephric duct. (p. 238)
3. Explain which structures in the female are developmentally analogous to the root and raphe of the penis and to the spongy urethra. (p. 238)
4. Explain which structures in the male are developmentally analogous to the round ligament of the uterus and ligament of the ovary. (p. 238)

II. Male genital system

5. State 3 structures located in the scrotum. (p. 239)
6. State which serous cavity can only be found in male. (p. 239)
7. State the name of the gland that produces the major portion of ejaculate. (p. 239)

III. Testis

8. State the 2 layers of the tunica vaginalis and how they form. (p. 240)
9. State which 2 types of ducts can be found in the lobules of the testis. (p. 240)
10. Explain the main steps of the descent of the testis and why they occur. (p. 241)
11. Specify the latest age by which the testes should be fully descended and explain why. (p. 241)
12. Describe the lymphatic drainage of the testes and explain its clinical significance. (p. 241)
13. Explain the function and location of the Sertoli and Leydig cells. (p. 241)
14. Draw a scheme of the arterial supply and venous drainage of the testes. (p. 241)

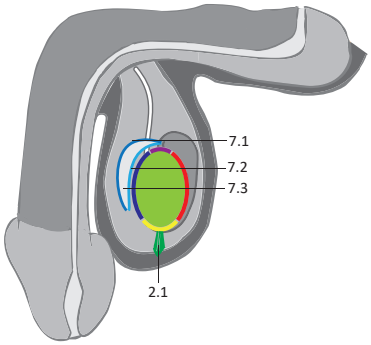

Describe the surfaces and parts of the testis

IV. Epididymis

15. Describe the 3 parts of the epididymis and 3 ligaments that attach the epididymis to the scrotum. (p. 242)
16. State the structure that connects the duct of the epididymis with the prostate and urethra. (p. 242)
17. Specify the functional differences between the testis and epididymis in the process of spermatozoa maturation. (p. 242)

V. Ductus deferens and spermatic cord

18. Explain the course of the six segments of the ductus deferens. (p. 243)
19. State which vessels pass posteriorly to the inguinal part of the ductus deferens. (p. 243)
20. List the 7 structures constituting the contents of the spermatic cord. (p. 243)
21. List the layers of the abdominal wall, eventually forming the layers of the spermatic cord. (p. 243)

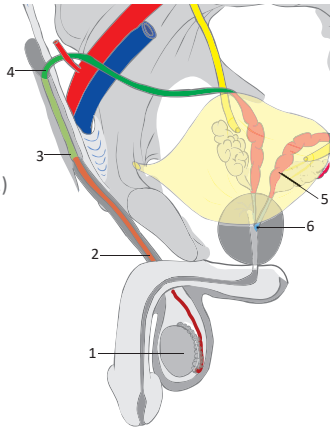

Describe the course of the ductus deferens

VI. Seminal glands and prostate

22. Describe the relation of the seminal glands to the ampulla of the ductus deferens. (p. 244)
23. State and describe the histological zones of the prostate and explain their clinical significance. (p. 245)
24. Explain the principle of the per rectum examination. (p. 245)
25. State the term used for the part of the prostate containing no glands. (p. 245)

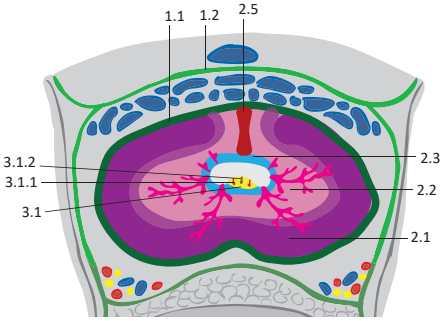

Describe the internal structure of the prostate

VII. Scrotum

26. Draw a cross-section of the wall of the scrotum and describe its layers. (p. 246)
27. State the layers of the abdominal wall that form the cremaster muscle and fascia. (p. 246)
28. State the layer of the scrotum that originates from Scarpa's fascia. (p. 246)
29. Draw a scheme of the vascular supply and the innervation of the scrotum. (p. 246)
30. Explain the function of the genitofemoral nerve in the innervation of the scrotum. (p. 246)

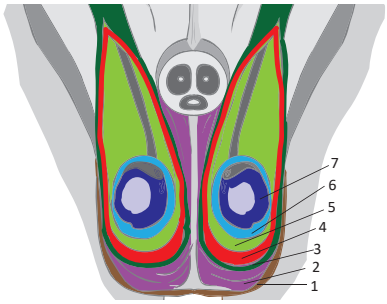

Describe the layers of the scrotum

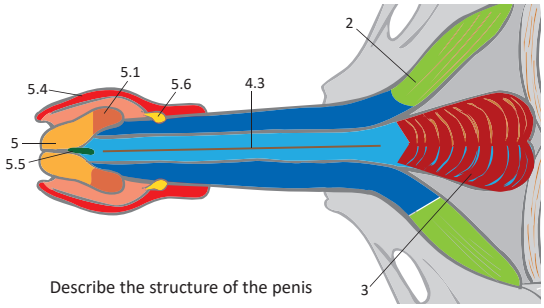

Describe the structure of the penis

VIII. Penis and male urethra

31. In a longitudinal section, describe the five basic parts of the penis. (p. 247)
32. Draw a transverse section of the penis and describe its vascular supply and venous drainage. (p. 247)
33. List the constricted segments of the male urethra. (p. 248)
34. Explain whether and how it is possible to straighten the curvatura prepubica. (p. 248)
35. In a longitudinal section, describe the physiological dilations of the male urethra. (p. 248)
36. Explain the difference in the activity of the parasympathetic and sympathetic systems in process of erection and ejaculation. (p. 248)

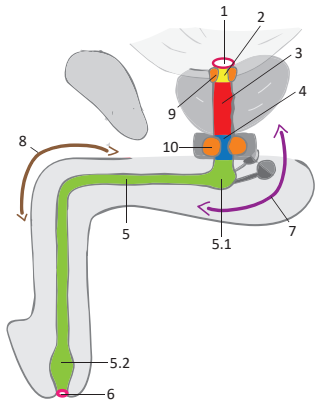

Describe the parts of the male urethra

IX. Female genital system

37. Name the internal and external female genital organs. (p. 249)
38. State the term for the final phase of development of a follicle before ovulation. (p. 249)
39. Explain the difference in function of the *corpus luteum menstruationis* and *corpus luteum graviditatis*. (p. 249)

X. Ovary

40. Describe the ligaments and the peritoneal fold of the ovary using a figure. (p. 250)
41. State the vessels that form the ovarian arcade. (p. 250)
42. State the layer of the ovary which contains its functional tissue. (p. 250)

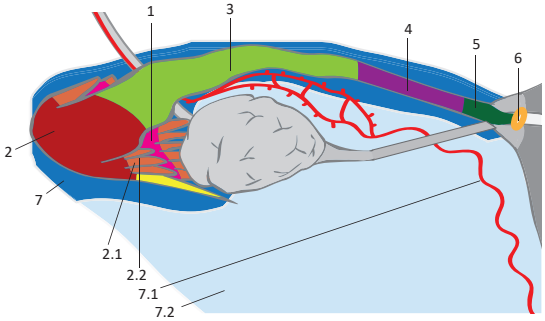

Describe the external structure of the Fallopian tube and its parts

XI. Uterine tube

43. Name the six parts of the uterine tube. (p. 251)
44. Explain the vascular supply of the uterine tube using a scheme. (p. 251)
45. Explain what is an ectopic pregnancy and state its most frequent location. (p. 251)

XII. Uterus and vagina

46. Describe the parts of the uterus using a figure. (p. 252)
47. Explain the difference between the zona basalis and zona functionalis of the endometrium. (p. 252)
48. Draw a sagittal section of the uterus in anteversion and anteflexion and specify their angles. (p. 253)
49. Describe the course of the *ligamenta cardinalia Mackenrodti*. (p. 253)
50. Draw a scheme of the lymphatic drainage of the uterus and specify the lymph nodes involved. (p. 253)
51. State the most caudal part of the peritoneal cavity in the female, how can it be palpated? (p. 254)
52. List the arteries supplying the vagina. (p. 254)

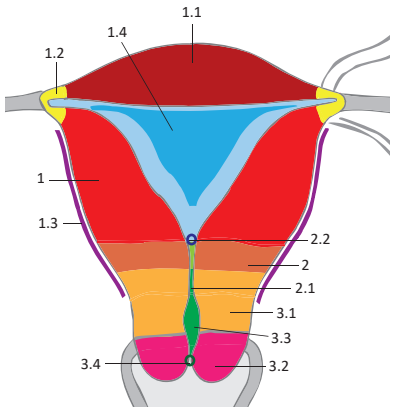

Describe the structure of the uterus

XIII. Female external genitalia and perineum

53. Specify the orifices found in the vestibule. (p. 255)
54. Name the 5 parts of the clitoris. (p. 255)
55. Describe the perineal muscles in male and female. (p. 256)

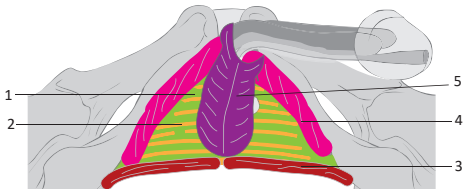

Describe the trigonum urogenitale in male

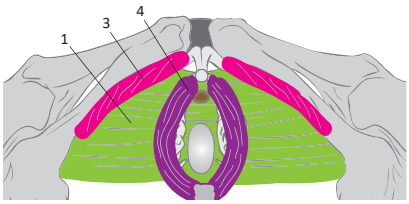

Describe the trigonum urogenitale in female

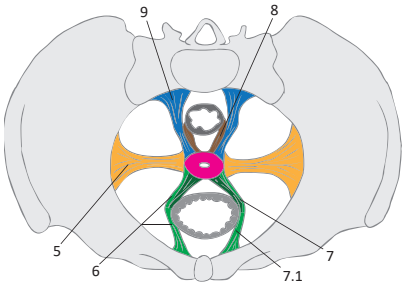

Describe the uterine parametral ligaments

This copy belongs to ali yaghoubi

We would like to **thank the following anatomists, clinicians and medical students** for their invaluable help, devotion and feedback in the preparation of this chapter.

Anatomists

Assoc. prof. Václav Báča, MD, PhD – Department of Anatomy, Third Faculty of Medicine, Prague, Czech Republic
Assoc. prof. Adriana Boleková, MD, PhD – Department of Anatomy, Pavol Jozef Šafárik University, Košice, Slovakia
Assoc. prof. Veronica Macchi, MD PhD – Institute of Human Anatomy, University of Padova, Italy

Clinicians

Andrej Černý, MD – Department of Gynaecology and Obstetrics, First Faculty of Medicine, Prague, Czech Republic
Lucie Mouková, MD, PhD – Department of Gynecologic Oncology, Masaryk Memorial Cancer Institute, Brno, Czech Republic
Ivo Minárik, MD, FEBU – Department of Urology, Second Faculty of Medicine,
Charles University in Prague and Motol University Hospital, Czech Republic

Medical students

Eva Fürstová
Kateřina Tomanová
Danil Yershov

1. AGUR, AMR. Grant's atlas of anatomy. 9th ed. Baltimore: Williams & Wilkins, 1991. ISBN 9780683037036.
2. CHUNG, K. W.; CHUNG, H. M. and N. L. HALLIDAY. BRS Gross Anatomy. 8th Ed. Philadelphia: Lippincott Williams & Wilkins, 2015. 544 p. ISBN 978-1-4511-9307-7.
3. LANZ, T. and W. WACHSMUTH. Praktische Anatomie. 7 bands. Berlin: Springer, 2003, 3658 p. ISBN 978-3-540-40571-9.
4. MILLS, S. E. Histology for pathologists. 4th Ed. Philadelphia: Lippincot Williams & Wilkins, 2012. 1328 p. ISBN-13: 978-1-4511-1303-7.
5. NETTER, F. H. Atlas of Human Anatomy. Professional Edition. 6th Ed. Oxford: Elsevier. 2014. 640 p. ISBN 978-1-455-75888-3.
6. OVALLE, W. K. and P. C. NAHIRNEY. Netter's Essential Histology: with Student Consult Access. 2nd Ed. Philadelphia: Saunders/Elsevier, 2013. 493 p. ISBN-13: 978-1-4557-0631-0.
7. ROHEN, J. W. LUTJEN-DRECOLL, E. and C. YOKOCHI. Color Atlas of Anatomy: A Photographic Study of the Human Body. 7th Ed. Stuttgart: Lippincot Williams & Wilkins, 532 p. ISBN 978-1-58255-856-1.
8. SNELL, R. S. Clinical anatomy by regions. 9th Ed. Philadelphia: Lippincott Williams & Wilkins, 2012. 768 p. ISBN 978-1-60913-446-4.
9. WILLIAMS, P. L., ed. Gray´s Anatomy: the anatomical basis of medicine and surgery. 38th Ed. New York: Churchill Livingstone, 1995, 2092 p. ISBN 0-443-05717-6.

Memorix Anatomy

9 Heart and blood vessels

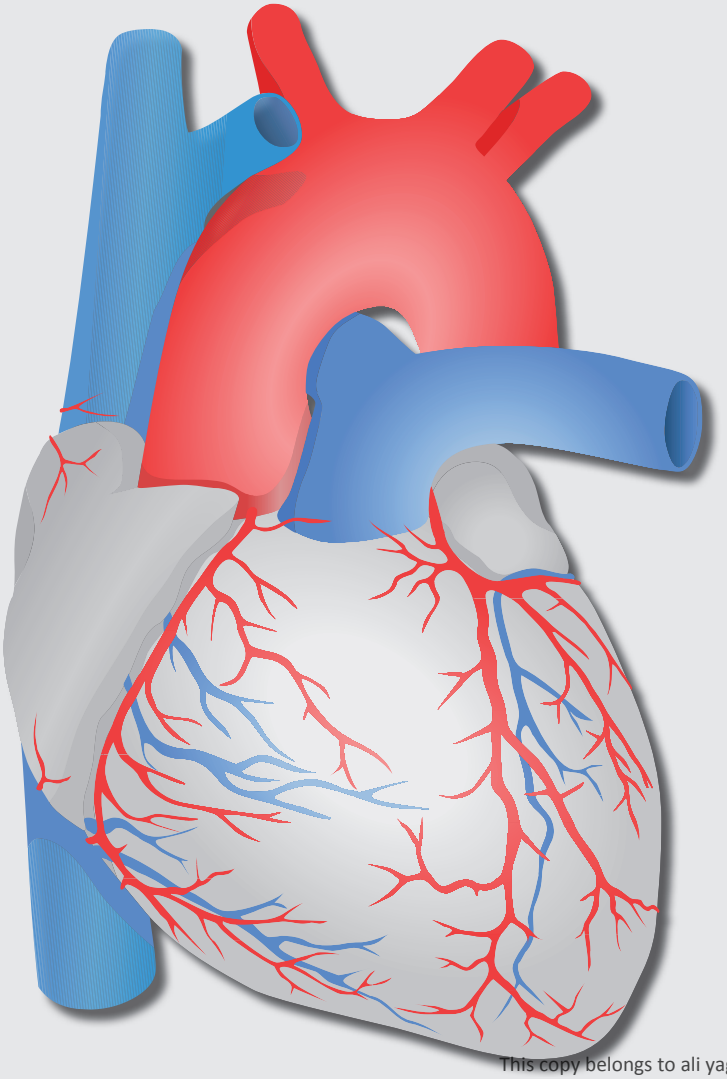

Matej Halaj
Barbora Beňová
David Kachlík
Radovan Hudák
Ondřej Volný
Adam Whitley

General overview of the blood vessels 264
General overview of the heart 265
Heart 266
Arteries 277
Veins 294
Schemes 302
Table 311
Review questions and figures 314
Acknowledgements and references 316

This copy belongs to ali yaghoubi

There are three types of blood vessels: **arteries, veins, and capillaries**. **Arteries** carry blood **from the heart to the organs**. **Veins** drain blood **from the organs** and direct it back **to the heart**. **Capillaries** form a **network of thin-walled vessels** in which oxygen and nutrient exchange between the blood and tissues takes place. All these types of vessels are organised in the **pulmonary and systemic circulation**. Direct connections between vessels of approximately the same calibre are called **anastomoses**.

Types of blood vessels

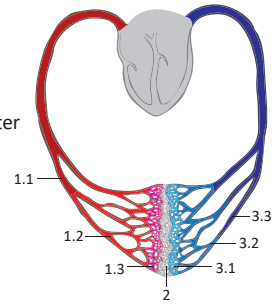

1 **Arteries** (*arteriae*)
- 1.1 **Large arteries** – elastic arteries
  - – the pulmonary trunk and the aorta with its major branches
- 1.2 **Medium-sized and small arteries** – muscular arteries
  - – regulate blood pressure by changing the size of their diameter
  - – constitute the majority of arteries
- 1.3 **Arterioles** (arteriolae) – 0.1–0.2 mm in diameter

2 **Capillaries** (*vasa capillaria*)

3 **Veins** (*venae*)
- 3.1 **Venules** (*venulae*) – 0.2–1 mm in diameter
- 3.2 **Small and medium-sized veins** – 1–9 mm in diameter
  - – the most common type of vein, contain valves
- 3.3 **Large veins** – the superior and inferior vena cava and their major tributaries

Histology

General anatomy of the vascular wall

1 **Intima** (*tunica intima*) – the innermost layer in contact with the blood
- 1.1 **Endothelium** – a single layer of flat endothelial cells
- 1.2 **Subendothelial layer** (*stratum subendotheliale*)
  - – loose connective tissue

- 2 **Media** (*tunica media*) – the middle layer
  - – contains reticular and elastic fibres and circularly arranged smooth muscle cells
- 3 **Adventitia** (*tunica adventitia/externa*) – the outermost layer
  - – contains longitudinally arranged collagen and elastic fibres
  - – the fibres cross-link and attach to the surrounding connective tissue

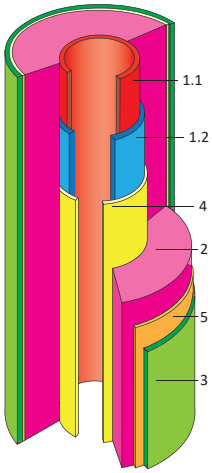

Longitudinal section of a muscular artery

Specifics of the structure of the arterial wall

– the media is the thickest layer due to its smooth muscle component
- 4 **Internal elastic lamina** (*membrana elastica interna*)
  - – a layer of elastic fibres on the inner side of the media of small and medium-sized arteries
- 5 **External elastic lamina** (*membrana elastica externa*)
  - – a layer of elastic fibres on the outer side of the media of small and medium-sized arteries

Specifics of the structure of the venous wall

– adventitia is the thickest layer
– venous valves are extensions of the intima located in small and medium-sized veins

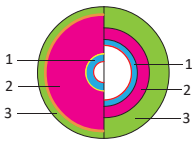

Cross-section of artery (left) and vein (right)

Anastomoses

Shunts (anastomoses) are direct connections between vessels.
They dilate to change the pattern of blood distribution in various tissues of the body.

1 **Arterio-venous (a-v) anastomoses** – directly connect arterioles and venules
- – are located in the skin of the palms and fingertips and function to regulate body temperature
- – are located in the kidneys, lungs and thyroid gland, where they participate in the regulation of blood pressure

2 **Arterio-arterial (a-a) anastomoses** – directly connect small and medium-sized arteries
- – are located in the gastrointestinal tract
- – form the palmar and plantar arches in the hands and feet
- – the circle of Willis is a special kind of arterio-arterial anastomosis

3 **Veno-venous (v-v) anastomoses** – directly connect small and medium-sized veins
- – constitute the porto-caval and the cavo-caval anastomoses between the portal vein and inferior vena cava, and inferior and superior vena cavae, respectively

Cor is the Latin term for heart.
Kardia is the Greek term for heart.
Vas is the Latin term for vessel (plural: vasa). The term vascularis means vascular.
Angeion is Greek for vessel.

The circulatory system consists of the heart and the blood and lymphatic vessels. The cardiovascular system consists of the heart and blood vessels.

Types of capillaries:
Continuous capillaries are lined by a smooth layer of endothelium that does not have any pores (fenestrations). This type of capillary is found in the majority of organs, including the brain and muscles.
Fenestrated capillaries with diaphragms are lined by endothelium that is decorated by small pores covered by diaphragms. They are located in organs where rapid exchange between tissue and blood takes place, such as in the intestines and endocrine glands.
Fenestrated capillaries without diaphragms are found in the glomeruli of the kidney
Sinusoids are characterised by a layer of endothelium with gaps between the endothelial cells and many fenestrations. They are found in the haematopoietic organs (liver, spleen, blood marrow, and dental pulp).

The thick muscular wall of arteries tends to maintain a circular lumen. Veins have a much thinner muscular wall and so the shape of their lumen often changes due to pressure from surrounding structures.

The vascular wall is supplied by the vasa vasorum and innervated by the nervi vasorum. The inner part of the vascular wall derives its nutrients by diffusion from the blood.

Clinical notes

Formation of a blood clot (thrombus) in the arterial or deep venous circulation is a clinically serious state. The thrombus may break off the vessel wall and block a vessel down stream to it. Such a complication is known as a thromboembolism.

Transposition of the great arteries is a congenital heart defect where the aorta is connected to the right ventricular outflow tract and the pulmonary trunk to the left ventricular outflow tract. The pulmonary and systemic circulations are therefore completely separated unless a ventricular septal defect allows for blood mixing, which fortunately occurs in most cases.

The anatomy of the heart wall resembles the large elastic arteries; its **internal and middle layers consist of endothelial cells and thick muscle tissue, respectively**. During development, the heart proceeds through three stages: **formation of the heart tubes, loop formation and septation.** A series originally paired vessels form the aortic arch with its branches. **The first contractions of the heart tube can be observed as early as the 20th day of intrauterine life.**

Flow of blood through the heart and the pulmonary circulation

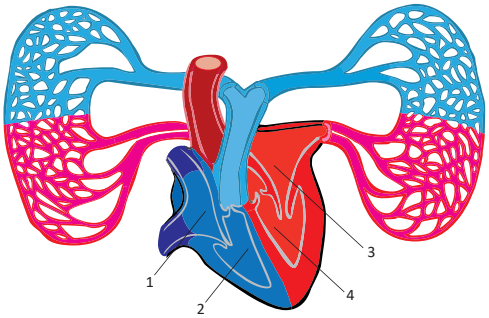

- Superior and inferior vena cava (*vena cava superior et inferior*)
- 1 **Right atrium** (*atrium dextrum*)
- 2 **Right ventricle** (*ventriculus dexter*)
- Pulmonary trunk (*truncus pulmonalis*)
  Pulmonary capillaries
- Pulmonary veins (*venae pulmonales*)
- 3 **Left atrium** (*atrium sinistrum*)
- 4 **Left ventricle** (*ventriculus sinister*)
- Aorta

Histology

Heart wall

- 1 **Endocardium** – the innermost layer of the heart wall lining the chambers of the heart
  – is composed of endothelium and connective tissue; forms the entire mass of the heart valves
  1.1 **Subendocardial layer** (*stratum subendocardiale*) – a layer of connective tissue containing part of the conducting system of the heart
- 2 **Myocardium** – consists of two layers of cardiac muscle in the atria and three layers in the ventricles
  2.1 **Vortex of heart** (*vortex cordis*) – the spiral-shaped musculature of the apex of the heart
- 3 **Epicardium** – the visceral layer of pericardium, a serosal membrane
  – lies over the heart and the vessels that supply the myocardium with oxygen and nutrients
  3.1 **Subepicardial layer** (*lamina subepicardiaca*)
  – consists of adipose and connective tissues embedding the vessels of the heart
- 4 **Pericardium** – a double-layered sac covering the heart in the middle inferior mediastinum
  – forms an impression on the diaphgram called the *area pericardiaca*
  - 4.1 **Serous pericardium** (*pericardium serosum*) – the inner layer of the parietal pericardium
    – is reflected onto the heart forming the epicardium (the visceral pericardium)
  - 4.2 **Fibrous pericardium** (*pericardium fibrosum*) – the outer layer of the parietal pericardium
    – is composed of dense connective tissue
  - 4.3 **Pericardial cavity** (*cavitas pericardiaca*)
    – a potential space between the epicardium and the (visceral) serous pericardium
    – contains a small amount of fluid, which allows smooth movements of the heart

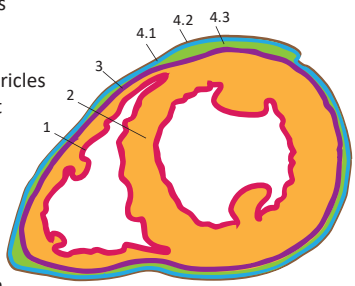

Transverse section of the heart at the level of the ventricles, inferior view

Heart valves (*valvae cordis*) – belong to the endocardium, are composed of three layers of avascular tissue:
a fibrous layer (*lamina fibrosa*) of dense connective tissue lined by endothelium on both sides
– commissures are junctions of the adjacent cusps of valves, formed by fibroelastic tissue

1 **Fibrous rings** (*anulus fibrosus*) – part of the cardiac skeleton that provide the attachment of the heart valves

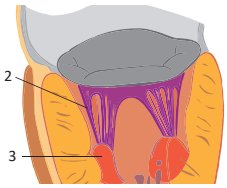

Atrioventricular valve

Characteristics of the atrioventricular (AV) valves

- 2 **Tendinous cords** *(chordae tendineae)* – anchor the AV valves to the papillary muscles
- 3 **Papillary muscles** (*musculi papillares*) – prevent the valves from prolapsing into the atria

Characteristics of the semilunar valves

- 4 **Nodules** (*noduli*) – central thickenings of the semilunar valvules
- 5 **Lunules** (*lunulae*) – peripheral attenuations of the semilunar valvules

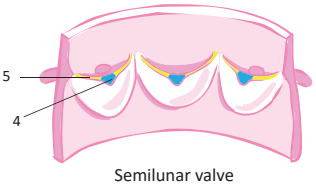

Semilunar valve

Development

1. **Early development** – mesodermal cells of the cardiogenic zone give rise to two heart tubes that fuse to form a single heart tube
2. **Loop formation** – the heart tube bends ventrally and then to the right, forming the first heart cavities
   – the heart tube is caudally attached to the septum transversum (the precusor of the central tendon of the diaphragm) and cranially to the aortic arches
   - 2.1 **Sinus venosus** – the future inflow tract of the right atrium (does not originate from the heart tube)
   - 2.2 **Common atrium** (*atrium commune*) – the future right atrium
   - 2.3 **Embryonic common ventricle** (*ventriculus communis*) – the future inflow tract of the ventricles
   - 2.4 **Conus arteriosus** (*conus arteriosus*) – the future outflow tract of the ventricles
   - 2.5 **Truncus arteriosus** (*truncus arteriosus*) – the future aorta and pulmonary trunk
3. **Septation** – formation of valves and septa
   – divides the heart into four chambers and separates the aorta from the pulmonary trunk

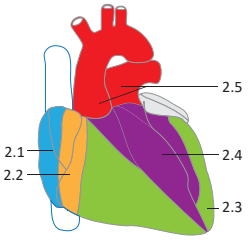

Heart divided into its original developmental parts

This copy belongs to ali yaghoubi

The heart is the main organ of the cardiovascular system. It is located **behind the sternum in the middle inferior mediastinum**. One-third of the heart is positioned to the right of the median plane whilst the other two-thirds are on the left side. **The cardiac axis** connects the opening of the superior vena cava with the apex of the heart; it **directs diagonally, ventrally, and caudally**. The heart consists of four chambers separated by septa and valves. **From the clinical and functional viewpoint, the heart is divided into the right heart and the left heart. The pericardium** is a firm sac **composed of two sheets** that are separated by **15–50 ml of serous fluid, enabling smooth heart movements**. Anteriorly, the heart is positioned in the pericardium freely while posteriorly it is attached by the main vessels entering and leaving the heart.

Topography of the heart in the pericardium

- 1 **Ventrally:** anterior inferior mediastinum and sternum
- 2 **Dorsally:** posterior inferior mediastinum and vertebral column
- 3 **Laterally:** descending phrenic nerves with the pericardiacophrenic vessels and pericardium lining the mediastinal pleura
- 4 **Cranially:** the aortic arch, arising from the heart and heading to the superior mediastinum
- 5 **Caudally:** central tendon of the diaphragm

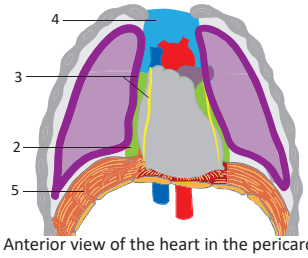

Anterior view of the heart in the pericardium

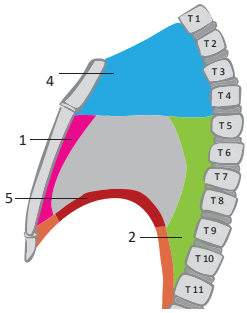

Sagittal section of the mediastinum

Projection of the heart onto the anterior thoracic wall

- **The projection of the heart on the anterior thoracic wall** is determined by four points:
  - **2nd intercostal space on the right**, 1 cm lateral to the sternum
  - **5th intercostal space on the right** near the linea sternalis
  - **5th intercostal space on the left** medial to the midclavicular line corresponds to the projection of the apex of the heart
  - **2nd intercostal space on the left side** 2 cm lateral to the sternum

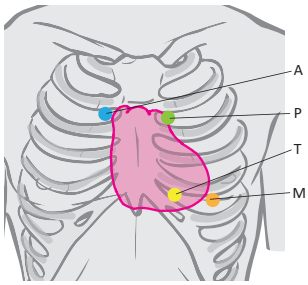

Projection of the heart and auscultation sites of the heart valves

Auscultation sites of the heart valves

- A – **Aortic valve:** 2nd right intercostal space close to the sternum
- P – **Pulmonary valve:** 2nd left intercostal space close to the sternum
- T – **Tricuspid valve:** 5th right or left intercostal space close to the sternum
- M – **Mitral valve:** 5th left intercostal space just medial to the midclavicular line

Pericardium

The pericardium forms several structures where its parietal layer and visceral layers fuse:

- 1 **Porta arteriarum** – a cranially positioned opening for the aorta and pulmonary trunk arising from the heart
- 2 **Porta venarum** – a caudally positioned opening for the two caval veins and the four pulmonary veins entering the heart
- 3 **Transverse pericardial sinus** (*sinus transversus pericardii*) – a space on the posterior surface of the pericardium between porta arteriarum and porta venarum
- 4 **Oblique pericardial sinus** (*sinus obliquus pericardii*) – a space beneath the area of the porta venarum

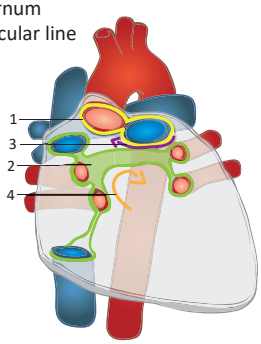

Anterior view of the posterior part of the pericadrium with the heart removed

The average weight of a human heart is 290–350 g.

The location of the heart depends on age, position of the diaphragm, the respiratory movements, the shape of the thorax and body position. In a short and wide thorax with a high position of the diaphragm the heart is positioned more horizontally. In a narrow and long thorax the heart is positioned more longitudinally.

Pendulum heart *(cor pendulum)* is a term for a heart located in a narrow and long thorax; the heart looks like it's hanging down from the great vessels.

The auscultation points are also termed Testut's points. Connecting these points with a line traces the circumference of the projection of the heart onto the thoracic wall.

Viscerosensory innervation of the heart is provided by branches of the phrenic nerves that innervate the pericardium.

The pericardiacophrenic arteries accompanying the phrenic nerves provide the arterial supply of the pericardium.

Clinical notes

Cardiac tamponade is a pathological disorder in which fluid accumulates in the pericardial cavity causing the heart to be unable to adequately distend during diastole. The pericardial cavity can expand to contain 1000 ml of fluid. If the increase of fluid occurs slowly over a long period time there may be no clinical manifestations. An acute tamponade is caused by a sudden increase of fluid, by approximately tens of millilitres (max. 200 ml) and is a medical emergency. This situation may occur due to rupture of free myocardial wall over a postischemic scar or as a result of rupture or dissection of the aorta.

Pericardiocentesis is a surgical procedure in which fluid is removed from the pericardial cavity. It is performed with a special needle that is inserted between the xiphoid process and the left costal margin within the infrasternal angle under ultrasound control. It is also performed, but less commonly, in the inferior interpleural area in the 5th left intercostal space near the left sternal border.

Structures

General parts

- 1 **Base of heart** (*basis cordis*) – faces superiorly, posteriorly, and medially
  - – the location of the great vessels entering and leaving the heart
  - – its superior margin reaches the border of the superior mediastinum
- 2 **Apex of heart** (*apex cordis*) – faces inferiorly, anteriorly, and laterally
  - – touches the thoracic wall at the 5th intercostal space in the midclavicular line

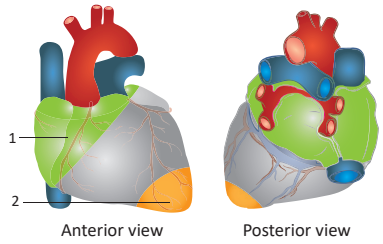

Anterior view Posterior view

Surfaces

- 1 **Anterior surface** (*facies anterior/sternocostalis*)
  - – is formed mainly by the right ventricle and partially by the left ventricle
- 2 **Inferior surface** (*facies inferior/diaphragmatica*) – faces the diaphragm
  - – is formed by the posterior surfaces of both ventricles
- 3 **Right and left pulmonary surfaces** (*facies pulmonalis dextra et sinistra*)
  - – the right pulmonary surface is formed by the right atrium
  - – the left pulmonary surface is formed by the left atrium and left ventricle
  - 3.1 **Cardiac impression** (*impressio cardiaca pulmonis*)
    - – the impression of the pulmonary surfaces of the heart on the lungs

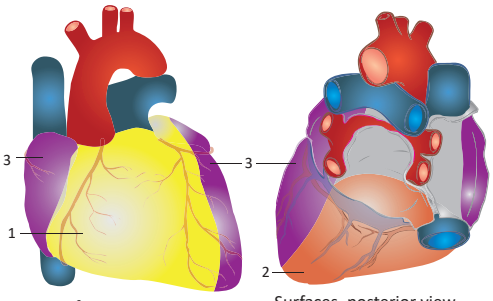

Surfaces, anterior view Surfaces, posterior view

Borders

- 1 **Right border** (*margo dexter/acutus*) – a sharp margin on the right ventricle
- 2 **Left border** (*margo sinister/obtusus*) – a rounded margin on the left ventricle

Sulci

- 3 **Coronary sulcus** (*sulcus coronarius*) – a groove on the surface of the heart separating the atria from the ventricles
  - – contains the right coronary artery, the circumflex branch of the left coronary artery, the great cardiac vein and the coronary sinus
- 4 **Anterior interventricular sulcus** (*sulcus interventricularis anterior*)
  - – a groove on the anterior surface of the heart between the right and left ventricles
  - – is formed by the interventricular septum
  - – contains the anterior interventricular branch and the great cardiac vein
- 5 **Posterior interventricular sulcus** (*sulcus interventricularis posterior*)
  - – a groove on the posterior surface of heart between the right and left ventricles
  - – is formed by the interventricular septum
  - – contains the posterior interventricular branch and middle cardiac vein
- 6 **Sulcus terminalis cordis** – is formed by the crista terminalis
  - – a groove close to the opening of the superior and inferior vena cava
  - – the border between the proper right atrium and the sinus venosus

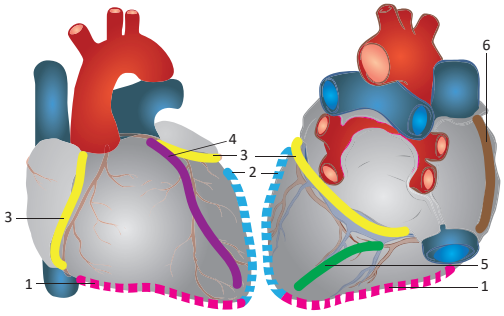

Borders and sulci, anterior view Borders and sulci, posterior view

Heart chambers

- 1 **Right atrium** (*atrium dextrum*)
  - – receives oxygen-poor blood from the systemic circulation
  - 1.1 **Right auricle** (*auricula dextra*)
- 2 **Left atrium** (*atrium sinistrum*)
  - – receives oxygen-rich blood from the pulmonary circulation
  - 2.1 **Left auricle** (*auricula sinistra*)
- 3 **Right ventricle** (*ventriculus dexter*) – receives blood from the right atrium and pumps it to the pulmonary circulation via the pulmonary trunk
- 4 **Left ventricle** (*ventriculus sinister*) – receives blood from the left atrium and pumps it to the systemic circulation via the aorta

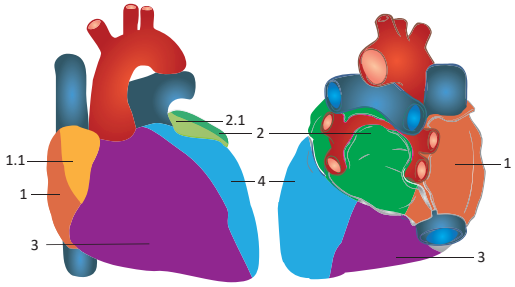

Heart chambers, anterior view Heart chambers, posterior view

Cardiac septa

5 **Interatrial septum** (*septum interatriale*) – a thin septum separating the right and left atria

6 **Interventricular septum** (*septum interventriculare*)
- – a thick septum separating the right and left ventricles
  - 6.1 **Membranous part** (*pars membranacea*) – the superior thin fibrous part between the inflow tract of the right ventricle and the outflow tract of the left ventricle
    - 6.1.1 **Atrioventricular septum** (*septum atrioventriculare*)
      - – part of the membranous part of interventricular septum, between the right atrium and the outflow tract of the left ventricle
  - 6.2 **Muscular part** (*pars muscularis*) – the inferior thick muscular part

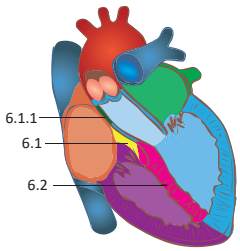

Frontal section of the heart showing the heart chambers and septa

This copy belongs to ali yaghoubi

Blood from the systemic circulation flows **through the superior and inferior vena cava into the right atrium**. The **tricuspid valve** directs blood from the right atrium into the right ventricle. The initial parts of the conducting system of the heart, **the sinoatrial and atrioventricular nodes**, are located in the wall of the right atrium.

Basic structures

- 1 **Right auricle** (*auricula dextra*) – an outpocketing appendage of the right atrium
  - 1.1 **Pectinate muscles** (*musculi pectinati*) – comb-like muscle fascicles inside the right auricle
- 2 **Interatrial septum** (*septum interatriale*) – a thin barrier separating the right and left atria
  - 2.1 **Oval fossa** (*fossa ovalis*) – an oval-shaped depression in the interatrial septum
    – a remnant of the septum primum and septum secundum that merge shortly after birth, closing the foetal interatrial shunt (*foramen ovale*)
    - 2.1.1 **Border of oval fossa** (*limbus fossae ovalis*)
      – an elevated ridge around the margin of the oval fossa
- 3 **Atrioventricular septum** (*septum atrioventriculare*) – a fibrous barrier between the right atrium and the outflow tract of the left ventricle
- 4 **Crista terminalis** – a muscular crest inside the right atrium
  – separates the sinus of the venae cavae from the proper right atrium
- 5 **Sulcus terminalis cordis** – a groove on the external surface of the right atrium corresponding to the crista terminalis
- 6 **Intervenous tubercle** (*tuberculum intervenosum*)
  – an elevated muscular ridge between the superior and inferior vena cava
  – directs blood from the superior vena cava to the right ventricle

Openings in the right atrium

- 7 **Sinus of venae cavae** (*sinus venarum cavarum*)
  – the posterior part of the right atrium where the superior and inferior vena cava enter
  - 7.1 **Opening of superior vena cava** (*ostium venae cavae superioris*)
  - 7.2 **Opening of inferior vena cava** (*ostium venae cavae inferioris*)
    - 7.2.1 **Valve of inferior vena cava / Eustachian valve** (*valvula venae cavae inferioris*)
      –a semilunar fold at the opening of the inferior vena cava
      –directs blood through foramen ovale to the left atrium during prenatal life
- 8 **Opening of coronary sinus** (*ostium sinus coronarii*)
  – the opening of the main vein draining blood from the heart
  - 8.1 **Valve of coronary sinus / Thebesian valve** (*valvula sinus coronarii*)
    – a fold covering the opening of the coronary sinus
- 9 **Openings of smallest cardiac veins** (*foramina venarum minimarum*)
- 10 **Right atrioventricular orifice** (*ostium atrioventriculare dextrum*) – an opening between the right atrium and the right ventricle covered by the tricuspid valve

Other structures

- 11 **Tricuspid valve / right atrioventricular valve** (*valva atrioventricularis dextra / tricuspidalis*)
- 12 **Triangle of Koch** (*trigonum nodi atrioventricularis*)
  – location of the atrioventricular node
  – its borders are:
  - 12.1 **Septal cusp of tricuspid valve**
  - 12.2 **Tendon of valve of inferior vena cava / Tendon of Todaro** (*tendo valvulae venae cavae inferioris*)
  - 12.3 **Opening of coronary sinus**

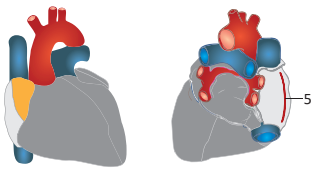

Anterior and posterior views of the heart, right ventricle in bright color

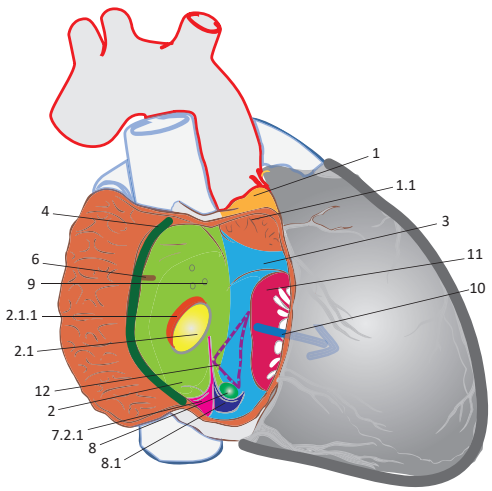

Open right ventricle after cutting off the right auricle

The anterior veins of the right ventricle are small veins on the anterior surface of the heart that open directly into the right atrium.

The right ventricular outflow tract is also called the conus arteriosus (*infundibulum / pars glabra*) because of its funnel-like shape narrowing cranially towards the opening of the pulmonary trunk.

The stroke volume is the volume of blood ejected in each heartbeat.

The thickness of the wall of the right ventricle is 3–4 mm. The left ventricular wall can be up to three times thicker (7–11 mm).

The septal papillary muscle is made up of several smaller muscles.

The crista terminalis separates the sinus venosus from the common atrium during prenatal development.

Clinical notes

Right heart failure results in blood congestion in the systemic circulation and an elevation in central venous pressure. This condition manifests with oedema, which accumulates around the ankles (perimalleolar oedema) due to gravity and elevated jugular venous pressure detected by increased filling of the external jugular veins. Blood also accumulates in the portal circulation, which leads to enlargement of the liver and spleen (hepatosplenomegaly) and an accumulation of fluid in the peritoneal cavity (ascites).

Tricuspid valve stenosis is a relatively infrequent condition in which the orifice of the tricuspid valve is narrowed, usually due to endocarditis in intravenous drug users.
Tricuspid insufficiency is a condition in which blood regurgitates through the tricuspid valve to the right atrium. In most cases, it is caused by increased pressure in the pulmonary circulation that results in dilation of the right fibrous ring and tricuspid insufficiency.

Pulmonary stenosis is a narrowing of the right ventricular outflow tract in the area of the pulmonary valve and usually occurs as a part of complex congenital heart defects.
Pulmonary valve insufficiency is a relatively rare condition in which blood regurgitates from the pulmonary trunk to the right ventricle. It is caused by a relative dilation of the right ventricle (result of volume overload and pulmonary hypertension) in adult patients treated for complex congenital heart defect in childhood.

Blood enters the right ventricle through the tricuspid valve. Blood is directed first through **the trabecular inflow tract, composed of muscular bundles (trabeculae carnae)**, and then through **the smooth outflow tract (conus arteriosus)**. Blood flows through the pulmonary valve to the pulmonary trunk and consequently throughout the entire pulmonary circulation where gas exchange takes place. The right ventricle pumps against the relatively low pulmonary blood pressure of around 20 mmHg.

Inflow tract

- 1 **Right atrioventricular orifice** (*ostium atrioventriculare dextrum*) – the opening between the right atrium and the right ventricle
- 2 **Tricuspid valve / right atrioventricular valve** (*valva atrioventricularis dextra/tricuspidalis*)
  - prevents retrograde flow from the right ventricle to the right atrium
  - 2.1 **Anterior cusp** (*cuspis anterior*) – is anchored to the anterior and septal papillary muscles
  - 2.2 **Posterior cusp** (*cuspis posterior*) – is anchored to the posterior and septal papillary muscles
  - 2.3 **Septal cusp** (*cuspis septalis*) – is anchored to the posterior and septal papillary muscles
- 3 **Papillary muscles** (*musculi papillares*) – muscles originating from myocardium, covered with endocardium and attached to the cusps of the tricupid valve by tendinous cords (*chordae tendineae*)
  - 3.1 **Anterior papillary muscle** (*musculus papillaris anterior*) – is attached to the anterior cusp
  - 3.2 **Posterior papillary muscle** (*musculus papillaris posterior*) – is attached to the posterior and septal cusps
  - 3.3 **Septal papillary muscle** (*musculus papillaris septalis*) – is attached to the anterior, posterior, and septal cusps
- 4 **Trabeculae carnae** – thick muscular bundles in the right ventricular inflow tract

Outflow tract – conus arteriosus

- 5 **Septomarginal trabecula / moderator band** (*trabecula septomarginalis*)
  - a muscular bundle connecting the interventricular septum with the anterior papillary muscle
  - the right bundle branch of the conducting system of the heart runs within the septomarginal trabecula
- 6 **Supraventricular crest** (*crista supraventricularis*) – a crest dividing the right ventricle into inflow and outflow tracts
- 7 **Opening of pulmonary trunk** (*ostium trunci pulmonalis*) – leads to the pulmonary trunk and contains the pulmonary valve
- 8 **Pulmonary valve** (*valva trunci pulmonalis*) – is composed of the three semilunar cusps
  - prevents retrograde flow of blood from the pulmonary trunk into the right ventricle
  - 8.1 **Anterior semilunar cusp** (*valvula semilunaris anterior*)
  - 8.2 **Right semilunar cusp** (*valvula semilunaris dextra*)
  - 8.3 **Left semilunar cusp** (*valvula semilunaris sinistra*)
- 9 **Interventricular septum** (*septum interventriculare*)
  - 9.1 **Muscular part** (*pars muscularis*)
  - 9.2 **Membranous part** (*pars membranacea*)
    - part of the cardiac skeleton

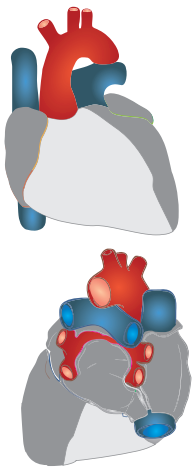

Anterior and posterior views of the heart, right ventricle in bright color

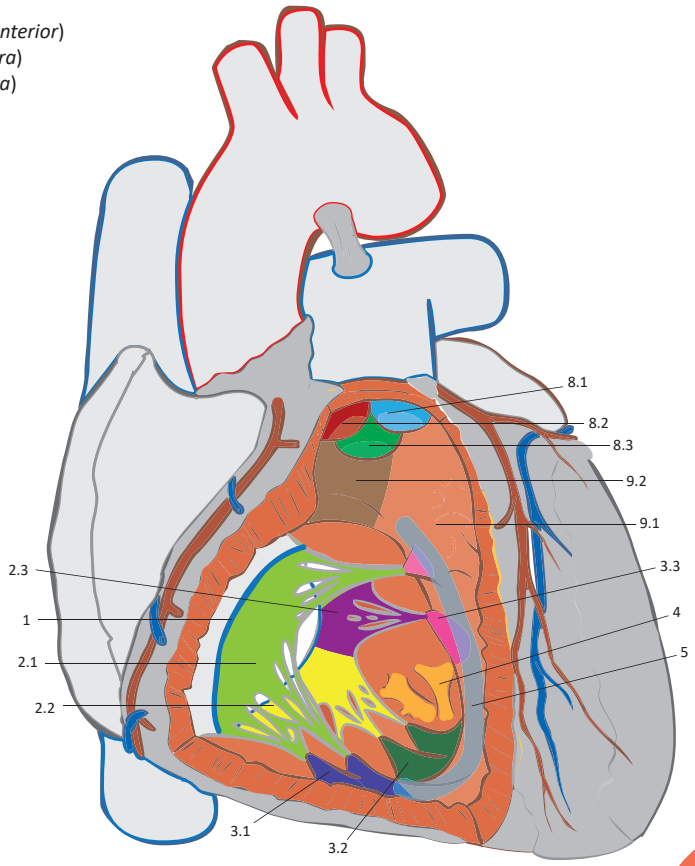

This copy belongs to ali yaghoubi

Oxygenated blood from the pulmonary circulation flows through **the four pulmonary veins to the left atrium** and then through **the mitral valve to the left ventricle.**

Basic structures

- 1 **Left auricle** (*auricula sinistra*) – an outpocketing appendage of the left atrium
  - 1.1 **Pectinate muscles** (*musculi pectinati*)
    – little muscular fascicles organised in ridges inside the left auricle
- 2 **Interatrial septum** (*septum interatriale*) – a septum between the right and left atria
- 3 **Valve of foramen ovale** (*valvula foraminis ovalis*)
  – a circular thinned area in the interatrial septum
  – the original valve covering the foramen ovale
  – postnatally merges with the primary interatrial septum and thus can be found on the opposite side of the oval fossa

Openings in the left atrium

- 4 **Openings of pulmonary veins** (*ostia venarum pulmonalium*)
  – openings of the four pulmonary veins, two right and two left veins
- 5 **Openings of smallest cardiac veins** (*ostia venarum minimarum*)
- 6 **Left atrioventricular orifice** (*ostium atrioventriculare sinistrum*)
  – an opening between the left atrium and the left vetricle containing the mitral valve

Other structures

- 7 **Mitral valve / left atrioventricular valve** (*valva atrioventricularis sinistra / valva mitralis*)
  7.1 **Anterior cusp** (*cuspis anterior*)
  7.2 **Posterior cusp** (*cuspis posterior*)

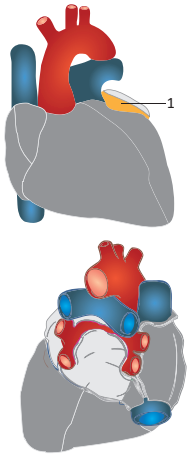

Anterior and posterior views of the heart; left atrium in bright color

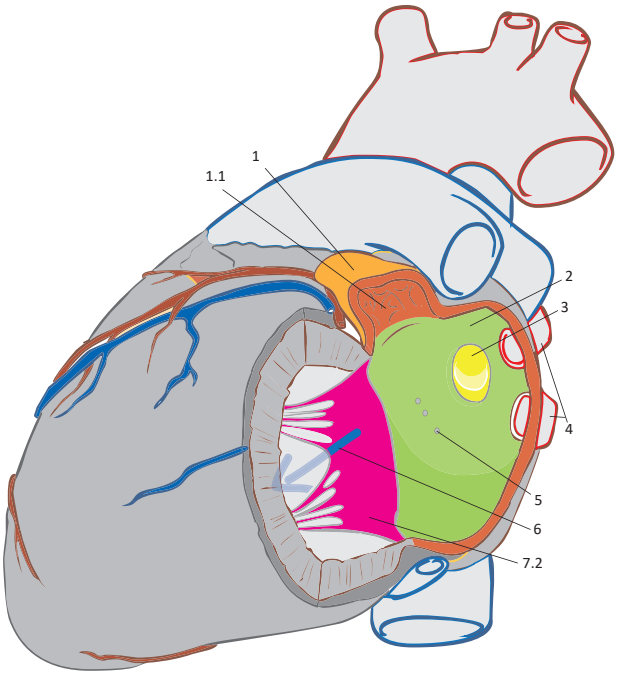

The posterior aortic sinus of Valsalva (*sinus aortae posterior Valsalvae*) is a noncoronary sinus, from which no coronary artery arises.

Normal blood pressure values are around 120/80 mmHg. Elevated blood pressure (hypertension) is defined as blood pressure over 140/90 mmHg. Blood pressure below 90/60 mmHg is considered abnormally low (hypotension).

Bicuspid valve is an obsolete term for the mitral valve.

Clinical notes

Left-sided heart failure leads to congestion of blood and elevated blood pressure in the pulmonary circulation. This situation results in lung oedema presenting as dyspnoea that is most prominent when lying down. Dyspnoea is relieved when the patient sits or stands up (orthopnoea).

Atrial fibrillation is a heart rhythm disorder in which the atria contract irregularly, chaotically, and thus ineffectively. This causes a change of blood flow in the atrial auricle from laminar to turbulent with an increased risk of blood clot formation. A blood clot may be released to the systemic circulation and obstruct an artery supplying the brain and/or other organs (thromboembolism), leading to a complete or partial loss of blood supply (ischaemia).

Mitral stenosis is described as a narrowing of the orifice of the mitral valve. It can lead to the accumulation of blood in the pulmonary circulation and lung oedema, which presents as dyspnoea. It is most commonly occurs as a sequela of rheumatic heart disease.

Mitral regurgitation (insufficiency) leads to reverse blood flow from the left ventricle to the left atrium during systole. It is one of the most common acquired valve defects, usually caused by a degenerative process of the valve. Mitral regurgitation often results in left-sided heart failure.

Aortic valve stenosis is a narrowing of the orifice of the aortic valve, usually caused by degenerative calcification (a process similar to atherosclerosis), thus presenting mostly in older age. It is a common acquired valve defects.

Aortic insufficiency leads to reverse flow from the aorta to the left ventricle. Most commonly, this is caused by degeneration or dilatation of the aortic ring and/or by other pathologic states.

Blood flows **from the left atrium through the mitral valve to the left ventricle**. It flows through the left ventricular **inflow tract composed of muscular bundles** (trabeculae carnae) and then through the **smooth left ventricular outflow tract** (the aortic vestibule). Blood is ejected through the aortic valve in**to the ascending aorta and then flows throughout** the entire systemic circulation. The left ventricle **pumps blood against the relatively high systemic blood pressure**.

Inflow tract

1 **Left atrioventricular orifice** (*ostium atrioventriculare sinistrum*)
– an opening between the left atrium and the left ventricle covered by the mitral valve
2 **Mitral valve / left atrioventricular valve** (*valva atrioventricularis sinistra / valva mitralis*)
– a valve preventing retrograde flow from the left ventricle to the left atrium
- 2.1 **Anterior cusp** (*cuspis anterior*) – is anchored to the anterior and posterior papillary muscles
- 2.2 **Posterior cusp** (*cuspis posterior*) – is anchored to the posterior and anterior papillary muscles

3 **Papillary muscles** (*musculi papillares*) – valve muscles originating from myocardium and covered with endocardium
– attached to the mitral valve cusps by tendinous cords (*chordae tendineae*)
- 3.1 **Anterior papillary muscle** (*musculus papillaris anterior*) – is attached to the anterior and posterior cusps
- 3.2 **Posterior papillary muscle** (*musculus papillaris posterior*) – is attached to the posterior and anterior cusps

Outflow tract

4 **Aortic vestibule** (*vestibulum aortae*) – the smooth part of the left ventricle below the aortic valve
5 **Aortic orifice** (*ostium aortae*) – the left ventricular opening to the ascending aorta containing the aortic valve
6 **Aortic valve** (*valva aortae*) – is composed of three semilunar cusps
– prevents reverse flow from the aorta to the left ventricle
- 6.1 **Left semilunar cusp** (*valvula semilunaris sinistra*)
  - 6.1.1 **Left (coronary) aortic sinus of Valsalva** (*sinus aortae sinister Valsalvae*)
    – a dilation of the aortic wall behind the left semilunar cusp where the left coronary artery arises
- 6.2 **Right semilunar cusp** (*valvula semilunaris dextra*)
  - 6.2.1 **Right (coronary) aortic sinus of Valsalva** (*sinus aortae dexter Valsalvae*)
    – a dilation of the aortic wall behind the right semilunar cusp where the right coronary artery arises
- 6.3 **Posterior semilunar cusp** (*valvula semilunaris posterior*)
  - 6.3.1 **Posterior (noncoronary) aortic sinus of Valsalva** (*sinus aortae posterior Valsalvae*)

7 **Interventricular septum** (*septum interventriculare*)
- 7.1 **Membranous part** (*pars membranacea*) – part of the cardiac skeleton
  - 7.1.1 **Atrioventricular septum** (*septum atrioventriculare*)
    – part of the membranous part of the interventricular septum overlying the right atrium and thus separating it from the left ventricular outflow tract
- 7.2 **Muscular part** (*pars muscularis*)

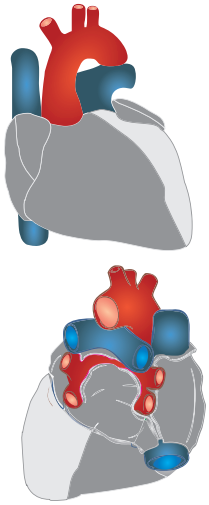

Anterior and posterior views of the heart; left ventricle in bright color

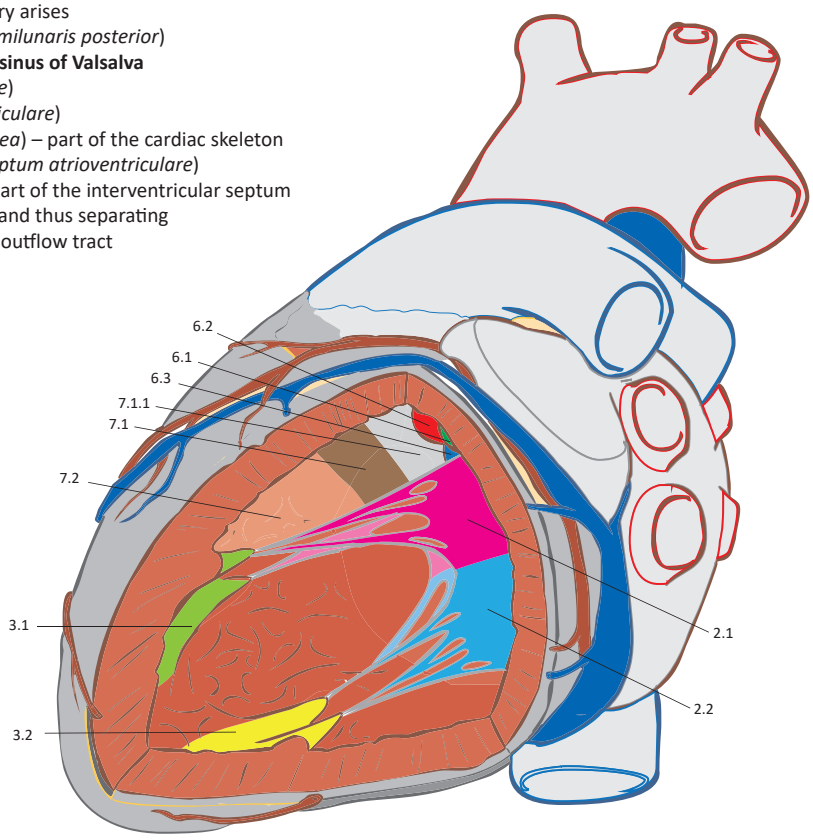

This copy belongs to ali yaghoubi

The valves are fibrous plates separating the atria from the ventricles and the ventricles from the great vessels leaving the heart. **They ensure unidirectional flow of blood**. Characterised by their shape, location, and dynamics, they are **divided into cuspidate and semilunar valves**. **The cuspidate valves** are opened by blood flowing **from the atrium into the ventricle** and are closed during ventricular systole. **The semicircular valves are pushed open as blood flows into the aorta and pulmonary trunk during ventricular systole**. During ventricular diastole blood flows into the heart and the semilunar valves close.

Cuspidate valves

1 **Tricuspidal valve / right atrioventricular valve** (*valva atrioventricularis dextra / valva tricuspidalis*)
– is composed of three cusps, which are attached to papillary muscles by tendinous cords
– separates the right atrium from the right ventricle
- 1.1 **Anterior cusp** (*cuspis anterior*) – is anchored to the anterior and septal papillary muscles by tendinous cords
- 1.2 **Posterior cusp** (*cuspis posterior*) – is anchored to the posterior and septal papillary muscles by tendinous cords
- 1.3 **Septal cusp** (*cuspis septalis*) – is anchored to the anterior, posterior and septal papillary muscles by tendinous cords

– the individual cusps are connected at the commissures
– there are three commisures: anteroseptal, posteroseptal, and anteroposterior

2 **Mitral valve / left atrioventricular valve**
(*valva atrioventricularis sinistra / valva bicuspidalis/mitralis*)
– contains two cusps that are attached to the papillary muscles by tendinous cords
– separates the left atrium and left ventricle
- 2.1 **Anterior cusp** (*cuspis anterior*) – anchored to the anterior and posterior papillary muscles by tendinous cords
- 2.2 **Posterior cusp** (*cuspis posterior*) –anchorded to the posterior and anterior papillary muscles by tendinous cords

– the cusps are connected at the anterolateral and posteromedial commissures

Semilunar valves

3 **Pulmonary valve** (*valva trunci pulmonalis*) – consists of three semilunar-shaped cusps
– is located between the right ventricle and the pulmonary trunk
- 3.1 **Anterior semilunar cusp** (*valvula semilunaris anterior*)
- 3.2 **Right semilunar cusp** (*valvula semilunaris dextra*)
- 3.3 **Left semilunar cusp** (*valvula semilunaris sinistra*)

4 **Aortic valve** (*valva aortae*) – is formed by three semilunar cusps
– is located between the left ventricle and the ascending aorta
- 4.1 **Right semilunar cusp** (*valvula semilunaris dextra*)
  - 4.1.1 **Right aortic sinus of Valsalva** (*sinus aortae dexter*)
    – a widening of the aorta containing the ostium of the right coronary artery
- 4.2 **Left semilunar cusp** (*valvula semilunaris sinistra*)
  - 4.2.1 **Left aortic sinus of Valsalva** (*sinus aortae sinister*)
    – a widening of the aorta containing the ostium of the left coronary artery
- 4.3 **Posterior semilunar cusp** (*valvula semilunaris posterior*)
  - 4.3.1 **Posterior aortic sinus of Valsalva** (*sinus aortae posterior*)

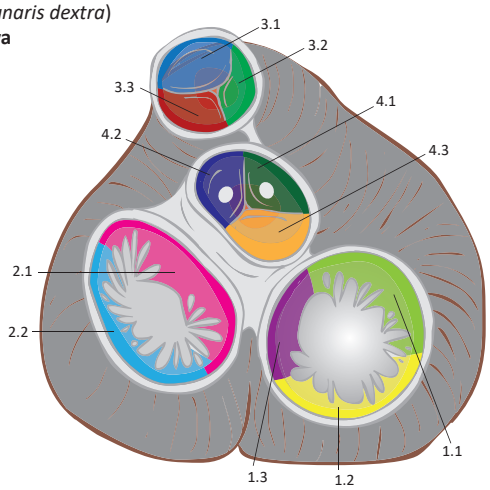

The right and left fibrous rings are oval and flat in comparison to the aortic and pulmonary rings, which are circle and garland-shaped (with three projections).

The tendon of Todaro (*tendo valvulae venae cavae inferioris*) originates in the right fibrous triangle, runs through the myocardium of the posterior wall of the right ventricle and circumscribes the atrioventricular node.

The tendon of infundibulum is tendon connecting the pulmonary ring (ventrally) and aortic ring (dorsally).

The membranous part of the interventricular septum (*pars membranacea septi interventricularis*) is the only part of the cardiac skeleton, which is vertically oriented.

The existence of specialised pathways spreading impulses from the right to the left atrium is disputable. The only exception is the interatrial bundle of Bachmann, which is, most likely, formed by non-pacemaking cardiomyocytes.

The sympathetic system increases the strength and frequency of myocardial contractions and the conductivity and excitability of the myocardium (positive inotropic, chronotropic, dromotropic, and bathmotropic effects, respectively).

The parasympathetic system decreases the strength and frequency of myocardial contractions and the conductivity and excitability of the myocardium (negative inotropic, chronotropic, dromotropic, and bathmotropic effects, respectively).

Clinical notes

A heart block is a block in the conducting system of the heart, which prevents the propagation of action potential through certain parts of the heart. Heart blocks are differentiated by their ECG profiles and clinical manifestations.

Sick sinus syndrome is a disorder of the sinu-atrial node (the main pacemarker of the heart). Many different patterns of the heart rhythm are typical for this syndrome.

Atrioventricular blockages represent affections of the atrioventricular communication and action potential transmission. Three stages of AV block are distinguished: 1st, 2nd and 3rd degree block

Types of bundle branch block: right block, left anterior hemiblock and left posterior hemiblock.

The **cardiac skeleton** is a fibrous structure that **surrounds the heart valves** and serves as an **attachment for the myocardial muscle**. It is a poor conductor of electricity and thus ensures that electrical impulses pass from the atria to the ventricles only through the atrioventricular bundle. The components of the cardiac skeleton are the **fibrous rings of the valves**, **the fibrous triangles, the membranous part of the interventricular septum**, which is located perpendicularly to the plane of the valves and the **tendon of the infundibulum**.

Fibrous rings

- 1 **Right fibrous ring** (*anulus fibrosus dexter*) – the fibrous ring of the tricuspid valve
- 2 **Left fibrous ring** (*anulus fibrosus sinister*) – the fibrous ring of the mitral valve
- 3 **Aortic ring** (*anulus aorticus*) – the fibrous ring of the aorta
- 4 **Pulmonary ring** (*anulus trunci pulmonalis*) – the fibrous ring of the pulmonary valve

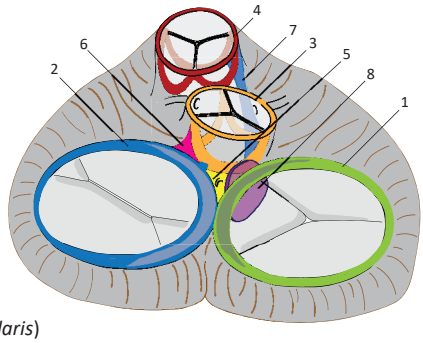

Other components

- 5 **Right fibrous triangle** (*trigonum fibrosum dextrum*) – situated between the right, left, and aortic fibrous rings, the atrioventricular bundle passes through this triangle
- 6 **Left fibrous triangle** (*trigonum fibrosum sinistrum*) – situated between the left and aortic fibrous rings
- 7 **Tendon of infundibulum** (*tendo infundibuli*)
- 8 **Membranous part of interventricular septum** (*pars membranacea septi interventricularis*)

3.7 Conducting system of the heart – Complexus stimulans cordis / systema conducens cordis

The heart has the capacity to **generate and conduct electric impulses**. These impulses are **produced in the sinu-atrial node** in the right atrium. They pass through the atria to the **atrioventricular node** and then pass through the **bundle of His** to reach the ventricles. After passing through the atrioventricular septum, the bundle of His divides into the **right and left bundles of Tawara,** which carry the impulses down the interventricular septum and into the left and right ventricles. The final branches of the cardiac conducting system are the **subendocardial branches of Purkinje**, which spread the impulses throughout the ventricular muscle.

Parts

- 1 **Sinu-atrial node of Keith-Flack / SA node** *(nodus sinuatrialis)*
  – is located in the right atrium between the superior vena cava and the right auricle
  – the main pacemaker of the heart, action potentials spread through atrial myocardium and interatrial connections to the AV node
- 2 **Atrioventricular node of Aschoff-Tawara / AV node** *(nodus atrioventricularis)* – is located in the right atrium within the triangle of Koch
  – is responsible for slowing SA impulses and passing transmission onto the atrioventricular fascicle
- 3 **Atrioventricular fascicle of Kent-Gaskell-His / Bundle of His** *(fasciculus atroventricularis)* – the continuation of the AV node, runs through the right fibrous triangle into the posterior part of the membranous part of the interventricular septum, then continues caudally and enters the muscular part of the interventricular septum, where it divides into the bundles of Tawara
- 4 **Bundles of Tawara** *(crus dextrum et sinistrum fasciculi atroventricularis)* – run through the interventricular septum to the heart apex where they divides into the subendocardial branches, the right bundle runs through the septomarginal trabecula of the right ventricle
  – the left bundle divides into an anterior and a posterior branch (*limbus anterior et posterior*)
- 5 **Subendocardial branches of Purkinje** *(rami subendocardiales)* – spread from the apex of the heart in the subendocardial layer to all the cardiac muscle cells of the ventricles

6 **Interconnections between the SA node and left atrium**
- 6.1 **Interatrial fascicle of Bachmann** *(fasciculus interatrialis)*

- 7 **Accessory interconnections between the SA node and AV node**

7.1 **Anterior internodal bundle of James**
7.2 **Middle internodal bundle of Wenckebach**
7.3 **Posterior internodal bundle of Thorel**

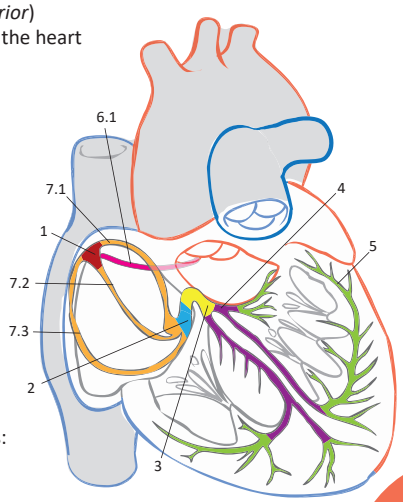

Autonomic innervation of the heart

Sympathetic system – cardiac nerves (*nervi cardiaci*)
– arise from all three cervical and a few thoracic sympathetic ganglia
Parasympathetic system – cardiac branches (*rami cardiaci*) – arise from the vagus nerve (n. X)
– fibres from the right vagus nerve primarily enter the SA node
– fibres from the left vagus nerve primarily enter the AV node
The cardiac plexus is a **mixed sympathetic and parasympathetic plexus** divided into two parts:
– the superficial cardiac plexus is located between the aorta and the pulmonary trunk
– the deep cardiac plexus is located between the aorta and the tracheal bifurcation

This copy belongs to ali yaghoubi

The **foetal circulation** is derived from the maternal circulation, hence the term **"foetoplacental" circulation**. In the placenta, maternal blood does not directly mix with foetal blood; it is separated from it by the **placental barrier**. Oxygen and nutrients are exchanged across this barrier. **Oxygenated blood from the placenta flows through the single umbilical vein to the foetus**. Less oxygenated blood from the aorta flows through the common iliac arteries, internal iliac arteries and the **two umbilical arteries** to the placenta for oxygenation. **Foetal shunts** maintain the highest possible oxygen concentration for the brain and other organs.

Basic pathway of the foetal circulation

- **Deoxygented blood**
- **Oxygenated blood:** placenta → umbilical vein → ductus venosus → inferior vena cava →
- **Mixed blood (high oxygen concentration):** inferior vena cava → right atrium → foramen ovale → left atrium → left ventricle →
- **Mixed blood (low oxygen concentration):** descending aorta → common iliac arteries → internal iliac arteries → umbilical arteries → placenta

Foetal shunts

- 1 **Ductus venosus / Arantius' duct**
  - **a shunt between the umbilical vein and the inferior vena cava**, bypassing the liver
  - despite the fact that the liver is an important organ during development, it is necessary to keep blood oxygenated to the greatest possible extent for the brain, which is why the liver circulation is bypassed
  - postnatally, the remnant of the ductus venosus is the ligamentum venosum, located on the visceral surface of the liver in the fissure for the ligamentum venosum
- 2 **Foramen ovale**
  - **a shunt between the right and left atria**, bypassing the pulmonary circulation
  - the pulmonary circulation is minimal during prenatal development, so most of the oxygenated blood is directed to the brain
  - postnatally, it is closed and the only remnant left is the oval fossa in the right atrium and the valve of the foramen ovale in the left atrium
- 3 **Ductus arteriosus / ductus Botalli**
  - **a shunt between the pulmonary trunk and the initial segment of the descending aorta,** bypassing the pulmonary circulation and the aortic arch
  - deoxygenated blood from the head, neck and upper limbs returning via the superior vena cava to the heart does not flow to the lungs as they are not ventilated
  - instead this blood flows through the ductus arteriosus to the initial segment of the descending aorta and its branches to the placenta to be oxygenated
  - due to this shunt, blood from the right ventricle does not mix with highly oxygenated blood for the head and brain
  - the ductus ateriosus closes postnatally forming the ligamentum arteriosum

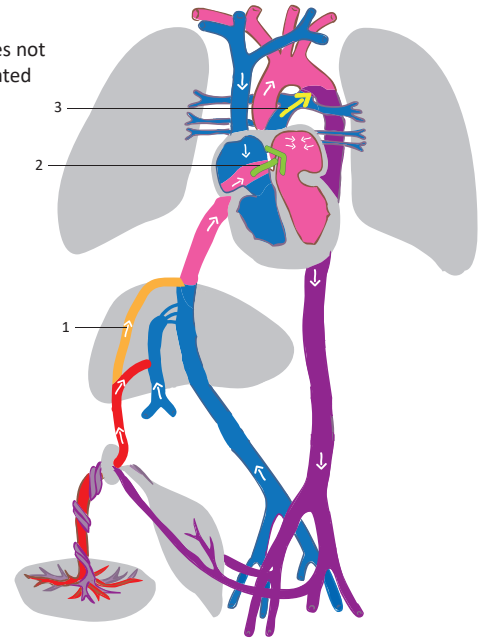

The foramen ovale is a unidirectional blood shunt covered by a valve composed of the septum primum and septum secundum. After the first few postnatal breaths, the left atrial pressure abruptly increases, which pushes the septum primum onto the secundum closing the foramen ovale. In 20–25 % of people, the closure is incomplete and blood keeps shunting through an opening in the interatrial septum (patent foramen ovale, FOA, *foramen ovale patens/pervium*). Under physiological conditions, this shunt causes no clinical symptoms unless haemodynamically significant. In such case, the clinical situation is described as a persistent foramen ovale (*foramen ovale apertum/persitents*).

Right and left coronary artery dominance depends on whether the posterior interventricular branch originates from the right, or left coronary artery, respectively. In one third of cases, both arteries equally supply the posterior interventricular branch. In 50 % of cases, the right coronary artery is dominant with a thick right posterolateral branch.

The coronary arteries, in the subepicardial layer on the heart's surface, have a tortuous course. This allows them to elongate and shorten as the heart contracts and dilates.

Lymph drainage from the heart goes from the left atrium and ventricle via the left lymphatic trunk to the inferior tracheobronchial nodes (and then to the right lymphatic duct). From the right atrium and ventricle, lymphatic drainage is directed through the right lymphatic trunk to the anterior mediastinal nodes (and then to the thoracic duct).

The oblique vein of the left atrium of Marshal (*v. obliqua atrii sinistri*) is a remnant of the left superior vena cava.

Clinical notes

Ischemic heart disease is the result of coronary artery disease on the heart. Coronary artery disease results from atherosclerosis obstructing the lumen of the coronary arteries. The extent of the obstruction leads to variable range of clinical entities: stable/unstable angina, myocardial infarction, sudden cardiac death and heart failure.

Angina pectoris is a form of ischaemic heart disease that classically presents with chest pain or discomfort.

The coronary arteries supply myocardium with oxygenated blood during diastole of the ventricles. They originate in the **right and left aortic sinuses of Valsalva** in the aortic bulb. Both coronary arteries pass in the coronary sulcus. **The main stem of the left coronary artery is short and divides early** in its course **into the anterior interventricular branch,** running on the anterior surface of the heart, **and the circumflex branch,** running posteriorly and to the left side of the heart. **The right coronary artery** passes across the right heart border and **terminates as the posterior interventricular branch**.

- 1 **Right coronary artery** (RCA) (*arteria coronaria dextra, ACD*)
  - – arises from the right aortic sinus
  - – runs in the coronary sulcus between the right auricle and the right ventricle
  - 1.1 **Conus branch** (*ramus coni arteriosi*) – the first branch
    - – supplies the right ventricular outflow tract
  - 1.2 **Sinu-atrial nodal branch** (*ramus nodi sinuatrialis*) – supplies the SA node
  - 1.3 **Atrial branches** (*rami atriales*)
    - – supply the right atrium and part of the left atrium
  - 1.4 **Ventricular branches** (*rami ventriculares*)
    - – small branches supplying the anterior and posterior walls of the right ventricle
  - 1.5 **Right marginal branch** (*ramus marginalis dexter, RMD*)
    - – a large branch for the right ventricle, passes on the right heart border
  - 1.6 **Posterior interventricular branch**
    (*ramus interventricularis posterior, RIP, RIVP*)
    - – the first terminal branch, runs in the posterior interventricular sulcus
  - 1.7 **Right posterolateral branch** (*ramus posterolateralis dexter, RPLD*)
    - – the second terminal branch, supplies the right part of the posterior wall of the left ventricle
- 2 **Left coronary artery** (LCA) (*arteria coronaria sinistra, ACS*) – a 1–2cm long stem that arises from the left aortic sinus and divides into two main branches: circumflex branch and anterior interventricular branch, intermediate branch additively
  - 2.1 **Anterior interventricular branch / left anterior descending artery** (LAD)
    (*ramus interventricularis anterior, RIA*) – descends in the anterior interventricular sulcus to the apex of the heart and supplies the left ventricle
    - 2.1.1 **Conus branch** (*ramus coni arteriosi*) – the first branch
      - – supplies the left ventricular outflow tract
    - 2.1.2 **Diagonal branch(es)** (*ramus diagonalis, RD*) – the thickest branch(es)
      - – supply the anterior wall of the left ventricle
      - – run diagonally across the ventricle towards the apex of the heart
    - 2.1.3 **Anterior ventricular branches** (*rami ventriculares anteriores*)
      - – supply the left ventricle
    - 2.1.4 **Interventricular septal branches** (*rami interventriculares septales)*
  - 2.2 **Circumflex branch** (*ramus circumflexus*, *RCX*)
    - – the second branch of the left coronary artery
    - – runs in the coronary sulcus between the left auricle and the left ventricle
    - – supplies the left atrium and ventricle
    - 2.2.1 **Atrioventricular branches** (*rami atrioventriculares*)
      - – supplies the left atrium and ventricle
    - 2.2.2 **Left marginal branch** (*ramus marginalis sinister*, *RMS*)
      - – supplies the lateral wall of the left ventricle
    - 2.2.3 **Atrial branches** (*rami atriales*) – supplies the left atrium
    - 2.3.4 **Left posterolateral branch**
      (*ramus posterolateralis sinister*, *RPLS*)
      - – the terminal branch on the left part of the posterior wall of the left ventricle
  - 2.3 **Intermediate branch** (*ramus intermedius*, *RIM*)
    - – a variable branch (25 %) originating from the LCA

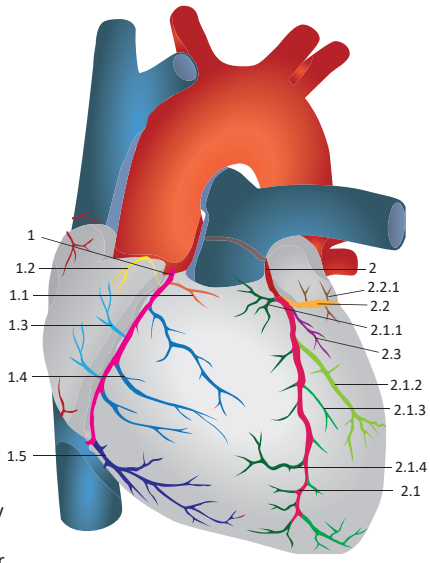

Anterior view of the heart

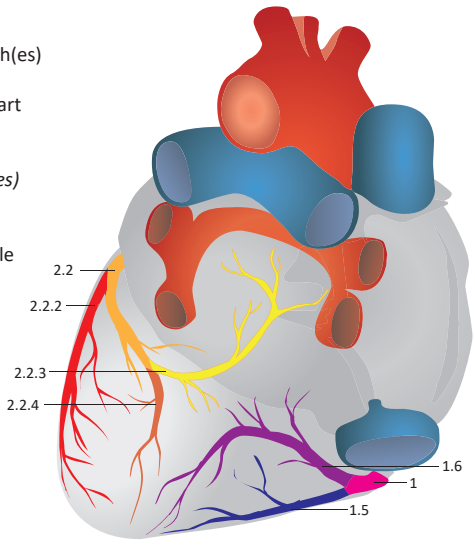

Posterior view of the heart

Distribution of the blood supply to the heart

- 1 **Right coronary artery** – supplies the right atrium and ventricle, posterior 1/3 of the interventricular septum, and the conducting system of the heart to the level of the proximal part of the bundle branches of Tawara
- 2 **Left coronary artery** – supplies the left atrium and ventricle and the anterior 2/3 of the interventricular septum
- 3 **Common supply from both arteries** – right anterior papillary muscle and left posterior papillary muscle

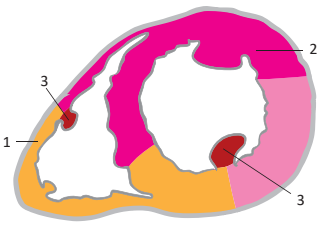

Transverse section of the heart at the level of the ventricles; inferior view

This copy belongs to ali yaghoubi

Venous blood is drained from the heart wall in three paths. The main venous drainage is via the coronary sinus, which opens into the right atrium. The anterior veins of the right ventricle drain blood from the right ventricular wall directly into the right atrium. **The Thebesian veins** direct blood individually into all four chambers of the heart.

- 1 **Coronary sinus** (*sinus coronarius*)
  - – is located in the coronary sulcus on the inferior wall of the heart
  - – collects blood from its tributaries and directs it to the right atrium
  - 1.1 **Great cardiac vein** (*vena cardiaca/cordis magna*)
    - – begins in the anterior interventricular sulcus and collects blood from the area supplied by the left coronary artery
    - 1.1.1 **Posterior vein of left ventricle** (*vena posterior ventriculi sinistri*)
  - 1.2 **Middle cardiac vein** (*vena cardiaca/cordis media*)
    - – courses through the posterior interventricular sulcus and drains blood from the area supplied by the posterior interventricular branch
  - 1.3 **Small cardiac vein** (*vena cardiaca/cordis parva*)
    - – usually a tiny vein draining the area of the right heart border
- 2 **Anterior veins of right ventricle** (*venae ventriculi dextri anteriores*)

3 **Small cardiac veins / Thebesian veins** (*venae cardiacae/cordis minimae*)

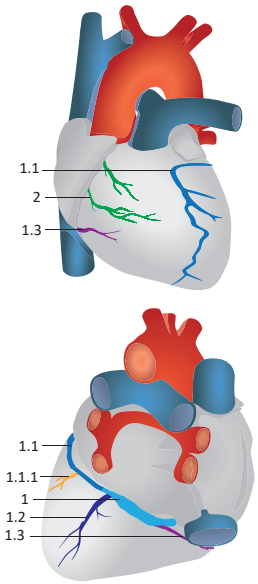

Anterior and posterior view of the heart

It is estimated that 40 % of venous blood from the heart is drained via the small cardiac veins and the anterior veins of the right ventricle (*vv. ventriculi dextri anteriores*).

The right and left oblique projections can be used to compliment the usual AP projection as part of the X-ray study of the heart.

Aortic arch variations:
- – vertebral artery (*a. vertebralis*) (3 %)
- – thyroid ima artery (*a. thyroidea ima*) (2 %)
- – arteria lusoria (*a. lusoria*) (1.5 %)
- – right aortic arch (*arcus aortae dexter*) (0.1 %)

The arteria lusoria is a variation of the right subclavian artery originating as the last branch of the aortic arch (after the origin of the left subclavian artery). Due to its course (posterior to the oesophagus), it may compress the oesophagus, which leads to problems with swallowing (dysphagia lusoria).

Clinical notes

Myocardial infarction is caused by an obstruction of blood flow in the coronary artery (usually by a thrombus) leading to ischemia and necrosis of the given segment of myocardium. Acute chest pain is the typical presenting symptom. However, it may be absent in some cases.

In myocardial infarction, pain radiates to the Head's zones of the T1–T4 spinal cord segments (the thoracic wall and the left side of the upper limb, including the little finger).

Acute treatment of myocardial infarction comprises:
PCI (percutaneous coronary intervention) – a dilation of the narrowed arterial segment by a catheter with an inflatable balloon at its tip, inserted via the femoral or radial artery, followed by placement of a bare metal (or drug-eluting) stent (a circular, net-like prosthesis used to mechanically dilate the artery).
CABG (coronary artery bypass grafting) – vascular bypass of a narrowed arterial segment using an autologous venous (great saphenous vein) or arterial (internal thoracic or radial artery) graft.
Thrombolysis – is indicated when PCI is not available.

Transoesophageal echocardiography: as the left atrium lies right in front of the oesophagus, an ECHO probe can be inserted into the oesophagus to give a better view of the left atrium than a transthoracic probe.

X-Ray view

Anteroposterior (AP) projection

Right margin
- 1 Right brachiocephalic vein
- 2 Superior vena cava
- 3 Right atrial margin
- 4 Inferior vena cava (in inspiration)

Left margin
- 5 Ascending aorta (posterior wall)
- 6 Left pulmonary artery
- 7 Left auricle
- 8 Left border of left ventricle

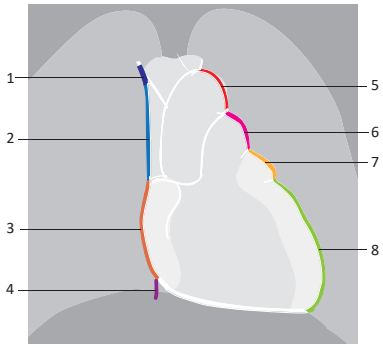

Anteroposterior projection, X-Ray

Echocardiography (ECHO)

– a non-invasive investigation of the heart using ultrasound
– the transthoracic projection through the anterior thoracic wall is the most common projection

Four-chamber projection
– a probe facing the apex of the heart can view the following structures simultaneously:
- 1 **Right atrium (with tricuspid valve)**
- 2 **Right ventricle**
- 3 **Left atrium (with mitral valve)**
- 4 **Left ventricle**
- 5 **Interatrial septum**
- 6 **Atrioventricular septum**
- 7 **Interventricular septum**

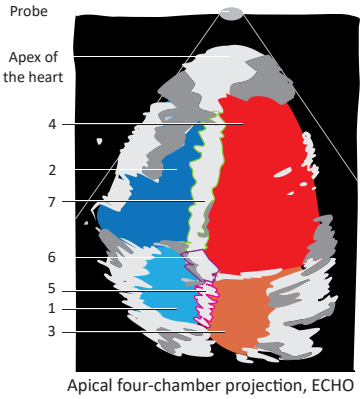

Apical four-chamber projection, ECHO

The aorta is the **longest** and **largest artery** of the human body. **The is an elastic artery**, which helps it maintain a **continuous flow of blood**. It originates in the left ventricle. Near its origin**, it gives off the coronary arteries** that supply the heart. The aorta then **continues into the cranially convex aortic arch**, which gives off branches supplying the head, neck, and upper extremities. The aorta then **descends in the thoracic cavity** and gives off branches for the thoracic organs, thoracic wall and back. It then passes through the diaphragm in front of the vertebral column. **The last part of the aorta** runs in the abdominal cavity; its branches supply the abdominal organs, abdominal wall, and back. Finally, **the aorta bifurcates into the right and left common iliac arteries,** which supply the pelvis and lower extremities.

- 1 **Ascending aorta** (*aorta ascendens*) – T4–T3
  - arises from the left ventricle and continues as the aortic arch in the superior mediastinum
- 2 **Aortic arch** (*arcus aortae*) – to the top of T2
  - passes dorsally and to the left in the superior mediastinum

3 **Descending aorta** (*aorta descendens*) – T3–L4
- 3.1 **Thoracic aorta** (*aorta thoracica*) – T3–T12
  - passes on the left side of the vertebral column and then in front of vertebrae in the inferior mediastinum
  - passes through the aortic hiatus of the diaphragm at the level of T12 and changes here into the abdominal aorta
- 3.2 **Abdominal aorta** (*aorta abdominalis*) – T12–L4
  - passes in front of the vertebral column inside the retroperitoneal space
  - bifurcates into the right and left common iliac arteries at the level of L4

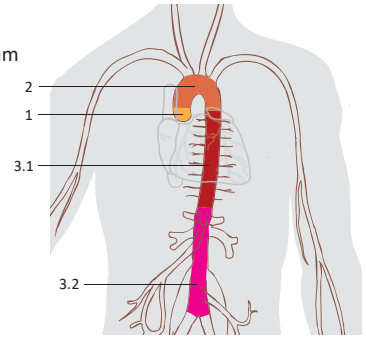

4.2 **Ascending aorta and aortic arch** – Aorta ascendens et arcus aortae

Blood flows **from the left ventricle** through the aortic valve **into the ascending aorta**. **The ascending aorta gives off the right and left coronary arteries in the aortic bulb**. It then continues as **the aortic arch,** which gives off branches supplying the head, neck, and upper extremities. The aortic arch turns dorsally and to the left, approaches the vertebral column and continues as **the descending aorta**.

Ascending aorta (*aorta ascendens*)

- 1 **Aortic bulb** (*bulbus aortae*) – the enlarged initial segment of the aorta
  - contains the aortic sinuses of Valsalva (*sinus aortae*) from which the coronary arteries arise
  - 1.1 **Right coronary artery** (*arteria coronaria dextra*) – arises from the right aortic sinus and supplies the right atrium and ventricle, posterior third of the interventricular septum, anterior papillary muscle of the right ventricle and posterior papillary muscle of the left ventricle
  - 1.2 **Left coronary artery** (*arteria coronaria sinistra*) – arises from the left aortic sinus and supplies the left atrium and ventricle, anterior two thirds of the interventricular septum, anterior papillary muscle of the right ventricle and posterior papillary muscle of the left ventricle

Aortic arch (*arcus aortae*)

- 2 **Brachiocephalic trunk** (*truncus brachiocephalicus*) – the first branch
  - an unpaired short artery on the right
  - originates behind the manubrium of the sternum and passes behind the right sternoclavicular joint where it divides into the right common carotid artery and the right subclavian artery
  - 2.1 **Right subclavian artery** (*arteria subclavia dextra*)
    - arises near the 1st rib on the right and passes into the scalene fissure
    - its branches supply the right upper extremity, part of the neck, head, brain, and the superior part of the thorax with part of the back
  - 2.2 **Right common carotid artery** (*arteria carotis communis dextra*)
    - arises near the head of the 1st rib on the right and passes through the visceral space of the neck
    - its branches supply part of the neck, head, and brain
- 3 **Left common carotid artery** (*arteria carotis communis sinistra*)
  - originates near the head of the 1st rib and passes through the visceral space of the neck
  - its branches supply part of the neck, head, and brain
- 4 **Left subclavian artery** (*arteria subclavia sinistra)*
  - arises near the 1st rib on the left and passes into the scalene fissure
  - its branches supply the left upper extremity, head, brain, part of the neck and the superior part of the thorax and back

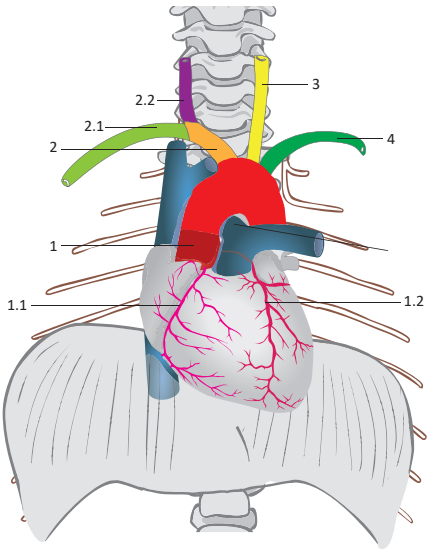

This copy belongs to ali yaghoubi

The right common carotid artery arises with the right subclavian artery from the brachiocephalic trunk. **The left common carotid artery arises directly from the aortic arch**. Each common carotid artery passes cranially along the trachea and bifurcates into the internal and external carotid arteries **within the carotid triangle** at the level of the superior margin of the thyroid cartilage (at the level of C4). **The common carotid artery** gives off no other branches as it **travels with the internal jugular vein, the vagus nerve** and the superior branch of the deep cervical ansa in the fibrous carotid sheath (*vagina carotica*).

- 1 **Common carotid artery** (*arteria carotis communis*)
  - ascends along the trachea
  - bifurcates within the carotid triangle
- 2 **External carotid artery** (*arteria carotis externa*)
  - passes ventromedially
  - has eight main branches within the neck and head
- 3 **Internal carotid artery** (*arteria carotis interna*)
  - passes dorsolaterally giving off no branches within the neck
  - enters the cranium to give off branches supplying the brain and eyeball

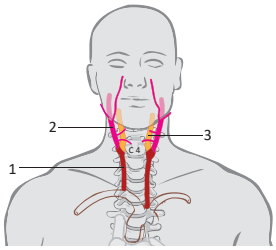

4.4 External carotid artery – Arteria carotis externa

The external carotid artery supplies the head, the majority of the organs and muscles of the **anterior part of the neck** and some of the **nuchal muscles**. It ascends through the carotid triangle, courses behind the **stylohyoid** and **posterior belly of the digastric** and pierces the **styloid septum** to enter the **prestyloid space**. It then enters the **retromandibular fossa** close to the angle of the mandible. It bifurcates into its terminal branches close to the neck of the mandible.

Ventral branches

- 1 **Superior thyroid artery** (*arteria thyroidea superior*)
  - the first branch of the external carotid artery
  - descends to the thyroid gland
- 2 **Lingual artery** (*arteria lingualis*)
  - the second branch
  - ascends to the tongue
- 3 **Facial artery** (*arteria facialis*) – the third branch
  - ascends across the face towards the orbit

Medial branches

- 4 **Ascending pharyngeal artery** (*arteria pharyngea ascendens*)
  - the only medial branch,
  - supplies the pharynx, middle ear, and dura mater

Dorsal branches

- 5 **Occipital artery** (*arteria occipitalis*)
  - passes to and supplies the occiput
- 6 **Posterior auricular artery** (*arteria auricularis posterior*)
  - passes right behind the auricle supplies the mastoid air cells, parotid gland and middle ear,

Terminal branches

- 7 **Superficial temporal artery** (*arteria temporalis superficialis*)
  - passes to and supplies the temple, vertex, and forehead
- 8 **Maxillary artery** (*arteria maxillaris*)
  - passes through the infratemporal fossa and the pterygopalatine fossa
  - supplies the masticatory muscles, dura mater, mandible and lower teeth, maxilla and upper teeth, middle ear, nasopharynx and palate and deep facial layers

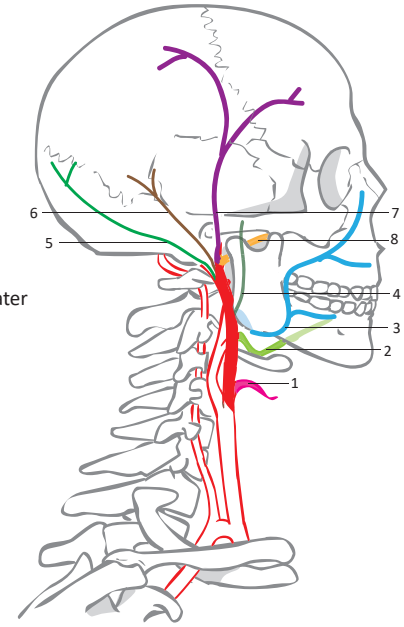

The carotid sinus (*sinus caroticus*) is an enlargement located at either the bifurcation of the common carotid artery or at the beginning of the internal carotid artery. Free nerve endings are located in the wall of the carotid sinus, which monitor blood pressure. Compression of the wall can cause a reflex decrease in blood pressure.

The carotid body (*glomus caroticum*) is located in the carotid bifurcation. It is a chemoreceptor, which detects changes in the internal environment (mainly partial pressure of oxygen, concentration of carbon dioxide and changes in pH).

The facial and lingual artery can arise from a common origin called the linguofacial trunk (*truncus linguofacialis*). This is important to known when performing catheterisation.

The sternocleidomastoid artery can arise directly from the external carotid artery as its lateral branch in about 25 % of cases.

Internal carotid artery page 472.

Clinical notes

The common carotid artery can be examined with a stethoscope. Such an examination is called auscultation and allows the detection of an abnormal sound called a bruit, which indicates the presence of stenosis. The bruit manifests as a regular rustling sound during each heart contraction and can indicate stenosis of the artery even when the pulse is normally palpable.

Carotid ultrasonography is an ultrasonographic procedure that shows the quality of blood flow within the carotid arteries. It measures the luminal diameter (6–7 mm), blood flow and the intima-media thickness (IMT), which is a marker of atherosclerosis.

Carotid stenosis is, in the majority of cases, caused by an atherosclerotic plaque. A piece of the plaque can break off and travel through the circulation to the blood vessels in the brain. The pieces can lodge in the vessel wall and restrict blood flow, causing a thrombembolic stroke.

The carotid tubercle / tubercle of Chassaignac is a synonym for the anterior tubercle of the transverse process of the sixth cervical vertebra. The common carotid artery can be compressed against it.

Superior thyroid artery (*arteria thyroidea superior*)

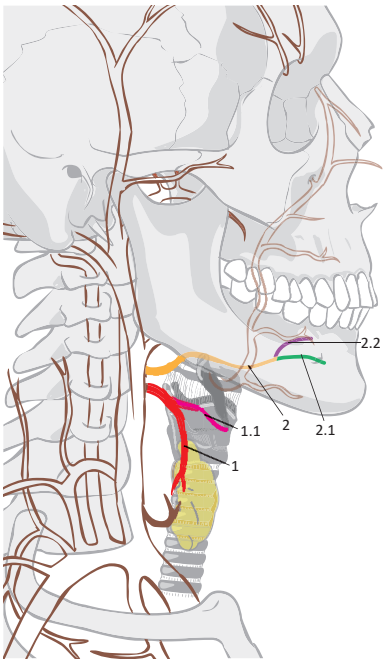

Course

– the first branch of the external carotid artery
– passes ventrally then descends to the anterior surface of the thyroid gland

- 1 **Superior thyroid artery** (*arteria thyroidea superior*)
  - 1.1 **Superior laryngeal artery** (*arteria laryngea superior*)
    – supplies the larynx and accompanies the superior laryngeal nerve as it passes through the thyrohyoid membrane
  - 1.2 **Anterior, posterior, and lateral branches** (*ramus anterior, posterior et lateralis*) – supply the thyroid gland
  - 1.3 **Infrahyoid, sternocleidomastoid, and cricothyroid branches** (*ramus infrahyoideus, sternocleidomastoideus et cricothyroideus*)
    – supply the sternocleidomastoid and infrahyoid muscles

Lingual artery (*arteria lingualis*)

Course

– arises from external carotid artery at the level of the lesser horn of the hyoid bone
– passes through the triangle of Pirogov and the angle of Béclard
– then it runs inferiorly to the hyoglossus passing through the paralingual canal to the tongue

- 2 **Lingual artery**
  - 2.1 **Sublingual artery** (*arteria sublingualis*)
    – supplies the sublingual gland and the floor of the oral cavity
    – arises from the lingual artery before entering the tongue
    – passes along the floor of the oral cavity below the sublingual gland
  - 2.2 **Deep lingual artery** (*arteria profunda linguae*) – passes inside the tongue between the genioglossus and the inferior longitudinal muscle to the apex of the tongue
  - 2.3 **Suprahyoid branch and dorsal lingual branches** (*ramus suprahyoideus et rami dorsales linguae*) – supply the oral part of the pharynx

Facial artery (*arteria facialis*)

Course

– the third branch from the external carotid artery, passes through the submandibular triangle to the ramus of the mandible
– then it passes behind (medially to) the stylohyoid and posterior belly of the digastric and either through or under the submandibular gland (the facial vein passes superficially to both the gland and muscles)
– reaches the face along the anterior margin of the masseter and has a tortuous course along the oral and nasal angles
– its terminal branch, the angular artery, ascends to the medial margin of the orbit where it anastomoses with the branches of the ophthalmic and infraorbital arteries

Branches and areas supplied

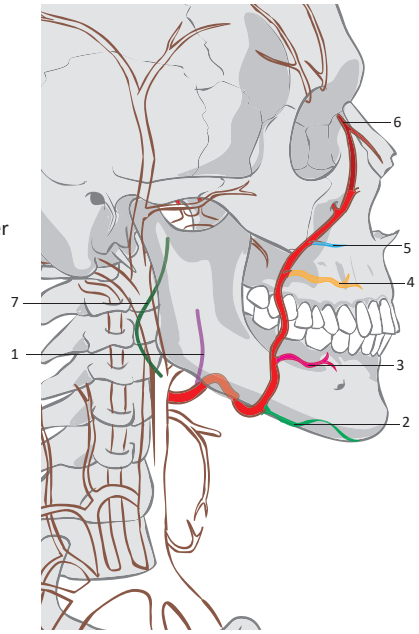

- 1 **Ascending palatine artery** (*arteria palatina ascendens*)
  – supplies the isthmus of the fauces, pharynx, and palate
  – passes cranially along the pharyngeal wall within the prestyloid space
- 2 **Submental artery** (*arteria submentalis*) – supplies the suprahyoid muscles
  – passes along the inferior surface of the mylohyoid
- 3 **Inferior labial branch** (*arteria labialis inferior*) – supplies the lower lip, passes under the orbicularis oris and anastomoses with the contralateral inferior labial branch
- 4 **Superior labial branch** (*arteria labialis superior*) – supplies the upper lip, passes under the orbicularis oris and anastomoses with the contralateral superior labial branch
- 5 **Lateral nasal branch** (*ramus lateralis nasi*) – supplies the nasal wing
- 6 **Angular artery** (*arteria angularis*) – supplies the medial angle of the eye
  – passes along the nasal wing to the medial angle of the eye

Ascending pharyngeal artery (*arteria pharyngea ascendens*)

Course

– passes medially, between the external and internal carotid arteries
– its branches feed the pharyngeal wall, cranial base, tympanic cavity, and dura mater

- 7 **Ascending pharyngeal artery**
  - 7.1 **Pharyngeal branches** (*rami pharyngeales*) – supply the pharyngeal wall
  - 7.2 **Inferior tympanic artery** (*arteria tympanica inferior*)
    – passes through the tympanic canaliculus to supply the tympanic cavity
  - 7.3 **Posterior meningeal artery** (*arteria meningea posterior*)
    – passes through the jugular foramen into the posterior cranial fossa

This copy belongs to ali yaghoubi

The occipital artery is the first dorsal branch of the external carotid artery. It supplies the external soft tissue of the occipital region and the nuchal muscles. **The posterior auricular artery is the second dorsal branch**. It supplies the auricle, mastoid cells, and part of the parotid gland.

Occipital artery (*arteria occipitalis*)

Course

– passes along the posterior margin of the posterior belly of the digastric to the base of the skull behind the mastoid process where it runs in the shallow occipital groove and enters the external soft tissue of the skull

- 1 **Occipital artery**
  - 1.1 **Sternocleidomastoid branches** (*rami sternocleidomastoidei*)
    – supply the sternocleidomastoid
  - 1.2 **Glandular branches** (*rami glandulares*) – supply the parotid gland
  - 1.3 **Auricular branch** (*ramus auricularis*)
    – supplies the posterior and medial surface of the auricle

Posterior auricular artery (*arteria auricularis posterior*)

Course

– passes along the posterior belly of the digastric behind the auricle and in front of the mastoid process

- 2 **Posterior auricular artery**
  - 2.1 **Parotid branch** (*ramus parotideus*)
    – supplies the parotid gland
  - 2.2 **Auricular branch** (*ramus auricularis*
    – supplies the auricle
  - 2.3 **Stylomastoid artery** (*arteria stylomastoidea*)
    – passes through the stylomastoid foramen into the facial canal
    - 2.3.1 **Posterior tympanic artery** (*arteria tympanica posterior*)
      – passes through the canaliculus for the chorda tympani and supplies the tympanic cavity

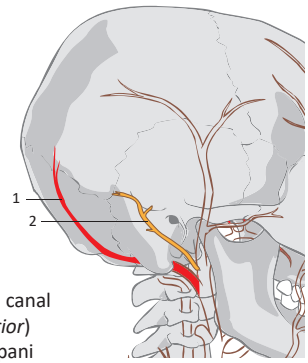

4.4.3 Superficial temporal artery – Arteria temporalis superficialis

The superficial temporal artery is one of the two terminal branches of the external carotid artery. It supplies **supplies the parotid gland, auricle, temporal muscle and external soft tissue of the skull within the temporal and zygomatico-orbital regions**.

Course

– ascends behind the temporomandibular joint through the parotid gland, then it crosses the zygomatic arch, and in front of the auricle it gives off branches that travel into the frontal, temporal, and parietal regions

Branches and areas supplied

- 1 **Transverse facial artery** (*arteria transversa faciei*)
  – supplies the face, running along the parotid duct
- 2 **Frontal branch** (*ramus frontalis*) – supplies the external soft tissue of the skull in the frontal region
- 3 **Parietal branch** (*ramus parietalis*) – supplies the external soft tissue of the skull in the parietal region
- 4 **Parotid branches** (*rami parotidei*)
  – supply the parotid gland
- 5 **Anterior auricular branches** (*rami auriculares anteriores*)
  – supply the temporomandibular joint and the lateral surface of the external acoustic meatus
- 6 **Zygomatico-orbital artery** (*arteria zygomaticoorbitalis*)
  – passes along the zygomatic arch to the lateral angle of the eye
- 7 **Middle temporal artery** (*arteria temporalis media*)
  – perforates the temporal fascia, supplies the temporalis and ascends along the squamous part of the temporal bone in a shallow groove for the middle temporal artery

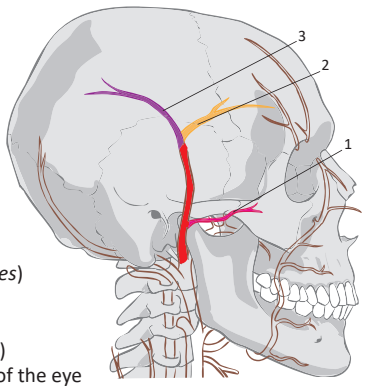

The stapedial branch of the stylomastoid artery is a small artery, which is an embryological remnant of the main artery of the second pharyngeal arch.

Other branches of the maxillary artery:

1. **Pterygomeningeal artery** (*a. pterygomeningea*) is an accessory artery supplying the pterygoids and the middle cranial fossa, branching from the pterygoid part of the maxillary artery.
2. **Middle superior alveolar artery** (*a. alveolaris superior media*), vein and nerve are variable structures which leave the infra-orbital groove and descend in the lateral wall of the maxillary sinus.
3. **Pharyngeal branch** (*r. pharyngeus*) is a smaller branch from either the pterygoid part of the maxillary artery or the artery of the pterygoid canal, which runs dorsally through the palatovaginal canal to the nasopharynx.

The right and left superior labial branches of the facial artery anastomose and form an arterial circle within the area of the upper lip. Similarly, the inferior labial branches form an arterial circle within the area of the lower lip.

Clinical notes

The facial artery is palpable where it crosses the margin of the mandible in front of the insertion of the masseter. This is a pressure point used to stop arterial bleeding.

The superficial temporal artery is palpable in front of the auricle and above the temporomandibular joint. The most common disease affecting this artery is a type of arteritis called Horton's disease or temporal arteritis. This disease manifests as a red painful line over the course of the superficial temporal artery.

The sphenopalatine artery is often responsible for nasal bleeding (epistaxis). It can be occluded with electrocautery or embolisation.

Electrocautery refers to a process that uses electric current to destroy vessels and stop bleeding. **Embolisation** is a procedure in which a chemical substance injected by an intra-arterial catheter causes selective occlusion of a blood vessel.

The maxillary artery is one of the two terminal branches of the external carotid artery. It is **divided into three parts within its course**. **It passes through the infratemporal and pterygopalatine fossae** and **supplies part of the acoustic meatus, tympanic cavity, maxilla, mandible, teeth, masticatory muscles, buccinator, part of the nasopharynx and auditory tube and the hard and soft palates.**

Course

- 1 **Mandibular part** (*pars mandibularis*)
  - – runs between the neck of the mandible and the sphenomandibular ligament and ascends to the infratemporal fossa
- 2 **Pterygoid part** (*pars pterygoidea*) – usually lies between the lateral and medial pterygoid muscles
- 3 **Pterygopalatine part** (*pars pterygopalatina*) – passes through the pterygomaxillary fissure to enter the pterygopalatine fossa

Branches of the mandibular part

1.1 **Deep auricular artery** (*arteria auricularis profunda*) – supplies the wall of the external acoustic meatus

1.2 **Anterior tympanic artery** (*arteria tympanica anterior*) – supplies the tympanic cavity

– passes through the petrotympanic fissure into the tympanic cavity

- 1.3 **Middle meningeal artery** (*arteria meningea media*)
  - – passes through the foramen spinosum to enter the middle cerebral fossa
  - 1.3.1 **Frontal, parietal, and orbital branches** (*ramus frontalis, parietalis et orbitalis*)
    - – supply the dura mater and part of the bony cranial vault
  - 1.3.2 **Petrosal branch** (*ramus petrosus*) – passes into the facial canal
  - 1.3.3 **Superior tympanic artery** (*arteria tympanica superior*)
    - – supplies the tympanic cavity
    - – passes through the canal for the lesser petrosal nerve
- 1.4 **Inferior alveolar artery** (*arteria alveolaris inferior*)
  - – enters the mandibular canal through the mandibular foramen
  - 1.4.1 **Mental branch** (*ramus mentalis*) – the terminal branch
    - – passes through the mental foramen to reach the mental region
  - 1.4.2 **Mylohyoid branch, dental, and gingival branches** (*ramus mylohyoideus, rami dentales et gingivales*)
    - – supply the mylohyoid, lower teeth and gingiva

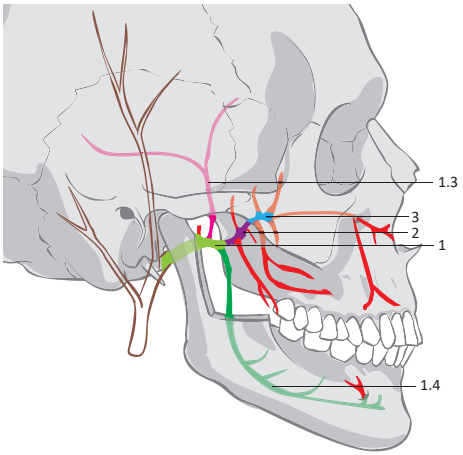

Branches of the pterygoid part

2.1 **Masseteric artery** (*arteria massetерica*) – passes through the mandibular notch and enters the medial surface of the masseter

2.2 **Deep temporal arteries** (*arteriae temporalis profundae*) – anterior and posterior

– two arteries running cranially and entering the temporalis from the medial side

2.3 **Pterygoid branches** (*aami pterygoidei*) – supply the pterygoids

2.4 **Buccal artery** (*arteria buccalis*) – passes on the lateral surface of the buccinator

Branches of the pterygopalatine part

- 3.1 **Posterior superior alveolar artery** (*arteria alveolaris posterior superior*)
  - – passes over the maxillary tuberosity and travels through the alveolar canals to reach the tooth sockets (*alveoli*) of the upper premolars and molars
- 3.2 **Infraorbital artery** (*arteria infraorbitalis*) – supplies the facial area under the orbit and the anterior upper teeth
  - – passes through the inferior orbital fissure and along the infraorbital groove
  - – enters the infraorbital canal and leaves it through the infraorbital foramen
  - 3.2.1 **Anterior superior alveolar arteries** (*arteriae alveolares superiors anteriores*)
    - – branch from the infraorbital artery in the infraorbital canal and descend in osseous canals to the tooth sockets of the upper incisors and canines
- 3.3 **Descending palatine artery** (*arteria palatina descendens*)
  - – descends in the greater palatine canal to the palate
  - 3.3.1 **Greater palatine artery** (*arteria palatina major*) – passes through the greater palatine foramen to reach the mucosa of the hard palate
  - 3.3.2 **Lesser palatine arteries** (*arteriae palatinae minores*) – pass through the lesser palatine canals and foramina to reach the mucosa of the soft palate
- 3.4 **Artery of pterygoid canal** (*arteria canalis pterygoidei*)
  - – passes through the pterygoid canal to reach the nasopharynx
- 3.5 **Sphenopalatine artery** (*arteria sphenopalatina*)
  - – passes through the sphenopalatine foramen to reach the posterior part of the nasal cavity
  - 3.5.1 **Posterior lateral nasal arteries and posterior septal nasal branches** (*arteriae nasales posteriores laterales et rami septales posteriores*)
    - – pass to the mucosa of the lateral wall of the nasal cavity and to the nasal septum

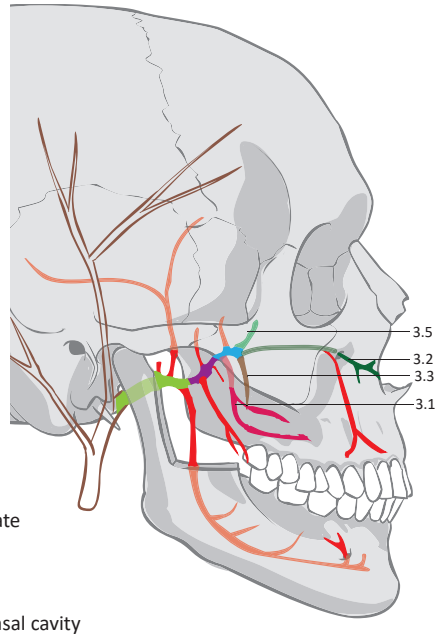

This copy belongs to ali yaghoubi

The subclavian artery arises from the **brachiocephalic trunk** on the **right side** and directly from the **aortic arch** on the **left side**. It supplies the **inferior part of the neck**, **posterior part of the brain**, **anterior and lateral thoracic walls**, **anterior abdominal wall**, and **upper extremity**. Its course is divided into three parts.

Course

1 **Intrascalenic/thoracic part** (*pars intrascalenica*)
– arches over the plural cupula in the groove for the subclavian artery
2 **Interscalenic/scalene part** (*pars interscalenica*) – enters the scalene fissure and lies in the groove for the subclavian artery of the first rib
3 **Extrascalenic/clavicular part** (*pars extrascalenica*)
– heads under the clavicle to the axillary fossa where it continues as the axillary artery

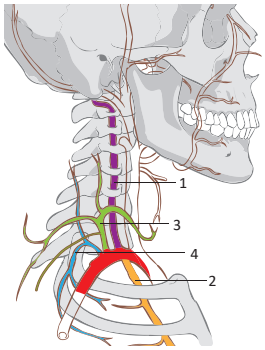

Branches and areas supplied

- 1 **Vertebral artery** (*arteria vertebralis*) – supplies part of the brain
- 2 **Internal thoracic artery** (*arteria thoracica interna*)
  – supplies the thorax and diaphragm
- 3 **Thyrocervical trunk** (*truncus thyrocervicalis*)
  – supplies the thyroid gland, larynx, lateral cervical region and its muscles and also scapular muscles
- 4 **Costocervical trunk** (*truncus costocervicalis*) – supplies the first two posterior intercostal muscles and the nuchal muscles

4.5.1 Vertebral artery – Arteria vertebralis

The vertebral artery is the first branch of the subclavian artery. It passes through the **transverse foramina of the cervical vertebrae** as it ascends in the neck. It supplies blood to **the circle of Willis**. The vertebral artery supplies the **posterior part of the brain**, **the cranial part of the spinal cord, cranial and spinal meninges and the deep cervical muscles**. Its course can be divided into four parts.

Course

1 **Prevertebral part** / V1 segment *(pars prevertebralis)*
– runs cranially between the longus coli and the scalenus anterior
2 **Transverse part** / V2 segment *(pars transversaria)* – enters the transverse foramen of the 6th cervical vertebra and ascends through the transverse foramina of the other cerivical vertebrae to the atlas
3 **Atlantic part** / V3 segment *(pars atlantica)* – after leaving the transverse foramen of the atlas, lies in the groove for the vertebral artery on the posterior arch of the atlas
– then perforates the posterior atlanto-occipital membrane and spinal dura mater and passes through the foramen magnum into the cranial cavity
4 **Intracranial part** / V4 segment *(pars intracranialis)* – is located in the posterior cerebral fossa on the clivus of the occipital bone, the two vertebral arteries fuse near the inferior margin of the pons to form the unpaired basilar artery

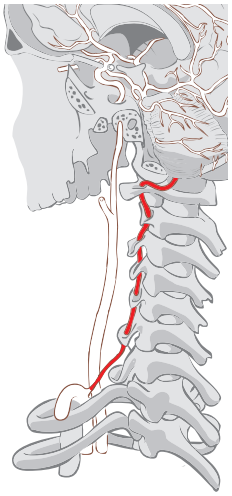

Extracranial branches

1 **Spinal branches** (*rami spinales*) – supply the spinal cord and its meninges
2 **Muscular branches** (*rami musculares*) – supply the deep cervical muscles

Intracranial branches

3 **Meningeal branch** (*ramus meningeus*) – runs through the foramen magnum to the cranial dura mater in the posterior cerebral fossa
4 **Posterior spinal artery** (*arteria spinalis posterior*)
– passes to the posterior surface of the medulla oblongata and descends on the posterior surface of the spinal cord usually as a paired artery
– supplies the posterior third of the spinal cord
5 **Anterior spinal artery** (*arteria spinalis anterior*) – an unpaired artery arising from two short branches from each vertebral artery
– enters the vertebral canal and descends in the anterior median fissure to supply the anterior two thirds of the spinal cord
6 **Posterior inferior cerebellar artery** „PICA“ (*a. cerebelli posterior inferior*)
– a paired branch supplying the inferior surface of the cerebellum and a part of the medulla oblongata

Internal mammary artery is an obsolete term for the internal thoracic artery.

The internal thoracic artery is the only vessel in the human body with a diameter of 1,8–2,6 mm, which has an elastic wall. Smaller arteries usually have muscular walls. The internal thoracic artery is an ideal graft for cardiac bypass because it is only rarely affected by atherosclerosis.

The branching pattern of the transverse cervical artery is highly variable. A deep branch may be present as an individual branch of the extrascalenic part of the subclavian artery in 33 % of cases.

Clinical notes

The internal thoracic artery can be used as a graft for bypassing a stenotic coronary vessel in cardiosurgery.

LIMA-RIA-bypass means a bypass from the left internal thoracic artery to the anterior interventricular branch of the left coronary artery.

The inferior thyroid artery crosses the recurrent laryngeal nerve at a right angle. Its arterial and nervous branches are often interwoven. Increased attention should be paid to the recurrent laryngeal nerve during thyroidectomy as its ligation carries a high risk of nervous damage with subsequent loss of voice and hoarseness.

Vertebrobasilar insufficiency (beauty parlour syndrome or syndrome of viewing cathedrals) is a pathological condition caused by decreased blood flow in the posterior part of the brain. It can be caused by congenital arterial stenosis and atherosclerosis and manifests as vertigo, dizziness and even as a stroke.

Subclavian steal syndrome occurs when the subclavian artery is occluded proximally to the origin of the vertebral artery. Blood is redirected from through the common carotid artery, internal carotid artery, and the circle of Willis, where it then passes in a retrograde direction through the vertebral artery to reach the subclavian artery, distal to the occlusion. In this way, circulation to the upper extremity distal to the occlusion is restored. Blood is “stolen” from the circle of Willis in order to supply the upper extremity; this can lead to the development of neurological symptoms resulting from brain ischaemia.

The internal thoracic artery arises from the caudal aspect of the subclavian artery and descends into the thorax. It supplies the anterior parts of the intercostal spaces, the sternum, the pericardium, and the diaphragm. **The thyrocervical trunk** supplies the thyroid gland, larynx, lateral cervical region, and cervical and scapular muscles. **The costocervical trunk** supplies the posterior parts of 1st and 2nd intercostal spaces and the deep nuchal muscles.

Internal thoracic artery (*arteria thoracica interna*)

Course

1. passes through the superior thoracic aperture to enter the thorax
2. runs approximately 1 cm laterally to the sternum through the anterior layer of the superior mediastinum and the anterior inferior mediastinum to the level of the 6th intercostal space
3. its terminal branch, the superior epigastric artery, passes through the diaphragm in front of the sternocostal triangle and terminates in the anterior abdominal wall

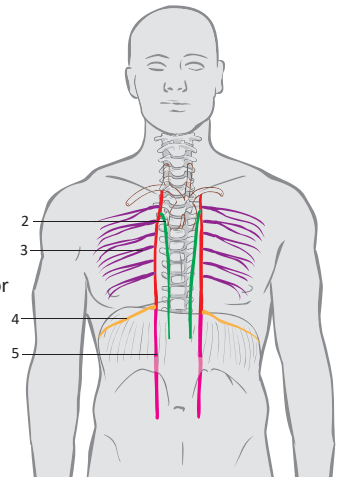

Branches and areas supplied

1 **Minor branches** – supply the thymus, sternum, trachea, and mediastinum

- 2 **Pericardiacophrenic artery** (*arteria pericardiacophrenica*) – travels with the phrenic nerve
  – supplies the pericardium and diaphragm
- 3 **Intercostal braches** (*rami intercostales*) – supply the intercostal muscles, pass within the superior part of the first six intercostal spaces and anastomose with the posterior intercostal arteries
  3.1 **Perforating branches** (*rami perforantes*)
  – perforate the intercostal spaces and supply the anterior thoracic wall
  3.1.1 **Medial mammary branches** (*rami mammarii mediales*) – supply the mammary gland
- 4 **Musculophrenic artery** (*arteria musculophrenica*) – the first terminal branch
  – passes from the 7th rib laterocaudally along the insertion of the diaphragm
  4.1 **Anterior intercostal branches** (*rami intercostales anteriores*)
  – supply the anterior part of the 7th to 9th intercostal spaces
- 5 **Superior epigastric artery** (*arteria epigastrica superior*) – the second terminal branch
  – passes through the diaphragm in front of the sternocostal triangle and descends on the posterior surface of the rectus abdominis (in the rectus sheath) where it anastomoses with the inferior epigastric artery

Thyrocervical trunk

Course – passes close to the medial margin of the anterior scalenus

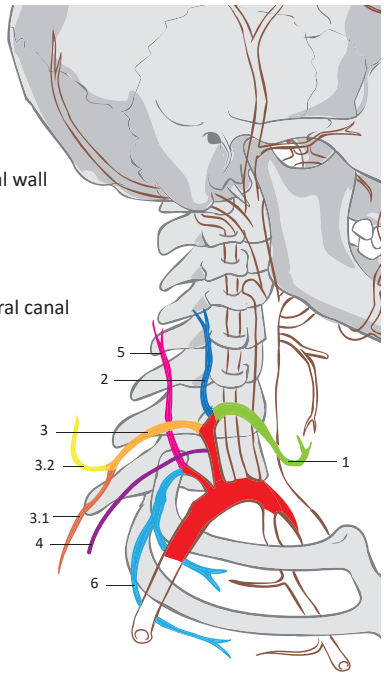

Branches and areas supplied

- 1 **Inferior thyroid artery** (*arteria thyroidea inferior*) – supplies the thyroid glands
  – ascends and turns medially at the level of the 6th cervical vertebra
  – crosses the recurrent laryngeal nerve close to the thyroid gland
  1.1 **Inferior laryngeal artery** (*arteria laryngea inferior*) – supplies the posterior laryngeal wall
  1.2 **Pharyngeal and tracheal branches** (*rami pharyngeales et tracheales*)
- 2 **Ascending cervical artery** (*arteria cervicalis ascendens*)
  – a small branch supplying the deep cervical muscles and spinal cord
  – runs on the anterior surface of the anterior scalenus medially to the phrenic nerve
  2.1 **Spinal branches** (*rami spinales*) – pass via the intervertebral foramina to the vertebral canal
- 3 **Transverse cervical artery** (*arteria transversa colli*)
  – passes ventrally to the anterior scalenus to reach the lateral cervical triangle
  - 3.1 **Deep branch, dorsal scapular artery** (*ramus profundus, arteria dorsalis scapulae*)
    – courses together with the dorsal scapular nerve and supplies the rhomboidei and levator scapulae
  - 3.2 **Superficial branch** (*ramus superficialis*) – supplies the trapezius
- 4 **Suprascapular artery** (*arteria suprascapularis*)
  – supplies the muscles attached to the posterior surface of the scapula
  – runs ventrally to the anterior scalenus to the superior margin of the scapula
  – passes above the superior transverse scapular ligament to enter the supraspinous fossa and then travels to the infraspinous fossa through the sphenoglenoid notch

Costocervical trunk

Course – arises dorsally to the anterior scalenus

Branches and areas supplied

- 5 **Deep cervical artery** (*arteria cervicalis profunda*) – passes between the transverse processes of the 7th cervical vertebra and the 1st thoracic vertebra and between the semispinalis cervicis and capitis
- 6 **Supreme intercostal artery** (*arteria intercostalis suprema*) – passes in front of the heads of the first two ribs
  6.1 **Posterior intercostal arteries** (*arteriae intercostales posteriores*) – supply the first two intercostal spaces from the posterior side

This copy belongs to ali yaghoubi

The axillary artery is a direct continuation of the subclavian artery. It gives off branches in the axillary fossa and then continues as the brachial artery. It supplies the **muscles of the shoulder joint, muscles bordering the axillary fossa, deltoid, lateral thoracic wall including its muscles and the mammary gland**. The axillary artery can be divided into **three parts** according to its relationship with the pectoralis minor.

Course

1 **Suprapectoral part** (*pars suprapectoralis*)
– originates from the subclavian artery when it's crossing the lateral margin of the 1st rib
2 **Retropectoral part** (*pars retropectoralis*) – descends behind the tendon of the pectoralis minor
3 **Infrapectoral part** (*pars infrapectoralis*) – is located between the inferior margin of the pectoralis minor and the inferior part of the teres minor and latissimus dorsi (at the level of the surgical neck of the humerus)

Branches and areas supplied

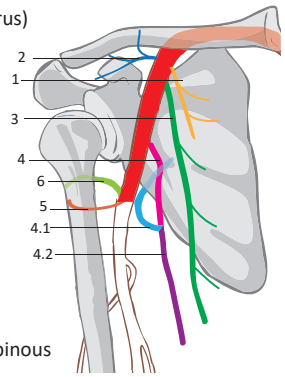

- 1 **Superior thoracic artery** (*arteria thoracis superior*)
  – supplies the pectoral muscles and the mammary gland
- 2 **Thoraco-acromial artery** (*arteria thoracoacromialis*)
  – runs through the clavipectoral triangle
  2.1 **Acromial and deltoid branch, pectoral branches** (*ramus acromialis, deltoideus et rami pectorales*)
- 3 **Lateral thoracic artery** (*arteria thoracica lateralis*)
  – descends on the serratus anterior, which it supplies
  3.1 **Lateral mammary branches** (*rami mammarii laterales*)
- 4 **Subscapular artery** (*arteria subscapularis*)
  - 4.1 **Circumflex scapular artery** (*arteria circumflexa scapulae*)
    – passes through the omotricipital foramen to the infraspinous fossa where it supplies the posterior scapular muscles
  - 4.2 **Thoracodorsal artery** (*arteria thoracodorsalis*)
    – passes over the latissimus dorsi, which it supplies
- 5 **Anterior circumflex humeral artery** (*arteria circumflexa humeri anterior*)
  – a smaller artery located on the anterior surface of the surgical neck of the humerus
- 6 **Posterior circumflex humeral artery** (*arteria circumflexa humeri posterior*)
  – a larger artery that passes through the humerotricipital foramen to supply the deltoid

The lateral thoracic artery descends on the surface of the serratus anterior with the long thoracic nerve.

The thoracodorsal artery runs on the inner surface of the latissimus dorsi with the thoracodorsal nerve.

The posterior circumflex humeral artery can be damaged in a fracture of the surgical neck of the humerus.

The radial artery is palpable in the radial foveola (the "anatomical snuff-box").

The princeps pollicis artery is an inaccurate but widespread term, usually synonymous with the first palmar metacarpal artery.

The radialis indicis artery is synonymous with the radial proper palmar digital artery. It most commonly arises from the first palmar metacarpal artery.

The superficial palmar arch is completely formed only in 27 % of cases. It is unclosed in a majority of cases.

The arteria comitans nervi mediani (median artery) accompanies the median nerve and can be variably enlarged. The artery supports the arterial supply of the palm.

4.7 **Brachial artery** – Arteria brachialis

The brachial artery is the continuation of the axillary artery. It supplies **the whole arm and elbow joint**. It terminates in the cubital fossa where it **bifurcates into the ulnary and radial arteries**. Its collaterals terminate in the **cubital articular anastomosis**.

Course

1. originates from the axillary artery, close to the inferior margin of the teres major and latissimus dorsi, at the level of the surgical neck of the humerus
2. descends on the medial surface of the arm to the cubital fossa

Branches and areas supplied

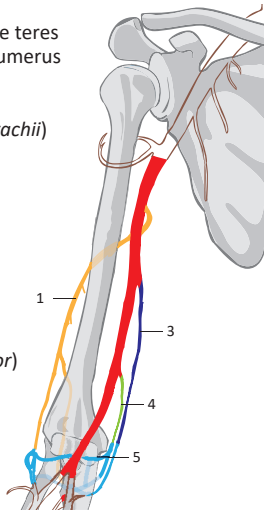

- 1 **Profunda brachii artery / deep artery of arm** (*arteria profunda brachii*)
  – runs between the lateral and medial heads of the triceps brachii and then passes in the radial canal with the radial nerve
  1.1 **Deltoid branch** (*ramus deltoideus*) – supplies the deltoid
  1.2 **Middle collateral artery** (*arteria collateralis media*)
  – enters the medial head of the triceps brachii
  1.3 **Radial collateral artery** (*arteria collateralis radialis*)
  – terminates in the cubital articular anastomosis
  2 **Humeral nutrient artery** (*arteria nutritia humeri*)
- 3 **Superior ulnar collateral artery** (*arteria collateralis ulnaris superior*)
  – descends on the anterior surface in the medial intermuscular septum of the arm with the ulnar nerve
  – terminates in the cubital articular anastomosis
- 4 **Inferior ulnar collateral artery** (*arteria collateralis ulnaris inferior*)
  – arises just above the cubital fossa
  – enters the cubital articular anastomosis
- 5 **Cubital articular anastomosis** (*rete articulare cubiti*) – a vascular plexus of the elbow joint
  – formed by the brachial, radial, and ulnar arteries

Clinical notes

The thoracodorsal artery serves as a nutritive vessel for muscle and myocutaneous flaps in plastic and reconstructive surgeries.

When measuring blood pressure, the stethoscope is placed over the brachial artery, medially to the biceps brachii tendon in the cubital fossa.

Pulse is most usually palpated by compressing the radial artery against the radius in the distal part of the forearm, a few centimetres proximal to the wrist.

The radial artery serves as an approach for diagnostic and therapeutic coronary catheterisation. The ulnar artery is less commonly used

The radial artery can be used to create an arterio-venous fistula (anastomosis) for haemodialysis. The most common type is the radiocephalic fistula.

The radial artery can be also used as a graft in coronary artery bypass surgery. Its diameter is 2.0–3.2 mm.

The radial and ulnar arteries are the terminal branches of the brachial artery. The radial artery supplies the **lateral part of the forearm and hand** and the ulnar artery supplies the **medial part of the forearm and hand**. Both arteries continue to the palm, but neither of them pass in the carpal tunnel. They form vascular arches within the palm. **The superficial palmar arch** is supplied mainly by the **ulnar artery** and the **deep palmar arch** is supplied mainly by the **radial artery**.

Radial artery (*arteria radialis*)

Course

1. its initial segment is located between the pronator teres and the brachioradialis
2. passes between the brachioradialis and flexor carpi radialis and then continues between the radial styloid process and scaphoid
3. then it runs on the lateral surface of the wrist to the radial foveola and passes through the first interdigital space to reach the palm

- 1 **Radial artery**
  - 1.1 **Radial recurrent artery** (*arteria recurrens radialis*) – heads proximally to the cubital articular anastomosis
  - 1.2 **Palmar carpal branch** (*ramus carpalis palmaris*) – terminates in the palmar carpal articular anastomosis
  - 1.3 **Superficial palmar branch** (*ramus palmaris superficialis*)
    – runs between the thenar muscles and participates in the formation of the superficial palmar arch
  - 1.4 **Dorsal carpal branch** (*ramus carpalis dorsalis*)
    – arises at the radial foveola and gives branches supplying the dorsum of the hand
  - 1.5 **First dorsal metacarpal artery** (*arteria metacarpalis dorsalis prima*)
    – divides into the dorsal digital arteries supplying the thumb and lateral side of the forefinger
  - 1.6 **First palmar metacarpal artery** (*arteria metacarpalis palmaris prima*)
    – arises where the radial artery enters the palm and divides into the palmar digital arteries, which supply both margins of the thumb and the lateral margin of the forefinger

Ulnar artery (*arteria ulnaris*)

Course

1. after its origin in the cubital fossa it passes along the ulnar side of the forearm
2. lies between the flexor digitorum superficialis and flexor digitorum profundus
3. distally it runs between the flexor carpi ulnaris and the flexor digitorum superficialis
4. enters the palm through the ulnar canal (Guyon's canal) with the ulnar nerve

- 2 **Ulnar artery**
  - 2.1 **Ulnar recurrent artery** (*arteria recurrens ulnaris*)
    – heads proximally to the cubital articular anastomosis
  - 2.2 **Common interosseous artery** (*arteria interossea communis*)
    – heads to the interosseous membrane of the forearm
    - 2.2.1 **Anterior interosseous artery** (*arteria interossea anterior*)
      – runs on the anterior surface of the interosseous membrane of the forearm, perforates the membrane proximally to the pronator teres and terminates in the palmar carpal articular anastomosis
    - 2.2.2 **Posterior interosseous artery** (*arteria interossea posterior*)
      – perforates the interosseous membrane of the forearm (distally to the oblique cord) and runs on the posterior surface of the forearm between the superficial and deep layers of the extensors
  - 2.3 **Palmar carpal branch** (*ramus carpalis palmaris*)
    – heads to the palmar carpal articular anastomosis
  - 2.4 **Dorsal carpal branch** (*ramus carpalis dorsalis*)
    – heads to the dorsal carpal articular anastomosis
  - 2.5 **Deep palmar branch** (*ramus palmaris profundus*)
    – anastomoses with the radial artery and forms the deep palmar arch

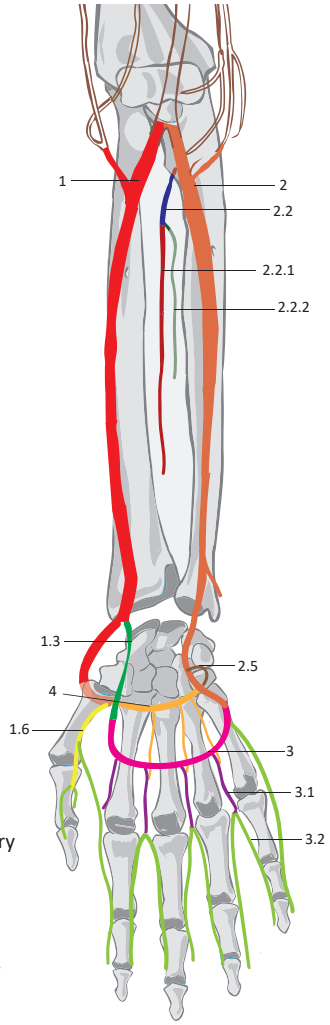

Superficial and deep palmar arches (*arcus palmaris superficialis et profundus*)

- 3 **Superficial palmar arch** (*arcus palmaris superficialis*) – is formed by an anastomosis between the larger trunk of the ulnar artery and the smaller superficial palmar branch of the radial artery
  - 3.1 **Common palmar digital arteries** (*arteriae digitales palmares communes*)
    – descend distally between the metacarpals
  - 3.2 **Proper palmar digital arteries** (*arteriae digitales palmares propriae*) – paired branches arising at the level of the metacarpal heads that run along the sides of the fingers
- 4 **Deep palmar arch** (*arcus palmaris profundus*) – is formed by an anastomosis between the larger terminal branch of the radial artery and the smaller deep palmar branch of the ulnar artery
  - 4.1 **Palmar metacarpal arteries** (*arteriae metacarpales palmares*)
    – supply the fingers, head distally and anastomose with the common digital arteries

This copy belongs to ali yaghoubi

The thoracic aorta is located between the aortic arch and the abdominal aorta. It supplies the 3rd–11th intercostal spaces, lateral and posterior thoracic walls, the vertebral column with the spinal cord and meninges, part of the diaphragm, and the lungs.

Course

1. begins at the level of the 3rd thoracic vertebra as the continuation of the aortic arch
2. descends on the left side of the vertebral column and oesophagus
3. subsequently it gets between the vertebral column and oesophagus
4. terminates by passing via the aortic hiatus at the level of the 12th thoracic vertebra (continues as the abdominal aorta)

Parietal branches

- 1 **Posterior intercostal arteries** (*arteriae intercostales posteriores*)
  - nine pairs of arteries, which enter the 3rd to 11th intercostal spaces from the posterior side
  - pass between the internal and innermost intercostal muscles
  - anastomose with the anterior intercostal branches
  - 1.1 **Subcostal artery** (*arteria subcostalis*)
    - a pair of arteries running below the 12th rib
- 2 **Superior phrenic arteries** (*arteriae phrenicae superiores*)
  - a small paired artery supplying the adjacent part of the diaphragm

Visceral branches

3 **Bronchial branches** (*rami bronchiales*)
- supply for the nutritive circulation of the lungs
- usually the left one is doubled and the right one is single

- 4 **Oesophageal branches** (*rami oesophageales*)
  - supply the thoracic part of the oesophagus

5 **Pericardiac branches** (*rami pericardiaci*)
- supply the posterior part of the pericardium

6 **Mediastinal branches** (*rami mediastinales*)
- supply the other mediastinal organs and connective tissue

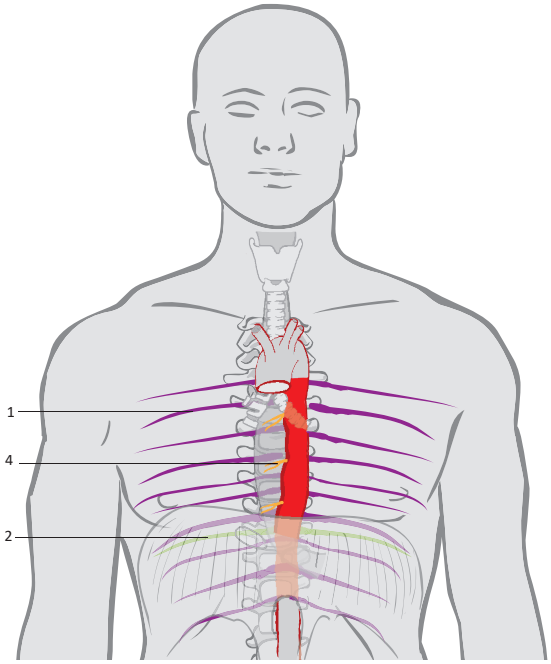

The aortic isthmus (*isthmus aortae*) is an insignificant constriction of the aorta at the border between the aortic arch and the thoracic aorta. It is located distal to the origin of the left subclavian artery at the attachment of the ligamentum arteriosum (a remnant of a fetal shunt: the *ductus arteriosus*). The aorta is slightly enlarged immediately below the isthmus.

The right bronchial branch (*ramus bronchialis dexter*) usually arises from the beginning of the third posterior intercostal artery.

Clinical notes

Aortic coarctation (*coarctatio aortae*) is a congenital constriction of the aorta. In a majority of cases, it is located within the aortic isthmus. It can lead to a decrease in blood pressure distal to the coarctation and an increase in blood pressure proximal to the coarctation. If the coarctation is not severe, collateral blood circulation may develop within the thoracic walls.

An aortic aneurysm (*aneurysma aortae*) is most commonly located in the abdominal aorta, ascending aorta and aortic arch. Atherosclerosis is one of the major causes of aortic aneurysms.

The abdominal aorta is the last part of the aorta. It is the continuation of the thoracic aorta **after passing through the aortic hiatus**. The abdominal aorta **terminates at the level of the 4th lumbar vertebra** by bifurcating into the right and left common iliac arteries. It supplies **the abdominal and pelvic organs, muscles of the abdominal wall and back, part of the diaphragm, and external genital organs.** The abdominal aorta has **parietal** and **visceral branches**.

Course

1. begins at the level of the aortic hiatus as the continuation of the thoracic aorta
2. descends in front of the vertebral column, on the left of the inferior vena cava
3. bifurcates into the common iliac arteries at the level of the 4th lumbar vertebra

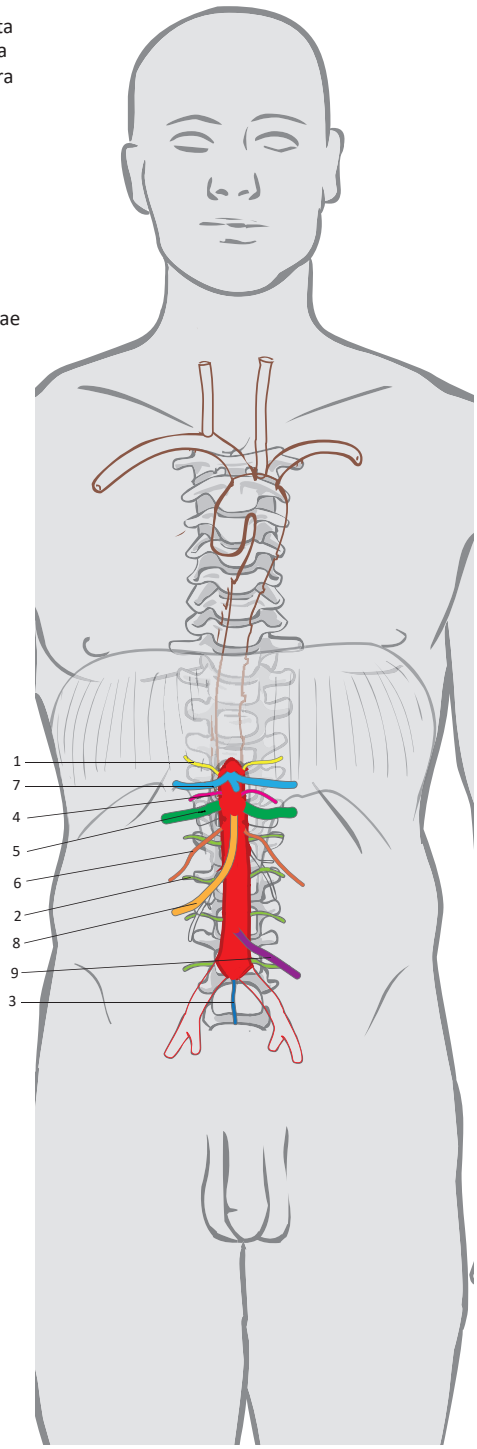

Parietal branches

- 1 **Inferior phrenic arteries** (*arteriae phrenicae inferiores*)
  - a large paired artery supplying the inferior surface of the diaphragm
  - 1.1 **Right and left superior suprarenal arteries** (*arteriae suprarenales superiores dextrae et sinistrae*)
    - several smaller arteries supplying the suprarenal gland from above
- 2 **Lumbar arteries** (*arteriae lumbales*)
  - four paired arteries running on the vertebral bodies of the lumbar vertebrae
  - terminate in the muscles of the abdominal wall
- 3 **Median sacral artery** (*arteria sacralis mediana*)
  - an unpaired artery, the caudal axial continuation of the aorta
  - arises from the aortic bifurcation and descends on the anterior surface of the sacrum to the coccyx
  - **Coccygeal body** (*glomus coccygeum*) – a glomerulus of arteriovenous anastomoses located in front of the coccygeal apex

Paired visceral branches

- 4 **Middle suprarenal artery** (*arteria suprarenalis media*)
- 5 **Renal artery** (*arteria renalis*)
  - arises almost at a right angle at the level of the 1st lumbar vertebra
  - runs across the psoas major and enters the hilum of the kidney
  - 5.1 **Inferior suprarenal artery** (*arteria suprarenalis inferior*)
- 6 **Ovarian artery** (*arteria ovarica*) – in females
  - supplies the ovary
  - arises at the level of the 2nd lumbar vertebra and passes along the posterior abdominal wall
  - enters the superior part of the broad ligamentum of the uterus via the suspensory ligament of the ovary
- 6 **Testicular artery** (*arteria testicularis*) – in males
  - supplies the testis and epididymis
  - arises at the level of the 2nd lumbar vertebra and passes along the posterior abdominal wall
  - crosses ventrally the common iliac artery and vein, while passing the border between the pelvis and abdomen
  - heads to the deep inguinal ring and runs inside the inguinal canal and spermatic cord to the scrotum

Unpaired visceral branches

- 7 **Coeliac trunk** (*truncus coeliacus*)
  - supplies the abdominal part of the oesophagus, stomach, spleen, liver, bile ducts, oral half of the duodenum, and the majority of the pancreas
- 8 **Superior mesenteric artery** (*arteria mesenterica superior*)
  - supplies the aboral half of the duodenum, inferior part of the pancreatic head, jejunum, ileum, caecum, ascending colon, and 2/3 of the transverse colon
- 9 **Inferior mesenteric artery** (*arteria mesenterica inferior*)
  - supplies the left 1/3 of the transverse colon, descending colon, sigmoid colon, and the majority of the rectum

This copy belongs to ali yaghoubi

The coeliac trunk is a one centimeter long trunk arising from the anterior side of the abdominal aorta at the level of T12 to L1. It trifurcates into **three main branches that supply the abdominal part of the oesophagus, stomach, spleen, liver, bile ducts, oral half of the duodenum, and the majority of the pancreas**.

- 1 **Left gastric artery** (*arteria gastrica sinistra*) – runs on the posterior wall of the omental bursa along the superior margin of the pancreas and the lesser curvature of the stomach, where it anastomoses with the right gastric artery forming the gastric arch

- 2 **Common hepatic artery** (*arteria hepatica communis*)
  – arises from the coeliac trunk, travels to the right and divides above the pylorus
  - 2.1 **Hepatic artery proper** (*arteria hepatica propria*)
    – passes inside the hepatoduodenal ligament with the main bile duct and the portal vein (which is positioned behind the artery) to the porta hepatis
    - 2.1.1 **Left branch** (*ramus sinister*) – supplies the left hepatic lobe
    - 2.1.2 **Right branch** (*ramus dexter*) – supplies the right hepatic lobe
      - 2.1.2.1 **Cystic artery** (*arteria cystica*)
        – arises from the right branch and supplies the gallbladder
    - 2.1.3 **Right gastric artery** (*arteria gastrica dextra*) – passes along the lesser curvature and anastomoses with the left gastric artery (forms the gastric arch)
  - 2.2 **Gastroduodenal artery** (*arteria gastroduodenalis*)
    – descends behind the pylorus
    - 2.2.1 **Right gastro-omental artery** (*arteria gastroomentalis, gastroepiploica dextra*)
      – anastomoses with the left gastro-omental artery along the greater curvature to form the gastro-omental arch supplying the adjacent part of the stomach and greater omentum
    - 2.2.2 **Anterior superior pancreaticoduodenal artery** (*arteria pancreaticoduodenalis superior anterior*)
      – descends behind the pancreatic head and descending part of the duodenum
      – anastomoses with the inferior pancreaticoduodenal artery to form the anterior pancreatic arch supplying the head of the pancreas
    - 2.2.3 **Posterior superior pancreaticoduodenal artery** (*arteria pancreaticoduodenalis superior posterior*)
      – anastomoses with the inferior pancreaticoduodenal artery to form the posterior pancreatic arch supplying the head of the pancreas

- 3 **Splenic artery** (*arteria splenica/lienalis*) – has a tortuous course as it runs to the left along the superior pancreatic margin to the splenic hilum
  - 3.1 **Pancreatic branches** (*rami pancreatici*) – supply the body and tail of the pancreas
  - 3.2 **Posterior gastric artery** (*arteria gastrica posterior*)
    – supplies the posterior wall of the stomach
  - 3.3 **Short gastric arteries** (*arteria gastricae breves*) – branches for the fundus of the stomach
  - 3.4 **Left gastro-omental artery** (*arteria gastroomentalis/gastroepiploica sinistra*)
    – descends along the greater curvature and anastomoses with the right gastro-omental artery

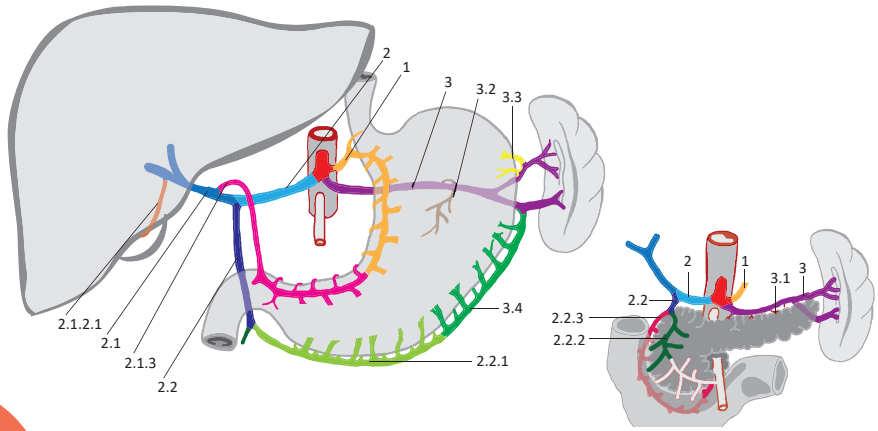

Tripus Halleri is an obsolete term for the coeliac trunk.

From the developmental point of view, the coeliac trunk is the artery supplying the foregut. The superior mesenteric artery supplies the midgut and the inferior mesenteric artery supplies the hindgut.

The marginal artery of the colon / marginal artery of Drummond (*arteria marginalis coli*) is formed by individual branches of the colic arteries. It has a variable caliber and runs along the wall of the large intestine.

The anastomosis of Haller / arc of Riolan *(anastomosis magna)* is an anastomosis between the middle and left colic arteries, located close to the left colic flexure. It interconnects the arterial beds of the superior and inferior mesenteric arteries.

The cystic artery passes through the cystohepatic triangle (triangle of Calot), where it can be ligated during cholecystecomy.

The right gastric artery arises from the hepatic artery proper in two thirds of cases. It is a branch of the common hepatic artery in the remaining cases.

The pancreatic branches include individual smaller or larger branches supplying the pancreatic body and tail (dorsal, inferior and greater pancreatic artery, prepancreatic artery, and the artery to the tail of the pancreas).

The superior mesenteric artery is the second unpaired branch of the abdominal aorta. It supplies the **aboral half of the duodenum, inferior half of the head of the pancreas, jejunum, ileum, caecum, vermiform appendix, and ascending colon.** It also supplies the **right two thirds of the transverse colon** and anastomoses with a branch of the inferior mesenteric artery. **The inferior mesenteric artery** is the third unpaired branch of the abdominal aorta. It supplies the **left third of the transverse colon, descending colon, sigmoid colon**. It continues to the pelvis as the superior rectal artery supplying the majority of the rectum.

- 1 **Superior mesenteric artery** (*arteria mesenterica superior*)
  – arises from the aorta at the level of L1 and runs inside the root of the mesentery
  - 1.1 **Inferior pancreaticoduodenal artery** (*arteria pancreaticoduodenalis inferior*)
    – passes between the duodenum and pancreas, which it supplies
    - 1.1.1 **Anterior branch** (*ramus anterior*) – anastomoses with the corresponding branch from the superior pancreaticoduodenal artery forming the anterior pancreatic arch
    - 1.1.2 **Posterior branch** (*ramus posterior*) – anastomoses with the corresponding branch from the superior pancreaticoduodenal artery forming the posterior pancreatic arch
  - 1.2 **Jejunal arteries** (*arteriae jejunales*) – run inside the mesentery to the loops of the jejunum,
    – divide into one or two arcades, which give off long branches termed arteriae rectae (average of 5 cm long)
  - 1.3 **Ileal arteries** (*arteriae ileales*) – run inside the mesentery to the loops of the ileum
    divide into two or three arcades which give off short branches termed the arteriae rectae (average of 2 cm long)
  - 1.4 **Ileocolic artery** (*arteria ileocolica*) – a terminal branch passing inside the mesentery to the caecum, which it supplies
    - 1.4.1 **Appendicular artery** (*arteria appendicularis*) – passes in the mesoappendix and supplies the vermiform appendix
    - 1.4.2 **Anterior and posterior caecal artery** (*arteria caecalis anterior et posterior*)
      – supply the anterior and posterior aspects of the caecum
  - 1.5 **Right colic artery** (*arteria colica dextra*) – passes retroperitoneally and heads to the ascending colon, which it supplies
    – anastomoses with the ileocolic artery and middle colic artery
  - 1.6 **Middle colic artery** (*arteria colica media*) – passes in the transverse mesocolon and supplies the transverse colon
    – anastomoses with both the right colic artery and the left colic artery, which is a branch of the inferior mesenteric artery

- 2 **Inferior mesenteric artery** (*arteria mesenterica inferior*)
  – arises at the level of L3 and heads down and to the left in the retroperitoneum
  where its branches either ascend to the left colic flexure or descend to the lesser pelvis
  - 2.1 **Left colic artery** (*arteria colica sinistra*) – supplies the descending colon
    and anastomoses with the middle colic artery close to the left colic flexure
  - 2.2 **Sigmoid arteries** (*arteriae sigmoideae*) – two to four arteries supplying the sigmoid colon
  - 2.3 **Superior rectal artery** (*arteria rectalis superior*)
    – a terminal branch of the inferior mesenteric artery while crossing the linea terminalis
    – supplies the rectal ampulla

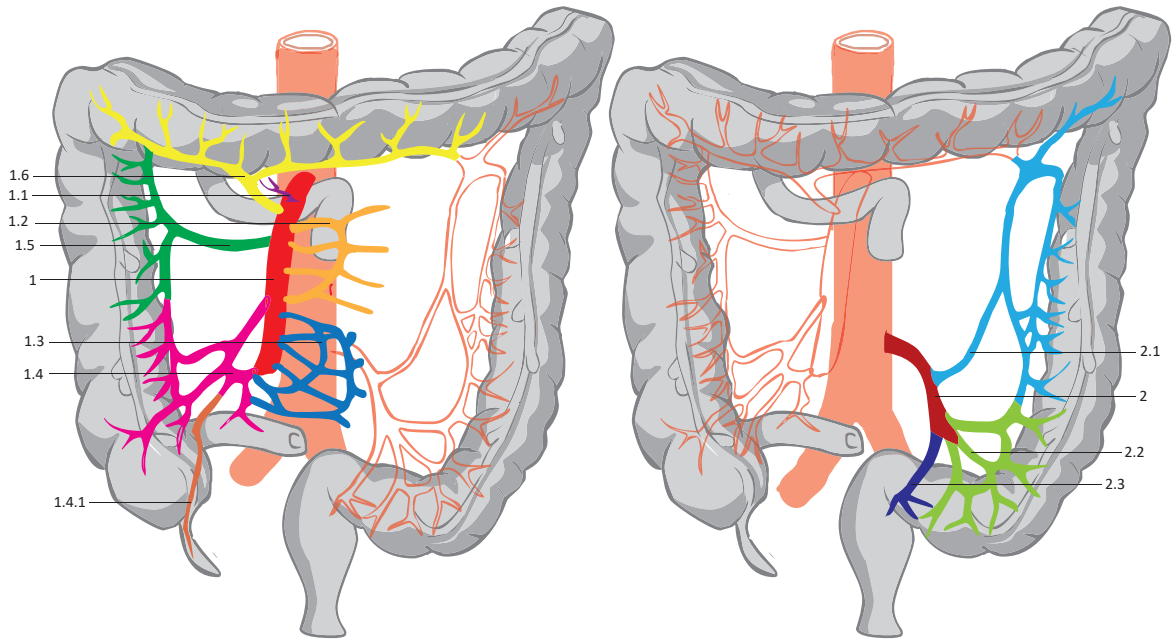

This copy belongs to ali yaghoubi

The common iliac artery is a paired continuation of the abdominal aorta from its bifurcation **at the level of L4**. The artery passes on the medial surface of the psoas major, and divides into the external and internal iliac arteries at the level of the sacroiliac joint. The common iliac artery **supplies the pelvis and lower extremities**.

Course

– arises from the bifurcation of the abdominal aorta

- 1 **Right common iliac artery** (*arteria iliaca communis dextra*)
  - – crosses the left common iliac vein at a right angle and descemds ventrally to the right common iliac vein
  - 1.1 **Internal iliac artery** (*arteria iliaca interna*)
    - – passes across the sacroiliac joint to the lesser pelvis and supplies both the pelvic wall and organs
  - 1.2 **External iliac artery** (*arteria iliaca externa*)
    - – passes medially to the psoas major and through the vascular space (under the inguinal ligament)
    - – continues as the femoral artery and continues to the lower extremity which it supplies

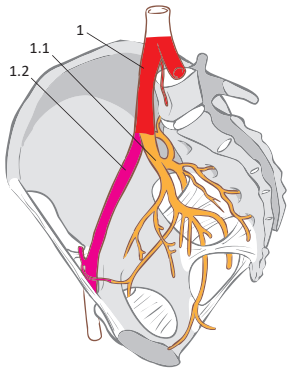

4.11.1 Internal iliac artery (parietal branches) – Arteria iliaca interna

The internal iliac artery is the medial branch of the common iliac artery. It descends behind the peritoneum to the lesser pelvis, where it passes in front of the sacroiliac joint and produces branches close to the sacral plexus. **The parietal branches supply the pelvic wall, gluteal muscles, and medial side of the thigh**.

- 1 **Iliolumbar artery** (*arteria iliolumbalis*) – supplies the iliopsoas, quadratus lumborum, ilium, and vertebral column including the cauda equina
- 2 **Lateral sacral arteries** (*arteriae sacrales laterales*)
  - – two branches (each then bifurcate) enter the anterior sacral foramina and supply the sacrum, cauda equina, and adjacent muscles of the back
- 3 **Obturator artery** (*arteria obturatoria*) – supplies the muscles of the medial femoral group, sacroiliac joint, accompanies the obturator nerve and vein passing via the obturator canal
- 4 **Superior gluteal artery** (*arteria glutea superior*) – supplies the gluteus maximus, medius, and minimus, passes together with the superior gluteal vein and nerve via the suprapiriform foramen and issues branches which course between passing gluteal muscles
- 5 **Inferior gluteal artery** (*arteria glutea inferior*) – supplies the gluteus maximus
  - – passes together with the inferior gluteal nerve and vein via the infrapiriform foramen

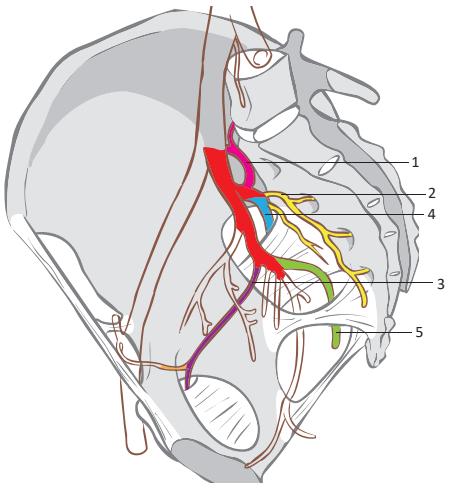

Pelvis with arteries, left anterior view to the right side of the pelvis

The iliolumbar artery gives off the iliac branch, which runs across the iliac fossa, and the lumbar branch, which ascends medially to the psoas major where it produces the spinal branch to the vertebral canal.

The internal iliac artery bifurcates into an anterior and a posterior trunk. The posterior trunk usually gives off the iliolumbar artery, lateral sacral arteries, and superior gluteal artery. All the other parietal and visceral branches originate from the anterior trunk.

The obturator artery gives off the pubic branch within the lesser pelvis.

The artery to the sciatic nerve (*arteria comitans nervi ischiadici*) is a thin artery accompanying the sciatic nerve.

Clinical notes

The corona mortis of Hesselbach is a term for an aberrant obturator artery arising from the bed of the external iliac artery, usually from the inferior epigastric artery. It crosses the pecten pubis (linea terminalis) and heads to the lesser pelvis and enters the obturator canal. The corona mortis is considered to be an anatomic variant, which is present in 25 % of cases. In 5 % of cases the beds of both arteries are interconnected via an anastomosis (accessory aberrant obturator artery).

The inferior epigastric artery serves as a nutritive vessel for muscle and myocutaneous flaps (rectus abdominis) in reconstructive surgery.

The visceral branches of the internal iliac artery supply the perineum and the organs within the lesser pelvis except for the rectal ampulla and part of the ovary and uterine tube.

- 1 **Umbilical artery** (*arteria umbilicalis*) – the main foetal artery carrying deoxygenated blood from fetus to the placenta
  – soon after the delivery its distal part obliterates (occluded part, *pars occlusa*) and forms the lateral umbilical ligament (inside the medial umbilical fold) within the anterior abdominal wall
  - 1.1 **Superior vesical arteries** (*arteriae vesicales superiores*) – arise from the unoccluded part (patent part, *pars patens*) of the umbilical artery and supply the superior part of the urinary bladder, part of the ureter and the urethra
- 2 **Inferior vesical artery** (*arteria vesicalis inferior*) – supplies the fundus of the urinary bladder
  – in female, it participates in the blood supply of the vagina, in male supplies blood to the prostate and seminal glands
- 3 **Middle rectal artery** (*arteria rectalis media*)
  – supplies the levator ani and terminates within the outer layers of the rectum (it is not necessary for its nutrition)
  – in female, it participates in the blood supply of the vagina, in male in the blood supply of the prostate and seminal glands
- 4 **Artery to ductus deferens** (*arteria ductus deferentis*) – in male
  – supplies the ductus deferens, prostate, seminal glands, and part of the ureter

4 **Uterine artery** (*arteria uterina*) – in female, supplies the uterus and part of the vagina, uterine tube, ovary, and ureter
– passes in the inferior part of the broad ligament of the uterus to the cervix of the uterus, crosses the ureter ventrally, close to the vaginal fornix and then tortuously ascends along the border of the uterus
- 4.1 **Ureteric branch** (*ramus uretericus*) – arises where the uterine artery crosses the ureter
- 4.2 **Uterine branches** (*rami uterini*) – travel to the uterine wall
- 4.3 **Vaginal branches** (*rami vaginales*) – travel to the vaginal fornices
- 4.4 **Tubal branch** (*ramus tubarius*) – the first terminal branch is a continuation from the uterine horn and enters the mesosalpinx to supply part of the uterine tube
- 4.5 **Ovarian branch** (*ramus ovaricus*) – the other terminal branch, enters the mesovary and forms the ovarian arcade with the ovarian artery

- 5 **Internal pudendal artery** (*arteria pudenda interna*)
  – accompanies the sciatic nerve, inferior gluteal artery and vein through the infrapiriform foramen, then winds around the ischial spine and passes through the lesser sciatic foramen to the ischioanal fossa, where it runs through the pudendal canal with the internal pudendal veins and pudendal nerve to the posterior margin of the urogenital diaphragm
  - 5.1 **Inferior rectal artery** (*arteria rectalis inferior*) – supplies the anal canal and anus
  - 5.2 **Perineal artery** (*arteria perinealis*) – runs forward along the perineum
    - 5.2.1 **Posterior scrotal/labial branches** (*rami scrotales/labiales posteriores*) – supply the posterior part of the scrotum / labia majora
  - 5.3 **Dorsal artery of penis/clitoris** (*arteria dorsalis penis/clitoridis*)
  - 5.4 **Deep artery of penis/clitoris** (*arteria profunda penis/clitoridis*)
  - 5.5 **Urethral artery** (*arteria urethralis*) – in male, heads to the corpus spongiosum penis
  - 5.6 **Artery of bulb of penis/vestibule** (*arteria bulbi penis / vestibuli*) – supplies the bulb of the penis / vestibule of the vagina and bulb of the vestibule

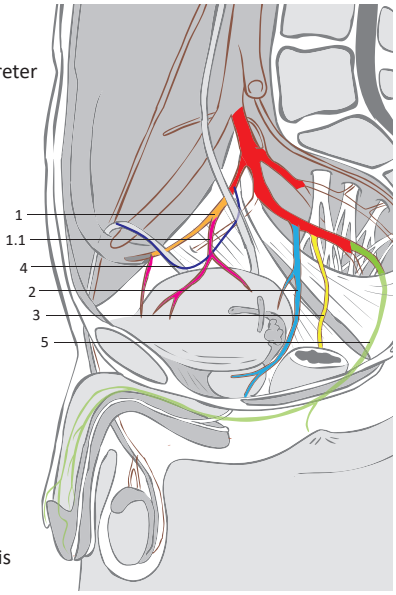

Sagittal section of the male pelvis

4.11.3 External iliac artery – arteria iliaca externa

The external iliac artery **travels to the vascular space (*lacuna vasorum*)** and passes laterally to the external iliac vein. After leaving the vascular space it **continues as the femoral artery and supplies the majority of the lower extremity, the anterior and lateral muscles of the abdominal wall, part of the wall of the greater pelvis and part of the scrotum** in males and the broad ligament of the uterus in females. The external iliac artery **issues two branches just medial to the inguinal ligament**.

Branches

- 1 **Inferior epigastric artery** (*arteria epigastrica inferior*) – ascends along the posterior surface of the anterior abdominal wall inside the lateral umbilical fold
  – anastomoses with the superior epigastric artery within the rectus abdominis, which it supplies
  - 1.1 **Pubic branch** (*ramus pubicus*) – runs to the pubic symphysis
  - 1.2 **Cremasteric artery** (*arteria cremasterica*) – in males
    – enters the inguinal canal and supplies the cremaster and spermatic cord
  - 1.3 **Artery of round ligament of uterus** (*arteria ligamenti teretis uteri*) – in females
    – enters the inguinal canal and travels to the round ligament of the uterus
- 2 **Deep circumflex iliac artery** (*arteria circumflexa ilium profunda*) – passes on the inner surface of the inferior margin of the anterior abdominal wall and travels to the anterior superior iliac spine

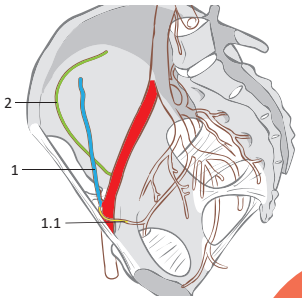

This copy belongs to ali yaghoubi

The femoral artery is the continuation of the external iliac artery after passing through the **vascular space** (*lacuna vasorum*)**.** It enters **the femoral triangle** on the anterior side of the thigh where it **gives off branches that supply the muscles of the thigh**. It passes between the two insertions of the adductor magnus (via the adductor hiatus) and **continues to the popliteal fossa as the popliteal artery**. The popliteal artery **supplies the knee joint and adjacent muscles and continues as the anterior and posterior tibial arteries to the leg**.

Femoral artery (*arteria femoralis*)

Course

1. runs through the vascular space and between the iliopsoas and pectineus in the iliopectineal fossa where it is positioned laterally to the common femoral vein
2. then it passes beneath the sartorius and between the adductor longus and the vastus medialis to reach the adductor canal of Hunter
3. then it courses between the two insertions of the adductor magnus and passes through the adductor hiatus to reach the popliteal fossa

Branches

- 1 **Superficial epigastric artery** (*arteria epigastrica superficialis*)
  – passes in the subcutaneous tissue of the anterior abdominal wall
- 2 **Superficial circumflex iliac artery** (*arteria circumflexa ilium superficialis*) – passes in subcutaneous tissue along the inguinal canal to the anterior superior iliac spine
- 3 **External pudendal arteries** (*arteriae pudendae externae*)
  – the deep and superficial external pudendal arteries supply the anterior part of the scrotum/labia majora as the anterior scrotal/labial branches (*rami scrotales/labiales anteriores*)
- 4 **Profunda femoris artery / deep artery of thigh** (*arteria profunda femoris*) – arises from the proximal part of the femoral atery and passes between the adductor magnus and longus
  – its branches supply the posterior side of the thigh
  - 4.1 **Medial circumflex femoral artery** (*arteria circumflexa femoris medialis*) – supplies the sacroiliac joint and the adductors and flexors of the thigh
  - 4.2 **Lateral circumflex femoral artery** (*arteria circumflexa femoris lateralis*)
    – supplies the quadriceps femoris
  - 4.3 **Perforating arteries** (*arteriae perforantes*)
    – three branches, which travel to the posterior side of the thigh to supply the adductors and flexors
- 5 **Descending genicular artery** (*arteria genus descendens*)
  – supplies the anterior thigh muscles and knee joint, passes through the adductor canal and perforates the vastoadductor membrane

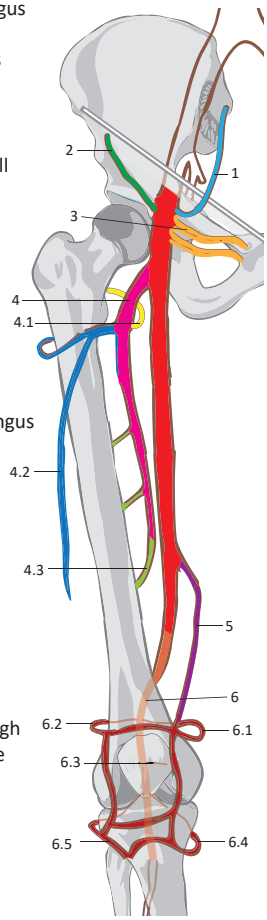

Popliteal artery (*arteria poplitea*)

Course

1. passes through the adductor hiatus to reach the popliteal fossa
2. then runs medially and below the popliteal vein and tibial nerve
3. bifurcates into the anterior and posterior tibial arteries over the popliteus

Branches

- 6 **Popliteal artery**
  - 6.1 **Superior medial genicular artery** (*arteria superior medialis genus*)
    – passes below the insertion of the semitendinosus and semimembranosus
  - 6.2 **Superior lateral genicular artery** (*arteria superior lateralis genus*)
    – passes below the insertion of the biceps femoris
  - 6.3 **Middle genicular artery** (*arteria media genus*)
    – passes over the posterior surface of the articular capsule
  - 6.4 **Inferior medial genicular artery** (*arteria inferior medialis genus*)
    – passes below the medial head of the gastrocnemius
  - 6.5 **Inferior lateral genicular artery** (*arteria inferior lateralis genus*)
    – passes below the lateral head of the gastrocnemius
  - 6.6 **Sural arteries** (*arteriae surales*) – paired branches supplying both heads of the gastrocnemius

The common femoral artery (*arteria femoralis communis*) is a clinical term for the common trunk of the femoral artery in the proximal part of the thigh. The common femoral artery bifurcates into the femoral artery (clinically termed the superficial femoral artery) and the deep artery of the thigh (clinically termed the deep femoral artery).

The genicular (articular) anastomosis (*rete articulare genus*) is a vascular network of the knee joint, which is formed by the branches of the femoral artery, the deep artery of the thigh, the popliteal artery and anterior and posterior tibial arteries.

The malleolar articular network (*rete malleolare*) is a vascular network around the ankles formed by the branches of the anterior tibial, posterior tibial and fibular arteries.

The arcuate artery (*arteria arcuata*) is a variable arch interconnecting the dorsal pedis artery and the lateral tarsal artery on the dorsum of the foot. The arcuate artery is present in 12 % of cases.

Clinical notes

The arterial pulse on the lower extremity can be palpated in four places:
– **Femoral artery** in the femoral triangle, caudal to the inguinal canal
– **Popliteal artery** in the popliteal fossa
– **Posterior tibial artery** behind the medial ankle
– **Dorsal pedis artery** on the dorsum of the foot, laterally to the tendon of the extensor hallucis longus

The medial circumflex femoral artery is the main artery of the hip joint. Fractures of the femoral neck may lead to compression or disruption of the retinacula of Weibrecht, through which vessels of the femoral head pass, which impairs the healing process.

Arterial aneurysms have a predilection for elastic arteries, such as the popliteal artery – the most affected peripheral artery.

Chronic lower limb ischaemia is a pathological condition caused by atherosclerosis of the arteries of the lower extremity. Small arteries are damaged in the microangiopathy of chronic diabetes mellitus, which can also lead to peripheral ischaemia or necrosis. Chronic lower limb ischaemia manifests as claudication (pain in the leg that occurs when walking).

The anterior tibial artery passes perforates the **interosseous membrane of the leg** and then descends along the anterior side of the leg **to the dorsum of the foot**. The anterior tibial artery supplies the knee joint, anterior side of the leg, dorsum of the foot, and part of the sole. **The posterior tibial artery** is a direct continuation of the popliteal artery. It descends along the posterior side of the leg and passes behind the medial malleolus. It passes **through the malleolar canal to the sole**, where it bifurcates into its terminal branches. The posterior tibial artery supplies the posterior and lateral sides of the calf and sole.

Anterior tibial artery (*arteria tibialis anterior*)

Course

1. perforates then travels along the anterior side of the interosseous membrane of the leg, to which it is attached by fibrous loops
2. is accompanied by the deep fibular nerve and anterior tibial veins
3. distally, it gets to the dorsum of the foot after passing under the superior and inferior extensor retinacula and continues as the dorsal pedis artery

Branches

1 **Anterior tibial recurrent artery** (*arteria recurrens tibialis anterior*) – terminates in the genicular articular anastomosis
2 **Anterior medial malleolar artery** (*arteria malleolaris anterior medialis*) – terminates in the medial malleolar network
3 **Anterior lateral malleolar artery** (*arteria malleolaris anterior lateralis*) – terminates in the lateral malleolar network
4 **Dorsalis pedis artery / dorsal artery of foot** (*arteria dorsalis pedis*)
– passes on the dorsum of the foot between the tendons of the extensor hallucis longus and the extensor digitorum longus and then continues as the deep plantar artery into the sole
4.1 **Lateral tarsal artery** (*arteria tarsalis lateralis*) – passes along the metatarsus laterally towards the toes
4.2 **Medial tarsal arteries** (*arteriaa tarsales mediales*) – small branches supplying the medial metatarsal margin
4.3 **Dorsal digital artery** (*arteria digitalis dorsales*) – supplies the lateral margin of the little toe
4.4 **Dorsal metatarsal arteries** (*arteriae metatarsales dorsales*)
– four arteries travelling to the toes, the medial ones are usually branches of the dorsalis pedis artery and the lateral ones are the branches of the lateral tarsal artery, but they can also be branches of the plantar arch from that pass from the sole of the foot
4.5 **Dorsal digital arteries** (*arteriae digitales dorsales*) – supply the adjacent surfaces of all toes
4.6 **Deep plantar artery** (*arteria plantaris profunda*) – the continuation of the dorsalis pedis artery, piercing through the first interdigital space to the sole where it anastomoses with the plantar arch

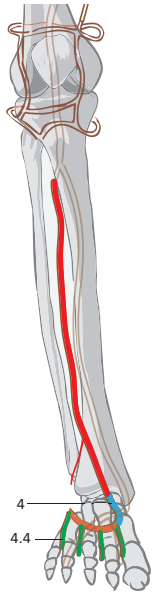

Right leg, anterior view

Posterior tibial artery (*arteria tibialis posterior*)

Course

1. passes under the tendinous arch of the soleus with the tibial nerve and posterior tibial veins
2. then descends under the soleus, between the two muscular layers of the calf
3. passes behind the medial malleolus and through the malleolar canal below the flexor retinaculum
4. while passing within the canal it bifurcates into two terminal branches: the medial and lateral plantar arteries

Branches

1 **Fibular/peroneal artery** (*arteria fibularis/peronea*) – descends in the musculofibular canal of Hyrtl to the ankle
1.1 **Calcaneal branches** (*rami calcanei*) – terminate in the calcaneal anastomosis and supply the calcaneus
1.2 **Lateral malleolar branches** (*rami malleolares laterales*) – terminate in the lateral malleolar network
1.3 **Tibial nutrient artery** (*arteria nutritia tibiae*) – supplies the tibia
1.4 **Perforating branch** (*ramus perforans*) – perforates the interosseous membrane of the leg and anastomoses with the anterior tibial artery above the ankle
2 **Medial malleolar branches** (*rami malleolares mediales*) – terminate in the medial malleolar network
3 **Medial plantar artery** (*arteria plantaris medialis*) – passes between the abductor hallucis and flexor digitorum brevis together with the medial plantar nerve and veins
3.1 **Superficial branch** (*ramus superficialis*) – supplies the subcutaneous tissue on the medial surface of the foot
3.2 **Deep branch** (*ramus profundus*) – supplies the muscles of the great toe
4 **Lateral plantar artery** (*arteria plantaris lateralis*) – passes between the flexor digitorum brevis and quadratus plantae proximally to the base of the fifth metatarsal bone
4.1 **Common plantar digital arteries and plantar digital arteries proper** (*arteriae digitales plantares communes et propriae*) – supply the adjacent parts of all toes
4.2 **Perforating branches** (*rami perforantes*) – interconnect the arteries of the sole and dorsum of the foot, occasionally individually supply the second to the fifth toe
5 **Plantar arch** (*arcus plantaris*) – both plantar arteries anastomose with each other and form an arterial arch within the sole, which gives off the plantar metatarsal arteries supplying the toes
5.1 **Plantar metatarsal arteries** (*arteriae metatarsales plantares*) – four arteries leading to the toes
5.1.1 **Plantar digital arteries** (*arteriae digitales plantares*) – supply the sides of the toes

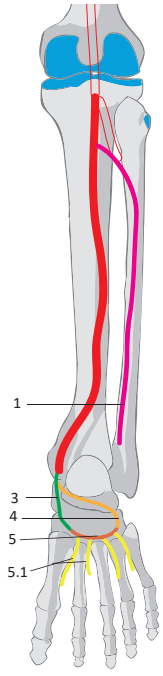

Right leg, posterior view

This copy belongs to ali yaghoubi

The superior vena cava is a **short vein** of a **large diameter (2–3 cm) without valves**, arising from the confluence of the right and left brachiocephalic veins at the level of the cartilage of the first right rib. It **descends vertically through the superior mediastinum** to **empty into the right atrium at the level of the third sternocostal joint**. It carries deoxygenated blood from the upper half of the body (head, neck, upper limbs, thorax and upper part of the back).

- 1 **Right brachiocephalic vein** (*vena brachiocephalica dextra*)
  – arises from the confluence of the right internal jugular vein with the right subclavian vein, descends behind the right margin of the manubrium of the sternum
  - **Right venous angle** (*angulus venosus dexter*) – the angle formed by the confluence of the right internal jugular vein with the right subclavian vein
    – the right lymphatic duct opens into the bloodstream here
  - 1.1 **Vertebral vein** (*vena vertebralis*) – follows the course of the vertebral artery

  1.2 Other tributaries – inferior laryngeal veins (*vv. laryngeae inferiores*), right internal thoracic vein (*vena thoracica interna dextra*), tracheal, thymic, bronchial, mediastinal, pericardiac veins (*vv. tracheales, thymicae, bronchiales, mediastinales, pericardiacae*) and supreme intercostal vein (*v. intercostalis suprema*)
- 2 **Left brachiocephalic vein** (*vena brachiocephalica sinistra*)
  – arises from the confluence of the left internal jugular vein with the left subclavian vein
  – is located anterior to the three arterial branches of the aortic arch
  – lies dorsally to the thymus in childhood
  - **Left venous angle** (*angulus venosus sinister*) – the angle formed the confluence of the left internal jugular vein with the left subclavian vein
    – the thoracic duct opens into the bloodstream here
  - 2.1 **Unpaired thyroid plexus** (*plexus thyroideus impar*), or the separate inferior thyroid vein (*v. thyroidea inferior*)
    – drains the inferior part of the thyroid gland
  - 2.2 **Vertebral vein** (*vena vertebralis*) – follows the course of the vertebral artery
  - 2.3 **Left internal thoracic vein** (*vena thoracica interna sinistra*)
    – usually doubled, accompanies the internal thoracic artery
    – tributaries: superior epigastric vein, musculophrenic vein, and anterior intercostal veins
  - 2.4 **Accessory hemiazygos vein** (*vena hemiazygos accessoria*)
    – cranially connected to the left superior intercostal vein
    – caudally drains into the superior part of the hemiazygos vein

  2.5 Other tributaries – inferior laryngeal veins (*vv. laryngeae inferiores*), tracheal, thymic, bronchial, mediastinal , pericardiac veins (*vv. tracheales, thymicae, bronchiales, mediastinales, pericardiacae*), supreme intercostal vein (*v. intercostalis suprema*) and the left superior intercostal vein (*v. intercostalis superior sinistra*)
- 3 **Azygos vein** (*vena azygos*)
  –arises on the right side of the lumbar part of the vertebral column from the confluence of the right subcostal vein with the right ascending lumbar vein
  – passes through the right crus of the diaphragm into the posterior inferior mediastinum and ascends behind the hilum of the right lung, then turns ventrally to drain into the superior vena cava
  - 3.1 **Hemiazygos vein** (*vena hemiazygos*)
    – arises on the left side of the lumbar part of the vertebral column from the confluence of the left subcostal vein with the left ascending lumbar vein
    – passes through the left crus of the diaphragm into the posterior inferior mediastinum,
    – diagonally crosses the vertebral column at level of T7–T9 and drains into the azygos vein

  3.2 Other tributaries – posterior intercostal veins (*vv. intercostales posteriors*); oesophageal, bronchial, pericardial, mediastinal and superior phrenic veins (*vv. oesophageales, bronchiales, pericardiacae, mediastinales, phrenicae superiores*)

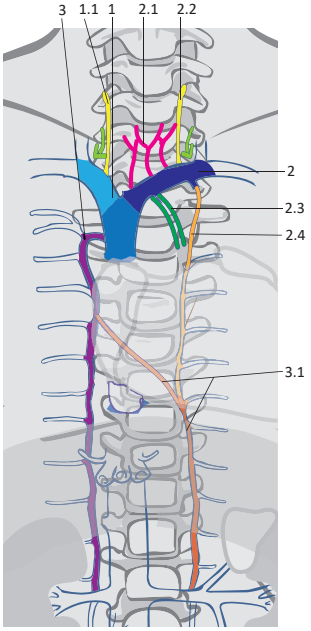

The anatomy of the veins of the neck varies among different individuals. This is especially true where veins drain into other veins. The facial, retromandibular, occipital, and external jugular veins all show considerable variation in their anatomy.

The pharyngeal plexus (*plexus pharyngeus*) is a venous network on the outer surface of the pharynx. It is connected to the pterygoid venous plexus, the suboccipital venous plexus and the anterior external vertebral venous plexus.

Azygos means unpaired in Greek.

The azygos and hemiazygos veins have no valves. They therefore may function as portocaval and cavocaval anastomoses.

The vertebral vein usually passes through the transverse foramina of C1–C7.

The supreme intercostal vein (*vena intercostalis suprema*) drains the posterior part of the first intercostal space and ends in the brachiocephalic vein.

The right superior intercostal vein (*vena intercostalis superior dextra*) drains the posterior part of the second and third intercostal spaces on the right and end in the azygos vein.

The left superior intercostal vein (*vena intercostalis superior sinistra*) drains the posterior part of the second, third and usually fourth intercostal spaces on the left and ends in the left brachiocephalic vein.

The only valve in the internal jugular vein is located near the inferior bulb.

The middle thyroid vein (*vena thyroidea media*) is present in 50 % of cases.

Cerebral veins see page 474.

Clinical notes

Superior vena cava syndrome is caused by a local expanding mass compressing the superior vena cava, causing swelling of the head and upper limbs.

The internal jugular vein is formed from the confluence of two intracranial sinuses: the sigmoid sinus and the inferior petrosal sinus. Its dilated initial segment, located in the jugular foramen, is called **the superior bulb**. It runs **caudally through the parapharyngeal space with the internal carotid artery and vagus nerve**. It widens behind the sternoclavicular joint as the inferior bulb, before joining **the subclavian vein to form the brachiocephalic vein**. It has both intracranial and extracranial tributaries and collects blood from the head (including the eye and brain) and the ventral part of the neck. The internal jugular vein and its tributaries usually don't have valves.

Intracranial tributaries

1 **Cerebral veins** (*venae cerebri*) – superficial and deep cerebral veins
2 **Meningeal veins** (*venae meningeae*) – veins from the cranial dura mater
3 **Dural venous sinuses** (*sinus durae matris*) – intracranial venous sinuses
4 **Diploic veins** (*venae diploicae*) – veins from the bones of the neurocranium
5 **Labyrinthine veins** (*venae labyrinthi*) – veins from the inner ear
6 **Emissary veins** (*venae emissariae*) – connections between intracranial and extracranial veins

Extracranial tributaries

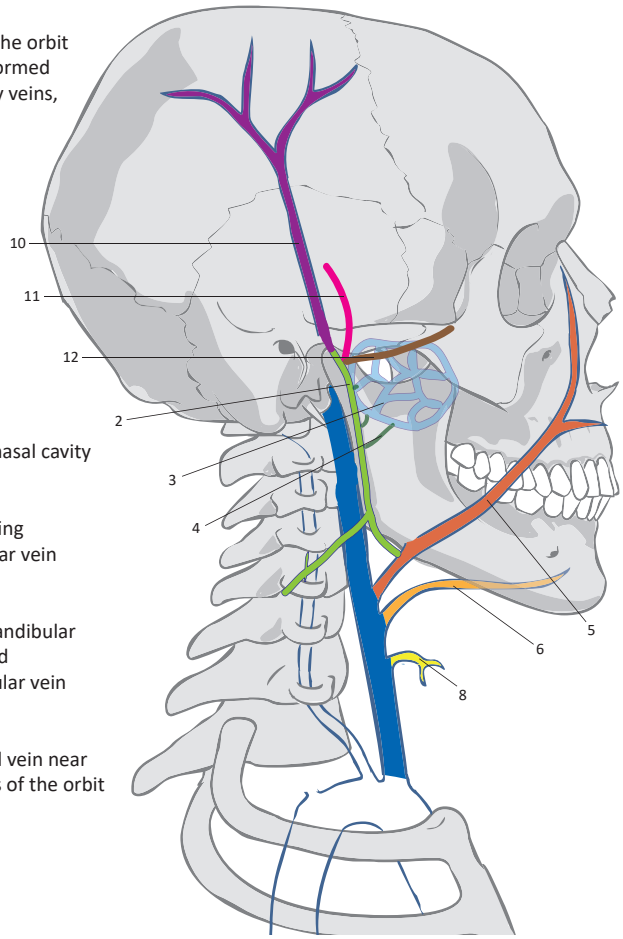

1 **Ophthalmic veins** (*venae ophthalmicae*) – drain the eye and the orbit
2 **Retromandibular vein** (*vena retromandibularis*) – is usually formed by the confluence of the superficial temporal vein, maxillary veins, middle temporal vein, and transverse facial vein
– descends in the retromandibular fossa within the parenchyma of the parotid gland
– bifurcates into anterior and posterior branches
– the anterior branch usually joins the facial vein
– the posterior branch joins the posterior auricular vein to form the external jugular vein
3 **Pterygoid plexus** (*plexus pterygoideus*)
– a venous plexus within the infratemporal fossa
3.1 **Superior alveolar veins** (*venae alveolares superiores*)
– drain the upper jaw
3.2 **Inferior alveolar vein** (*vena alveolaris inferior*)
– drain the lower jaw and mandibular region
3.3 **Sphenopalatine vein** (*vena sphenopalatina*) – drains the nasal cavity
3.4 **Palatine veins** (*venae palatinae*)
– drain the region of the soft and hard palate
4 **Maxillary veins** (*venae maxillares*) – very short veins connecting the pterygoid plexus to the initial part of the retromandibular vein
5 **Facial vein** (*vena facialis*) – drains the facial part of the head
– courses from the medial angle of the eye on the face, ventrally to the masseter, over the mandible into the submandibular region, where it lies superficially to the submandibular gland
– is usually joined by the anterior branch of the retromandibular vein
– alternatively, it may terminate alone in the retromandibular or external jugular vein
5.1 **Angular vein** (*vena angularis*) – the beginning of the facial vein near the medial angle of the eye, anastomoses with the veins of the orbit
5.2 **Deep facial vein** (*vena profunda faciei*)
– connects the pterygoid plexus to the facial vein, passing between the masseter and buccinator
5.3 **External palatine vein** (*vena palatina externa*)
– drains the soft palate and the pharyngeal tonsil
6 **Lingual vein** (*vena lingualis*) – collects blood from the tongue
6.1 **Sublingual vein** (*vena sublingualis*) – drains the deep parts of the tongue
6.2 **Vena comitans of hypoglossal nerve** (*vena comitans nervi hypoglossi*) – follows the hypoglossal nerve
7 **Pharyngeal veins** (*venae pharyngeae*) – drain the pharyngeal plexus
8 **Superior thyroid veins** (*venae thyroideae superiores*) – drain the cranial parts of the thyroid gland and larynx and contribute to one of two common venous trunks (thyrolingual or thyrolinguofacial trunk)
9 **Middle thyroid vein** (*vena thyroidea media*) – drains the middle parts of the thyroid gland
10 **Superficial temporal vein** (*vena temporalis superficialis*) – drains the frontal, parietal, and temporal regions
11 **Middle temporal vein** (*vena temporalis media*) – drains the temporal muscle
12 **Transverse facial vein** (*vena transversa faciei*) – follows the parotid duct and drains the facial region
13 **Posterior auricular vein** (*vena auricularis posterior*) – drains the region of the auricle

This copy belongs to ali yaghoubi

The external jugular vein is a superficial vein of the neck that usually **arises from the confluence of the posterior auricular vein and the posterior branch of the retromandibular vein.** It descends **on the lateral side of the neck, crosses the sternocleidomastoid** and opens **into the venous angle** or in its vicinity. It usually has a valve at its termination. It drains the regions of the auricle and neck.

- 1 **Retromandibular vein** (*vena retromandibularis*)
  - runs within the parotid gland parenchyma
  - one of the few veins that bifurcates
  - the anterior branch usually opens into the facial vein
  - the posterior branch joins the posterior auricular vein to form the external jugular vein
- 2 **Occipital vein** (*vena occipitalis*) – drains the back of the head
  - usually opens into the vertebral vein
  - frequently has a connection with the external jugular vein
- 3 **Posterior auricular vein** (*vena auricularis posterior*)
  - drains the region of the auricle
- 4 **Anterior jugular vein** (*vena jugularis anterior*) – drains the anterior cervical region, descends close to the midline
  - the jugular venous arch (*arcus venosus jugularis*) is a short connection with the contralateral vein
- 5 **Transverse cervical veins** (*venae transversae colli*)
  - drain the lateral cervical region
- 6 **Suprascapular vein** (*vena suprascapularis*)
  - drains the area supplied by the suprascapular artery, doubled in its peripheral course

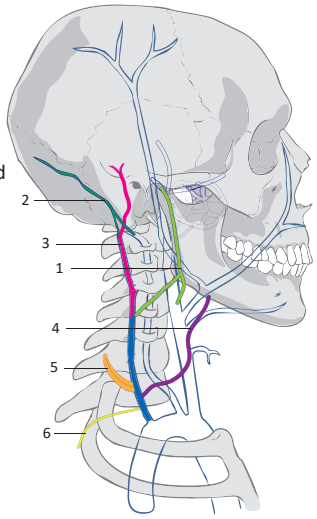

Venous blood flows from the palm to the dorsum of the hand due to higher pressure on the palm. This explains the location of the venous network on the dorsum of the hand.

The inferior vena cava into four parts: the infrarenal part, suprarenal part, hepatic part and thoracic part.
The ratio of the diameter of the suprarenal part to the hepatic part is useful for the evaluation of the venous blood flow through the liver.
The inferior vena cava has a diameter of 3.5 cm at its opening in the heart.

The median antebrachial vein (*vena mediana antebrachii*) courses on the anterior aspect of the forearm and opens into the median cubital vein.

The cubital perforating vein of Gracz (*vena cubitalis perforans*) is a connection between the superficial and deep venous systems in the cubital fossa.

5.4 Subclavian and axillary veins – Vena subclavia et vena axillaris

The axillary vein is the continuation of the brachial veins in the axilla. It becomes **the subclavian vein at the outer border the 1st rib**. The subclavian vein **courses ventrally to the anterior scalene muscle** and the scalene fissure, and dorsally to the sternoclavicular joint. **It opens into the venous angle**, where it joins the internal jugular vein to **form the brachiocephalic vein**. The subclavian vein has only minor tributaries as most of the veins following branches of the subclavian artery open into either the brachiocephalic vein or the internal jugular vein. Both veins have at least one valve.

- 1 **Subclavian vein** (*vena subclavia*)
  - 1.1 **Dorsal scapular vein** (*vena scapularis dorsalis*)
    - drains the area supplied by the dorsal scapular artery
  - 1.2 **Pectoral veins** (*venae pectorales*) – drains the pectoral muscles
- 2 **Axillary vein** (*vena axillaris*)
  - 2.1 **Thoraco-epigastric veins** (*venae thoracoepigastricae*)
    - drain the subcutaneous tissue of the anterior and lateral aspects of the thoracic wall
    - anastomose with the subcutaneous abdominal veins
  - 2.2 **Lateral thoracic vein** (*vena thoracica lateralis*)
    - drains the lateral aspect of the thoracic wall
  - 2.3 **Anterior circumflex humeral vein** (*vena circumflexa humeri anterior*)
    - drains the area supplied by the anterior circumflex humeral artery
  - 2.4 **Posterior circumflex humeral vein** (*vena circumflexa humeri posterior*)
    - drains the area supplied by the posterior circumflex humeral artery
  - 2.5 **Cephalic vein** (*vena cephalica*)
    - a superficial vein of the upper limb arising from the dorsal venous plexus of the hand
    - passes through the infraclavicular (oval) fossa in the clavipectoral fascia

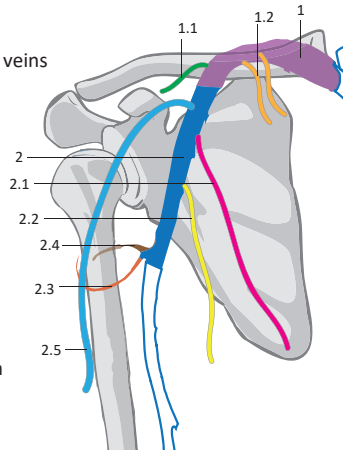

Clinical notes

Central venous pressure can be evaluated by examination of the jugular vein filling pressure. In a patient sitting at 30° the jugular veins shouldn't fill more than 2cm above the sternoclavicular joint. Distension of the jugular vein beyond this level can occur in right ventricular insufficiency, tricuspidal valve disease and superior vena cava syndrome. In patients with right ventricular failure, applying sustained pressure for 10 s on the right hypochondrium causes the jugular venous pressure to increase significantly (> 4cm).

Central venous catheterisation is the insertion of a catheter into the internal jugular or subclavian vein. It is used for long-term intravenous administration of medication, fluids or nutrition, and for the measurement of central venous pressure (normal value 1–10 mmHg). Potential complications are: pneumothorax caused by puncturing the cervical pleura and injury to the brachial plexus and subclavian artery.

Patients with pulmonary emboli originating in the veins of the lower limbs or the pelvis, in which medical anticoagulation is ineffective or contraindicated, may benefit from the insertion of a metallic filter (of Greenfield) into the inferior vena cava, to prevent thrombi from reaching the pulmonary circulation.

The veins of the upper limb form two systems. **The superficial system** lies superficially to the fascia of the muscles and lacks corresponding arteries. **The veins of the deep system** follow the course of the arteries; **two veins accompany each artery** up to the armpit.

Superficial system

1 **Intercapitular veins** (*venae intercapitulares*) – connections draining venous blood from the palm to the dorsal venous network of the hand

- 2 **Dorsal venous network of hand** (*rete venosum dorsale manus*)
  – a venous plexus on the dorsum of the hand
- 3 **Basilic vein** (*vena basilica*) – arises at the dorsal venous network of the hand
  – courses on the medial side of the forearm, runs in the medial bicipital groove in the arm and pierces the brachial fascia at the hiatus basilicus to join the brachial veins
  – alternatively, may ascend deep to the fascia all the way up to the axilla
- 4 **Cephalic vein** (*vena cephalica*) –arises at the dorsal venous network of the hand
  – courses on the lateral side of the forearm, runs in the lateral bicipital groove in the arm and then in the deltopectoral groove (*sulcus deltopectoralis*) at the shoulder
  – pierces the clavipectoral fascia in the clavipectoral triangle (in the infraclavicular fossa) to join the axillary vein
- 5 **Median cubital vein** (*vena mediana cubiti*)
  – connects the cephalic vein with basilic vein across the cubital fossa

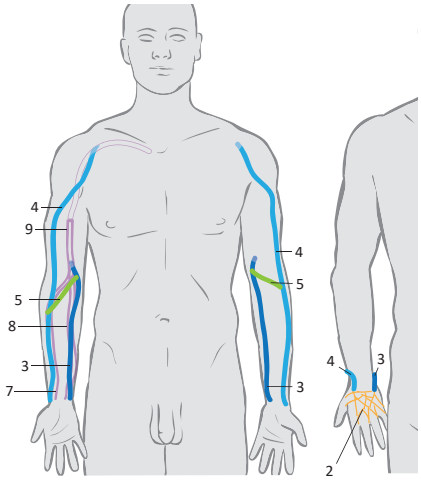

Deep system

6 **Deep venous palmar arch** (*arcus venosus palmaris profundus*) – drains the fingers and metacarpals

- 7 **Radial veins** (*venae radiales*) – thin veins draining the area supplied by the radial artery
- 8 **Ulnar veins** (*venae ulnares*) – thin veins draining the area supplied by the ulnar artery
- 9 **Brachial veins** (*venae brachiales*) – drain the area supplied by the brachial artery

5.6 **Inferior vena cava** – Vena cava inferior

The inferior vena cava is the largest vein in the human body. It collects blood from the inferior half of the body (below the diaphragm) and possesses **no valves**. **It arises from the junction of the right and left common iliac veins** at the level of L4–L5. **It is runs on the right of the abdominal aorta**, **courses dorsally to the liver** in the groove for the inferior vena cava and passes **through the diaphragm** in the caval opening. It has both parietal and visceral tributaries.

Parietal tibutaries

- 1 **Lumbar veins** (*venae lumbales*) – four pairs, follow the lumbar arteries
  - 1.1 **Ascending lumbar vein** (*vena lumbalis ascendens*)
    – a vertical connection between the common iliac vein and the azygos/hemiazygos vein, intersecting the lumbar veins
- 2 **Inferior phrenic veins** (*venae phrenicae inferiores*) – drain the inferior part of the diaphragm

3 **External vertebral venous plexuses** (*plexus venosi vertebrales externi*) – a venous networks surrounding the vertebral column

Visceral tibutaries

- 4 **Hepatic veins** (*venae hepaticae*) – three veins from the liver opening into the hepatic part of the inferior vena cava
- 5 **Right suprarenal vein** (*vena suprarenalis dextra*) – drains the right suprarenal gland
- 6 **Renal veins** (*venae renales*) – arise from the kidneys following the course of the renal arteries
  – the left one runs dorsally to the pancreas and ventrally to the abdominal aorta
  – the right one runs dorsally to the descending part of the duodenum and head of the pancreas
  - 6.1 **Capsular veins** (*venae capsulares*) – drain adipose tissue surrounding the kidney
  - 6.2 **Left suprarenal vein** (*vena suprarenalis sinistra*) – drains the left suprarenal gland
  - 6.3 **Left testicular/ovarian vein** (*vena testicularis/ovarica sinistra*)
    – opens into into the left renal vein
- 7 **Testicular vein** (*vena testicularis*) – in male, begins as the pampiniform plexus on the dorsal aspect of the testis and epididymis, courses through the inguinal canal, then runs on the anterior aspect of the psoas major and passes ventrally to the external iliac vessels
  – doubled in most of its course and possesses valves
  - 7.1 **Right testicular vein** – opens into the inferior vena cava
- 7 **Ovarian vein** (*vena ovarica*) – in female, begins in the ovary, courses ventrally to the external iliac vessels on the anterior aspect of the psoas major, doubled in most of its course, possesses valves
  - 7.1 **Right ovarian vein** – opens into the inferior vena cava

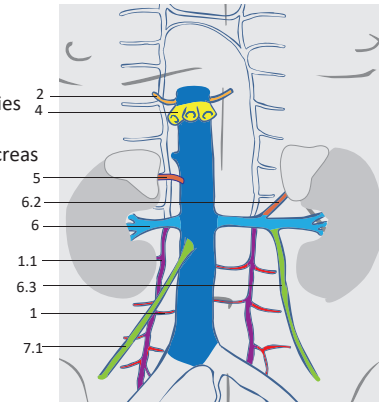

This copy belongs to ali yaghoubi

The portal vein drains blood from the unpaired organs of the abdominal cavity into the liver. It is formed by the confluence of the superior mesenteric vein with the splenic vein. It passes inside the hepatoduodenal ligament (behind the bile duct and the hepatic artery proper) into the porta hepatis where it bifurcates into right and left branches supplying the hepatic lobes. The portal vein possesses no valves.

- 1 **Superior mesenteric vein** (*vena mesenterica superior*)
  – passes on the right side of the superior mesenteric artery, behind the pancreas within the pancreatic notch, and joins the splenic vein to form the portal vein
  - 1.1 **Pancreaticoduodenal veins** (*venae pancreaticoduodenales*)
    – collect blood from the head of the pancreas and from the duodenum
  - 1.2 **Pancreatic veins** (*venae pancreaticae*)
    – collect blood from the body and tail of the pancreas
  - 1.3 **Right gastro-omental vein** (*vena gastroomentalis dextra*)
    – collects blood from the greater curvature of the stomach and the greater omentum
  - 1.4 **Jejunal and ileal veins** (*venae jejunales et ileales*)
    – collect blood from the loops of the jejunum and ileum
  - 1.5 **Ileocolic vein** (*vena ileocolica*)
    – collects blood from the terminal part of the small intestine and from the caecum
    - 1.5.1 **Appendicular vein** (*vena appendicularis*)
      – collects blood from the vermiform appendix
  - 1.6 **Right colic vein** (*vena colica dextra*) – collects blood from the ascending colon
  - 1.7 **Middle colic vein** (*vena colica media*) – collects blood from the transverse colon
- 2 **Splenic vein** (*vena splenica*)
  – collects blood from the spleen, the fundus of the stomach and part of the pancreas
  – originates in the splenic hilum, passes above the tail of the pancreas and then behind the body of the pancreas to join the superior mesenteric vein forming the portal vein
  - 2.1 **Inferior mesenteric vein** (*vena mesenterica inferior*) – its caudal part accompanies the inferior mesenteric artery, its cranial part accompanies the left colic vein
    – usually opens into the splenic vein behind the head of the pancreas
    - 2.1.1 **Left colic vein** (*vena colica sinistra*) – collects blood from the descending colon
    - 2.1.2 **Sigmoid veins** (*venae sigmoideae*) – collect blood from the sigmoid colon
    - 2.1.3 **Superior rectal vein** (*vena rectalis superior*) – collects blood from the rectal ampulla
- 3 **Left gastric vein** (*vena gastrica sinistra*) – collects blood from the left part of the lesser curvature
  – anastomoses with the right gastric vein to form a venous arch along the lesser curvature
  - 3.1 **Oesophageal veins** (*venae oesophageae*)
    – collect blood from the abdominal part of the oesophagus
- 4 **Right gastric vein** (*vena gastrica sinistra*)
  – collects blood from the right part of the lesser curvature of the stomach, anastomoses with the left gastric vein to form a venous arch along the lesser curvature
  - 4.1 **Prepyloric vein** (*vena prepylorica*)
    – collects blood from the pyloric part of the stomach
- 5 **Cystic vein** (*vena cystica*)
  – collects blood from the gallbladder (doubled in some cases)
- 6 **Paraumbilical veins** (*venae paraumbilicales*)
  – two thin veins passing along the round ligament of the liver

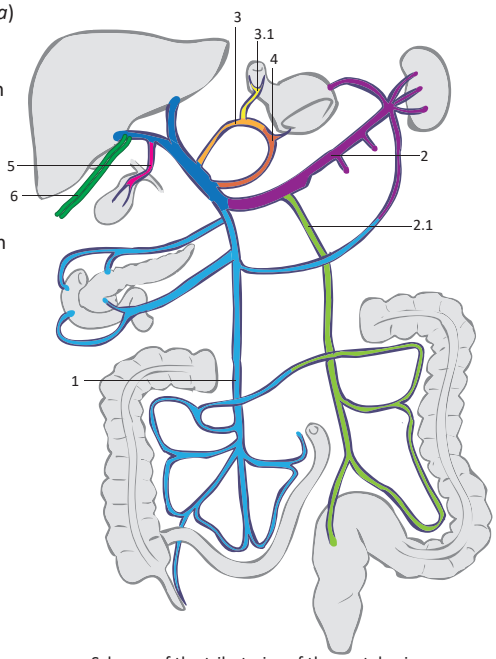

Scheme of the tributaries of the portal vein

The inferior mesenteric vein empties into the splenic vein in 50 % of cases, into the superior mesenteric vein in 40 % of cases and directly into the beginning of the portal vein in 10 % of cases.

The gastropancreaticocolic trunk of Henle is a short trunk formed by the confluence of the right gastro-omental vein, right superior colic vein and anterior pancreaticoduodenal vein. It is situated behind the head of the pancreas.

Portal hypertension may cause the adventitial veins of the oesophagus to dilate, leading to the formation of paraoesophageal varices.

Interconnections between the vertebral venous plexuses and other extravertebral veins as known as the plexus of Batson. These interconnections do not possess valves and may serve as a route for the spread of metastasis or inflammation.

Cavocaval anastomoses may dilated to allow collateral circulation.

Clinical notes

Portal hypertension is a condition of increased pressure in the portal system. It is caused by obstruction to the portal venous blood flow, which may occur in the circulation before the liver (prehepatic portal hypertension – within the portal vein and its tributaries), inside the liver parenchyma (intrahepatic portal hypertension) or after the liver (posthepatic portal hypertension – between the liver and right heart). One of the most common causes of intrahepatic portal hypertension is liver cirrhosis. Increased pressure inside the liver leads to the redistribution of portal blood into the systemic circulation, circumventing the liver. This is achieved through portocaval anastomoses, connections between the portal and the caval systems.

The porto-caval anastomoses are **connections between the tributaries of the portal vein and the superior or inferior vena cava**. Under physiological conditions, blood flows **from the portal vein to the liver** and these anastomoses are small and closed. **If blood pressure in the portal system rises, these anastomoses enlarge and form varicose dilations, which have a high propensity to rupture and bleed.**

- 1 **Anastomoses between the gastric and oesophageal veins**
  – are located in the submucosa of the oesophagus and can enlarge into oesophageal varices
  1.1 **Oesophageal veins** – open into the azygos and hemi-azygos veins (to the inferior vena cava)
- 2 **Anastomoses in the rectum** – are located in the internal rectal venous plexus / haemorrhoidal plexus in the submucosa of the rectum and can enlarge, forming internal haemorrhoids
  2.1 **Superior rectal vein** – drains into the inferior mesenteric vein (to the portal vein)
  2.2 **Middle rectal veins** – drains into the internal iliac vein (to the inferior vena cava)
  2.3 **Inferior rectal veins** – drains into the internal pudendal vein (to the inferior vena cava)
- 3 **Anastomoses between the paraumbilical veins and the subcutaneous veins around the umbilicus** – are located within the subcutaneous tissue of the umbilicus
  – their enlargement is termed caput Medusae ("head of Medusa")
  3.1 **Thoraco-epigastric veins** – open into the axillary vein (to the superior vena cava)
  3.2 **Superficial epigastric veins** – open into the great saphenous vein and then subsequently into the common femoral vein (to the inferior vena cava)
- 4 **Anastomoses between the paraumbilical veins and the vesical venous plexus**
  – are located around the umbilicus and are connected to the vesical venous plexus via the veins of Burrow, which pass along the median umbilical ligament
  4.1 **Vesical venous plexus** – opens into the internal iliac vein (to the inferior vena cava)
- 5 **Anastomoses within the retroperitoneal space** (veins of Retzius) – are located within the mesentery and mesocolons and in places where the unpaired abdominal organs are attached, between the superior and inferior mesenteric veins and the inferior vena cava
- 6 **Anastomoses between the veins of the liver and the phrenic veins**
  – are located within the posterior surface of the liver and on the bare area of the liver
  6.1 **Inferior phrenic veins** – open into the inferior vena cava
  6.2 **Pericardiacophrenic veins** – open into the brachiocephalic veins (to the superior vena cava)

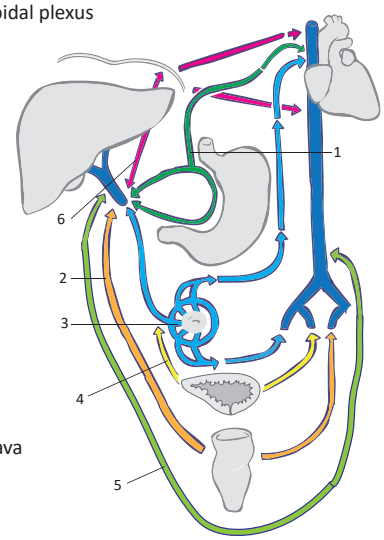

Scheme of the porto-caval anastomoses

5.9 Cavo-caval anastomoses

The cavo-caval anastomoses are **connections between the circulatory beds of the superior and inferior vena cava**. Under physiological conditions they are small. They **become clinically significant when one of the caval veins is occluded**.

- 1 **Anastomoses between the lumbar veins and the azygos vein or hemi-azygos vein** – are located retroperitoneally in the lumbar region
  1.1 **Azygos vein** – arises on the right side of the lumbar vertebral column from the confluence of the right subcostal vein with the right ascending lumbar vein, passes through the right crus of the diaphragm into the posterior inferior mediastinum to drain into the superior vena cava at the level of T4
  1.2 **Hemi-azygos vein** – arises on the left side of the lumbar vertebral column from the confluence of the left subcostal with the left ascending lumbar vein, passes through the left crus of the diaphragm to the posterior inferior mediastinum and crosses the vertebral column at the level of T7–9 to empty into the azygos vein
  1.3 **Ascending lumbar vein** – intersects the lumbar veins (which drain into the inferior vena cava) as it ascends to join the subcostal vein to form the azygos/hemi-azygos vein, which empties into the superior vena cava
- 2 **Anastomoses between the inferior and superior epigastric veins**
  – are located inside the rectus sheath
  2.1 **Superior epigastric veins** – continue as the internal thoracic veins and open into the left brachiocephalic vein on the left and directly into the superior vena cava on the right
  2.2 **Inferior epigastric veins** – open into the external iliac vein (to inferior vena cava)
- 3 **Anastomoses between the superficial epigastric veins and the thoraco-epigastric veins**
  – are located within the subcutaneous layer of the abdominal wall
  3.1 **Superficial epigastric veins** – open into the great saphenous vein, which flows into the common femoral vein (to the inferior vena cava)
  3.2 **Thoraco-epigastric veins** – open into the axillary vein (to the superior vena cava)
- 4 **Anastomoses between the vertebral venous plexuses and other veins**
  4.1 **Internal vertebral venous plexus** – is located in the epidural space of the vertebral canal and is connected to the vertebral and occipital veins and the suboccipital venous plexus (to the superior vena cava)
  4.2 **Anterior and posterior external vertebral venous plexuses** – surround the vertebral column and are connected to the azygos/hemiazygos vein (to the superior vena cava) and the lumbar, iliolumbar, and sacral veins (to the inferior vena cava)

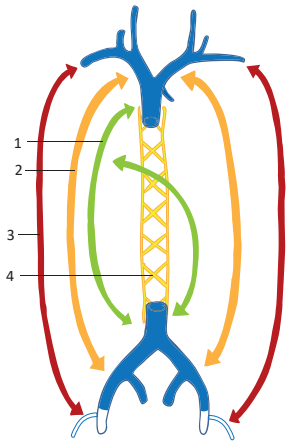

Scheme of the cavo-caval anastomoses

This copy belongs to ali yaghoubi

The common iliac vein originates at the confluence of the internal and external iliac veins ventrally to the sacro-iliac joint. The common iliac veins join to form the inferior vena cava at the level of the vertebra L4. These veins usually do not possess valves.

- 1 **Internal iliac vein** (*vena iliaca interna*)
  – collects blood from the lesser pelvis
- 2 **External iliac vein** (*vena iliaca externa*)
  – collects blood from the lower extremities and part of the anterior abdominal wall
- 3 **Ascending lumbar vein** (*vena lumbalis ascendens*)
  – crosses the lumbar veins within the lumbar region
- 4 **Median sacral vein** (*vena sacralis mediana*)
  – an unpaired vein opening into the left common iliac vein
- 5 **Iliolumbar vein** (*vena iliolumbalis*) – collects blood from the region supplied by the iliolumbar artery

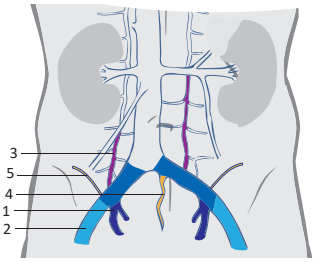

5.10.1 Internal iliac vein – Vena iliaca interna

The internal iliac vein is **formed by the confluence of the inferior gluteal veins with the internal pudendal veins.** It has both parietal and visceral tributaries. The parietal tributaries collect blood from regions supplied by homonymous arteries; usually two parietal veins accompany each of the arteries outside the lesser pelvis.

Parietal tributaries

- 1 **Superior gluteal veins** (*venae gluteae superiores*)
- 2 **Inferior gluteal veins** (*venae gluteae inferiores*)
- 3 **Obturator veins** (*venae obturatoriae*)
- 4 **Lateral sacral veins** (*venae sacrales laterales*)
- 5 **Internal pudendal veins** (*venae pudendae internae*)

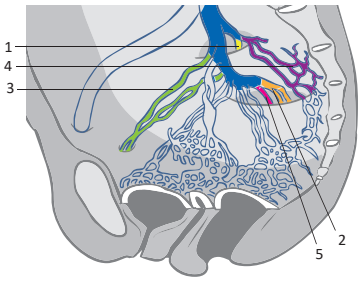

Veins of the right half of the female pelvis

Visceral tributaries

- 1 **Pudendal plexus of Santorini** (*plexus pudendus*)
  – is located in the retropubic space
  1.1 **Deep dorsal vein of penis/clitoris** (*vena dorsalis profunda penis/clitoridis*)
  – passes between the pubis and perineal muscles and enters the lesser pelvis
  2 **Prostatic venous plexus** (*plexus venosus prostaticus*)
  – is located behind the symphysis
  – surrounds the prostate and
  – is connected to the vesical venous plexus
- 3 **Vesical venous plexus** (*plexus venosus vesicalis*)
  – is located below the base of the urinary bladder
- 4 **Vaginal venous plexus** (*plexus venosus vaginalis*)
  – surrounds the vagina
  – is connected to the vesical venous plexus
- 5 **Uterine venous plexus** (*plexus venosus uterinus*)
  – is located close to the uterine margins within the broad ligament of the uterus and is connected to the vaginal venous plexus, ovarian veins and via the veins of the round ligament of the uterus to the external pudendal veins
  5.1 **Uterine veins** (*venae uterinae*)
  5.2 **Vaginal veins** (*venae vaginales*)
  6 **External rectal venous plexus** (*plexus venosus rectalis externus*) – is located around the rectum
- 7 **Internal rectal venous plexus / haemorrhoidal plexus** (*plexus venosus rectalis internus / plexus haemorrhoidalis*) – helps to retain stool
  7.1 **Inferior rectal veins** (*venae rectales inferiores*)
  – open into the internal pudendal veins within the area surrounding the anal canal
  7.2 **Middle rectal vein** (*vena rectalis media*) – a vein connected to the outer veins of the rectum
- 8 **Sacral venous plexus** (*plexus venosus sacralis*)
  – is connected to the median sacral vein and the lateral sacral veins

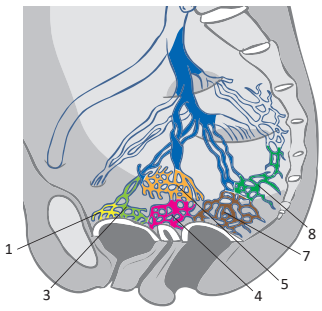

Venous plexuses of the right half of the female pelvis

The internal rectal venous plexus (haemorrhoidal plexus) is situated in the submucosa of the anal canal. Its distension contributes to stool continence. Its dilation in portal hypertension causes internal haemorrhoids.

The term perforator is in clinic used for both venous and arterial perforators. A venous perforator interconnects the superficial (subcutaneous) and deep venous system. An arterial perforator is an artery which penetrates through a muscle and fascia into subcutaneous tissue.

The so-called third system of the lower limb venous circulation is formed by a small subcutaneous system (*systema venosum laterale of Albanese*). It is situated on the lateral side of the knee region and is interconnected via perforators with the deep venous system.

The venous corona mortis (crown of death) is a variable interconnection between the inferior epigastric vein and obturator vein in the vicinity of the linea terminalis seen in 75 % of people.

The main trunk of the great/small saphenous vein is enclosed between the subcutaneous fascia (fascia saphena) and superficial muscular fascia. This organization resembles "Egyptian eye" on ultrasound examination.

Venous perforators page 311.

Clinical notes

Fractures and other trauma in the pelvic region are associated with severe bleeding (both arterial bleeding and profuse venous bleeding from the venous plexuses).

Slow blood flow in the pelvic venous plexus is associated with formation of blood clots (thrombosis), which carry a risk of embolisation to the lungs.

The venous systems of the lower limbs are connected to the pelvic plexuses by the perineal veins and the veins in the inguinal canal, obturator canal and infrapiriform foramen. The direction of blood flow depends on pressure gradients (two-way circulation), and great varices may develop inside the lesser pelvis.

The internal iliac vein and its tributaries are associated with profuse venous bleeding if harmed. The pelvic veins must be spared very carefully during surgical procedures because it is very difficult to suture the walls of the veins or to ligate bleeding veins in this region.

The external iliac vein is **the continuation of the common femoral vein**. It originates below the medial part of the inguinal ligament within the vascular space. It passes along the psoas major, medially to the external iliac artery and enters the lesser pelvis to join the **internal iliac vein to form the common iliac vein**.

- 1 **Inferior epigastric vein** (*vena epigastric inferior*)
  – collects blood from the anterior abdominal wall, its peripheral part is doubled
- 2 **Deep circumflex iliac vein** (*vena circumflexa ilium profunda*)
  – collects blood from the iliac region and the adjacent abdominal wall
  – its peripheral part is doubled

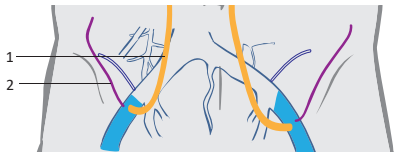

5.11 Veins of the lower limb – Venae membri inferioris

The veins of the lower extremity are divided into **2 systems. The superficial system** consists of the veins in the subcutaneous tissue, which do not accompany arteries. **The deep system** consists of the veins accompanying the arteries; two veins usually accompanying each artery. **Perforators** (perforating veins, *venae perforantes*) **interconnect the two systems**.

Superficial system

1 **Superficial dorsal digital and metatarsal veins** (*venae digitales et metatarsales dorsales superficiales*)
– collect blood from the dorsal aspect of the toes and metatarsals

- 2 **Dorsal venous network of foot** (*rete venosum dorsale pedis*) – a network of superficial veins on the dorsum of the foot
- 3 **Dorsal venous arch of foot** (*arcus venosus dorsalis pedis*) – a venous arch on the dorsum of the foot
  3.1 **Medial marginal vein** (*vena marginalis medialis*) – arises from the dorsal venous arch and passes along the medial margin of the dorsum of the foot and then continues as the great saphenous vein
  3.2 **Lateral marginal vein** (*vena marginalis lateralis*) – arises from the dorsal venous arch and passes along the lateral margin of the dorsum of the foot and then continues as the small saphenous vein
- 4 **Small saphenous vein** (*vena saphena parva*) – a continuation of the lateral marginal vein
  – passes on the lateral surface of the foot, behind the lateral malleolus, and on the posterior surface of the calf with the sural nerve
  – passes between the two heads of the gastrocnemius and penetrates the crural fascia to drain into the popliteal vein within the popliteal fossa
- 5 **Great saphenous vein** (*vena saphena magna*) – a continuation of the medial marginal vein
  – passes on the medial side of the foot, in front of the medial malleolus, then continues on the medial side of the calf accompanying the saphenous nerve
  – passes through the saphenous hiatus in the fascia lata and empties into the femoral vein
  - **Subinguinal venous confluence** (*confluens venosus subinguinalis*):
    5.1 **Superficialis, anterior, and posterior accessory saphenous vein**
    5.2 **Anterior and posterior circumflex femoral vein**
    5.3 **Superficial epigastric vein** – anastomoses with the thoraco-epigastric veins
    5.4 **Superficial circumflex iliac vein** – passes along the inguinal ligament
    5.5 **External pudendal veins** – drains the pubic region

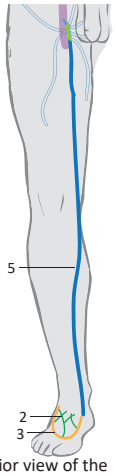

Anterior view of the superficial veins of the right leg

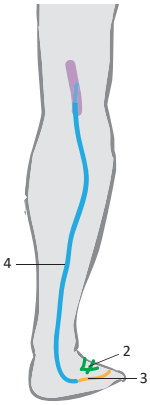

Posterior view of the superficial veins of the right leg

Deep system

Dorsum of the foot

1 **Deep dorsal digital and metatarsal veins** (*venae digitales et metatarsales dorsales profundae*)
– open into the dorsal veins of the foot

2 **Dorsal veins of foot** (*venae dorsales pedis*) – open into the anterior tibial veins

Sole of the foot

1 **Deep plantar digital veins** (*venae digitales plantares profundae*) – open into the deep plantar metatarsal veins

2 **Deep plantar metatarsal veins** (*venae matatarsales profundae*) – open into the medial and lateral plantar veins

3 **Medial and lateral plantar veins** (*venae plantares mediales et laterales*) – open into the posterior tibial veins

Veins of the leg

Anterior and posterior tibial veins *(vv. tibiales anteriores et posteriores)* – drain into the popliteal vein

Fibular veins *(vv. fibulares)* – drain into the posterior tibial veins

Veins of the thigh

1 **Popliteal vein** (*vena poplitea*) – arises from the confluence of the anterior and posterior tibial veins
– is located in the popliteal fossa and passes through the adductor hiatus to the adductor canal

- 2 **Femoral vein** (*vena femoralis*) – courses medially to the femoral artery and empties into the common femoral vein at the femoral triangle
- 3 **Deep vein of thigh** (*vena profunda femoris*) – collects blood from the interior and posterior surface of the thigh
- 4 **Common femoral vein** (*vena femoralis communis*) – arises at the junction of the femoral vein with the deep vein of the thigh
  - 4.1 **Great saphenous vein** (*vena saphena magna*)

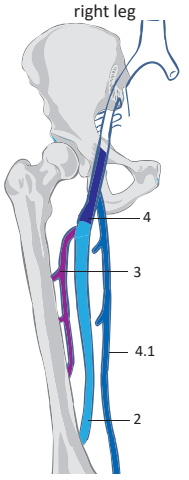

Deep and superficial veins of the right lower limb

This copy belongs to ali yaghoubi

Cardiac valves

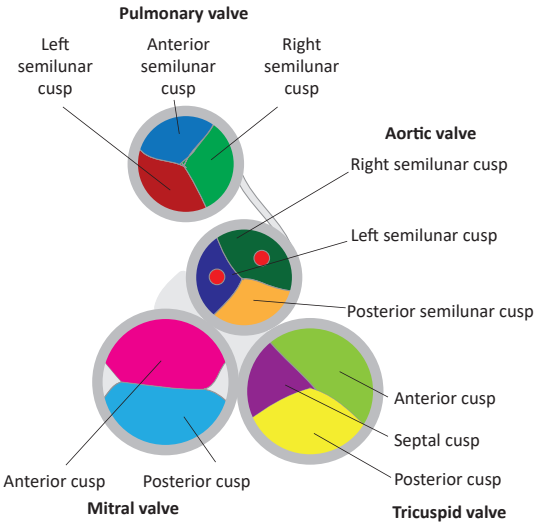

Fibrous skeleton of the heart

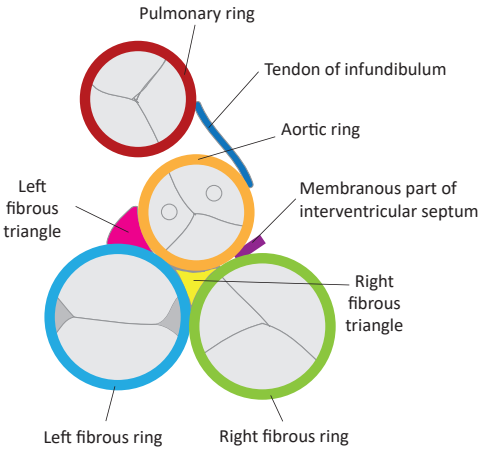

6.1.2 Conducting system of the heart

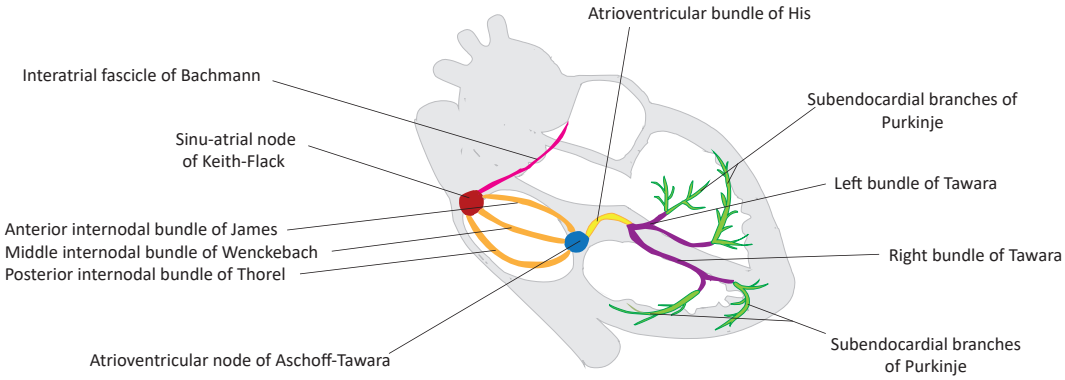

6.1.3 Venous drainage of the heart

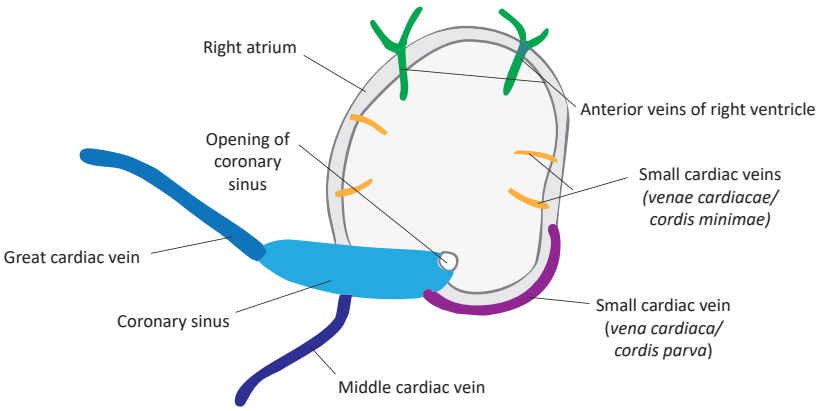

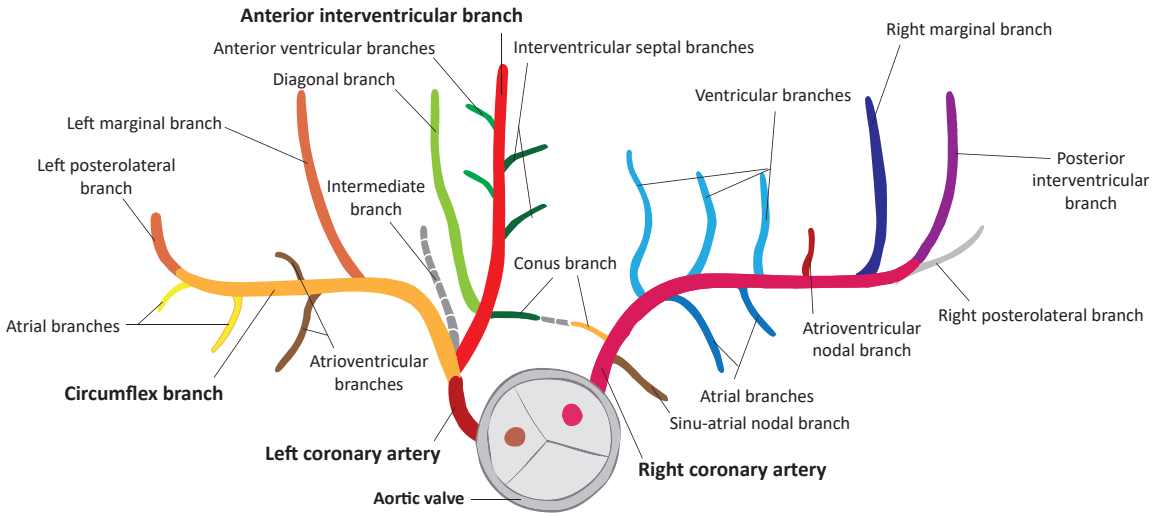

6.1.5 Foetal circulation

Basic pathway of the foetal circulation

- **Deoxygented blood**
- **Oxygenated blood:** placenta → umbilical vein → **ductus venosus** → inferior vena cava →
- **Mixed blood (high oxygen concentration):** inferior vena cava → right atrium → **foramen ovale** → left atrium → left ventricle →
- **Mixed blood (low oxygen concentration):** descending aorta → common iliac arteries → internal iliac arteries → umbilical arteries → placenta

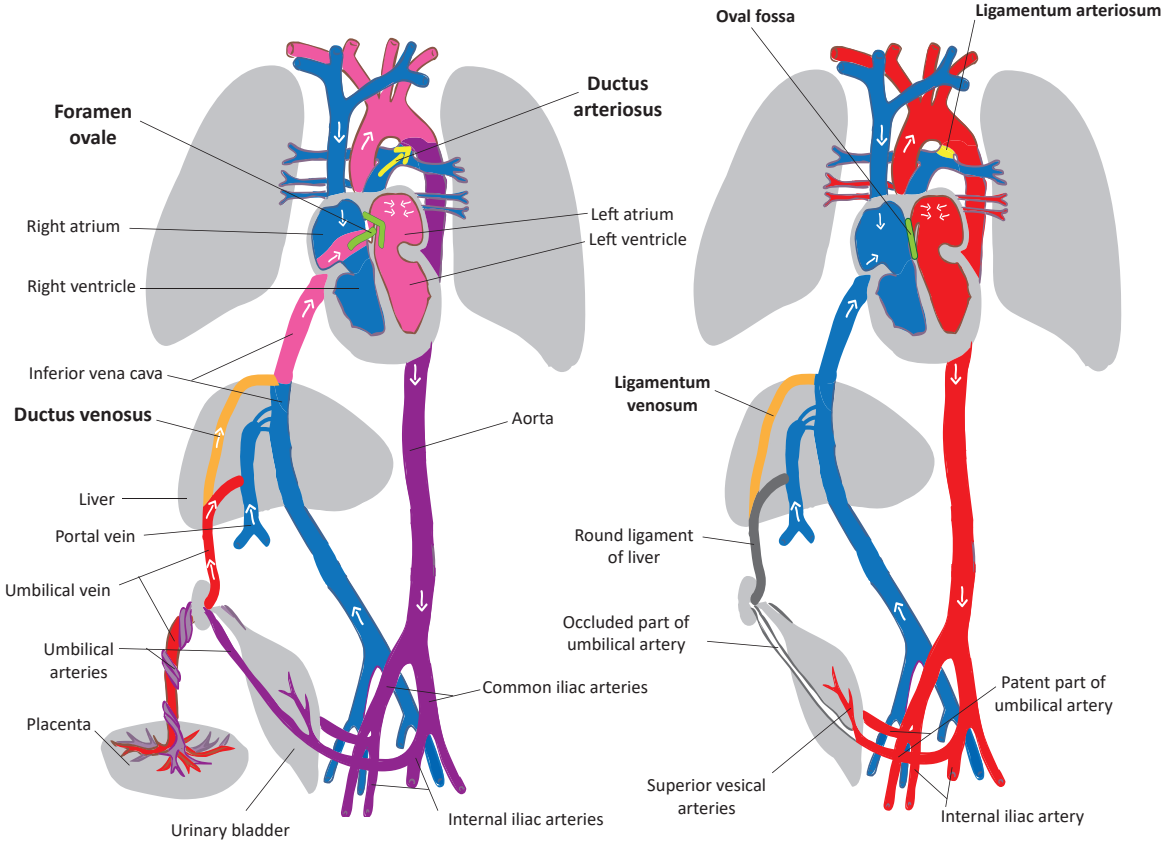

This copy belongs to ali yaghoubi

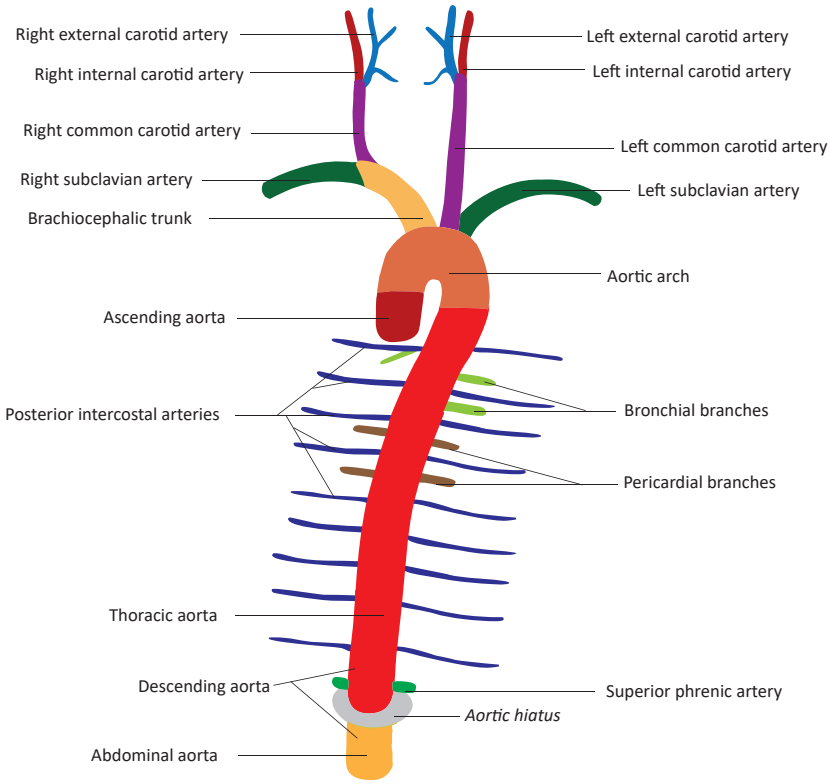

6.2.2 External carotid artery

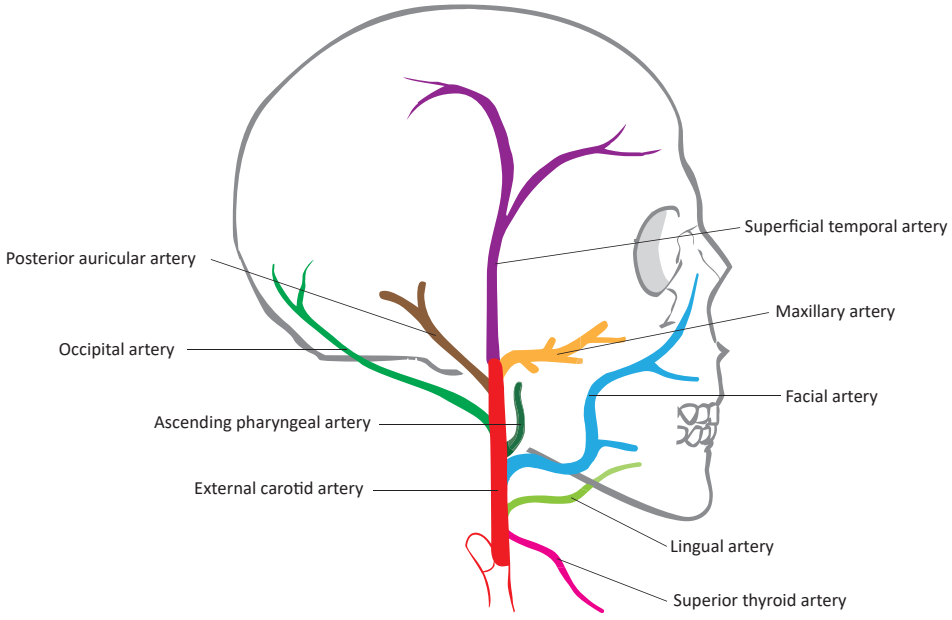

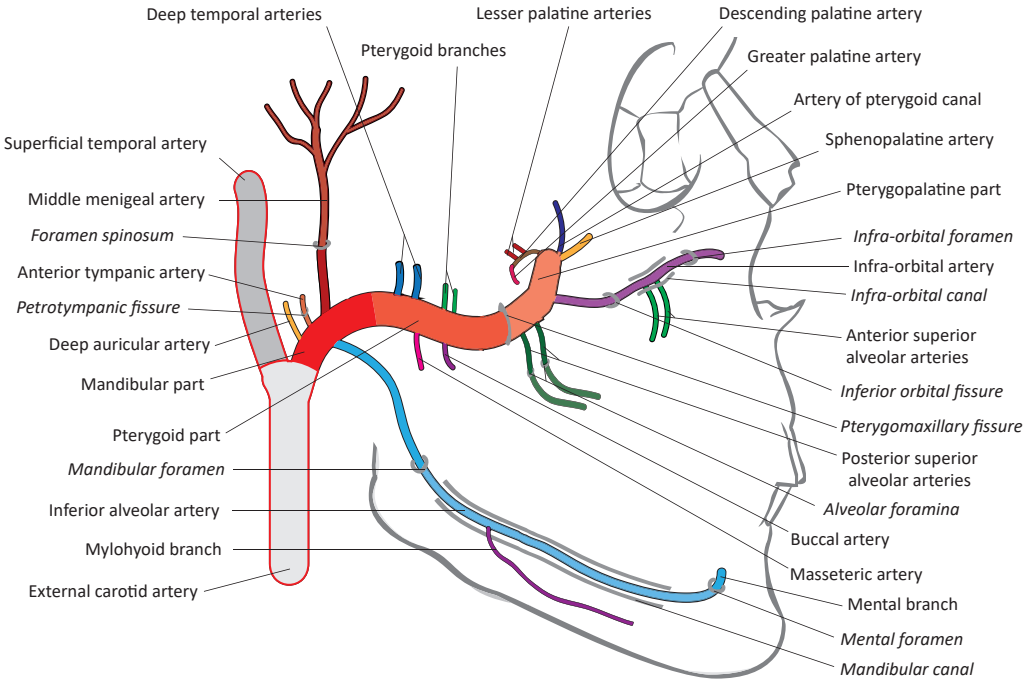

6.2.4 Subclavian artery

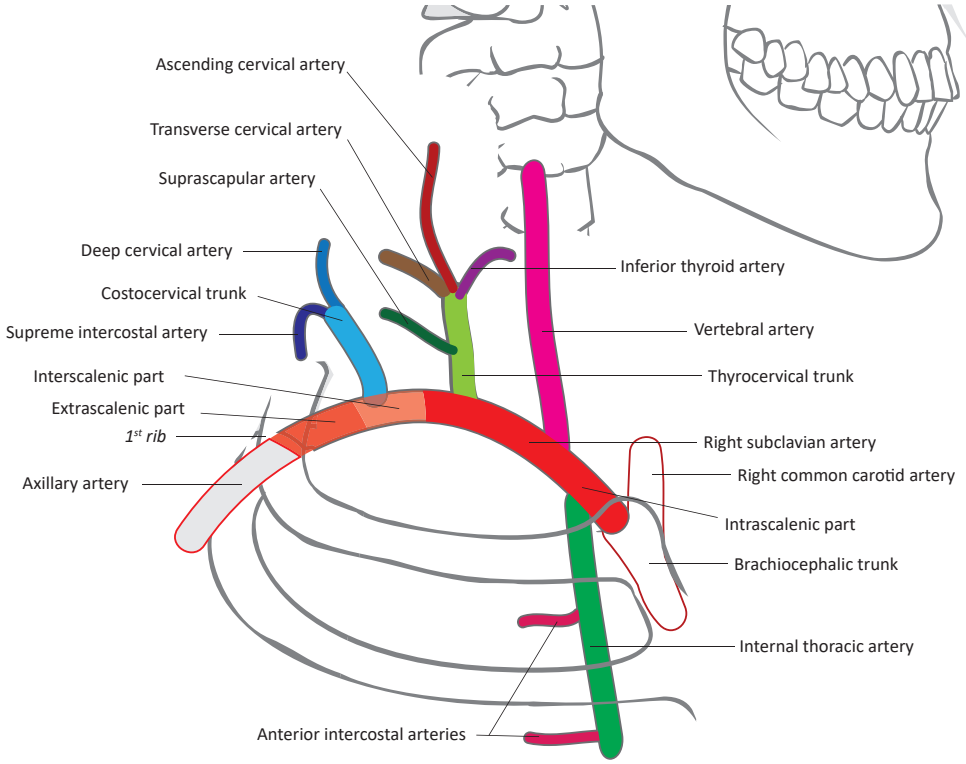

This copy belongs to ali yaghoubi

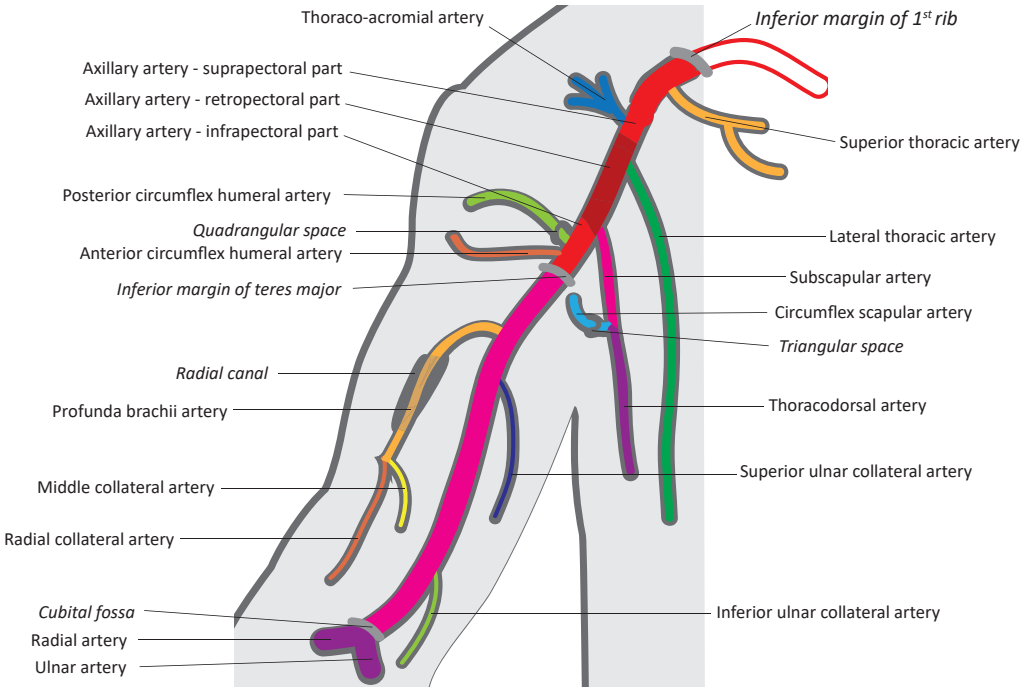

6.2.6 Radial and ulnar arteries

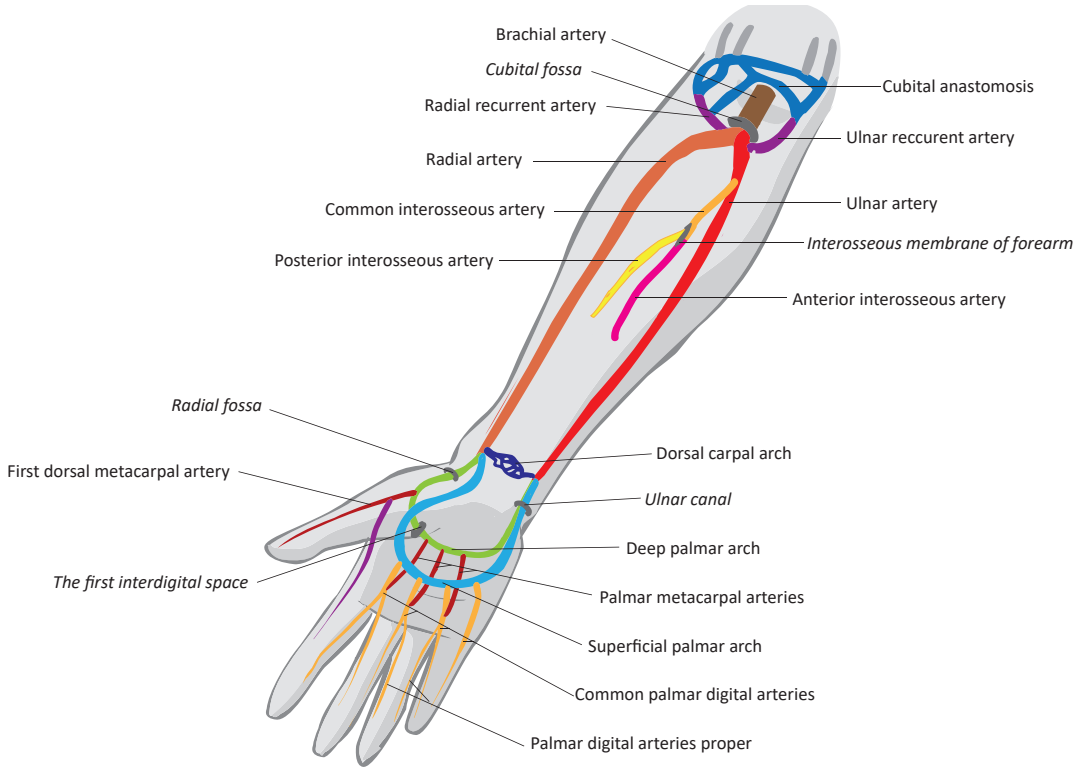

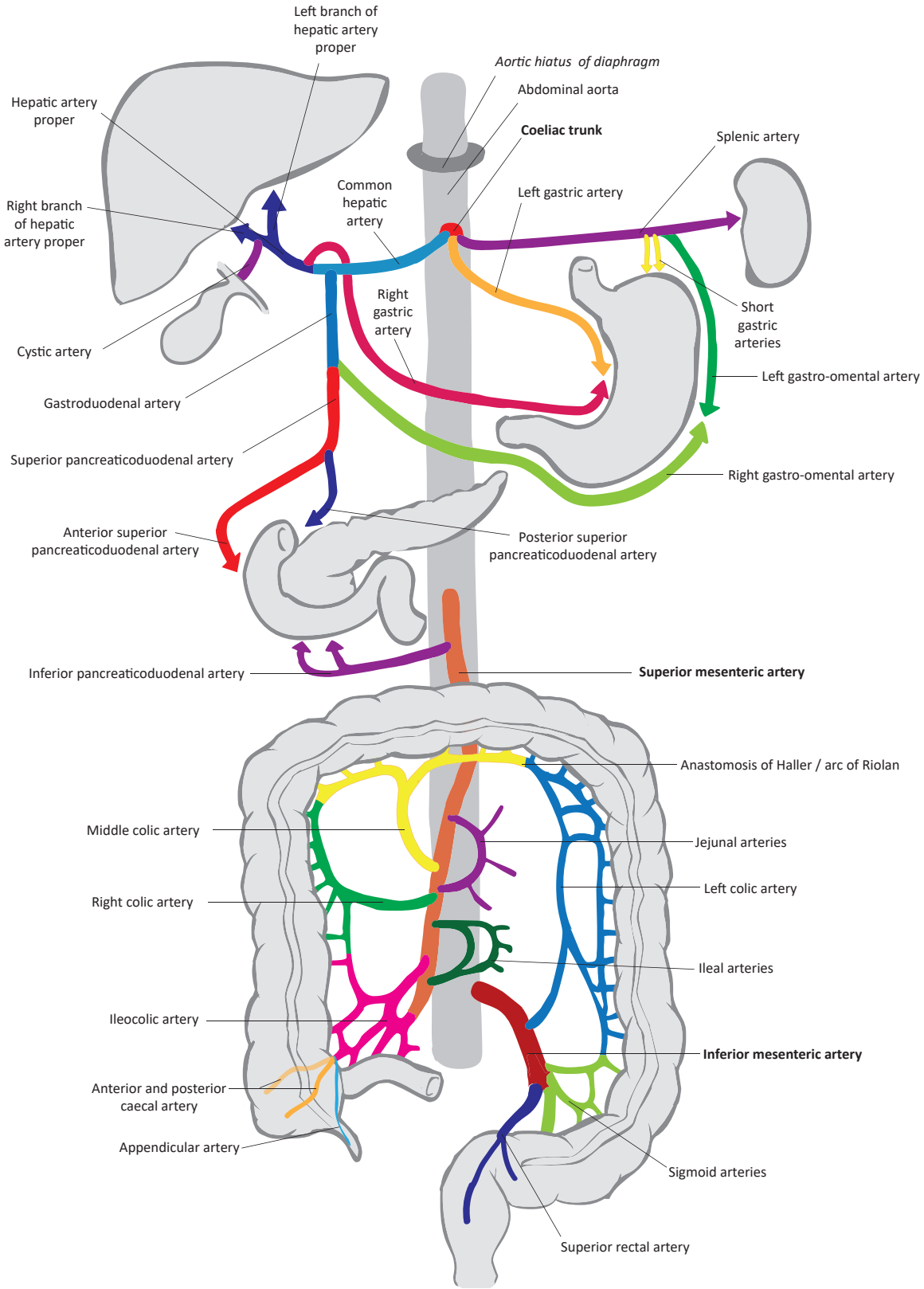

This copy belongs to ali yaghoubi

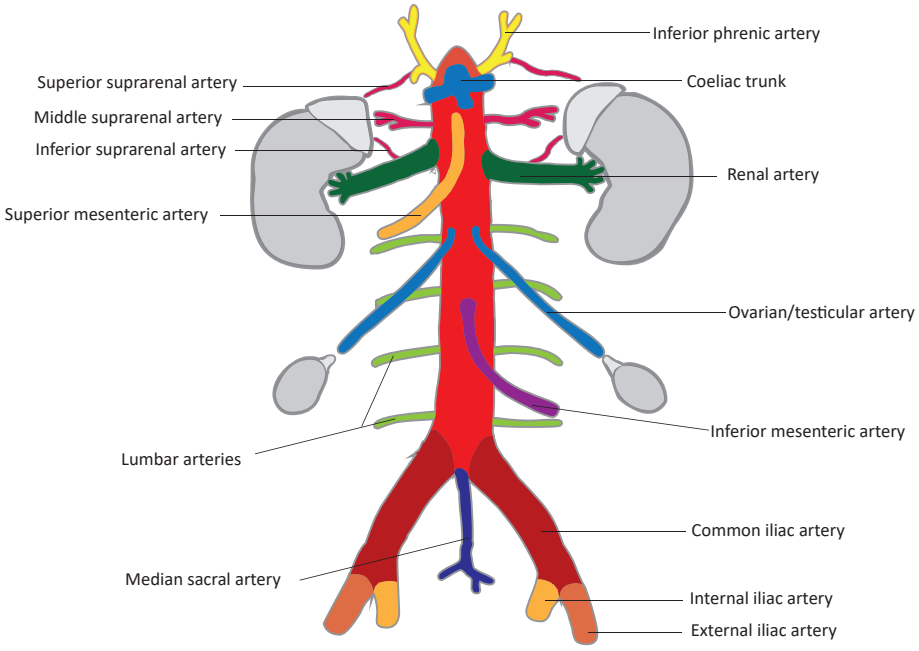

6.2.9 Internal iliac artery

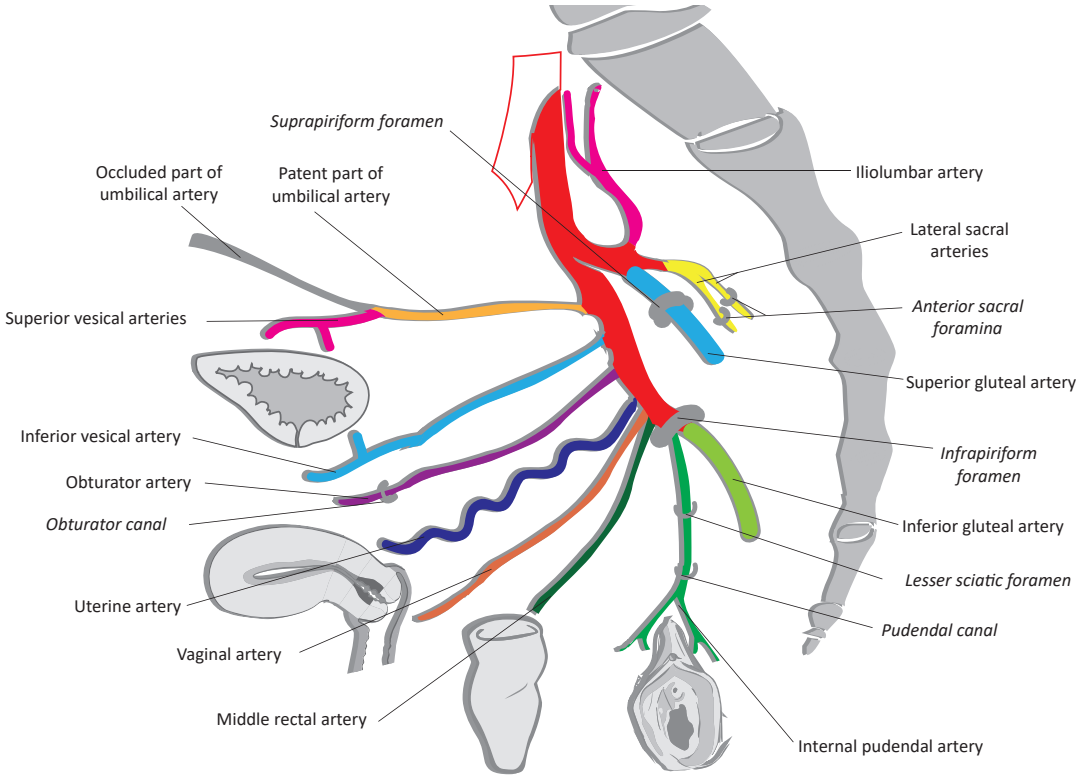

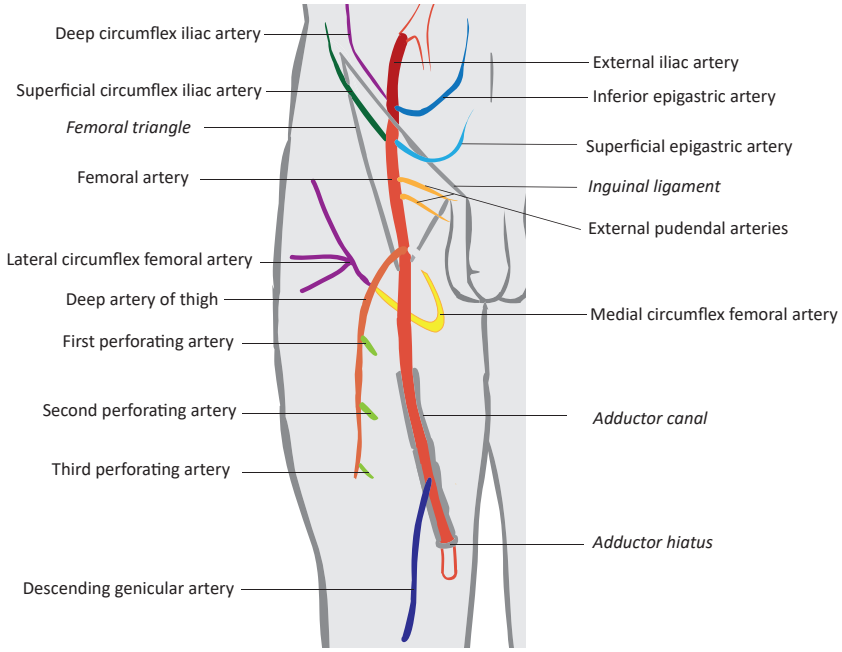

6.2.11 Popliteal artery and anterior and posterior tibial arteries

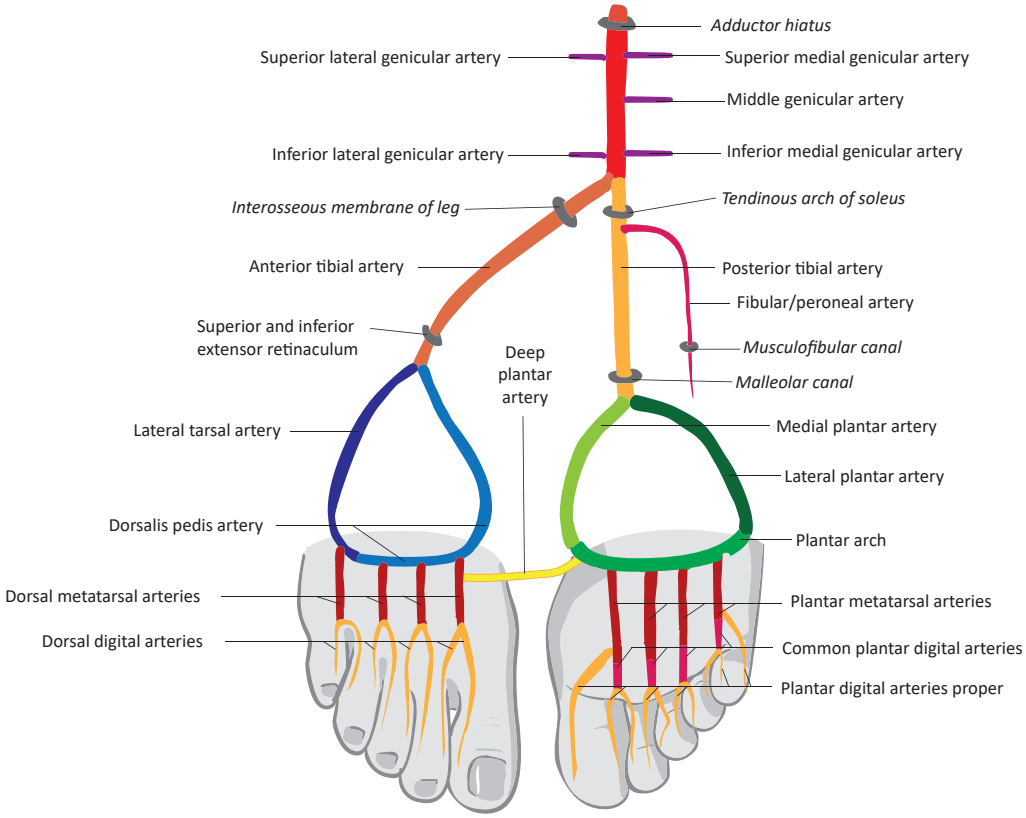

This copy belongs to ali yaghoubi

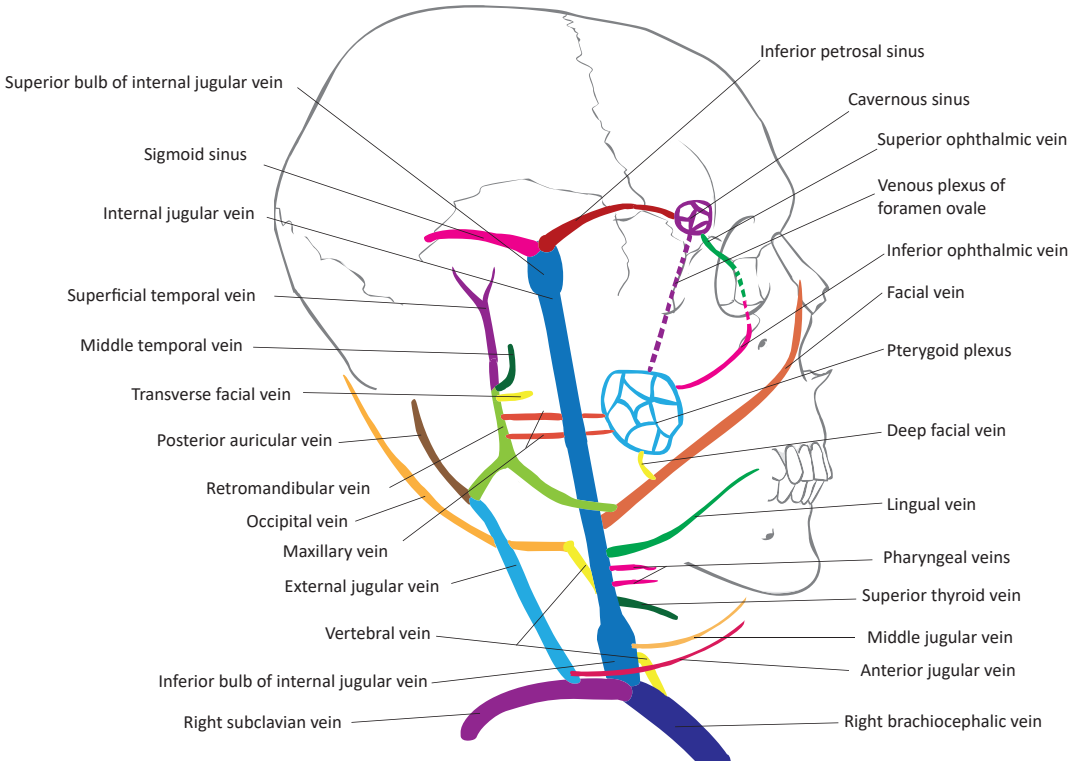

6.3 Venous drainage of the upper limb

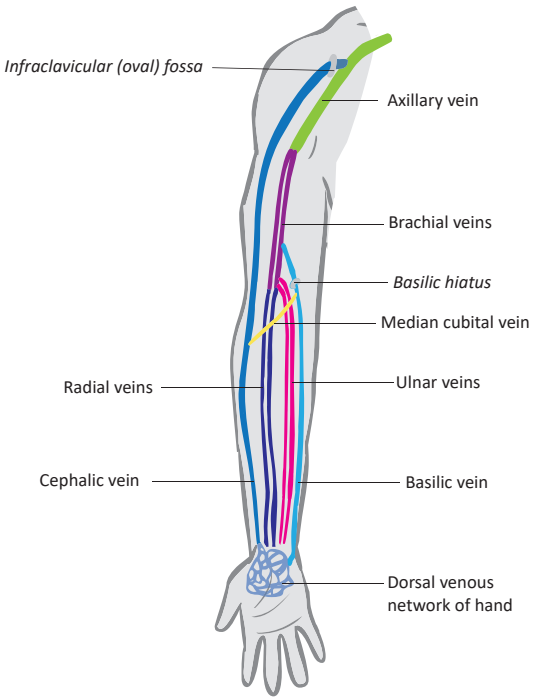

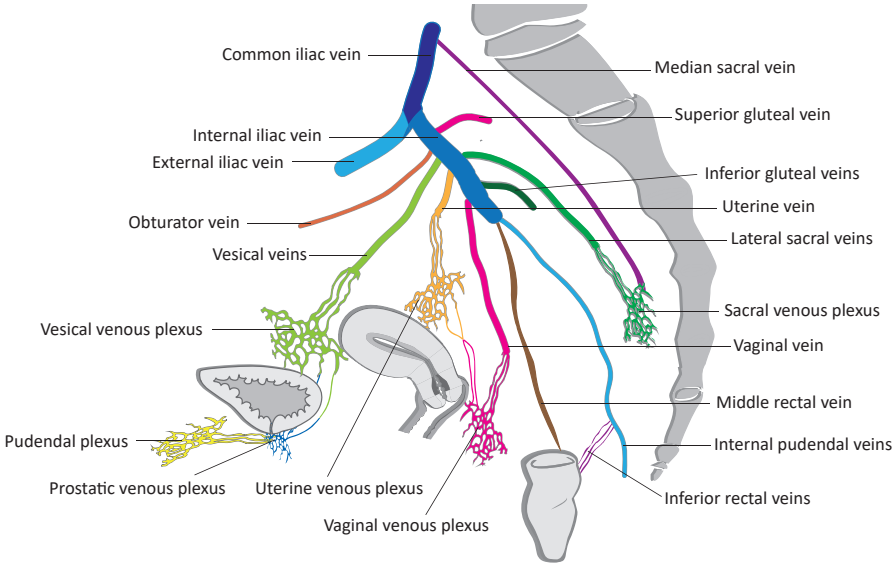

6.3 Venous drainage of the lower limb

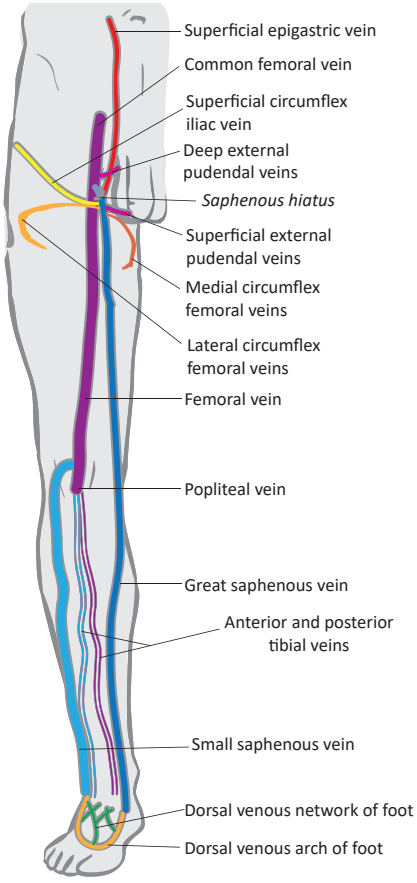

Perforators – perforating veins (*venae perforantes*)	
General structure and function	**Clinical importance**
Transfascial anastomoses that interconnect the deep (80% of blood) and superficial venous system of the lower extremity	Venous hypertension or valvular insufficiency can lead to a change of blood flow direction and subsequently cause ischemic changes
Contain valves	Varices can develop when insufficiency of valves occurs
Can be divided into 6 groups according to position (foot, ankle, leg, knee, thigh, buttocks)	Approximately 40 clinically important perforating veins (examination by ultrasound)
Simple, double or multiple	Their damage can cause venous ulcer of the leg
Accompanied by a small artery and cutaneous nerve (triad of Staubesand)	Are one of the causes of deep vein thrombosis which can lead to pulmonary embolism
The most important perforators	
Cockett's perforators – three veins called the venae perforantes cruris posteriores tibiales – interconnect the posterior accessory great saphenous vein and posterior tibial veins – 7cm, 13.5, and 18.5 proximally to the sole	
Boyd's perforator – vena perforans cruris paratibialis superior	
Dodd's perforator (adductor canal perforator) – vena perforans canalis adductorii	

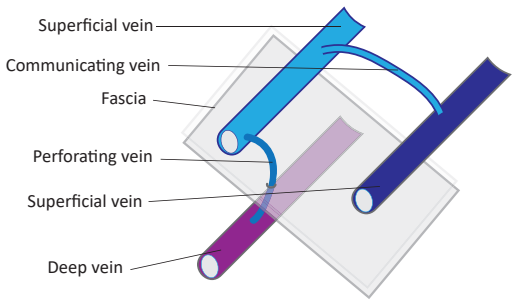

This copy belongs to ali yaghoubi

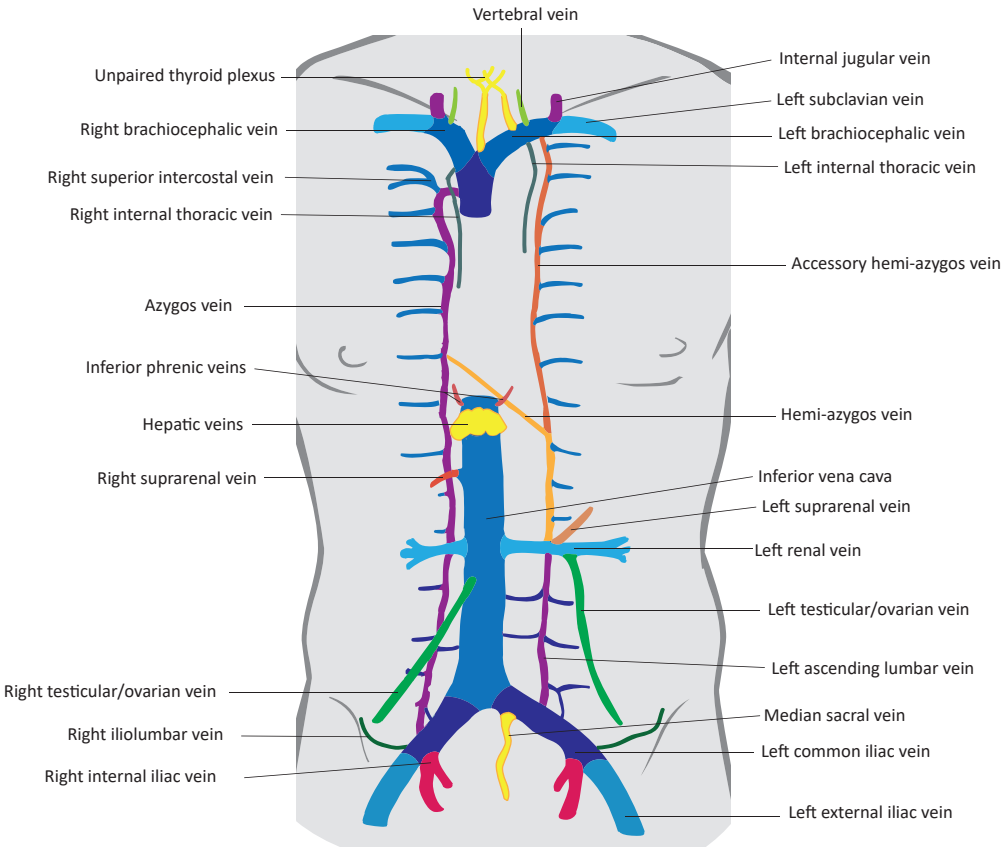

6.3 Cavo-caval anastomoses

1 **Anastomoses between the lumbar veins and azygos (hemiazygos) vein**
2 **Anastomoses between the inferior epigastric veins and superior epigastric veins**
3 **Anastomoses between the superficial epigastric veins and thoraco-epigastric veins**
4 **Anastomoses between the vertebral plexuses and other veins**

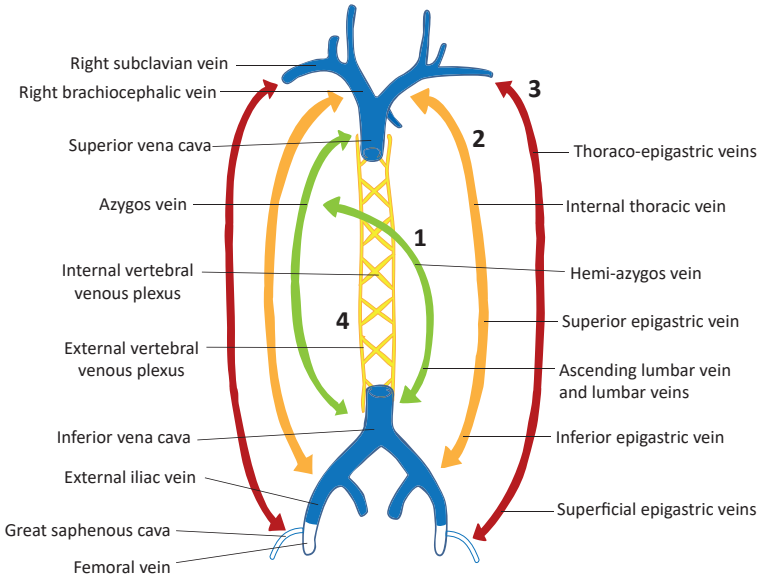

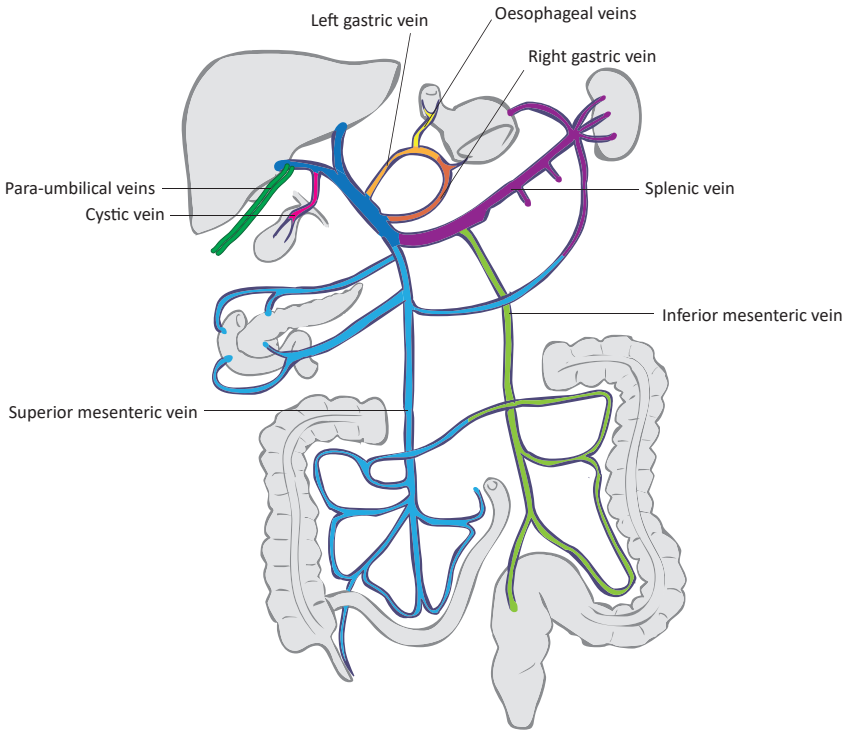

6.3 Porto-caval anastomoses

1 **Anastomoses between the gastric and oesophageal veins**
2 **Anastomoses within the rectal area**
3 **Anastomoses between the para-umbilical veins and subcutaneous veins within the umbilical region**
4 **Anastomoses between the paraumbilical veins and venous plexus surrounding the urinary bladder**
5 **Anastomoses within the retroperitoneal space**
6 **Anastomoses between the hepatic and phrenic veins**

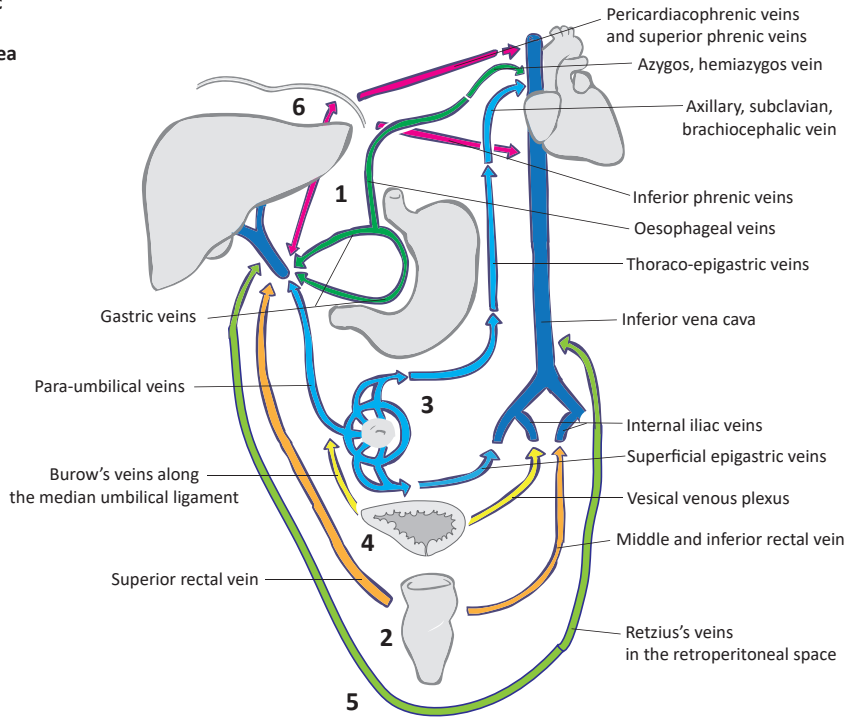

This copy belongs to ali yaghoubi

I. General structure of vessels

1. Explain the main difference between arteries and veins. (p. 264)
2. State the three types of anastomoses found in the circulatory system. (p. 264)

II. Heart

3. Describe the four layers of the heart wall. (p. 265)
4. Describe the places where the parietal and visceral serous pericardium meet. (p. 266)
5. State the surfaces of the heart and describe their features. (p. 267)
6. State the four heart grooves (sulci) and the structures passing through them. (p. 267)
7. State the venous openings in the right atrium. (p. 268)
8. State the structure positioned in the triangle of Koch. (p. 268)
9. State the parts of the interventricular septum. (p. 269)
10. Describe the course of the septomarginal trabecula. (p. 269)
11. Describe the structure that separates the right atrium from the right ventricle. (p. 269)
12. State the structure that separates the left atrium from the left ventricle. (p. 270)
13. Explain both the anatomical and functional differences between the atrioventricular and semilunar valves. (p. 272)
14. Explain the function of the papillary muscles with regard to their insertion. (p. 272)
15. Explain the three functions of the cardiac skeleton. (p. 273)
16. State the structure of the conducting system of the heart, which is also known as the pacemaker of the heart and explain what the term pacemaker means. (p. 273)
17. State the main branches of the left coronary artery. (p. 274)
18. Explain the function of the foetal shunts. (p. 275)
19. State the three foetal shunts and the vessels which they interconnect. (p. 275)

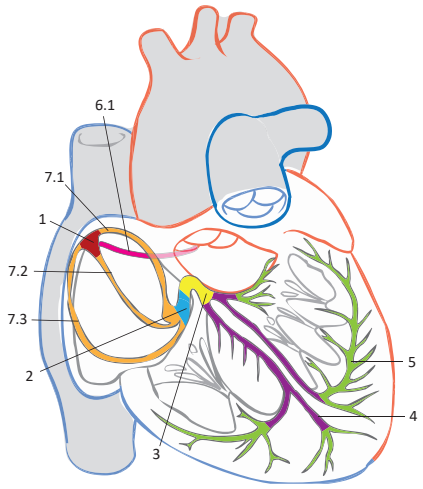

Describe the parts of the conducting system of the heart

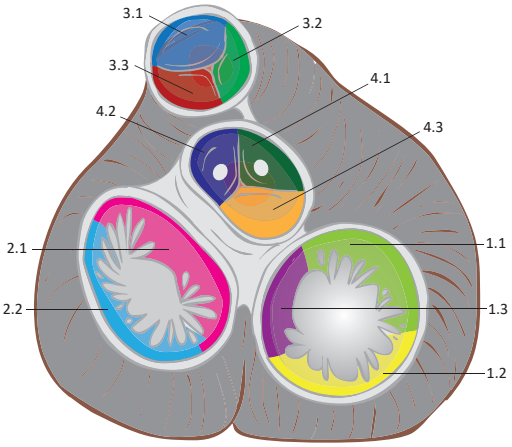

Describe the heart valves

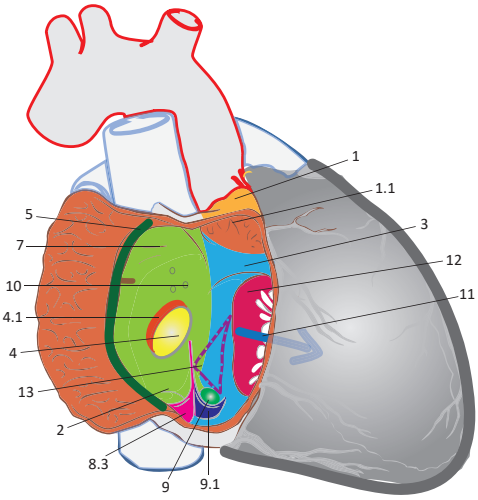

Describe the structures in the right atrium

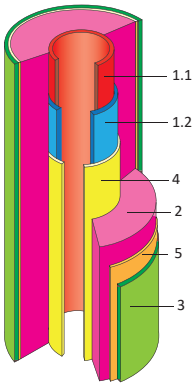

Describe the structure of the wall of a muscular artery

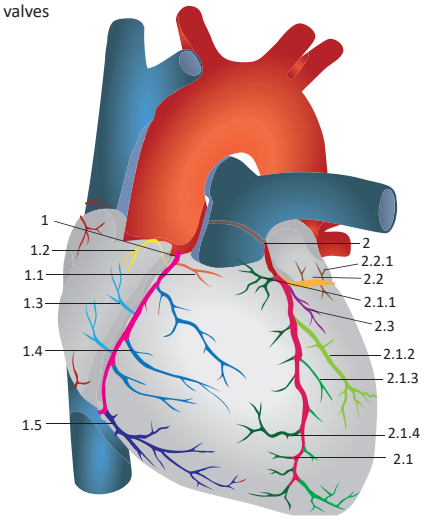

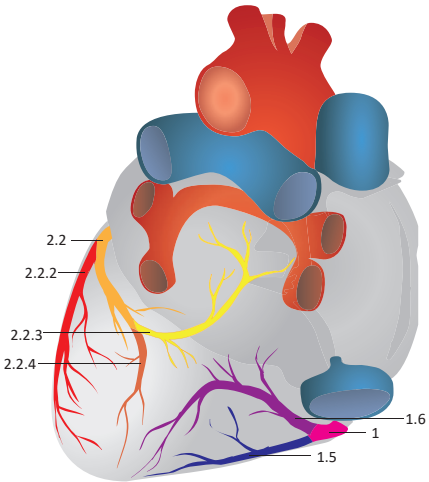

Describe the branches of the coronary arteries

III. Arteries

20. State the four parts of the aorta. (p. 277)
21. State the vessels that extend from the aortic arch and describe where they arise. (p. 277)
22. List the eight branches of the external carotid artery. (p. 278)
23. Explain the function of the carotid body. (p. 278)
24. Describe the course of the lingual artery. (p. 279)
25. Describe the parts of the maxillary artery and its course. (p. 281)
26. State the four main branches of the subclavian artery and where they arise. (p. 282)
27. Describe the topographical relationship between the suprascapular artery and the transverse scapular ligaments. (p. 283)
28. Describe the course of the radial artery. (p. 285)
29. Describe the course of the ulnar artery. (p. 285)
30. Explain the difference between the superficia and the deep palmar arch. (p. 285)
31. Describe the course of the thoracic aorta. (p. 286)
32. Describe the pattern of ramification of the abdominal aorta. (p. 287)
33. Describe the course of the abdominal aorta. (p. 287)
34. State the three branches of the coeliac trunk. (p. 288)
35. Explain the term anastomosis of Haller. (p. 288)
36. List the organs supplied by the superior mesenteric artery. (p. 289)
37. List the five parietal branches of the internal iliac artery. (p. 290)
38. State the four places where pulse on the lower extremity can be palpated. (p. 292)

IV. Veins

39. Describe the course of the superior vena cava. (p. 294)
40. List the thirteen extracranial tributaries of the internal jugular vein. (p. 295)
41. Describe the superficial venous system of the upper extremity. (p. 297)
42. State the two veins from which the portal vein is constituted. (p. 298)
43. Describe the place of origin of the portal vein. (p. 298)
44. List and describe the six portocaval anastomoses. (p. 299)
45. List and describe the four cavocaval anastomoses. (p. 299)
46. List the eight visceral tributaries of the internal iliac vein. (p. 300)
47. Describe the superficial venous system of the lower extremity. (p. 301)

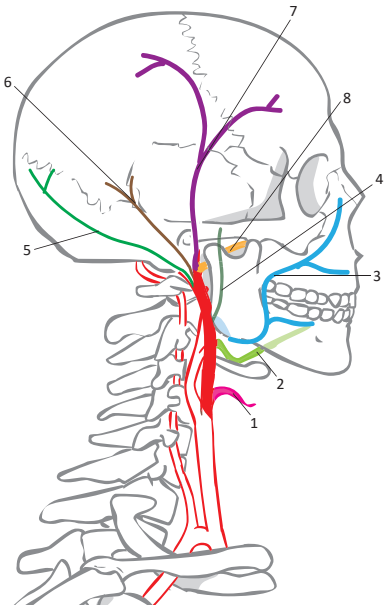

Describe the branches of the external carotid artery

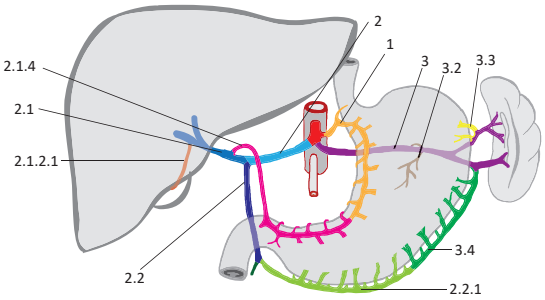

Describe the branches of the coeliac trunk

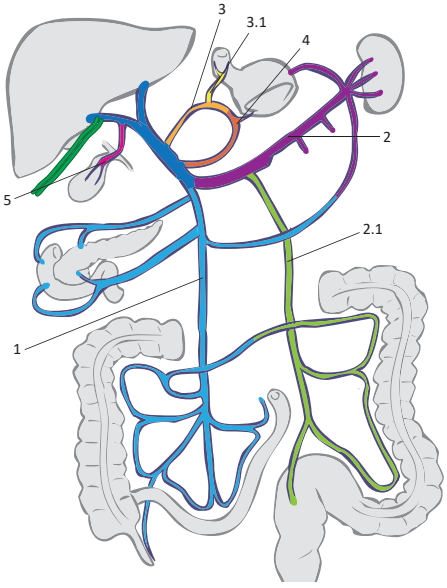

Describe the tributaries of the portal vein

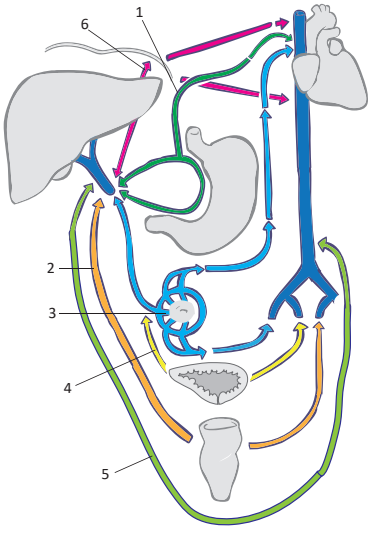

Describe the scheme of the porto-caval anastomoses

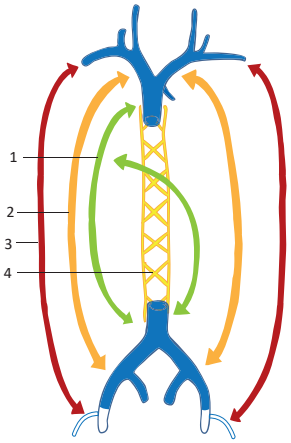

Describe the scheme of the cavo-caval anastomoses

This copy belongs to ali yaghoubi

We would like to **thank the following anatomists, physicians and medical students** for their invaluable help, devotion and feedback in the preparation of this chapter.

Anatomists

Assoc. prof. Václav Báča, MD, PhD – Department of Anatomy, Third Faculty of Medicine, Prague, Czech Republic
Assoc. prof. Květuše Lovásová, VDM, PhD – Department of Anatomy, Pavol Jozef Šafárik University, Košice, Slovakia
Marcela Bezdíčková, DSc, PhD – Department of Anatomy, Faculty of Medicine and Dentistry, Palacký University Olomouc, Czech Republic
Georg Feigl, Univ.-Ass. Dr.med. univ. – Medical University of Graz, Institute of Anatomy, Austria

Clinicians

Anna Chaloupka, MD – Department of Cardiology and Angiology, St. Anne's Faculty Hospital, Brno, Czech Republic
Štepán Jelínek, MD – Department of Vascular Surgery, Na Homolce Hospital, Prague, Czech Republic)

Medical students

Linda Kašičková
Daanish Khorasani
Jan Brtek
Danil Yershov
Ramkumar Nagarajan

9 References

1. AGUR, A. M. R. and A. F. DALLEY. Grant's Atlas of Anatomy. 13th Ed. Philadelphia: Lippincot Williams & Wilkins, 2012, 888 p. ISBN 978-1-60831-756-1.
2. BRAUNWALD, E. and R. O. BONOW. Braunwald's heart disease: a textbook of cardiovascular medicine. 9th Edition. Philadelphia: Saunders/Elsevier, 2012. 2136 p. ISBN 978-0-8089-2436-4.
3. CHUNG, K. W.; CHUNG, H. M. and N. L. HALLIDAY. BRS Gross Anatomy. 8th Ed. Philadelphia: Lippincott Williams & Wilkins, 2015. 544 p. ISBN 978-1-4511-9307-7.
4. LANZ, T. and W. WACHSMUTH. Praktische Anatomie. 7 bands. Berlin: Springer, 2003, 3658 p. ISBN 978-3-540-40571-9.
5. MILLS, S. E. Histology for pathologists. 4th Ed. Philadelphia: Lippincot Williams & Wilkins, 2012. 1328 p. ISBN-13: 978-1-4511-1303-7.
6. NETTER, F. H. Atlas of Human Anatomy. Professional Edition. 6th Ed. Oxford: Elsevier. 2014. 640 p. ISBN 978-1-455-75888-3.
7. SNELL, R. S. Clinical anatomy by regions. 9th Ed. Philadelphia: Lippincott Williams & Wilkins, 2012. 768 p. ISBN 978-1-60913-446-4.
8. WILLIAMS, P. L., ed. Gray´s Anatomy: the anatomical basis of medicine and surgery. 38th Ed. New York: Churchill Livingstone, 1995, 2092 p. ISBN 0-443-05717-6.

Memorix Anatomy

10 Lymphatic and immune systems



David Kachlík
Radovan Hudák
Ondřej Volný
Adam Whitley

General overview 318
Lymphatic vessels 319
Thymus 320
Bone marrow 320
Spleen 321
Tonsils 322
Non-encapsulated lymphoid tissue 323
Lymph nodes 323
Schemes 331
Review questions and figures 332
Acknowledgements and references 334

This copy belongs to ali yaghoubi

The lymphatic and immune systems are formed by **lymphatic vessels, organs and immune cells** with the substances secrete. Lymphatic vessels are responsible for **unidirectional drainage of extracellular fluid into the bloodstream.** They originate as blind-ended tubes in intercellular spaces (lymphatic capillaries), which drain into the larger lymphatic vessels before gathering into lymphatic trunks and flowing into the two main lymphatic ducts ducts. Lymphatic fluid (or simply "lymph") is drained at the venous angle into the venous systemic blood. The lymphatic vessels are located in almost every tissue **except for cartilage, cornea, bone marrow, placenta and the central nervous system**. In these sites drainage of extracellular fluid occurs in a different way.
The lymphatic system is integrally related to the immune system. They cooperate together in forming immune reactions that protect the body from infections, cancerous growths and toxic substances.

Function

Lymphatic system

1. **immune function:** cellular and humoral immunity (antibody-mediated immune system)
2. **extracellular fluid drainage** into the systemic blood circulation
3. **transport of proteins, chylomicrones and fatty acids** into the systemic blood circulation
4. **elimination of senescent erythrocytes** by macrophages in the spleen (90 %), bone marrow and liver

Immune system

Primary immune organs

1. **de novo genesis of immune cells** the site of the process of differentiation and maturation
2. **the bone marrow is responsible for the production of all immune cells** (granulocytes, monocytes and lymphocytes)

Secondary immune organs

1. responsible for **interaction between naive lymphocytes and antigen-presenting cell** (APC)
2. initiation of **specific immune responses** and **genesis** of immune memory cells
3. responsible for **the production of effective lymphocytes against specific agents**

Organs

Primary (central) organs

- 1 **Thymus**
- 2 **Bone marrow** (*medulla ossium*)

Secondary (peripheral) organs

- 3 **Spleen** *(splen/lien)*
- 4 **Tonsils** (*tonsillae*)
- 5 **Lymph nodes** (*nodi lymphoidei*)
- 6 **Lymphoid nodules** (*noduli lymphoidei*)

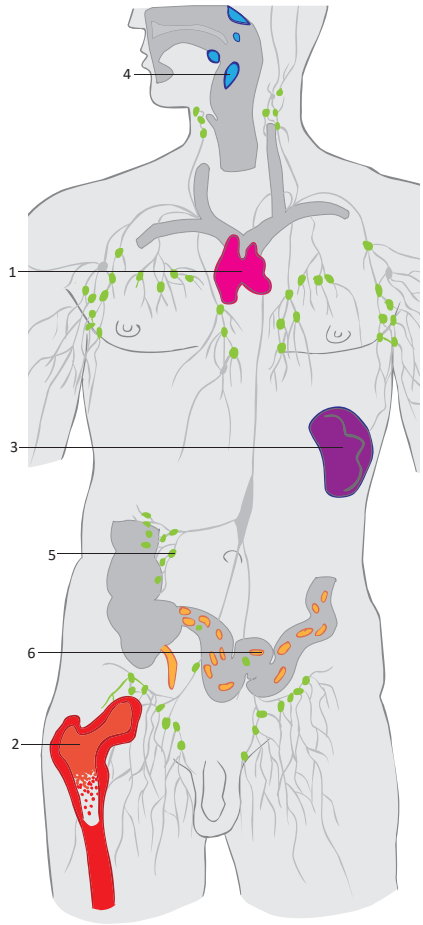

Daily production of lymph is about 60 ml/kg.

Lymph *(lympha)* is formed from interstitial fluid that flows into lymphatic capillaries. It is fundamentally different and easily distinguishable from plasma by its relative lack of protein.

Chylus is intestinal lymph. It has a milky appearance and contains chylomicrons.

Chylomicrons are products of enterocytes. They transport triacylglycerol and cholesterol from the intestinal lumen through lymphatic vessels into the bloodstream.

The central nervous system does not contain any lymphatic vessels. Instead, interstitial fluid drains to the outside of the brain alongside the pulsating cerebral arteries, through the cribriform plate of the ethmoidal bones and also partially into the CSF.

Embryonic development of the lymphoid organs:
The thymus is derived from the endoderm of the ventral part of the third pharyngeal pouch. Cells from the neural crest also contribute to its development.
The spleen develops by an accumulation of mesenchyme cells within the dorsal mesogastrium.
The tonsils arise from the endoderm of the second pharyngeal pouch. In the 3rd month of intrauterine life the epithelium forms a reticular framework. This is followed by migration of lymphocytes, which form lymphoid nodules.
Lymph nodes develop either from collapsing lymphatic sacs during the third month (primary lymph nodes) or from aggregations of mesenchymal cells that proliferate along capillary plexuses (secondary lymph nodes).

Clinical notes

Lymphography (lymphangiography) is a medical imaging technique in which lymphatic vessels and lymph nodes are visualised injecting contrast dye and taking X-ray pictures.
Lymphoscintigraphy is a similar technique performed by injecting radioisotopes and imaging with positron emission tomography (PET) scans.

Lymphoedema is swelling due to congestion of lymphatic fluid. It occurs when lymph drainage is insufficient and may progress to elephantiasis, a condition where parts of the skin, subcutaneous tissues or entire regions (scrotum, limbs) swell up to large or even massive proportions.

Lymphatic capillaries are blind-ended tubes with a special microscopic structure that ensures a **unidirectional flow of extracellular fluid**. Lymphatic capillaries drain into the bigger lymphatic vessels. **Lymph nodes are found along the network of lymphatic vessels**. Lymphatic vessels contain valves, which supports the unidirectional fluid to the lymphatic trunks and ducts. **The lymphatic ducts** drain lymph into the venous blood at the venous angle.

1 **Lymphatic capillaries** (*vasa lymphocapillaria*)
- collect extracellular fluid with metabolic substances, antigens (viruses, bacteria and/or pre-tumor or tumor cells) and antigen-presenting cells
- form a lymphocapillary network *(rete lymphocapillare)*, whose wall is made of only one layer of endothelium (running together with blood capillaries and venules; in the small intestine, run in the axis of a villus)

2 **Lymphatic vessels** (*vasa lymphoidea*)
- are thin-walled vessels containing valves
- their course is interrupted by lymph nodes
- in organs, there are subcapsular and deep lymphatic networks
- in extremities, there are superficial and deep collectors accompanying particular veins
  - the superficial collectors are located in subcutaneous tissue and empty into the cubital and axillary nodes in the upper limb, and the popliteal and inguinal nodes in the lower limb
  - the deep collectors run together with the deep vessels

2.1 **Collectors of the upper extremity**
- 2.1.1 **Lateral collectors** – to the axillary lymph nodes along the cephalic vein
- 2.1.2 **Medial collectors** – to the axillary lymph nodes along the basilic vein (drain the superficial cubital lymph nodes of the cubital region)
- 2.1.3 **Anterior collectors** – to the superficial cubital lymph nodes along the median antebrachial vein

2.2 **Collectors of the lower extremity**
- 2.2.1 **Medial collectors** (10–15) – to the superficial inguinal lymph nodes, along the great saphenous vein
- 2.2.2 **Lateral collectors** (1–3) – to the superficial inguinal lymph nodes, along the tributaries of the great saphenous vein
- 2.2.3 **Posterior collectors** (2–3) – to the superficial popliteal lymph nodes, along the small saphenous vein

2.3 **Deep lymphatic vessels** – accompany the deep vessels of the lower extremity,
- to the deep popliteal lymph nodes and the deep inguinal lymph nodes

3 **Lymphatic trunks** (*trunci lymphatici*)

Paired
- 3.1 **Jugular trunk** (*truncus jugularis*)
  - lymphatic drainage from half of the head and neck
- 3.2 **Subclavian trunk** (*truncus subclavius*) – lymphatic drainage from the collectors of the upper extremity
  - the axillary lymphatic plexus is a network of lymphatic vessels and lymph nodes in the axilla, which drains in the subclavian trunk
- 3.3 **Bronchomediastinal trunk** (*truncus bronchomediastinalis*)
  - lymphatic drainage from half of the thorax
- 3.4 **Lumbar trunk** (*truncus lumbalis*) – lymphatic drainage from the lower extremity and half of the pelvis

Unpaired
- 3.5 **Intestinal trunk** (*truncus intestinalis*)
  - lymphatic drainage from the unpaired abdominal organs

4 **Lymphatic ducts** (*ductus lymphatici*) – irregular drainage areas
- 4.1 **Right lymphatic duct** (*ductus lymphaticus dexter*)
  - **a short duct originating from the 3 main lymphatic trunks:** the right jugular, right subclavian and right bronchomediastinal trunks
  - **collects lymph** from the right half of the head and neck, right upper extremity and right half of the thoracic cavity
  - **there is an exception:** lymphatic drainage from the right half of the heart goes to the thoracic duct
- 4.2 **Thoracic duct** (*ductus thoracicus*)
  - **originates from the lumbar trunks**
  - **collects lymph** from both lower extremities, pelvis, abdominal cavity, the left half of the thoracic cavity, left upper extremity and the left half of the head and neck
  - **is divided into 4 parts according to its course**: lumbar, abdominal, thoracic and cervical parts
    - 4.2.1 **Cisterna chyli** – a widened situated at the beginning of the thoracic duct at the level of T11–L1
  - **there is an exception:** lymphatic drainage from the 4th to 10th segment of the left lung and left half of the heart runs to the right lymphatic duct

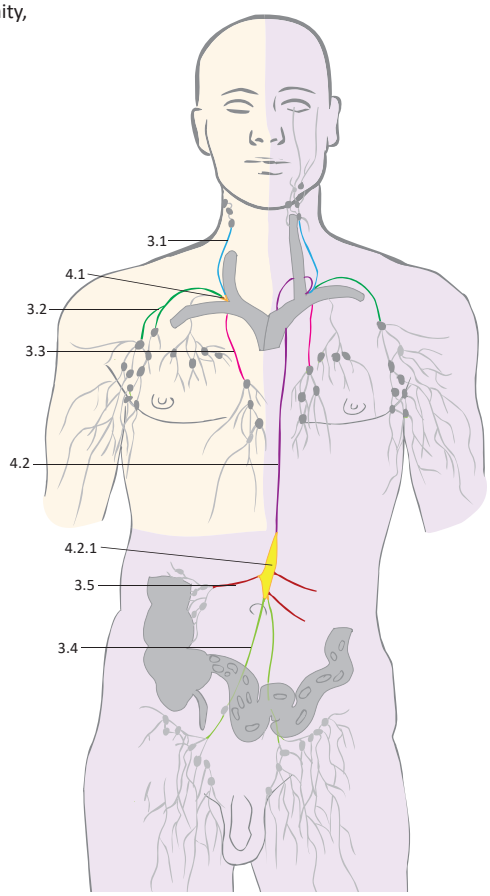

This copy belongs to ali yaghoubi

The thymus is a lymphoepithelial organ located in the **ventral part of the superior mediastinum** just behind the sternum. It contains T-lymphocytes undergoing maturation. The T-lymphocytes are selected in the thymus to recognise self from non-self, meaning they are programmed to recognise and attack foreign antigens that may be a potential threat to the organism. **The thymus is the largest and most active during the neonatal period. During the teenage years it begins to atrophy and involute**. After the age of around fifty, the thymus is almost completely replaced by an adipose tissue. However, residual thymus tissue may persist throughout the rest of life.

Structure

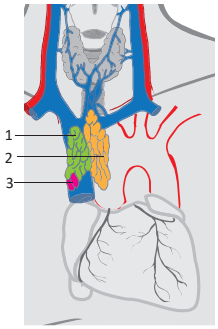

- 1 **Right lobe** (*lobus dexter*)
- 2 **Left lobe** (*lobus sinister*)
- 3 **Lobules** (*lobuli*)
  4 **Cortical septa** (*septa corticalia*) – bands of mediastinal fibrous tissue in the cortex
  5 **Cortex** – composed mainly of T-lymphocytes
  6 **Medulla** – contains epithelial reticular tissue, fewer T-lymphocytes and corpuscles of Hassal

Function

1. **Programming of T cells progenitors**
2. **central tolerance** – distinction between self and non-self antigens
3. **most of the T-lymphocytes are eliminated** by apoptosis (programmed cell death) during the process of positive and negative selection
4. **selected T-lymphocytes migrate to the secondary lymphatic organs**
5. **endocrine function:** influences T-lymphocyte proliferation and maturation, regulates their functions and influences the migration of macrophages

The weight of the thymus is age related. In newborns it is 16 g (10–35 g), in adults 20–50 g and among the elderly 5–15 g.

Hassall's corpuscles / thymic corpuscles are structures in the medulla of the thymus. Their function is still not fully known.

The size of the spleen is 10–13 cm in length, 6–8 cm in width and 4 cm in thickness.

The weight of the spleen is 140–160 g in men and 120–150 g in women. A weight of even 200 g can still be considered physiological because the weight is highly dependent on the extent of blood flow.

Clinical notes

A sternal puncture is a diagnostic procedure in which a needle is inserted into the bone marrow of the manubrium of the sternum to collect a sample for cytological evaluation in blood disorders and malignancies.

A trephine biopsy is a procedure in which a cylindrically shaped core of bone is obtained for histopathological evaluation. Unlike sternal puncture, this procedure shows the structure and cellularity of the bone marrow including its supportive connective tissue, which can help to diagnose on-going disorders. In children up to the age of two, bone marrow from the tibia is collected.In the elderly, samples are drawn from the hip bone, usually from the area of the posterior superior iliac spine and occasionally from the anterior superior iliac spine.

Splenomegaly is the pathological enlargement of the spleen. It has a wide variety of causes such as viral mononucleosis, liver disease, lymphoma and leukaemia.

2-stage rupture of the spleen is a life threatening situation and a diagnostic challenge in closed abdominal trauma. After injury to the pulp, the splenic parenchyma ruptures and blood accumulates under the capsule. The pressure under the capsule rises and eventually causes the capsule to rupture, which causes blood to spill out into the peritoneal cavity.

Splenectomy is the surgical removal of the spleen. Without the spleen the human body is susceptible to infections caused by encapsulated bacteria such as pneumococcus, meningococcus and haemophilus. Thus vaccination against these pathogens is paramount.

4 Bone marrow – Medulla ossium

From the eight month of intrauterine development, **bone marrow is the sole organ of haematopoiesis**. It is situated **inside the medullary cavity in long bones and between the trabeculae of cancellous bone**. Throughout life, bone marrow slowly transforms from active hematopoietic red marrow into inactive adipose yellow marrow .

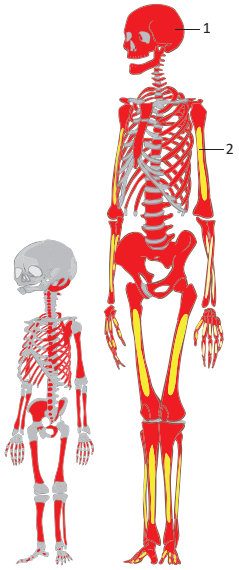

- 1 **Red marrow** (*medulla osseum rubra*)
  – **the main haematopoietic organ**
  – contains stem cells, which differentiate into leukocytes, erythrocytes and megakaryocytes
  – platelets (thrombocytes) are formed by disintegration of megakaryocytes
  – **the reticular framework of bone marrow** is composed of reticular connective tissue, sinusoids formed by endothelial cells and macrophages
  – **at the age of 20 red marrow is replaced by yellow marrow** in the medullary cavity of all long bones except for the proximal ends of the humerus and femur
  – **red marrow persists in cancellous bone** in the epiphyses of long bones, short bones and flat bones (pelvis, sternum, ribs and in the diploe of certain regions of the skull)

- 2 **Yellow marrow** (*medulla osseum flava*)
  – is composed of reticular connective tissue with a high content of adipocytes
  – has the ability to reactivate into red marrow

The spleen is the largest secondary lymphoid organ. **It is active in the initiation of immune reactions against antigens filtered from the blood stream and participates in the degradation of blood cells**. It is an **intraperitoneal organ**, located in the left hypochondrium in the area between the 9th and 11th rib. The pleural cavity extends behind the diaphragmatic surface of the spleen. In a healthy human, the spleen is not palpable during physical examination.

External structure

- 1 **Posterior extremity** (*extremitas posterior*) – the dorsal end of the spleen
- 2 **Anterior extremity** (*extremitas anterior*) – the ventral end of the spleen
- 3 **Superior border** (*margo superior*) – the upper front sharp margin
- 4 **Inferior border** (*margo inferior*) – the lower back more obtuse margin
- 5 **Splenic hilum** (*hilum splenicum*) – the entry point for the splenic vessels and nerves
- 6 **Diaphragmatic surface** (*facies diaphragmatica*)
  – the dorsocranial surface adjacent to the diaphragm
- 7 **Visceral surface** (*facies visceralis*) – the ventral surface in contact with the stomach, left kidney, pancreas and left colic flexure (splenic flexure)
- 8 **Splenic recess of omental bursa** (*recessus splenicus bursae omentalis*)

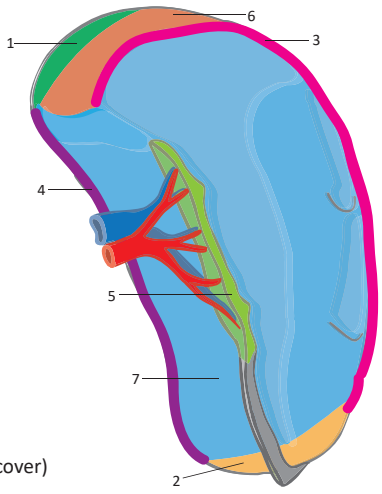

Supporting ligaments

1 **Splenorenal/lienorenal ligament** (*ligamentum splenorenale*) – between the spleen and kidney
2 **Gastrosplenic ligament** (*ligamentum gastrosplenicum*) – between the spleen and stomach
3 **Splenocolic ligament** (*ligamentum splenocolicum*) – between the spleen and transverse colon

Internal structure

- 1 **Serosa / serous coat** (*tunica serosa / peritoneum viscerale*) – the peritoneum (a thin outer cover)
- 2 **Capsule** (*tunica fibrosa*) – fibrous capsule (thick inner cover)
  - 2.1 **Splenic trabeculae** (*trabeculae splenicae*)
    – fibrous septa extending from the capsule into the parenchyma
- 3 **Splenic pulp** (*pulpa splenica*) – the main substance of the spleen
  - 3.1 **White pulp** (*pulpa alba*)
    – **Periarteriolar lymphoid sheath** (*vagina lymphoidea periarteriolaris* – PALS)
    – populated largely by T-lymphocytes
    – **Marginal zone** (*zona marginalis*) – a region composed of macrophages (antigen-presenting cell) and B-lymphocyte
    – **Splenic lymphoid nodules** (*noduli lymphoidei splenici*) – contain many lymphocytes
  - 3.2 **Red pulp** (*pulpa rubra*) – is composed of connective tissue
    – constitutes the splenic cords of Billroth and the splenic sinuses between them

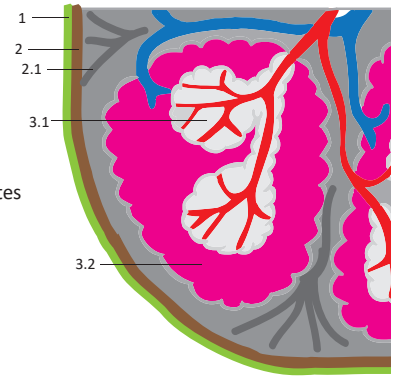

Cross section of the spleen

Functions

– elimination of microorganisms from the blood
– specific immune reaction against antigens filtered from blood
– activation and proliferation of lymphocytes and synthesis of antigens and antibodies
– degradation of erythrocytes and trombocytes
– erythropoiesis until the 7th month of intrauterine life

Blood supply

Arterial supply:

Splenic artery (*arteria splenica*), which branches into:

1. **Splenic branches** (*rami splenici*)
2. **Trabecular arteries** (*arteriae trabeculares*)
3. **Sheathed arteries of white pulp** (*arteriolae vaginatae pulpae albae*)
   – within the periarteriolar lymphoid sheath
4. **Central (nodular) arterioles** (*arteriolae centrales/nodulares*)
5. **Penicillar arteries** (*arteriolae penicillares*)
6. **Penicillar arterioles** (*arteriolae penicillares*)
7. **Open circulatory system** – blood is flows freely into the red pulp and then into the splenic sinuses
8. **Close circulatory system** – blood is kept within the splenic sinuses
9. **Sinusoids** (*vasa sinusoidea splenica*) – in the red pulp

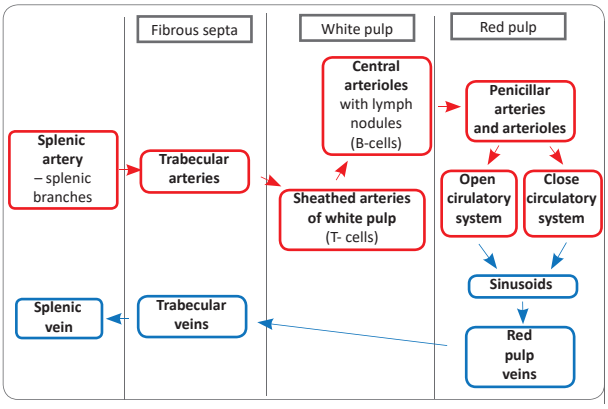

Scheme of the vascular supply of the spleen

Venous drainage:

– **the red pulp veins** (*venae pulpae rubrae*) into the **trabecular veins** (*venae trabeculares*)
– then to the **splenic vein** (*vena splenica*) and into the portal vein (*vena portae*)

This copy belongs to ali yaghoubi

The tonsils form a **protective barrier** against foreign pathogenic particles at the **entrance to the respiratory and digestive tracts**. The tonsils are composed of small lymphoid nodules with germinal centres. They are located under the mucosa of the pharynx and root of the tongue and are arranged in a ring shape, called the **pharyngeal lymphoid ring / Waldeyer's ring** *(anulus lymphoideus pharyngis)*. This ring is connected caudally to the lymphoid tissue of the larynx.

Pharyngeal lymphoid ring (*anulus lymphoideus pharyngis Waldeyeri*)

Unpaired tonsils

- 1 **Pharyngeal/nasopharyngeal tonsil / adenoid** (*tonsilla pharyngealis*)
  - **location:** the vault of the pharynx (*fornix pharyngis*)
  - **structure:** pits (*fossulae*), crypts (*cryptae*) and nodules (*noduli*)
  - is coated with a thin capsule
- 2 **Lingual tonsil** (*tonsilla lingualis*)
  - **location:** the root of the tongue (*radix linguae*)
  - **structure:** crypts (*crypta*) and nodules (*noduli*)

Geminate tonsils – bilateral tonsils

- 3 **Palatine tonsil** (*tonsilla palatina*)
  - **location:** the back of the throat in the tonsillar fossa (*fossa tonsillaris*) behind the palatoglossal arch (*arcus palatoglossus*) and in front of the palatopharyngeal arch (*arcus palatopharyngeus*)
  - **structure:** pits (*fossulae*), crypts (*cryptae*)
  - coated with a thick capsule
  - located within a large tonsillar bed

- 4 **Tubal tonsil** (*tonsilla tubaria*)
  - **location:** near the pharyngeal opening of the auditory tube (*ostium pharyngeum tubea auditivae*)
  - **structure:** crypts (*cryptae*)
  - the smallest tonsil

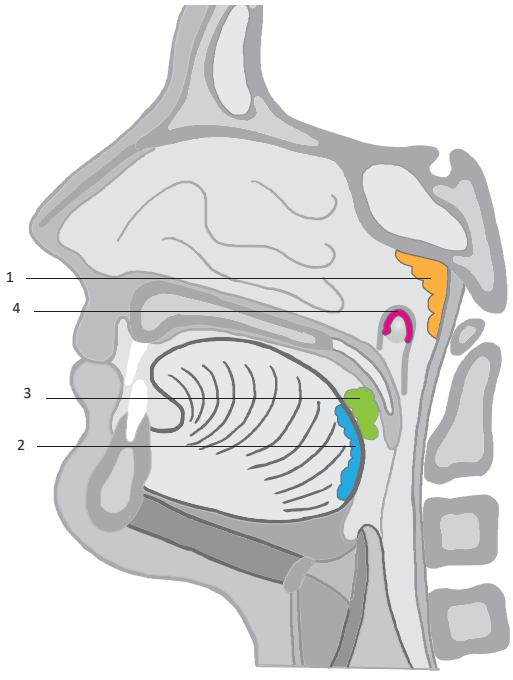

Sagittal section through the head and neck

Lymph nodes are small, self-contained organs surrounded by fibrous capsules and located along the course of lymphatic vessels.

Lymphoid nodules/follicles are masses of densely packed lymphocytes embedded in various tissues of the body including the cortex of lymph nodes, the spleen, the tonsils and the mucosa of the intestine. They are composed of a germinal centre consisting of various cells (dendritic cells, centrocytes and centroblasts) and a marginal zone, containing mainly immature B-cells. A primary nodule lacks the germinal centre. A secondary nodule has a germinal centre, which is formed after the first contact with an antigen.

Dendritic cells are a type of antigen presenting cell (APC).

Centroblasts and centrocytes are forms of activated B-cells, which gradually change into plasma cells or memory B-cells. Plasma cells produce antibodies. Memory cells are inactive cells that serve to provide a faster immune reaction on recurrent infection.

Clinical notes

Adenoid is a clinical term for the pharyngeal tonsil. Adenectomy is the surgical removal of the adenoid.

Lymphadenopathy is a term used for enlarged lymph nodes. Lymphadenopathy is usually painful in inflammation but usually painless in tumour metastasis.

Lateral bands is a clinical term for the dispersed lymphatic tissue in the lateral wall of the pharynx.

The sentinel node needs to be examined before surgical treatment of tumours. To perform a sentinel node biopsy, firstly a fluorescent or radioactive substance is injected into the tumour. The region is carefully dissected and the sentinel node is detected by a change in colour or radioactivity. The excised lymphatic tissue is then sent for a cytological examination for malignancy.

The TNM staging system
T (tumour) – the size of the primary tumour
N (nodes) – involvement of nearby (regional) lymph nodes
M (metastasis) – spread of cancer to distant body parts

Routes of metastatic spread
1.transcoelomic spread (spread and implantation of tumour cells on the peritoneum/pleura.)
2.lymphogenous spread
3.haematogenous spread

Nonencapsulated lymphoid tissue consists of lymphoid tissue located both diffusely and in nodules spread throughout the body. It forms the mucosal immune system (**MALT / mucosa-associated lymphoid tissue**), which contains the same amount of lymphocytes as the rest of the body. It is so extensive because the mucosa of the body forms a vary large surface area through which pathogenic particles can enter the body. MALT (diffuse and organised) forms **immune barriers** against pathogens in the **digestive and respiratory systems, the skin and other organs**.

1 **Diffuse mucosa-associated lymphoid tissue** (D-MALT)
– diffuse cells located mainly in the digestive system
2 **Organised mucosa-associated lymphoid tissue** (O-MALT)
– concentrations of lymphoid tissue
2.1 **Gut associated lymphoid tissue** (GALT)
- 2.1.1 **Solitary lymphoid nodules** (*nodi lymphoidei solitarii*)
- 2.1.2 **Aggregated lymphoid nodules** (*nodi lymphoidei agregati*)
  – **Peyer's patches** (*agmina Peyeri*) in the ileum
  – **Lymph nodules of vermiform appendix** (*appendix vermiformis caeci*)

- 2.2 **Nose associated lymphoid tissue** (NALT)
- 2.3 **Bronchus associated lymphoid tissue** (BALT)
- 2.4 **Surface associated lymphoid tissue** (SALT) – keratinocytes, mast cells, Langerhans cells

2.5 **Conjunctiva associated lymphoid tissue** (CALT)
2.6 **Urinary tract associated lymphoid tissue** (UTALT) – ureter, urinary bladder

- 2.7 **Other organs:** vagina, mammary gland

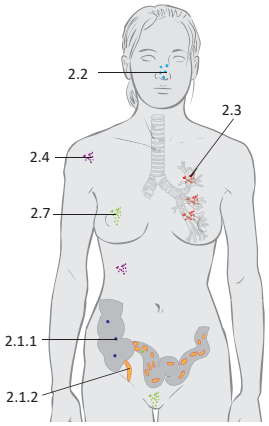

8 Lymph nodes – Nodi lymphoidei (nodi lymphatici, lymphonodi)

Lymph nodes are small oval-shaped organs that range in size from 1 to 25 mm. The total number of lymph nodes in the body is about 500. Lymph nodes contain **lymphocytes, macrophages and dendritic cells**. They act as filters of lymph and sites of **initiation of specific immune responses** Naïve lymphocytes circulate between lymph nodes searching for foreign antigens on the surface of antigen presenting cells. Antigen presentation induces the activation, proliferation and differentiation of naïve lymphocytes into **mature T-lymphocytes (T-cells) and mature B-lymphocytes (effector B-cells / plasmocytes), which are capable of amounting a proper immune response.**

Structure

- 1 **Capsule** (*capsula*)
  1.1 **Trabeculae** – extend from the internal surface of the capsule to the inner part of the lymph node
- 2 **Hilum** – a concave site containing the entering blood vessels and usually one exiting efferent lymphatic vessel
- 3 **Cortex** – contains lymph nodules, predominantly of B-cells
  - 3.1 **Paracortex** – contains most of the T-cells
- 4 **Medulla** – contains B-cells, macrophages and plasma cells

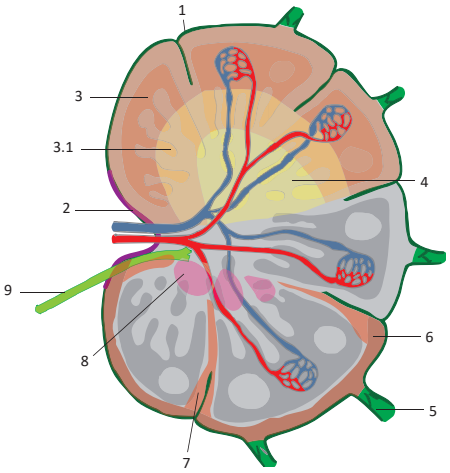

Circulation of lymph inside the lymph node

- 5 **Afferent lymphatic vessels** (*vasa lymphatica afferentia*)
- 6 **Subcapsular/marginal sinus** (*sinus subcapsularis/marginalis*)
  – is located under the capsula, and drains lymph from the afferent vessels
- 7 **Internodular sinuses** (*sinus internodulares*)
  – radiate from the capsule into the medulla
- 8 **Medullary sinuses** (*sinus lymphatici medullares*) – collecting lymph from the medulla and draining into the hilum
- 9 **Efferent lymphatic vessel** (*vas lymphaticum efferens*)

Body location

1. **Tributary region** – a specific area drained by a group of lymph nodes
2. **Regional lymph nodes** – a group of lymph nodes draining a specific anatomic region
3. **Sentinel lymph node** – the first lymph node or group of lymph nodes draining a particular organ
   – the first lymph node (or group of lymph nodes) to be invaded by metastasising cancer cells
   – swelling always indicates a pathological process

This copy belongs to ali yaghoubi

The lymph nodes of the head constitute a small group of only a few lymph nodes that are mostly **located around the auricles and on back of the head**.

Lymph nodes of the head

- 1 **Occipital nodes** – (*nodi lymphoidei occipitales*)
- 2 **Mastoid nodes** – (*nodi lymphoidei mastoidei*)
- 3 **Parotid nodes** – (*nodi lymphoidei parotidei*)
  – divided into superficial and deep nodes
- 4 **Facial nodes** – (*nodi lymphoidei faciales*)

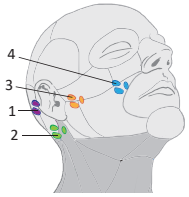

The **cervical lymph nodes** are located both **superficially and deeply in the neck**. The oral cavity, pharynx and larynx drain predominantly to the deep lateral lymph nodes.

Lymph nodes classification according to the spatial arrangement

1 **Anterior and lateral cervical nodes**
(*nodi lymphoidei cervicales anteriores et laterales*)
2 **Deep and superficial cervical nodes**
(*nodi lymphoidei cervicales profundi et superficiales*)
- 3 **Submental node** (*nodi lymphoidei submentales*)
- 4 **Submandibular node** (*nodi lymphoidei submandibulares*)
- 5 **Pretracheal nodes** (*nodi lymphoidei pretracheales*)
- 6 **Paratracheal nodes** (*nodi lymphoidei paratracheales*)
- 7 **Retropharyngeal nodes** (*nodi lymphoidei retropharyngei*)

8 **Jugulodigastric node** (*nodus lymphoideus jugulodigastricus*)
9 **Jugulo-omohyoid node**
(*nodus lymphoideus juguloomohyoideus)*

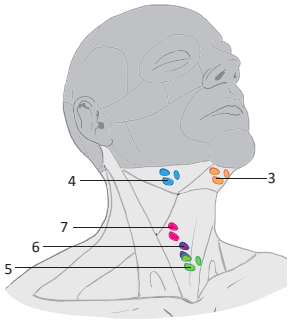

Hands-on classification

- 1 **Deep lateral cervical nodes**
  (*nodi lymphoidei cervicales laterales profundi*)
  – a chain of lymph nodes along the internal jugular vein
- 2 **Accessori nodes** (*nodi lymphoidei accessorii*)
  – a chain of lymph nodes along the accessory nerve
- 3 **Supraclavicular nodes** (*nodi lymphoidei supraclaviculares*)
  - 3.1 **Node of Virchow-Troiser (a signal node)**
    – is located above the left clavicle
    – its enlargement may indicate a tumour of the stomach (70 %), left mammary gland, left lung, large intestine, left side of the neck or a primary lymphoma

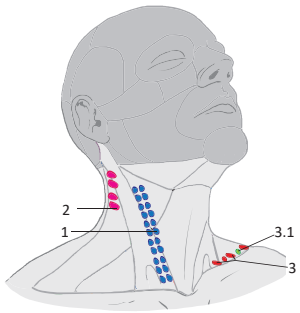

Clinical classification

6 areas are distinguished for performing block-neck dissections.

Ia drains the lower lip, mouth, anterior third of the tongue and lower jaw
Ib drains the mouth, nasal cavity, skin and subcutaneous tissue of half of the face
II a+b drains the nasal cavity, mouth, pharynx, larynx and parotid glands
III drains the mouth, pharynx and larynx
IV drains the laryngopharynx (hypopharynx), oropharynx and larynx
V a+b drains the nasopharynx and oropharynx
VI drains the thyroid gland

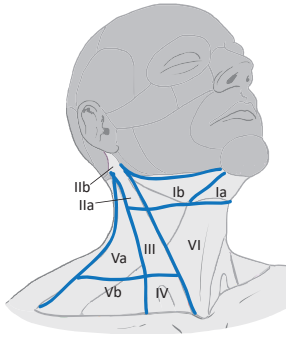

Only small and inconstant lymph nodes are located within the facial part of the head, mainly in the nasolabial groove or on the surface of the buccal fat pad.

The tonsillar node / node of Wood *(nodus tonsillaris)* a submandibular node located near the wall of the pharynx. Lymph from the tonsils is drained here. A painful lymphadenopathy can thus occur in tonsillitis.

The retropharyngeal node / node of Rouvier *(nodus retropharyngeus)* is a retropharyngeal node located in the retropharyngeal space, draining lymph from the middle ear. It can enlarge during inflammation of the middle ear.

The jugulodigastric node / node of Küttner *(nodus jugulodigastricus)* is a deep lateral cervical node located in the carotid triangle, at the intersection of the anterior belly of the digastric with the internal jugular vein. It drains lymph from the root of the tongue.

The jugulo-omohyoid node is a deep lateral cervical node located in the carotid triangle, at the intersection of the superior belly of the omohyoid with the internal jugular vein. It drains lymph from the anterior third of the tongue.

Clinical notes

The occipital nodes are enlarged in rubeolla/German measles and in chronic toxoplasmosis. Palpation of the lymph nodes of the head and neck is a standard part of the physical examination.
The node of Virchow-Troiser is located at the last segment of the thoracic duct and thus can be affected in a wide variety of tumours.

Block-neck dissection is the surgical removal of all cervical lymph nodes along with adipose tissue and/or the sternocleidomastoid muscle for treatment of head and neck malignancies.

Axillary exenteration is the complete removal of the level I and II axillary nodes (according to Berg) in breast cancer. The level III lymph nodes are inaccessible due to their location behind the brachial plexus and axillary vessels.

Elephantiasis is stage three lymphoedema. Elephantiasis of the upper limb can occur as a complication of axillary exenteration in the surgical treatment of breast cancer metastasis. In such cases, it is caused by impaired lymph drainage due to the removal of lymph nodes and disruption of the deep lymphatic vessels.

The lymph nodes of the upper limb are located mainly in **the axillary fossa** where they form a dense network that drains lymph from a large region that include **the upper limb, the mammary gland and the lateral and ventral aspects of the thorax**.

Collecting lymphatic vessels of the upper limbs (collectors)

- 1 **Lateral collectors** – into the axillary lymph nodes along the cephalic vein
- 2 **Medial collectors** – into the axillary lymph nodes along the basilic vein (with the superficial cubital lymph nodes inserted in the cubital region)
- 3 **Anterior collectors** – into the superficial cubital lymph nodes along the median antebrachial vein

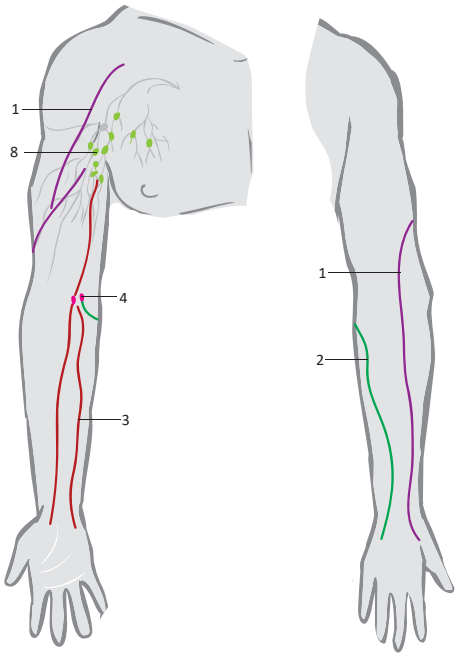

Lymph nodes of the upper limb

- 4 **Superficial and deep cubital nodes** (*nodi lymphoidei cubitales superficiales et profundi*)
- 5 **Brachial nodes** (*nodi lymphoidei brachiales*)
- 6 **Deltopectoral/Infraclavicular nodes** (*nodi lymphoidei deltopectorales/infraclaviculares*)
- 7 **Interpectoral nodes of Rotter** (*nodi lymphoidei interpectorales*)
- 8 **Axillary nodes** (*nodi lymphoidei axillares*) – a group of up to 40 lymph nodes

Axillary lymph nodes

Anatomical classification (5 groups):

- 1 **Apical nodes** (*nodi apicales*)
- 2 **Central nodes** (*nodi centrales*)
- 3 **Humeral/lateral nodes** (*nodi humerales*)
- 4 **Subscapular/posterior nodes** (*nodi subscapulares*)
- 5 **Pectoral/anterior nodes** (*nodi pectorales*)
  - 5.1 **Sorgius node**
    - – located at the 2nd or 3rd slip of the serratus anterior
    - – the sentinel lymph node of the mammary gland

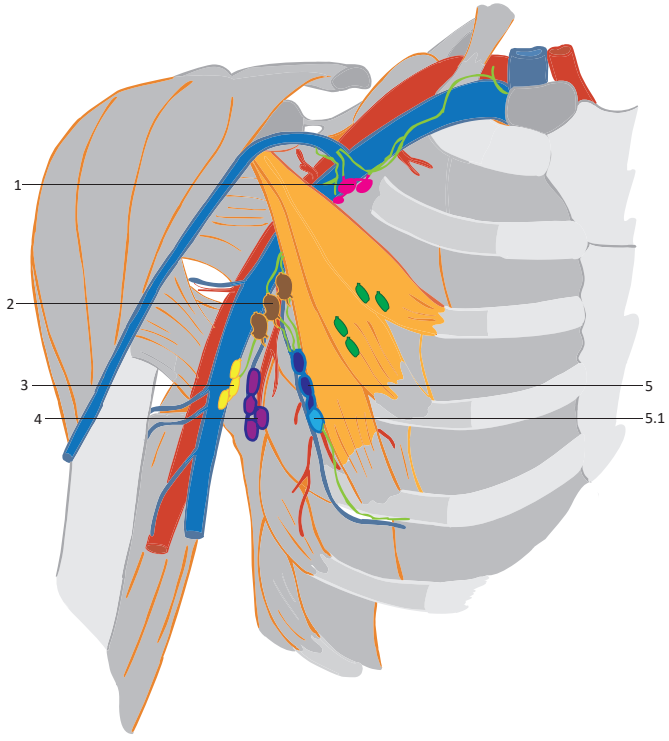

Clinical classification (according to Berg)

- **Pectoralis minor** (*musculus pectoralis minor*)

I. Under pectoralis minor

- Pectoral nodes – ventrally
- Subscapular nodes – dorsally
- Humeral nodes – lateral

II. Behind pectoralis minor

- Central nodes
- Apical nodes – partially
- Interpectoral nodes

III. Behind the neurovascular bundle

- Apical nodes

This copy belongs to ali yaghoubi

The lymph nodes of the thorax are located in the mediastinum. They drain **the intrathoracic organs and the mammary gland**. Unfortunately this location is poorly accessible, which makes it difficult to differentiate pathological enlargement of these lymph nodes.

Classification according to the position in the mediastinum

1 **Superior**
- 1.1 **Superior tracheobronchial lymph nodes** (*nodi lymphoidei tracheobronchiales superiores*)
- 1.2 **Paratracheal lymph nodes** (*nodi lymphoidei paratracheales*)

2 **Inferior anterior** (*nodi lymphoidei mediastinales anteriores*)
- 2.1 **Paramammary lymph nodes** (*nodi lymphoidei paramammarii*)
- 2.2 **Parasternal lymph nodes** (*nodi lymphoidei parasternales*)
- 2.3 **Intercostal lymph nodes** (*nodi lymphoidei intercostales*)
- 2.4 **Superior diaphragmatic lymph nodes** (*nodi lymphoidei phrenici superiores*)
- 2.5 **Prepericardial lymph nodes** (*nodi lymphoidei prepericardiaci*)

3 **Inferior middle**
- 3.1 **Bronchopulmonary lymph nodes** (*nodi lymphoidei bronchopulmonales*)
- 3.2 **Inferior tracheobronchial lymph nodes** (*nodi lymphoidei tracheobronchiales inferiores*)
- 3.3 **Lateral pericardial lymph nodes** (*nodi lymphoidei pericardiaci laterales*)

4 **Inferior posterior** (*nodi lymphoidei mediastinales posteriores*)
- 4.1 **Juxta-oesophageal lymph nodes** (*nodi lymphoidei juxtaoesophageales*)
- 4.2 **Prevertebral lymph nodes** (*nodi lymphoidei prevertebrales*)

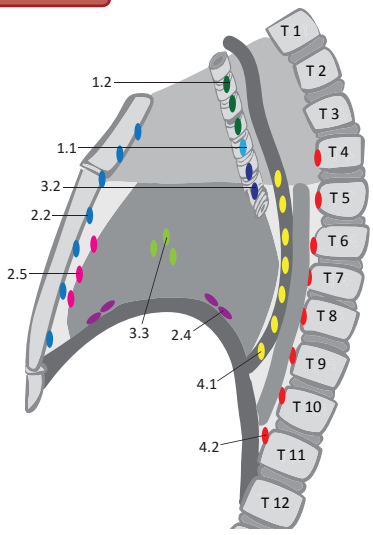

Scheme of the thoracic lymph nodes

Classification according to the organs drained

- 5 **Intrapulmonary lymph nodes** (*nodi lymphoidei intrapulmonales*) – are located along the course of the bronchi inside the lung parenchyma
- 6 **Bronchopulmonary lymph nodes** (*nodi lymphoidei bronchopulmonales*) – are located in the hilum of the lung, close to the entry of the main bronchi into the lungs
- 7 **Inferior tracheobronchial lymph nodes** (*nodi lymphoidei tracheobronchiales inferiores*) – are located below the bifurcation of the trachea
- 8 **Right and left superior tracheobronchial lymph nodes** (*nodi lymphoidei tracheobronchiales superiores dextri et sinistri*) – are located lateral to the bifurcation of the trachea
- 9 **Paratracheal lymph nodes** (*nodi lymphoidei paratracheales*) – are located along the trachea

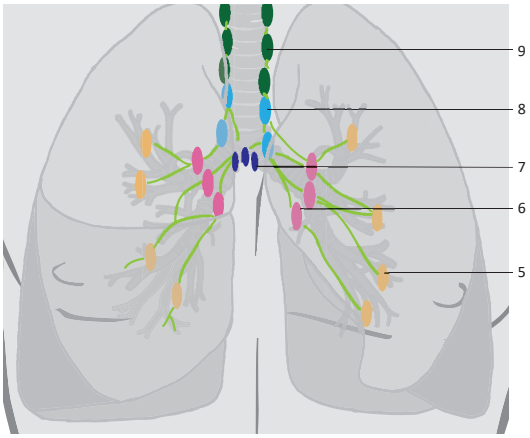

Lymph from the thoracic wall (from the parasternal lymph nodes) is drained on the left side to the thoracic duct, while on the right side to the right lymphatic trunk. Lymph from the other groups of lymph nodes is drained to the medinastinal and lumbar lymph nodes.

The paraaortic, aortocaval and paracaval lymph nodes are clinical terms for the lumbar lymph nodes.

The intestine can be considered to be the largest lymphatic organ due to the huge amount of lymphatic nodules within its wall.

Clinical notes

Hodgkin's lymphoma is a cancer of the lymphatic system that usually manifests in the lymph nodes. In the majority of cases, it occurs in the lymph nodes of the neck, axilla or mediastinum. It spreads to adjacent lymph nodes or to the systemic circulation. It typically occurs in young adults and the elderly.

Paraaortic lymphadenectomy is the surgical removal of the lumbar lymph nodes in malignancies of the ovaries, testes, uterus or kidneys.

Retroperitoneal lymphadenopathy refers to an enlargement of the lumbar lymph nodes. It can be caused by the spread of tumour cells. It manifests by various symptoms, such as swelling of the lower limbs due obstruction of lymphatic drainage and compression of the large veins, renal failure due to compression of the ureters and pain caused by compression of nerves.

The lymph nodes of the intraperitoneal organs drain to the coeliac lymph nodes and then **via two or three intestinal trunks to the thoracic duct**. The **lumbar lymph nodes** collect lymph from **the pelvic region, lower extremities, abdominal wall, paired organs of the abdominal cavity, gonads and the organs of the inframesocolic part of the peritoneal cavity**. Lymph from the lumbar lymph nodes is subsequently drained to the paired lumbar trunks and to the thoracic duct. **Lymph from the unpaired organs of the abdominal cavity** drains firstly to the lymph nodes situated along the vessels within the walls of these organs and then to the lymph nodes located along the unpaired branches of the abdominal aorta. Lymph from the **coeliac lymph nodes** is collected **by the intestinal trunks and drained into the thoracic duct**. Lymph from the **superior mesenteric lymph nodes** is collected by the **coeliac and lumbar lymph nodes**. Lymph from the **inferior mesenteric lymph node**s is drained solely to the **lumbar lymph nodes**.

Parietal lymph nodes (nodi lymphoidei parietales)

- 1 **Left lumbar lymph nodes**
  (*nodi lymphoidei lumbales sinistri*)
  1.1 **Lateral aortic, preaortic, postaortic lymph nodes**
  (*nodi lymphoidei aortici laterales, preaortici, retroaortici*)
- 2 **Intermediate lumbar lymph nodes**
  (*nodi lymphoidei lumbales intermedii*)
- 3 **Right lumbar lymph nodes**
  (*nodi lymphoidei lumbales dextri*)
  3.1 **Lateral caval, precaval, retrocaval lymph nodes**
  (*nodi lymphoidei cavales laterales, precavales, retrocavales*)
- 4 **Inferior diaphragmatic lymph nodes**
  (*nodi lymphoidei phrenici inferiores*)
  5 **Inferior epigastric lymph nodes**
  (*nodi lymphoidei epigastrici inferiores*)

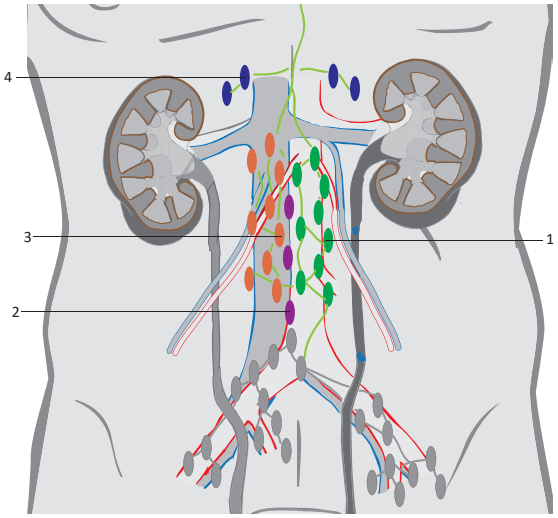

Visceral lymph nodes (nodi lymphoidei viscerales)

- 1 **Gastric, gastroomental, pyloric and pancreaticoduodenal lymph nodes**
  (*nodi lymphoidei gastrici, gastroomentales, pylorici et pancreaticoduodenales*)
- 2 **Pancreatic lymph nodes** (*nodi lymphoidei pancreatici*)
- 3 **Splenic lymph nodes** (*nodi lymphoidei splenici*)
- 4 **Hepatic lymph nodes** (*nodi lymphoidei hepatici*)
- 5 **Superior mesenteric lymph nodes**
  (*nodi lymphoidei mesenterici superiores*)
  5.1 **Juxta-intestinal mesenteric lymph nodes**
  (*nodi lymphoidei juxtaintestinales*)
  5.2 **Central superior mesenteric lymph nodes**
  (*nodi lymphoidei mesenterici superiores centrales*)
  5.3 **Ileocolic lymph nodes** (*nodi lymphoidei ileocolici*)
  5.4 **Precaecal and retrocaecal lymph nodes**
  (*nodi lymphoidei precaecales et retrocaecales*)
  5.5 **Appendicular lymph nodes** (*nodi lymphoidei appendiculares*)
  5.6 **Mesocolic and paracolic lymph nodes**
  (*nodi lymphoidei mesocolici et paracolici*)
  5.7 **Right, middle and left colic lymph nodes**
  (*nodi lymphoidei colici dextri, medii et sinistri*)
- 6 **Inferior mesenteric lymph nodes**
  (*nodi lymphoidei mesenterici inferiores*)
  6.1 **Sigmoid lymph nodes** (*nodi lymphoidei sigmoidei*)
  6.2 **Superior rectal lymph nodes** (*nodi lymphoidei rectales superiores*)

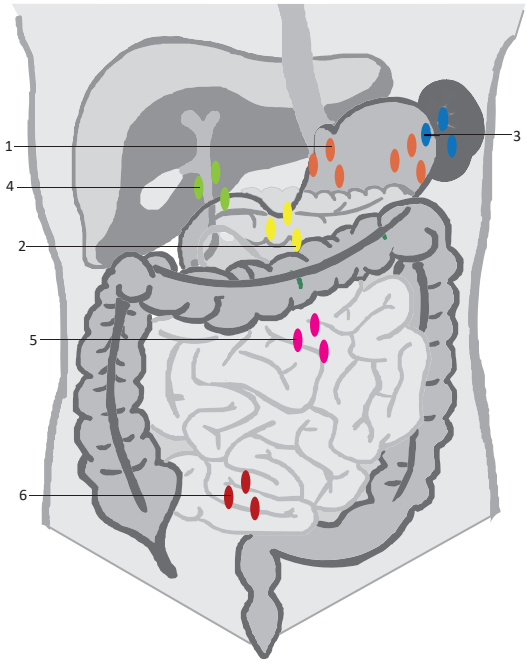

This copy belongs to ali yaghoubi

Lymph from the pelvic organs drains into **the internal and external iliac lymph nodes. Lymph from the gonads drains into the lumbar lymph nodes** as these organs originated in the superior lumbar region.

Parietal lymph nodes (nodi lymphoidei parietales)

- 1 **Common iliac lymph nodes** (*nodi lymphoidei iliaci communes*)
- 2 **External iliac lymph nodes** (*nodi lymphoidei iliaci externi*)
  - 2.1 **Obturator lymph nodes** (*nodi lymphoidei obturatorii*)
- 3 **Internal iliac lymph nodes** (*nodi lymphoidei iliaci interni*)
  - 3.1 **Superior and inferior gluteal lymph nodes** (*nodi lymphoidei gluteales superiores et inferiores*)
  - 3.2 **Sacral lymph nodes** (*nodi lymphoidei sacrales*)

Nodi lymphoidei viscerales

- 4 **Paravesical lymph nodes** (*nodi lymphoidei paravesicales*)
- 5 **Parauterine lymph nodes** (*nodi lymphoidei parauterini*)
- 6 **Paravaginal lymph nodes** (*nodi lymphoidei paravaginales*)
- 7 **Pararectal lymph nodes** (*nodi lymphoidei pararectales*)

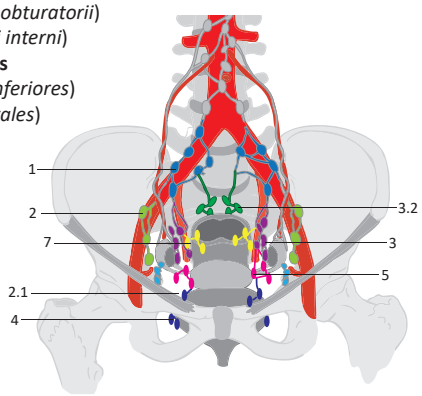

8.7 Lymph nodes of the lower limb – Nodi lymphoidei membri inferioris

The lymph nodes of the lower limbs are **mainly located in the inguinal region and femoral triangle**. They **drain lymph from the lower extremities, external genital organs and part of the anterior and lateral abdominal walls**.

Collecting lymphatic vessels of the lower limbs (collectors)

- 1 **Medial collecting vessels** (10–15) – are located along the great saphenous vein and drain into the superficial inguinal lymph nodes
- 2 **Lateral collecting vessels** (1–3) – are located along the tributaries of the great saphenous vein and drain into the superficial inguinal lymph nodes
- 3 **Posterior collecting vessels** (2–3) – are located along the small saphenous vein and drain into the superficial popliteal lymph nodes

Lymph nodes

- 4 **Popliteal lymph nodes** (*nodi lymphoidei poplitei*) – are divided into a superficial and a deep group
- 5 **Inguinal lymph nodes** (*nodi lymphoidei inguinales*)
  - 5.1 **Superficial inguinal lymph nodes** (*nodi lymphoidei inguinales superficiales*) 8–12
    - **superomedial, superolateral and inferior group**
    - drain almost the entire lower limb (except for its posterior surface), the skin and subcutaneous tissue of the gluteal region, perineum, anus, penis/clitoris, vaginal vestibule, scrotum/labia majora, horns of the uterus, and inferior anterior abdominal wall
    - 5.1.1 **Lymph node of Cabanas** (*nodus lymphoideus inguinalis superficialis superomedialis*)
      - the sentinel lymph nodes of the penis
  - 5.2 **Deep inguinal lymph nodes** (*nodi lymphoidei inguinales profundi*) 2–5
    - 5.2.1 **Node of Clocquet–Rosenmüller** (*nodus lymphoideus inguinalis profundus proximalis*)
      - is situated medially in the vascular space (*lacuna vasorum*)

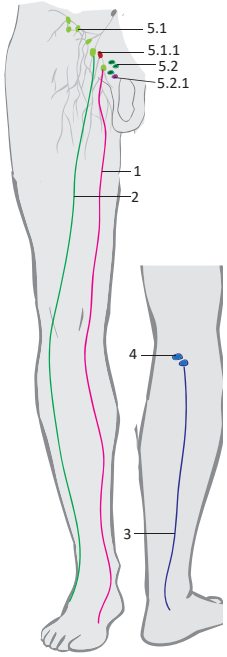

Plague buboes are swollen lymph nodes in the inguinal region. They are associated with the bubonic plague caused by the bacteria Yersinia pestis.

The external iliac lymph nodes form three bands along the homonymous veins. These lymph nodes collect lymph from the lower limbs, walls of the lesser pelvis, inferior part of the abdominal wall, parts of the uterus and urinary bladder and external genital organs.

The internal iliac lymph nodes collect lymph from the walls and organs of the lesser pelvis, the deep tissue of the perineum, external genital organs and gluteal region.

The superficial inguinal lymph nodes are positioned within the subcutaneous layer of the femoral triangle, close to the saphenous hiatus. Lymph is drained through the cribriform fascia to the deep inguinal lymph nodes. The deep inguinal lymph nodes are the tributary lymph nodes of the lower limbs (except for the gluteal region), they are located at the bottom of the femoral triangle (within the iliopectineal fossa) close to the vascular space.

Lymphatic drainage of the heart: the left atrium and ventricle are drained via the left lymphatic outflow system to the inferior tracheobronchial nodes and then into the right lymphatic duct. Lymph from the right atrium and ventricle is drained via the right lymphatic outflow system into the anterior mediastinal lymph nodes and then into the thoracic duct.

Clinical notes

Pelvic lymphadenectomy is the surgical removal of the lymph nodes in the pelvic cavity. It is usually performed in malignancies and their lymphatic metastases in this region.

The obturator lymph nodes may be affected in uterine malignancies. They are located along the obturator vessels.

The sacral lymph nodes may be affected in malignancies of the cervix of the uterus, prostate and caecum.

Respiratory system

1 **Nose** – submandibular lymph nodes
2 **Nasal cavity** – retropharyngeal and deep cervical lymph nodes
3 **Larynx** – deep cervical and paratracheal lymph nodes
4 **Trachea** – paratracheal and superior, right inferior and left inferior tracheobronchial lymph nodes
5 **Bronchi** – intrapulmonar lymph nodes
– into the bronchopulmonary and subsequently to the tracheobronchial lymph nodes

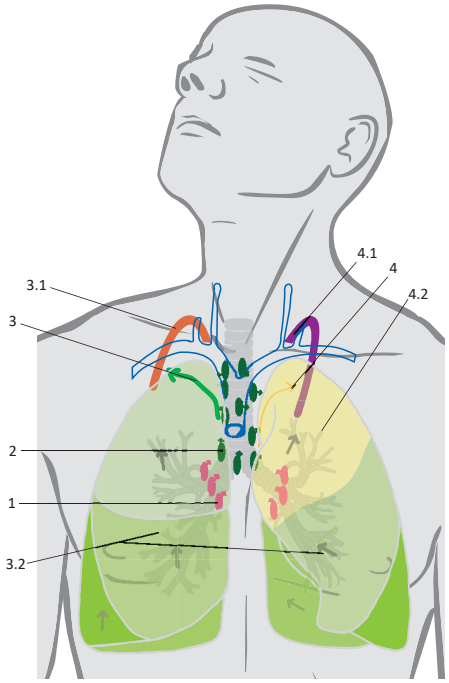

Lungs

- 1 **Bronchopulmonary lymph nodes**
- 2 **Inferior, right and left tracheobronchial lymph nodes**
- 3 **Right bronchomediastinal trunk**
  - 3.1 **Into the right lymphatic duct**
  - 3.2 **Drainage area:** whole right lung, inferior lobe of the left lung, both lingual segments of the superior lobe of the left lung (IV, V)
- 4 **Left bronchomediastinal trunk**
  - 4.1 **Into the thoracic duct**
  - 4.2 **Drainage area:** superior lobe of the lung (I–III) except for the both lingual segments

Digestive system

1 **Oral cavity**
1.1 **Face** – facial lymph nodes (on the surface of the buccinator), submandibular lymph nodes
1.2 **Lips** – submandibular and submental lymph nodes
1.3 **Gingiva** – submandibular lymph nodes
1.4 **Teeth:** submandibular and deep cervical lymph nodes
1.5 **Tongue**
1.5.1 **Apex** – submental lymph nodes
1.5.2 **Margin** – submandibular lymph nodes
1.5.3 **Radix and corpus** – deep cervical lymph nodes and also to the contralateral lymph nodes due to an incomplete lingual septum
1.6 **Palatine tonsil** – node of Wood at the level of the angle of the mandible and deep cervical lymph nodes
1.7 **Salivary glands**
1.7.1 **Submandibular gland** – submandibular lymph nodes
1.7.2 **Sublingual gland** – submandibular lymph nodes
1.7.3 **Parotid gland** – parotid lymph nodes, superficial and deep cervical lymph nodes
2 **Pharynx** – retropharyngeal lymph nodes
3 **Oesophagus**
3.1 **Cervical part** – deep cervical lymph nodes
3.2 **Thoracic part** – tracheobronchial and posterior mediastinal lymph nodes
3.3 **Abdominal part** – left gastric lymph nodes
4 **Stomach** – coeliac lymph nodes and subsequently to the thoracic duct and into the left supraclavicular lymph nodes (lymph nodes of Virchow-Troisier which are palpable)
4.1 **Body of stomach** – right and left gastric lymph nodes, right and left gastroomental lymph nodes
4.2 **Fundus of stomach** – splenic lymph nodes and left gastroomental lymph nodes
4.3 **Pylorus** – pyloric lymph nodes
5 **Duodenum** – pyloric, hepatic and mesenteric lymph nodes
– to the coeliac lymph nodes and then to the thoracic duct
6 **Jejunum and ileum** – superior mesenteric lymph nodes, to the coeliac and lumbar lymph nodes and then to the thoracic duct
7 **Large intestine**
7.1 **Terminal part of the ileum, caecum, vermiform appendix and adjacent part of the colon**
– into the ileocolic, precaecal, retrocaecal, appendicular, paracolic lymph nodes
7.2 **Ascending colon** – right colic lymph nodes
7.3 **Right two-thirds of the transverse colon** – middle colic lymph nodes
7.4 **Left one-third of the transverse colon, descending colon and sigmoid colon** – left colic lymph nodes
7.5 **Rectum** – inferior mesenteric lymph nodes, internal and external iliac lymph nodes, sacral lymph nodes
8 **Liver** – hepatic and coeliac lymph nodes and other via the diaphragm (to the anterior and posterior mediastinal lymph nodes, superior and inferior, parasternal lymph nodes)
9 **Pancreas** – hepatic, coeliac, pancreatic and splenic lymph nodes

This copy belongs to ali yaghoubi

Urinary tract

1 **Kidneys** – drain into the lumbar lymph nodes
– three complex lymphatic networks from the parenchyma and the fibrous and adipose capsule
2 **Urinary bladder** – drains into the paravesical lymph nodes, then into the common, internal and external iliac lymph nodes
3 **Female urethra** –drains into the paravesical lymph nodes, then into the common, internal and external iliac lymph nodes

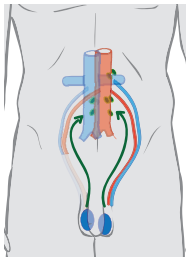

Male genital system

1 **Testes** – drain into the lumbar lymph nodes
2 **Epididymis** – drains into the lumbar lymph nodes
3 **Seminal vesicles** – drain into the internal and external iliac lymph nodes
4 **Prostate** – drains into the internal and external iliac lymph nodes, sacral lymph nodes
5 **Scrotum** – drains into the superficial inguinal lymph nodes
6 **Penis** – the skin of the penis drains into the superficial inguinal lymph nodes
– the node of Cabanas is the sentinel node of the penis
6.1 **Glans** – drains into the deep inguinal lymph nodes and the internal iliac lymph nodes
6.2 **Corpora cavernosa and male urethra** – drain into the external iliac lymph nodes

Female genital system

- 1 **Ovaries** – drain into the lumbar lymph nodes
- 2 **Uterine tubes** – drain into the lumbar lymph nodes
  - 2.1 **Isthmus** – drains into the superficial inguinal lymph nodes

3 **Uterus**
- 3.1 **Corpus** – drains into the internal iliac lymph nodes
- 3.2 **Fundus** – drains into the lumbar lymph nodes
- 3.3 **Margins** – drain into the superficial inguinal lymph nodes alongside the round ligament of the uterus
- 3.4 **Anterior part of the cervix** – drains into the internal iliac lymph nodes
- 3.5 **Posterior part of the cervix** – drains into the sacral lymph nodes

4 **Vagina**
- 4.1 **Upper part cranial to the hymen** – drains into the internal iliac lymph nodes
- 4.2 **Lower part cranial to the hymen** – drains into the external iliac lymph nodes
- 4.3 **Caudally to the hymen** – drains into the external iliac lymph nodes

- 5 **External female genital organs** – drain into the superficial inguinal lymph nodes
  - 5.1 **Clitoris and labia minora** – drain into the deep inguinal lymph nodes

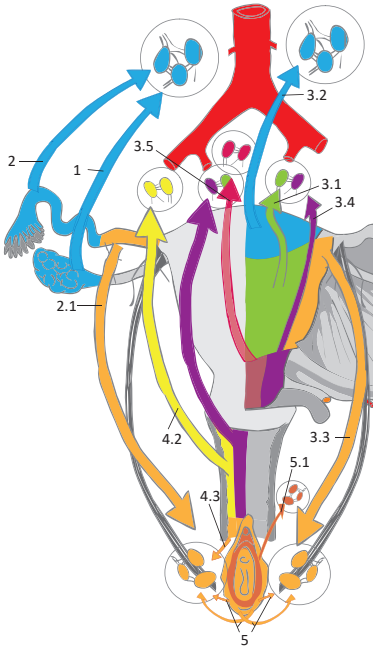

Lymphatic drainage of the female genital organs

Mammary gland

The lymphatic drainage of the mammary gland is complex. It begins at the subareolar plexus of Sappey.

1 **Axillary lymph nodes**
- 1.1 **Node of Sorgius**
  – the sentinel node of the mammary gland
  – the caudal-most lymph node of the pectoral lymph nodes
  – located at the 2nd or 3rd slip of the anterior serratus muscle

- 2 **Parasternal lymph nodes**
- 3 **Supraclavicular lymph nodes**
- 4 **Axillary lymph nodes**

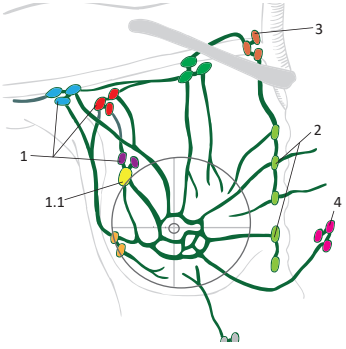

Lymphatic drainage of the mammary gland

Clinical notes

The majority of mammary tumours occur in the superior lateral quadrant of the mammary gland. Therefore metastases usually spread to the axillary lymph nodes.

The lymphatic systems of both mammary glands are interconnected. This explains why metastases may spread to the contralateral mammary gland or even (rarely) to the contralateral axillary lymph nodes.

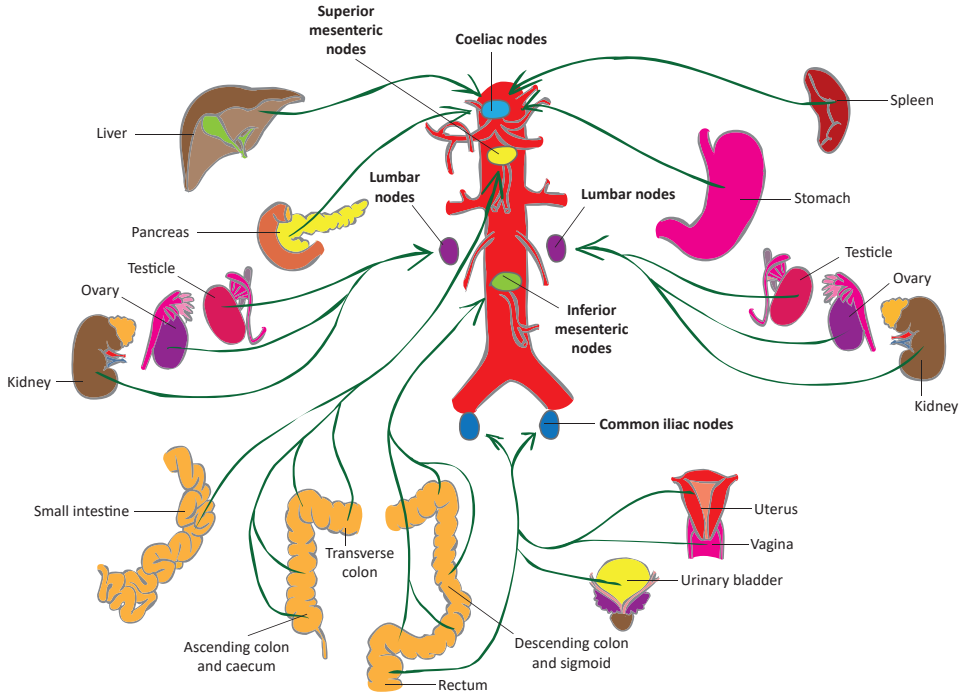

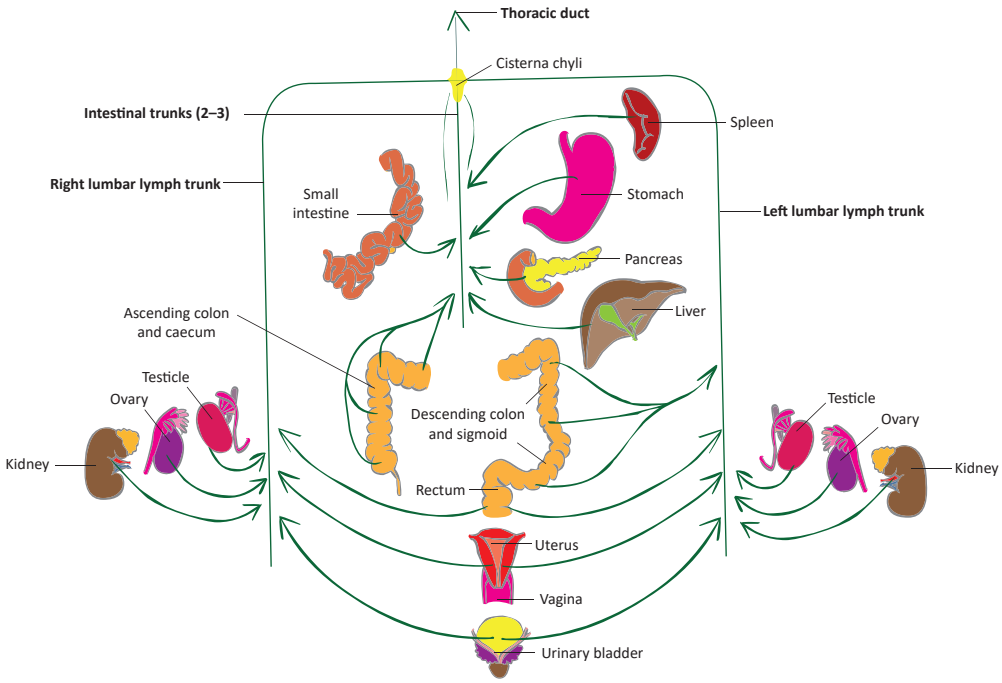

This copy belongs to ali yaghoubi

I. Lymphatic and immune system

1. Explain the abbreviation "nn.l.". (p. 318)
2. State the 6 organs of the immune and lymphatic systems and divide them into the primary and secondary lymphatic organs. (p. 318)
3. State the functions of the lymphatic system. (p. 318)
4. Explain in which organs the specific immune reaction is activated. (p. 318)
5. State the five parts of the human body, where lymphatic vessels are not present. (p. 318)

II. Lymphatic vessels

6. Explain the differences between the lymphatic and vascular capillaries. (p. 319)
7. State the collectors of the upper and lower limbs. (p. 319)
8. Describe the parts of the body, which are drained into the thoracic duct. (p. 319)
9. State the three trunks from which the thoracic duct is created and state the location of the thoraic duct (p. 319)

III. Thymus

10. Describe the topography of the thymus. (p. 320)
11. State the main functions of the thymus. (p. 320)
12. Explain the term involution of the thymus. (p. 320)

IV. Bone marrow

13. Describe the changes of location of the bone marrow. (p. 320)
14. Explain the conversion of red marrow into yellow marrow. (p. 320)
15. Explain whether it is possible for yellow marrow to change back into the red marrow. (p. 320)

V. Spleen

16. Explain the main functions of the spleen. (p. 321)
17. Describe the syntopy and topography of the spleen. (p. 321)
18. State the structure where vessels enter the spleen. (p. 321)
19. Name the part of the spleen where T-lymphocytes are located. (p. 321)
20. Describe the structure and main functions of the red pulp. (p. 321)
21. Explain the differences between the open and closed circulation inside the spleen. (p. 321)

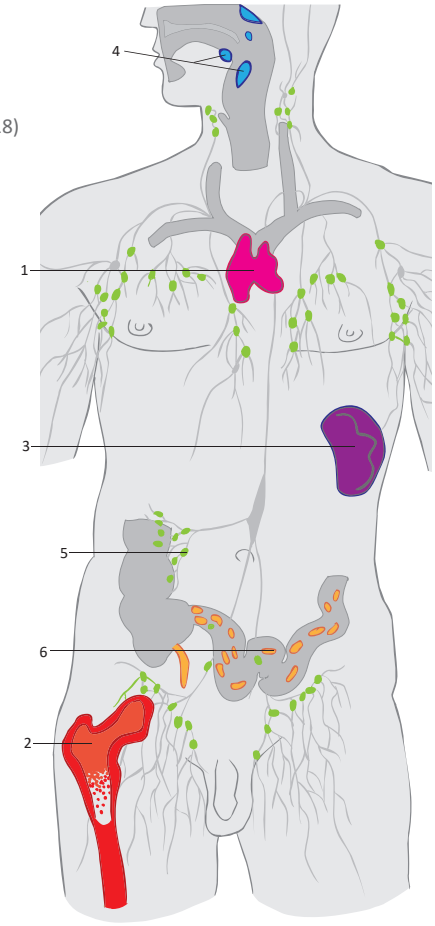

Describe the organs of the immune and lymphatic system

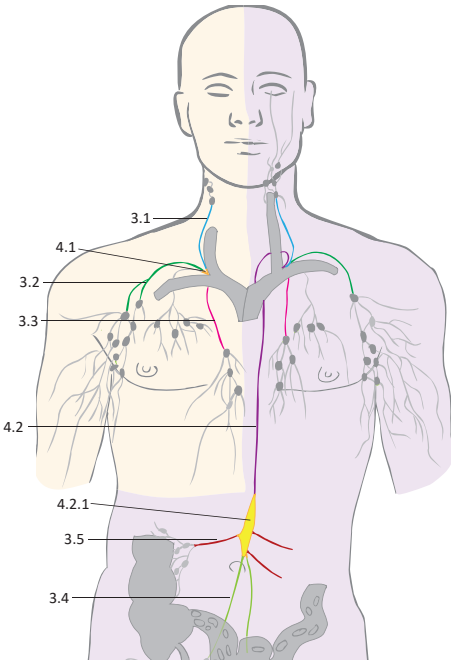

Describe the lymphatic vessels

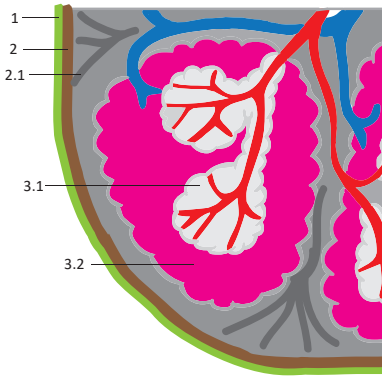

Describe the internal structures of the spleen

VI. Tonsils

22. State 4 tonsils of the lymphatic ring of Waldeyer. (p. 322)
23. List the paired and unpaired tonsils and give their locations. (p. 322)
24. Describe the location of the pharyngeal tonsil. (p. 322)

VII. Non-encapsulated lymphoid tissue

25. State several tissues/structures where the non-capsulated lymphatic tissue is located. (p. 323)
26. Explain the abbreviation GALT. (p. 323)
27. Explain the term Peyer's patches and describe their structure and function. (p. 323)

VIII. Lymph nodes

28. State the parts of the lymph node containing B-lymphocytes. (p. 323)
29. Explain the term sentinel lymph node and give some examples. (p. 323)
30. Explain where the lymph node of Rouvière can be palpated in children suffering from infections of the middle ear. (p. 324)
31. State the location of the node of Virchow-Troisier and the areas/organs it drains. (p. 324)
32. State the organs that in the presence of a malignancy may be associated with an enlargement of the node of Virchow-Troisier. (p. 324)
33. Describe the clinical classification of neck the lymph nodes (six areas of cervical block dissection in otorhinolaryngology). (p. 324)
34. State the location of the node of Sorgius and the region and organ/s it drains. (p. 325)
35. Describe the topography of the muscle which divides the axillary lymph nodes into three clinically relevant groups. (p. 325)
36. State the location and tributary area of the node of Cabanas. (p. 328)

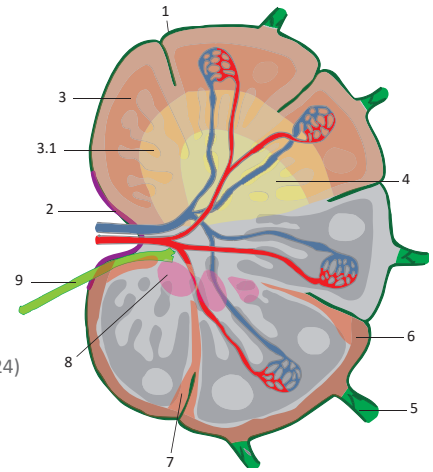

Describe the structure of the lymph node

VIII. Tributary lymph nodes

37. State the lymph nodes collecting lymph from the superior lobe of the left lung. (p. 329)
38. State lymph nodes collecting lymph from the testis. (p. 330)
39. Describe and compare the lymphatic drainage of the internal and external female genital organs. (p. 330)
40. Describe the drainage of the mammary gland in great detail. (p. 330)

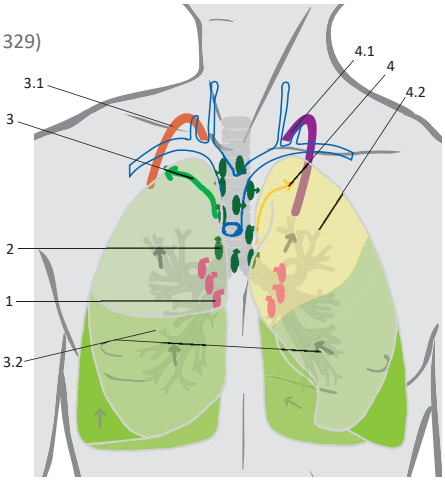

Describe the lymphatic drainage of the lungs

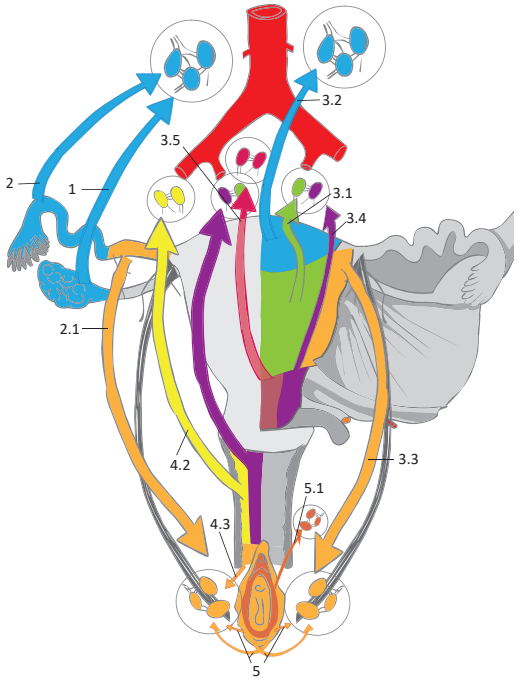

Describe the lymphatic drainage of the female genital organs

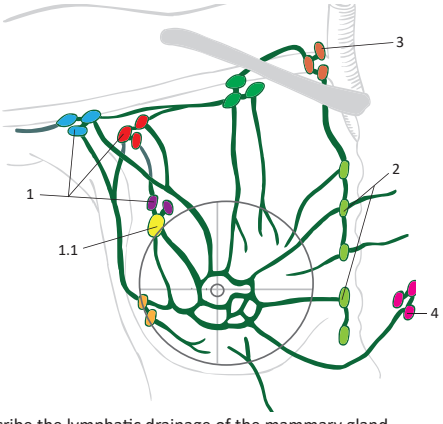

Describe the lymphatic drainage of the mammary gland

This copy belongs to ali yaghoubi

We would like to **thank the following anatomists, physicians and medical students** for their invaluable help, devotion and criticism during making this chapter.

Anatomists

Assoc. prof. Václav Báča, MD, PhD – Department of Anatomy, Third Faculty of Medicine, Prague, Czech Republic
Prof. Susana N. Biasutto, MD – Faculty of Medical Sciences, National University of Córdoba, Argentina
Šnajdr Pavel, MD, PhD – Department of Anatomy, First Faculty of Medicine, Prague, Czech Republic

Clinicians

Martin Štork, MD – Hematology and Oncology Clinic, University Hospital Brno, Czech republic

Students

Linda Kašičková
Monika Hejduková

11 References

1. AGUR, A. M. R. and A. F. DALLEY. Grant's Atlas of Anatomy. 13th Ed. Philadelphia: Lippincot Williams & Wilkins, 2012, 888 p. ISBN 978-1-60831-756-1.
2. BRAUNWALD, E. and R. O. BONOW. Braunwald's heart disease: a textbook of cardiovascular medicine. 9th Edition. Philadelphia: Saunders/Elsevier, 2012. 2136 p. ISBN 978-0-8089-2436-4.
3. CHUNG, K. W.; CHUNG, H. M. and N. L. HALLIDAY. BRS Gross Anatomy. 8th Ed. Philadelphia: Lippincott Williams & Wilkins, 2015. 544 p. ISBN 978-1-4511-9307-7.
4. LANZ, T. and W. WACHSMUTH. Praktische Anatomie. 7 bands. Berlin: Springer, 2003, 3658 p. ISBN 978-3-540-40571-9.
5. MILLS, S. E. Histology for pathologists. 4th Ed. Philadelphia: Lippincot Williams & Wilkins, 2012. 1328 p. ISBN-13: 978-1-4511-1303-7.
6. NETTER, F. H. Atlas of Human Anatomy. Professional Edition. 6th Ed. Oxford: Elsevier. 2014. 640 p. ISBN 978-1-455-75888-3.
7. SNELL, R. S. Clinical anatomy by regions. 9th Ed. Philadelphia: Lippincott Williams & Wilkins, 2012. 768 p. ISBN 978-1-60913-446-4.
8. WILLIAMS, P. L., ed. Gray´s Anatomy: the anatomical basis of medicine and surgery. 38th Ed. New York: Churchill Livingstone, 1995, 2092 p. ISBN 0-443-05717-6.

Memorix Anatomy

11 Peripheral nervous system

Ondřej Volný
Matej Halaj
David Kachlík
Radovan Hudák
Adam Whitley

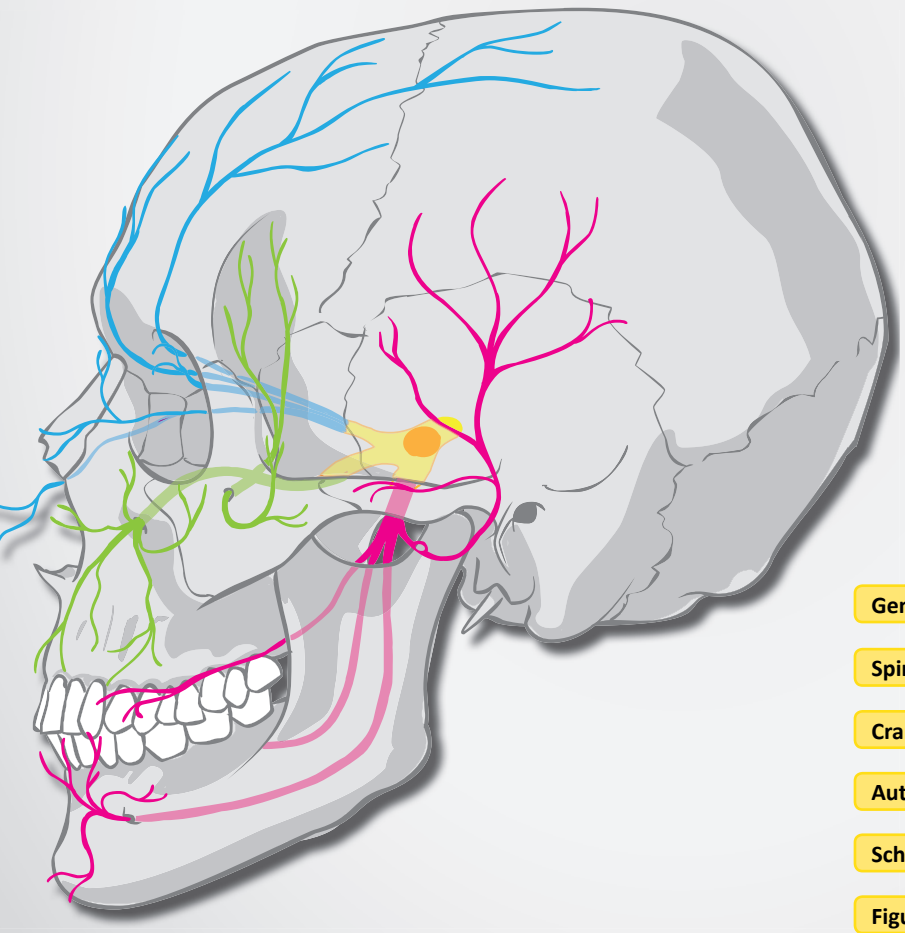

General overview	336
Spinal nerves	339
Cranial nerves	352
Autonomic nervous system	367
Schemes	375
Figures and review questions	385
Acknowledgements and references	388

This copy belongs to ali yaghoubi

The **peripheral nervous system** (PNS) consists of **nerves** and neural **ganglia**. Nerves enable **bidirectional communication** between the central nervous system and the rest of the body (referred to as the periphery). There are **31 pairs of spinal nerves** originating from the spinal cord and **12 pairs of cranial nerves** from the brainstem. The **autonomic nervous system** (ANS) is a division of the PNS. It is subdivided into the **sympathetic, parasympathetic and enteric nervous systems**. Ganglia are groups of cell bodies of nerves, located outside of the CNS. **Spinal ganglia** contain the cell bodies of sensory nerves. **Autonomic ganglia** contain synapsing visceromotor neurones; they contain a preganglionic axon synapsing on the dendrites of the postganglionic neurone. The cell body of the postganglionic neurone is located in the ganglion. Nerve fibres are axons and are either **myelinated** or **non-myelinated**. They are grouped together into nerve fascicles, which are further grouped together to form a periphal nerve.

Classification

- 1 **Cranial nerves** (*nervi craniales*) – 12 pairs
- 2 **Cervical nerves** (*nervi cervicales*) – 8 pairs
- 3 **Thoracic nerves** (*nervi thoracici*) – 12 pairs
- 4 **Lumbar nerves** (*nervi lumbales*) – 5 pairs
- 5 **Sacral nerves** (*nervi sacrales*) – 5 pairs
- 6 **Coccygeal nerve** (*nervus coccygeus*) – 1 pair

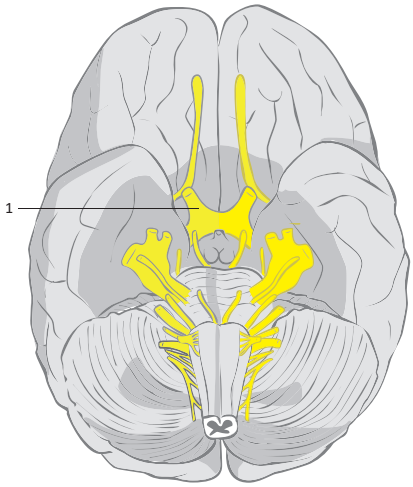

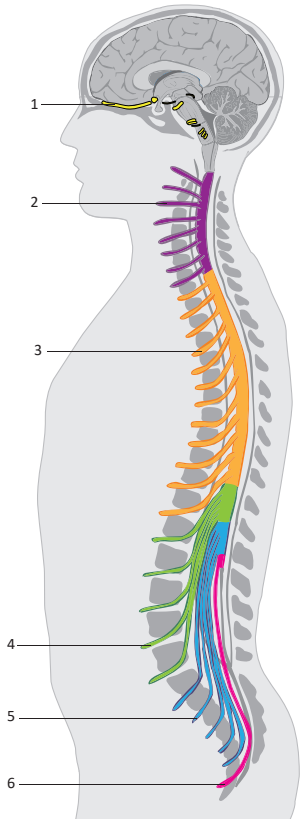

Peripheral nerve

1 **Nerve** (*nervus*)
– the peripheral nerve is a bundle of axons surrounded by fibrous tissue and supplied by small vessels called the vasa nervorum
- 1.1 **Epineurium** – a sheath of fibrous tissue covering a peripheral nerve
  – emits septa into the nerve, dividing the fascicles
- 2 **Fascicle** (*fasciculus*) – a bundle of axons (nerve fibres)
  - 2.1 **Perineurium** – a fibrous sheath covering one fascicle
- 3 **Types of nerve fibres**
  - 3.1 **Axons of alpha motor neurones**
    - 3.1.1 **Schwann cells**
      – responsible for myelin production
  - 3.2 **Peripheral branches of pseudounipolar neurones**
  - 3.3 **Axons of autonomic neurones**
- 3.4 **Endoneurium** – a fibrous sheath surrounding each myelinated nerve fibre

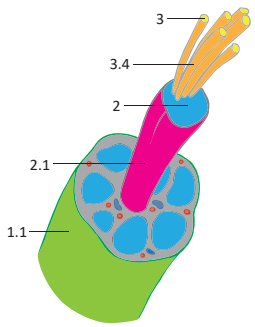

CNS is an abbreviation for the central nervous system.
PNS is an abbreviation for the peripheral nervous system.

A peripheral nerve does not contain any neuronal bodies (*perikarya*).

The nerve fibres travelling in a peripheral nerve are arranged in a wavy pattern. This prevents them from being harmed when they are stretched during limb movements.

Clinical notes

From the clinical point of view, there are two types of motor neurones. The upper motor neurone (UMN) is located in the cerebral cortex and the lower motor neuron (LMN) is located in the anterior horns of the spinal cord and in the nuclei of the cranial nerves.

Flaccid paralysis is caused by damage to the lower motor neurone. Muscle tone is decreased (hypotonia), partial or complete impairment of voluntary movement (paresis or plegia, respectively) and tendon reflexes are weakened or completely absent (hyporeflexia or areflexia, respectively). Viral poliomyelitis is an example of lower motor neuron disease. Spinal muscular atrophy (SMA) is a group of genetically determined diseases of the lower motor neurons.

Spastic paralysis is caused by damage to the upper motor neurone. It occurs as a result of lesions in the cerebral motor cortex or from damage to the axons of UMN that descend from the cortex to the spinal cord. This may arise after ischaemic insults such as occur in strokes and in periventricular perinatal hypoxia that can occur from complicated labour. Spastic paralysis manifests as partial or complete impairment of voluntary movements (paresis or plegia), increased muscle tone (hypertonia) and signs of spasticity (hyperreflexia and irritative pyramidal signs including the Babinski sign). Cerebral palsy is a classic example of an upper motor neurone disorder.

To suture nerves a special microsurgical technique is used to apply stitches to the perineurium of individual fascicles.

The **spinal nerve** is formed from an anterior and a posterior spinal root, which fuse and leave the vertebral canal through the intervertebral foramen. The **anterior root** consists of **efferent (motor) fibres** and the **posterior root** consists of **afferent (sensory) fibres**. The posterior root contains the **spinal ganglion** (*ganglion spinale*), containing the cell bodies of the afferent nerves entering the spinal cord. Outside the vertebral canal, the spinal nerve divides into a **posterior branch** (*ramus posterior*) and an **anterior branch** (*ramus anterior*). These branches contain **both afferent and efferent fibres**.

- 1 **Grey matter of the spinal segment**
  - 1.1 **Anterior horn** (*cornu anterius*) – the cell bodies (*perikarya*) of the somatomotor neurones
  - 1.2 **Lateral horn** (*cornu laterale*) – the cell bodies of the visceromotor neurones
  - 1.3 **Intermediate zone** (*zona intermedia*) – the cell bodies of the viscerosensory neurones
  - 1.4 **Posterior horn** (*cornu posterius*) – the cell bodies of the somatosensory neurones

  2 **Spinal nerve**

  2.1 **Rootlets** (*fila radicularia*)
    - 2.1.1 **Anterior root** (*radix anterior/ventralis*) – emerges from the anterolateral groove (*sulcus anterolateralis*)
    - 2.1.2 **Posterior root** (*radix posterior/dorsalis*) – emerges from the posterolateral groove (*sulcus posterolateralis*)
    - 2.1.3 **Spinal ganglion** (*ganglion sensorium nervi spinalis*) – a sensory ganglion within the posterior root

  - 2.2 **Trunk of spinal nerve** (*truncus nervi spinalis*)
    - 2.2.1 **Anterior branch** (*ramus anterior*) – innervates the anterior part of the trunk and limbs
    - 2.2.2 **Posterior branch** (*ramus posterior*) – innervates the back
    - 2.2.3 **Meningeal branch** (*ramus meningeus*) – innervates the spinal dura mater
    - 2.2.4 **White ramus communicans** (*ramus communicans albus*)
      – a branch of the spinal nerve going to the sympathetic ganglion
      – contains preganglionic and afferent fibres, which either transmit signals to other neurones and leave the ganglion as the grey ramus communicans (*ramus communicans griseus*), interganglionic branches or pass through the ganglion and continue as the splanchnic nerves (*nn. splanchnici*)
- 3 **Ganglion of sympathetic trunk** (*ganglion trunci sympathici*)
  – the synapse between pre and postganglionic neurons in the sympathetic ganglia
  – in contrast to parasympathetic ganglia, a significant amount of signal divergence occurs (as one preganglionic neuron connects to several postganglionic neurons)
  - 3.1 **Grey ramus communicans** – originates from the sympathetic ganglion and merges into the spinal nerve containing postganglionic fibers
- 4 **Intervertebral foramen** (*foramen intervertebrale*) – the exit for the spinal nerve

  5 **Fibres according to their function in the peripheral nerve**
  - 5.1 **Somatomotor fibres** – regulate movements and tension in skeletal muscles
  - 5.2 **Visceromotor fibres** – participate in the regulation of activity of smooth muscle cells, myocardial cells and glands
    - 5.2.1 **Preganglionic fibers** (C8–L3, S2–S4) – join the ganglia of the sympathetic trunk via the white rami communicantes
    - 5.2.2 **Postganglionic sympathetic fibers** (C8–L3) – emerge from the ganglia of the sympathetic trunk
      – rejoin the spinal nerves via the grey rami communicantes
      – other fibres give rise to the sympathetic trunk or leave the ganglia independently
    - 5.2.3 **Preganglionic parasympathetic fibers** (S2–S4)
      – do not synapse in the ganglia of the sympathetic trunk
  - 5.3 **Somatosensory fibers** – transfer information from mechanoreceptors, exteroreceptors, proprioceptors and termoreceptors on the body surface
  - 5.4 **Viscerosensory fibers** – transfer information from baroreceptors, chemoreceptors and receptors inside the internal organs (wall tension, special receptors for pain and chemical stimuli)

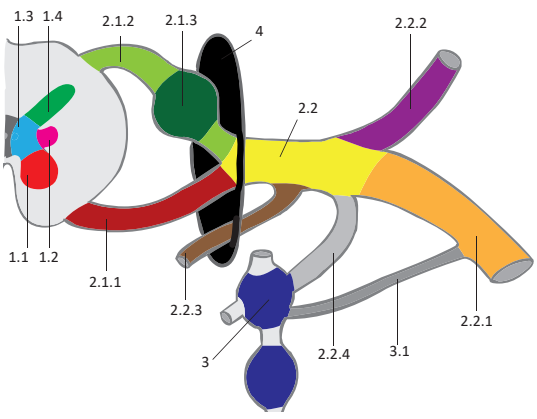

Scheme of the spinal nerve

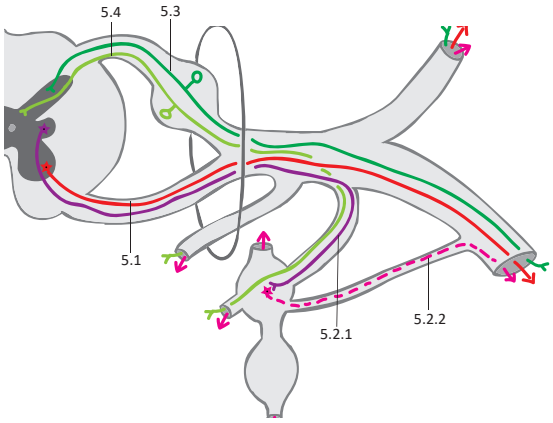

Scheme of the spinal nerve

This copy belongs to ali yaghoubi

The nervous system **constantly monitors changes of external and internal environments**. **A reflex is a physiological phenomenon** that occurs in response to a change in the **internal or the external environment**. The reflex arc provides the anatomical basis for a reflex. It consists of a peripheral receptor, which transmits a signal to the CNS, where the signal is processed and a command is given to an effector organ. Reflex arcs may contain a **various number of synapses**. The simplest reflex arc is the monosynaptic reflex, which consists of two neurones: an afferent sensory neurone and a efferent motor neurone.

Receptors

– react to changes in the external and internal environments
– transduce these changes to action potentials, which pass information to the CNS

Division according to the location of the stimulus:

1 **Exteroreceptors** – receptors that react to stimuli in the external environment
2 **Interoreceptors** – receptors that react to stimuli in the internal environment
  2.1 **Proprioceptors** – receptors located in muscles, tendons and joint capsules that provide information about the location of different parts of the body
  2.2 **Visceroreceptors** – receptors located in the internal organs and vessels

Division according to the nature of the stimulus:

1 **Mechanoreceptors** – react to mechanical stimuli (touch, pressure, vibration, stretch)
2 **Chemoreceptors** – react to chemical stimuli
3 **Thermoreceptors** – react to temperature
4 **Photoreceptors** – react to light

Afferent (centripetal) pathways

– conduct signals from receptors to the CNS
– are formed by axons of sensory neurons
– their cell bodies are located outside the CNS in the dorsal root ganglia
1 **Somatosensory** (somatic sensory) – transfer signals from receptors in the skin and structures of the locomotor system
2 **Viscerosensory** (visceral sensory) – transfer signals from visceroreceptors in the internal organs
3 **Special sensory** – carry signals from the special sense organs (vision, hearing, motion and balance, smell and taste)

Efferent (centrifugal) pathways

– transmit impulses from the CNS to effector organs in the periphery through efferent neurones
– the efferent neurone is the (somatomotor or visceromotor) lower motor neuron
– the cell body of the efferent neuron is located in the spinal cord, its axon leaves the CNS to form the motor part of the peripheral nerve
1 **Somatomotor tracts** – innervate striated muscle
2 **Visceromotor tracts** – innervate smooth muscles and glandular cells

Effectors

– an organ or a tissue executing the commands of the CNS
1 **Muscle cells** – contraction of skeletal muscles (somatomotor / somatic motor) myocardial and smooth muscles (visceromotor / visceral motor)
2 **Glands** – secretion (sweat, saliva, tears and glands of hollow organs)

The reflex arc

- 1 **Receptor**
- 2 **Afferent branch**
- 3 **Neurons within the CNS**
- 4 **Efferent branch**
- 5 **Effector**

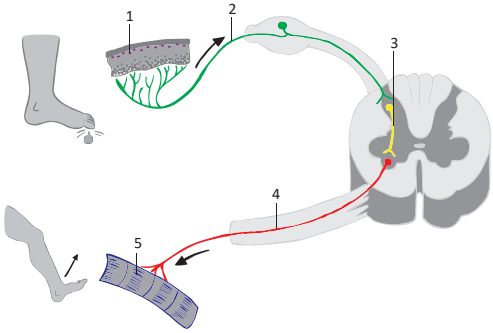

A mixed nerve (*nervus mixtus*) contains several different types of nerve fibres. Most nerves are mixed nerves and contain somatomotor, somatosensory, visceromotor and viscerosensory fibres.

Examples of purely sensory cutaneous nerves: saphenous nerve, sural nerve and lateral cutaneus nerve of the forearm.

The stretch (myotatic) reflex is a monosynaptic reflex. The afferent limb originates in the muscle spindle, travels in the spinal nerve and posterior root, enters the spinal cord and synapses on an alpha motor neurone in the anterior horn. The efferent limb (the alpha motor neurone) travels to the neuromuscular junction and synapses on a muscle. Transection of a peripheral nerve will abolish its corresponding reflex, resulting in areflexia. Damage to the spinal cord above a reflex arc results in destruction of inhibiting impulses from higher neuronal centres, resulting in hyper-reflexia.

Polysynaptic reflex arcs contain one or more interneurons between the afferent and efferent limbs.

Muscles originate from the segmentally organised somites. Each somite gives rise to muscle tissue (myotome), part of the skeleton (sclerotome) and an area of skin and subcutaneous tissue (dermatome). Each somite is innervated by one segment of the spinal cord. The structures that the somite differentiates into retain this innervation as they mature and migrate to form different parts of the body. The myotome divides into an epaxial and a hypaxial division. The epaxial muscles are located posterior to the vertebral column and are innervated by the posterior branches of the spinal nerves. The hypaxial muscles are located ventral to the vertebral column and are innervated by the anterior branches of the spinal nerves. The musculature of the limbs originates from the hypaxial division; thus, all plexuses are derived from the anterior branches of the spinal nerves

Sensory radicular area (*area radicularis sensoria*) is the area of the skin (dermatome) innervated by one posterior spinal root.

Motor radicular area (*area radicularis motoria*) is the muscles (myotome) that are innervated by one anterior spinal root.

Dermatome (*area nervina*) is the area (peripheral nerve field) innervated by one peripheral nerve.

There are 31 pairs of spinal nerves. After leaving the intervertebral foramen, the spinal nerve divides into **two main branches: the posterior branch** (*ramus posterior*) **and the anterior branch** (*ramus anterior*). Both branches contain afferent and efferent fibres. The **posterior branches** retain segmental organisation and provide motor innervation of the epaxial muscles of the back and the sensory innervation of the nape, back and buttocks. The **anterior branches form plexuses** (*plexus nervosi*) for the limbs and retain **segmental organisation** only in the **thoracic nerves** (*nervi thoracici*).

Spinal nerves

1 **Cervical nerves** (*nervi cervicales*) C1 to C8
– 8 pairs of cervical nerves, which innervate the skin and muscles of the upper limbs, head and neck
2 **Thoracic nerves** (*nervi thoracici*) T1 to T12
– 12 pairs of thoracic nerves, which innervate the intercostal muscles, skin and muscles of the back and thorax
3 **Lumbar nerves** (*nervi lumbales*) L1 to L5
– 5 pairs of lumbar nerves, which innervate the muscles and skin of the abdomen, thighs and skin of the genital organs
4 **Sacral nerves** (*nervi sacrales*) S1 to S5
– 5 pairs of sacral nerves, which innervate the skin and muscles of the lower extremities
5 **Coccygeal nerve** (*nervus coccygeus*) Co
– 1 pair, rudimentary in humans

Posterior branches of the spinal nerves

– are thinner and shorter than the anterior branches
– innervate the posterior (epaxial) part of the trunk
– provide motor innervation for the epaxial muscles of the back
– provide sensory innervation for the skin of the nape, back and buttocks
– retain segmental organisation

- 1 **Suboccipital nerve** (*nervus suboccipitalis*) – the posterior branch of C1
  – a purely motor nerve for the suboccipital muscles and the semispinalis capitis
- 2 **Greater occipital nerve** (*nervus occipitalis major*)
  – the posterior branch of C2
  – a purely somatosensory nerve for the skin posterior to the interauricular line (a line joining the auricles in the frontal plane)
- 3 **Third occipital nerve** (*nervus occipitalis tertius*)
  – the posterior branch of C3
  – a purely somatosensory nerve innervating a narrow area of the skin medial to the greater occipital nerve

4 **Superior clunial nerves** (*nervi clunium superiores*)
– the posterior branches of L1 to L3
– provides somatosensory innervation of the superior gluteal region
5 **Middle clunial nerves** (*nervi clunium medii*)
– the posterior branches of S1 to S3
– provides somatosensory innervation of part of the gluteal region

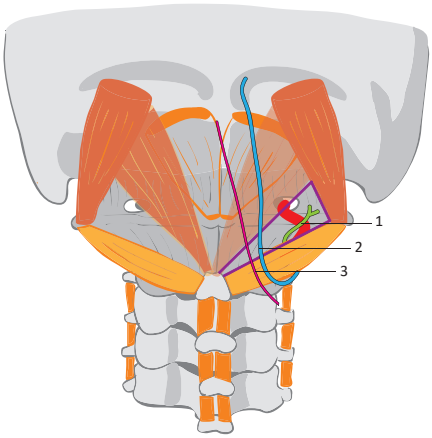

Suboccipital triangle and occipital nerves, posterior view

Anterior branches of the spinal nerves

– are longer and thicker branches than the posterior branches
– provide both motor and sensory innervation of the limbs and the hypaxial part of the trunk
– provide motor innervation of the muscles of the anterior abdomen, thorax and neck (except for the suprahyoid muscles)
– provide sensory innervation of the skin on the anterior aspect of the abdomen and thorax

- 1 **Cervical plexus** (*plexus cervicalis*) – C1 to C4
- 2 **Brachial plexus** (*plexus brachialis*) – C4 to T1
- 3 **Thoracic nerves** (*nervi thoracici*) – T1 to T12
- 4 **Lumbar plexus** (*plexus lumbalis*) – T12 to L4
- 5 **Sacral plexus** (*plexus sacralis*) – L4 and L5 and S1 to S4

6 **Coccygeal plexus** (*plexus coccygeus*) – S5 and Co

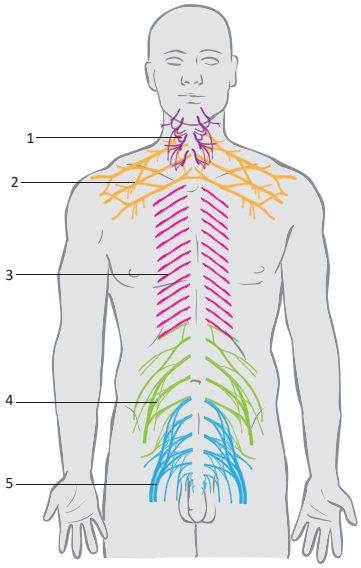

Anterior branches of the spinal nerves

This copy belongs to ali yaghoubi

The **cervical plexus** consists of spinal nerves **C1 to C4** and is located in the lateral cervical region. It produces both sensory and motor nerves. The sensory nerves reach the skin through the **the nerve point** (*punctum nervosum*), a gap in the superficial cervical fascia located approximately half-way along the posterior margin of the sternocleidomastoid. **The motor nerves** innervate the **anterior group** of cervical muscles. **The phrenic nerve** passes through the mediastinum and innervates the diaphragm.

Somatosensory branches

- 1 **Lesser occipital nerve** (*nervus occipitalis minor*) – C2 to C3
  - – a somatosensory nerve, which travels along the posterior margin of the sternocleidomastoid in a cranial direction
  - – innervates the lateral part of the nape region
- 2 **Great auricular nerve** (*nervus auricularis magnus*) – C2 to C3
  - – a somatosensory nerve, which travels along the sternocleidomastoid muscle in a cranial direction
  - 2.1 **Anterior branch** (*ramus anterior*) – innervates the skin over the anterior part of the auricle of the inferior part in the parotideomasseteric region
  - 2.2 **Posterior branch** (*ramus posterior*) – innervates the skin of the posterior part of the auricle and the mastoid region
- 3 **Transverse cervical nerve** (*nervus transversus colli*) – C3
  - – runs ventrally across the sternocleidomastoid muscle
  - 3.1 **Superior branch** (*ramus superior*) – innervates the skin of the suprahyoid region
    - 3.1.1 **Superficial ansa cervicalis** (*ansa cervicalis superficialis*)
      - – a loop forming a connection with the cervical branch of the facial nerve (*ramus colli nervi facialis*), which carries motor fibres for the platysma
  - 3.2 **Inferior branch** (*ramus inferior*) – innervates the skin of the infrahyoid region
- 4 **Supraclavicular nerves** (*nervi supraclaviculares*) – C3 to C4
  - – three groups of sensory nerves
  - – pass superficially over the clavicle giving off branches in a caudal direction
  - 4.1 **Medial supraclavicular nerves** (*nervi supraclaviculares mediales*)
    - – innervate the skin over the manubrium
  - 4.2 **Intermediate supraclavicular nerves** (*nervi supraclaviculares intermedii*)
    - – innervate the skin of the infraclavicular region (*regio infraclavicularis*)
  - 4.3 **Lateral supraclavicular nerves** (*nervi supraclaviculares laterales*)
    - – innervate the skin of the acromial region (*regio acromialis*)

- 5 **Nerve point** (*punctum nervosum*) – the point where the sensory cervical nerves pass through the superficial layer of the cervical fascia, emerging dorsally to the sternocleidomastoid muscle

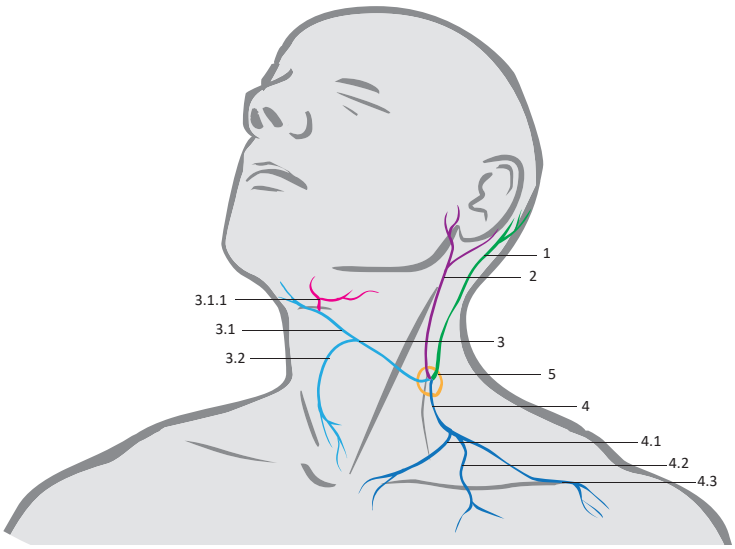

Somatosensory branches of the cervical plexus

The hypoglossal nerve joins and travels with the superior root of the deep ansa cervicalis *(radix superior ansae cervicalis profundae)*. However, it does not participate in the motor innervation of the infrahyoid muscles.

Clinical notes

Surgical procedures in the area of the carotid bifurcation require very careful precision not to injury the motor branches of the cervical plexus.

The phrenic nerve must not be harmed when opening the pericardium during heart surgery.

Phrenic nerve irritation results in twitches of the diaphragm causing hiccups (singultus).

Unilateral damage to the phrenic nerve leads to ipsilateral paresis of the diaphragm and unilateral respiratory impairment.

Transverse lesions of the spinal cord above C4 often lead to respiratory arrest. This is common in vertebral column trauma.

Plexus and branches

- 1 **Muscular branches** (*rami musculares*) – C1 to C4
  - – innervate the rectus capitis lateralis, rectus capitis anterior, longus capitis, longus colli muscles, scalenus anterior and scalenus medius
- 2 **Deep cervical loop** (*ansa cervicalis profunda*)
  - – innervates the infrahyoid muscles,
  - – is formed by the superior and inferior roots
    - 2.1 **Superior root** (*radix superior*) – C1 and C2
      - – motor branches of the cervical plexus
      - – travels with the hypoglossal nerve, but does not exchange of fibres
      - – leaves the hypoglossal nerve as it passes the internal carotid artery
      - – then descends to join the inferior root
    - 2.2 **Inferior root** (*radix inferior*) – C2 to C3
      - – motor branches of the cervical plexus
      - – joins the superior root
- 3 **Lesser occipital nerve** (*nervus occipitalis minor*) – C2 to C3
- 4 **Great auricular nerve** (*nervus auricularis magnus*) – C2 to C3
- 5 **Transverse cervical nerve** (*nervus transversus colli*) – C3
- 6 **Supraclavicular nerves** (*nervi supraclaviculares*) – C3 to C4
- 7 **Phrenic nerve** (*nervus phrenicus*) – C3 to C5

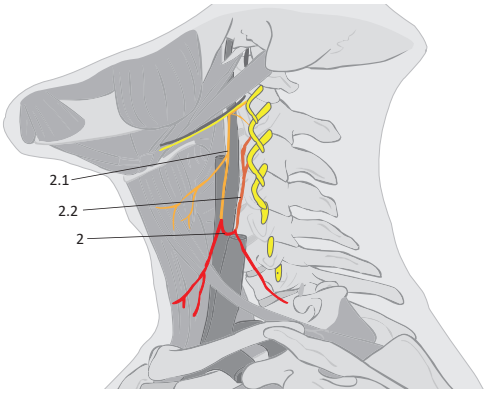

Deep cervical loop, lateral view

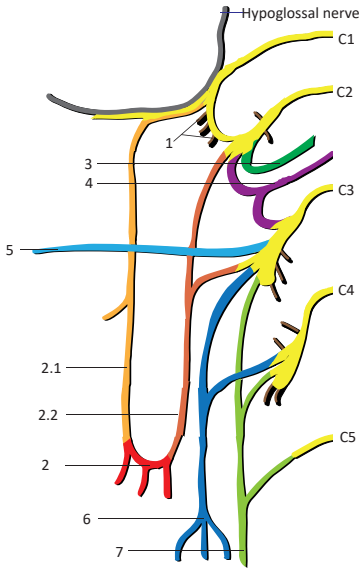

Scheme of the cervical plexus

Mixed branch

- **Phrenic nerve** (*nervus phrenicus*)
  - – from C4, with accessory fibres from C3 and C5
  - – descends bilaterally on the surface of the anterior scalenus muscle and travels through the superior thoracic aperture to reach the thoracic cavity

  Right phrenic nerve (*nervus phrenicus dexter*)
  - – passes between the right subclavian artery and vein
  - – descends on the right side from the right brachiocephalic vein and right superior vena cava
  - – runs on the surface of the pericardium and enters the diaphragm near the caval opening

  Left phrenic nerve (*nervus phrenicus sinister*)
  - – passes between the left subclavian artery and vein
  - – descends behind the left brachiocephalic vein ventrally to the aortic arch and pulmonary hilum
  - – runs on the surface of the pericardium and enters the diaphragm at or venral to the central tendon

  Branches of the phrenic nerve
  - 1 **Phrenic branches** (*rami phrenici*)
    - – provide motor innervation of the diaphragm
  - 2 **Pericardial branches** (*rami pericardiaci*)
    - – provide somatosensory innervation of the pericardium
  - 3 **Pleural branches** (*rami pleurales*)
    - – provide somatosensory innervation of the mediastinal and diaphragmatic pleura
  - 4 **Phrenicoabdominal branches** (*rami phrenicoabdominales*)
    - – provide somatosensory innervation of the parietal peritoneum under the diaphragm (down to the gallbladder and pancreas)
  - 5 Sensory branches for the thymus

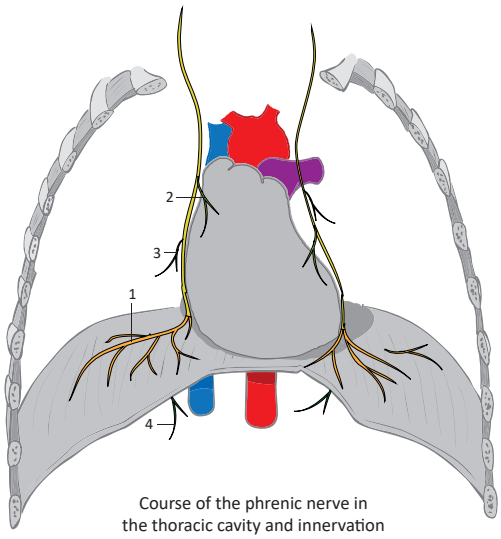

Course of the phrenic nerve in the thoracic cavity and innervation of the diaphragm, anterior view

This copy belongs to ali yaghoubi

The initial part of the brachial plexus consists of the anterior branches of spinal nerves **C5–C8** and connections from **spinal segments C4 and T1**. These roots converge to form **three parallel trunks: the superior** (C4–C6), **middle** (C7), **and inferior** (C8–T1) **trunks**. The trunks pass through the **scalenic fissure** into the omoclavicular triangle and then divide to form the cords. The clavicle divides the plexus topographically into a **supraclavicular and an infraclavicular part**.

- 1 **Anterior branches of spinal nerves** (*rami anteriores nervorum spinalium*)
  2 **Trunks** *(trunci)*
  - 2.1 **Superior trunk** (*truncus superior*)
  - 2.2 **Middle trunk** (*truncus medius*)
  - 2.3 **Inferior trunk** (*truncus inferior*)

  3 **Divisions**
  4 **Cords** *(fasciculi)*
  - 4.1 **Medial cord** (*fasciculus medialis*)
  - 4.2 **Posterior cord** (*fasciculus posterior*)
  - 4.3 **Lateral cord** (*fasciculus lateralis*)
- 5 **Supraclavicular part** (*pars supraclavicularis*)
- 6 **Infraclavicular part** (*pars infraclavicularis*)

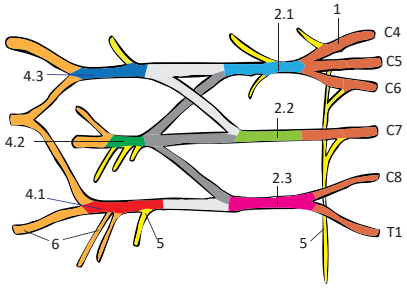

The trunks of the brachial plexus divide to form the cords. Three posterior divisions form the posterior cord, two anterior divisions form the lateral cord and one anterior division forms the medial cord.

The cords of the brachial plexus are named according to their position to the axillary artery.

Erb's point (*punctum supraclaviculare*) is located 2–3 cm above a point between the middle and lateral thirds of the clavicle, anterior to the transverse projection of vertebra C6 and lateral to the sternocleidomastoid. Hypersensitivity in this area indicates damage to the brachial plexus.

The nerves innervating the muscles of the anterior side of the arm, forearm and hand originate from the anterior branches of the brachial plexus (from the medial and lateral cords). The posterior groups of the arm and forearm are innervated by the radial nerve, which is a branch of the posterior cord.

The musculocutaneous nerve is the only nerve of the arm that penetrates a muscle (the coracobrachialis).

2.2.1 Supraclavicular part of the brachial plexus

The **supraclavicular part of the brachial plexus** (*pars supraclavicularis plexus brachialis*) gives off nerves in the omoclavicular triangle, which innervate the **spinohumeral, thoracohumeral and scapular muscles**. Somatomotor fibres predominate in these nerves.

- 1 **Dorsal scapular nerve** (*nervus dorsalis scapulae)* – C5
  – penetrates the scalenus medius and follows the deep branch of the transverse cervical artery
  – innervates the levator scapulae and rhomboid major and minor
- 2 **Suprascapular nerve** (*nervus suprascapularis*) – C4 to C5
  – follows the suprascapular artery and veins towards the suprascapular notch
  – passes underneath the superior transverse scapular ligament to reach the supraspinous fossa
  – passes through the spinoglenoid notch to reach the infraspinous fossa
  – innervates the supraspinatus and infraspinatus, and provides sensory innervation for part of the capsule of the shoulder joint
- 3 **Subscapular nerves** (*nervi subscapulares*) – C5 to C7
  – two branches innervating the subscapularis and teres major
- 4 **Long thoracic nerve** (*nervus thoracicus longus*) – C6 to C7
  – provides motor innervation for the serratus anterior
  – travels with the lateral thoracic artery and vein on the lateral side of the thorax
- 5 **Thoracodorsal nerve** (*nervus thoracodorsalis*) – C6 to C8
  – innervates the latissimus dorsi
  – travels with the thoracodorsal vessels on the lateral side of the scapula and the latissimus dorsi
- 6 **Subclavian nerve** (*nervus subclavius*) – C5 to C6
  – a small nerve for the subclavius
  7 **Pectoral nerves** (*nervi pectorales*) – C5–T1
  - 7.1 **Lateral pectoral nerve** (*nervus pectoralis lateralis*)
  - 7.2 **Medial pectoral nerve** (*nervus pectoralis medialis*)
    – emerges from the clavipectoral triangle
    – innervates the pectoralis major and minor

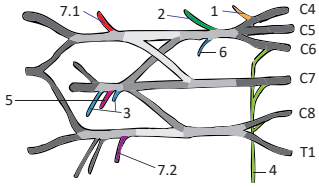

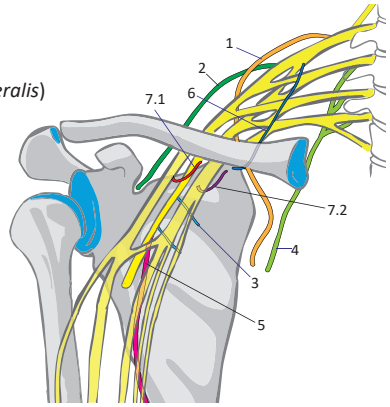

Clinical notes

Paresis of the long thoracic nerve impairs the function of the serratus anterior. The scapula no longer adheres strongly to the thorax and so protrudes from the patient's back as what is called a winged scapula (*scapula alata*). Abduction of the arm above the horizontal plane is also impaired.

The median nerve is most commonly damaged in the carpal tunnel, which results in carpal tunnel syndrome. Shoulder dislocation and stab and bullet wounds can damage the nerve in the axilla. Colles' fracture and slash wounds on the wrist may damage the nerve in the forearm. Damage to the median nerve results in impaired pronation of the forearm (pronator teres and quadratus), impaired opposition and flexion of the thumb (opponens pollicis and the deep head of the flexor pollicis brevis) and impaired flexion of the second and third finger. Flexion of the fourth and fifth finger is preserved, due to the part of the flexor digitorum profundus innervated by the ulnar nerve. The clinical sign is called the "benedict hand (preacher's hand)".

The nerves of the **infraclavicular part of the brachial plexus** (*pars infraclavicularis plexus brachialis*) emerge from **the cords**. The cords are located around the **axillary artery** and give both mixed and purely sensory branches, which innervate the entire upper extremity. The cords eventually split into **7 terminal branches**. The **axillary nerve** and the **radial nerve** arise from the posterior cord, the **musculocutaneous nerve** from the lateral cord, and the **ulnar nerve** from the medial cord. The medial and the lateral cords give off the medial and lateral roots of the median nerve, which fuse to form the median nerve.

Infraclavicular part

- 1 **Medial cord** (*fasciculus medialis*)
  - 1.1 **Medial cutaneous nerve of arm** (*nervus cutaneus brachii medialis*)
  - 1.2 **Medial cutaneous nerve of forearm** (*nervus cutaneus antebrachii medialis*)
  - 1.3 **Ulnar nerve** (*nervus ulnaris*)
  - 1.4 **Medial root of median nerve** (*radix medialis nervi mediani*)
- 2 **Lateral cord** (*fasciculus lateralis)*
  - 2.1 **Musculocutaneous nerve** (*nervus musculocutaneus*)
  - 2.2 **Lateral root of median nerve** (*radix lateralis nervi mediani*)
- 3 **Posterior cord** (*fasciculus posterior)*
  - 3.1 **Axillary nerve** (*nervus axillaris*)
  - 3.2 **Radial nerve** (*nervus radialis*)

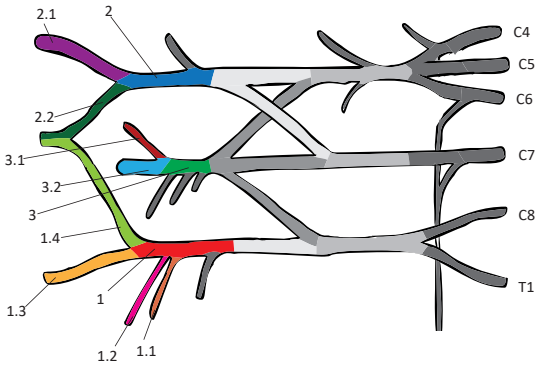

Lateral cord

- 1 **Musculocutaneus nerve** (C5–C7)

  Course
  1. penetrates the coracobrachialis
  2. passes between the biceps brachii and the brachialis
  3. its terminal branch runs on the lateral aspect of the forearm

  Branches and structures innervated

  1.1 **Motor branches for the anterior muscle group of the arm:** coracobrachialis, brachialis, biceps brachii

  1.2 **Lateral cutaneous nerve of forearm / lateral antebrachial cutaneous nerve** (*nervus cutaneus antebrachii lateralis*)
  – terminal sensory branch for the lateral forearm
- 2 **Median nerve** (C5–T1) – arises from the lateral and medial roots

  Course
  1. follows the brachial artery and veins within the medial brachial intermuscular septum (*septum intermusculare brachii mediale*)
  2. enters the cubital fossa (*fossa cubitalis*)
  3. runs within the pronator canal (*canalis pronatorius*) between the two heads of the pronator teres and then passes between the two heads of the flexor digitorum superficialis
  4. runs between the flexor digitorum superficialis and profundus in the forearm
  5. runs more superficially in the distal part of the forearm, between the palmaris longus and the flexor carpi radialis
  6. enters the palm though the carpal tunnel (*canalis carpi*)

  Branches and structures innervated:

  2.1 **Articular branches** (*rami articulares*) – sensory innervation for the elbow joint

  2.2 **Muscular branches and anterior interosseous nerve** (*rami musculares et nervus interosseus antebrachii anterior*)
  – motor innervation for almost all of the anterior antebrachial muscles: flexor carpi radialis, palmaris longus, pronator teres, flexor digitorum superficialis, flexor pollicis longus, flexor digitorum profundus (for the 2nd and 3rd finger), pronator quadratus

  2.3 **Palmar branch** (*ramus palmaris*)
  – provide sensory innervation for the skin of the thenar eminence

  2.4 **Common palmar digital nerves** (*nervi digitales palmares communes*) – I, II and III
  – motor branches for the muscles of the thenar eminence: abductor pollicis brevis, opponens pollicis and the superficial head of the flexor pollicis brevis,
  – motor branches for the 1st and 2nd lumbricals
  – split into the proper palmar digital nerves (*nervi digitales palmares proprii*) which innervate the skin of digits 1–3 and the radial side of the 4th digit and reach the distal phalanges on both the palmar and the dorsal sides

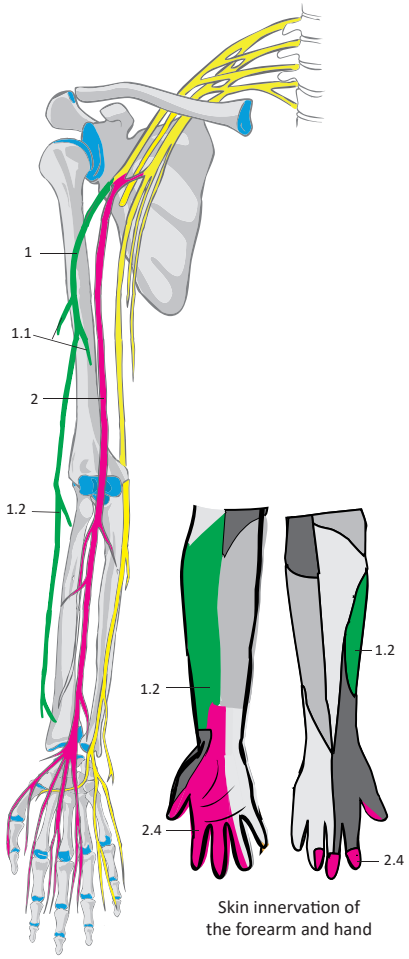

Skin innervation of the forearm and hand

This copy belongs to ali yaghoubi

Medial cord

- 1 **Medial cutaneous nerve of arm / medial brachial cutaneous nerve** (*nervus cutaneus brachii medialis*) – C8–T1
  – sensory innervation of the medial aspect of the arm
- 2 **Medial cutaneous nerve of forearm / medial antebrachial cutaneous nerve** (*nervus cutaneus antebrachii medialis*) – C8–T1
  – sensory innervation of the medial part of the forearm
  – follows the basilic vein through the hiatus basilicus

3 **Median nerve** – C5–T1
– arises from the lateral and medial roots

- 4 **Ulnar nerve** (*nervus ulnaris*) – C7–T1

Course

1. travels with the superior collateral ulnar artery and veins in the medial brachial intermuscular septum
2. passes through the groove for the ulnar nerve behind the medial epicondyle of the humerus, here it is covered by fascia and skin only
3. passes through the cubital canal between the two heads of the flexor carpi ulnaris
4. runs between and innervates the flexor carpi ulnaris and the flexor digitorum profundus
5. enters the palm via the ulnar canal

Branches and structures innervated:

4.1 **Articular branches** (*rami articulares*)
– sensory innervation of the elbow joint

4.2 **Muscular branches** (*rami musculares*) in the forearm
– provide motor innervation for the flexor carpi ulnaris and the part of the flexor digitorum profundus that acts on the 4th and 5th fingers

4.3 **Dorsal branch of ulnar nerve** (*ramus dorsalis nervi ulnaris*)
4.3.1 **Common and proper digital dorsal nerves** (*nervi digitales dorsales communes et proprii*)
– provide sensory innervation of the 4th and 5th fingers and the ulnar side of the 3rd finger

4.4 **Superficial branch of ulnar nerve** (*ramus superficialis nervi ulnaris*)
– travels in the palm of the hand
4.4.1 **Muscular branch** (*ramus muscularis*)
– innervates the palmaris brevis
4.4.2 **Common and proper palmar digital nerves** (*nervi digitales palmares communes et proprii*)
– provide sensory innervation for the 5th finger and the ulnar side of the 4th finger

4.5 **Deep branch of ulnar nerve** (*ramus profundus nervi ulnaris*)
– innervates all hypothenar muscles, palmar and dorsal interossei, lumbricals III and IV, adductor pollicis and deep head of the flexor pollicis brevis

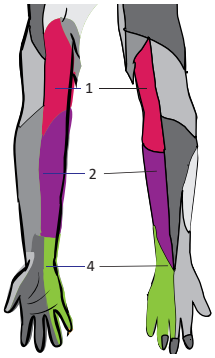

Skin innervation of the arm, forearm and hand

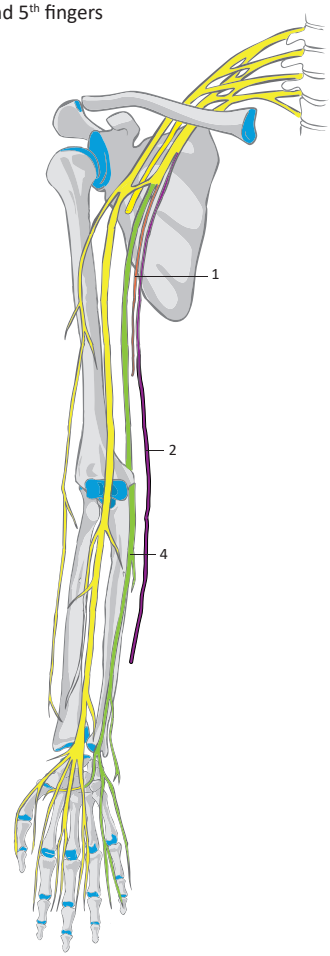

Right upper limb, forearm in supination

The lateral branches of the 2nd and 3rd intercostal nerves form the intercostobrachial nerve (*n. intercostobrachialis*), which runs through the axillary lymph nodes and joins the medial cutaneous nerve of the arm.

The ulnar nerve is particularly vulnerable as it travels behind the medial epicondyle. This point is colloquially known as the "funny bone".

The most commonly assessed reflexes of nerves originating in the brachial plexus are:
– the bicipital reflex (C5)
– the brachioradial reflex (C5–C6)
– the tricipital reflex (C7)
– the finger flexors (C8)

Clinical notes

The ulnar nerve is most commonly harmed in narrow anatomical spaces such as the cubital and ulnar canals. Fractures of the elbow and forearm often damage both the ulnar and median nerves. Injury to the ulnar nerve results in an impairment in motor function giving rise to the clinical appearance of a "claw hand".

Axillary nerve palsy can occur due to a fracture of the surgical neck of the humerus. It manifests as impaired abduction of the arm and predisposes to subluxations of the shoulder due to instability of the head of the humerus.

Radial nerve injuries are fairly common. They are usually caused by fractures of the distal part of the humerus affecting the groove for the radial nerve (Holstein-Lewis fractures). Fractures of the forearm may also affect the radial nerve. Radial nerve injuries manifest as an absent the tricipital reflex and weakness in elbow extension. Another prominent sign of radial nerve palsy is an inability to extend the wrist causing a condition called wrist drop.

Selective surgical transsection of the sensory branches of the posterior interosseous nerve of the forearm can relieve otherwise uncontrollable pain of the wrist (such that may occur in osteoarthrosis or rheumatoid arthritis).

Posterior cord

- 1 **Axillary nerve** (*nervus axillaris*) – C5–C6

  Course

  – passes with the posterior circumflex humeral artery and veins through the humerotricipital foramen to the posterior part of the surgical neck of the humerus

  Branches and structures innervated:

  1.1 **Muscular branches** (*rami musculares*)
  – innervate the deltoid and teres minor muscles

  1.2 **Articular branches** (*rami articulares*)
  – sensory innervation for a part of the shoulder joint capsule

  1.3 **Superior lateral cutaneous nerve of arm / superior lateral brachial cutaneous nerve** (*nervus cutaneus brachii lateralis superior*)
  – sensory innervation of the skin of the deltoid region

- 2 **Radial nerve** (*nervus radialis*)
  – C5–C8 and an additional branch from T1

  Course

  1. spirals down the radial canal (a space bound by the groove for the radial nerve and the medial and lateral heads of the triceps brachii on the posterior surface of the humerus) with the deep brachial artery and veins
  2. perforates the lateral intermuscular septum to enter the anterior compartment of the arm, where it travels between brachialis and the brachioradialis
  3. runs through the cubital fossa, where it divides into the superficial and deep branches
  4. the deep branch enters the dorsal forearm through the supinator canal (a space between two heads of the supinator)
  5. the superficial branch runs with the radial artery and veins to the radial fossa, where it divides into somatosensory branches for the dorsum of the hand

  Branches and structures innervated:

  2.1 **Muscular branches in the arm** (*rami musculares*)
  – innervate the triceps brachii and anconeus

  2.2 **Muscular branches in the forearm** (*rami musculares*)
  – innervate all posterior and lateral muscles of the forearm

  2.3 **Inferior lateral cutaneous nerve of arm / Inferior lateral brachial cutaneous nerve** (*nervus cutaneus brachii lateralis inferior*)
  – sensory innervation of the distal part of the deltoid region and lateral part of the arm

  2.4 **Posterior cutaneous nerve of arm / posterior brachial cutaneous nerve** (*nervus cutaneus brachii posterior*)
  – sensory innervation of the posterior side of the arm

  2.5 **Posterior cutaneous nerve of forearm / posterior antebrachial cutaneous nerve** (*nervus cutaneus antebrachii posterior*)
  – sensory innervation of the posterior side of the forearm

  2.6 **Superficial branch** (*ramus superficialis*)
  – branches from the radial nerve in the cubital fossa and travels with the radial vessels

  2.6.1 **Dorsal digital nerves** (*nervi digitales dorsales*)
  – sensory innervation of the thumb and forefinger and the radial side of the 3rd finger (proximal and middle phalanges only)

  2.7 **Deep branch** (*ramus profundus*) – runs through the supinator canal to get to the posterior compartment of the forearm, where it passes between the deep and superficial layers, giving off muscular branches

  2.7.1 **Posterior interosseous nerve** (*nervus interosseus antebrachii posterior*)
  – runs on the posterior side of the interosseous membrane of the forearm with the posterior interosseous vessels
  – innervates the periosteum of both the radius and ulna, the interosseous membrane and both radio-ulnar joints

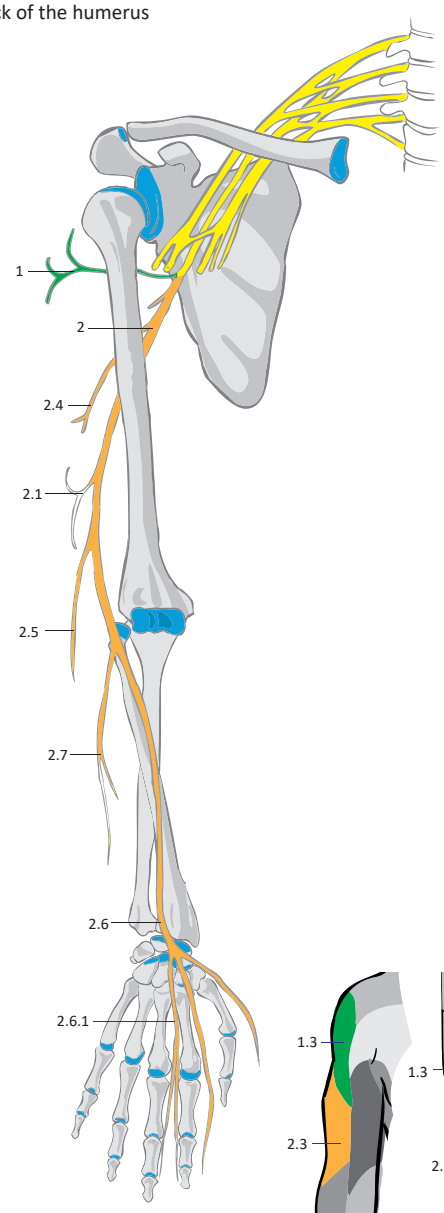

Right upper limb, forearm in pronation

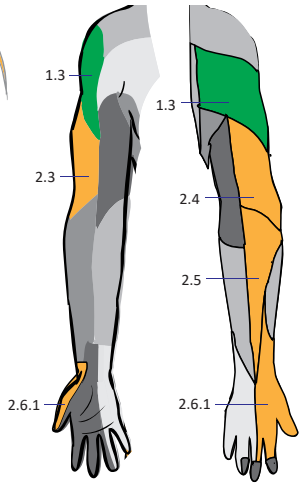

Skin innervation of arm, forearm and hand

This copy belongs to ali yaghoubi

The intercostal nerves are the **anterior branches of the thoracic nerves**. They retain **segmental organisation** and do not form plexuses. They run dorsally on the inner surface of the external intercostal muscles towards the costal angle. They follow the ribs ventrally between the internal and innermost intercostal muscles. Each intercostal space contains a **neurovascular bundle** consisting of an intercostal vein, artery and nerve. The nerve is the most inferior structure of the neurovascular bundle. The **subcostal nerve** is the anterior branch of the **last thoracic nerve** (T12) and runs inferiorly to the last rib.

1 **Muscular branches** (*rami musculares*)
– innervates the external, internal and innermost intercostal muscles, subcostales, transversus thoracis, rectus abdominis, external oblique, internal oblique, transversus abdominis, quadratus lumborum and pyramidalis

- 2 **Lateral cutaneous branches** (*rami cutanei laterales*) – somatosensory innervation of the lateral part of the mammary and inframammary regions and abdomen
- 3 **Anterior cutaneous branches** (*rami cutanei anteriores*) – somatosensory innervation of the medial part of the mammary and inframammary region and abdomen

4 Branches for the parietal pleura and peritoneum

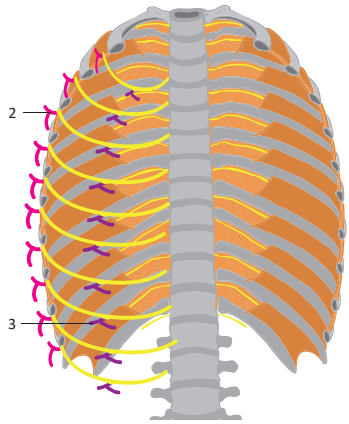

VAN is a mnemonic for the structures travelling in the intercostal space. The **V**ein is the most cranial structure, followed by the **A**rtery and then the **N**erve.

The most commonly assessed reflexes in the abdomen:
– the epigastric region is stimulated for assessing the T7-8 segment
– the mesogastric region is stimulated for assessing the T9–10 segment
– the hypogastric region is stimulated for assessing the T11–12 segment

The cremasteric reflex (L2) is provoked by stimulating the skin of the medial thigh with a sharp object. This induces contraction the cremaster muscle, causing the ipsilateral testis to ascend towards the body.

2.4 **Lumbar plexus** – Plexus lumbalis (T12–L4)

The **lumbar plexus** is formed from the **anterior branches of spinal nerves L1–L4** and a contributing branch from **T12**. The plexus is located within the **psoas major**, lateral to the lumbar vertebrae.

Lumbar plexus nerves

- 1 **Iliohypogastric nerve** (*nervus iliohypogastricus*)
- 2 **Ilioinguinal nerve** (*nervus ilioinguinalis*)
- 3 **Genitofemoral nerve** (*nervus genitofemoralis*)
- 4 **Lateral cutaneous nerve of thigh** (*nervus cutaneus femoris lateralis*)
- 5 **Femoral nerve** (*nervus femoralis*)
- 6 **Obturator nerve** (*nervus obturatorius*)

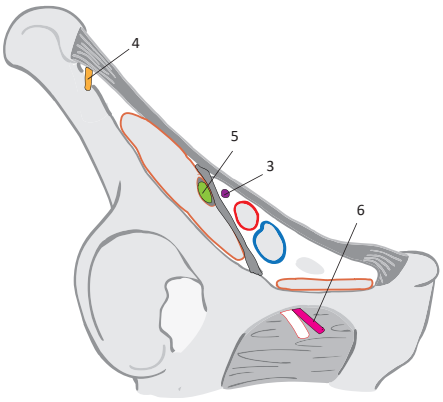

Vascular and muscular spaces and the obturator canal

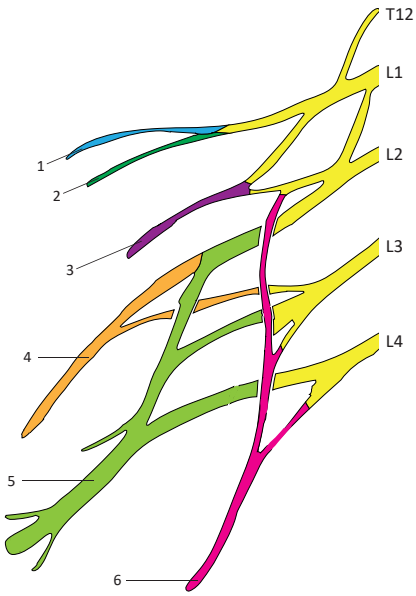

Scheme of the lumbar plexus

Clinical notes

Herpes zoster occurs after reactivation of the varicella-zoster virus lying latent inside a spinal ganglion. A painful vesicular rash appears on the dermatome supplied by the spinal nerve in which the virus is residing.

Pelvic fractures, hip dislocations, surgeries and incorrectly applied intramuscular injections can harm the femoral nerve. Induration of the inguinal lymphatic nodes and aneurysms of the femoral artery are the most common non-traumatic causes of femoral nerve injury. The motor symptoms of femoral nerve injury occur as are a result of impaired function of the quadriceps femoris. Walking without support and walking upstairs become difficult. It is impossible for the patient to raise his/her lower limb when lying supine. Standing and squatting become unstable. In certain cases, hyperextension of the knee (genu recurvatum, back knee) may occur when standing.

Meralgia paresthetica results from compression of the lateral cutaneous nerve of the thigh in the muscular space. Its symptomatology consists of acute intermittent pain and loss of sensation on the lateral thigh above the knee. It is common in obese and diabetic patients.

Branches

- 1 **Iliohypogastric nerve** (*nervus iliohypogastricus*) – T12–L1
  - – emerges laterally from the psoas major
  - – passes between the internal oblique and the transversus abdominis
  - – runs above the iliac crest travelling ventrocaudally
  - – terminates in the hypogastric and inguinal regions
  - 1.1 **Muscular branches** (*rami musculares*)
    - – motor branches for the internal oblique and transversus abdominis
  - 1.2 **Lateral cutaneous branch** (*ramus cutaneus lateralis*)
    - – somatosensory innervation of the skin of the lateral abdomen
  - 1.3 **Anterior cutaneous branch** (*ramus cutaneus anterior*)
    - – innervates the skin around the superficial inguinal ring
- 2 **Ilioinguinal nerve** (*nervus ilioinguinalis*) – L1
  - – emerges laterally from the psoas major and continues below the iliohypogastric nerve
  - – travels through the inguinal canal (*canalis inguinalis*)
  - – innervates the skin of the anterior part of the scrotum (in men) and the skin on the anterior part of the labia majora (in women)
- 3 **Genitofemoral nerve** (*nervus genitofemoralis*) – L2–L3
  - – penetrates the psoas major and leaves it on its ventral surface
  - 3.1 **Genital branch** (*ramus genitalis*) – passes through the inguinal canal
    - – innervates the cremaster, dartos fascia and a small area on the medial side of the thigh (in men)
    - – innervates part of the labia majora and a small area on the medial side of the thigh (in women)
  - 3.2 **Femoral branch** (*ramus femoralis*) – passes through the vascular space
    - – innervates the skin of the medial side of the thigh
- 4 **Lateral cutaneous nerve of thigh / lateral femoral cutaneous nerve** (*nervus cutaneus femoris lateralis*) – L2–L3
  - – emerges laterally from the psoas major
  - – runs laterocaudally on the iliacus towards the anterior superior iliac spine
  - – travels through the muscular space beneath the lateral attachment of the inguinal ligament to reach the lateral thigh
  - – provides somatosensory innervation for the lateral thigh
- 5 **Femoral nerve** (*nervus femoralis*) – L2–L4

  Course: emerges laterally from the psoas major, travels above the iliopsoas, passes medially through the muscular space to reach the anterior thigh and femoral triangle, then splits into muscular and cutaneous branches

  Branches and structures innervated:
  - 5.1 **Muscular branches** (*rami musculares*)
    - – innervate the iliopsoas, quadriceps femoris, sartorius and pectineus
  - 5.2 **Anterior cutaneous branches** (*rami cutanei anteriores*)
    - – provide somatosensory innervation for the anterior side of the thigh
  - 5.3 **Saphenous nerve** (*nervus saphenus*) – the terminal somatosensory branch, which follows the great saphenous vein distally on the leg
    - – runs in the adductor canal and leaves it ventrally through the vastoadductor lamina
    - – is accompanied by the descending genicular artery under the skin of the knee
    - – travels with the great saphenous vein under the skin of the leg
    - 5.3.1 **Infrapatellar branch** (*ramus infrapatellaris*)
      - – provides somatosensory innervation of the skin inferior to the patella
    - 5.3.2 **Medial cutaneous nerve of leg / medial crural cutaneous nerve** (*rami cutanei cruris mediales*) – provides somatosensory innervation for the skin of the medial part of the leg
- 6 **Obturator nerve** (*nervus obturatorius*) (L2–L4)

  Course: emerges medially from the psoas major and passes through the obturator canal

  Branches and structures innervated
  - 6.1 **Muscular branches** (*rami musculares*) – innervates the obturator externus
  - 6.2 **Anterior branch** (*ramus anterior*) – innervates the gracilis, adductor longus, adductor brevis, pectineus (a diploneural muscle also innervated by the femoral nerve) and provides somatosensory innervation for the medial thigh
  - 6.3 **Posterior branch** (*ramus posterior*) – innervates the adductor magnus (a diploneural muscle, also innervated by the sciatic nerve)
    - 6.3.1 **Articular branches** (*rami articulares*)
      - – participate in the somatosensory innervation of the hip joint

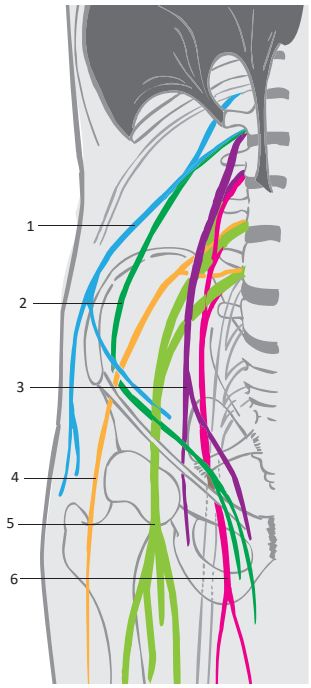

Anterior view of the right lumbar plexus

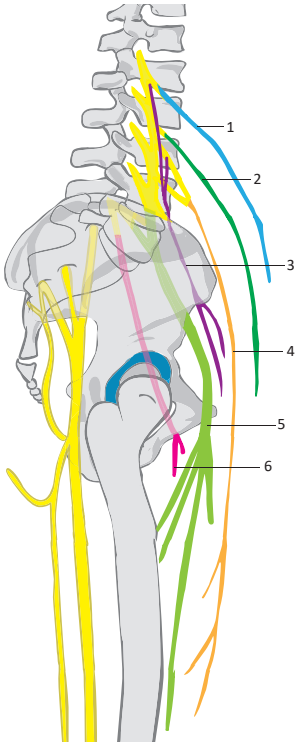

Lateral view of the right lumbar plexus

This copy belongs to ali yaghoubi

The **sacral plexus** arises from the spinal nerves of **S1 to S4** and recieves contributing branches from **L4 and L5** via the lumbosacral trunk (*truncus lumbosacralis*). It is located on the **pelvic surface of the sacral bone**. Along with the lumbar plexus it provides somatomotor and somatosensory innervation for the lower limb.

Nerves of the sacral plexus

- 1 **Superior gluteal nerve** (*nervus gluteus superior*)
- 2 **Inferior gluteal nerve** (*nervus gluteus inferior*)
- 3 **Posterior cutaneous nerve of thigh** (*nervus cutaneus femoris posterior*)
- 4 **Pudendal nerve** (*nervus pudendus*)
- 5 **Sciatic nerve** (*nervus ischiadicus*)

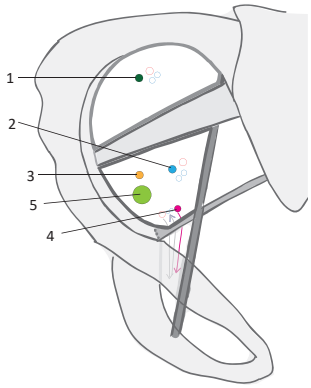

Posterior view of the left suprapiriform and infrapiriform foramina

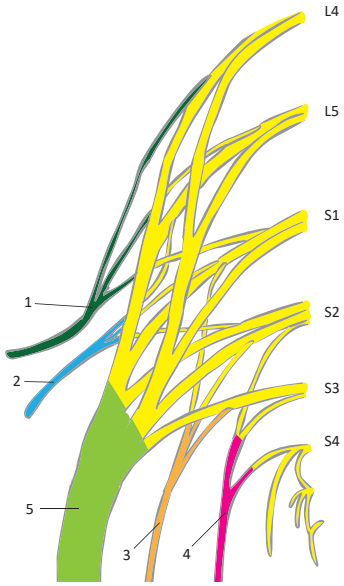

Nerves of the sacral plexus

Branches

1 **Superior gluteal nerve** (*nervus gluteus superior*) – L4–S1
– runs through the suprapiriform foramen with superior gluteal artery and veins
– innervates the gluteus medius, gluteus minimus and tensor fasciae latae

2 **Inferior gluteal nerve** (*nervus gluteus inferior*) – L5–S2
– runs through the infrapiriform foramen with the inferior gluteal artery and veins
– innervates the gluteus maximus

3 **Posterior cutaneous nerve of thigh / posterior femoral cutaneous nerve** (*nervus cutaneus femoris posterior*) – S1–S3
– runs through the infrapiriform foramen and passes over the inferior border of the gluteus maximus
– provides somatosensory innervation to the dorsal thigh,
– distally travels with the cranial extension of the small saphenous vein
3.1 **Inferior clunial nerve** (*nervi clunium inferiores*)
– provides somatosensory innervation to the distal part of the gluteal region
3.2 **Perineal branches** (*rami perineales*) – provide somatosensory innervation to the perineal skin

4 **Pudendal nerve** (*nervus pudendus*) – S2–S4
Course: runs through the infrapiriform foramen with the internal pudendal artery and veins, turns around the ischial spine into the lesser sciatic foramen, enters the ischioanal fossa and passes inside the pudendal canal to reach the external genital organs
Branches and structures innervated:
4.1 **Muscular branches** (*rami musculares*) – innervate the levator ani and ischiococcygeus
4.2 **Inferior rectal branches** (*nervi rectales inferiores*) – innervate the external anal sphincter and provide somatosensory innervation to the skin around the intergluteal crest
4.3 **Perineal nerves and muscular branches** (*nervi perineales et rami musculares*)
– motor branches for the transversus perinei superficialis, transversus perinei profundus, bulbospongiosus and ischiocavernosus
4.3.1 **Posterior scrotal nerves** (*nervi scrotales posteriores*)
– provide somatosensory innervation to the skin on the dorsal part of scrotum
4.3.2 **Posterior labial nerves** (*nervi labiales posteriores*)
– provide somatosensory innervation to the dorsal part of the labia
4.4 **Dorsal nerve of penis** (*nervus dorsalis penis*)
– provides somatosensory innervation to the penis and urethral mucosa
4.4 **Dorsal nerve of clitoris** (*nervus dorsalis clitoridis*) – somatosensory innervation of the clitoris

The sciatic nerve is the longest and thickest nerve in the human body. At its thickest point, it may be thicker than the spinal cord

The peroneal nerve (*nervus peroneus*) is a synonym for the fibular nerve.

Clinical notes

Paresis of the inferior gluteal nerve results in impaired function of the gluteus maximus, limiting extension of the hip joint. This causes difficulties in walking upstairs.

Disorders of the superior gluteal nerve lead to an impairment in abduction of the hip joint. Walking and standing on one foot become difficult and patients develop a duck-like gait. The Trendelenburg sign is positive. It is demonstrated by asking the patient to stand on the affected leg; the unsupported side of the pelvis will drop lower than the side the patient is standing on.

Pelvic fractures, hip dislocations and incorrectly applied injections can harm the sciatic nerve. Mild forms of sciatic nerve injury hinder the function of the extensors of the thigh and the flexors of the leg.

Damage to the tibial nerve usually occurs in the malleolar canal and can result from cut wounds, ankle fractures and incorrectly applied plasters. It presents as impaired plantar flexion (an inability to stand on tiptoes) due to impaired function of the triceps surae. The ankle jerk reflex is absent. Due to the predominance of the un-antagonised dorsal flexion of the tibialis anterior, the heel is the first part of the foot to touch the ground while walking. This results in a syndrome called "club foot" (*pes calcaneus*).

The fibular nerve is covered only by skin where it lies near the head of the fibula. In this location the nerve is most vulnerable to trauma and compression from incorrectly applied casts. Dislocations and sprains of the knee may also harm this nerve. The anterior muscles of the leg become impaired, resulting in a "flapping foot" and an inability to stand on the heels. The arches of the foot gradually deteriorate due to dysfunction of the fibularis longus.

5 **Sciatic nerve** (nervus ischiadicus) – L5–S2 with contributions from L4 and S3
Course: passes through the infrapiriform foramen between the muscles of the posterior thigh then descends distally towards the popliteal fossa
Branches and structures innervated – splits into two main branches (usually in the distal third of the thigh): the tibial nerve and the common fibular nerve
5.1 **Muscular branches** (*rami musculares*) – innervates the biceps femoris, semitendinosus, semimembranosus and part of the adductor magnus
5.2 **Articular branches** (*rami articulares*) – partial somatosensory innervation of the hip joint
5.3 **Common fibular nerve** (*nervus fibularis communis*)
– runs medially to the tendon of the biceps femoris and passes through the popliteal fossa into the fibular canal between the fibularis longus and the soleus behind the head of the fibula
5.3.1 **Articular branches** (*rami articulares*)
– somatosensory innervation of the knee joint and tibiofibular joint
5.3.2 **Lateral sural cutaneous nerve** (*nervus cutaneus surae lateralis*)
– provides somatosensory innervation to the lateral calf
– the sural communicating branch (*ramus communicans fibularis*) emerges from it and joins the medial sural cutaneous nerve; together they form the sural nerve (*nervus suralis*)
5.3.3 **Superficial fibular nerve** (*nervus fibularis superficialis*)
– runs between the fibula and the fibularis longus
– continues between the fibular muscles, which it innervates (muscular branches),
– penetrates the fascia, reaches the surface and runs superficially over the extensor retinacula
5.3.3.1 **Medial dorsal cutaneous nerve** (*nervus cutaneus dorsalis medialis*) – splits into the dorsal digital nerves of the foot (*nn. digitales dorsales pedis*) which innervate the medial side of the 1st toe, lateral side of the 2nd toe and medial side of the 3rd toe
5.3.3.2 **Intermedial dorsal cutaneous nerve** (*nervus cutaneus dorsalis intermedius*)
– splits into the dorsal digital nerves of the foot which innervate the lateral side of the 3rd toe, the whole of the 4th toe and the medial side of the 5th toe
5.3.4 **Deep fibular nerve** (*nervus fibularis profundus*)
– runs through the fibular canal and anterior intermuscular septum of the leg into a space between the tibialis anterior and extensor hallucis longus
– follows the anterior tibial artery and veins under the extensor retinaculum and emerges on the surface in the 1st interdigital space
5.3.4.1 **Lateral dorsal digital nerve of toe** (*nervus digitalis dorsalis hallucis lateralis*)
– somatosensory innervation of the lateral side of the 1st toe
5.3.4.2 **Medial dorsal digital nerve of toe** (*nervus digitalis dorsalis digiti secundi medialis*)
– somatosensory innervation of the medial side of the 2nd toe
5.4 **Tibial nerve** (*nervus tibialis*)
– passes through the popliteal fossa with the popliteal artery and vein
– travels with the posterior tibial artery and veins under the tendinous arch of the soleus
– descends between the posterior muscles of the calf
– reaches the sole via the malleolar canal (*canalis malleolaris*) and then divides into the medial and lateral plantar nerves (*n. plantaris medialis et lateralis*)
5.4.1 **Medial sural cutaneous nerve** (*nervus cutaneus surae medialis*)
– runs with the small saphenous vein under the skin
– joins the sural communicating branch (*ramus communicans fibularis*) from the lateral sural cutaneous nerve to form the sural nerve
5.4.1.1 **Sural nerve** (*nervus suralis*) – somatosensory innervation of the calf and lateral side of the heel, follows the small saphenous vein
5.4.2 **Muscular branches** (*rami musculares*) – innervates the posterior muscles of the calf
5.4.3 **Medial plantar nerve** (*nervus plantaris medialis*) – follows the medial plantar artery and veins
– innervates the abductor hallucis, flexor digitorum brevis and the 1st and 2nd lumbrical
5.4.3.1 **Proper plantar digital nerve of toe** (*nervus digitalis plantaris proprius hallucis*)
– innervates the flexor hallucis brevis and the skin of the medial side of 1st toe
5.4.3.2 **Common plantar digital nerves** (*nervi digitales plantares communes*)
– split into the proper digital plantar nerves (*nervi digitales plantares proprii*), which innervate the lateral side of the 1st toe, both sides of the 2nd and 3rd toe and the medial side of the 4th toe
5.4.4 **Lateral plantar nerve** (*nervus plantaris lateralis*) – travels with the lateral plantar artery and veins to the 5th toe and innervates the quadratus plantae
5.4.4.1 **Superficial branch** (*ramus superficialis*) – gives off the proper plantar digital nerves of the 4th and 5th toe
5.4.4.2 **Deep branch** (*ramus profundus*) – travels to the interossei and the oblique head of the adductor hallucis
– innervates the abductor digiti minimi, flexor digiti minimi brevis, interossei, adductor hallucis and the lumbricals of the 4th and 5th toes

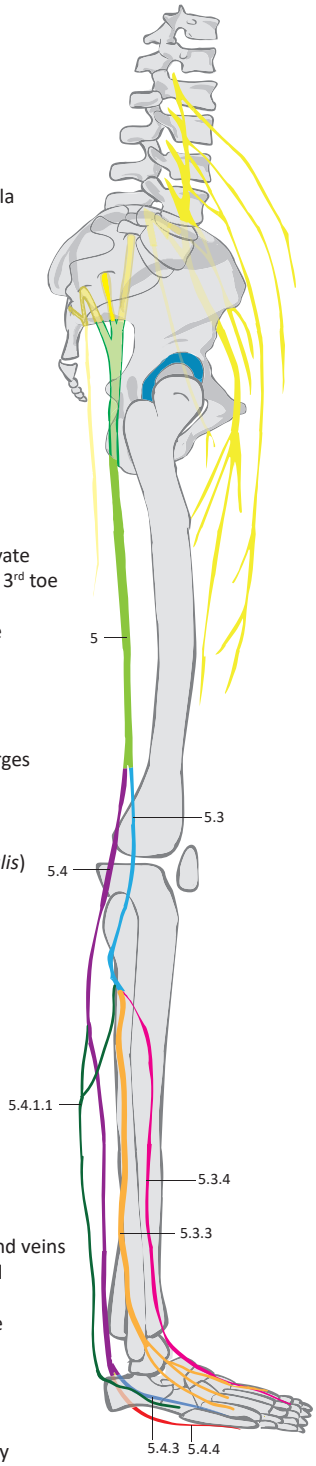

This copy belongs to ali yaghoubi

A dermatome (*area radicularis sensoria*) is an **area of skin innervated by a posterior root of a single spinal nerve**. **A myotome** (*area radicularis motorica*) is a **group of muscles innervated by an anterior root of a single spinal nerve**. Adjacent dermatomes may overlap, but never cross the midline of the body. Dermatomes retain segmental organisation on the thorax and abdomen and are arranged longitudinally along the long axes of the limbs. In the second intercostal space, the dermatomes skip from C4 to T2. The dermatome T4 contains the skin of the nipple; **T10** contains the **navel** (*umbilicus*).

Dermatomes

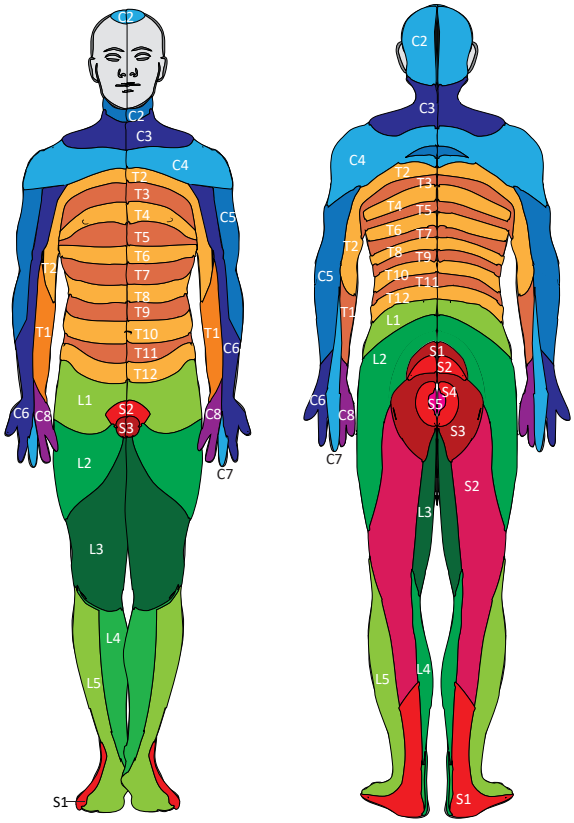

Head's zones – areas of referred pain

- 1 **Diaphragm** (C3–C5)
- 2 **Lungs** (T2–T5)
- 3 **Heart** (C8–T4)
- 4 **Oesophagus** (T4–T6) – the middle of the sternum
- 5 **Stomach** (T6–T9) – the epigastrium and the left part of the thorax
- 6 **Liver, gall bladder** (T7–T9) – the right subcostal area (Murphy's point), under the right scapula and the neck (both anterior and posterior aspects)
- 7 **Intestine**
  - 7.1 **Small intestine** (T8–L1)
  - 7.2 **Large intestine to the Cannon-Böhm point** (T11–L1) – aboral to the Cannon-Böhm point (L1–L2)
  - 7.3 **Vermiform appendix** (T11–T12)
- 8 **Pancreas** (T7–9) – dorsally to the inferior thoracic vertebra
- 9 **Kidneys** (T10–L1)
- 10 **Ureters and urinary bladder** (T11–L2)
- 11 **Uterine tubes** (T10–L1) **and uterus** (T12–L1)
- 12 **Ovaries and testes** (T10–T11)
- 13 **Uterine cervix and prostate** (S2–4)

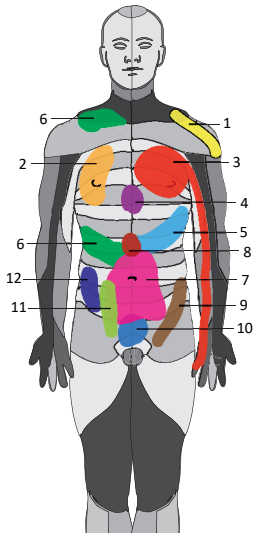

A myotome is a group of muscles, which preserves its segmental innervation and therefore is innervated by one anterior branch of a spinal nerve.

A dermatome is innervated by one posterior root of a spinal nerve. This is why the pain often spreads in strips.

The muscles innervated from one spinal segment share the same embryological origin.

One spinal segment does not exclusively supply one nerve. Therefore, the radial nerve (C5–C8) is partially formed by the same segments as the axillary nerve (C5–C6).

Clinical notes

Head's zones are areas of skin innervated by the same spinal cord segments as particular internal organs. Due to rich interconnections of neurons within the spinal cord (convergence), diseases of the internal organs may cause pain or hyperesthesia of certain skin areas (referred or radiating pain). The skin of the anterior thorax and left upper limb corresponds to the heart. Cardiac pain can radiate further to the ulnar side of the left forearm and the little finger. This occurs in diseases such as angina pectoris and myocardial infarction.

The proper knowledge of dermatomes helps determine the level of spinal cord injury.

Intervertebral disc herniation is the most common cause of harm to the spinal nerves. It typically occurs at the spinal roots of L5 or S1. The pain typically radiates into the corresponding dermatomes. This differs from pain in peripheral nerve fields caused by injury to a peripheral nerve.

Pain in the L5 dermatome spreads on the lateral side of the thigh and leg down to the dorsal side of the foot and big toe. This segment innervates several muscles; there is weakness of plantar extension and the patient is unable to walk on his heels or extend the big toe.

Pain in the S1 segment radiates on the posterior thigh and calf towards the 5th toe. The function of the gluteus maximus is impaired and the patient has difficulties standing up from sitting and struggles to walk on tip toes.

Peripheral nerve field refers to the structures innervated by a single peripheral nerve. **The peripheral skin nerve field** (*area nervina sensoria*) is the area of **skin innervated by a single peripheral nerve**. **The peripheral muscle nerve field** (*area nervina motorica*) is the **group of muscles innervated by a single peripheral nerve**.

Area radicularis (dermatome) versus area nervina (nerve field) – examples

- 1 **Dermatome C5** – the area of skin innervated by all the nerves derived from the C5 spinal nerve root
- 2 **Dermatome C6** – the area of skin innervated by all the nerves derived from the C6 spinal nerve root
- 3 **Peripheral skin nerve field C5–C6** – the skin area innervated by a peripheral nerve, originating from spinal roots C5 and C6

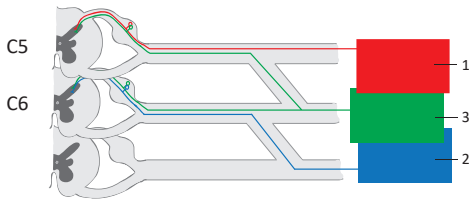

Area radicularis (dermatome) versus area nervina (nerve field)

Peripheral skin nerve fields (*areae nervinae sensoriae*)

1 **Trigeminal nerve**
- 1.1 **Ophthalmic nerve** – supraorbital nerve
- 1.2 **Maxillary nerve** – infraorbital nerve
- 1.3 **Mandibular nerve** – mental nerve

2 **Cervical plexus**
- 2.1 **Lesser occipital nerve** (C2–C3)
- 2.2 **Great auricular nerve** (C2–C3)
- 2.3 **Transverse cervical nerve** (C3)
- 2.4 **Supraclavicular nerves** (C3–C4)

3 **Brachial plexus**
- 3.1 **Axillary nerve** (C5–C6) – superior lateral cutaneous nerve of arm
- 3.2 **Radial nerve** (C5–T1) – inferior lateral and posterior cutaneous nerve of arm
- 3.3 **Medial cutaneous nerve of arm** (C8–T1)
- 3.4 **Medial cutaneous nerve of forearm** (C8–T1)
- 3.5 **Musculocutaneous nerve** (C5–C7)
  – lateral cutaneous nerve of forearm
- 3.6 **Radial nerve** (C6–C8)
  – posterior cutaneous nerve of forearm
- 3.7 **Ulnar nerve** (C7–T1)
- 3.8 **Radial nerve** (C6–C8) – superficial branch
- 3.9 **Median nerve** (C6–T1)

4 **Thoracic nerves**
- 4.1 **Intercostal nerves** – anterior cutaneous branches
- 4.2 **Intercostal nerves** – lateral cutaneous branches

5 **Lumbar plexus**
- 5.1 **Iliohypogastric nerve** (T12–L1)
- 5.2 **Ilioinguinal nerve** (L1)
- 5.3 **Lateral cutaneous nerve of thigh** (L2–L3)
- 5.4 **Genitofemoral nerve** (L1–L2)
- 5.5 **Femoral nerve** (L2–L4)
  – anterior cutaneous branches
  - 5.5.1 **Saphenous nerve**
- 5.6 **Obturator nerve** (L2–L4) – cutaneus branch

6 **Sacral plexus**
- 6.1 **Posterior cutaneous nerve of thigh** (S1–S3)
  - 6.1.1 **Inferior clunial nerves**
- 6.2 **Sciatic nerve** (L4–S3)
  - 6.2.1 **Common fibular nerve**
    – lateral sural cutaneous nerve
  - 6.2.2 **Superficial fibular nerve**
  - 6.2.3 **Deep fibular nerve**
  - 6.2.4 **Sural nerve**
  - 6.2.5 **Tibial nerve** – medial sural cutaneous nerve
  - 6.2.6 **Medial plantar nerve**
  - 6.2.7 **Lateral plantar nerve**
- 6.3 **Pudendal nerve** (S2–S4)

7 **Posterior branches**
- 7.1 **Greater occipital nerve** (C2)
- 7.2 **Third occipital nerve** (C3)
- 7.3 **Posterior branches of spinal nerves**
- 7.4 **Superior** (L1–L3) **and middle** (S1–S3) **clunial nerves**

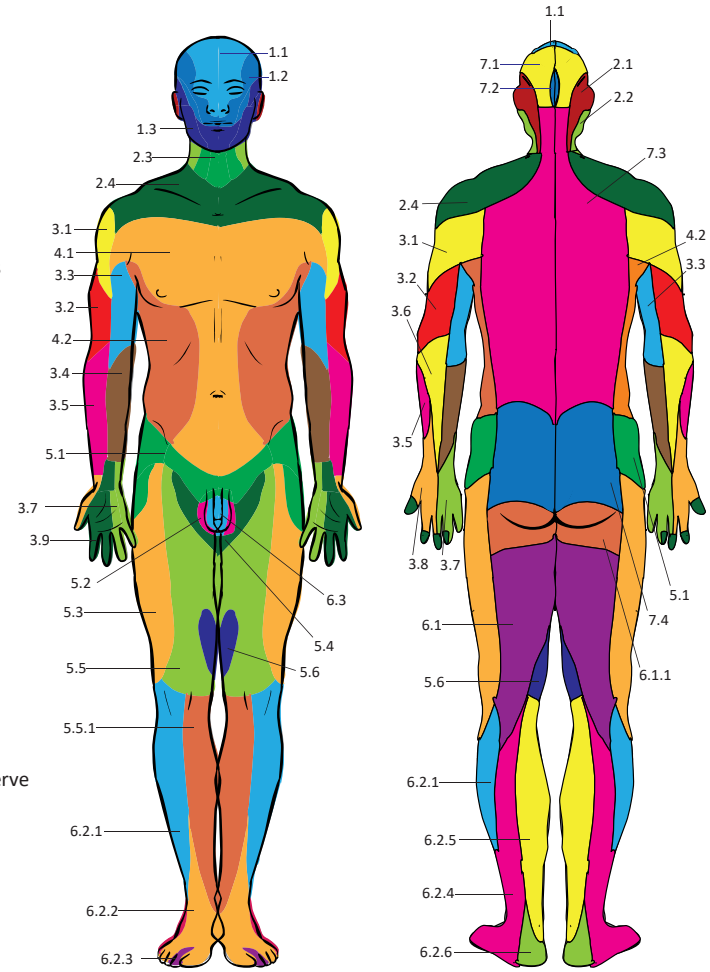

This copy belongs to ali yaghoubi

The twelve pairs of the cranial nerves emerge from the brain and brain stem. The first cranial nerve, **the olfactory nerve,** phylogenetically originates from the telencephalon. The second cranial nerve, **the optic nerve**, arises from the **diencephalon**. **The remaining ten pairs** emerge from the **brainstem**. From the developmental point of view, only these ten nerves are true cranial nerves.

Division

N. I **Olfactory nerve** (*nervus olfactorius*)
– **afferent:** sense of smell

N. II **Optic nerve** (*nervus opticus*)
– **afferent:** sense of vision

N. III **Oculomotor nerve** (*nervus oculomotorius*)
– **somatomotor:** four eye muscles (the superior, inferior and medial rectus and the inferior oblique) and the levator palpebrae superioris
– **visceromotor (parasympathetic):** the ciliary body and the sphincter pupillae

N. IV **Trochlear nerve** (*nervus trochlearis*)
– **somatomotor:** the superior oblique

N. V **Trigeminal nerve** (*nervus trigeminus*)
– **somatomotor:** the 4 masticatory muscles (masseter, temporalis and lateral and medial pterygoids), mylohyoid, anterior belly of the digastric, tensor veli palatini and tensor tympani
– **somatosensory:** the skin of the head ventral to the interauricular line, the dura mater and oral and nasal mucosa

N. VI **Abducent nerve** (*nervus abducens*)
– **somatomotor:** one eye muscle (the lateral rectus)

N. VII **Facial nerve** (*nervus facialis*)
– **somatomotor:** the stapedius, mimetic muscles, platysma, stylohyoid and posterior belly of the digastric
– **visceromotor (parasympathetic):** sublingual, submandibular and lacrimal glands and other small glands (nasal, palatine and nasopharyngeal)
– **special sensory:** sense of taste in the anterior 2/3 of the tongue

N. VIII **Vestibulocochlear nerve** (*nervus vestibulocochlearis*)
– **special sensory:** sense of hearing and balance

N. IX **Glossopharyngeal nerve** (*nervus glossopharyngeus*)
– **somatomotor:** the stylopharyngeus
– **visceromotor (parasympathetic):** innervation of the parotid gland and buccal glands
– **viscerosomatosensory:** carotid body and carotid sinus
– **somatosensory:** mucosa of the posterior part of the tongue, isthmus of the fauces, posterior part of the oral cavity, superior half of the pharynx, palatine tonsils and tympanic cavity
– **special sensory:** taste in the posterior third of the tongue

N. X **Vagus nerve** (*nervus vagus*)
– **somatomotor:** muscles of the pharynx, larynx and soft palate
– **visceromotor (parasympathetic):** trachea, bronchi, lungs, heart, oesophagus, liver, pancreas, small intestine, vermiform appendix, ascending colon, transverse colon, spleen, adrenals, kidneys, ovaries, testes
– **viscerosensory:** the aforementioned organs
– **somatosensory:** part of the auricle, external acoustic meatus, dura mater, larynx and pharynx
– **special sensory:** taste in the epiglottis

N. XI **Accessory nerve** (*nervus accessorius*)
– **somatomotor:** trapezius and sternocleidomastoid
some branches join the vagus nerve to innervate the laryngeal muscles

N. XII **Hypoglossal nerve** (*nervus hypoglossus*)
– **somatomotor:** 3 extraglossal (genioglossus, styloglossus and hyoglossus) and 4 intraglossal muscles (superior and inferior longitundinal, transverse and vertical muscles)

Classification according to the type of nerve fibres

Sensory:
Somatosensory – n. V, IX, X
Viscerosensory – n. IX, X
Special sensory – n. I, II, VII, VIII, IX, X

Motor:
Somatomotor (of somite origin) – n. III, IV, VI, XII
Branchiomotor (of branchial origin) – n. V, VII, IX, X, XI
Visceromotor (parasympathetic) – n. III, VII, IX, X

The cranial nerves are marked by Roman numerals I-XII.

A mnemonic for the origin of the cranial nerves: 1–1–2–4–4
1 nerve emerges from the telencephalon
1 nerve emerges from the diencephalon
2 nerves emerge from the mesencephalon
4 nerves emerge from the pons
4 nerves emerge from the medulla oblongata

The true cranial nerves originate from the brainstem nuclei.
The false cranial nerves are the olfactory nerve (n. I) and the optic nerve (n. II). The spinal root (radix spinalis) of the accessory and hypoglossal nerves arise from several spinal cord segments. They are drawn inside the skull during embryogenesis. This explains the close relation of the hypoglossal nerve to the deep cervical ansa.

The branchial motor (branchiomotor) neurones are somatomotor neurones for the muscles originating in the branchial (pharyngeal) arches.

The ganglia of the cranial nerves, just as the ganglia of the spinal nerves, contain pseudounipolar neurones. However, these ganglia have a different embryologic origin. They originate from neural crest cells and cells of the epibranchial (epipharyngeal) placodes.

The lateral mixed system is the name for the common origin of the glossopharyngeal, vagus and accessory nerves from the medulla oblongata and their shared pathway through the jugular foramen out of the skull. These nerves also share some nuclei in the brainstem.

The nuclei of the cranial nerves, see page 411.

Origin of the cranial nerves

Telencephalon
- N. I **Olfactory nerve**
  – the olfactory triangle

Diencephalon
- N. II **Optic nerve**
  – the lateral geniculate body

Mesencephalon
- N. III **Oculomotor nerve**
  – the groove for the oculomotor nerve in the interpeduncular fossa
- N. IV **Trochlear nerve**
  – caudal to the inferior colliculus

Pons
- N. V **Trigeminal nerve**
  – next to the middle cerebellar peduncle
  (*pedunculus cerebellaris medius*)
- N. VI **Abducens nerve**
  – the medullopontine sulcus at the border with the medulla oblongata
- N. VII **Facial nerve**
  – the cerebellopontine angle
- N. VIII **Vestibulocochlear nerve**
  – the cerebellopontine angle

Medulla oblongata
- N. IX **Glossopharyngeal nerve** – the retro-olivary groove
- N. X **Vagus nerve** – the retro-olivary groove
- N. XI **Accessory nerve** – the retro-olivary groove
- N. XII **Hypoglossal nerve** – the pre-olivary groove

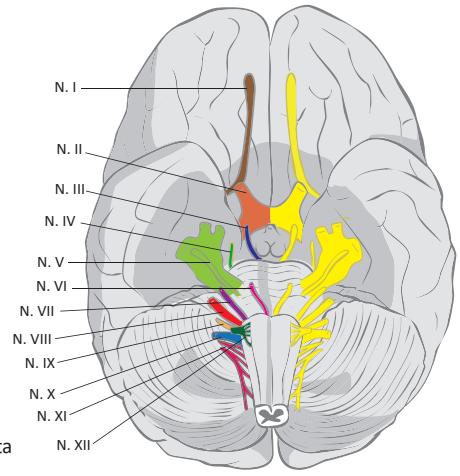

Origins of the cranial nerves

How the nerves leave the skull

Anterior cranial fossa (*fossa cranii anterior*)
- N. I **Olfactory nerve**
  – through the cribriform plate of the ethmoidal bone

Middle cranial fossa (*fossa cranii media*)
- N. II **Optic nerve**
  – through the optic canal of the sphenoid bone
- N. III **Oculomotor nerve**
  – through the superior orbital fissure of the sphenoid bone
- N. IV **Trochlear nerve**
  – through the superior orbital fissure of the sphenoid bone
- N. V **Trigeminal nerve** – through the sphenoid bone
  - V_1 **Ophthalmic nerve** (*nervus ophthalmicus*)
    – through the superior orbital fissure
  - V_2 **Maxillary nerve** (*nervus maxillaris*)
    – through the foramen rotundum
  - V_3 **Mandibular nerve** (*nervus mandibularis*)
    – through the foramen ovale
- N. VI **Abducent nerve**
  – through the superior orbital fissure of the sphenoid bone
- N. VII **Facial nerve**
  – through the internal acoustic meatus of the temporal bone
- N. VIII **Vestibulocochlear nerve**
  – through the internal acoustic meatus of the temporal bone

Posterior cranial fossa (*fossa cranii posterior*)
- N. IX **Glossopharyngeal nerve**
- N. X **Vagus nerve**
- N. XI **Accessory nerve**
  – through the posterolateral part of the jugular foramen
  (between the temporal and occipital bones)
- N. XII **Hypoglossal nerve**
  – through the hypoglossal canal

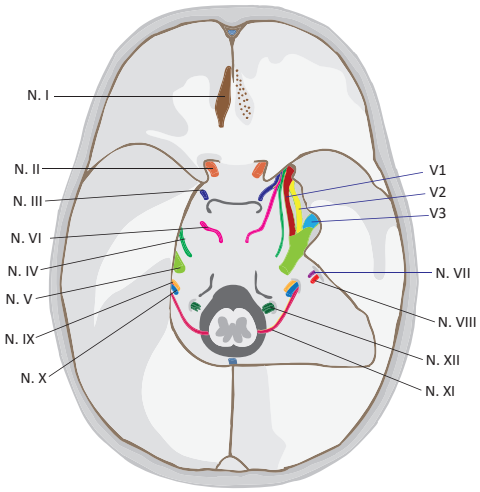

Course of the cranial nerves through the dura mater

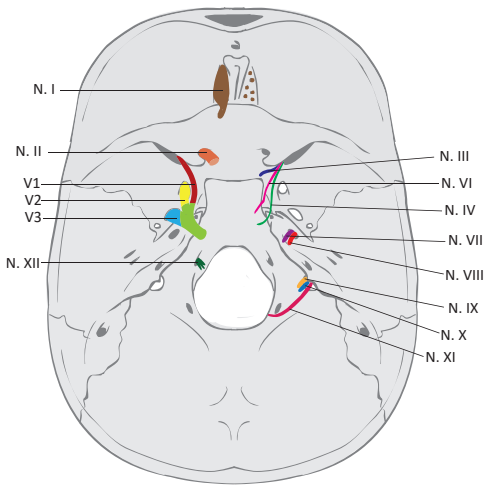

Course of the cranial nerves through the skull

This copy belongs to ali yaghoubi

The **olfactory nerve** conducts the sensation of smell to the brain via the olfactory bulb and tract. It develops from a **pouch of the telencephalon**. It consists of the axons of the olfactory cells **(fila olfactoria)** in the **nasal mucosa**, which penetrate the cribriform plate of the ethmoid bone and enter the anterior cranial fossa, where they synapse with the **mitral cells** in the olfactory bulb. The axons of mitral cells travel in the olfactory tract to the **olfactory trigone** and the **olfactory area** of the cerebral cortex.

- 1 **Olfactory region** (*pars olfactoria cavitatis nasi*) – specialised olfactory epithelium on the roof of the nasal cavity and superior part of the nasal septum
- 2 **Olfactory cells** – bipolar neurons
- 3 **Olfactory nerve** (*fila olfactoria / nervus olfactorius*)
  – consists of bundles of axons of the olfactory cells
  – passes through the cribriform plate to synapse in the olfactory bulb
- 4 **Olfactory bulb** – consists of olfactory nerve synapsing on mitral cells
- 5 **Olfactory tract** (*tractus olfactorius*) – the axons of the mitral cells
  – travels to the cortex and subcortical structures

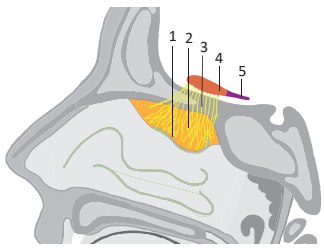

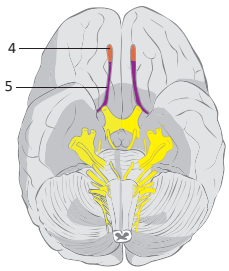

The neurones of the olfactory tract send impulses to the olfactory cortex for the conscious perception of smell. They also send impulses to some subcortical structures (the amygdala, septum verum and dorsomedial thalamus). The subcortical connections work in cooperation with the limbic system to create emotional reactions and revoke both good and bad memories in response to smell.

The fibres of the oculomotor nerve destined for the superior rectus decussate within the brain stem and join the contralateral nerve.

The fibres of the trochlear nerve decussate within the tectum of the mesencephalon.

Contraction of the ciliary muscle (*m. ciliaris*) focuses the eye on near objects. Relaxation focuses the eye on distant objects.

The sphincter pupillae (*m. sphincter pupillae*) narrows the pupil (miosis).

Visual pathway, see page 466.
Olfactory pathway, see page 462.

3.2 N. II Optic nerve – Nervus opticus

The optic nerve carries **visual information** to the brain via the optic tract. It develops from a pouch of the diencephalon. It consists of the **axons of the retinal ganglion** cells (the 3rd order neurons of the optic pathway). It originates on the posterior side of the eyeball and enters the cranial cavity through the **optic canal**. It passes through the **optic chiasma, where about half of its fibres decussate with the contralateral nerve** and then continues as the **optic tract** to the **lateral geniculate nucleus** in the metathalamus. The meninges cover the optic nerve in its entire course from the brain to the eyeball. Dura mater forms the external sheath of the optic nerve and the leptomeninges form the internal sheath of the optic nerve. The central retinal artery enters the optic nerve in the orbit and supplies the retina.

1 **Retina** – contains the 1st, 2nd and 3rd order neurons of the optic pathway
- 2 **Optic nerve** – the axon of the 3rd order neurons of the optic pathway (optic ganglion)
- 3 **Optic chiasma** – the decussation of the right and the left optic nerves
- 4 **Optic tract** – the continuation of the optic nerve to the metathalamus

5 **Lateral geniculate nucleus** – the site of synapse with the 4th order neurons of the optic pathway

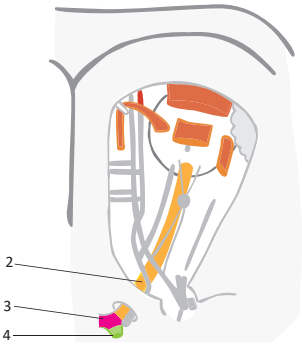

Superior view of the right orbit and the course of the optic nerve

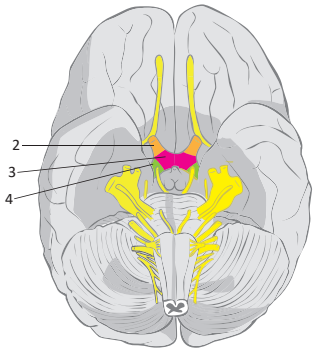

Clinical notes

Hyposmia is a reduced ability to smell.

Anosmia is a complete loss of smell.

Hyperosmia is increased sensitivity to smell.

Parosmia is a qualitative smell defect.

Unilateral paresis of the oculomotor nerve causes divergent strabismus, dilated pupil (mydriasis), impaired accommodation (cycloplegia), ptosis and double vision (diplopia).

Unilateral paresis of the trochlear nerve causes diplopia while looking down and laterally.

There are **two nuclei** for the oculomotor nerve in the **midbrain**: the nucleus of the oculomotor nerve and the accessory posterior nucleus of the oculomotor nerve. The oculomotor nerve emerges from the midbrain in the **interpeduncular fossa**. It penetrates the dura mater to run laterally in the wall of the **cavernous sinus**. It **enters the orbit** through the superior orbital fissure. **It carries parasympathetic fibres and somator motor fibres.** The parasympathetic fibres innervate the ciliary muscle, which focuses the eye on near objects (accomodation), and the sphincter pupillae, which constricts the pupil. The somatomotor fibres innervate most of the extraocular muscles.**The parasympathetic visceromotor** fibres synapse in the **ciliary ganglion**, which is located posterior to the eyball in the orbit.

Nuclei

- 1 **Nucleus of oculomotor nerve** (*nucleus nervi oculomotorii*)
  - – a somatomotor nucleus
  - – innervates the superior, inferior and medial rectus, inferior oblique and levator palpebrae superioris
- 2 **Accessory posterior nucleus of oculomotor nerve / Edinger-Westphal nucleus** (*nucleus accessorius dorsalis nervi oculomotorii*)
  - – a visceromotor parasympathetic nucleus
  - – innervates the sphincter pupillae and ciliary muscles

Course

1. emerges from midbrain in the interpeduncular fossa
2. penetrates the dura mater and runs laterocranially in the cavernous sinus
3. enters the orbit via the superior orbital fissure within the common tendinous ring (*anulus tendineus communis*)

Branches and structures innervated:

- 3 **Superior branch** (*ramus superior*)
  - – innervates the superior rectus and levator palpebrae superioris
- 4 **Inferior branch** (*ramus inferior*) –
  - – innervates the inferior and medial rectus and inferior oblique
  - 4.1 **Branch to ciliary ganglion** (*ramus ad ganglion ciliare*)
    - – parasympathetic preganglionic fibres from the Edinger-Westphal nucleus for the ciliary ganglion
- 5 **Ciliary ganglion** (*ganglion ciliare*) – a parasympathetic ganglion
  - – is located within the orbit, posterior to the eyeball and lateral to the optic nerve
  - 5.1 **Short ciliary nerves** (*nervi ciliares breves*)
    - – contain parasympathetic postganglionic fibres, which leave the ciliary ganglion to innervate the ciliary muscle and sphincter pupillae

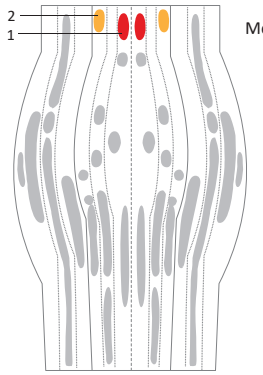

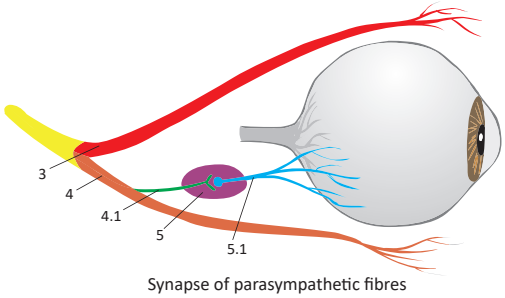

Synapse of parasympathetic fibres in the ciliary ganglion

3.4 N. IV Trochlear nerve – Nervus trochlearis

The trochlear nerve decussates in the midbrain before emerging under the inferior colliculus. It is the **only nerve that leaves from the posterior side of the brainstem**. It passes the lateral surface of the mesencephalon to enter and run on the lateral wall of the **cavernous sinus**. It then enters the orbit via the **superior orbital fissure**. The trochlear nerve is exclusively **somatomotor** and innervates only one muscle: **the superior oblique**.

- 1 **Trochlear nerve** (*nervus trochlearis*)

Nucleus

- 2 **Nucleus of trochlear nerve** (*nucleus nervi trochlearis*)
  - – a somatomotor nucleus in the mesencephalon
  - – innervates the superior oblique

Course

1. emerges under the inferior colliculus on the posterior side of the mesencephalon
3. passes around the cerebral peduncle within the cisterna ambiens
4. runs laterocranially in the cavernous sinus
5. enters the orbit via the superior orbital fissure, but not within the common tendinous ring

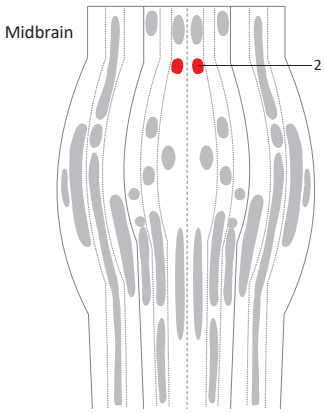

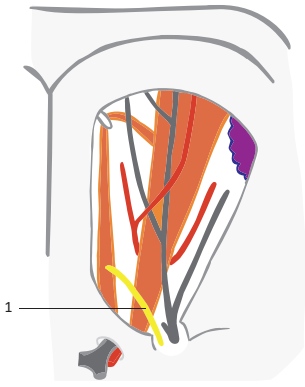

Superior view of the right orbit

This copy belongs to ali yaghoubi

The trigeminal nerve leaves the **pons** at the level of the middle cerebellar peduncle. The nerve has two roots: a **sensory root** (*radix sensoria*) and a **motor root** (*radix motoria*). The trunk of the nerve is formed from both roots and runs towards the apex of petrous part of the temporal bone, where the somatosensory **trigeminal ganglion** is located in the **trigeminal impression** (*impressio trigeminalis*). The nerve then splits into **three terminal branches**: the ophthalmic nerve, the maxillary nerve and the mandibular nerve. The skin and organs of the face and head up to the interauricular line receive **somatosensory fibres** from branches of the trigeminal nerve. All three branches of the trigeminal nerve carry somatosensory fibres, but only the **mandibular nerve contains motor fibres**. They innervate the **masticatory muscles** and four other **muscles**, which originate **from the first pharyngeal arch**. Parasympathetic and sympathetic fibres join peripheral branches of trigeminal nerve at autonomic ganglia to innervate glands and smooth muscle of the head and neck.

Nuclei

- 1 **Mesencephalic nucleus of trigeminal nerve** (*nucleus mesencephalicus nervi trigemini*)
  – the most dorsal nucleus in the mesencephalon
  – receives proprioceptive information from the masticatory, mimetic and extra-ocular muscles
- 2 **Principal nucleus of trigeminal nerve** (*nucleus principalis nervi trigemini*)
  – is located in the pons
  – receives information about fine touch, vibration and some proprioception
- 3 **Spinal nucleus of trigeminal nerve** (*nucleus spinalis nervi trigemini*) – is located in the medulla oblongata and spinal cord (C1–3)
  – receives information about crude touch, pain and temperature
  – receives the same modalities from n. IX and n. X
- 4 **Motor nucleus of trigeminal nerve** (*nucleus motorius nervi trigemini*) – is located in the pons
  – innervates the muscles of the first pharyngeal arch: masticatory muscles (masseter, temporalis, lateral and medial pterygoid), tensor tympani, tensor veli palatini, anterior belly of the digastric and the mylohyoid

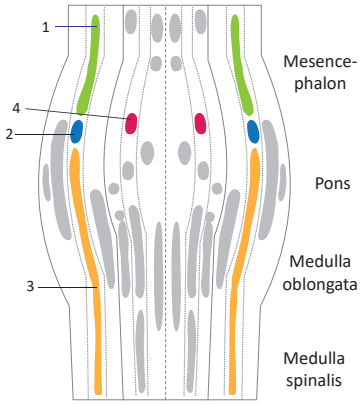

Distribution of the trigeminal nerve nuclei in the brainstem and spinal cord

Main branches

- 1 **Trigeminal nerve** (*nervus trigeminus*)
  - 1.1 **Trigeminal ganglion / Gasser's ganglion** (*ganglion trigeminale*)
- 2 **Ophthalmic nerve** (*nervus ophthalmicus*)
- 3 **Maxillary nerve** (*nervus maxillaris*)
- 4 **Mandibular nerve** (*nervus mandibularis*)

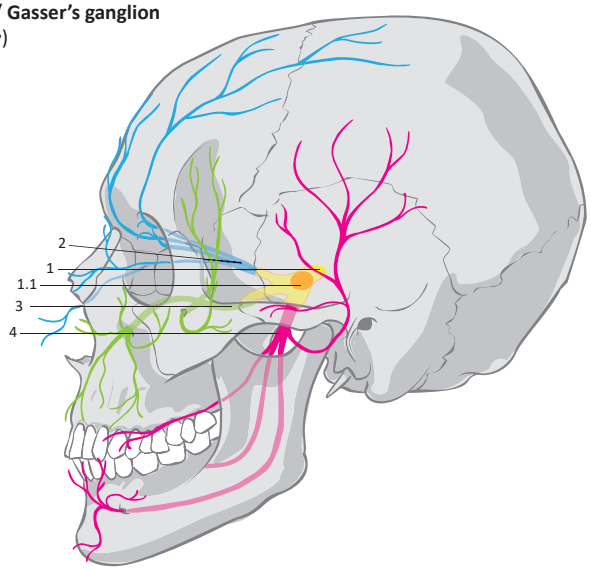

The trigeminal nerve is the largest cranial nerve.

The mesencephalic nucleus of the trigeminal nerve receives proprioception information from the masticatory muscles. A feedback loop is located between it and the motor nucleus of the trigeminal nerve. This ensures optimal masticatory muscles tension and prevents damage of the teeth.

The function of this loop may be demonstrated as follows: if you try to bite your tongue very strongly, the feedback loop diminishes the tension of the masticatory muscles in order to prevent injury.

The principal nucleus of the trigeminal nerve was formerly called the pontine nucleus of the trigeminal nerve.

The sensory part of the trigeminal nerve was formerly called the greater portion *(portio major)* and the motor part the lesser portion *(portio minor)*.

The points at which the branches of the trigeminal nerve leave the skull are palpable on the face:
V1 (as the supraorbital nerve)
– in the eyebrows, on a line passing vertically through the pupil
V2 (as the infraorbital nerve)
– inferior to the eye, on a line between the pupil and angle of the mouth
V3 (as the mental nerve)
– on the mandible, on a line passing vertically downwards from the angle of the mouth.
Painful palpation at any of these points signifies pathological irritation of the trigeminal nerve.

The superior and inferior dental and gingival branches (*rami gingivales et dentales superiores and inferiores*) form the superior and inferior dental plexus.

Clinical notes

Trigeminal neuralgia / prosopalgia is characterised by intensive unbearable episodic facial pain in areas innervated by branches of the trigeminal nerve (the supraorbital, infraorbital and mental nerves). The most common cause is impingement of the trigeminal nerve by an aberrant loop of the superior cerebellar artery at the junction between the CNS and PNS, where oligodendrocytes and Schwann cells meet (the Obersteiner-Redlich zone). This may be treated by microvascular decompression. Non-lesional causes can be treated by gama-knife surgery (radiosurgery) of the trigeminal ganglion.

V_1 Ophthalmic nerve (*nervus ophthalmicus*)

Fibres

– somatosensory innervation of the face (forehead, upper eyelids, nasal dorsum), part of the dura mater, the orbit and its content, part of the mucosa in the nasal cavity and the paranasal sinuses

Course

– passes through the superior orbital fissure into the orbit
– some of its branches continue to the forehead

Branches and structures innervated

- 1 **Lacrimal nerve** (*nervus lacrimalis*)
  – runs along the lateral rectus towards the lacrimal gland
  – receives a communicating branch with the zygomatic nerve (*ramus communicans nervi lacrimalis cum nervo zygomatico*), which brings parasympathetic fibres to the lacrimal gland
  – innervates the skin of the lateral part of the eyelid and the adjacent part of the conjunctiva
- 2 **Frontal nerve** (*nervus frontalis*)
  – runs between the orbital periosteum and the levator palpebrae superioris
  - 2.1 **Supratrochlear nerve** (*nervus supratrochlearis*) – innervates the skin and conjunctiva of the medial part of the eyelid and the skin of the forehead
  - 2.2 **Supraorbital nerve** (*nervus supraorbitalis*)
    - 2.2.1 **Medial branch** (*ramus medialis*) – leaves the orbit via the frontal notch
      – innervates the skin of the upper eyelid and forehead
    - 2.2.2 **Lateral branch** (*ramus lateralis*) – leaves the orbit via the supraorbital notch
      – innervates the skin of the upper eyelid and forehead
- 3 **Nasociliary nerve** (*nervus nasociliaris*)
  – runs from the lateral part of the orbit to its medial wall
  - 3.1 **Communicating branch with ciliary ganglion** (*ramus communicans cum ganglio ciliari*)
    – carries sensory fibres for the eyeball, which pass through the ciliary ganglion and then continue as the short ciliary nerves (*nervi ciliares breves*) to reach the eyeball
  - 3.2 **Long ciliary nerves** (*nervi ciliares longi*) – sensory innervation of the eyeball
  - 3.3 **Posterior ethmoidal nerve** (*nervus ethmoidalis posterior*)
    – leaves the orbit via the posterior ethmoidal foramen and orbitoethmoidal canal
  - 3.4 **Anterior ethmoidal nerve** (*nervus ethmoidalis anterior*) – leaves the orbit through the anterior ethmoidal foramen, runs through the orbitocranial canal and then through the cribriform plate into the nasal cavity
    – sensory innervation of the frontal sinus, anterior nasal mucosa and skin of the apex and dorsum of the nose
  - 3.5 **Infratrochlear nerve** (*nervus infratrochlearis*) – the terminal branch of the ophthalmic nerve
    – sensory innervation of the medial part of both eyelids and the adjacent conjunctiva

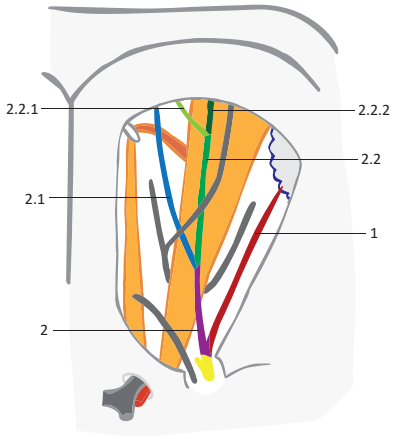

Superior level of the orbit – right side

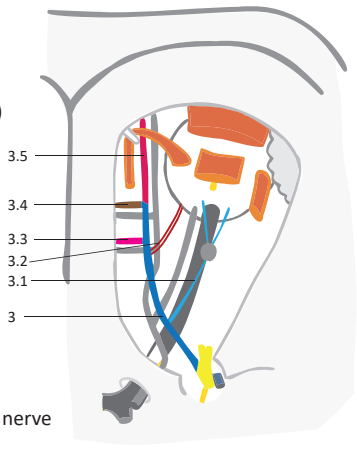

Middle level of the orbit – right side

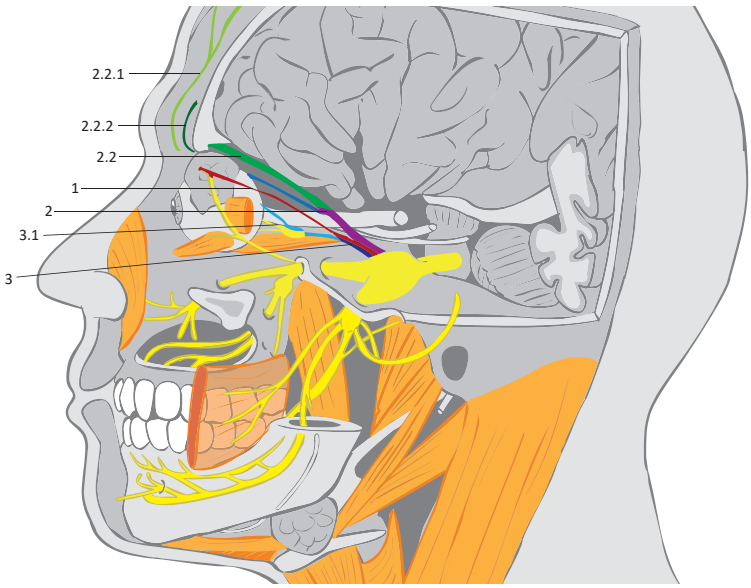

This copy belongs to ali yaghoubi

V_2 Maxillary nerve (*nervus maxillaris*)

Fibers

– somatosensory innervation of the middle part of the face (lower eyelid, upper lip, ala of nose and upper part of the cheek), upper teeth and part of the nasal, oral and nasopharyngeal mucosa

Course

– runs through the foramen rotundum to reach the pterygopalatine fossa
– branches at the pterygopalatine ganglion

Branches and structures innervated

- 1 **Zygomatic nerve** (*nervus zygomaticus*) – reaches the orbit via the inferior orbital fissure, runs on the inferior orbital wall
  – enters the zygomatico-orbital foramen and branches within the zygomatic bone
    - 1.1 **Zygomaticofacial branch** (*ramus zygomaticofacialis*)
      – reaches the upper lateral part of the cheek via the zygomaticofacial foramen
      – innervates the skin of the zygomatic region
    - 1.2 **Zygomaticotemporal branch** (*nervus zygomaticotemporalis*)
      – reaches the temporal fossa by passing through the zygomaticotemporal foramen
      – innervates the skin of the temporal region
- 2 **Infraorbital nerve** (*nervus infraorbitalis*) – enters the orbit through the inferior orbital fissure, runs in the infra-orbital groove then enters the infra-orbital canal
  – leaves the infra-orbital canal through the infra-orbital foramen to reach the anterior surface of the maxilla, where it branches into:
    - 2.1 **Inferior palpebral branches** (*rami palpebrales inferiores*)
      – innervate the skin and conjunctiva of the lower eyelid
    - 2.2 **Superior labial branches** (*rami labiales superiores*) – innervate the skin of the upper lip and the adjacent part of the mucosa in the oral vestibule
    - 2.3 **External nasal branches** (*rami nasales externi*) – innervate the skin of the ala of the nose
    - 2.4 **Internal nasal branches** (*rami nasales interni*) – innervate the nasal vestibule mucosa
- 3 **Posterior superior alveolar branches** (*rami alveolares superiores posteriores*)
  – travel towards the maxillary tuberosity and enter the alveolar foramina, then travel in the alveolar canals to reach the posterior upper teeth
    - 3.1 **Superior dental branches** (*rami dentales superiores*)
      – innervate the teeth of the upper jaw
    - 3.2 **Superior gingival branches** (*rami gingivales superiores*) – innervate the adjacent gingiva
- 4 **Anterior superior alveolar branches and middle superior alveolar branch** (*rami alveolares superiores anteriores et ramus alveolaris superior medius*)
  – originate in the infra-orbital canal and groove
    - 4.1 **Superior dental branches** (*rami dentales superiores*)
      – innervate the remaining teeth of the upper jaw
    - 4.2 **Superior gingival branches** (*rami gingivales superiores*) – innervate the adjacent gingiva
- 5 **Posterior nasal branches** (*rami nasales posteriores*)
  – innervate the posterior 2/3 of the nasal mucosa
- 6 **Greater palatine nerve** (*nervus palatinus major*) and **lesser palatine nerves** (*nervi palatini minores*) – innervate the mucosa of the hard and soft palates
- 7 **Pharyngeal nerve** (*nervus pharyngeus*) – innervate the mucosa of the nasopharynx

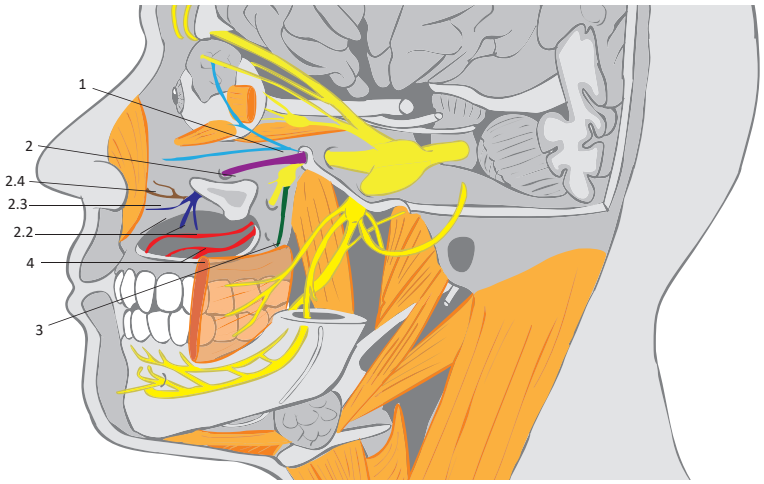

The three branches of the infraorbital nerve (for the eyelid, nose and upper lip) in the infra-orbital foramen are collectively known as the *pes anserinus minor*.

The function of the trigeminal nerve may be assessed by the following reflexes:
The masseter reflex is provoked by tapping the teeth of the lower jaw. Stretching tendon of the masseter evokes its contraction.
The corneal reflex is provoked by gently touching the conjunctiva. It results in the contraction of the orbicularis oculi (causing a wink). The ophthalmic nerve provides the afferent limb of the reflex arc and the facial nerve provides the efferent limb.

The trigeminal nerve innervates most of the meninges. Each of its branches gives off one meningeal branch:
V1 – tentorial branch (*ramus tentorius*) before passing through the superior orbital fissure
V2 – meningeal branch (*ramus meningeus*) before passing through the foramen rotundum
V3 – meningeal branch (*ramus meningeus*) is given off in the infratemporal fossa and enters the cranial cavity via the foramen spinosum.
The ventral part of the falx cerebri is innervated by the anterior ethmoidal nerve.
A tiny part of the meninges around the jugular foramen is innervated by the vagus nerve.

Clinical notes

Regional anaesthesia is different for the upper and lower jaw. For the lower teeth it is administered at a single point posterior to the 3rd molar, next to the trunk of the inferior alveolar nerve. For the upper teeth there are 3 points (anterior, middle, posterior) to administer anaesthesia to the individual branches of the infraorbital nerve as they leave the maxilla.

Herpes zoster ophthalmicus is caused by reactivation of the varicella-zoster virus in the ophthalmic nerve. It presents with a painful rash in of the skin innervated by the ophthalmic nerve and can affect the conjunctiva and cornea.

V_3 Mandibular nerve – *nervus mandibularis*

Fibres
– somatosensory innervation of the skin of the lower part of the face (lower lip, part of the cheek and chin), teeth of the lower jaw and part of the oral mucosa
– innervation of 8 muscles: 4 masticatory muscles, anterior belly of digastric, mylohyoid, tensor veli palatini and tensor tympani

Course
– travels through the foramen ovale to reach the infratemporal fossa, where it gives of its terminal branches
– the otic ganglion is found on the medial side of the nerve

Somatomotor branches
1 **Deep temporal branches** (*nervi temporales profundi*) – innervate the temporalis
2 **Medial and lateral pterygoid nerves** (*nervus pterygoideus medialis et lateralis*) – innervate the medial and lateral pterygoid muscles
3 **Masseteric nerve** (*nervus massetericus*) – innervates the masseter
4 **Mylohyoid muscle** (*nervus mylohyoideus*) – innervates the mylohyoid and the anterior belly of the digastric
5 Branches for the tensor veli palatini and tensor tympani

Somatosensory branches
- 1 **Meningeal branch** (*ramus meningeus*) – innervates the meninges of the middle cranial fossa
- 2 **Buccal nerve** (*nervus buccalis*) – innervates the skin of the face and the adjacent part of the oral mucosa
- 3 **Auriculotemporal nerve** (*nervus auriculotemporalis*) – innervates part of the auricle and the skin of the temporal region
  – forms a loop around the middle meningeal artery
- 4 **Inferior alveolar nerve** (*nervus alveolaris inferior*) – innervates the teeth, gingiva and oral mucosa
  – passes through the mandibular foramen and canal
  - 4.1 **Mental nerve** (*nervus mentalis*) – the terminal branch emerging from the mental foramen
    – innervates the skin covering the body of the mandible
- 5 **Lingual nerve** (*nervus lingualis*) – a thick nerve, somatosensory innervation of the anterior 2/3 of the tongue
  - 5.1 **Chorda tympani** – a branch of the facial nerve containing visceromotor and sensory taste fibers
    – joins the lingual nerve and continues to the submandibular ganglion and into the tongue
    – gustatory fibers carry taste information from the anterior 2/3 of the tongue (from the apex to the terminal sulcus, excluding the vallate papillae)

  5.2 **Submandibular ganglion** (*ganglion submandibulare*) – a parasympathetic ganglion for fibres from the facial nerve

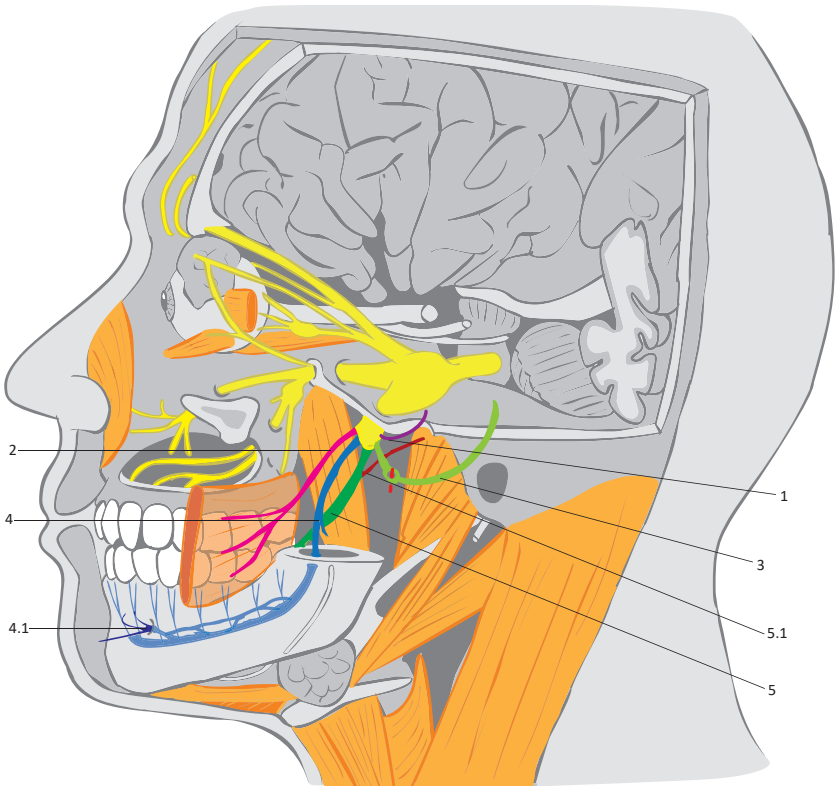

This copy belongs to ali yaghoubi

The abducent nerve originates at the border between the pons and the medulla oblongata, the **medullopontine sulcus** (*sulcus bulbopontinus*). It travels ventrolaterally on the internal surface of the base of the skull, penetrates the meninges and runs medially within the **cavernous sinus**. It reaches the **orbit** through the **superior orbital fissure** and common tendinous ring and innervates the **lateral rectus**, which causes the eyeball to abduct.

- 1 **Abducens/abducent nerve**

Nucleus

- 2 **Nucleus of abducens nerve** (*nucleus nervi abducentis*)
  - a somatomotor nucleus
  - is located in the pons, inferior to the facial colliculus
  - innervates the lateral rectus

Course

1. emerges from the medullopontine sulcus between the pons and medulla oblongata
2. leaves the brainstem on the ventral side
3. runs on the base of the skull, penetrates the dura mater then runs through Dorello canal to enter the cavernous sinus
4. enters the orbit via the superior orbital fissure and common tendinous ring

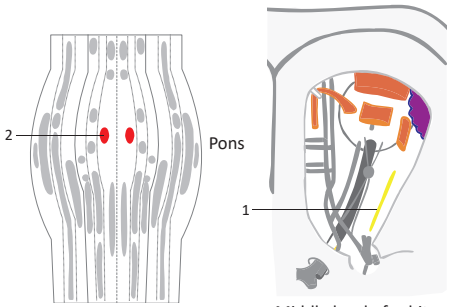

Middle level of orbit, right side

Dorello canal / canal of abducent nerve is a passage between the apex of the petrous part of the temporal bone and the petrosphenoideal ligament of Gruber. It contains the abducent nerve and inferior petrosal sinus. The abducent nerve is in an extradural position as it travels in this canal.

The gustatory nucleus is located in the rostral part of the solitary tract. It receives taste fibres from the facial nerve and sends impulses to the thalamus and cortex.

Clinical notes

Unilateral paresis of the abducent nerve manifests as convergent strabism and diplopia (double vision) when looking to the side.

Central paralysis of the facial nerve presents as a drop of the contralateral angle of the mouth. However, innervation of both eyelids remains unaltered. The most common cause is a stroke.

Peripheral paralysis of the facial nerve may arise from a lesion at any point of the nerve. It presents as dysfunction of both the upper and lower branches, so that one whole half of the face is affected. Apart from paresis of the orbicularis oris it has other manifestation, including:

Lagophthalmus – an inability to close the eye caused by dysfunction of the orbicularis oculi.

Xerophthalmia – conjunctival and corneal dryness caused by dysfunction of the lacrimal gland. It increases the risk of corneal scaring and subsequent blindness and eye infections.

Xerostomia – dryness of the mouth due to dysfunction of the sublingual and submandibular glands.

Hyperacusis – pain when hearing loud sounds due to an impaired stapedial reflex.

Hypogeusis – decreased perception of taste caused by dysfunction of the chorda tympani.

If the facial nerve is transsected (e.g. in parotidectomy), the lesion can be bridged by a graft from either the sural or hypoglossal nerve.

3.7 N. VII Facial nerve – Nervus facialis

The facial nerve develops from the **2nd pharyngeal arch.** It innervates **all the facial muscles**. It emerges from the pons near the cerebellopontine angle as two roots: the facial motor root and the intermediate nerve. The facial motor root carries somatomotor fibres and the intermediate nerve carries visceromotor and special sensory fibres. The two roots run in the **internal acoustic meatus** and then pass through the **facial nerve canal where they unite.** The facial nerve leaves the skull through the **stylomastoid foramen**. It gives off its terminal branches within the substance of the **parotid gland**.

Nuclei

- 1 **Motor nucleus of facial nerve** (*nucleus nervi facialis*)
  - a somatomotor nucleus for innervation of all facial muscles, platysma, stylohyoid and posterior belly of the digastric
- 2 **Superior salivatory nucleus** (*nucleus salivatorius superior*)
  - a visceromotor nucleus for parasympathetic innervation of the lacrimal gland, nasal glands, palatine glands, nasopharyngeal glands, submandibular gland, sublingual gland and lingual glands
- 3 **Gustatory nucleus** (*nucleus gustatorius*)
  - a special sensory nucleus
  - the rostral part of the nuclei of the solitary tract
  - receives impulses from the chorda tympani
- 4 **Spinal nucleus of trigeminal nerve** (*nucleus spinalis nervi trigemini*)
  - somatosensory fibres from the facial nerve synapse in this nucleus

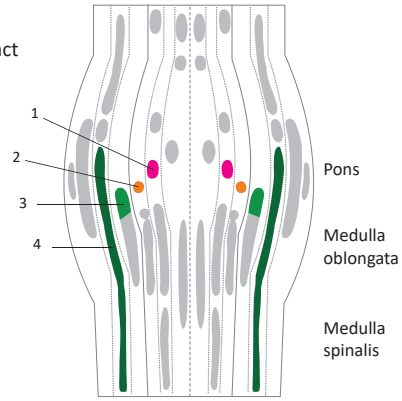

Parts

1 **Facial nerve** – somatomotor fibres
2 **Nervus intermedius**
2.1 **Visceromotor fibers (for glands)**
– greater petrosal nerve, chorda tympani
2.3 **Special sensory fibers (taste)**
– chorda tympani, greater petrosal nerve

Course

1. within the brainstem, it turns around the nucleus of the abducens nerve and thus elevates the facial colliculus on the floor of the fourth ventricle
2. leaves the pons at the **pontocerebellar angle**
3. runs in the posterior cerebral fossa
4. enters the internal acoustic canal and passes through the anterior superior quadrant of the fundus
   – this is where the **facial canal / Fallopian canal** (*canalis nervi facialis*) starts
5. travels through the facial canal
   - 5.1 runs ventrolaterally in the **labyrinthic part** (*pars labyrinthica*),
   - 5.2 takes a 90° turn at **the geniculum of the facial canal** (*geniculum canalis nervi facialis*),
   - 5.3 runs dorsolaterally in the **tympanic part** (*pars tympanica*),
   - 5.4 runs caudally in the **mastoid part** (*pars mastoidea*)
6. leaves the skull via the **stylomastoid foramen** (*foramen stylomastoideum*)
7. enters the parotid gland, where it splits into inferior and superior branches, which form the **parotid plexus** (*plexus intraparotideus*), which gives rise to the terminal branches for the facial muscles

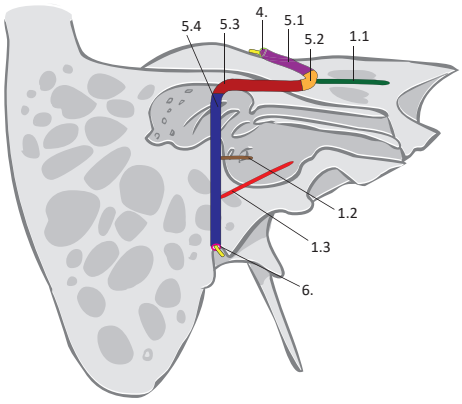

Right facial canal scheme, lateral view

Branches and structures innervated

1 **Branches arising within the facial canal**
- 1.1 **Greater petrosal nerve** (*nervus petrosus major*)
  – emerges from geniculum of the facial canal and runs in the canal for the greater petrosal nerve
  – travels through the hiatus for the greater petrosal nerve, then lies in the groove for the greater petrosal nerve
  – runs through the sphenopetrosal synchondrosis and the pterygoid canal
  – reaches the pterygopalatine fossa where it terminates in the pterygopalatine ganglion
  – brings parasympathetic fibres from superior salivatory nucleus and some taste fibres to the pterygopalatine ganglion
  - 1.1.1 **Geniculate ganglion** (*ganglion geniculi*) – a special sensory ganglion of the facial nerve located in the first flexure of the facial canal within the petrous part of the temporal bone
    – contains pseudounipolar neurons for the chorda tympani (taste fibres)
- 1.2 **Nerve to stapedius** (*nervus stapedius*) – branches from the facial nerve in the mastoid part of the facial canal
  – innervates the stapedius
- 1.3 **Chorda tympani** – branches from the facial nerve in the mastoid part of the facial canal
  – passes through the canaliculus for the chorda tympani to reach the tympanic cavity
  – runs within a mucosal fold between malleus and stapes and then turns ventrocaudally towards the petrotympanic fissure
  – leaves the tympanic cavity via the petrotympanic fissure to enter the infratemporal fossa
  – joins the lingual nerve to travel to the submandibular ganglion
  – provides parasympathetic innervation for the submandibular and sublingual glands and the lingual glands in the anterior 2/3 of the tongue

2 **Branches after the stylomastoid foramen**
- 2.1 **Posterior auricular nerve** (*nervus auricularis posterior*) – runs ventrally to the mastoid process on the medial surface of the auricle
  - 2.1.1 **Occipital branch** (*ramus occipitalis*) – innervates the occipital belly of the occipitofrontalis
  - 2.1.2 **Auricular branch** (*ramus auricularis*) – innervates the auricular muscles and the proper muscles of the auricle
- 2.2 **Digastric branch** (*ramus digastricus*)
  – innervates of the posterior belly of the digastric and the stylohyoid

3 **Branches forming the parotid plexus**
– somatomotor branches
- 3.1 **Temporal branches** (*rami temporales*)
  – innervate the facial muscles of the forehead (frontal region) and temporal region
- 3.2 **Zygomatic branches** (*rami zygomatici*)
  – innervate the orbicularis oculi, zygomatic muscles and muscles of the nose
- 3.3 **Buccal branches** (*rami buccales*) – innervate the muscles of the cheek and upper lip
- 3.4 **Marginal mandibular branch** (*ramus marginalis mandibulae*) – innervates the muscles of the chin and lower lip
- 3.5 **Cervical branch** (*ramus colli*)
  – innervates the platysma and participates in formation of the superficial cervical ansa

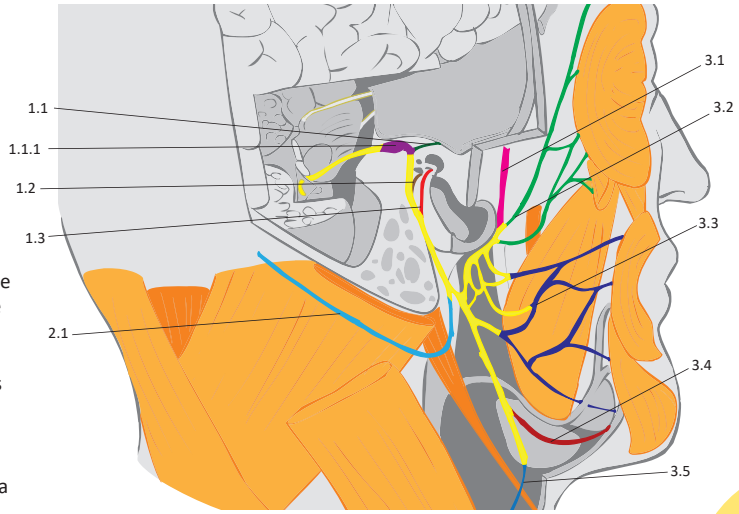

This copy belongs to ali yaghoubi

The vestibulocochlear nerve emerges from the **pons** at the **pontocerebellar angle**. It passes through the **internal acoustic meatus** and bifurcates into the cochlear nerve and the vestibular nerve. **The cochlear nerve** transmits sound information. It consists of axons of the bipolar neurons of the cochlear ganglion, whose cell bodies are located in the modiolus of the bony cochlear. Their dendrites receive signals from the spiral organ of Corti and their axons synapse in the **two cochlear nuclei** (anterior and posterior) in the brainstem. The **vestibular nerve** transmits information about balance, motion and acceleration. It is formed by axons of the **bipolar neurons of the vestibular ganglion** travelling through the internal acoustic meatus. Their dendrites receive information from the **saccule, utricule and semicircular ducts** and their axons synapse in the **four vestibular nuclei** (superior, inferior, medial and lateral) in the pons and in the cerebellum.

Nuclei

- 1 **Medial, lateral, superior, and inferior vestibular nuclei** (*nucleus vestibularis medialis, lateralis, superior et inferior*)
  – special sensory nuclei of the vestibular nerve
- 2 **Anterior and posterior cochlear nuclei** (*nucleus cochlearis anterior et posterior*)
  – special sensory nuclei of the cochlear nerve

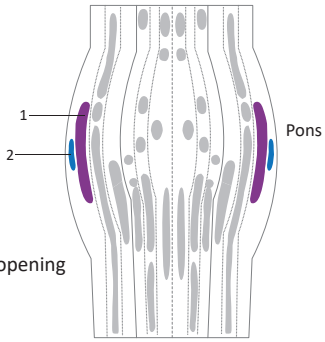

Course

1. leaves the pons at the pontocerebellar angle
2. runs in the posterior cranial fossa
3. enters the internal acoustic meatus via the internal acoustic opening
   – the cochlear nerve penetrates the anterior inferior quadrant (the cochlear area) of the fundus with the tractus spiralis foraminosus
   – the vestibular nerve penetrates the superior and inferior posterior quadrants (vestibular areas)

Fundus of the internal acoustic meatus

Anterior inferior quadrant

- 1 **Cochlear area** (*area cochlearis*) – cochlear nerve

Superior posterior quadrant

- 2 **Superior vestibular area** (*area vestibularis superior*)
  – utriculo-ampullary nerve (*nervus utriculoampullaris*) from the vestibular nerve (*nervus vestibularis*)

Inferior posterior quadrant

- 3 **Inferior vestibular area** (*area vestibularis inferior*)
  – saccular nerve (*nervus saccularis*) from the vestibular nerve (*nervus vestibularis*)
- 4 **Singular foramen** (*foramen singulare*)
  – posterior ampullary nerve (*nervus ampullaris posterior*)

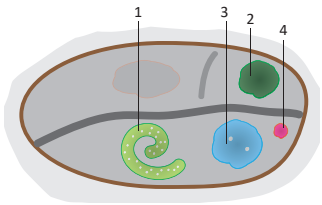

Scheme of the right internal acoustic meatus

Parts

- 1 **Vestibular nerve** (*nervus vestibularis*) – special sensory fibres
  – transmit information about position and motion
  1.1 **Vestibular ganglion** (*ganglion vestibulare*)
  – is located on the fundus of the internal acoustic meatus
- 2 **Cochlear nerve** (*nervus cochlearis*) – special sensory fibers
  – transmits auditory impulses from the cochlea
  2.1 **Cochlear ganglion** (*ganglion cochleare*)
  – is located in the modiolus of the bony cochlea

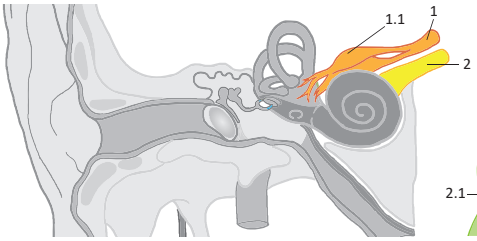

Frontal section of the external acoustic meatus

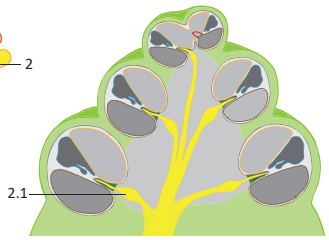

Vertical section of the bony cochlea

The vestibular nuclei are located in the vestibular area under the floor of the fourth ventricle.

The cochlear nuclei are situated under the acoustic tuberculum, which is located in the lateral corner of the fourth ventricle.

The spiral ganglion of Corti (*ganglion spirale*) is an obsolete term for the cochlear ganglion

The stato-acoustic nerve (*nervus statoacusticus*) is an obsolete for the vestibulocochelar nerve.

The tensor veli palatini is the only muscle of the soft palate innervated by the trigeminal nerve and not by the pharyngeal plexus.

Clinical notes

Unilateral lesions of the vestibulocochlear nerve cause hearing loss (hypacusis), tinnitus, vertigo, nystagmus (involuntary repetitive eye movements) and gait disorders (titubation).

Unilateral paresis of the glossopharyngeal nerve presents as dysphagia (difficulty of swallowing), impaired gag reflex, loss of sensitivity and mildly decreased taste perception (hypogeusis).

Glossopharyngeal neuralgia presents as episodic severe pain in the regions supplied by the glossopharygenal nerve (ear, root of tongue, nasopharynx and tonsils).

The glossopharyngeal nerve emerges from the medulla oblongata at the **retro-olivary groove** and leaves the cranial cavity via the **jugular foramen**. It **forms the lateral mixed system** with the vagus and accessory nerves. It contains **motor, sensory and special sensory fibres**. It innervates the muscles of the pharynx and soft palate, glands and mucosa of the pharynx, posterior third of the tongue, parotid gland and middle ear. It transmits taste impulses from the posterior third of the tongue and the vallate papillae.

Proper nuclei of the glossopharyngeal nerve

- 1 **Nucleus ambiguus** – a somatomotor nucleus
  - – innervates the stylopharyngeus
- 2 **Inferior salivatory nucleus** (*nucleus salivatorius inferior*)
  - – a parasympathetic visceromotor nucleus
  - – innervates the parotid and buccal glands and the glands of the auditory tube
  - – its fibers synapse in the otic ganglion and tympanic ganglion
- 3 **Nuclei of solitary tract** (*nuclei tractus solitarii*) – a viscerosensory nucleus
  - 3.1 **Gustatory nucleus** (*nucleus gustatorius*) – a special sensory nucleus
    - – the rostral part of the nuclei of the solitary tract
    - – transmits taste information from the posterior third of the tongue and vallate papillae

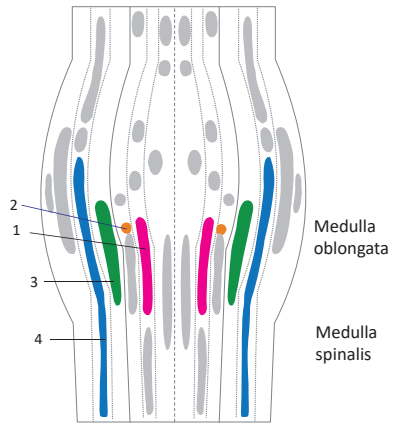

Nucleus of the trigeminal nerve, which receives somatosensory fibres from the glossopharyngeal nerve

- 4 **Spinal nucleus of trigeminal nerve** (*nucleus spinalis nervi trigemini*)
  - – a somatosensory nucleus
  - – receives somatosensory fibres from the glossopharyngeal nerve

Course

1. emerges from the medulla oblongata at the retro-olivary groove with the vagus and accessory nerves
2. leaves the cranial cavity via the jugular foramen
3. forms the superior ganglion above the jugular foramen and the inferior ganglion just below it
4. after leaving the skull, runs between the internal carotid artery and the internal jugular vein
5. joins the lateral side of the stylopharyngeus, which it innervates, and enters the pharyngeal wall, where it contributes to forming the pharyngeal plexus

Branches and structures innervated

- 1 **Tympanic nerve** (*nervus tympanicus*)
  - – emerges from the inferior ganglion and enters the tympanic cavity via the tympanic canaliculus
  - 1.1 **Lesser petrosal nerve** (*nervus petrosus minor*)
    - – a branch arising in the tympanic cavity carrying parasympathetic fibres
    - – passes through the canal, hiatus and groove for the lesser petrosal nerve
    - – penetrates the sphenopetrosal synchondrosis, (often via the petrosal foramen) to reach the infratemporal fossa
    - – synapses in the otic ganglion
    - – parasympathetic visceromotor innervation of the parotid and buccal glands
- 2 **Carotid branch** (*ramus sinus carotici*)
  - – descends to the carotid sinus and carotid body
  - – transfers viscerosensory information from baroreceptors and chemoreceptors
- 3 **Pharyngeal branches** (*rami pharyngei*)
  - – form the pharyngeal plexus, which provides motor and sensory innervation of the pharyngeal muscles, pharyngeal mucosa and muscles of the soft palate
- 4 **Stylopharyngeal branch** (*ramus stylopharyngeus*)
  - – innervates the stylopharyngeus
- 5 **Tonsillar branches** (*rami tonsillares*)
  - – sensory innervation of the palatine tonsil and the palatoglossal and palatopharyngeal arches
- 6 **Lingual branches** (*rami linguales*)
  - – carry sensory and taste information from the root of the tongue and the vallate papillae

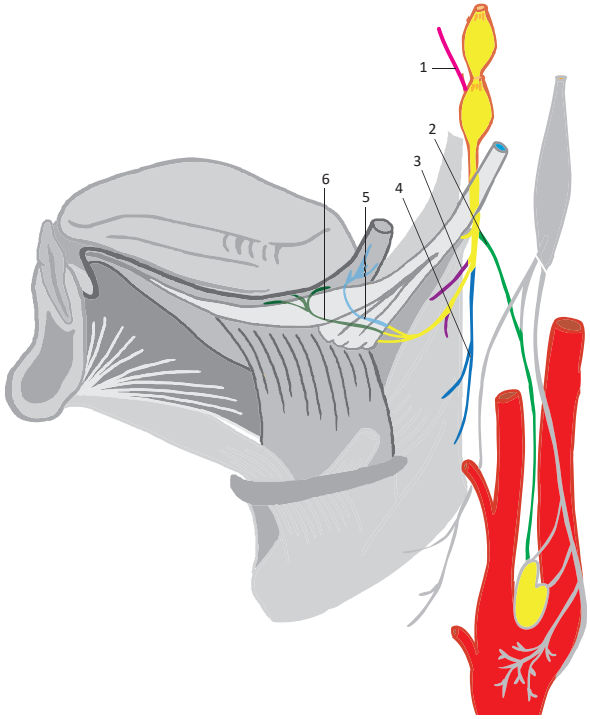

This copy belongs to ali yaghoubi

The vagus nerve originates in the **retro-olivary groove** of the medulla oblongata and leaves the cranial cavity via the **jugular foramen**. It **forms the lateral mixed system** with the glossopharyngeal and accessory nerves. It contains **motor, sensory and special sensory** (taste) fibres and is the only cranial nerve to reach the **abdominal cavity**. It gives numerous branches, which provide **parasympathetic and viscerosensory innervation** to the organs of the neck, thorax and abdomen, down to the Cannon-Böhm point at the left end of the transverse colon.

Nuclei

Proper nuclei of the vagus nerve

- 1 **Nucleus ambiguus** – a somatomotor nucleus
  - – innervates the muscles of the soft palate, pharynx and larynx
- 2 **Posterior nucleus of vagus nerve** (*nucleus posterior nervi vagi*)
  - – a parasympathetic visceromotor nucleus
  - – innervates the smooth muscle and glands of the internal organs
  - – innervates the myocardium and conducting system of the heart
- 3 **Nuclei of solitary tract** (*nuclei tractus solitarii*)
  - – a viscerosensory nucleus
  - – the axons synapse in the superior and inferior ganglia in the area of the jugular foramen
  - 3.1 **Gustatory nucleus** (*nucleus gustatorius*)
    - – a special sensory nucleus
    - – the rostral part of the nuclei of the solitary tract
    - – receives taste information from the epiglottis, epiglottic valleculae and part of the root of the tongue

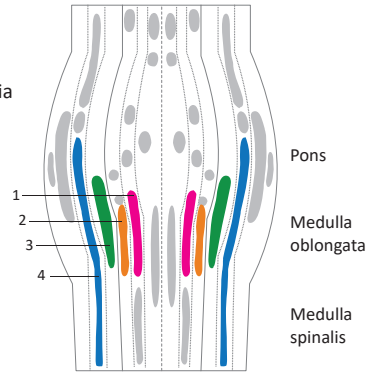

Nucleus of the trigeminal nerve, which receives somatosensory fibres from the vagus nerve

- 4 **Spinal nucleus of trigeminal nerve** (*nucleus spinalis nervi trigemini*) – a somatosensory nucleus
  - – receives sensory fibres from part of the auricle, external acoustic meatus, dura mater and mucosa of the larynx and pharynx

Course

1. leaves the medulla oblongata in the retro-olivary groove with the glossopharyngeal and accessory nerves
2. leaves the cranial cavity via the jugular foramen
3. its superior ganglion is located above the level of the jugular foramen and inferior ganglion below it
4. runs in the visceral space of the neck with the internal jugular vein and the internal carotid artery (caudally with the common carotid artery) within the carotid sheath
5. descends through the superior thoracic aperture, runs dorsally to the bronchi and caudally joins the oesophagus
   - – gives off the right recurrent laryngeal nerve, which passes under the right subclavian artery, and the left recurrent laryngeal nerve, which passes under the aortic arch
6. in the posterior mediastinum, the left vagus nerve moves so it becomes ventral to the oesophagus and the right vagus nerve moves so it becomes dorsal to the oesophagus
7. the left vagus forms the ventral trunk and the right vagus forms the dorsal trunk follows the oesophagus through the diaphragm via the oesophageal hiatus
8. parasympathetic branches in the abdominal cavity give rise to the autonomic plexuses
9. branches reach the individual organs together with vessels

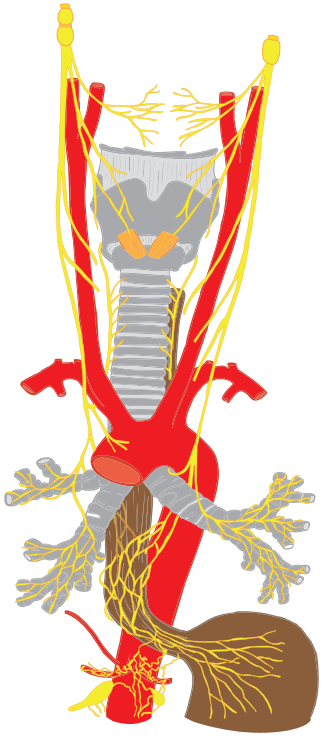

The anastomosis of Galen is a term for a connection between the internal branch of the superior laryngeal nerve and the recurrent laryngeal nerve.

The left vagus nerve travels ventrally and the right vagus nerve travels dorsally to the oesophagus. This is due to the rotation of the primitive gut of 90° clockwise during embryogenesis.

The vagus nerve innervates the pharyngeal muscles (except for the stylopharyngeus), muscles of the soft palate (except for the tensor veli palatini), laryngeal muscles and muscles of the upper half of the esophagus.

The function of the vagus nerve may be assessed by the following reflexes:
The pharyngeal (gag) reflex is triggered by touching the root of the tongue, pharyngeal wall or palatine arches. It evokes contraction of the pharyngeal muscles and causes nausea.
The oculocardial reflex (Aschner-Dagnini reflex) is induced by stimulating the vagus nerve by applying pressure on the eyeballs. This causes a decrease in pulse rate. The reflex can also be stimulated by pressing the carotid sinus or hitting the epigastrium (to irritate the coeliac plexus) or the testes.

The auricular branch of the vagus nerve (Arnold nerve) innervates a small area in the concha of the auricle and external acoustic meatus called the Ramsay Hunt zone.
The principal gastric branch of Latarjet (from the anterior gastric branch) supplies the lesser curvature of the stomach. Selective vagotomy used to be performed to treat peptic ulcer by surgically interrupting this nerve.

Clinical notes

Unilateral paresis of the vagus nerve causes dysphagia, hoarseness and divergence of the uvula.

Bilateral paresis of the vagus nerve causes rhinolalia, speech defects (dysarthria) and paresis of both vocal cords.

Irritation of the vagus nerve may cause bradycardia, smooth muscle spasms (laryngospasm, bronchospasm) and disturbances in gastrointestinal passage.

In pharmacoresistant depression or epilepsy, vagal nerve stimulation (VNS) is a therapeutic option.

Branches and structures innervated

1 **Meningeal branch** (*ramus meningeus*) – somatosensory innervation of the dura mater in the posterior cranial fossa
2 **Auricular branch** (*ramus auricularis*) – somatosensory innervation of the external acoustic meatus and concha of the auricle
3 **Pharyngeal branches** (*rami pharyngei*) – somatomotor and sensory innervation of the pharynx
3.1 **Pharyngeal plexus** (*plexus pharyngeus*) – a mixed plexus for the mucosa, glands and muscles of the pharynx
4 **Branch for carotid body** (*ramus glomi carotici*) – viscerosensory fibers entering the branches of the glossopharyngeal nerve for the carotid body and carotid sinus
– carries baroreceptor and chemoreceptor information
5 **Superior laryngeal nerve** (*nervus laryngeus superior*)
– a mixed branch originating from the inferior ganglion
5.1 **Internal branch** (*ramus internus*) – a sensory branch for the upper larynx, root of the tongue and epiglottis
– enters the larynx through the thyrohyoid membrane
5.2 **External branch** (*ramus externus*)
– a mixed branch, which travels with the superior thyroid artery and innervates the cricothyroid and certain pharyngeal muscles
– carries parasympathetic and viscerosensory branches for the thyroid and parathyroid glands
6 **Recurrent laryngeal nerve** (*nervus laryngeus recurrens*)
– innervates the majority of the laryngeal muscles and the laryngeal mucosa below the vocal cords
– on the right side, it passes under the right subclavian artery, on the left side under the aortic arch
– runs cranially between the trachea and oesophagus in the tracheo-oesophageal groove
6.1 **Tracheal branches** (*rami tracheales*)
– visceromotor and viscerosensory fibers for the tracheal mucosa
6.2 **Oesophageal branches** (*rami oesophagei*) – visceromotor and viscerosensory branches for the cervical part of the oesophagus
6.3 **Pharyngeal branches** (*rami pharyngei*) – visceromotor and viscerosensory branches for the pharyngeal mucosa
6.4 **Terminal branch / inferior laryngeal nerve** (*nervus laryngeus inferior*)
– innervates the laryngeal muscles (except for the cricothyroid) and laryngeal mucosa below the vocal folds
7 **Cardiac branches** (*rami cardiaci*)
– visceromotor and viscerosensory fibers for the heart
7.1 **Superior cervical, inferior cervical and thoracic cardiac branches** (*rami cardiaci cervicales superiores, cervicales inferiores et thoracici*)
– emerge from the vagus at different levels
7.2 **Cardiac plexus** (*plexus cardiacus*) – a mixed plexus for the heart
– contain the parasympathetic cardiac branches from the vagus nerve and sympathetic cardiac nerves from the sympathetic trunk
8 **Bronchial branches** (*rami bronchiales*) – viscerosensory and visceromotor branches for the mucosa, glands and smooth muscles of the bronchi
9 **Pulmonary branches** (*rami pulmonales*)
– viscerosensory and visceromotor fibres
– the continuation of the bronchial branches into the lungs
9.1 **Pulmonary plexus** (*plexus pulmonalis*) – a mixed plexus in the lungs consisting of both parasympathetic and sympathetic fibres
10 **Oesophageal plexus** (*plexus oesophageus*)
– visceromotor and viscerosensory fibres for the oesophageal mucosa, glands and muscles
11 **Anterior and posterior gastric branches** (*rami gastrici anteriores et posteriores*)
– visceromotor and viscerosensory fibers for the stomach
12 **Hepatic branches** (*rami hepatici*) – visceromotor and viscerosensory fibers for the liver
– run along the common hepatic artery and hepatic artery proper
13 **Renal branches** (*rami renales*) – viscerosensory and visceromotor branches for the kidneys, upper part of the urinary tract, adrenals and (partially) testes/ovaries
14 **Coelic branches** (*rami coeliaci*) – visceromotor and viscerosensory branches, which along with the sympathetic nerves form the coeliac plexus
– plexuses for the adrenals, kidneys, pancreas, ovaries, testes, small intestine, caecum, ascending colon and 2/3 of the transverse colon (to the Cannon–Böhm point, where they meet with the parasympathetic branches from the sacral plexus)
14.1 **Coeliac plexus** (*plexus coeliacus*) – a mixed plexus for the abdominal organs containing the parasympathetic and viscerosensory fibers from the n. X and sympathetic fibers from the splanchnic nerves

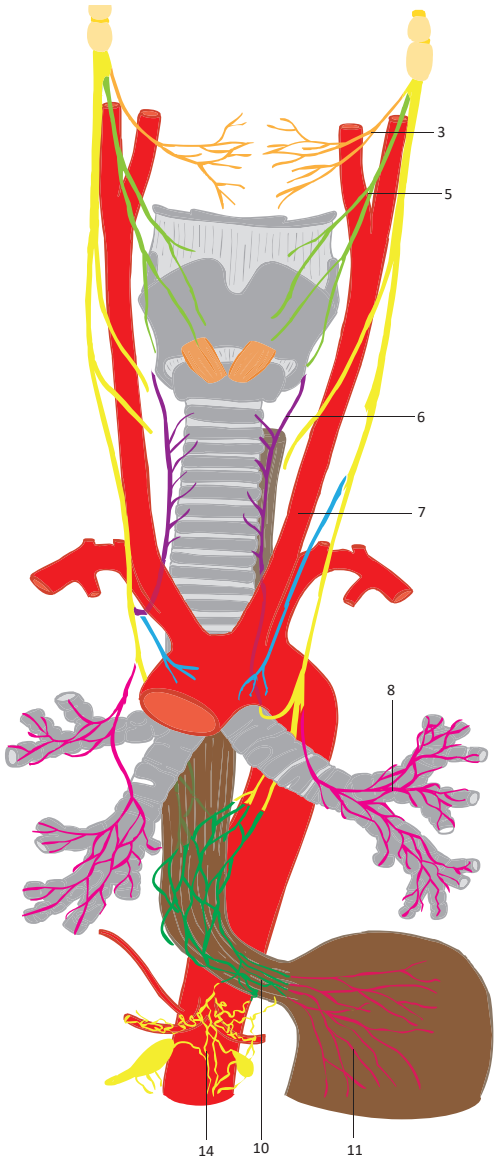

This copy belongs to ali yaghoubi

The accessory nerve emerges from the medulla oblongata at the **retro-olivary groove** and leaves the cranial cavity via the **jugular foramen**. It forms the **lateral mixed system** with the vagus and glossopharyngeal nerves. It contains **somatomotor fibres** that innervate the sternocleidomastoid and trapezius. The accessory nerve is the only cranial nerve, which has a **nucleus outside the brainstem** (in the cervical spinal cord). Its fibres merge inside the skull at the level of the foramen magnum to form the trunk of the accessory nerve.

- 1 **Accessory nerve**

Nuclei

- 2 **Nucleus ambiguus**
  - the cranial root (*radix cranialis*)
  - is located in the medulla oblongata
- 3 **Spinal nucleus of accessory nerve** (*nucleus spinalis nervi accessorii*)
  - spinal roots (*radix spinalis*) from spinal segments C1–C6
  - ascend laterally to the spinal cord and reach the posterior cranial fossa via the foramen magnum

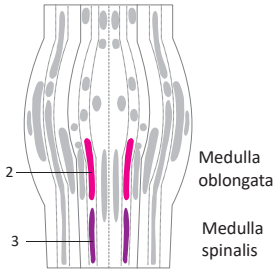

Course

1. leaves the cranial cavity via the jugular foramen
2. passes behind the internal jugular vein and the transverse process of the atlas
3. continues through the sternocleidomastoid towards the trapezius
4. runs within the trapezius parallel to the medial border of the scapula

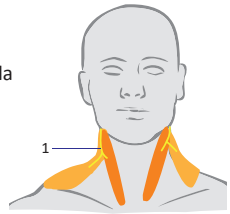

Branches and structures innervated

1 **Internal branch** (*ramus internus*) – joins the vagus nerve and participates in the innervation of the larynx

2 **External branch** (*ramus externus*)
– innervates the sternocleidomastoid and trapezius

The name of the accessory nerve originates from its older name *nervus accessorius ad vagum* (accessory to vagus), because some of its fibres join the vagus nerve.

The sternocleidomastoid and trapezius receive somatomotor fibers from the accessory nerve and spinal segments C2–C4. The spinal root of the accessory innervates muscles derived from somites and was secondarily encompassed into the cranial cavity and therefore separated from direct muscular branches.

The hypoglossal nerve does not participate in the innervation of the thyrohyoid. Fibres from the cervical plexus (C1) run with the hypoglossal to innervate the thyrohoid.

ANS is an abbreviation for the **A**utonomic **N**ervous **S**ystem.

The vegetative nervous system is an obsolete term for the ANS.

The sympathetic nervous system is called the thoraco-lumbar part of the ANS and the parasympathetic nervous system the cranio-sacral part of the ANS.

3.12 N. XII Hypoglossal nerve – Nervus hypoglossus

The hypoglossal nerve emerges from the medulla oblongata at the **pre-olivary groove** and leaves the cranial cavity via the **hypoglossal canal**. It forms an arch in its course in the neck. **Somatomotor fibres** from the cervical plexus (the superior root of the deep cervical ansa) join the nerve, but leave it after a short distance. The hypoglossal nerve innervates the **muscles of the tongue**.

- 1 **Hypoglossal nerve**

Nucleus

- 2 **Nucleus of hypoglossal nerve** (*nucleus nervi hypoglossi*) – a somatomotor nucleus

Course

1. leaves the cranial cavity via the hypoglossal canal
2. passes ventrally between the internal jugular vein and the internal carotid artery
3. forms an arch in the carotid triangle and continues into the submandibular triangle
4. enters the root of the tongue where it gives off its terminal branches

Proper branches and structures innervated

Lingual branches (*rami linguales*)
– innervate the muscles of the tongue, except for the palatoglossus (n. X)

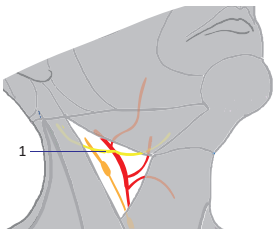

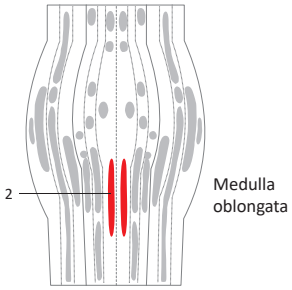

Clinical notes

The external branch of the accessory nerve can be easily harmed at the spine of the scapula. This can occur from falls on to the back. Lesions in this location impair the ascending part of the trapezius, which is then not able to rotate the scapula, preventing the arm from being abducted above the level of the shoulder. The anterior serratus has a synergistic function, but it is not able to perform this movement alone due to the excessive mass of the limb. The superior angle of the scapula protrudes outwards in what is called a winged scapula *(scapula alata)*.

Lesions of the nucleus of the hypoglossal nerve cause fine trembling of muscle fibres (fasciculation).

Unilateral paresis of the hypoglossal nerve cause deviation of the tongue to the side of the lesion (*hemiglossoplegia*) and atrophy of the muscles and mucosa of the tongue.

The autonomic nervous system (ANS) is a relatively independent part of the nervous system. It innervates smooth muscle in the internal organs, skin and vessels and regulates the activity of the heart and glands. The effector component of the ANS consists of preganglionic and postganglionic visceromotor fibres. Preganglionic fibres enter autonomic ganglia, where they branch extensively and form synapses with postganglionic neurons. The postganglionic fibres travel to the target organs. **The hypothalamus and reticular formation** are the highest centres of the ANS. The ANS is functionally **divided into the sympathetic part** (*pars sympathica)* **and the parasympathetic parts** *(pars parasympathica*)**. The enteric nervous system** is located within the wall of the gastrointestinal tract (myenteric and submucous plexus). It regulates the function of the gastrointestinal tract and is relatively independent from the rest of the ANS.

Centres and nuclei

1 **Central part of the ANS**
- 1.1 **Hypothalamus**
- 1.2 **Reticular formation** (*formatio reticularis*)
- 1.3 **Limbic system**

2 **Parasympathetic part**
- 2.1 **Nuclei of the brainstem** – parasympathetic nuclei of n. III, n. VII, n. IX and n. X
- 2.2 **Intermediolateral nuclei** (*nuclei intermediolaterales*) **S2–S4**
  – parasympathetic nuclei in the sacral segments of the spinal cord

3 **Sympathetic part**
- 3.1 **Intermediolateral nuclei** (*nuclei intermediolaterales*) **C8–L3**
  – sympathetic nuclei in the thoracic and lumbar segments of the spinal cord

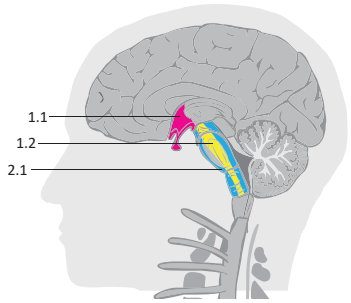

Nerves, ganglia, plexuses

1 **Parasympathetic part**
– purely parasympathetic ganglia are only found in the head
– ganglia are situated closely to the innervated organs
- 1.1 **Oculomotor nerve** (*nervus oculomotorius*)
  - 1.1.1 **Ciliary ganglion** (*ganglion ciliare*)
- 1.2 **Facial nerve** (*nervus facialis*)
  - 1.2.1 **Pterygopalatine ganglion** (*ganglion pterygopalatinum*)
  - 1.2.2 **Submandibular ganglion** (*ganglion submandibulare*)
- 1.3 **Glossopharyngeal nerve** (*nervus glossopharyngeus*)
  - 1.3.1 **Otic ganglion** (*ganglion oticum*)
- 1.4 **Vagus nerve** (*nervus vagus*) – forms ganglia within the walls of organs
- 1.5 **Sacral splanchnic nerves** (*nervi splanchnici sacrales*)

2 **Sympathetic part**
– purely sympathetic paravertebral ganglia are located in the sympathetic trunk
- 2.1 **Sympathetic trunk** (*truncus sympathicus*)
  – consists of the paravertebral ganglia interconnected by interganglional branches (*rami interganglionares*)

3 **Mixed plexuses**
– are composed of both sympathetic and parasympathetic fibres
- 3.1 **Cardiac plexus** (*plexus cardiacus*)
- 3.2 **Pulmonary plexus** (*plexus pulmonalis*)
- 3.3 **Oesophageal plexus** (*plexus oesophageus*)
- 3.4 **Abdominal aortic plexus** (*plexus aorticus abdominalis*)
  - 3.4.1 **Coeliac plexus** (*plexus coeliacus*)
    – contains the paired coeliac ganglion (*ganglion coeliacum*)
  - 3.4.2 **Renal and suprarenal plexuses** (*plexus renalis et suprarenalis*)
    – contain the paired aorticoorenal ganglion (*ganglion aorticorenale*)
  - 3.4.3 **Testicular and ovarian plexus** (*plexus testicularis et ovaricus*)
  - 3.4.4 **Ureteric plexus** (*plexus uretericus*)
  - 3.4.5 **Superior mesenteric plexus** (*plexus mesentericus superior*)
    – contains the unpaired superior mesenteric ganglion (*ganglion mesentericum superius*)
  - 3.4.6 **Inferior mesenteric plexus** (*plexus mesentericus inferior*)
    – contains the unpaired inferior mesenteric ganglion (*ganglion mesentericum inferius*)
- 3.5 **Superior hypogastric plexus** (*plexus hypogastricus superior*)
- 3.6 **Inferior hypogastric plexus** (*plexus hypogastricus inferior*)

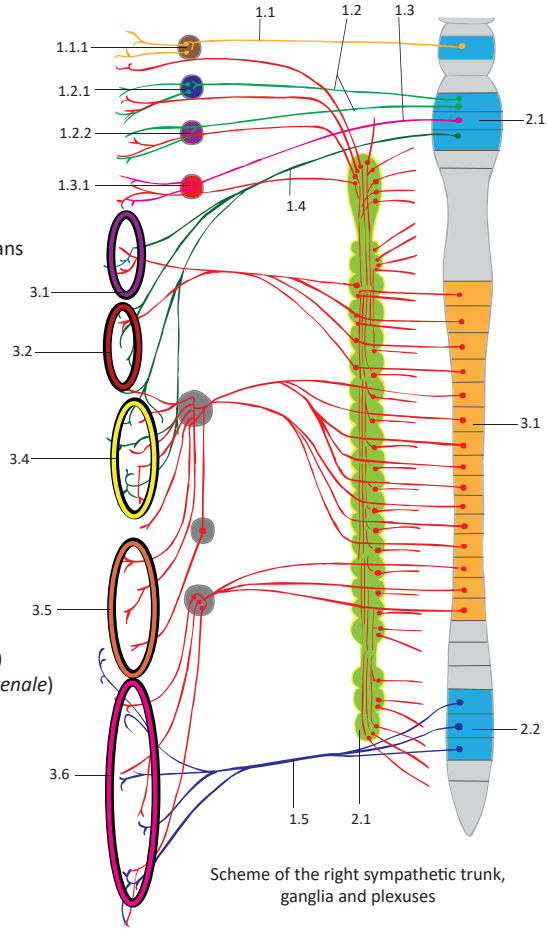

Scheme of the right sympathetic trunk, ganglia and plexuses

This copy belongs to ali yaghoubi

The sympathetic nervous system consists of both central and peripheral parts. The central part consists of the **intermediolateral nuclei** in the grey mater of spinal cord segments C8-L3. **The paried sympathetic trunks** make up the peripheral part. They lie lateral to the vertebral bodies and extend all the way from the base of the skull to the coccyx. They penetrate the diaphragm as they pass from the thorax to the abdomen, and then lie in the retroperitoneal space. The sympathetic trunks consist of a series of ganglia, interconnected by interganglionic branches. The sympathetic nervous system **increases energy expenditure and catabolism. It increases heart rate and myocardial contractility, dilates bronchi, increases blood pressure and indirectly increases blood glucose and lipid levels.**

Connection of fibres in the sympathetic nervous system

1 **Preganglionic fibers**
– neurones of the intermediolateral nuclei (C8–L3)
- 1.1 **White rami communicantes** (*rami communicantes albi*)
  – heavily myelinated axons of neurones from the intermediolateral nucleus
  – enter the ganglia of the sympathetic trunk
  – the preganglionic fibres enter ganglia from the level of the cervicothoracic ganglion (*ganglion cervicothoracicum*) to the lumbar ganglion (*ganglion lumbale*) L3
- 1.2 **Interganglionic branches** (*rami interganglionares*)
  – preganglionic fibers reach the more remote ganglia via interganglionic branches

2 **Postganglionic fibers**
- 2.1 **Grey rami communicantes** (*rami communicantes grisei*)
  – emerge from all ganglia of the sympathetic trunk
  – join the spinal nerves and innervate cutaneous glands and smooth muscle in the skin (the erector pili muscles)
- 2.2 **Vascular branches** (*rami vasculares*)
  – travel with arteries
  – form plexuses in the adventitia
  – provide sympathetic innervation of the organs and limbs
- 2.3 **Visceral branches, splanchnic nerves** (*rami viscerales, nervi splanchnici*)
  – travel towards the organs

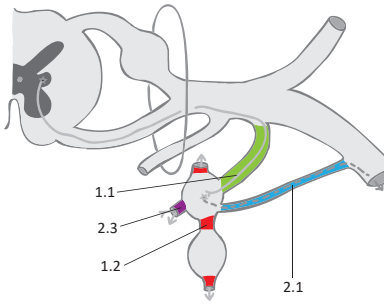

Sympathetic trunk

1 **Cervical ganglia** (*ganglia cervicalia*) – 3 pairs
– are located lateral to the cervical vertebral column, within the prevertebral layer of the cervical fascia
- 1.1 **Superior cervical ganglion** (*ganglion cervicale superius*)
- 1.2 **Middle cervical ganglion** (*ganglion cervicale medium*)
- 1.3 **Inferior cervical ganglion** (*ganglion cervicale inferius*)
  - 1.3.1 **Cervicothoracic, stellate, ganglion** (*ganglion cervicothoracicum, stellatum*)
    – is formed by fusion of the inferior cervical ganglion with first thoracic ganglion (*ganglion thoracicum primum*)
    – is present in the majority of cases

- 2 **Thoracic ganglia** (*ganglia thoracica*) – 10–11 pairs
  – are located lateral to the thoracic vertebral column
- 3 **Lumbar ganglia** (*ganglia lumbalia*) – 4–5 pairs
  – are located lateral to the lumbar vertebral column
- 4 **Sacral ganglia** (*ganglia sacralia*) – 4 pairs
  – are located on the pelvic surface of the sacrum, medial to the anterior sacral foramina (*foramina sacralia anteriora*)
- 5 **Ganglion impar** – the caudal ganglion
  – is unpaired
  – is located in front of the coccyx
  – connects the left and right sympathetic trunks

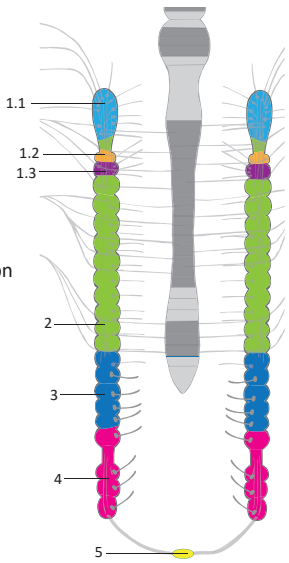

Scheme of the right and left sympathetic trunks

The part of the internal carotid plexus within the carotid sinus is sometimes called the cavernous plexus (*plexus cavernosus*).

The subclavian ansa (*ansa subclavia*) is a connection between the middle cervical ganglion and cervicothoracic ganglion, which forms a loop around the subclavian artery.

The splanchnic nerves (*nervi splanchnici*) consist mainly of preganglionic fibres, which synapse in either the prevertebral or intramural ganglia.

The sacral ansa (*ansa sacralis*) is the terminal part of both sympathetic trunks. It connects the 4th sacral ganglia with the ganglion impar.

Clinical notes

Impairment of the sympathetic internal carotid plexus (*plexus caroticus internus*) may be caused by dissection of the internal carotid artery (usually traumatic or postoperative separation of the intima from the media) or by damage to the cervicothoracic ganglion (by tumors in the apex of the lungs). The clinical manifestation is called **Claude Bernard-Horner syndrome.** It presents as ptosis (drooping of the upper eyelid), miosis (constricted pupil), enophthalmos (posterior displacement of the eyeball) and anhidrosis in the face (absence of sweating).

Cervical ganglia

1 **Superior cervical ganglion** (*ganglion cervicale superius*)
– is located on the surface of the longus capitis at the level of C2–C4
– its preganglionic fibers originate from spinal segments C8–T1
Postganglionic fibers:
1.1 **Grey rami communicates** (*rami communicantes grisei*) – join the first 4 cervical nerves
1.2 **Jugular nerve** (*nervus jugularis*) – travels towards the jugular foramen
– connects the inferior ganglion of the glossopharyngeal nerve with the inferior ganglion of the vagus nerve
– functionally it is a grey ramus communicans composed of postganglionic fibers
1.3 **Internal carotid nerve** (*nervus caroticus internus*) – forms the internal carotid plexus (*plexus caroticus internus*) within the adventitia of the carotid artery, travels the cavernous sinus and then splits along the branches of the internal carotid artery
1.3.1 **Caroticotympanic nerves** (*nervi caroticotympanici*) – pass through the caroticotympanic canaliculi into the tympanic cavity
1.3.2 **Deep petrosal nerve** (*nervus petrosus profundus*) – carries sympathetic fibers into the pterygopalatine ganglion
– enters the base of the skull at the sphenopetrosal synchondrosis
– fuses with the greater petrosal nerve to form the nerve of the pterygoid canal, then travels to the pterygopalatine fossa
1.3.3 **Sympathetic root of ciliary ganglion** (*radix sympathica ganglii ciliaris*)
– arises from the ophthalmic plexus (*plexus ophthalmicus*)
– passes through the ciliary ganglion without synapsing and forms the short ciliary nerves
– synapse with unmyelinated postganglionic fibers takes place in the superior cervical ganglion
1.3.4 **Orbital branches** (*rami orbitales*) – from the ophthalmic plexus
– innervates superior and inferior tarsal muscle and orbitalis
1.4 **External carotid nerves** (*nervi carotici externi*)
– approach the external carotid artery, form the external carotid plexus (*plexus caroticus externus*) within adventitia of the external carotid artery and then continues downward to the common carotid artery
1.4.1 **Sympathetic root of submandibular ganglion** (*radix sympathica ganglii submandibularis*)
– arises from the plexus of the facial artery (*plexus arteriae facialis*)
1.4.2 **Sympathetic root of otic ganglion** (*radix sympathica ganglii otici*)
– arises from the plexus of the middle meningeal artery (*plexus arteriae meningeae mediae*)
1.4.3 **Branches for carotid body** (*rami glomi carotici*)
1.5 **Laryngopharyngeal branches** (*rami laryngopharyngei*)
– join the pharyngeal branches from the glossopharyngeal and vagus nerves and form the pharyngeal plexus
1.6 **Superior cervical cardiac nerve** (*nervus cardiacus cervicalis superior*)
– on the left, it runs behind the common carotid artery, on the right it, runs behind the brachiocephalic trunk
– enters the mediastinum and terminates in the cardiac plexus (*plexus cardiacus*)

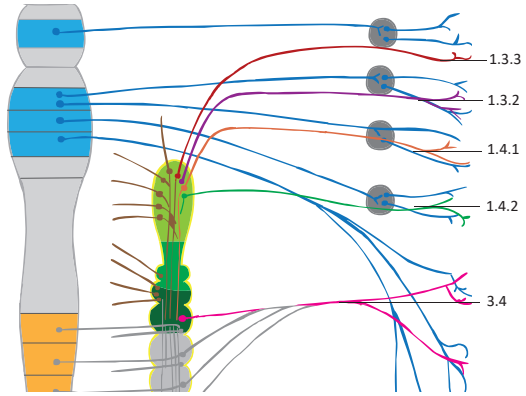

Scheme of the left sympathetic trunk, ganglia and plexuses

2 **Middle cervical ganglion** (*ganglion cervicale medium*) – is located on the surface of the longus colli at the level of C6
– in this area, the sympathetic trunk splits into several bundles that surround and form a loop around the subclavian artery
– the preganglionic fibres are derived from spinal segments C8–T1
Postganglionic fibers:
2.1 **Grey rami communicantes** (*rami communicantes grisei*) – join the 5th and 6th cervical nerves
2.2 **Vascular branches** (*rami vasculares*) – head towards the common carotid artery,
– form the common carotid plexus (*plexus caroticus communis*)
2.3 **Visceral branches** (*rami viscerales*) – innervate the thyroid gland and parathyroid glands
2.4 **Middle cervical cardiac nerve** (*nervus cardiacus cervicalis medius*)
– terminates in the cardiac plexus with the superior cervical cardiac nerve

3 **Inferior cervical ganglion** (*ganglion cervicale inferius*) – in the majority of cases, merges with the 1st thoracic ganglion forming the cervicothoracic/stellate ganglion (*ganglion cervicothoracicum/stellatum*)
– is located anterior to the transverse process (*processus transversus*) of C7 and posterior to the vertebral artery
– its preganglionic fibers originate from spinal segments C8–T1
Postganglionic fibers:
3.1 **Grey rami communicantes** (*rami communicantes grisei*) – join the 6th and 7th cervical nerves and the 1st thoracic nerve
3.2 **Vascular branches** (*rami vasculares*) – travel towards the subclavian artery and form the subclavian plexus for the upper limb
3.3 **Visceral branches** (*rami viscerales*) – innervate the thyroid gland and parathyroid glands
3.4 **Inferior cervical cardiac nerve** (*nervus cardiacus cervicalis inferior*) – terminates in the cardiac plexus
3.5 **Vertebral nerve** (*nervus vertebralis*) – travels towards the vertebral artery and forms a plexus around it

This copy belongs to ali yaghoubi

Thoracic ganglia

– 10–11 ganglia
– the trunk passes through the lumbar part of the diaphragm
– the preganglionic fibres originate from the thoracic spinal segments
– the white rami communicantes emerge from the intercostal nerves

Postganglionic fibers:

1 **Grey rami communicantes** (*rami communicantes grisei*)
– join the intercostal nerves

2 **Vascular branches** (*rami vasculares*)
– follow the individual branches of the thoracic aorta

3 **Thoracic cardiac nerves** (*nervi cardiaci thoracici*)
– arise from from the 2nd – 4th thoracic ganglia
– terminate in the cardiac plexus (*plexus cardiacus*)

4 **Pulmonary branches** (*rami pulmonales*)
– arise from the 2nd – 5th thoracic ganglia
– form the pulmonary plexus (*plexus pulmonalis*) with parasympathetic fibres from the vagus nerve

5 **Oesophageal branches** (*rami oesophagei*)
– form the oesophageal plexus (*plexus oesophageus*) with parasympathetic branches from the left and right vagus nerves

6 **Greater splanchnic nerve** (*nervus splanchnicus major*)
– arises from the 5th (6th) – 9th thoracic ganglia
– enters the abdominal cavity through the lumbar part of the diaphragm (through the innominate foramen)
– terminates in the coeliac plexus (*plexus coeliacus*)

7 **Lesser splanchnic nerve** (*nervus splanchnicus minor*)
– originates from the 10th and 11th thoracic ganglia
– enters the abdomen through the lumbar part of the diaphragm
– terminates in the coeliac, renal and adrenal plexuses (*plexus coeliacus, plexus renalis et suprarenalis*)

8 **Least splanchnic nerve** (*nervus splanchnicus imus*)
– arises from the 12th thoracic ganglion
– terminates in the renal and adrenal plexus (*plexus renalis et suprarenalis*)

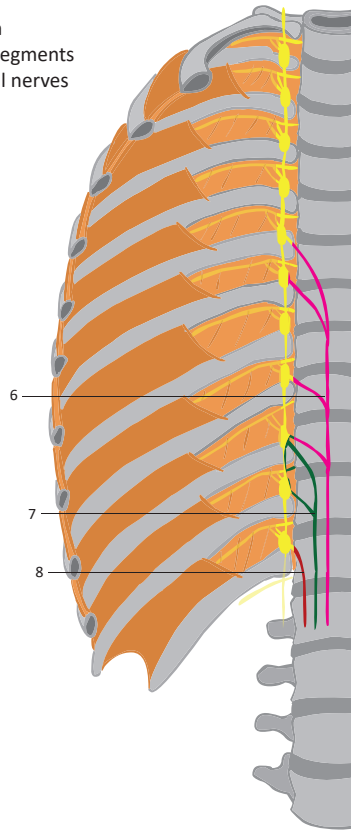

Right sympathetic trunk and its splanchnic nerves

Abdominal ganglia

– 4–5 ganglia in the lumbar region and 4–5 ganglia in the sacral region
– the preganglionic fibers originate from spinal segments L1–L3
– the right sympathetic trunk (*truncus sympathicus dexter*) lies medially to the psoas major and posteriorly to the inferior vena cava
– the left sympathetic trunk (*truncus sympathicus sinister*) lies medially to the psoas major and laterally to the abdominal aorta
– both trunks enter the lesser pelvis, travel caudally and merge together at the ganglion impar

Postganglionic fibers:

1 **Grey rami communicantes** (*rami communicantes grisei*)
– join the lumbar and sacral spinal nerves

2 **Lumbar splanchnic nerves** (*nervi splanchnici lumbales*)
– terminate in the abdominal aortic plexus and the plexuses around the branches of the abdominal aorta

3 **Sacral splanchnic nerves** (*nervi splanchnici sacrales*)
– terminate in the inferior hypogastric plexus

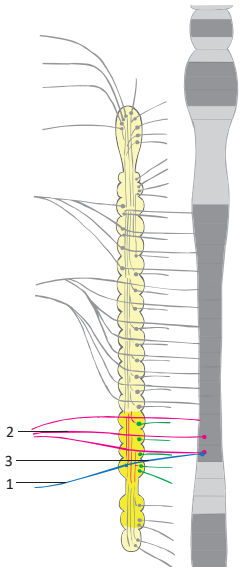

Scheme of the abdominal and splanchnic nerves

The anastomosis of Jacobson is formed by the tympanic nerve, tympanic plexus and minor petrosal nerve. It contains autonomous fibres for the otic ganglion.

The Cannon-Böhm point corresponds to a developmental border between the midgut (innervated by the vagus nerve) and hindgut (innervated by the sacral splanchnic nerves).

The parasympathetic nervous system is **divided into a cranial part** (*pars cranialis*) **and a sacral part** (*pars sacralis*). The cranial part consists of the cranial nerves that carry parasympathetic fibres and their associated ganglia**.** The border between parasympathetic innervation from the cranial and sacral parts lies at the left colic flexure and is called the **Cannon-Böhm point**. The **sacral part consists of the 2nd to 4th sacral nerves**. The preganglionic fibres originate in the intermediolateral nucleus of the spinal segments **S2–S4** and travel as the **sacral splanchnic nerves** to the **inferior hypogastric plexus**. They synapse with neurones in ganglia within the plexus or pass through the plexus to synapse with neurones in the walls of the target organs. The sacral part innervates the large intestines aboral to the left colic flexure, the urinary bladder, erectile bodies and the internal genital organs (except for the gonads). The parasympathetic nervous system is **responsible for activities associated with restoring energy stores and anabolic reactions. It slows down the heart rate, constricts bronchi, increases intestinal peristalsis and gland secretion and contracts of the detrusor muscle.**

Cranial part

- 1.1 **Oculomotor nerve** (*nervus oculomotorius*)
  - innervates the ciliary body and sphincter pupillae
  - 1.1.1 **Ciliary ganglion** (*ganglion ciliare*) – is located in the orbit
- 1.2 **Facial nerve** (*nervus facialis*)
  - 1.2.1 **Submandibular ganglion** (*ganglion submandibulare*)
    - is located in the submandibular triangle
    - innervates the submandibular, sublingual and lingual glands
    - fibres from the chorda tympani reach the submandibular ganglion via the lingual nerve
  - 1.2.2 **Pterygopalatine ganglion** (*ganglion pterygopalatinum*)
    - is located in the pterygopalatine fossa
    - innervates the lacrimal, palatine, nasal and nasopharyngeal glands
- 1.3 **Glossopharyngeal nerve** (*nervus glossopharyngeus*)
  - innervates the parotid gland
  - preganglionic fibres reach the otic ganglion (*ganglion oticum*) via the tympanic nerve, tympanic plexus (*plexus tympanicus*) and lesser petrosal nerve
  - the postganglionic fibres travel to the parotid gland via the auriculotemporal nerve and to the buccal glands via the buccal nerve
  - 1.3.1 **Otic ganglion** (*ganglion oticum*)
    - is located in the infratemporal fossa
- 1.4 **Vagus nerve** (*nervus vagus*)
  - innervates of smooth muscle, glands, internal organs and myocardium

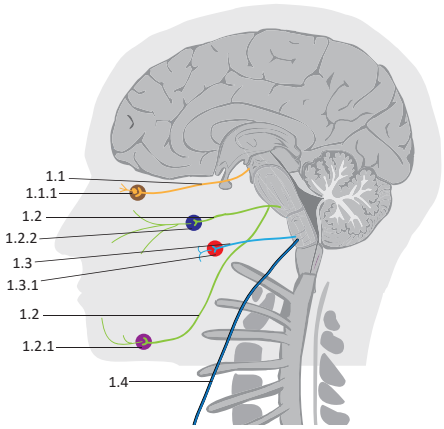

Scheme of the cranial parasympathetic system

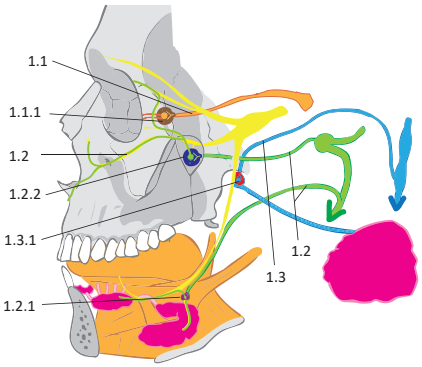

Scheme of the cranial parasympathetic system and secretory innervation of the salivary glands

Sacral part

Intermediolateral nucleus (*nucleus intermediolateralis*) S2–S4
– sacral parasympathetic nuclei in the lateral horns of the spinal cord
Sacral splanchnic nerves (*nervi splanchnici sacrales*)
– preganglionic fibers
– parasympathetic fibres into the inferior hypogastric plexus (*plexus hypogastricus inferior*)
– preganglionic fibres enter the mixed pelvic plexuses around the organs of the lesser pelvis and synapse with postganglionic fibres in the purely parasympathetic ganglia

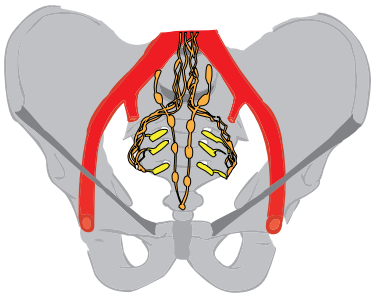

Scheme of the sacral parasympathetic system

This copy belongs to ali yaghoubi

The mixed plexuses of the thorax are the **cardiac plexus** (*plexus cardiacus*), **pulmonary plexus** (*plexus pulmonalis*), and **thoracic aortic plexus** (*plexus aorticus thoracicus*). The thoracic aortic plexus passes along the aorta through the aortic hiatus of the diaphragm into the retroperitoneal space, where it follows the branches of the aorta to reach the abdominal organs.

Thorax

- 1 **Cardiac plexus** (*plexus cardiacus*)
  - – spreads around the aortic arch and
  - – is subdivided according its relation to the aortic arch
  - – **Superficial cardiac plexus** (*plexus cardiacus superficialis*)
    - – lies between the aortic arch and the pulmonary trunk
  - – **Deep cardiac plexus** (*plexus cardiacus profundus*)
    - – lies between the aortic arch and the trachea
  - 1.1 **Sympathetic fibres**
    - – increas heart rate, conduction speed, contractility and excitability
    - 1.1.1 **Superior cervical cardiac nerve** (*nervus cardiacus cervicalis superior*)
    - 1.1.2 **Middle cervical cardiac nerve** (*nervus cardiacus cervicalis medius*)
    - 1.1.3 **Inferior cervical cardiac nerve** (*nervus cardiacus cervicalis inferior*)
    - 1.1.4 **Thoracic cardiac nerves** (*nervi cardiaci thoracici*)
  - 1.2 **Parasympathetic fibres**
    - – decreas heart rate, conduction speed, contractility and excitability
    - 1.2.1 **Superior cardiac branch** (*ramus cardiacus superior*)
    - 1.2.2 **Inferior cardiac branch** (*ramus cardiacus inferior*)
    - 1.2.3 **Thoracic cardiac branches** (*rami cardiaci thoracici*)
- 2 **Pulmonary plexus** (*plexus pulmonalis*) – a mixed plexus supplying the lungs
  - 2.1 **Sympathetic fibres**
    - – dilate bronchial smooth muscle, widening the bronchial lumen
    - – inhibit secretion of mucosal glands
    - 2.1.1 **Thoracic pulmonary branches** (*rami pulmonales thoracici*)
  - 2.2 **Parasympathetic fibers**
    - 2.2.1 **Bronchial branches** (*rami bronchiales*)
      - – increase tension of bronchial smooth muscle, narrowing the bronchial lumen
      - – stimulate secretion of mucosal glands
- 3 **Oesophageal plexus** (*plexus oesophageus*)

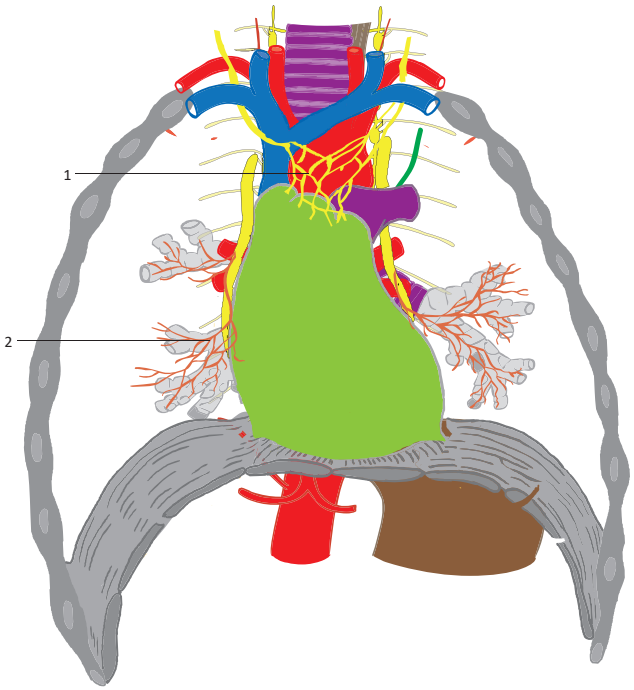

Difference in nomenclature:
– **nerves (*nervi*)** are formed by **sympathetic** fibres
– **branches (*rami*)** are formed by **parasympathetic** fibres

Accelerating nerves (*nervi accelerantes*) is an obsolete name for the sympathetic cardiac nerves, which accelerate heart rate. Retarding nerves (*nervi retardantes*) in an obsolete name for the parasympathetic cardiac branches, which slow the heart rate.

The cardiac plexus continues along the left and right coronary arteries as the left and right coronary plexuses and participates in adjusting the diameter of their lumen. It reaches the conducting system of the heart along the branches of the coronary arteries, where it regulates heart rate. Sympathetic fibres dilate the coronary arteries increasing perfusion of the heart. An increase in sympathetic activation results in tachycardia, higher contraction force, and a higher demand for oxygen and nutrients. Parasympathetic fibres constrict the coronary arteries. Increased parasympathetic activity causes bradycardia and lowers the metabolic demands of the myocardium.

The pulmonary sympathetic fibres dilate the bronchi. This occurs in response to increased oxygen demand. The dilated bronchi increase respiratory gas exchange. The work needed for active inspiration is indirectly decreased by bronchodilation.

The activity of smooth muscle, myocardium, and gland secretion is controlled by signal molecules and hormones. Epinephrine (adrenaline) causes tachycardia and increases heart contraction force. Nitric oxide (NO) causes vasodilation. Angiotensin II is the most potent vasoconstrictor and serotonin potentiates intestinal peristalsis.

Clinical notes

Renal denervation is an intravascular procedure that uses radiofrequency pulses to ablate the sympathetic fibres of the renal plexus. It is performed by entering a catheter into the femoral and passing it up the renal artery. It is used to treat intractable hypertension.

Abdomen

- 1 **Aortic abdominal plexus** (*plexus aorticus abdominalis*)
  - – surrounds the abdominal aorta
  - – splits into two iliac plexuses at the aortic bifurcation
  - – ramifies into several smaller plexuses, which innervate individual organs
  - 1.1 **Sympathetic fibres**
    - – come from the sympathetic trunk (*truncus sympathicus*)
    - 1.1.1 **Greater splanchnic nerve** (*nervus splanchnicus major*)
    - 1.1.2 **Lesser splanchnic nerve** (*nervus splanchnicus minor*)
    - 1.1.3 **Least splanchnic nerve** (*nervus splanchnicus imus*)
    - 1.1.4 **Lumbar splanchnic nerves** (*nervi splanchnici lumbales*)
  - 1.2 **Parasympathetic fibres**
    - – come from the vagus nerve (*nervus vagus*)
    - 1.2.1 **Coeliac branches** (*rami coeliaci*)
    - 1.2.2 **Gastric branches** (*rami gastrici*)
    - 1.2.3 **Hepatic branches** (*rami hepatici*)
    - 1.2.4 **Renal branches** (*rami renales*)

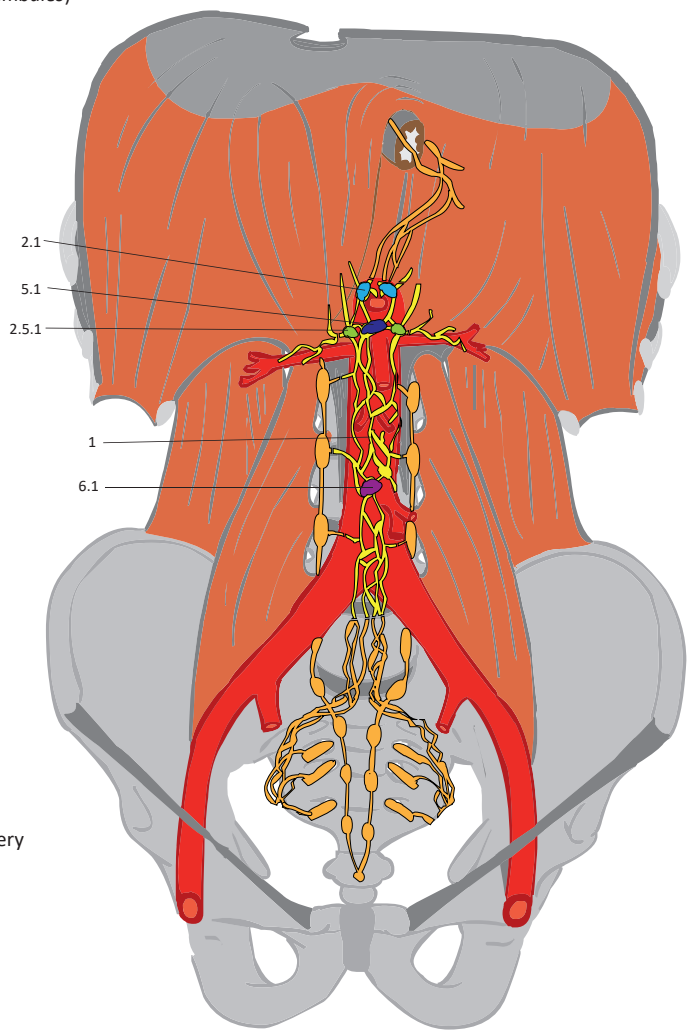

Subplexuses of the abdominal aortic plexus

2 **Coeliac plexus** (*plexus coeliacus*)
- – is located around the coeliac trunk (*truncus coeliacus*)
- 2.1 **Right and left coeliac ganglia** (*ganglion coeliacum dextrum et sinistrum*)
  - – are located on both sides of the coeliac trunk
  - – follow the branches of the coeliac trunk

Subplexuses:
- 2.2 **Hepatic plexus** (*plexus hepaticus*)
- 2.3 **Gastric plexus** (*plexus gastricus*)
- 2.4 **Splenic plexus** (*plexus splenicus*)
- 2.4 **Pancreatic plexus** (*plexus pancreaticus*)
- 2.5 **Renal and suprarenal plexuses** (*plexus renalis et suprarenalis*)
  - – paired plexuses
  - – innervate the kidneys and adrenal glands
  - 2.5.1 **Aorticorenal ganglion** (*ganglion aorticorenale*)
    - – a paired ganglion located at the origin of the renal artery

3 **Testicular/ovarian plexus** (*plexus testicularis/ovaricus*)
- – innervates the gonads
- – follows the gonadal vessels to the testes/ovaries

4 **Ureteric plexus** (*plexus uretericus*) – innervates the ureters

5 **Superior mesenteric plexus** (*plexus mesentericus superior*)
- – is located at the point where the superior mesenteric artery emerges from the aorta
- – participates in the innervation of the intestines from the major duodenal papilla to the left colic flexure
- 5.1 **Superior mesenteric ganglion** (*ganglion mesentericum superius*)
  - – an unpaired ganglion
  - – is located at the point where the superior mesenteric artery emerges from the aorta

6 **Inferior mesenteric plexus** (*plexus mesentericus inferior*)
- – is located at the level of the inferior mesenteric artery
- – parasympathetic fibres come from the sacral part of the parasympathetic nervous system
- – innervates the descending colon, sigmoid colon and rectal ampulla
- 6.1 **Inferior mesenteric ganglion** (*ganglion mesentericum inferius*)
  - – unpaired ganglion
  - – there may be multiple inferior mesenteric ganglia
  - – located at the origin of the inferior mesenteric artery

This copy belongs to ali yaghoubi

Pelvis

- 1 **Superior hypogastric plexus / presacral nerve** (*plexus hypogastricus superior / nervus presacralis*)
  - the continuation of the abdominal aortic plexus (*plexus aorticus abdominalis*)
  - splits into the right and left hypogastric nerves (*nervus hypogastricus dexter et sinister*) at the sacral promontory
    - 1.1 **Lumbar and sacral splanchnic nerves (L4, L5 and S1)** (*nervi splanchnici lumbales et sacrales*)
    - 1.2 **Aortic abdominal plexus** (*plexus aorticus abdominalis*)
- 2 **Inferior hypogastric plexus / pelvic plexus** (*plexus hypogastricus inferior / plexus pelvicus*)
  - a mixed plexus forming a continuation of the hypogastric nerves
  - passes laterally to the rectum into the lesser pelvis
  - the parasympathetic fibres come from the white communicating branches of S2–4 via the sacral splanchnic nerves
  - parasympathetic fibres synapse in ganglia close to the pelvic organs
  - branches into smaller plexuses which innervate the individual organs of the lesser pelvis and follow the branches of the internal iliac artery
  - 2.1 **Rectal plexus** (*plexus rectalis*) – innervates the rectum
  - 2.2 **Vesical and ureteric plexus** (*plexus vesicalis et uretericus*)
    - innervates the urinary bladder and the pelvic part of the ureter
  - 2.3 **Prostatic plexus** (*plexus prostaticus*)
    - innervates the smooth muscle of the prostate, prostatic part of urethra, prostatic and urethral glands and seminal glands
  - 2.4 **Deferential plexus** (*plexus deferentialis*) – innervates the ductus deferens
  - 2.5 **Uterovaginal plexus** (*plexus uterovaginalis*) – innervates the ovaries, uterus and vagina
  - 2.6 **Cavernous nerves of clitoris/penis** (*nervi cavernosi clitoridis/penis*)
    - innervates the cavernous bodies of the penis and clitoris

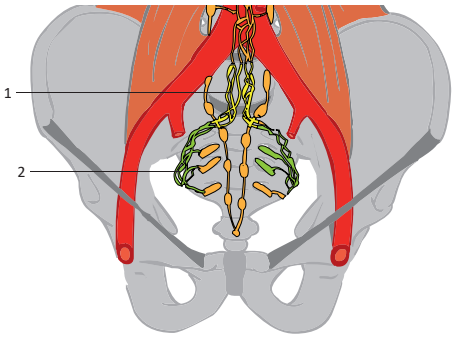

4.4 Enteric nervous system

The enteric nervous system is a separate part of the ANS. It is located in the **wall of the digestive tract**. It **controls gastrointestinal functions** more or less independently from the rest of the ANS.

- 1 **Submucous plexus / Meissner's plexus** (*plexus submucosus*)
  - an autonomic plexus in the submucosa of the digestive tract
  - plays an important role in the regulation of secretion of substances into the intestinal lumen and blood supply of the intestinal wall
  - operates predominantly on a local level
- 2 **Myenteric plexus / Auerbach's plexus** (*plexus myentericus*)
  - a plexus in the smooth muscle of the digestive tract
  - controls and coordinates of peristalsis
  - operates on larger segments of the digestive tract

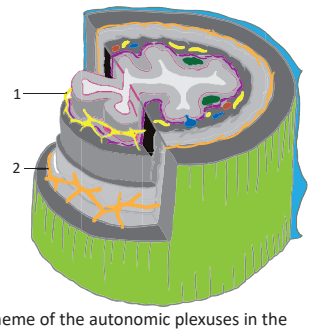

Scheme of the autonomic plexuses in the digestive tube (submucous and myenteric plexus)

Clinical notes

Hirschsprung disease (congenital megacolon / intestinal aganglionosis) is a congenital absence of the ganglia of the enteric nervous system in the aboral part of the colon. It leads to permament contraction of the aganglionic segment causing accumulation of stool above the contracted segment dilating the colon.

Cajal cells are found in the digestive tract. They are believed to be the pacemaker cells of intestinal peristalsis. GIST tumors (gastrointestinal stromal tumors) arise from these cells.

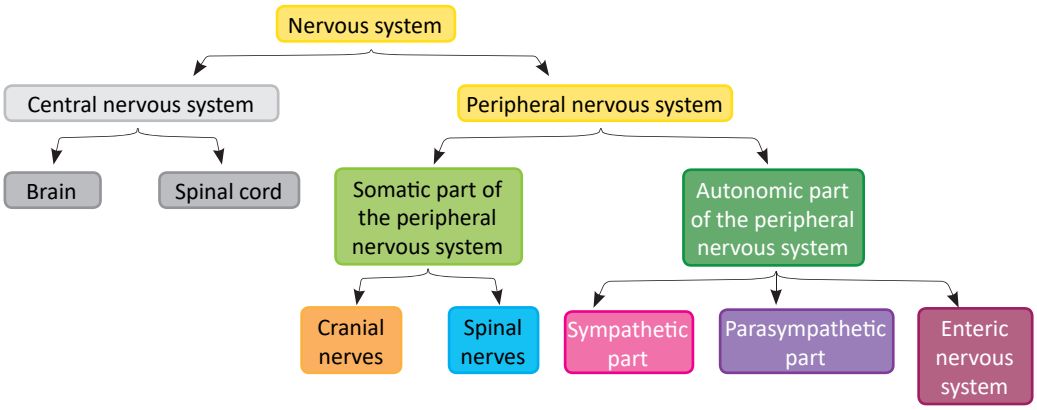

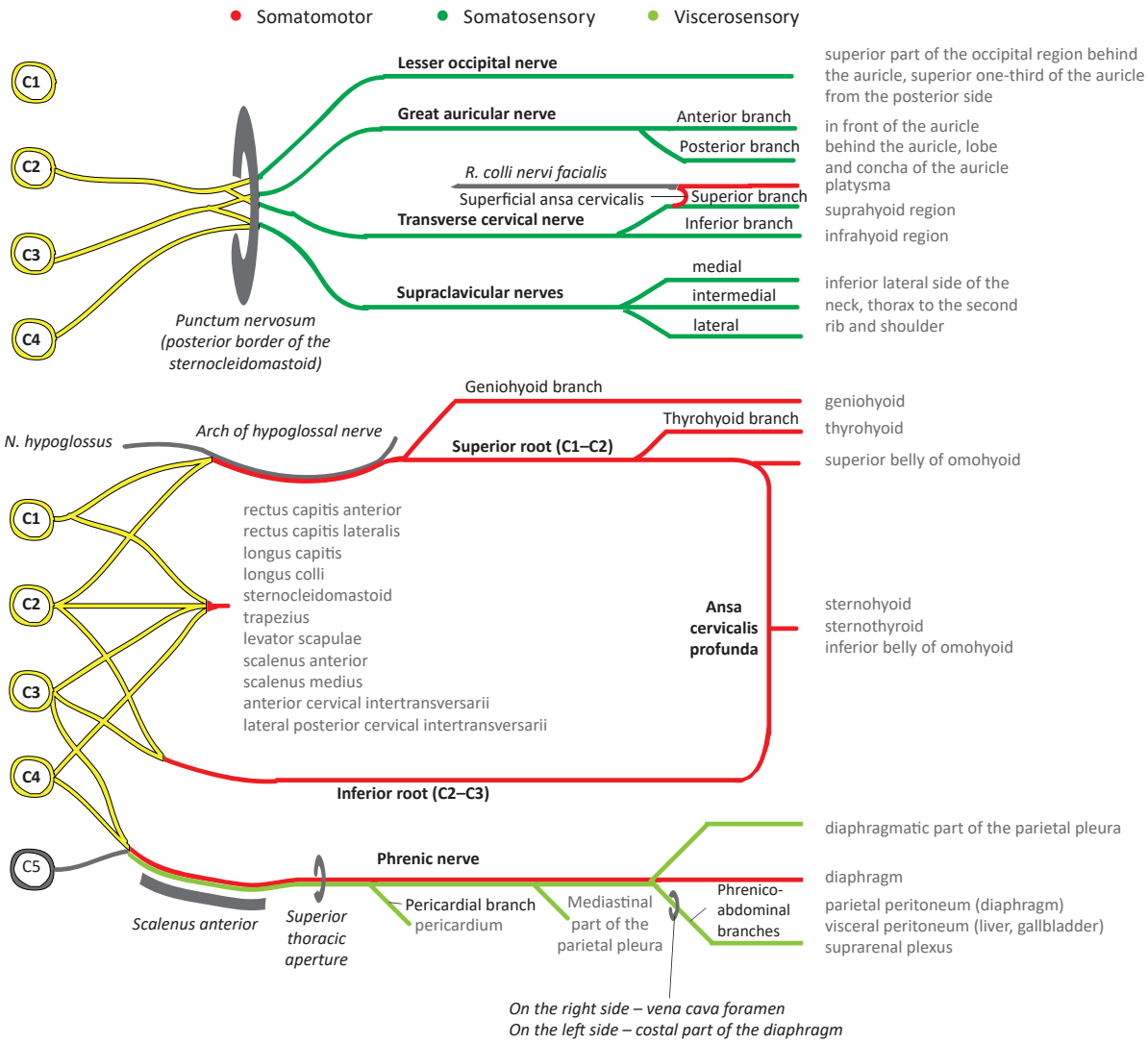

This copy belongs to ali yaghoubi

Brachial plexus

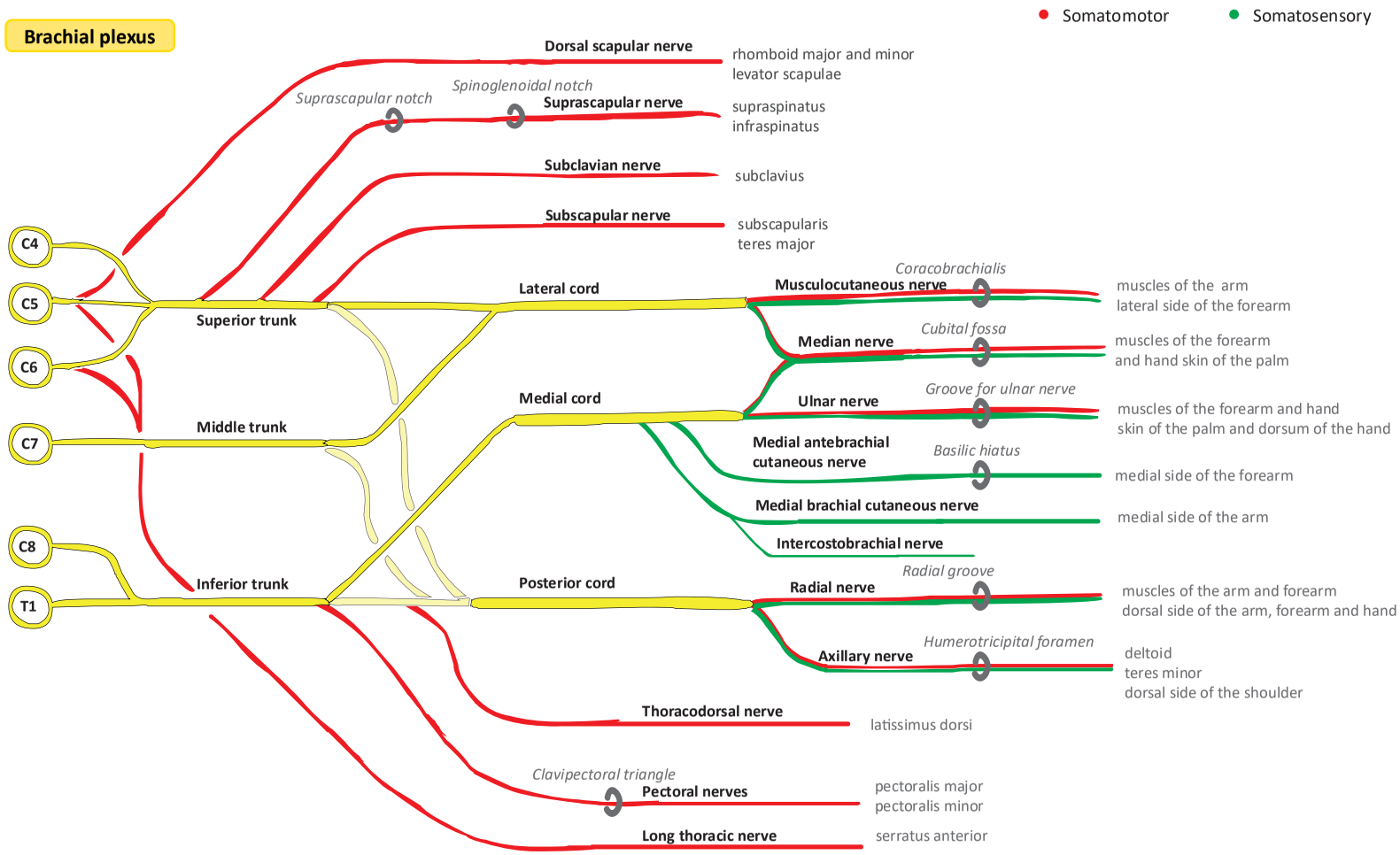

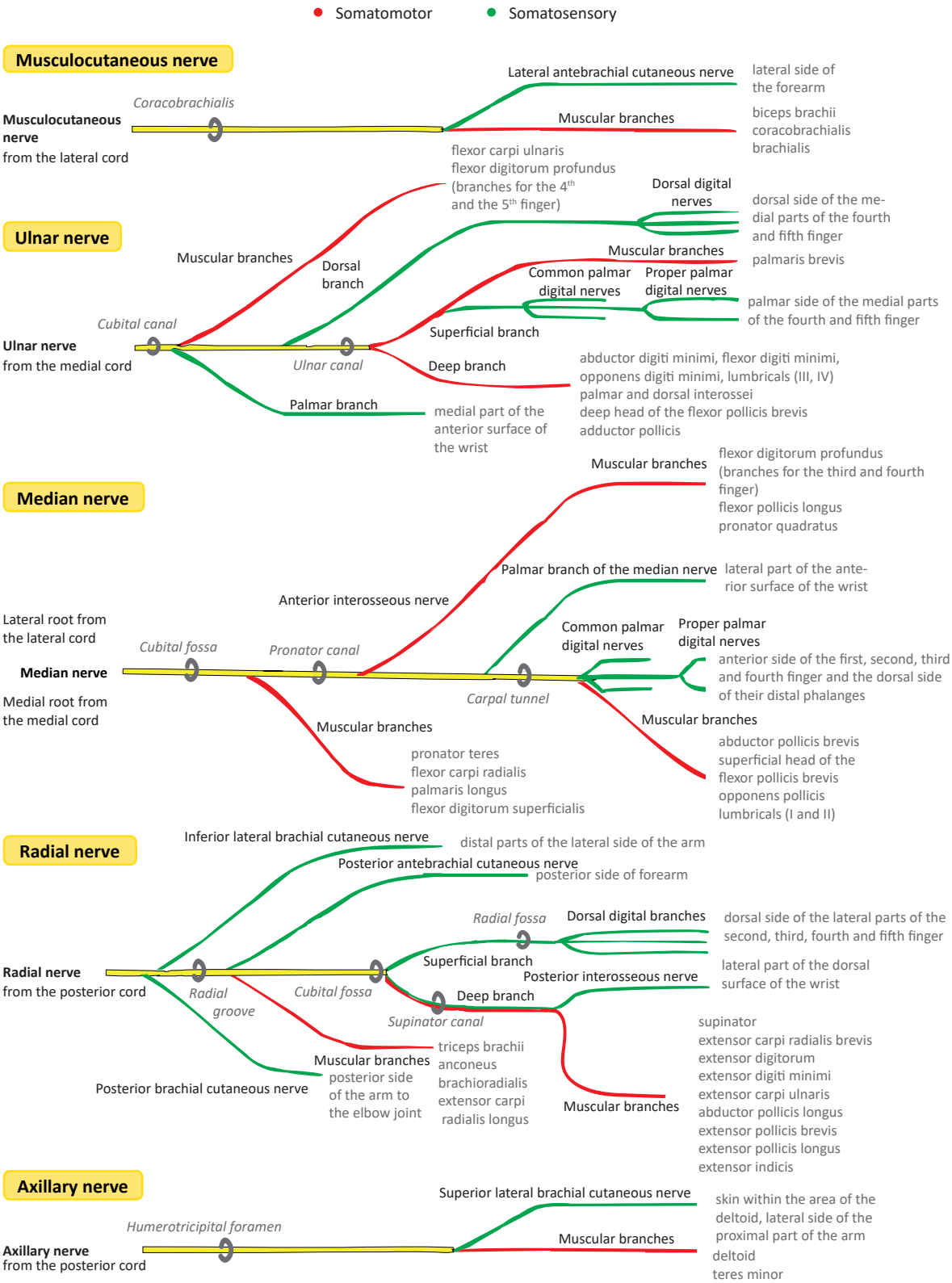

This copy belongs to ali yaghoubi

Somatomotor Somatosensory

Lumbar plexus

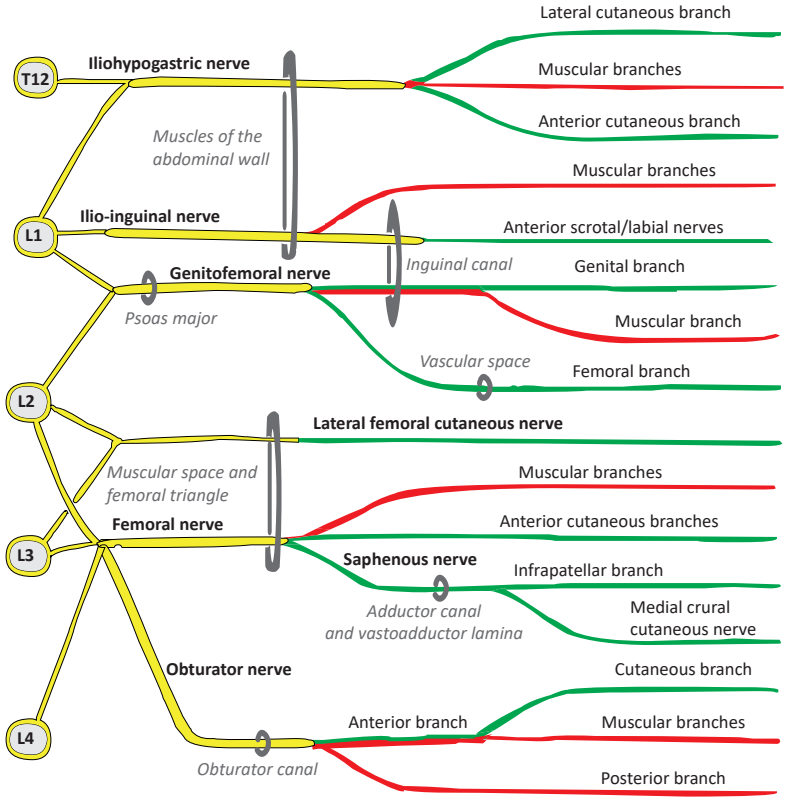

Sacral plexus

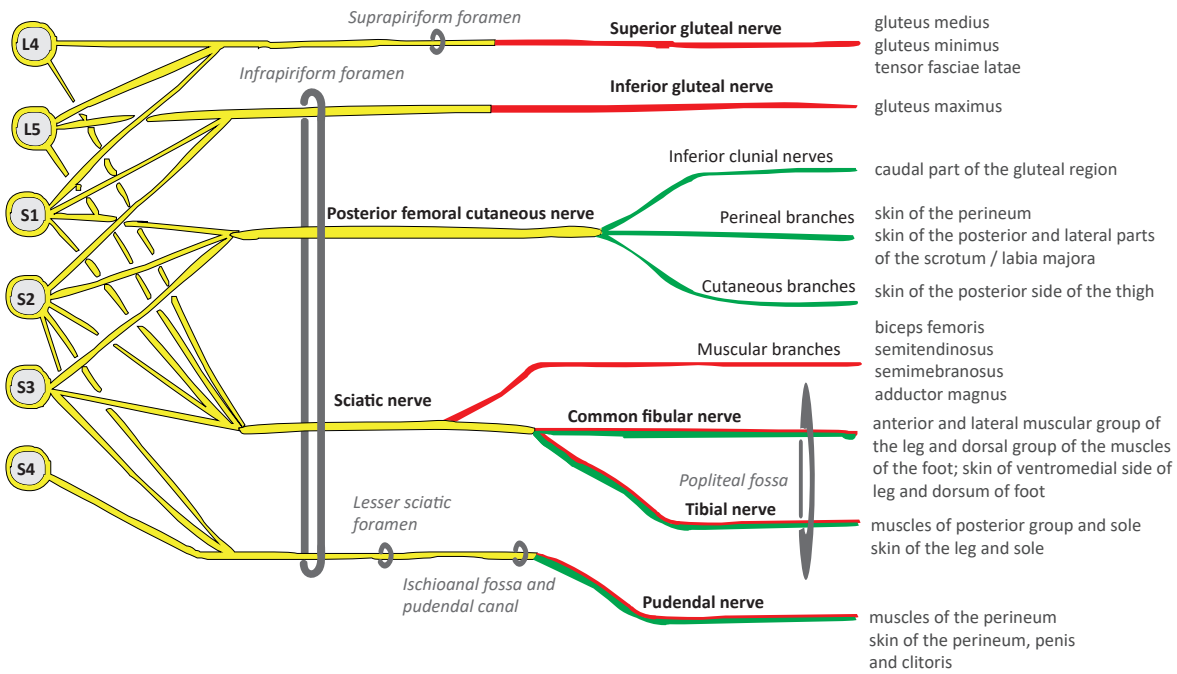

Tibial nerve, common fibular nerve

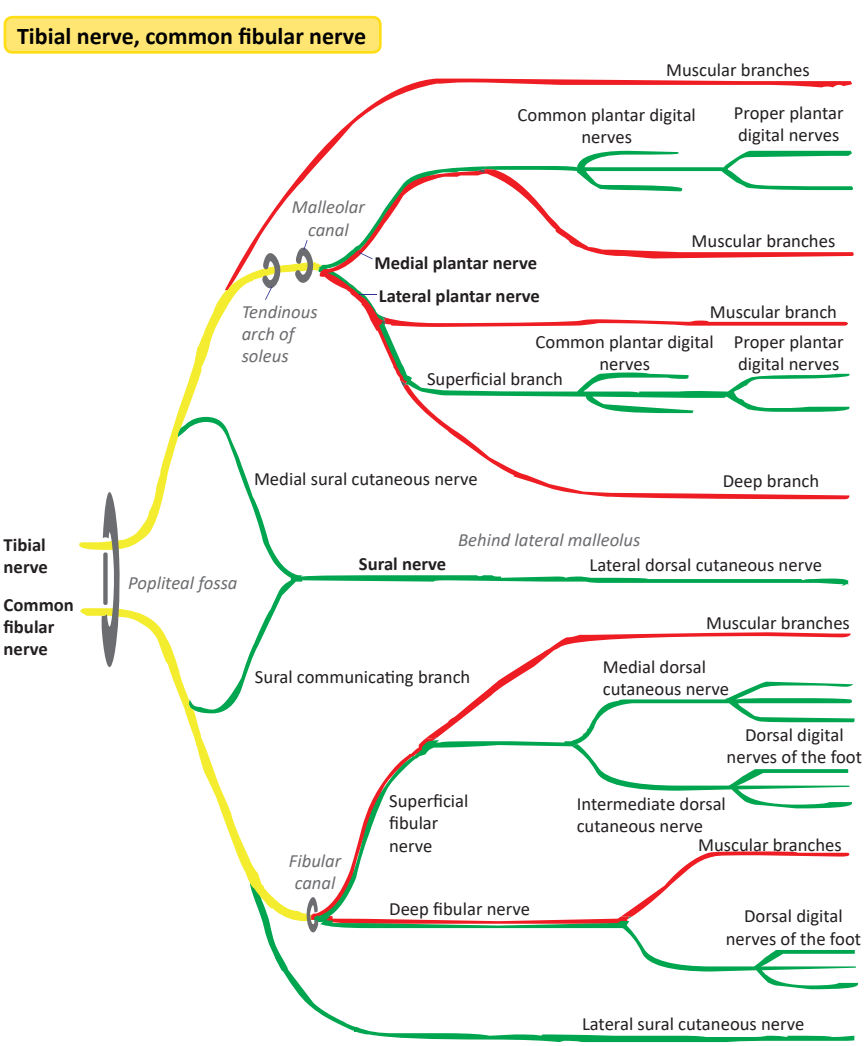

triceps surae
plantaris
popliteus
tibialis posterior
flexor digitorum longus
flexor hallucis longus

skin of the plantar surface of the medial parts from the first to the fourth finger

abductor hallucis
flexor hallucis brevis
flexor digitorum brevis
lumbricals (I and II)

quadratus plantae

skin of the plantar surface of the lateral parts of the fourth and fifth finger

flexor digiti minimi brevis
abductor digiti minimi, adductor hallucis
lumbricals (III and IV), interossei

skin of the posterior surface of the leg, lateral surface of the malleolus and margin of the foot including the lateral margin of the fifth finger

fibularis longus et brevis

skin of the dorsum of the foot, medial margin of toe and adjacent margin of the second and third finger

skin of the dorsum of the foot, adjacent margin of the third, fourth and fifth finger

tibialis anterior
extensor digitorum longus
extensor digitorum brevis
extensor hallucis longus
extensor hallucis brevis

skin of the adjacent margin of the first and second finger

skin of the lateral surface of the calf

Pudendal nerve

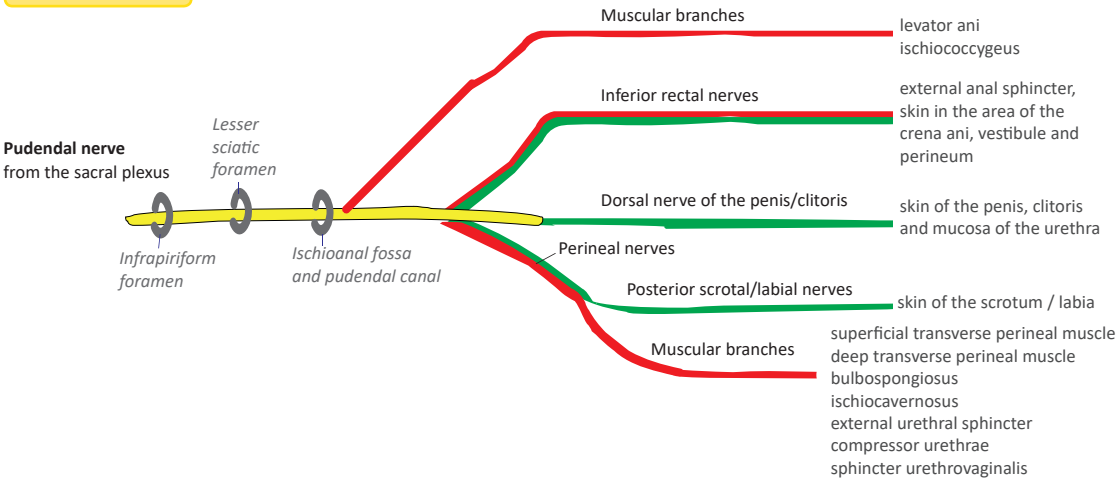

levator ani
ischiococcygeus

external anal sphincter,
skin in the area of the crena ani, vestibule and perineum

skin of the penis, clitoris and mucosa of the urethra

skin of the scrotum / labia

superficial transverse perineal muscle
deep transverse perineal muscle
bulbospongiosus
ischiocavernosus
external urethral sphincter
compressor urethrae
sphincter urethrovaginalis

This copy belongs to ali yaghoubi

Somatomotor Parasympathetic part Sensory

Olfactory nerve



Optic nerve

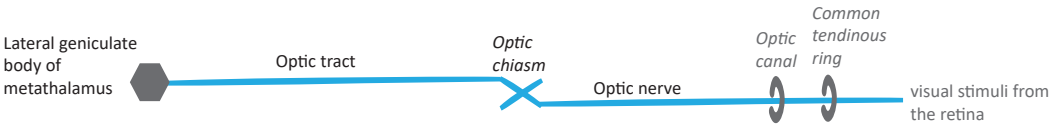

Oculomotor nerve

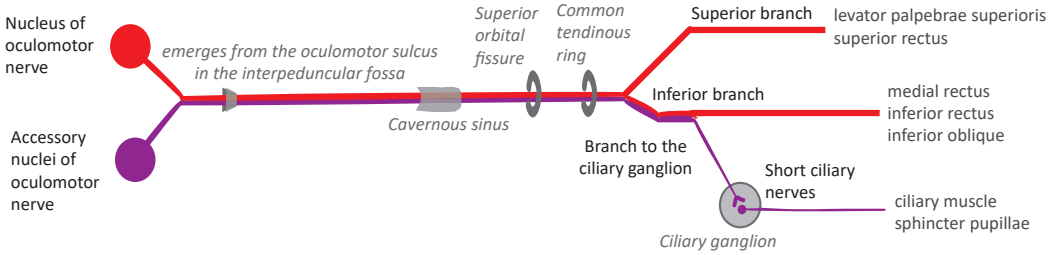

Trochlear nerve

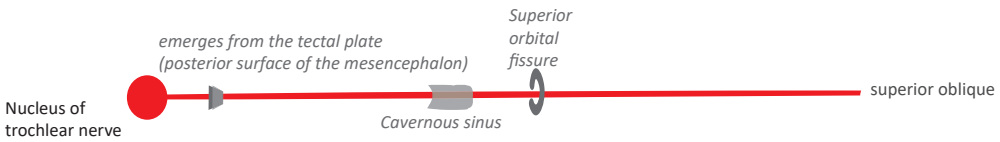

Abducens nerve

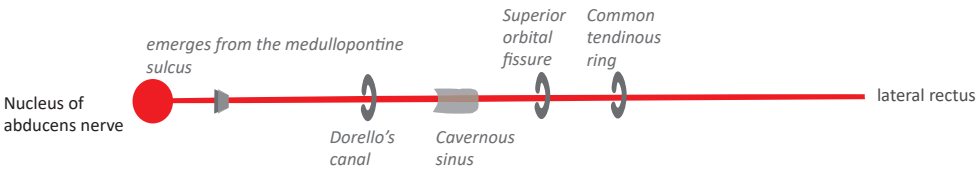

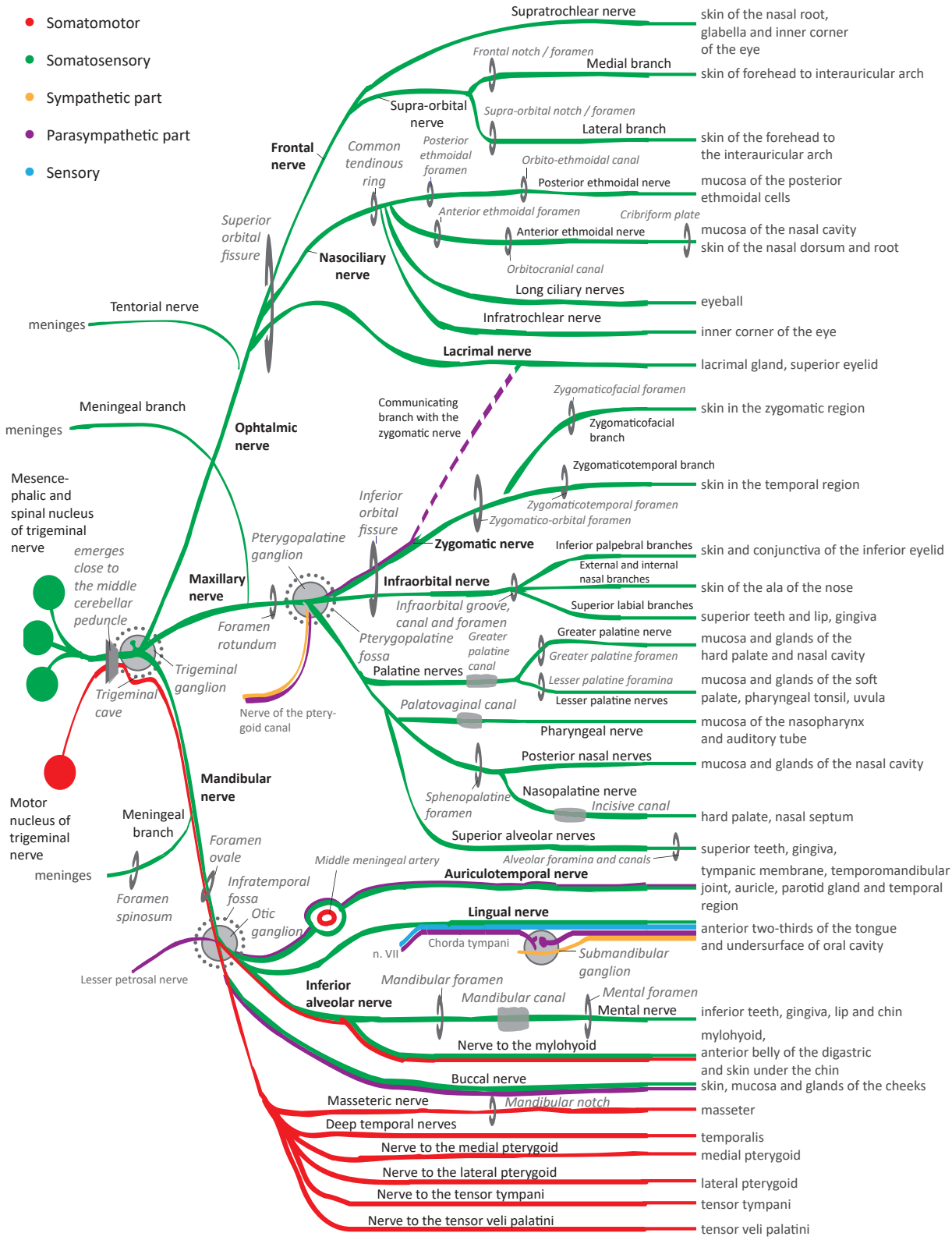

This copy belongs to ali yaghoubi

Facial nerve

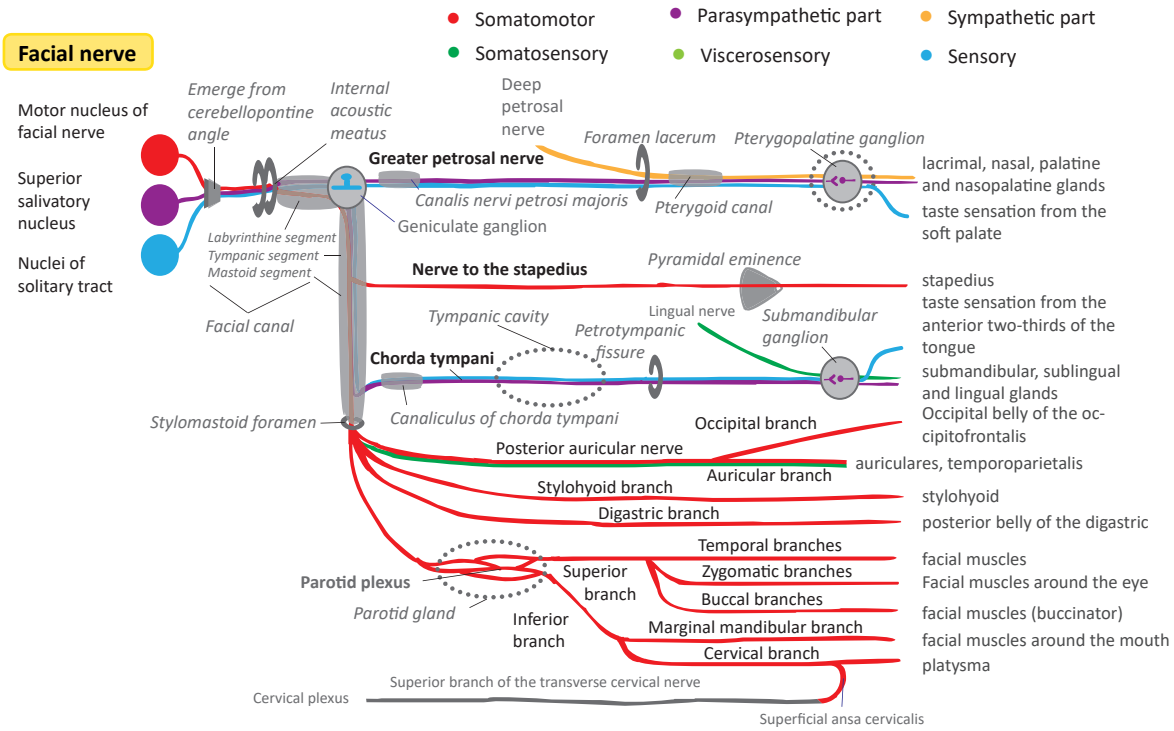

Vestibulocochlear nerve

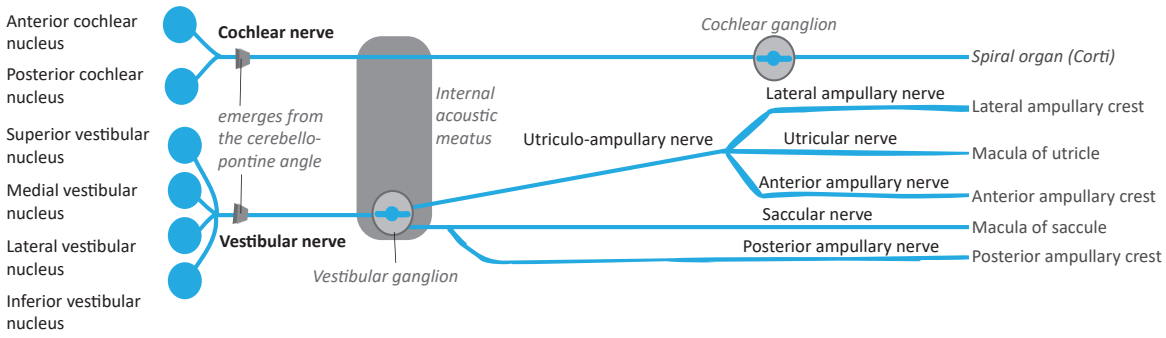

Glossopharyngeal nerve

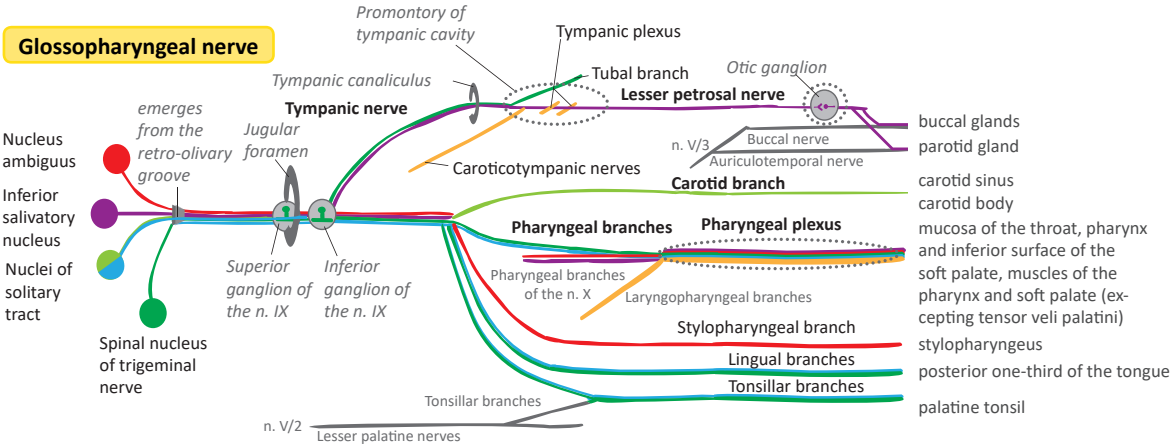

Somatomotor · Parasympathetic part · Sympathetic part · Somatosensory · Viscerosensory · Sensory

Vagus nerve

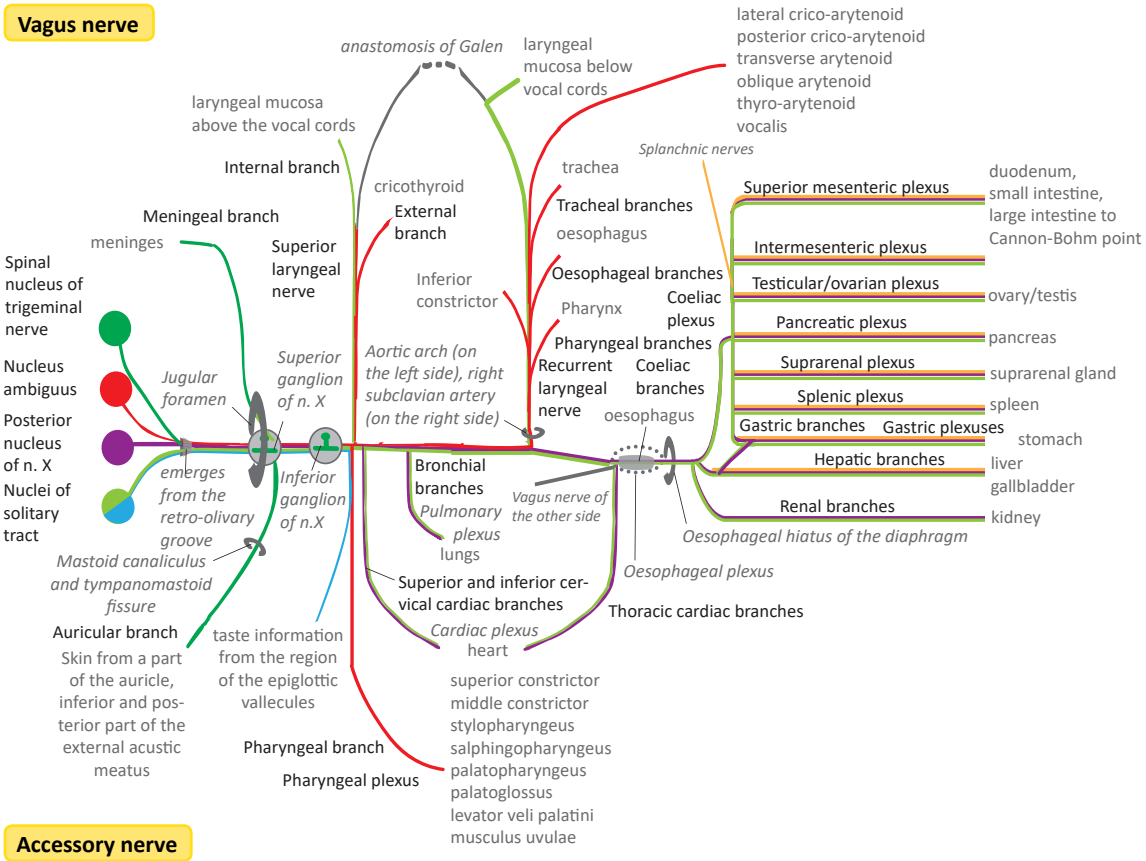

Accessory nerve

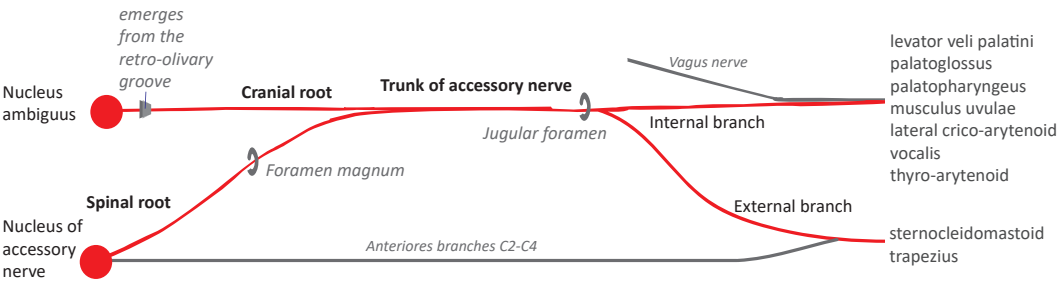

Hypoglossal nerve

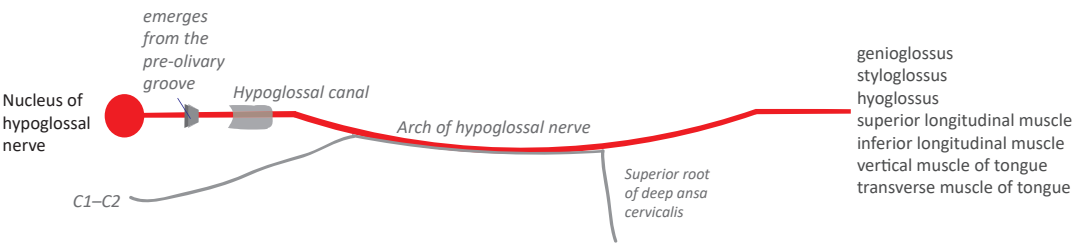

This copy belongs to ali yaghoubi

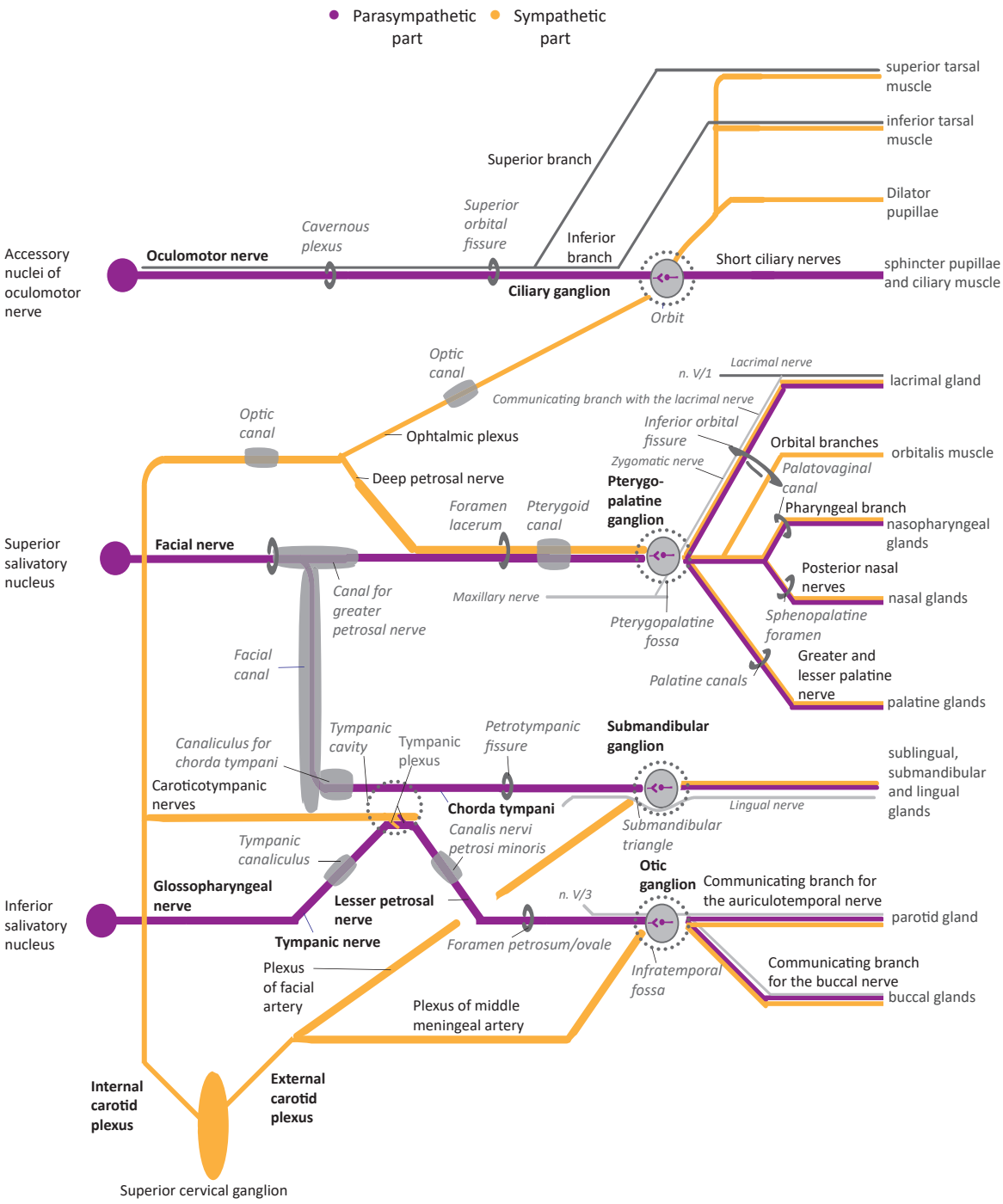
Parasympathetic part
Sympathetic part
Accessory nuclei of oculomotor nerve
Oculomotor nerve
Cavernous plexus
Superior orbital fissure
Superior branch
Inferior branch
Ciliary ganglion
Short ciliary nerves
Orbit
superior tarsal muscle
inferior tarsal muscle
Dilator pupillae
sphincter pupillae and ciliary muscle
Optic canal
Ophtalmic plexus
Deep petrosal nerve
Superior salivatory nucleus
Facial nerve
Foramen lacerum
Pterygoid canal
Canal for greater petrosal nerve
Facial canal
Maxillary nerve
Pterygo-palatine ganglion
Pterygopalatine fossa
n. V/1
Lacrimal nerve
Communicating branch with the lacrimal nerve
Inferior orbital fissure
Zygomatic nerve
Orbital branches
Palatovaginal canal
Pharyngeal branch
Posterior nasal nerves
Sphenopalatine foramen
Palatine canals
Greater and lesser palatine nerve
lacrimal gland
orbitalis muscle
nasopharyngeal glands
nasal glands
palatine glands
Canaliculus for chorda tympani
Caroticotympanic nerves
Tympanic cavity
Tympanic plexus
Petrotympanic fissure
Chorda tympani
Canalis nervi petrosi minoris
Submandibular ganglion
Submandibular triangle
Lingual nerve
sublingual, submandibular and lingual glands
Inferior salivatory nucleus
Glossopharyngeal nerve
Tympanic canaliculus
Lesser petrosal nerve
Tympanic nerve
Foramen petrosum/ovale
n. V/3
Otic ganglion
Communicating branch for the auriculotemporal nerve
parotid gland
Infratemporal fossa
Communicating branch for the buccal nerve
buccal glands
Plexus of facial artery
Plexus of middle meningeal artery
Internal carotid plexus
External carotid plexus
Superior cervical ganglion

I. General structure of the peripheral nervous system

1. Describe the classification of the peripheral nervous system. (p. 336)
2. Describe the structure of a peripheral nerve. (p. 336)
3. Describe the general structure of a spinal nerve. (p. 337)
4. State the types of fibres found within a peripheral nerve. (p. 337)
5. Describe the afferent and efferent arms of the reflex arch. (p. 338)
6. Describe a monosynaptic reflex. (p. 338)
7. List the differences between the anterior and posterior branches of spinal nerves. (p. 338)
8. Describe the reflex arc in the figure. (p. 338)

II. Cervical plexus

9. List all the sensory branches of the cervical plexus. (p. 340)
10. Describe the superficial cervical loop. (p. 340)
11. Describe the deep cervical loop and list the structures it innervates. (p. 341)
12. Describe the course of the both phrenic nerves. (p. 341)

III. Brachial plexus

13. Describe the basic morphology of the brachial plexus. (p. 342)
14. Name the seven principal branches emerging from the supraclavicular part of the brachial plexus (p. 342)
15. List the eight principal branches emerging from the infraclavicular portion of the brachial plexus. (p. 343)
16. Describe the course of the median nerve. (p. 343)
17. List the muscles innervated by the ulnar nerve. (p. 344)
18. Describe the course of the radial nerve. (p. 345)
19. Name the four structures innervated by the axillary nerve. (p. 345)

IV. Thoracic nerves

20. Describe the course of the intercostal nerve. (p. 346)
21. List the 13 muscles innervated by the thoracic nerves. (p. 346)

V. Lumbar plexus

22. Name the six principal branches of the lumbar plexus. (p. 346)
23. Describe the pathway of the ilioinguinal nerve. (p. 347)
24. Name the four structures innervated by the genitofemoral nerve. (p. 347)
25. Describe the course of the femoral nerve. (p. 347)
26. List the five structures innervated by the obturator nerve. (p. 347)

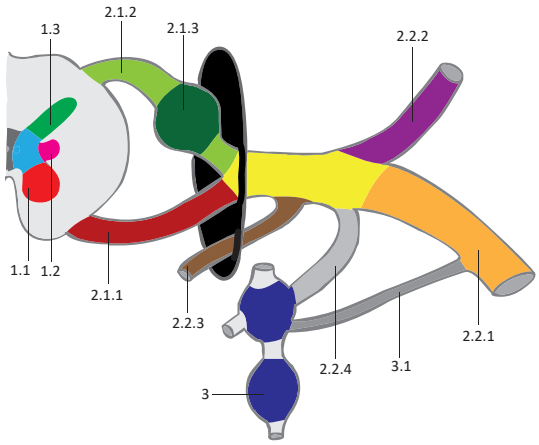

Describe the elementary structure of the peripheral nerve

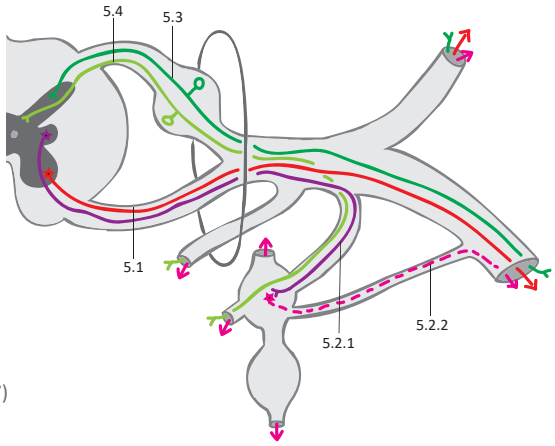

Describe particular nerve fibers in the peripheral nerve

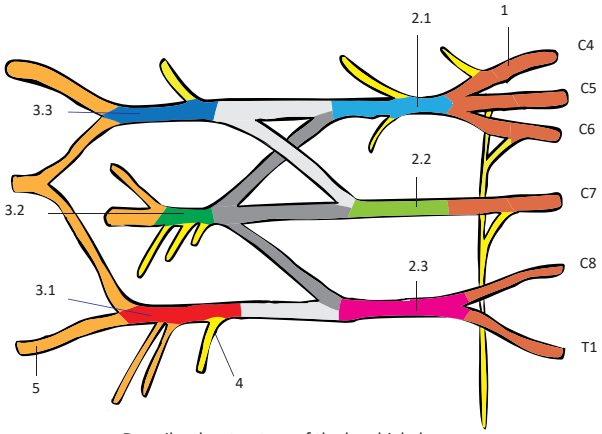

Describe the structure of the brachial plexus

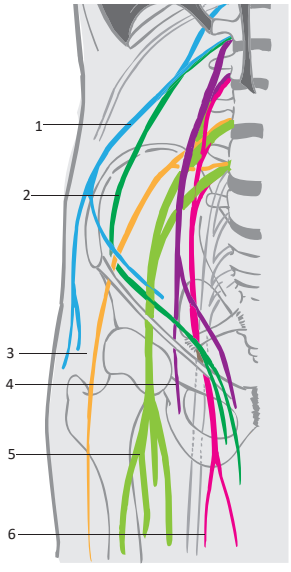

Describe the structure of the lumbar plexus

This copy belongs to ali yaghoubi

VI. Sacral plexus

27. Name the five main branches of the sacral plexus. (p. 348)
28. List the four nerves that pass through the infrapiriform foramen. (p. 348)
29. Describe the course of the pudendal nerve. (p. 348)
30. Name the five structures innervated by the pudendal nerve. (p. 348)
31. Describe the course of the sciatic nerve. (p. 349)
32. Explain the point of origin of the sural nerve. (p. 349)
33. Describe the course of the common fibular nerve and state the structures it innervates. (p. 349)
34. Describe the course of the tibial nerve and state the structures it innervates. (p. 349)

VII. Dermatomes and peripheral nerve fields

35. Define what dermatomes and myotomes are. (p. 350)
36. Explain what Head zones are and describe their significance. (p. 350)
37. Explain the difference between motor and sensory peripheral nerve fields. (p. 351)

VIII. Cranial nerves

38. Name the twelve cranial nerves. (p. 352)
39. Classify the cranial nerves according to the nature of their fibres. (p. 352)
40. State the four cranial nerves, which contain visceromotor fibers. (p. 352)
41. State the three cranial nerves, which contain somatosensory fibers. (p. 352)
42. Explain what the mixed lateral system is. (p. 352)
43. List the two cranial nerves, which originate from the mesencephalon. (p. 353)
44. List the three cranial nerves, which originate from the medulla oblongata. (p. 353)
45. State the foramina, through which the 12 cranial nerves leave the skull. (p. 353)
46. Describe the course of the olfactory nerve. (p. 354)
47. Explain what the optic nerve consists of and describe its course. (p. 354)
48. State the two branches of the oculomotor nerve and describe its course. (p. 355)
49. Give the eponymous term for the parasympathetic nucleus of the oculomotor nerve. (p. 355)
50. Describe the consequences of a unilateral lesion of the oculomotor nerve. (p. 354)
51. Describe the course of the trochlear nerve and state the muscle it innervates. (p. 355)
52. Describe the course of the trigeminal nerve and its origin in the brainstem. (p. 356)

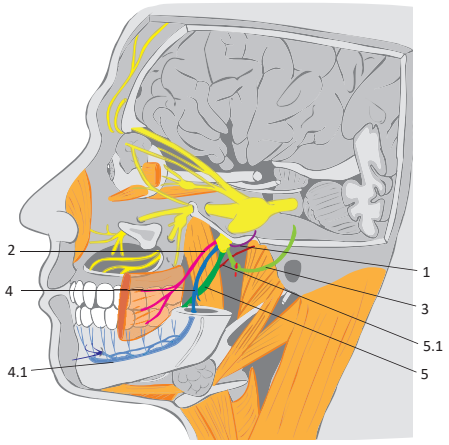

Describe the branches of the mandibular nerve

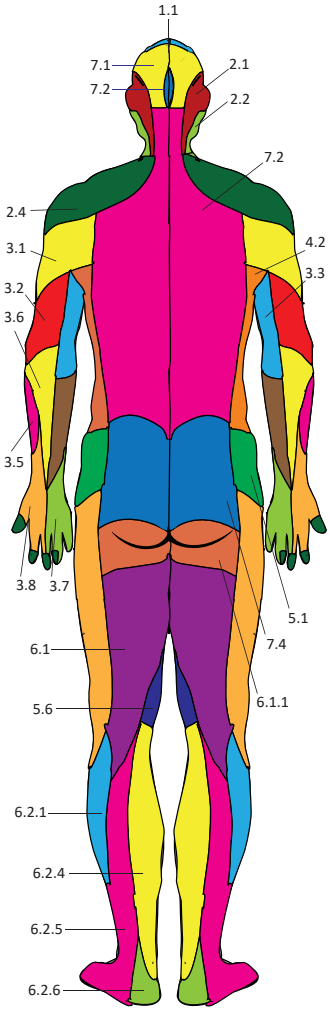

Describe the sensory nerve areas

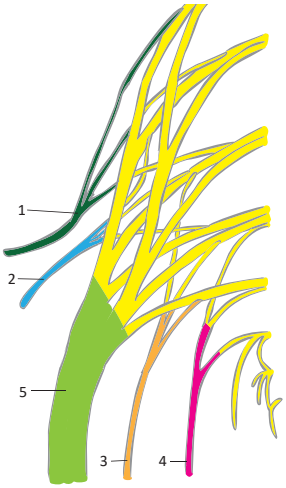

Describe the branches of the sacral plexus

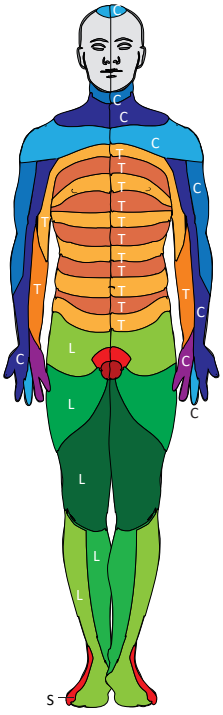

Describe the dermatomes

VIII. Cranial nerves

53. State the four nuclei, which contribute to the trigeminal nerve. (p. 356)
54. Describe the function of the mesencephalic nucleus of the trigeminal nerve. (p. 356)
55. State the three principal branches of the trigeminal nerve and describe their course. (p. 356)
56. State the three branches of the ophthalmic nerve and list the structures they innervate. (p. 357)
57. State the five branches of the maxillary nerve and list the structures they innervate. (p. 358)
58. State the five branches of the mandibular nerve and list the structures they innervate. (p. 359)
59. Describe the course of the abducent nerve and state the muscle it innervates. (p. 360)
60. Describe the course of the facial nerve and list its three nuclei. (p. 360)
61. List the ten principal branches of the facial nerve and state the structures they innervate. (p. 361)
62. Describe the clinical presentation of peripheral paralysis of the facial nerve. (p. 360)
63. Explain the function of the gustatory nucleus. (p. 360)
64. Describe the course of the vestibulocochlear nerve and state its two nuclei. (p. 362)
65. State the two principal branches of the vestibulocochlear nerve and list the structures they innervate. (p. 362)
66. Describe the course of the vestibulocochlear nerve through the internal acoustic meatus. (p. 362)
67. Describe the course of the glossopharyngeal nerve and state its four nuclei. (p. 363)
68. State the six branches of the glossopharyngeal nerve. (p. 363)
69. Describe the course of the vagus nerve through the body and state its four nuclei. (p. 364)
70. Describe the course of the accessory nerve and list the three structures it innervates. (p. 365)
71. Describe the course of the hypoglossus nerve and describe its relation to the deep ansa cervicalis. (p. 366)

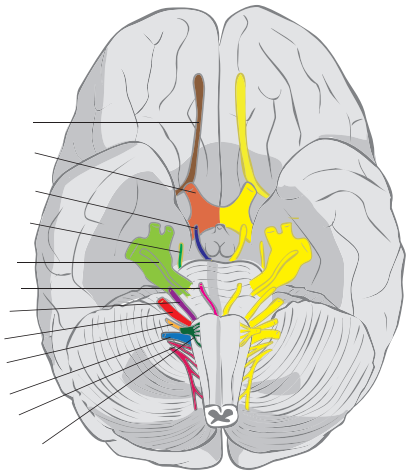

Describe how the cranial nerves leave the skull

III. Autonomic nervous system

72. Describe interconnections of the sympathetic fibres. (p. 368)
73. List all functions of the sympathetic system. (p. 368)
74. Describe the interconnections of the parasympathetic fibers. (p. 371)
75. State the functions of parasympathetic nerves. (p. 371)
76. List the three cervical sympathetic ganglia. (p. 370)
77. Describe the classification of the parasympathetic portion of the ANS. (p. 371)
78. Explain what the Cannon-Böhm point is. (p. 371)
79. State the nine parts of the mixed nervous plexuses of the thorax and abdomen. (p. 372–373)
80. Explain the function of the enteric nervous system. (p. 374)

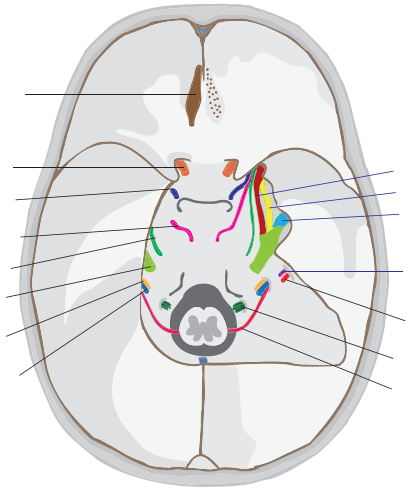

Describe how the cranial nerves pass through the dura mater

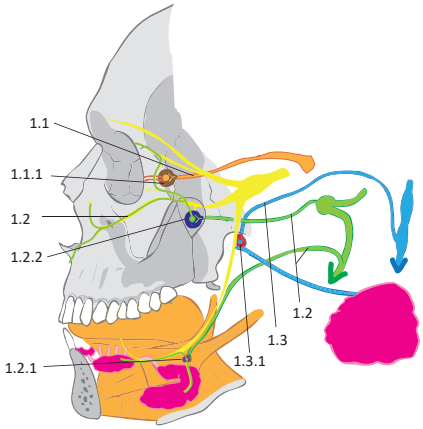

Describe the nerves and ganglia of the cranial part of the parasympathic system

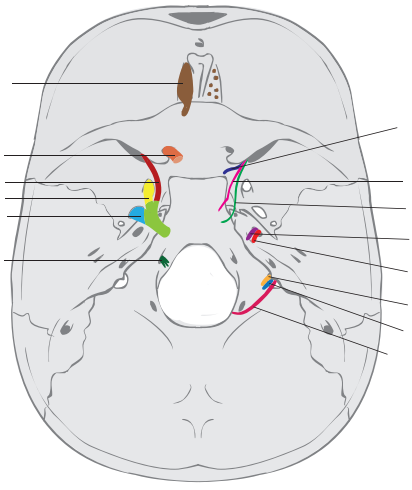

Describe how the cranial nerves pass through the skull

This copy belongs to ali yaghoubi

We would like to **thank the following anatomists, clinicians and medical students** for their invaluable help, devotion and feedback in the preparation of this chapter.

Anatomists

Assoc. prof. Václav Báča, MD, PhD – Department of Anatomy, Third Faculty of Medicine, Prague, Czech Republic
Prof. Hans J. Ten Donkelaar, MD, PhD – Radboud University Nijmegen Medical Center, Nijmegen, Netherlands
Prof. Darina Kluchová, MD, PhD – Department of Anatomy, Pavol Jozef Šafárik University, Košice, Slovakia
Marcela Bezdíčková, DSc, PhD – Department of Anatomy, Faculty of Medicine and Dentistry, Palacký University Olomouc, Czech Republic
Assoc. prof. Dr. Med. Dzintra Kažoka – Institute of Anatomy and Anthropology, Riga Stradiņš University, Latvia
Georg Feigl, Univ.-Ass. OA Priv.-Doz. Dr.med.univ. – Medical University of Graz, Institute of Anatomy, Austria
Marek Joukal, MD – Department of Anatomy, Faculty of Medicine, Masaryk University, Brno, Czech Republic

Clinicians

Prof. Robert Kuba, MD, PhD – First Department of Neurology, St. Anne's Faculty Hospital, Brno, Czech Republic
Jan Novák, MD – Department of Internal Medicine, St. Anne's Faculty Hospital, Brno, Czech Republic
and Department of Physiology, Faculty of Medicine, Masaryk University, Brno, Czech Republic
Ondřej Strýček, MD – First Department of Neurology, St. Anne's Faculty Hospital, Brno, Czech Republic
Christopher d'Esterre, MSc, PhD – Calgary Stroke Program, University of Calgary, Calgary, Canada

Medical students

Lukáš Mach
Linda Kašičková
Danil Yershov
Emilía Petríková
Therese George
Verena Leppmeier
Christoph Wawoczny
Sebastian Schmitz

7 References

1. DONKELAAR, H. Clinical neuroanatomy: brain circuitry and its disorders. Berlin: Springer, 2011. 834 p. ISBN 978-3-642-19134-3.
2. FIX, J. D. High-yield neuroanatomy. 4th Ed. Philadelphia: Lippincot Williams & Wilkins, 2009. 160 p. ISBN 978-0-7817-7946-3.
3. KIERNAN, J. and N. RAJAKUMAR. Barr's the human nervous system: an anatomical viewpoint. 10th Ed. Philadelphia: Lippincott Williams & Wilkins, 2014. 448 p. ISBN 978-1-4511-7327-7.
4. KOUKOLÍK, F. and L. HOUDEK. Lidský mozek. 3rd ed. Praha: Galén, 2012. 400 p. ISBN 9788072627714.
5. LANZ, T. and W. WACHSMUTH. Praktische Anatomie. 7 bands. Berlin: Springer, 2003, 3658 p. ISBN 978-3-540-40571-9.
6. MILLS, S. E. Histology for pathologists. 4th Ed. Philadelphia: Lippincot Williams & Wilkins, 2012. 1328 p. ISBN-13: 978-1-4511-1303-7.
7. MOORE, K. L.; DALLEY, A. F. and A. AGUR. Clinically oriented anatomy. 7th Ed. Philadelphia: Lippincot Williams & Wilkins, 2014. 1139 p. ISBN 978-1-4511-1945-3.
8. NETTER, F. H. Atlas of Human Anatomy. Professional Edition. 6th Ed. Oxford: Elsevier. 2014. 640 p. ISBN 978-1-455-75888-3.
9. NIEUWENHUYS, R.; VOOGD, J. and C. HUIJZEN. The human central nervous system: A Synopsis and Atlas. 4th Ed. Berlin: Springer, 2007. 967 p. ISBN 978-3-540-34684-5.
10. NOLTE, J: Nolte's The Human Brain: An Introduction to its Functional Anatomy With Student Consult Online Access. 6th Ed. Philadelphia: Mosby/Elsevier, 2008, 79 p. ISBN 978-0-323-04131-7.
11. OVALLE, W. K. and P. C. NAHIRNEY. Netter's Essential Histology: with Student Consult Access. 2nd Ed. Philadelphia: Saunders/Elsevier, 2013. 493 p. ISBN-13: 978-1-4557-0631-0.
12. ROHEN, J. W. LUTJEN-DRECOLL, E. and C. YOKOCHI. Color Atlas of Anatomy: A Photographic Study of the Human Body. 7th Ed. Stuttgart: Lippincot Williams & Wilkins, 532 p. ISBN 978-1-58255-856-1.
13. ROWLAND, L. P. and T. A. PEDLEY. Merritt's neurology. 12th Edition. Philadelphia: Lippincot Williams & Wilkins , 2010. 1216 p. ISBN 978-0-7817-9186-1.
14. SNELL, R. S. Clinical Neuroanatomy. 7th Edition. Philadelphia: Lippincot Williams & Wilkins, 2009, 560 p. ISBN 978-0-7817-9427-5.
15. WILLIAMS, P. L., ed. Gray´s Anatomy: the anatomical basis of medicine and surgery. 38th Ed. New York: Churchill Livingstone, 1995, 2092 p. ISBN 0-443-05717-6.

Memorix Anatomy

12 Central nervous system

Ondřej Volný
David Kachlík
Radovan Hudák
Petr Vaněk
Adam Whitley



General overview	390
Spinal cord	398
Brainstem	402
Reticular formation	414
Cerebellum	418
Diencephalon	424
Telencephalon	432
Limbic system	444
Sensory system	450
Motor system	456
Special sensory tracts	462
Ventricular system and meninges	468
Blood supply of the spinal cord and brain	472
Sections	482
Schemes	488
Review questions and figures	494
Acknowledgements and references	500

This copy belongs to ali yaghoubi

The central nervous system consists of the **spinal cord** and **brain**. The **brainstem** is the part of the brain that connects to the spinal cord. It is composed of the **medulla oblongata, pons and midbrain**. Rostral to the brainstem is the **diencephalon**, which transmits information to the largest and evolutionary youngest part of the brain: the **telencephalon**. The **cerebellum** is situated posterior to the brainstem in the posterior cranial fossa.

Parts of the central nervous system

- 1 **Medulla spinalis** – spinal cord
- 2 **Medulla oblongata**
- 3 **Pons**
- 4 **Mesencephalon**
- 5 **Cerebellum**
- 6 **Diencephalon**
- 7 **Telencephalon**

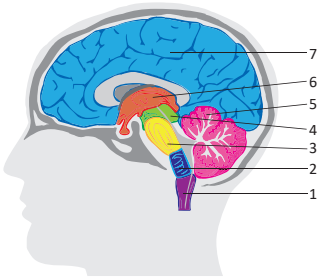

1.1 Microscopic structure – neurones

Neurones are the functional cells of the nervous system. The neurone is composed of a **cell body** and its **cytoplasmic projections (axons and dendrites)**. Neurones transmit electrical signals along their **excitable membranes**. Information is passed between neurones through specialised junctions called **synapses**.

Structure

- 1 **Nerve cell body** (*perykarion, neurosoma*)
  – receives, creates and transmits electrical impulses
- 2 **Axon** – a single long neuronal projection
  - transmits impulses in a centrifugal direction (away from the cell body)
- 3 **Dendrites** – multiple short projections
  – transmit impulses in a centripetal direction (towards the nerve cell body)

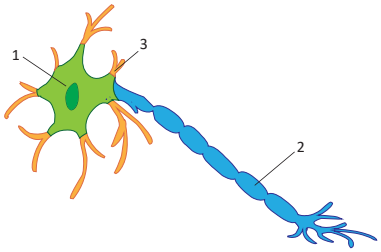

Types of neurones according to their projections

- 1 **Bipolar neurones**
  – possess one axon and one dendrite with branches
  – their projections are located on the opposite poles of the neurone
  – include the rods and cones of the retina, olfactory neurones and the bipolar neurones of the cochlear and vestibular ganglia
- 2 **Pseudounipolar neurones** (T cells)
  – possess one axon and one dendrite which merge together into a structure called the axodendrite near the nerve cell body
  – constitute the afferent somatosensory neurones in the spinal and cranial nerve ganglia
- 3 **Multipolar neurones**
  – possess one axon and many dendrites which give the cell a star-like shape
  – include the efferent motor neurones and the neurones of the autonomic nervous system and are widespread in the central nervous system

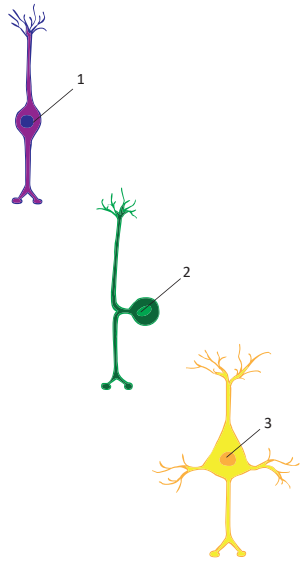

Central nervous system

CNS is an abbreviation for the central nervous system.

Neurones differ in size, shape and function, e.g. pyramidal cells in the cortex (Betz's neurons as the largest cortical neurons in lamina V), Purkinje´s cells in the cerebellum or retinal neurones.

The glial limiting membrane (*membrana limitans glialis perivascularis*) is a thin barrier formed by cytoplasmic projections from astrocytes covering the capillaries entering the central nervous system. It forms part of the blood brain barrier.

Clinical notes

A glioma is a type of brain tumour that arises from glial cells.

In the CNS, oligodendrocytes produce myelin. In the PNS, Schwann cells have this function. Oligodendrocytes and Schwann cells differ in their ability to regenerate damaged neuronal projections. Oligodendrocytes are limited in this function; injury of the CNS is permanent with a low probability of complete restoration of function. In contrast, Schwann cells are endowed with a better ability to regenerate damaged nerve tissue. Thus, neurosurgical suturing of peripheral nerves helps with the process of regeneration of damaged neuronal projections.

The CNS contains more than 100 billion neurones in childhood. During development many of these neurones perish in the process of programmed cell death. Other neurones become specialised. They sprout projections and connect to neuronal circuits and pathways. The final result is the creation of a complex network, known as the connectome of the human brain.

Neurones are highly differentiated cells with an exceedingly restricted mitotic ability. Proliferation of neurones takes place in only a few areas of the CNS. These areas, or "nests", include parts of the hippocampus and the olfactory system.

Insults to the development of the brain give rise to neurodevelopmental diseases such as epilepsy, autism and behavioural disorders and schizophrenia.

Progressive neuronal loss in the adult brain gives rise to neurodegenerative diseases such as Alzheimer's disease, other types of dementia and Parkinson's disease.

Neuroglia (glial cells) are the supporting cells of the nervous system. They provide **nutrition** and **mechanical support and protection** to neurones. They are capable of **phagocytosis** and function to **repair damage** to nervous tissue. They include astrocytes, oligodendrocytes, microglia and ependymal cells.

Neuroglia

1 **Astrocytes** – the largest neuroglia
– have long projections ending in vascular end-feet, which make contact with capillaries of the pia mater to form the glial limiting membrane (*membrana limitans glialis*), a part of the blood brain barrier
- 1.1 **Protoplasmic astrocytes** – have short ramified projections – are more common in grey matter
- 1.2 **Fibrous astrocytes** – have long, less ramified projections – are more common in white matter

- 2 **Oligodendrocytes**/oligodendroglia – are responsible for myelination in grey and white matter of the CNS
- 3 **Microglia** – the smallest neuroglia
  – are capable of phagocytosis
  – arise from mesenchymal cells, which migrate into developing nervous tissue
- 4 **Ependymal cells** / ependymocytes
  – line the central canal, ventricles and choroid plexus
  – responsible for cerebrospinal fluid (CSF) production
  – transmit signals via molecules dissolved in CSF
  - 4.1 **Tanycytes** – ependymal cells with long projections that make tight contact with hypothalamic nuclei
    – transfer signals from CSF to the CNS and play a role in the hypothalamic-hypophyseal axis

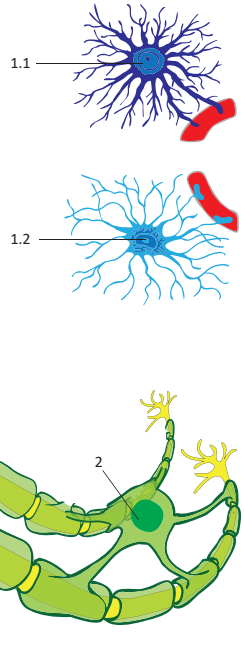

1.3 Distribution of white and grey matter

Nervous tissue is formed by **white and grey matter**. **Grey matter** contains **nerve cell bodies**. W**hite matter** mainly consists of **neuronal projections**. The distribution of grey and white matter differs in the brain and in the spinal cord. **In the telencephalon and cerebellum, grey matter is located on the surface** and forms the cerebral and cerebellar **cortices**. Deep grey matter structures are called **basal nuclei** in the cerebrum and **cerebellar nuclei** in the cerebellum. In contrast to the brain, **white matter in the spinal cord** (neuronal tracts) **is located superficially** and grey matter is located deeply.

- 1 **Grey matter** (*substantia grisea*) – nervous tissue rich in nerve cell bodies and dendrites
  1.1 **Brain and cerebellar cortex** – nerve cell bodies in a laminar distribution
  1.2 **Nuclei** – nerve cell bodies, which form bordered and visible structures (nuclei) with specfic functions (motor, associate and somatosensory)
  1.3 **Ganglia** – nerve cell bodies in the peripheral nervous system (somatosensory, sensory and autonomic)
- 2 **White matter** (*substantia alba*) – nervous tissue rich myelinated axons and glial cells
- 3 **Reticular formation** (*formatio reticularis*) – a phylogenetically old tissue consisting of nuclei with connections to neuronal tracts, located predominantly in the brainstem

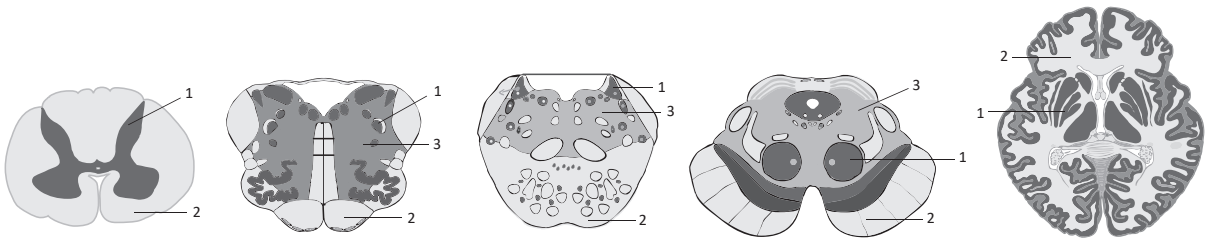

Cross-section of the spinal cord | Cross-section of the medulla oblongata | Cross-section of the pons | Cross-section of the midbrain | Cross-section of the telencephalon

This copy belongs to ali yaghoubi

The development of the nervous system begins in the **3rd week of intrauterine life** with thickening of the dorsal midline ectoderm to form the **neuroectoderm**. The neuroectoderm is induced to invaginate in the midline to form the **neural tube**, which later develops into the brain and spinal cord. Development is not complete until early adulthood; myelination of nervous tracts and synapse formation in the cerebral cortex occurs extensively in the postnatal period.

Developmental stages

- 1 **Neural/medullary plate** (*lamina neuralis/medullaris*) – the first stage
  - – is formed from neuroectodermal tissue in the midline of the dorsal surface of the embryo
  - – the notochord (*chorda dorsalis / notochorda*) is situated ventrally to the neural plate and induces sequences in development by secreting growth factors
- 2 **Neural groove** (*sulcus neuralis*) – the second stage
  - – the neural plate deepens to form the neural groove bordered by the paired neural edges
  - – the neural crest (crista neuralis) forms on the both sides of the neural groove
  - – the cells of the neural crest give rise to the spinal and autonomic ganglia, adrenal gland, paraganglia (which include the carotid body and aortic bodies and the organ of Zuckerkandl), Schwann cells, melanocytes, Merkel cells, odontoblasts, parafollicular cells of the thyroid gland and cells of the diffuse neuroendocrine system
- 3 **Neural tube** (*tubus neuralis*) – the third stage
  - – is formed by fusion of the neural edges
  - – the primitive central canal gives rise to the ventricles and the definitive central canal
  - – the paired sulcus limitans is situated inside the primitive central canal, separating the functionally distinct basal and alar plates

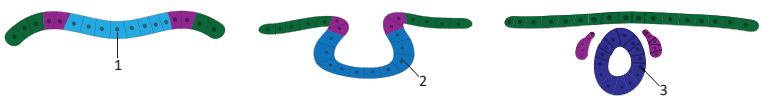

Plates and nuclei

- 1 **Alar plate** (*lamina dorsolateralis*)
  - – is located dorsally and gives rise to the somatosensory and viscerosensory nuclei
  - – in the spinal cord it gives rise to the sensory nuclei of the posterior horns (for temperature, pain, vibration and proprioception of the body)
  - – in the brainstem it gives rise to the sensory nuclei of the trigeminal nerve (for temperature, pain, vibration and propriception of the head), gustatory nucleus (the rostral part of the solitary nucleus containing the termination of gustatory fibres from the from the facial, glossopharyngeal and vagus nerves), nuclei of the solitary tract receiving information from internal organs and the cochlear and vestibular nuclei
- 2 **Basal plate** (*lamina ventrolateralis*)
  - – is situated ventrally and gives rise to the motor nuclei
  - – in the spinal cord it gives rise to the somatomotor nuclei of the ventral horn (for innervation of striated muscles) and the visceromotor nuclei of the lateral horn (for innervation of smooth and cardiac muscle and exocrine glands)
  - – in the brainstem it gives rise to the motor nuclei of oculomotor, trochlear, abducent and hypoglossal nerves (n. III, IV, V and XII) for innervation of muscles of somite origin
  - 2.1 **Branchiomotor nuclei**
    - – nuclei in the brainstem, which give rise to the motor nuclei of the trigeminal, facial, glossopharyngeal, vagus and accessory nerves (n. V, VII, IX, X and XI)
    - – muscles innervated by these nuclei are of branchial origin, which is different from striated muscles found in other parts of the body, which is of somite origin

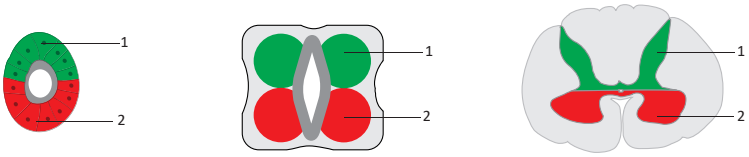

Central nervous system

With the exception of microglia, which are of mesenchymal origin, the **central nervous system is of neuroectodermal origin**.

Shortened step-by-step development of the CNS:
1. ectoderm
2. ectoderm is getting thicker – neuroectoderm
3. flat neural plate
4. deepening into the neural groove
5. bulging of neural edges
6. closing into the neural tube and derivation of the neural crest

Developmental rule of the CNS – the younger the structure is, the closer it is to the neocortex.

Development of the limbic system:
1. **The amygdaloid body** finishes developing in the first year of postnatal life. The immature amygdaloid body is responsible for the extreme orality of infants. The mature amygdaloid is responsible for fear and credulity.
2. **The cingulate gyrus and septum verum** finish maturation in the toddler and in pre-school periods, respectively. These structures are responsible for socialization and the development of human relationships
3. **The orbitofrontal and associative cortex** finish development at the age of 12 years. These structures are responsible for executive functions, planning and logical thinking.

The rhomboid fossa is named according to the rhomboid shape of the floor of the fourth ventricle.

The lateral ventricles are horseshoe shaped and have projections in the occipital, frontal and temporal lobes. During brain development, the lateral ventricles, as derivatives of the central canal, follow the growth of the telencephalon.

The development of the insular lobe (*insula*) is different to the other lobes. The insular lobe doesn't contain any part of the ventricular system. It is located inside the lateral cerebral fossa, hidden by the opercula of the frontal, parietal and temporal lobes.

There are many novel features at each hierarchical level of development. In the forebrain, three components are recognised: the telencephalon, hypothalamus with the optic vesicle and the diencephalon. The telencephalon and hypothalamus constitute the secondary prosencephalon. The hypothalamus may be considered as a part of the diencephalon.

The process of brain development is called **encephalisation**. It begins with the development of the **brain vesicle**. The brain vesicle differentiates into three parts: the **rhombencephalon, mesencephalon** and **prosencephalon**. The rhombencephalon divides into the metencephalon and myelencephalon, which give rise to the brainstem and cerebellum, respectively. The prosencephalon divides into the diencephalon and telencephalon. The mesencephalon does not undergo further differentiation. The brain is situated in a confined space; thus, during the period of fast growth and development flexures develop.

Differentiation of the primitive brain

- 1 **Prosencephalon**
  - – differentiates into the diencephalon and telecephalon
  - 1.1 **Diencephalon**
    - – the central canal of the diencephalon forms the third ventricle
  - 1.2 **Telencephalon**
    - – the central canal of the telencephalon forms the paired lateral ventricles
- 2 **Mesencephalon**
  - – the central canal forms the cerebral acqueduct, which connects the third and fourth ventricles
- 3 **Rhombencephalon**
  - – differentiates into the metecephalon and myelencephalon
  - 3.1 **Metencephalon**
    - – gives rise to the cerebellum and pons
  - 3.2 **Myelencephalon**
    - – gives rise to the medulla oblongata, its central canal forms the fourth ventricle

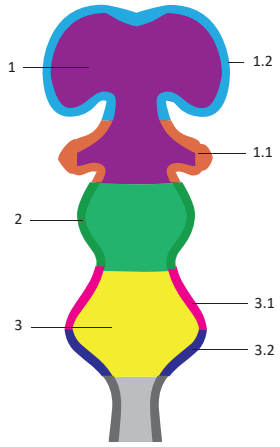

Scheme of differentiation

Flexures (*flexurae*)

- 4 **Cervical flexure** (*flexura cervicalis*)
  - – ventrally concave
  - – is located between the spinal cord and brainstem
- 5 **Pontine flexure** (*flexura pontina*)
  - – ventrally convex
  - – is located in the pons (serves as a space for the cerebellum)
  - – its development follows the mesencephalic flexure
- 6 **Mesencephalic flexure** (*flexura mesencephalica*)
  - – ventrally concave
  - – is located in the mesencephalon

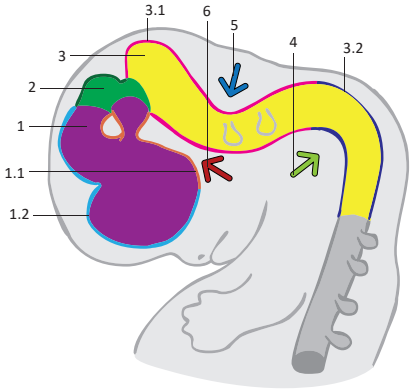

Differentiation of the brain vesicles in the foetus

Telencephalon development

1 **Pallium** – has four developmental domains
- 1.1 **Dorsal pallium** – forms the isocortex/neocortex
- 1.2 **Lateral pallium** – forms the claustro-insular complex
- 1.3 **Medial pallium** – forms the hippocampal formation
- 1.4 **Ventral pallium** – forms the olfactory cortex and pallial amygdala

2 **Subpallium** – has four developmental domains
- 2.1 **Striatum**
- 2.2 **Pallidum**
- 2.3 **Innominate substance / diagonal band area**
- 2.4 **Preoptic area**

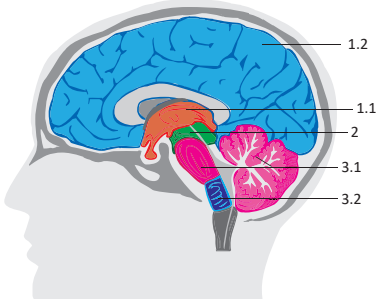

Analogical parts of the brain formed by differentiation

This copy belongs to ali yaghoubi

A **tract** is a bundle of axons, which interconnects grey matter structures in CNS and transmits impulses of the same manner. Tracts are divided by the **number of synapses** they pass through, the **direction of impulse propagation**, and the **type of information** they transmit. **Motor tracts** transmit information for movements and sensory tracts transmit perception data. **Somatic tracts** transmit impulses to and from skin, skeletal muscles, tendons and joints. **Visceral tracts** transmit impulses to and from the viscera, glands and blood vessels. The **special senses** are hearing, balance, vision, taste and smell. Information about these senses is carried in **special sensory tracts**.

Classification according to the number of connected neurones

Single-neurone tracts

– are formed by axons of one type of neurons
– include the cortico-spinal, rubro-spinal, spino-cerebellar tracts

Multi-neuron tracts

– are formed by a series of neurones
– interconnect several levels of the CNS
– the number of "neurons" corresponds to the number of individual axons which form the tract
– direct somatomotor or somatosensory tracts feature up to three axons (nerve cell bodies)
2-neuron tracts – spino-reticulo-thalamic, cortico-ponto-cerebellar tract or olfactory tract
3-neuron tracts – medial lemniscus and gustatory or vestibular tract
4-neuron tracts – auditory and visual tract

Tracts which form loops
– interconnect structures in one or more levels of the CNS
– tracts form an enclosed loop with connections to other nervous structures
– include the basal ganglia and limbic system circuits

Classification according to the main function

1 **Associative tracts** (*fibrae associationis*)
– interconnect two structures in one hemisphere or at the level of the same half of the spinal cord
– include the arcuate fasciculus (*fasciculus arcuatus*) which interconnects the speech centres (Broca's and Wernicke's areas)

2 **Commissural tracts** (*fibrae commisurrales*)
– interconnect the hemispheres
– include the corpus callosum, which is the main connection between the two hemispheres of the brain and the anterior and posterior white commissures, which interconnect the right and left halves of the spinal cord

3 **Projection tracts** (*fibrae projectionis*)
– interconnect individual levels of the CNS
– include the medial lemniscus, which connects the spinal cord with the nuclei of the medulla oblongata (gracile and cuneate nucleus) through the thalamus to the cortex

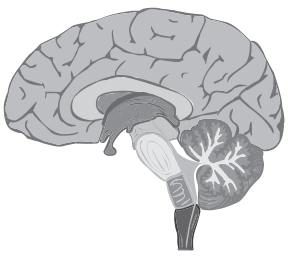

Sagittal section of the pons and spinal cord



Cross-section of the brain

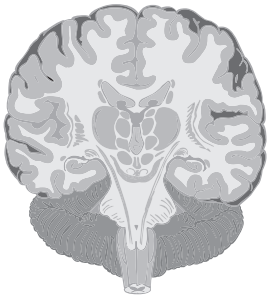

Frontal (coronal) section of the brain

An electrical synapse is a connection between two neurones formed by gap junctions. They are much less common than chemical synapses.

A nervous tract transmits signals between the different levels of the CNS.

A reflex arch consists of a sensory nerve connected to a motor nerve through the CNS. It allows a rapid motor response to a sensory stimulation.

A neuronal tract is described by its origin, course through different levels of the CNS, location and number of synapses, decussations and by where it terminates. In this textbook, we use the following abbreviations when describing neuronal tracts:
O – origin
C – course
T – termination
F – function

For easier reading we have used hyphens for the names of multi-neurone or neuronal tracts (e.g. cortico-spinal tract). However, in official anatomical terminology, hyphens are not used (e.g. corticospinal tract).

Clinical notes

The pyramidal tract (cortico-spinal tract) is a bineuronal tract. The first order neurones are located in the cerebral cortex and are referred to as upper motor neurones (UMN). The second order neurones are located in the spinal cord (or brainstem motor nuclei) and are referred to as lower motor neurones (LMN). The clinical manifestation of upper and lower motor neurone diseases are very different.

Classification of tracts according to the course and impulse propagation

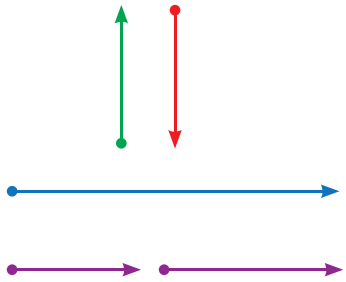

- **Ascending tracts**
  – interconnect lower to higher levels of the CNS
- **Descending tracts**
  – interconnect higher to lower levels of the CNS

- **Primary/direct tracts**
  – single-neuron tracts
  – evolutionary younger (cortico-spinal tract which directly connects cortical neurons and spinal cord motor neurons)
- **Secondary/indirect tracts**
  – multi-neuron tracts
  – synapse in at least one nuclei before reaching their target structure
  – include the cortico-reticulo-spinal tract

Classification according bundles type

1 **Somatomotor tracts** – regulate striated muscles
2 **Visceromotor tracts** – regulate tone and motility of smooth muscle, myocardium and secretory glands
2.1 **Parasympathetic system** – part of the autonomic nervous system
2.2 **Sympathetic system** – part of the autonomic nervous system
3 **Somatosensory tracts** – transmit information from mechanoreceptors, exteroreceptors, proprioceptors and thermoreceptors
4 **Viscerosensory tracts** – transmit information from internal organs and interoreceptors
5 **Special sensory tracts** – transmit information from the special sensory organs

1.7 Directions, planes and special terms of the central nervous system

Directions in the brain are described differently in comparison with the rest of the body. The axis of the brainstem is inclined at an angle of 45° to the long axis of the spinal cord. The spinal cord is situated vertically and the telencephalon is situated horizontally. **Planes** in the CNS are also described in a different manner. On magnetic resonance imaging and computed tomography the frontal plane is called the **coronal plane** and the axial plane is referred to as the **sagittal plane**.

Directions in the brain:

- 1 **Rostral, frontal, cranial** (*rostralis, frontalis, cranialis*) – towards the forehead
- 2 **Caudal** (caudalis, *occipitalis*) – towards the lower parts of the CNS (spinal cord, etc.)
- 3 **Dorsal** (*dorsalis*) – towards the vertex of the skull
- 4 **Ventral** (*ventralis, basalis*) – towards the base of the skull
- 5 **Medial** (*medialis*) – towards the midline
- 6 **Lateral** (*lateralis*) – from the midline

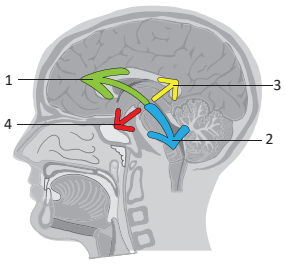

Directions in the brain

Directions in the telencephalon:

- 1 **Frontal** (*frontalis, rostralis*) – towards the forehead
- 2 **Occipital** (*occipitalis*) – towards the back of the head
- 3 **Dorsal** (*dorsalis*) – towards the vertex of the skull
- 4 **Basal** (*basalis, ventralis*) – towards the base of the skull
- 5 **Medial** (*medialis*) – towards the midline
- 6 **Lateral** (*lateralis*) – from the midline

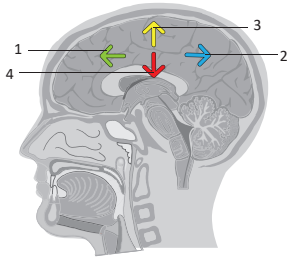

Direction in the telencephalon

Planes in the brain and head:

Coronal plane – frontal plane
Axial plane – sagittal plane

This copy belongs to ali yaghoubi

The CNS function is hierarchical and is based on the development of the nervous system. The human nervous system, in a simplified way, can be divided into **four main levels**. **The structures younger in development are functionally superior to the older ones.** Each level has a **motor and a sensory part** which cooperate and provide reflexes and complex responses. Individual levels are **interconnected via nervous tracts**. **The functions of the first three levels occur subconsciously. Only the fourth level (the cortex) is responsible for consciousness.**

I. **Spinal cord** – regulates monosynaptic and polysynaptic reflexes
- mediates communication between the CNS and PNS via the 31 pairs of spinal nerves
- **the somatosensory nuclei** in the posterior horns receive information from peripheral receptors
- **the motor neurones** in the anterior horns send impulses to effector organs (muscles and glands)

II. **Brainstem** – is responsible for complex reflexes and vital functions
- mediates communication between the CNS and PNS via the 10 pairs of the cranial nerves
- **connects the telencephalon and diencephalon to the cerebellum**
- **the somatosensory nuclei** are mainly located **in the lateral parts** of the brainstem
- **the motor nuclei** are mainly located **in medially** in the brainstem
- **the reticular formation** is a complex network of neurones and interneurones in the brainstem, which is responsible for vital functions, cranial nerve reflexes and consciousness as well as many other complex nervous functions

III. **Subcortical structures**
- **somatosensory subcortical structures** include sensory thalamic nuclei, which regulate sensory information entering the cortex
- **somatomotor subcortical structures** include the motor circuits of the basal ganglia and the motor nuclei of the thalamus and are responsible for motor programming
- **visceromotor subcortical structures** are located in the hypothalamus and control the autonomic nervous system and the endocrine functions of the hypophysis
- **the sensory thalamic nuclei** regulate sensory information entering the cortex
- **the motor circuits of the basal ganglia and the motor nuclei of the thalamus** and are responsible for motor programming
- **the hypothalamus** controls the autonomic nervous system and the hypophysis

IV. **Cortex** – is responsible for a wide variety of functions, including consciousness, perception, thinking, planning, concentration, memory, self-perception, self-criticism, and voluntary motor functions
- **primary sensory areas** are responsible for the conscious perception of all sensory modalities
- **the primary motor area** is responsible for voluntary motor control
- **secondary cortical areas** are associated with primary areas and process information
- **secondary motor areas** are involved in planning and regulation of movements
- **associative cortex** is reciprocally connected with primary and secondary areas
- the cortex is highest functioning part of the CNS

Multilevel systems

Reticular formation, limbic system and cerebellum
- these structures are connected via complex tracts and circuits with almost all parts of the CNS

Limbic system – is composed of both cortex and subcortical structures

1 **Cortical parts**
- are responsible for intentional manifestation of emotion and memory consolidation
- e.g. cingulate gyrus, parahippocampal gyrus, hippocampal formation

2 **Subcortical areas**
- are responsible for subconscious emotion and memory processes
- include some of the thalamic and hypothalamic nuclei and the amygdaloid body

The human brain receives vast amounts of information, but just a minority of it reaches the consciousness. The rest of the input is processed subconsciously or inputs are evaluated as noise and are not processed.

Simplified example of CNS functions and levels:
Imagine, you are walking on a sand beach and step on a nail. You will immediately flex the affected limb to move it away from the nail. This is a **spinal cord reflex**, a function of **the first level of the CNS**.
As the affected leg moves away from the painful stimulus, the extensor muscles of the contralateral leg are activated and postural muscles of the back are activated to maintain balance as the centre of gravity changes. This is mediated through brainstem nuclei and the cerebellum in the **second level of the CNS**.
Then, signals transmitting pain information reach the diencephalon. The basal ganglia cooperate with limbic system in creating the emotional component of pain. This is a function of the **third level of the CNS**.
Finally, sensory information reaches the **fourth level of the CNS**: our consciousness. This occurs when impulses reach the thalamus and cortex. Our reaction depends on the limbic system and neocortical activity. We can behave rationally by sitting down and treating the wound or we can let our limbic system get the better of us and scream and cry.

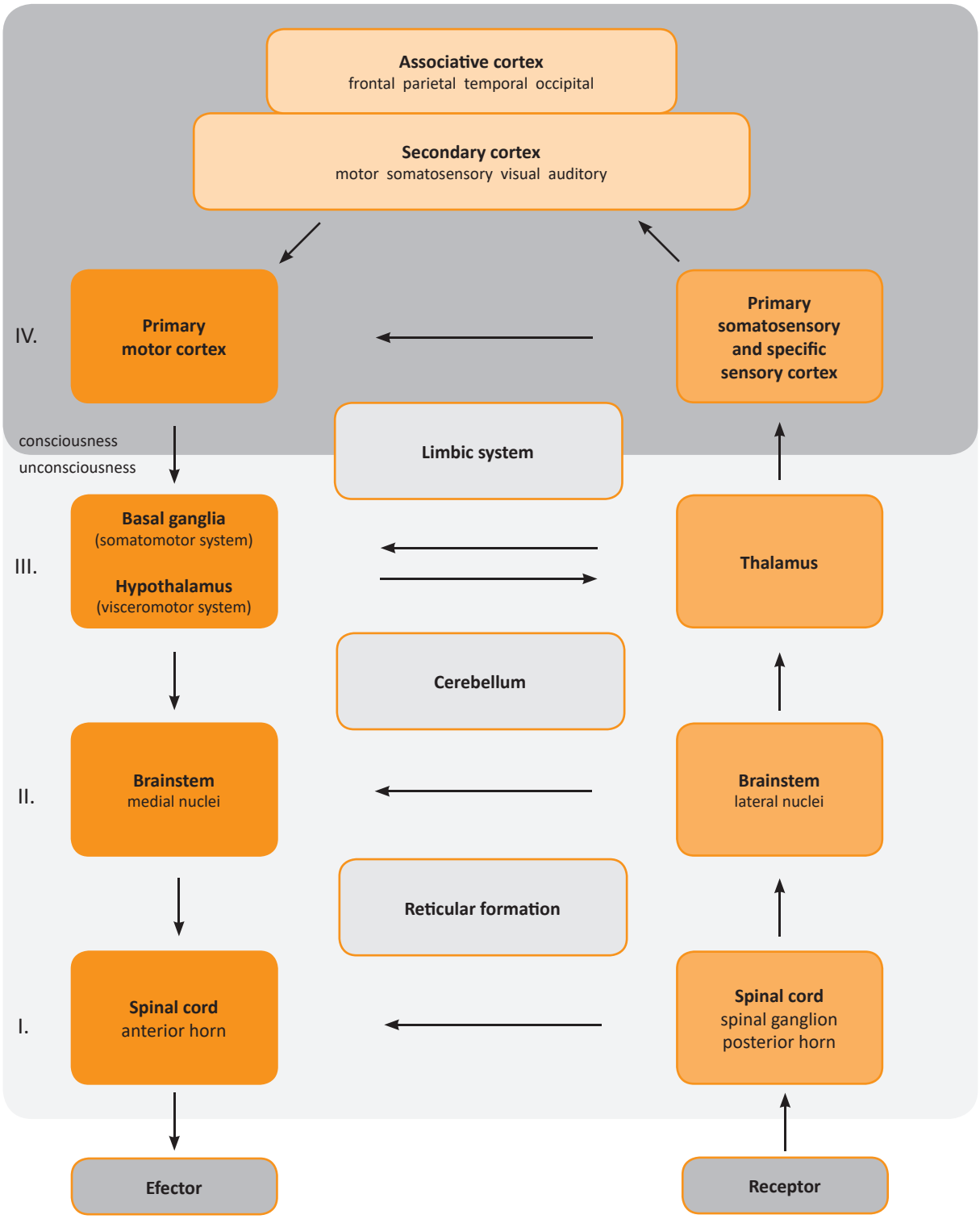

The reticular formation, limbic system and the cortex are interconnected by tracts with almost all parts of the CNS.
These structures are not assigned by arrows in this simplified scheme of the CNS.

This copy belongs to ali yaghoubi

The spinal cord is enclosed **in the vertebral canal** and is **covered with the meninges**. **Its structure is similar to the primitive neural tube with the central canal inside**. In early stages of development, the spinal cord fills the vertebral canal completely and segment position corresponds to the respective vertebra. The vertebral column grows quicker than the spinal cord. Hence, **the caudal part of the vertebral canal contains just nerve roots** (cauda equina) and **the caudal end of the spinal cord is situated at the level of L1–L2**. The spinal cord consists of **31 segments** (8 cervical, 12 thoracic, 5 lumbar, 5 sacral and 1 coccygeal).

Topography

- 1 **Cranially:** continuous with medulla oblongata
  - 1.1 **Cranial borderline:**
    - – foramen magnum
    - – decussation of pyramids (*decussatio pyramidum*)
    - – the first cranial nerve, which is located between the occipital bone and atlas
- 2 **Caudally:** ends at the level of L1–L2
  - 2.1 **Medullary cone** (*conus medullaris*)
  - 2.2 **Spinal part of filum terminale** (*pars spinalis fili terminalis*)
    - – a threadlike structure of glial tissue that extends caudally from the medullary cone to the dural mater in the sacral region
  - 2.3 **Cauda equina** consists of lumbar, sacral and coccygeal nerves that pass caudally to the medullary cone

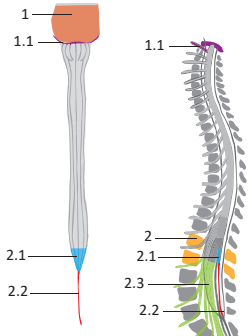

Vertebromedullary topography

Chipault´s rule: describes the relationship between the spinal cord segments and the vertebrae

- 1 **Spinous processes of cranial cervical vertebrae**
  - – correspond to the same cord segments
- 2 **Spinous processes of caudal cervical vertebrae**
  - – segment + 1 (e.g. vertebra C7 = spinal segment C8)
- 3 **Spinous processes of cranial thoracic vertebrae**
  - – segment + 2 (e.g. vertebra T3 = spinal segment T5)
- 4 **Spinous processes of caudal thoracic vertebrae** – segment + 3
- 5 **Vertebrae T10–T12** – lumbar segments L1–L4
- 6 **Vertebrae T12–L1 (epiconus)**
  - – lumbar and sacral segments L5–S2
- 7 **Vertebrae L1–L2 (conus)**
  - – sacral and single coccygeal segments S3–S5 and Co

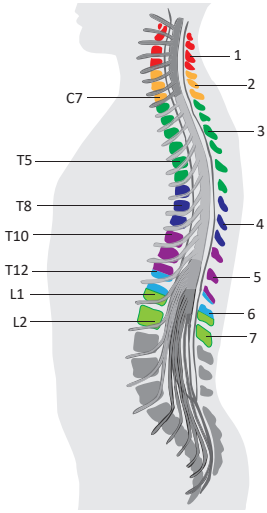

Vertebromedullary topography

Layers and spaces of the vertebral canal

Layers of the vertebral canal

- 1 **Vertebral periosteum** (*endorhachis*)
- 2 **Spinal dura mater** (*dura mater spinalis*)
- 3 **Spinal arachnoid mater** (*arachnoidea mater spinalis*)
- 4 **Spinal pia mater** (*pia mater spinalis*)

Spaces

- 5 **Epidural space** (*spatium epidurale*)
  - – is located between the periosteum and spinal dura mater
  - – consists of loose and adipose connective tissue and the internal venous vertebral plexus (*plexus venosi vertebrales interni*)
- 6 **Subdural space** (*spatium subdurale*)
  - – a potential space between the dura mater and arachnoid mater
- 7 **Subarachnoid/leptomeningeal space** (*spatium subarachnoideum*)
  - – is located between the arachnoid mater and pia mater
  - – is filled with cerebrospinal fluid (*liquor cerebrospinalis*)

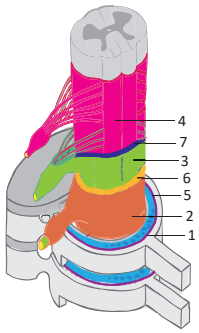

Layers and spaces of the vertebral canal

Myelos is the Greek term for the spinal cord.

The length of the spinal cord is 40 to 50 cm and its weight is almost 30 g.

The ascent of the spinal cord (*ascensus medullae spinalis*) is a term used for non-proportional growth of the vertebral column and spinal cord (see vertebromedullary rule and topography).

Segmental stratification is used for describing spinal nerves and nervous plexus (e.g. the brachial plexus is composed of the segments C5 to C8 with connection from the C4 and T1 segment)

Segments are not visible macroscopically.

The grey matter of the spinal cord is divided into three columns. The term "horn" is used to describe the two dimensional representation of a column.

The spinal cord is fixed within the vertebral canal by meninges, denticulate ligaments (extensions of pia mater), spinal nerves and the filum terminale.

Scheme of a spinal nerve see page 337.
Meninges see page 471.
Vascular supply of the spinal cord see page 476.
Vertebral column see page 568.

Clinical notes

Conus medullaris syndrome is caused by damage to the conus medullaris (S3-S5). It is manifested by a decrease or loss of sensation in a saddle-shape distribution (perianal, perigenital and inner femoral region), faecal and urinary incontinence and erectile dysfunction. The short flexors of the toes are affected, but this does not cause a noticeable loss of function.

Epiconus syndrome is caused by damage to the epiconus (L5 to S2). It is manifested by palsy and atrophy of the extensors of the foot and muscles of the leg. Extension and flexion of the foot becomes difficult or even impossible. Sensation is impaired in dermatomes L5 to S2. Bowel and bladder dysfunction can also sometimes occur.

Macroscopic appearance of the spinal cord

1 **Enlargements** (*intumescentia*)
– are located over the spinal segments which supply the plexuses for the limbs
- 1.1 **Cervical enlargement** (*intumescentia cervicalis*) C8–T2 – for the brachial plexus
- 1.2 **Lumbosacral enlargement** (*intumescentia lumbosacralis*) L4–S2
  – for the lumbar and sacral plexus

2 **Fissures** (*fissurae*) **and groove** (*sulci*) separate spinal cord fascicles
- 2.1 **Anterior median fissure** (*fissura mediana anterior*)
  – a ventrally situated deep fissure
- 2.2 **Anteriolateral (ventrolateral) sulcus** (*sulcus anterolateralis*)
  – for the centrifugal axons of motor and visceromotor neurons (*fila radicularia anteriora*)
- 2.3 **Posterolateral (dorsolateral) sulcus** (*sulcus posterolateralis*)
  – for the centripetal projections of pseudounipolar neurons of spinal ganglia (fila radicularia posteriora)
- 2.4 **Posterior intermediate sulcus** (*sulcus intermedius posterior*)
  – separates the gracile and cuneate fasciculi

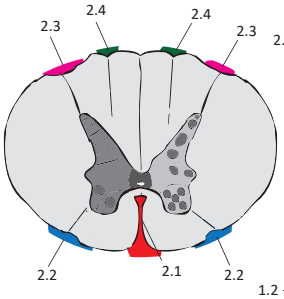

Cross-section

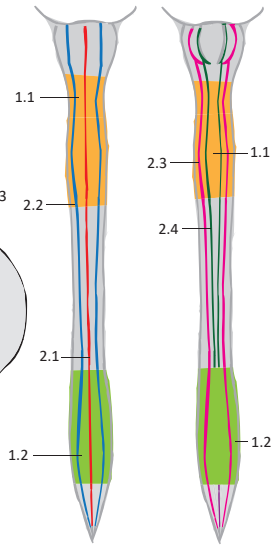

Anterior and posterior view

Spinal cord grey and white matter

1 **Grey substance** (*substantia grisea*)
- 1.1 **Anterior horn** (*cornu anterius*) – contains somatomotor neurones and interneurones
- 1.2 **Lateral horn** (*cornu laterale*) – contains visceromotor neurones and interneurones
- 1.3 **Posterior horn** (*cornu posterius*) – contains somatosensory neurones and interneurones
  - 1.3.1 **Apex** – the dorsal narrow part of the posterior horn
  - 1.3.2 **Head** – the centrally located wide part of the posterior horn
  - 1.3.3 **Neck** – the narrow part of the posterior horn located near the intermediate column
  - 1.3.4 **Base** – nearby the lateral horn
- 1.4 **Intermediate column** (*columna intermedia*)
  – contains viscerosensory neurones and interneurones
  – grey substance between the posterior and anterior horn
- 1.5 **Central zone** (*zona centralis*)
  – grey substance around the central canal
  – interconnects the right and left parts of the spinal cord
  - 1.5.1 **Anterior grey commissure** (*commissura grisea anterior*)
    – in front of the central canal
  - 1.5.2 **Posterior grey commissure** (*commissura grisea posterior*)
    – behind the central canal
- 1.6 **Columns** (*columnae*)
  - 1.6.1 **Anterior column** (*columna anterior*)
    – the three-dimensional (3D) projection of the anterior horn
  - 1.6.2 **Intermedial column** (*columna intermedia*) – 3D projection of the intermediate horn
  - 1.6.3 **Posterior column** (*columna posterior*) – 3D projection of the posterior horn

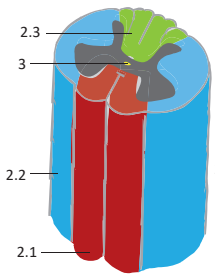

Anterolateral view

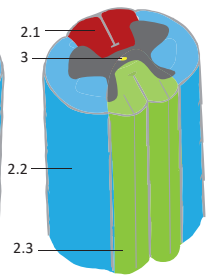

Posterolateral view

2 **White substance** (*substantia alba*)
– is divided by the course of the axons of the ventral and dorsal roots
- 2.1 **Anterior (ventral) funiculus** (*funiculus anterior*)
  – is located between the anterior median fissure and anterolateral sulcus
  – contains both motor and sensory tracts
- 2.2 **Lateral funiculus** (*funiculus lateralis*)
  – situated between the anterolateral and posterolateral sulcus
  – contains both motor and sensory tracts
- 2.3 **Posterior (dorsal) funiculus** (*funiculus posterior*)
  – is located between the posterolateral sulcus and posterior median sulcus
  – is divided by the posterior intermediate sulcus into:
  - 2.3.1 **Gracile fasciculus of Goll** (*fasciculus gracilis*)
  - 2.3.2 **Cuneate fasciculus of Burdach** (*fasciculus cuneatus*)
- 2.4 **Fasciculi proprii** – contains spino-spinal tracts
  – a bilateral connection of the spinal segments

3 **Central canal** (*canalis centralis*)
- 3.1 **Anterior white commissure** (*commissura alba anterior*)
  – in front of the central canal
- 3.2 **Posterior white commissure** (*commissura alba posterior*)
  – behind the central canal

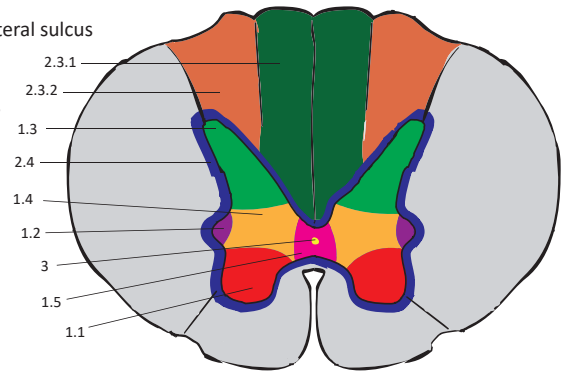

Cross-section

This copy belongs to ali yaghoubi

The grey matter of the spinal cord surrounds the central canal in a butterfly shape. It can be divided into a system of layers (**Rexed's laminae**) or into **individual nuclei**. **The white matter** of the spinal cord forms a system of **ascending, descending and associative tracts**, which enable communication between the spinal cord and higher levels of the CNS. The white matter is organised into three **funiculi** (anterior, lateral and posterior), which contain neuronal tracts (also known as fasciculi). The proportion of white to grey matter is different at different levels of the spinal cord. This is visible in cross-sections of the spinal cord.

Tracts in the spinal cord

Classification of spinal cord tracts according to their location within the spinal cord

1 **Posterior funiculus**
- 1.1 **Spinobulbar tract/fibres** (*tractus spinobulbaris*) – part of the medial lemniscus

2 **Anterior and lateral funiculus** (only ascending tracts are displayed)
- 2.1 **Anterior and lateral spinothalamic tract** (*tractus spinothalamicus anterior et lateralis*), **spinotectal tract** (*tractus spinotectalis*), **spinoreticular tract** (*tractus spinoreticularis*)
- 2.2 **Anterior spinocerebellar tract** (*tractus spinocerebellaris anterior*)
- 2.3 **Posterior spinocerebellar tract** (*tractus spinocerebellaris posterior*)
- 2.4 **Spino-olivary tract** (*tractus spinoolivaris*)

3 **Anterior and lateral funiculus** (only descending tracts are displayed)
- 3.1 **Corticospinal tract** (*tractus corticospinalis*)
  - 3.1.1 **Anterior corticospinal tract** (*tractus corticospinalis anterior*)
  - 3.1.2 **Lateral corticospinal tract** (*tractus corticospinalis lateralis*)
- 3.2 **Medial and lateral vestibulospinal tract** (*tractus vestibulospinalis medialis et lateralis*)
- 3.3 **Reticulospinal tract** (*tractus reticulospinalis*)
- 3.4 **Tectospinal tract** (*tractus tectospinalis*)
- 3.5 **Rubrospinal tract** (*tractus rubrospinalis*)
- 3.6 **Interstitiospinal tract** (*tractus interstitiospinalis*)
- 3.7 **Raphespinal tract** (*tractus raphespinalis*)

Classification of spinal cord tracts according to the direction of impulse transmission

- 4 **Ascending tracts**
- 5 **Descending tracts**

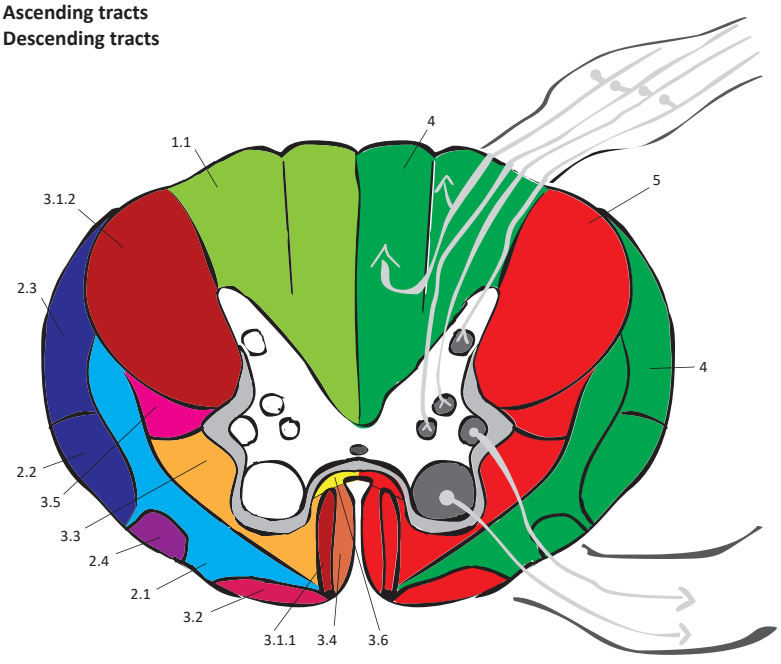

Cross-section

The endogenous analgesic system modifies perception of pain. Laminae II and III modulate afferent pain signals. Endogenous opioids and their receptors are essential for this function. The reticular formation is able to increase or decrease pain perception through its projections to the interneurons of laminae II and III of the spinal cord.

The cervical spinal cord contains two additional motor nuclei and one sensory nucleus.

The nucleus of phrenic nerve (phrenic nucleus; nucleus nervi phrenici) is located between C3 to C5. Its axons innervate the diaphragm.

The nucleus of accessory nerve (*nucleus nervi accessorii*) is located between C2 to C4. Its axons form the spinal root of the accessory nerve (radix spinalis nervi accessorii).

The spinal nucleus of trigeminal nerve (*nucleus spinalis nervi trigemini*) extends from the pons to C2. It is a somatosensory nucleus for pain and thermal sensation of the head. Somatosensory information from cranial nerves V, IX and X reach this nucleus. Afferent fibres reach the spinal nucleus of the trigeminal nerve through the spinal tract of the trigeminal nerve, which lies alongside and medial to the nucleus.

The anterolateral funiculus is a common term for the anterior and lateral funiculi.

The anterior horn consists of anterolateral, posterolateral, anteromedial, postermedial and central nuclei.

Beta motor neurons innervate both intrafusal and extrafusal muscle spindles. Their existence in humans is disputed.

Clinical notes

Spinal cord stimulation is a procedure used to relive chronic pain. Electrodes are inserted into the epidural space and mild electric currents are used to stimulate the spinal cord.

Spinal nuclei

1 **Posterior horn** – somatosensory nuclei
- 1.1 **Marginal nucleus** (*nucleus marginalis/apicalis*) – consists of interneurones, which modulate afferent information
- 1.2 **Central gelatinous substance** (*substantia gelatinosa Rolandi*) – consists of interneurones, which modulate afferent information
- 1.3 **Nucleus proprius** – the location of the first synapse of the neurones of the anterolateral system
  – neurones modulate afferent information as pain, gross skin sensation and thermal information
  – the axons of the 2nd order neurones cross to the contralateral side and ascend to the thalamus (spinothalamic tract), to the reticular formation (spinoreticular tract) and tectum of midbrain (spinotectal tract)
- 1.4 **Posterior thoracic nucleus** (*nucleus thoracicus posterior of Stilling-Clarke*)
  – the neurons where the first proprioceptive neurons connect with the 2nd neuron, information comes from the lower limb and caudal part of the trunk
  – the nucleus is situated in the segments C8 to L3, the axons of the 2nd neurons ascend to the cerebellum (spinocerebellar tracts)

2 **Zona intermedia** – viscerosensory area
- 2.1 **Intermediomedial nucleus** (*nucleus intermediomedialis*)
  – the neurons where the first viscerosensory neurons connect with the 2nd neuron (visceral wall tension, mechanical, thermal, chemical and pain stimuli from the viscera)

3 **Lateral horn** – visceromotor nuclei
- 3.1 **Intermediolateral nucleus** (*nucleus intermediolateralis*)
  – preganglionic sympathetic fibers in the C8 to L3 segments
  – preganglionic parasympathetic fibres in the S2 to S4 segments

4 **Anterior horn** – somatomotor neurons
- 4.1 **Motor nuclei**
  – alpha motor neurons (alpha motoneurons) for extrafusal muscular fibers
  – gamma motor neurons (gamma motoneurons) for intrafusal fibers of muscle spindle

Rexed´s laminae and corresponding nuclei

- **Lamina I** – apical nucleus
  – pain (nociception) and thermal sensation
- **Lamina II and III** – gelatinous substance
  – consists of small groups of neurones
- **Lamina IV + V (VI)** – nucleus proprius
  – integrates somatosensory information
  – the origin of the spinothalamic, spinoreticular and spinotectal tracts
- **Lamina VI** – posterior thoracic nucleus (C8 to L3)
  – a proprioceptive nucleus at the base of the posterior horn
  – the origin of the spinocerebellar tracts
- **Lamina VII** – contains interneurones of the zona intermedia, intermediomedial nucleus, intermediolateral nucleus and part of the posterior thoracic nucleus
- **Lamina VIII** – the medial group of motor neurones and interneurones for the muscles of the trunk and proximal limbs
- **Lamina IX** – the lateral group of motor neurones and interneurones and motor interneurons for the muscles of the limbs
- **Lamina X** – zona centralis

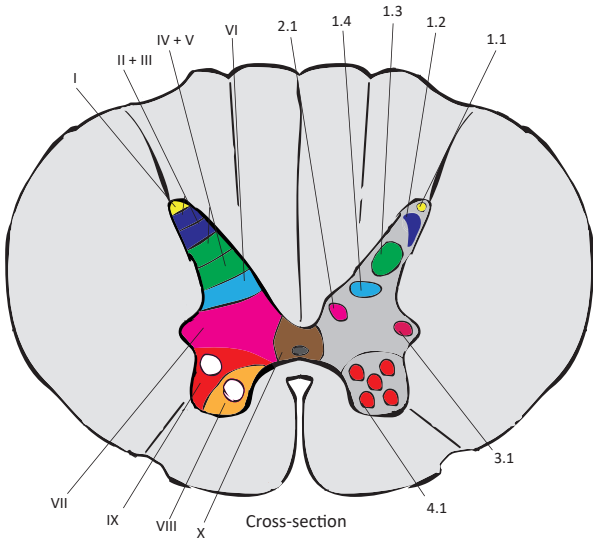

Cross-section

Distribution of grey and white matter in the spinal cord

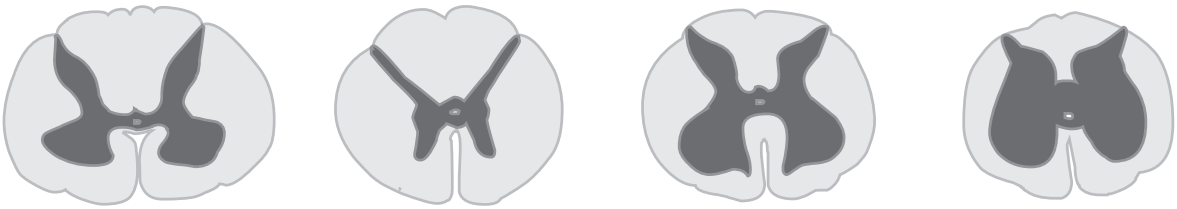
Cervical segment | Thoracic segment | Lumbar segment | Sacral segment

This copy belongs to ali yaghoubi

The brainstem **connects the spinal cord to the diencephalon**. **Its ventral surface is in contact with the clivus** of the occipital bone. Dorsally, it is **connected to the cerebellum via the three pairs of cerebellar peduncles**. **The fourth ventricle lies between the brainstem and the cerebellum.** Macroscopically, the brainstem is divided into **three parts:** medulla oblongata, pons and the midbrain. The brainstem contains **nuclei of the cranial nerves, nervous tracts and the reticular formation**, which contains the **cardiorespiratory centres** and is responsible for several phylogenetically old reflexes.

Classification

- 1 **Medulla oblongata** – extends from the decussation of the pyramids to the medullopontine sulcus
- 2 **Pons** – extends from the medullopontine sulcus to the caudal margin of the interpeduncular fossa
- 3 **Mesencephalon** – extends from the caudal margin of the interpeduncular fossa to the dorsal margin of the mammilary bodies

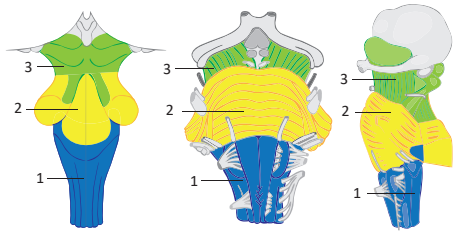

Structures and function

1 **Nuclei of the 10 cranial nerves** – important structures of interconnections and cranial nerves reflexes (role of the reticular formation)
2 **Motor nuclei of the extrapyramidal system** – responsible for motor functions
3 **Special sensory nuclei** – visual, auditory, gustatory and vestibular
4 **Reticular formation** – responsible for brainstem reflexes
– containing centers of vital reflexes (centre for cardiovascular reflexes, blood pressure monitoring, ventilation and autonomic system control)
– some nuclei are connected to afferent and efferent systems
5 **Afferent somatosensory and special sensory tracts** – pass through the brainstem
– important for interconnection between the spinal cord, subcortical structures and cortex
6 **Efferent motor tracts** – tracts of the extrapyramidal system
– tracts from the cortex (corticospinal tract and corticonuclear tracts)
7 **Afferent and efferent tracts of the cerebellum**
– connect the cerebellum to the rest of the CNS

External features – ventral surface

- 1 **Decussation of pyramids / motor decussation** (*decussatio pyramidum*)
- 2 **Inferior olive** (*oliva*)
  - 2.1 **Pre-olivary groove** (*sulcus preolivaris*)
  - 2.2 **Retro-olivary groove** (*sulcus retroolivaris*)
- 3 **Medullopontine sulcus** (*sulcus bulbopontinus*)
- 4 **Cerebellar peduncles** (*pedunculi cerebellares*)
  - 4.1 **Inferior cerebellar peduncle** (*pedunculus cerebellaris inferior*)
  - 4.2 **Middle cerebellar peduncle** (*pedunculus cerebellaris medius*)
  - 4.3 **Superior cerebellar peduncle** (*pedunculus cerebellaris superior*)
- 5 **Basilar sulcus** (*sulcus basilaris*)
- 6 **Cerebral crura** (*crura cerebri*)
- 7 **Exits of the cranial nerves**
  - III **Oculomotor nerve** (*n. oculomotorius*)
  - IV **Trochlear nerve** (*n. trochlearis*)
  - V **Trigmeninal nerve** (*n. trigeminus*)
  - VI **Abducent nerve** (*n. abducens*)
  - VII **Facial nerve** (*n. facialis*)
  - VIII **Vestibulocochlear nerve** (*n. vestibulocochlearis*)
  - IX **Glossopharyngeal nerve** (*n. glossopharyngeus*)
  - X **Vagus nerve** (*n. vagus*)
  - XI **Accessory nerve** (*n. accessorius*)
  - XII **Hypoglossal nerve** (*n. hypoglossus*)

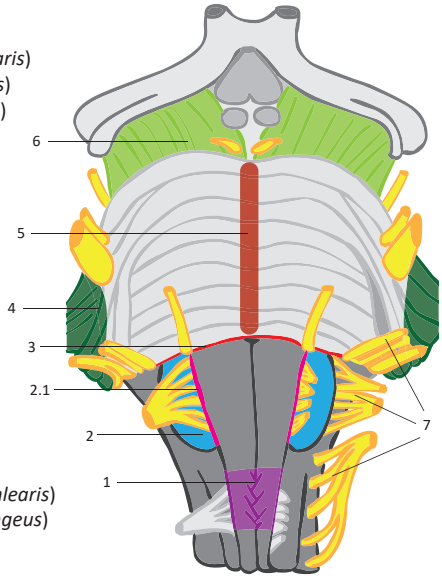

Anterior view of the brainstem

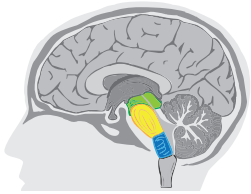

Dorsally, the pons and the rostral part of the medulla oblongata form a slight depression called the rhomboid fossa. The rhomboid fossa is the floor of the fourth ventricle. The neural tube failed to close completely at the rhomboid fossa and thus, the structures of the original basal and alar plates remain separated by the sulcus limitans. The basal plate forms the medial eminence under which motor nuclei are located. The alar plate is separated by the sulcus limitans and contains the somatosensory and special sensory nuclei.

The rhomboid fossa (*fossa rhomboidea*) maintains its original arrangement. The basal plate forms the medial eminence under which motor nuclei are situated. The alar plate is separated by the sulcus limitans and forms a base for somatosensory and special sensory nuclei.

The branchiomotor nucleus of the facial nerve is shifted ventrolaterally and its fibers form a loop around the abducens nucleus called the internal genu of the facial nerve (crus internum nervi facialis). These fibres form an elevation in the rhomboid fossa called the colliculus facialis. Axons leaving the other branchiomotor nuclei (n. V, IX and X) also form loops, but these loops run around their respective nuclei and do not form elevations on the surface of the brainstem.

External structure

- 1 **Rhomboid fossa** (*fossa rhomboidea*) – the floor of the fourth ventricle
  – the cerebellum is situated dorsally
  2 **Dorsal surface of the brainstem**
  - 2.1 **Superior colliculus** (*colliculus superior*)
  - 2.2 **Inferior colliculus** (*colliculus inferior*)
  - 2.3 **Exit of the trochlear nerve**
  - 2.4 **Cuneate tubercle** (*tuberculum cuneatum*)
  - 2.5 **Gracile tubercle** (*tuberculum gracile*)
  - 2.6 **Trigeminal tubercle** (*tuberculum trigeminale*)

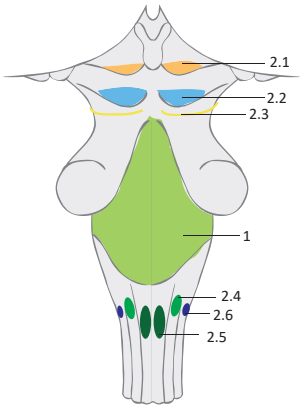

External structure of the brainstem, posterior view

Rhomboid fossa

Topography

- 1 **Rhomboid fossa**
- 2 **Dorsally:** the cerebellum together with the choroid membrane (*tela choroidea*) forms the roof of the fourth ventricle
- 3 **Rostrally:** communicates with the third ventricle through the aqueduct of the midbrain
- 4 **Caudally:** the central canal of the spinal cord
  5 **Laterally:** a narrow recess that extends laterally from the rhomboid fossa along side the interior cerebellar peduncle

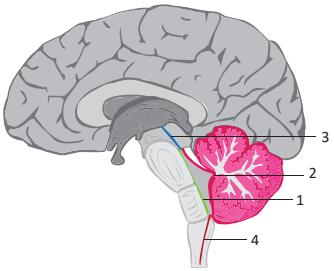

Topography of the rhomboid fossa, sagittal section of the brain

Anatomical structures

- 1 **Median sulcus** (*sulcus medianus*)
  – a groove in the middle of the rhomboid fossa
  – connects the central canal with the aqueduct of the midbrain
  - 1.1 **Medial eminence** (*eminentia medialis*)
    – is located lateral to the median sulcus
    – the motor nuclei of the brainstem are situated underneath it
- 2 **Sulcus limitans** – a groove located lateral to the median eminence
  – forms the border between the basal and alar plates
- 3 **Facial colliculus** (*colliculus facialis*) – an elevation made by fibres leaving the facial nucleus as they loop around the abducens nucleus
- 4 **Vestibular area** (*area vestibularis*) – is located lateral to the sulcus limitans
  – the vestibular nuclei are situated underneath it
  4.1 **Acoustic tubercle** (*tuberculum acusticum*)
  – a small tubercle in the area of the lateral recess
  – the acoustic nuclei are located underneath it
- 5 **Medullary stria of fourth ventricle** (*striae medullares ventriculi quarti*)
  – are composed of myelinated fibres that connect the pons and cerebellum entering the inferior cerebellar peduncle
- 6 **Hypoglossal trigone** (*trigonum nervi hypoglossi*)
  – an area where the nucleus of the N. XII is situated
- 7 **Vagal trigone** (*trigonum nervi vagi*) – an area where the vagal part of the nucleus ambiguus is situated
- 8 **Inferior fovea** (*fovea inferior*) – the parasympathetic nuclei of the N. X are situated under this depression
- 9 **Locus caeruleus** – a small bluish area
  – cells producing norepinephrine are situated under it
  10 **Cerebellar peduncles** (*pedunculi cerebellares*) – paired cerebellar connections
  - 10.1 **Inferior cerebellar peduncle** (*pedunculus cerebellaris inferior*)
    – connects the oblongata and cerebellum
  - 10.2 **Middle cerebellar peduncle** (*pedunculus cerebellaris medius*)
    – connects the pons and cerebellum
  - 10.3 **Superior cerebellar peduncle** (*pedunculus cerebellaris superior*)
    – connects the midbrain and cerebellum
- 11 **Funiculus separans** – separates the area postrema (one of circumventricular organs)
- 12 **Grey line** (*taenie cinerea*) – a greyish strip visible after dissection of the inferior medullary vellum
- 13 **Obex** – the point where the central canal opens into the fourth ventricle
  14 **Inferior and superior medullary vella** (*velum medullare inferius et superius*)
  – form the roof of the fourth ventricle

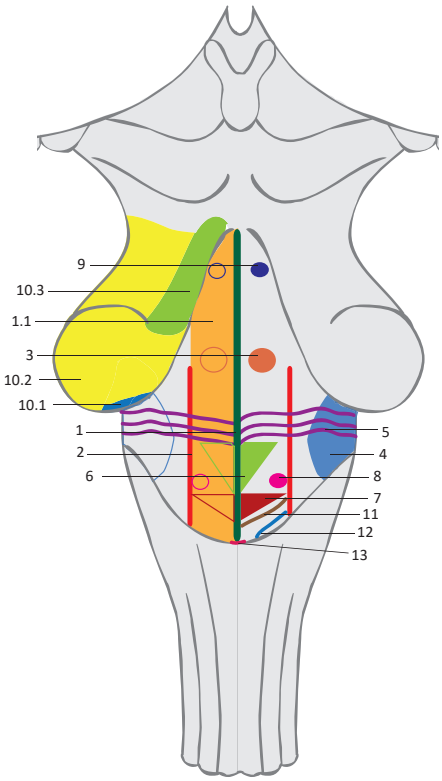

Anatomical structures of the rhomboid fossa, posterior view to the brainstem

This copy belongs to ali yaghoubi

The medulla oblongata is the caudal most part of the brainstem. The central canal expands rostrally into the medulla oblongata to form the fourth ventricle. The grey matter of the medulla oblongata **contains the nuclei of the cranial nerves (n. V, IX, X, XI and XII)** as well as several **other nuclei including the gracile and cuneate nuclei and the inferior olivary complex.** The medullary reticular formation contains the **centres for blood pressure and circulation control (the vasomotor centre), cardiac centres, breathing centres and centres for cranial nerves reflexes.**

External features

- 1 **Pyramid** (*pyramis medullae oblongatae*)
  – a paired elevation of the medulla oblongata containing the corticospinal tract
  - 1.1 **Decussation of pyramids / motor decussation** (*decussatio pyramidum*) – the site where the fibres of the corticospinal tract cross to the opposite side
- 2 **Ventral median fissure** (*fissura mediana anterior*)
- 3 **Inferior olive** (*oliva*) – a paired elevation on the ventral surface of the medulla oblongata formed by the the inferior olivary complex
  - 3.1 **Pre-olivary groove** (*sulcus preolivaris*) – a groove in front of the inferior olive, the exit of the n. XII
  - 3.2 **Retro-olivary groove** (*sulcus retroolivaris*)
    – a groove behind the inferior olive, the exit of the n. IX, X and XI
- 4 **Medullopontine sulcus** (*sulcus bulbopontinus*) – a transverse groove between the medulla oblongata and pons
  – the exit of the n. VI
- 5 **Inferior cerebellar peduncle** (*pedunculus cerebellaris inferior*)
  – consists of the restiform and juxtarestiform body
  – connects the medulla oblongata to the cerebellum
  – contains the afferent and efferent tracts of the cerebellum
- 6 **Rhomboid fossa** (*fossa rhomboidea*) – together with the pons forms the rhomboid-shaped floor of the fourth ventricle
- 7 **Gracile tubercle** (*tuberculum gracile*) – the medial tubercle on the dorsal surface is formed by the gracile nucleus
- 8 **Cuneate tubercle** (*tuberculum cuneatum*) – the lateral tubercle on the dorsal surface is formed by the cuneate nucleus
- 9 **Trigeminal tubercle** (*tuberculum trigeminale*)
  – a tubercle on the lateral surface is formed by the spinal nucleus and tract of trigeminal nerve

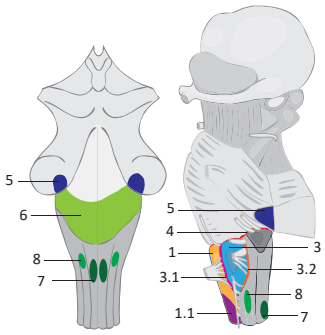

Posterior and lateral view

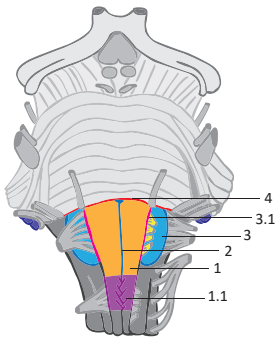

Anterior view

Internal features

At the level of the deccusation of pyramids

- 1 **Central canal** (*canalis centralis*)
- 2 **Grey matter** (*substantia grisea*)
- 3 **Reticular formation** (*formatio reticularis*)
- 4 **White matter** (*substantia alba*)
  - 4.1 **Posterior funiculus** (*funiculus posterior*)
  - 4.2 **Laterali funiculus** (*funiculus lateralis*)
  - 4.3 **Anterior funiculus** (*funiculus anterior*)
    - 4.3.1 **Pyramids** (*pyramides medullae oblongatae*)

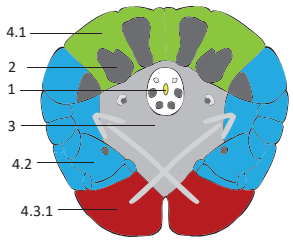

Cross-section of the medulla oblongata

At the level of the inferior olive

- 1 **Fourth ventricle** (*ventriculus quartus*)
- 2 **Grey matter** (*substantia grisea*)
- 3 **Reticular formation** (*formatio reticularis*)
- 4 **White matter** (*substantia alba*)
  - 4.1 **Inferior cerebellar peduncles** (*pedunculi cerebellares inferiors*)
  - 4.2 **Pyramids** (*pyramides medullae oblongatae*)

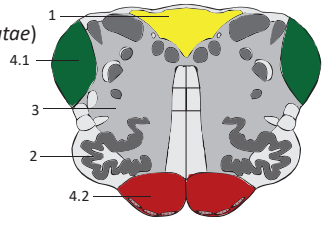

Cross-section of the medulla oblongata

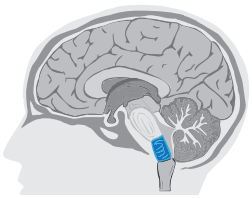

The bulb of the spinal cord and myelencephalon are synonyms for the medulla oblongata. Nuclei situated here are referred to as bulbar nuclei.

The posterior cerebellomedullary cistern (*cisterna magna*) is located dorsal and the pontomedullary cistern is located ventral to the medulla oblongata.

The decussation of the medial lemniscus (*decussatio lemnisci medialis*), also known as the sensory decussation, is the crossing of axons of the spino-bulbo-thalamo-cortical tract after they synapse in the gracile and cuneate nuclei.

The arcuate nuclei (*nuclei arcuati*) are analogues of the pontine nuclei situated in the caudal part of the medulla oblongata at the level of the inferior olive. They are afferent nuclei of the cerebellum. On the surface of the brainstem, the fibres leaving the arcuate nuclei are visible as the anterior external arcuate fibres. They enter the cerebellum as mossy fibres.

The inferior olivary complex (*complexus olivaris inferior*) contains the inferior, posterior and accessory olivary nuclei.

Clinical notes

Lateral medullary syndrome (Wallenberg´s syndrome) is group of symptoms that can result from occlusion of the posterior inferior cerebellar artery (PICA). The symptoms correspond to the affected nuclei.

- **Nucleus ambiguus** (ipsilateral dysphagia and dysartria)
- **Spinal nucleus and tract of trigeminal nerve** (ipsilateral analgesia and thermoanaesthesia of the head)
- **Vestibular nuclei** (vertigo, nausea, vomiting and nystagmus)
- **Descending sympathetic fibers** (ipsilateral Horner´s syndrome – ptosis, miosis, enophtalmus, anhidrosis of forehead)
- **Cerebellum** (ataxia)
- **Spinothalamic tract** (contralateral analgesia and thermoanaesthesia of the body)

Cross-section at the level of the decussation of the pyramids (nuclei and tracts)

1 **Nuclei of the cranial nerves**
- 1.1 Nucleus of hypoglossal nerve
- 1.2 Posterior nucleus of vagus nerve
- 1.3 Spinal nucleus of trigeminal nerve
- 1.4 Nucleus ambiguus
- 1.5 Nuclei of solitary tract / solitary nuclei

2 **Specific nuclei of the brainstem**
- 2.1 Gracile nucleus
- 2.2 Cuneate nucleus

3 **Cranial nerves tracts**
- 3.1 Spinal tract of trigeminal nerve
- 3.2 Solitary tract

4 **Proper tracts of the brainstem**
- 4.1 Medial longitudinal fasciculus
- 4.2 Posterior (dorsal) longitudinal fasciculus

5 **Ascending tracts**
- 5.1 Medial lemniscus
- 5.2 Spinal lemniscus (comprising the spinothalamic, spinoreticular and spinotectal tract)
- 5.3 Spino-olivary tract
- 5.4 Anterior and posterior spinocerebellar tract

6 **Descending tracts**
- 6.1 Corticospinal tract
  6.2 Corticonuclear tract
- 6.3 Reticulospinal tract
- 6.4 Medial and lateral vestibulospinal tract
- 6.5 Tectospinal tract
- 6.6 Rubrospinal tract

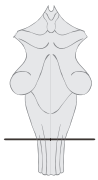

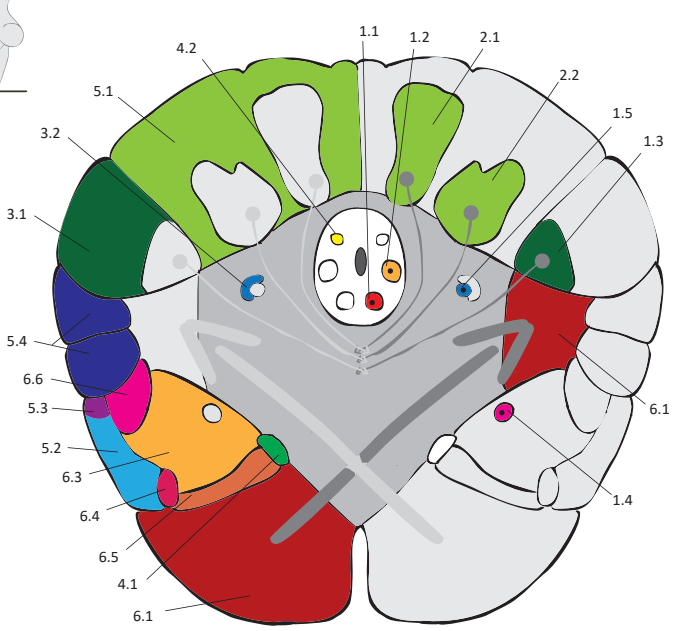

On the left side the tracts are illustrated, on the right side nuclei

Rostral cross-section at the level of the inferior olive (nuclei and tracts)

1 **Nuclei of the cranial nerves**
- 1.1 Nucleus of hypoglossal nerve
- 1.2 Posterior (dorsal) nucleus of vagus nerve
- 1.3 Vestibular nuclei
- 1.4 Spinal nucleus of trigeminal nerve
- 1.5 Nucleus ambiguus
- 1.6 Nuclei of solitary tract / solitary nuclei

2 **Specific nuclei of the brainstem**
- 2.1 Inferior olivary complex
  2.2 Arcuate nuclei
- 2.3 Accessory cuneate nucleus

3 **Tracts of the cranial nerves nuclei**
- 3.1 Spinal tract of trigeminal nerve
- 3.2 Solitary tract

4 **Proper tracts of the brainstem**
- 4.1 Medial longitudinal fasciculus
- 4.2 Posterior (dorsal) longitudinal fasciculus

5 **Ascending tracts**
- 5.1 Medial lemniscus
- 5.2 Spinal lemniscus (comprising the spinothalamic, spinoreticular and spinotectal tract)
- 5.3 Anterior and posterior spinocerebellar tract

6 **Descending tracts**
- 6.1 Corticospinal tract
  6.2 Corticonuclear tract
  6.3 Reticulospinal tract
- 6.4 Medial and lateral vestibulospinal tract
- 6.5 Tectospinal tract
- 6.6 Rubrospinal tract

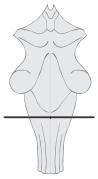

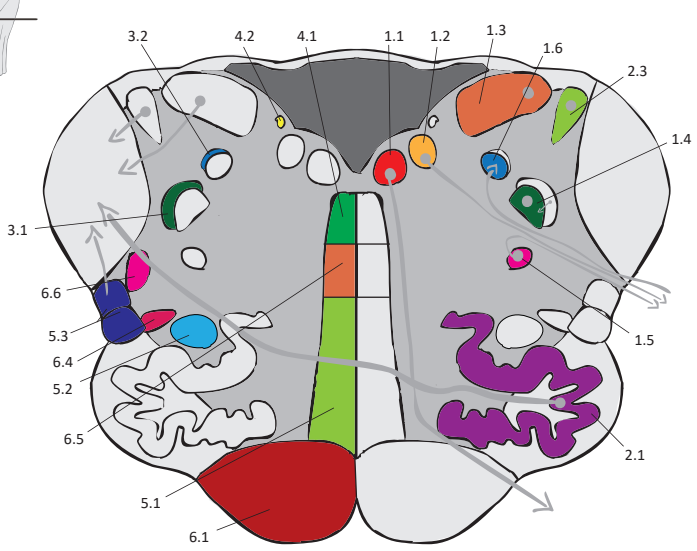

On the left side the tracts are illustrated, on the right side nuclei

This copy belongs to ali yaghoubi

The pons is the widest part of the brainstem. It is continuous caudally with the medulla oblongata and rostrally with the midbrain. Its caudal part forms part of the floor of the fourth ventricle. Its grey matter c**ontains the nuclei of the cranial nerves (n. V, VI, VII, VIII), the superior olivary nucleus and the pontine nuclei**. The **breathing centres** are located in the pontine reticular formation.

External features

- 1 **Bulbopontine sulcus** (*sulcus bulbopontinus*)
  - – marks the transition between the medulla oblongata and the pons
  - – n. VI emerges from the brainstem
- 2 **Middle cerebellar peduncles** (*pedunculi cerebellares medii*)
  - – connect the pons and cerebellum
  - – form the lateral borders of the pons
  - – contain the afferent pontocerebellar tracts
- 3 **Rhomboid fossa** (*fossa rhomboidea*)
  - – is on the dorsal surface of the pons
  - – together with the medulla oblongata, forms the floor of the fourth ventricle
- 4 **Facial colliculus** (*colliculus facialis*)
  - – a little eminence formed by the nucleus of the facial nerve and its fibres as they loop around the abducens nerve
- 5 **Basilar sulcus** (*sulcus basilaris*)
  - – a groove on the ventral surface of the pons containing the basilar artery
- 6 **Pontocerebellar angle** (*angulus pontocerebellaris*)
  - – contains the facial and vestibulocochlear nerves as they emerge from the brainstem
- 7 **Trigeminofacial line** (*linea trigeminofacialis of Henle*)
  - – an arbitrary borderline between nerves V and VII, which separates the pons from the cerebellum

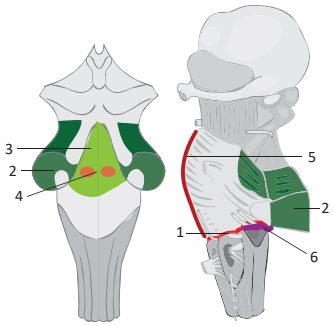

Posterior and lateral view

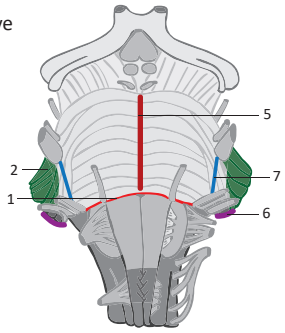

Anterior view

Development classification

- 1 **Basilar part of pons** (*pars basilaris pontis*)
  - – the evolutionary younger ventral part which contains the pontine nuclei and motor tracts (*fibrae pontis*)
- 2 **Tegmentum of pons** (*tegmentum pontis*)
  - – the older dorsal part close to the floor of the fourth ventricle
  - – contains the nuclei of the cranial nerves, reticular formation, ascending tracts, descending extrapyramidal tracts and special brainstem tracts

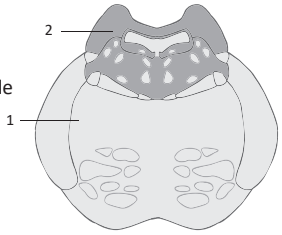

Cross-section of the pons

Internal features

- 1 **Fourth ventricle** (*ventriculus quartus*)
- 2 **Grey substance** (*substantia grisea*)
- 3 **Reticular formation** (*formatio reticularis*)
- 4 **White substance** (*substantia alba*)
  - 4.1 **Transverse pontine fibers** (*fibrae pontis transversae*)
    - – the transversal pontocerebellar tracts which form crosswise stripes in the basilar part of the pons
    - – they originate in the pontine nuclei and they continue through the middle cerebellar peduncles
  - 4.2 **Middle cerebellar peduncles** (*pedunculi cerebellares medii*)
  - 4.3 **Longitudinal pontine fibers** (*fibrae pontis longitudinales*)
    - – consist of the corticospinal tract as it passes through the pontine nuclei

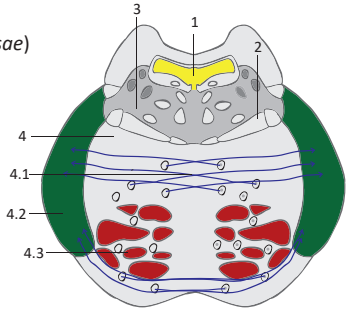

Cross-section of the pons

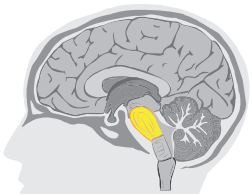

Pons Varoli is an obsolete eponym for the pons.

The trapezoid body (*corpus trapezoideum*) is formed by the axons of the anterior cochlear nucleus as they cross the midline. It contains small dispersed nuclei (*nuclei corporis trapezoidei*). After decussating, the axons of the anterior cochlear nucleus join the lateral lemniscus.

The superior olivary nucleus (*nucleus olivaris superior*) is associated with the auditory tract. The trapezoid body inhibits the contralateral superior olivary nucleus. These nuclei are involved in sound localization based on the synaptic delay.

The centre for horizontal gaze is located in the pons. The centre for vertical gaze is located more rostral, in the midbrain.

Clinical notes

Persistent vegetative state (formerly known as apallic syndrome and coma vigile) is a condition in which a patient is not able to react to external stimuli or make voluntary movements. Reflexes are usually intact, as is the sleep-wake cycle. The patient is in a state of non-awareness, but is able to breathe without support. The vegetative state is a result of extensive damage to the cortex and connections to subcortical nuclei or extensive bilateral damage of the thalami.

Caudal cross-section at the level of the colliculus facialis (nuclei and tracts)

1 **Nuclei of the cranial nerves**
- 1.1 Nucleus of facial nerve
- 1.2 Nucleus of abducens nerve
- 1.3 Vestibular nuclei
- 1.4 Cochlear nuclei
- 1.5 Spinal nucleus of trigeminal nerve
- 1.6 Superior salivatory nucleus
- 1.7 Nuclei of solitary tract / solitary nuclei

2 **Specific nuclei of the brainstem**
- 2.1 Superior olivary nucleus
- 2.2 Pontine nuclei

3 **Tracts of the cranial nerves nuclei**
- 3.1 Spinal tract of trigeminal nerve
- 3.2 Solitary tract

4 **Proper tracts of the brainstem**
- 4.1 Medial longitudinal fasciculus
- 4.2 Tegmental central tract
- 4.3 Pontocerebellar tract
- 4.4 Posterior (dorsal) longitudinal fasciculus
- 4.5 Vestibulocerebellar tract
- 4.6 Lateral lemniscus

5 **Ascending tracts**
- 5.1 Medial lemniscus
- 5.2 Spinal lemniscus (comprising the spinothalamic, spinoreticular and spinotectal tract)
- 5.3 Anterior spinocerebellar tract

6 **Descending tracts**
- 6.1 Corticospinal tract
- 6.2 Corticonuclear tract
- 6.3 Reticulospinal tract
- 6.4 Vestibulospinal tract
- 6.5 Tectospinal tract
- 6.6 Rubrospinal tract

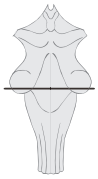

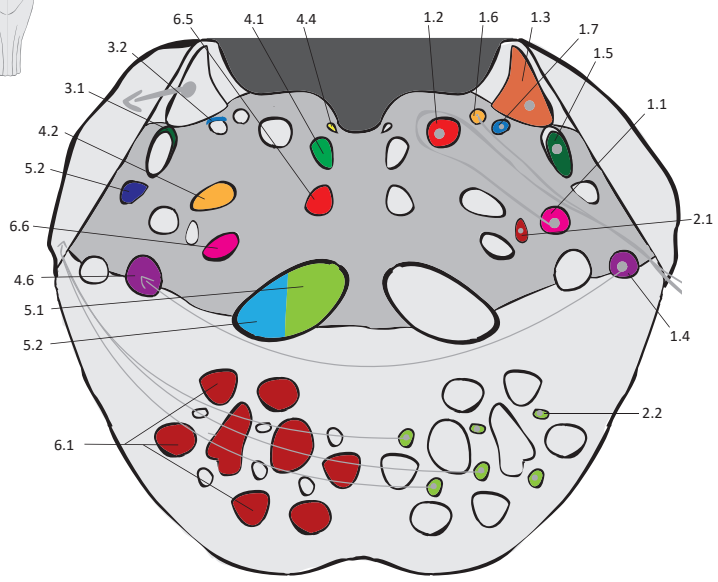

On the left side the tracts are illustrated, on the right side nuclei

Rostral cross-section at the level of the trigeminal motor nucleus

1 **Nuclei of the cranial nerves**
- 1.1 Mesencephalic nucleus of trigeminal nerve
- 1.2 Motorius nucleus of trigeminal nerve
- 1.3 Principal nucleus of trigeminal nerve

2 **Specific nuclei of the brainstem**
- 2.1 Pontine nuclei

3 **Tracts of the cranial nerves nuclei**
- 3.1 Solitary tract

4 **Proper tracts of the brainstem**
- 4.1 Medial longitudinal fasciculus
- 4.2 Posterior (dorsal) longitudinal fasciculus
- 4.3 Tegmental central tract
- 4.4 Lateral lemniscus

5 **Ascending tracts**
- 5.1 Medial lemniscus
- 5.2 Spinal lemniscus (comprising the spinothalamic, spinoreticular and spinotectal tract)
- 5.3 Anterior spinocerebellar tract

6 **Descending tracts**
- 6.1 Corticospinal tract
- 6.2 Corticonuclear tract
- 6.3 Reticulospinal tract
- 6.4 Tectospinal tract
- 6.5 Rubrospinal tract

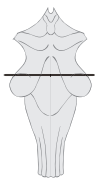

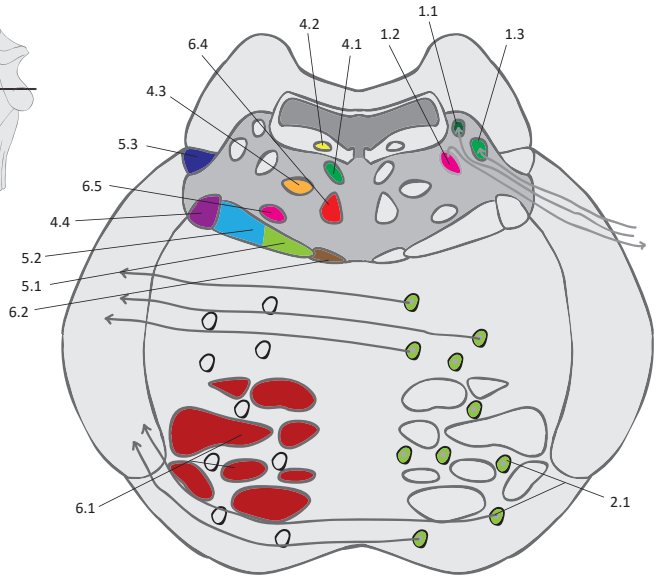

On the left side the tracts are illustrated, on the right side nuclei

This copy belongs to ali yaghoubi

The mesencephalon is situated between the pons and the diencephalon. Macroscopically, it is divided into **the tectum** of midbrain, **tegmentum** of midbrain and **cerebral crura**. The substantia nigra is situated between the tegmentum and crura. **The aqueduct of the midbrain** (cerebral aqueduct of Sylvius), which connects the third and fourth ventricles, is located in the tegmentum. The cerebral crura connect the midbrain to the cerebral hemispheres. The grey matter of the midbrain contains **cranial nerve nuclei (n. III, IV), red nucleus, substantia nigra, interpeduncular nucleus, periaqueductal grey substance, interstitial nucleus of Cajal, elliptic nucleus of Darkschewitsch, nuclei of inferior colliculus and pretectal nuclei**. The midbrain is responsible for reflex movements of the eyes, head and body in the direction of visual and auditory stimuli. The mesencephalic reticular formation processes slow pain and autonomic projections from the hypothalamus.

External and internal features

- 1 **Tectum of midbrain** (*tectum mesencephali*)
  - – the dorsal part of the midbrain
  - – formed by the superior and inferior colliculi
  - 1.1 **Superior colliculus** (*colliculus superior*)
    - – a division of the visual pathway enters into the layers lying under this structure
    - – consists of seven layers of grey and white matter (*laminae*), which have a retinotopic organisation
    - – responsible for the rapid eye movement phase of sleep
    - – its function is associated with rapid and controlled eye movement
    - – the brachium of superior colliculus connects the superior colliculus with the lateral geniculate body
  - 1.2 **Inferior colliculus** (*colliculus inferior*)
    - – the third order neurones of the auditory pathway are located here
    - – contains three nuclei with tonotopic organization
    - – the brachium of colliculus inferior connects the inferior colliculus with the medial geniculate body
- 2 **Tegmentum of midbrain** (*tegmentum mesencephali*)
  - 2.1 **Aqueduct of midbrain** (*aqueductuc mesencephali Sylvii*)
  - 2.2 **Periaqueductal grey substance** (PAG; *substantia grisea centralis*)
  - 2.3 **Reticular formation** (*formatio reticularis*)
  - 2.4 **Nuclei and tracts of the cranial nerves**
  - 2.5 **Specific nuclei and tracts of the brainstem**
    - 2.5.1 **Posterior tegmental deccusation** (*decussatio tegmentalis posterior*)
      - – a crossing of the tectospinal tract
    - 2.5.2 **Anterior tegmental deccusation** (*decussatio tegmentalis anterior*)
      - – a crossing of the rubrospinal tract
  - 2.6 **Superior cerebellar peduncles** (*pedunculi cerebellares superiores*) – connect the midbrain and cerebellum, contain afferent and efferent cerebellar tracts
- 3 **Cerebral crus** (*crus cerebri/mesencephali*) – the ventral paired part containing descending tracts
- 4 **Pretectal area** (*area pretectalis*) – a group of four small nuclei in front of the lateral border of the superior colliculus, situated at the borderline between the midbrain and epithalamus

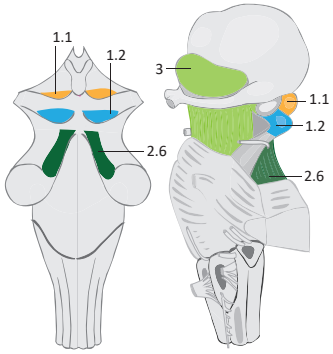

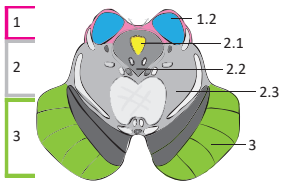

Cross-section at the level of the inferior colliculus

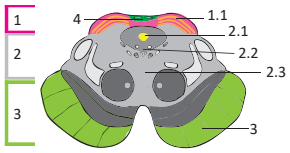

Cross-section at the level of the superior colliculus

Topography

1 **Ventrally:** interpeduncular fossa, posterior perforated substance, interpeduncular cistern and terminal division of basilar artery into the posterior cerebellar arteries
2 **Dorsally:** pineal gland, quadrigeminal cistern, great cerebral vein and the exit of the n. IV
3 **Laterally:** ambient cistern, n. IV and basal vein

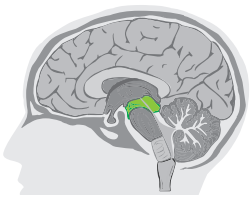

Tectum is the Latin word for shield. **Tegmentum** is the Latin word for roof frame and **crus** is the Latin word for stalk.

The term basis pedunculi is used for the cerebral crus and substantia nigra together.

The tectum of midbrain is the centre of the visual and auditory reflexes. It consists of a series of laminae and nuclei where a visual and auditory information is processed on a subconscious level.

The role of the tectum is described in the following example:
Flashing lights (visual information) and the sound of an approaching train (auditory information) enter the tectum. The nuclei of the tectum are activated and reflex activity is provoked. The head then turns to allow the eyes to fixate on the source of the stimuli. Conscious processing is activated after a delay, as signals are passed through the thalamus to the cortex. Activation of these structures is responsible for the evaluation of danger and forming complex reactions. The subject can then evaluate their distance from the train, the speed of the train, whether they are in the train's trajectory and whether it is appropriate to move or not.

The decussation of the trochlear nerve (*decussatio fibrarum nervorum trochlearium*) occurs in the midbrain before the nerve emerges just under the inferior colliculus.

The cerebral peduncle is formed from the ventral parts of the midbrain, namely the tegmentum and the cerebral crus. The tegmentum forms the posterior part of the cerebral peduncle and the cerebral crus forms the anterior part of the cerebral peduncle.

The posterior perforated substance is located in the interpeduncular fossa. It contains the posteriomedial central arteries (*arteriae centrales posteromediales*) as they enter the brainstem.

The oculomotor nerve emerges from the midbrain at the interpeduncular fossa.

Caudal section at the level of the inferior colliculus (nuclei and tracts)

1 **Nuclei of the cranial nerves**
- 1.1 Nucleus of trochlear nerve
- 1.2 Mesencephal nucleus of trigeminal nerve

2 **Specific nuclei of the brainstem**
- 2.1 Substantia nigra – compact part
- 2.2 Substantia nigra – reticular part
- 2.3 Nuclei of inferior colliculus
- 2.4 Interpeduncular nucleus

3 **Tracts of the cranial nerves nuclei**
- 3.1 Mesencephal tract of trigeminal nerve
- 3.2 Superior cerebellar peduncular deccussation

4 **Proper tracts of the brainstem**
- 4.1 Medial longitudinal fasciculus
- 4.2 Posterior (dorsal) longitudinal fasciculus
- 4.3 Tegmental central tract
- 4.4 Lateral lemniscus

5 **Ascending tracts**
- 5.1 Medial lemniscus
- 5.2 Spinal lemniscus (comprising the spinothalamic tract) and Trigeminal lemniscus
- 5.3 Brachium of inferior colliculus

5.4 Spinotectalis and spinoreticular tract

6 **Descending tracts**
- 6.1 Corticospinal tract
- 6.2 Corticonuclear tract
- 6.3 Frontopontine tract
- 6.4 Occipito-parieto-temporopontine and corticoreticular tract
- 6.5 Tectospinal tract
- 6.6 Rubrospinal tract

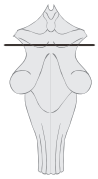

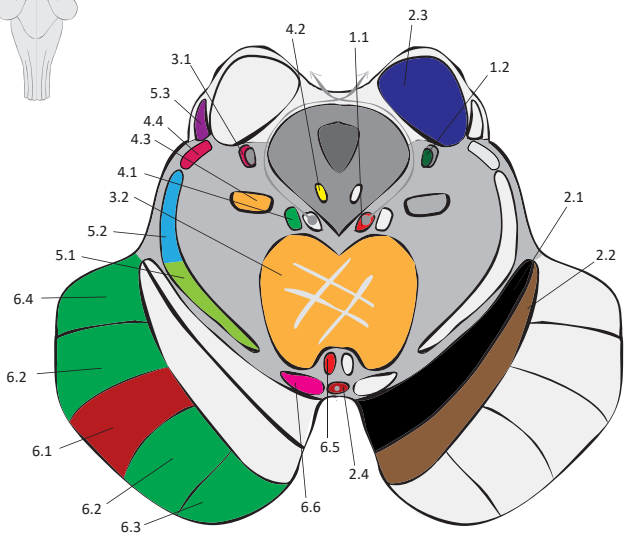

On the left side the tracts are illustrated, on the right side nuclei

Rostral section at the level of the superior colliculus (nuclei and tracts)

1 **Nuclei of the cranial nerves**
- 1.1 Nucleus of oculomotor nerve
- 1.2 Posterior accessory nucleus of oculomotor nerve (nucleus of *Edinger-Westphali)*

2 **Specific nuclei of the brainstem**
- 2.1 Substantia nigra – compact part
- 2.2 Substantia nigra – reticular part
- 2.3 Laminae of superior colliculus
- 2.4 Red nucleus
- 2.5 Periaqueductal grey substance
- 2.6 Interstitial nucleus of *Cajal,* Elliptic nucleus of *Darkschewitch*
- 2.7 Pretectal nuclei

3 **Tracts of the cranial nerves nuclei**

3.1 Mesencephal tract of trigeminal nerve

4 **Proper tracts of brainstem**
- 4.1 Medial longitudinal fasciculus
- 4.2 Posterior (dorsal) longitudinal fasciculus
- 4.3 Tegmental central tract

5 **Ascending tracts**
- 5.1 Medial lemniscus
- 5.2 Spinal lemniscus (comprising the spinothalamic tract) and Trigeminal lemniscus
- 5.3 Brachium of colliculus inferior

6 **Descending tracts**
- 6.1 Corticospinal tract
- 6.2 Corticonuclear tract
- 6.3 Frontopontine tract
- 6.4 Occipito-parieto-temporopontine and corticoreticular tract

6.5 Tectospinal tract (crossing in the anterior and posterior tegmental deccusation)

6.6 Rubrospinal tract (crossing in the anterior tegmental deccusation)

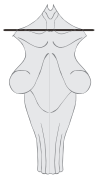

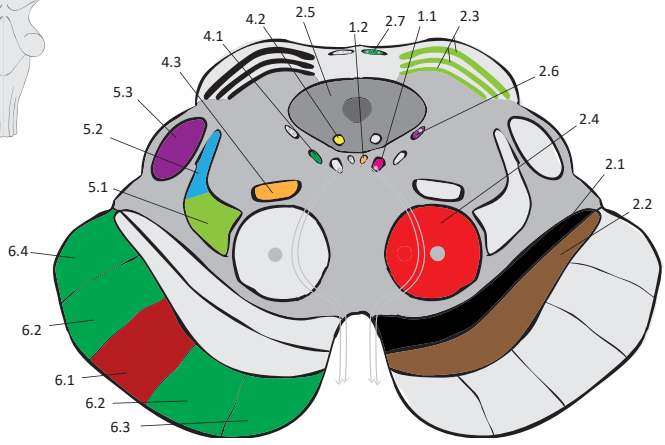

On the left side the tracts are illustrated, on the right side nuclei

This copy belongs to ali yaghoubi

The cranial nerves nuclei are located in the brainstem. The cranial nerve nuclei are classified according to their main function as **efferent (motor) nuclei** and **afferent (sensory) nuclei**.

1 **Somite somatomotor nuclei** – somite origin
– innervate the extra-ocular muscles and muscles of tongue
1.1 **Nucleus of oculomotor nerve** (*nucleus nervi oculomotorii*)
– levator palpabrae superioris, inferior oblique, superior inferior and medial rectus muscle
1.2 **Nucleus of trochlear nerve** (*nucleus n. trochlearis*) – superior oblique muscle
1.3 **Nucleus of abducent nerve** (*nucleus n. abducentis*) – lateral rectus muscle
1.4 **Nucleus of hypoglossal nerve** (*nucleus n. hypoglossi*)
– intrinsic tongue muscles, genioglossus, hyoglossus and styloglossus
2 **Branchial somatomotor nuclei** (branchiomotor)
– innervate muscles that originate from the pharyngeal arches
2.1 **Motor nucleus of trigeminal nerve** (*nucleus motorius n. trigemini*)
– innervates muscles of the first pharyngeal arch (masticatory muscles, mylohyoid, anterior belly of digastric, tensor tympani and tensor veli palatini)
2.2 **Motor nucleus of facial nerve** (*nucleus n. facialis*)
– innervates muscles of the second pharyngeal arch (facial muscles, platysma, stylohyoid, stapedius and posterior belly of digastric)
2.3 **Nucleus ambiguus** – innervates muscles of the third, fourth and sixth pharyngeal arch (muscles of soft palate and fauces, muscles of pharynx and oesophagus
– glossopharyngeal nerve, vagus nerve and cranial root of accessory nerve)
2.4 **Spinal nucleus of accessory nerve** (*nucleus spinalis n. accessori*) – innervates the muscles of the cervical somite origin, innervated by the spinal root and external branch of accessory nerve (*ramus externus n. XI*), innervation of the sternocleidomastoid and trapezius
3 **Visceromotor nuclei** – parasympathetic
3.1 **Posterior accessory nucleus of oculomotor nerve / ncl. of Edinger-Westphali** (*nucleus accessorius dorsalis n. oculomotorii*)
– contains the cell bodies of the preganglionic fibres of the oculomotor nerve that pass to the ciliary ganglion
– innervates the sphincter pupillae and ciliary body
3.2 **Superior salivatory nucleus** (*nucleus salivatorius superior*)
– contains cell bodies of the preganglionic fibres that synapse in the pterygopalatine and submandibular ganglia
– innervates the submandibular, sublingual, small lingual, lacrimal, nasal, palatine and nasopharyngeal glands
3.3 **Inferior salivatory nucleus** (*nucleus salivatorius superior*)
– contains the cell bodies of the preganglionic fibres that synapse in the otic ganglion
– innervates the parotid and buccal glands
3.4 **Posterior nucleus of vagus nerve** (*nucleus posterior nervi vagi*) – contains the preganglionic fibres that travel in the vagus nerve to various ganglia in the neck, thorax and abdomen
– provides parasympathetic innervation of internal organs as far as the Cannon-Böhm point (between the midgut and hindgut)
4 **Viscerosensory nuclei**
4.1 **Nuclei of solitary tract / solitary nuclei** (*nuclei tractus solitarii*)
– receive information from the internal organs via the facial, glossopharyngeal and vagus nerves
4.1.1 **Gustatory nucleus** (*nucleus gustatorius*) – gustatory information from the tongue, palate and fauces via the facial, glossopharyngeal and vagus nerve
5 **Somatosensory nuclei**
5.1 **Spinal nucleus of trigeminal nerve** (*nucleus spinalis nervi trigemini*)
– receives pain, temperature, crude touch and pressure information from the face
– afferent information runs via the trigeminal, glossopharyngeal and vagus nerves
5.2 **Principal nucleus of trigeminal nerve** (*nucleus principalis nervi trigemini*)
– receives information about discriminative touch from the face
5.3 **Mesencephalic nucleus of trigeminal nerve** (*nucleus mesencephalicus nervi trigemini*)
– receives proprioception information from the masticatory and extra-oculars muscles, temporomandibular joint and teeth and their suspensory apparatus
– afferent information runs via the trigeminal, oculomotor, trochlear and abducent nerve
6 **Special sensory nuclei**
6.1 **Vestibular nuclei** (*nuclei vestibulares – superior, lateralis, inferior and medialis*)
– receives information about balance and movement of the head
6.2 **Cochlear nuclei** (*nuclei cochleares – anterior et posterior*) – receives auditory information form the spiral organ of Corti of inner ear, the axons run mainly in the lateral lemniscus

The pontine nucleus of the trigeminal nerve is an obsolete term for the principal nucleus of the trigeminal nerve.

The intermediate nerve (*nervus intermedius*) carries parasympathetic and gustatory fibres to the facial nerve.

The nuclei of solitary tract are a group of autonomic nuclei; all afferent viscerosensory information is transmitted via these nuclei, including the gustatory information (gustatory part of the solitary nuclei – nucleus gustatorius).

Scheme of the nuclei of the cranial nerves see page 488.

Clinical notes

Locked-in syndrome is a condition in which a patient is aware and conscious, but cannot move due to paralysis of all voluntary muscles. Only the eye muscles are spared and the patient can communicate with eye movements. It is usually a result of basilar occlusion and occlusion of the perforators supplying the basilar part of the brainstem. The midbrain (which contains the oculomotor nuclei) remains intact.

Hemiparesis means weakness of the muscles on one side of the body and **hemiplegia** means total loss of function of muscles on one side the body.

Alternating brain stem syndromes are caused by lesions that affect cranial nerve nuclei and the pyramidal tract on one side of the brain stem. As they occur cranially to the decussation of the pyramids, they cause ipsilateral cranial nerve palsies and contralateral hemiparesis/hemiplegia.

Superior alternating hemiplegia (Weber's syndrome) is caused by damage to the basal part of the midbrain causing ipsilateral palsy of the oculomotor nerve and contralateral hemiparesis/hemiplegia.

Middle alternating hemiplegia (Millard-Gubler´s syndrome) is caused by damage to the basal part of the pons, which results in ipsilateral central facial palsy and contralateral hemiparesis/hemiplegia)

Inferior alternating hemiplegia (Jackson´s syndrome) is caused by damage to the basal part of the medulla oblongata, resulting in ipsilateral hypoglossal nerve palsy and contralateral hemiparesis/hemiplegia.

- 1 **Somite somatomotor nuclei**
  - N. III Nucleus of oculomotor nerve
  - N. IV Nucleus of trochlear nerve
  - N. VI Nucleus of abducent nerve
  - N. XII Nucleus of hypoglossal nerve
- 2 **Branchial somatomotor nuclei**
  - N. V Motor nucleus of trigeminal nerve
  - N. VII Motor nucleus of facial nerve
  - N. IX Nucleus ambiguus
  - N. X Nucleus ambiguus
  - N. XI Nucleus ambiguus
  - N. XI Spinal nucleus of accessory nerve
- 3 **Visceromotor nuclei** (parasympathetic)
  - N. III Posterior accessory nucleus of oculomotor nerve
  - N. VII Superior salivatory nucleus
  - N. IX Inferior salivatory nucleus
  - N. X Posterior nucleus of vagus nerve
- 4 **Viscerosensory nuclei**
  - N. VII Nuclei of solitary tract
  - N. IX Nuclei of solitary tract
  - N. X Nuclei of solitary tract
- 5 **Somatosensory nuclei**
  - N. V_s Spinal nucleus of trigeminal nerve
  - N. V_p Principal nucleus of trigeminal nerve
  - N. V_m Mesencephalic nucleus of trigeminal nerve
- 6 **Special sensory nuclei**
  - N. VIII_v Vestibular nuclei
  - N. VIII_c Cochlear nuclei

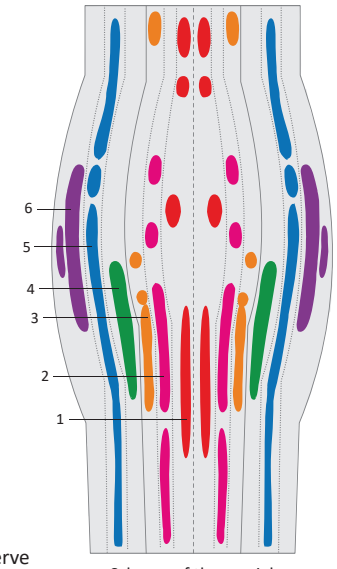

Scheme of the cranial nerves nuclei in the brainstem

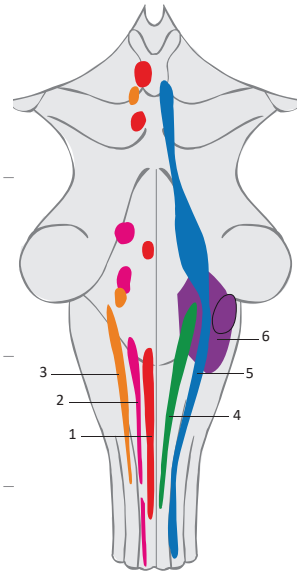

Dorsal surface of the brainstem with the cranial nerves nuclei

3.5 Tracts of the cranial nerves

Cranial nerves tracts are similar to the spinal cord tracts; they consist of bundles of myelinated axons carrying information to and from nuclei.

- 1 **Spinal tract of trigeminal nerve** (*tractus spinalis n. trigemini*) – consists of fibres from the trigeminal nerve which run in the dorsolateral part of the pons and medulla oblongata
  – it reaches the segment C2, the axons originate in the spinal nucleus of n. V
  – forms the trigeminal tubercle, an impression visible on the lateral surface of the brain stem
  2 **Trigeminothalamic tract** (*tractus trigeminothalamicus, lemniscus trigeminalis*)
  - 2.1 **Anterior and lateral trigeminothalamic tracts** (*tractus trigeminothalamicus anterior et lateralis*) – travel from the spinal trigeminal nucleus to the the ventral posteromedial nucleus of the thalamus (ncl. VPM)
    – decussates, transmits pain and thermal information from the facial part of the head
  - 2.2 **Posterior trigeminothalamic tract** (*tractus trigeminothalamicus posterior*)
    – extends from the prinicipal trigeminal nucleus to the ventral posteromedial nucleus of the thalamus (ncl. VPM)
    – does not decussate, transmits information of touch, pressure and discriminative sensation from the facial part of the head
- 3 **Mesencephalic tract of trigeminal nerve** (*tractus mesencephalicus n. trigemini*)
  – the fibers of the trigeminal nerve to the nucleus of the same name which represents a proprioception nucleus of the brainstem
- 4 **Solitary tract** (*tractus solitarius*) – a bundle of fibers for the nucleus of solitary tract (autonomic and gustatory information)
  - 4.1 **Solitariothalamic tract** (*tractus solitariothalamicus*) – does not decussate
    – carries gustatory information to the ventral posteromedial nucleus of the thalamus and give collaterals to the parabrachial nuclei
  - 4.2 **Solitariospinal tract** (*tractus solitariospinalis*) – a descending tract from the nuclei of solitary tract into the autonomic spinal cord nuclei, this tract is important for control of autonomic function of the cardiovascular, respiratory, digestive and urogenital systems
  - 4.3 **Solitarioreticular tract** (*tractus solitarioreticularis*) – is responsible for bidirectional communication with the reticular formation

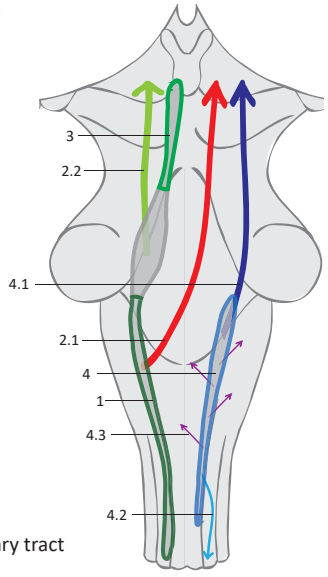

Dorsal surface of the brainstem with the tracts of the cranial nerves

This copy belongs to ali yaghoubi

The brainstem and its main parts contain nuclei associated with **sensory perception and proprioception** (gracile and cuneate nuclei, inferior olivary complex and mesencephalic nucleus of n. V), **special sensory perception** (superior olivary nucleus, nuclei of trapezoid body, nuclei of inferior colliculus, laminae of superior colliculus, pretectal nuclei), **motor nuclei** (red nucleus, pontine and arcuate nuclei, interstitial and elliptic nucleus), **basal nuclei** (substantia nigra), **chemical nuclei** producing neurotransmitters (e.g. substantia nigra, locus caeruleus, ventral tegmental area of Tsai) and **limbic nuclei** (interpeduncular nucleus).

1 **Medulla oblongata**
- 1.1 **Gracile nucleus** (*ncl. gracilis*) – a nucleus in which the spinobulbothalamic tract is interpolated (tactile information, static proprioception from the inferior half of the trunk and lower limbs)
- 1.2 **Cuneate nucleus** (*ncl. cuneatus*) – contains second order neurones of the medial lemnicus system transmitting information about fine touch and proprioception from the upper half trunk and upper limbs
- 1.3 **Accessory cuneate nucleus** (*ncl. cuneatus accessorius*) – its axons form the cuneocerebellar tract and continue to the cerebellum (information about movements in time)
- 1.4 **Inferior olivary complex** (*complexus olivaris inferior*) – part of the Papez control cerebellar circuit, transmits information about current movements
  - 1.4.1 **Principal olivary nucleus** (*ncl. olivaris principalis*)
  - 1.4.2 **Posterior and medial accessory olivary nucleus** (*ncl. olivaris accessorius posterior et medialis*) – receive afferent information from the spinal cord and vestibular apparatus and send efferent information to the cerebellum – represents an integrative center for proprioception and vestibular information
- 1.5 **Arcuate nuclei** (*ncll. arcuati*) – has a similar function to the pontine nuclei

2 **Pons**
- 2.1 **Superior olivary nucleus** (*ncl. olivaris superior*) – receives information from the auditory tracts (collaterals), its activity is important for recognising sound sources
  - 2.1.1 **Nuclei of trapezoid body** (*ncll. corporis trapezoidei*) – receive information from the auditory tract (collaterals); inhibit the superior olivary nucleus and contribute to better distinguishing of sound sources
- 2.2 **Pontine nuclei** (*ncll. pontis*) – are located between the fibres of the pyramidal tracts – are an important component of the motor circuits between the cortex and cerebellum – receive information from the corticopontine tract; their axons form the pontocerebellar tract, which decussates and enters the middle cerebellar peduncle

3 **Mesencephalon**
- 3.1 **Substantia nigra (reticular part)** – an output nucleus of the basal ganglia circuits – is located at the border between the tectum of midbrain and the cerebral crura
- 3.2 **Substantia nigra (compact part)** – produces dopamine – dopamine is passed through the nigrostriatal tract into the striatum
- 3.3 **Laminae of superior colliculus** (*laminae colliculi superioris)* – small rostral bumps in the tectum of midbrain, receive information from the visual tract (collaterals), and via the tectospinal tract they influence movements of the head and neck muscles in response to visual stimuli
- 3.4 **Nuclei of inferior colliculus** (*ncll. colliculi inferioris*) – small caudal bumps in the tectum of midbrain, serve as an interconnection between the cochlear nuclei and nucleus of medial geniculate body (part of the auditory tract)
- 3.5 **Red nucleus** (*ncl. ruber*) – is located in the rostral part of the tegment, affects the flexor activity of the proximal part of the limbs and forms part of the Papez cerebellar control circuit
- 3.6 **Periaqueductal grey substance / central grey substance** (PAG; *substantia grisea centralis*) – interconnects information from the hypothalamus to the autonomic nuclei of the brainstem via the central tegmental tract – in cooperation with the reticular formation, it is associated with pain regulation
- 3.7 **Interstitial nucleus** (*ncl. interstitialis Cajali*) – with the elliptic nucleus receives information from the vestibular nuclei via the medial longitudinal fascicle – its axons synapse on the oculomotor nuclei and are responsible for coordinating hand, neck and eye movements
- 3.8 **Elliptic nucleus** (*ncl. ellipticus Darkschewitchi*) – function is very similar to the interstitial nucleus
- 3.9 **Caerulean nucleus** (*ncl. caeruleus*, A6) – produces norepinephrine
- 3.10 **Pretectal nuclei** (*ncll. pretectales*) – a group of four nuclei, in front of the lateral margin of superior colliculus, are involved in the pupillary reflexes and eye movement coordination
- 3.11 **Interpeduncular nucleus** (*ncl. interpeduncularis*) – under the floor of interpeduncular fossa
- 3.12 **Ventral tegmental area of Tsai** (*area ventralis tegmentalis*, A10) – produces dopamine

The periaqueductal grey substance is involved in pain perception and the central inhibition of pain. It is connected to the reticular formation and limbic system. Through connections to the hypothalamus it influences the hypothalamo-hypophyseal axis and the autonomic nervous system. Its lateral part is associated with the sympathetic nervous system and stress-induced analgesia. Its ventromedial part influences the activity of the parasympathetic nervous system.

The pars compacta of the substantia nigra and the red nucleus are easily visible on magnetic resonance imaging due to their high iron content.

The red nucleus is divided into two parts: the magnocellular part and the parvocellular part. The magnocellular part is made up of large neurones. It is phylogenetically older and is located caudal to the parvocellular part. The parvocellular part dominates in human brains. It is made up of small neurones and is associated with the Papez control circuit.

The red nucleus contains a pigment called lipofuscin, which is responsible for its red colour, which is seen in sections of the brainstem.

The interpeduncular nucleus integrates the olfactory and limbic systems with the nuclei of the autonomic nervous system in the brainstem and spinal cord. It plays a role sleep-wake cycle by regulating the rapid eye movement phase of sleep.

The ventral tegmental area of Tsai (*area ventralis tegmentalis*) delivers dopamine to the cerebral cortex via the mesocortical tract and to the nucleus accumbens via the mesolimbic tract. It is know as the centre of love and addiction because an elevated concentration of dopamine in the cortex and nucleus accumbens evokes happiness, joy, desire and craving (besides other feelings).

Clinical Notes

A low level of dopamine production in the substantia nigra pars compacta leads to the clinical symptoms of Parkinson's disease.

1 **Medulla oblongata**
- 1.1 **Gracile nucleus**
- 1.2 **Cuneate nucleus**
- 1.3 **Accessory cuneate nucleus**
- 1.4 **Inferior olivary complex**
  - 1.4.1 **Principal olivary nucleus**
  - 1.4.2 **Posterior and medial accessory olivary nucleus**
- 1.5 **Arcuate nuclei**

2 **Pons**
- 2.1 **Superior olivary nucleus**
- 2.2 **Pontine nuclei**
- 2.3 **Nuclei of trapezoid body**

3 **Mesencephalon**
- 3.1 **Substantia nigra (reticular part)**
- 3.2 **Substantia nigra (compact part)**
- 3.3 **Laminae of superior colliculus** (7 layers)
- 3.4 **Nuclei of inferior colliculus**
- 3.5 **Nucleus ruber**
- 3.6 **Periaqueductal grey substance**
- 3.7 **Interstitial nucleus** and **elliptic nucleus**
- 3.8 **Pretectal nuclei**
- 3.9 **Interpeduncular nucleus**
- 3.10 **Ventral tegmental area of Tsai**

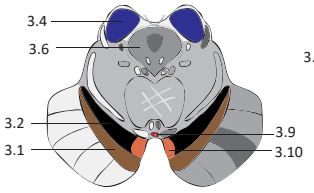

5 – Caudal section of the mesencephalon

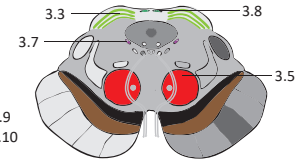

6 – Rostral section of the mesencephalon

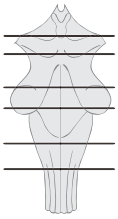

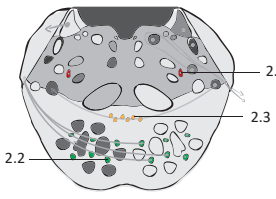

3 – Caudal section of the pons

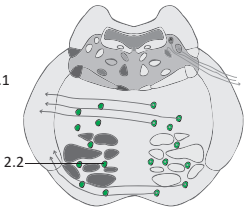

4 – Rostral section of the pons

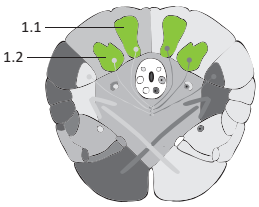

1 – Caudal section of the medulla oblongata

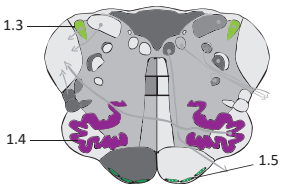

2 – Rostral section of the medulla oblongata

Neuronal tracts in the brainstem interconnect structures within the brainstem and **connect the brainstem to higher and lower levels of the CNS**. They are responsible for coordinating brainstem functions.

- 1 **Medial longitudinal fascicle** (fasciculus longitudinalis medialis)
  - – extends from the midbrain through the brainstem into the spinal cord where it is located in the anterior funiculus
  - – innerconnects the nuclei of the extraocular muscles with vestibular nucleus, elliptic nucleus, interstitial nucleus and the cervical spinal cord
  - – important for coordination of eyes movement with the head
    - 1.1 **Posterior commissure** (*commissura posterior*)
      - – a structure where the fibers of the interstitial nucleus and nucleus of posterior commissure decussate and join the contralateral medial longitudinal fascicle
- 2 **Posterior longitudinal fascicle** (*fasciculus longitudinalis posterior Schützi*)
  - – passes through the PAG of midbrain, connecting the medial hypothalamus and autonomic nuclei of brainstem and reticular formation

3 **Central tegmental tract** (*tractus tegmentalis centralis*)
- – an ascending connection of the reticular formation with the intralaminar nuclei of thalamus, descending connections from the tegmentum of midbrain to the inferior olivary complex

- 4 **Lateral lemniscus** (*lemniscus lateralis*)
  - – axons from the cochlear nuclei to the inferior colliculus, functionally it is a component of the auditory tract (contains axons of second neurons).

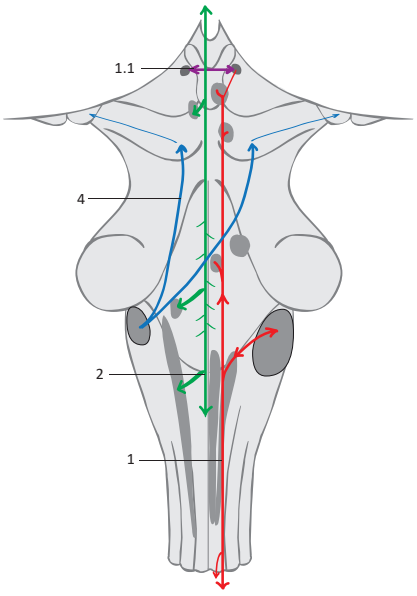

Dorsal surface of the brainstem with specific tracts of the brainstem

This copy belongs to ali yaghoubi

The reticular formation is a **complex network of phylogenetically old nuclei**. It extends **from the cervical spinal cord through the brainstem into the diencephalon** and is **connected to almost all parts of the CNS**. Afferent information enters the reticular formation through tracts and collaterals. The reticular formation contains vital centres for breathing, heart rate and blood pressure. It **coordinates the activity of the cranial nerves, is involved in processing pain, regulates motor activity and the endocrine system and controls wakefulness through the reticular activating system.**

Topography

- 1 **Medulla spinalis** – the lateral part of the lateral horn of the cervical segments
- 2 **Medulla oblongata** – underneath the floor of fourth ventricle
- 3 **Pons** – underneath the floor of fourth ventricle
- 4 **Mesencephalon** – in the tegmentum
- 5 **Diencephalon** – reticular thalamic nuclei and zona incerta



Section of the medulla spinalis

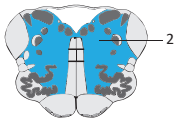

Section of the medulla oblongata

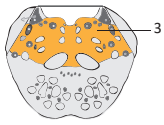

Caudal section of the pons

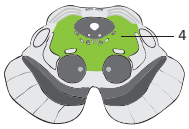

Rostral section of the mesencephalon

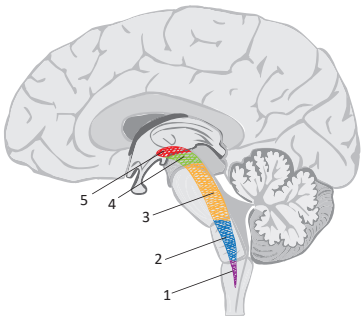

Sagittal section of the brain

Classification according to the longitudinal systems

- 1 **Rapheal system** – unpaired
  - travels longitudinally through the brain stem
  - sends efferent fibres to the nuclei of the magnocellular system, spinal cord, brainstem and telencephalon
  - reciprocally connected to the limbic system (mainly to hypothalamic nuclei)
  - has a predominantly inhibitory effect on the structures it innervates
  - produces serotonin and participates in the descending system of pain inhibition at the level of the spinal cord segments
- 2 **Medial (magnocellular) system** – paired
  - is located between the rapheal and lateral systems
  - the main system of the RF nuclei is composed of large controlling neurons
  - is connected to almost all parts of the CNS
  - forms part of the ascending reticular activation system (ARAS)
- 3 **Lateral (parvocellular) system** – paired
  - is located in the lateral part of the medulla oblongata and pons
  - formed by small neurons (parvocellular)
  - afferent information come from the somatosensory, viscerosensory and special sensory tracts
  - efferent information run to the medial system of RF nuclei and to the cerebellum
  - responsible for the reflex loops of the cranial nerves and participates in autonomic function

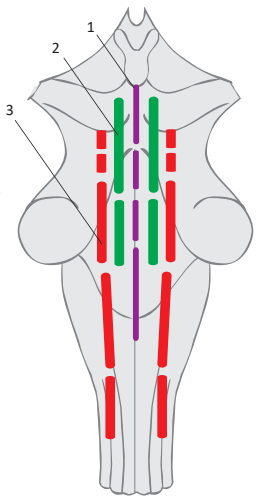

Dorsal surface of the brainstem with longitudinal systems of RF

The term "reticular formation" refers to its net-like organisation, where nervous impulses spread out from each other. The contrary occurs in the spinal cord, where afferent signals from peripheral nerves converge.

The spino-reticular tract (*tractus reticulo-spinalis*) directly transmits pain information to the reticular formation. The reticulo-thalamic tract (*tractus reticulo-thalamicus*) relays this information to the thalamus. These tracts are involved in the transmission of chronic pain to the cortex. Other ascending tracts (spinothalamic, spinotectal, spinoolivary and spinocerebellar) send collaterals to the reticular formation, which function to modulate the activity of the reticular formation.

The parabrachial nuclei (*nuclei parabrachiales*) represent a group of nuclei of the RF, situated in the borderline between the pons and midbrain (nearby the superior cerebellar peduncle). Information comes from the nuclei of solitary tract. Functionally, they are involved in pain perception (central pain inhibition, emotional and autonomic component of pain) and in brainstem respiratory centers.

The lateral parabrachial nucleus is associated with the descending pain inhibition system and with transmission of affective-emotional component of pain (with cooperation of the hypothalamus and amygdaloid body).

The medial parabrachial nucleus is associated with gustatory perception (its axons run into the gustatory nucleus of the thalamus – ventrolateral posteromedial nucleus), involved in e.g. gustatory aversion (protects organism against repeated ingestion of inedible, disgusting or toxic food and drinks).

The nucleus of Kölliker-Fuse is a part of the pneumotaxic centre. It regulates breathing rate by sending signals, which terminate inspiration.

Chemical brain system see page 477.

Clinical notes

Increased intracranial pressure (intracranial hypertension) can lead to herniation of the cerebellar tonsils through the foramen magnum. This can quickly lead to death by compression of the cardiorespiratory centres in the reticular formation of the brainstem

Classification according to the transverse organization of the neuroaxis

- 1 **Spinal cord level**
  - – is situated in the lateral part of the lateral horn of the cervical segments C1 to C8
  - 1.1 Ciliospinal centre of Budge (*nucleus ciliospinalis*)
  - 1.2 Cornucommissural nuclei (*nucleus cornusommissuralis anterior and posterior*)
- 2 **Rhombencephalic level**
  - – situated in the medulla oblongata and pons lying under the floor of fourth ventricle
  - – contains vitally important centers (respiration control, pneumotaxic and apnoic/apneustic center; cardiovascular centers for heart activity and blood pressure control)
  - 2.1 **Locus caeruleus** (A6) – a component of brain chemical system producing norepinephrine (noradrenaline)
  - 2.2 **Raphe nuclei** (*nuclei raphes*) (B1 to B8)
    - – a group of brain chemical nuclei producing serotonin
  - 2.3 **Small adrenergic group** (A1, A2) – is reciprocally interconnected with the hypothalamus and amygdaloid body, is involved in body temperature monitoring and control, cooperates with the centers for respiration and cardiovascular control
- 3 **Mesencephalic level**
  - 3.1 **Periaqueductal grey substance** (PAG, *substantia grisea centralis*)
  - 3.2 **Ventral tegmental area of Tsai** (*area ventralis tegmentalis Tsai*) (A10)
    - – a chemical nucleus producing dopamine for the cortex and nucleus accumbens
  - 3.3 **Compact part of substantia nigra** (*pars compacta substantiae nigrae*) (A9)
    - – a chemical nucleus producing dopamine for the striatum
- 4 **Diencephalic level**
  - – localized in the thalamus and subthalamus
  - 4.1 **Reticular thalamic nuclei** (*nuclei reticulares thalami*) and **zona incerta**
    - – are not components of the ARAS
    - – reticular cells produce gaba-amino-butyric acid (GABA-ergic nuclei)
    - – majority of afferent information are excitatory collaterals from specific nuclei of the thalamus and from the cortex
    - – efferent information is mainly inhibitory (GABA-ergic), predominately for the thalamus but not for the cerebral cortex
    - – the main function of these cells is to determine new stimuli and distinguish them from familiar stimuli
    - – they are also involved in body temperature regulation and control
  - 4.2 **Intralaminar thalamic nuclei** (*nuclei intralaminares thalami*)
    - – represent a component of the ARAS
    - – are involved in modulation and afferentation of slow and chronic central pain

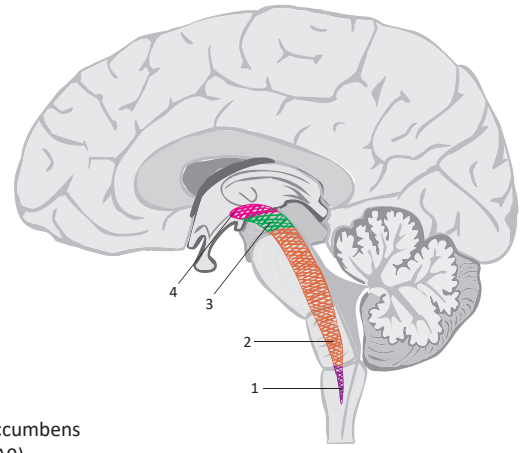

Sagittal section of the brain

Other functional parts of the reticular formation

1 **Precereballer nuclei** (*nuclei precerebellares*)
- – represent nuclei interconnected with the cerebellum and its motor circuits
- – are involved in pre-processing of motor information directed to the cerebellar cortex which comes from the cortical motor area and motor nuclei of brainstem
- – the principal function is inhibition of cerebellar activity via the reticulocerebellar tract (*tractus reticulocerebellaris*)

2 **Monoaminergic system** – producing neurotransmitters
- 2.1 **Catecholaminergic system** – responsible for noradrenaline and dopamine production
  - – a group of nuclei termed A1 to A7 – noradrenergic system
  - – a group of nuclei termed A8 to A10 – dopaminergic system
  - **A6** **Locus caeruleus** – produces noradrenaline for almost the entire CNS
  - **A9** **Compact part of substantia nigra** – produces dopamine for the striatum
  - **A10** **Ventral tegmental area of Tsai** – produces dopamine for the limbic system and cortex
- 2.2 **Serotoninergic system** – produces serotonine
  - – a group of nuclei termed B1 to B7 (rapheal system)

This copy belongs to ali yaghoubi

Afferent fibres

- 1 **From the spinal cord** – spinoreticular tract and its collaterals
  - – responsible for RF activation
  - 1.1 **Direct afferentation from the spinoreticular tract**
    - – carries slow pain
    - – continues as the spinoreticulothalamic tract to the thalamus and cortex
  - 1.2 **Indirect afferentation**
    - – collaterals from all ascending tracts
    - – involvement in sensory ascending tracts
- 2 **From the trigeminal nerve** – trigeminoreticular tract
  - – the somatosensory spinal nucleus of trigeminal nerve
  - – the RF plays an important role in trigeminal reflex loops
- 3 **From the cerebellum** – cerebelloreticular tract
  - – the RF is involved in the motor circuits of the spinal cord and cranial nerves
- 4 **From the motor nuclei of brainstem**
  - – tectum of midbrain, red nucleus, vestibular nuclei and inferior olivary complex
  - – the RF is responsible for interconnection of the nuclei associated with the extrapyramidal motor system
- 5 **From the hypothalamus and limbic system**
  - – from the amygdaloid body, septum verum and hippocampus via the posterior longitudinal fasciculus
  - – these reciprocal connections influence activity of the vital centers in the RF
- 6 **From the thalamus** – thalamoreticular tract
  - – from the intralaminar and median nuclei of thalamus, a reciprocal interconnection of the RF with the thalamus and cortex
- 7 **From the cortex** – corticoreticular tract
  - – a reciprocal connection between the RF and motor, somatosensory and associative cortical areas

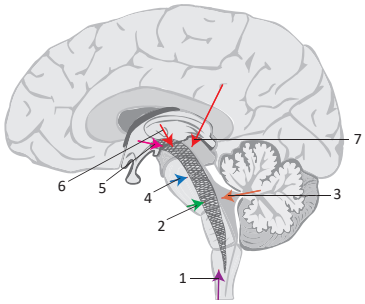

Efferent fibres

- 1 **To the spinal cord** – reticulospinal tract
  - – responsible for integration of cortical and cerebellar function in the somatomotor nuclei in the spinal cord
  - – responsible for communication between the spinal cord (visceromotor nuclei) and hypothalamus and limbic system
  - – responsible for pain inhibition at the level of the spinal cord
  - – descending reticular inhibitory system (DRIS)
- 2 **To the nuclei of the cranial nerves**
  - – reticulonuclear tract
  - – interconnects the nuclei of the cranial nerves and is responsible for reflex loops of the brainstem
- 3 **To the cerebellum** – reticulocerebellar tract
  - – associated with the motor circuits of the cerebellum
- 4 **To the cortex** – through the reticulothalamocortical tract
  - – this system is termed the ascending reticular activation system (ARAS)

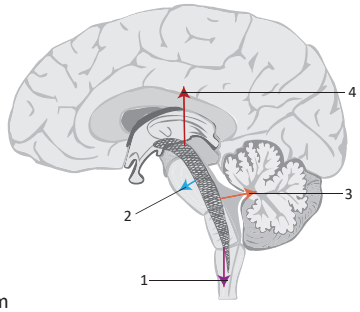

One of the effects of caffeine is inhibition of the inhibitory receptors (adenosine-diphosphate receptors) of the ascending reticular activating. By blocking of these receptors, caffeine enhances the cerebral activity, increasing alertness and concentration.

The respiration centres include:
1. **The rostral-ventral and caudal--ventral respiratory groups** (*centrum respiratorium ventrale rostrale et caudale*)
2. **Bötzinger group of expiratory neurons** (*centrum expiratorium medullae*)
3. **Pre-Bötzinger cells** (*centrum generans motus respiratorius*) – generate the respiratory rhythm

The apnoeic (apneustic) centre is physiologically activated at the peak of inspiration and is responsible for the short pause that occurs between inspiration and expiration. It is possible to consciously activate the apnoeic centre to hold the breath for longer periods of time. However, the increasing levels of carbon dioxide will eventually overpower the cortical stimulation of the apnoeic centre and reflex inspiration will be activated.

Clinical notes

Damage of the tectum intensifies the effect of the reticular formation on the motor neurons in the spinal cord. This leads to increased tone of the anti-gravity muscles via the reticulospinal tract, which causes extension and internal rotation of the lower limbs, extension and pronation of the upper limbs and hyperextension of the head and back (opisthotonus).

Damage to the ARAS leads to loss of consciousness and decerebral rigidity.

Ondine's curse disease (congenital central hypoventilation syndrome) is form of central sleep apnea. It is characterised by hypoventilation that occurs during sleep and is caused by an acquired or developmental lesion in the respiratory centres. It is name after a fairy from German mythology named Ondine, who, after being cheated on by her lover, made unfaithful men forget to breathe.

Sudden infant death syndrome (SIDS) is the sudden death of an infant, typically occurring during sleep. Similar to Ondine's curse diease, it is believed to be caused by defective or immature respiratory centres.

Functions

1 **Activation – ascending reticular activation system (ARAS)**
– its continual activity is responsible for consciousness and alertness
– afferent information come from the entire body
and efferent impulses are directed to the thalamus and cortex
– consists of the brain chemical nuclei – cholinergic (Ch5 and Ch6) and locus caeruleus (A6)

2 **Inhibition**
– responsible for inhibition of neurons in ascending as well as descending manner
– its increased activity participates in weariness and induction of sleeping
– consists of brain chemical nuclei – mainly the serotoninergic raphe nuclei (B1 to B7)

3 **Site of connection**
– responsible for processing of sensory stimuli entering the CNS (important structure for signal divergence)

4 **Vital centers and reflexes**
– defensive reflexes: reflex of blinking, lacrimation, sneezing, coughing and vomiting
– feeding reflexes: reflex of intake, swallowing, salivation and digestive juices production

5 **Regulatory centers for vital functions**
5.1 **Cardiovascular center – vasomotor center** (blood circulation)
– localized underneath the vagal trigone in the medulla oblongata
– afferent information runs via the n. IX and n. X from baroreceptors
in the carotid sinus (*sinus caroticus*) and para-aortic bodies (*glomera aortica*), respectively
– efferent information runs via the sympathetic nervous system
to the intermediolateral nuclei of spinal cord
– blood pressure increases due to higher activity of the sympathetic system
which leads to constriction of arterioles
5.2 **Cardiovascular center – heart rate activity**
– acceleration of heart rate – impact of the sympathetic system (*nervi cardiales*)
– deceleration of heart rate – impact of the parasympathetic system (*nervi vagi*)
5.3 **Respiration centers**
– are located in the medulla oblongata near the nucleus solitarius
– they cooperate with the superordinate centres in the pons (the pneumotaxic and apneustic centres)
– neurons for inspiration and expiration send impulses to the respiratory muscles via the reticulospinal tract
– most impulses are sent to the nucleus of the phrenic nerve in segments C3 to C5 innervation of the diaphragm
5.4 **Pneumotaxic center**
– the superior respiration center in the pons, gives orders to centers in the medulla oblongata,
it is responsible for periodicity of breathing
– impulses come from the nuclei of solitary tract
(information from osmoreceptors, chemoreceptors, muscle spindles of the respiratory muscles)
and also emotions from the limbic system structures
– responsible for changes of breathing pattern during
different actions, such as speaking, singing, swimming etc.
5.5 **Apneustic center**
– localized in the pons, is responsible for pauses during breathing and regulation of inspiration and expiration
– apnoe means no breathing.
5.6 **Pontine micturition center (of Barrington)**
– the superior center in the rostral pons responsible for evacuation of the urinary bladder
– is connected with the Onuf´s nucleus in the segment S2 to S4 (sacral micturition center)
to control wall tension of the urinary bladder
– increased activity of the parasympathetic system intensifies
tension of the urinary bladder – detrusor (*m. detrusor vesicae*)
– decreased activity of the sympathetic system relaxes the internal urethral sphincter (*m. sphincter urethrae internus)*

6 **Body temperature regulation**
– the nuclei in the rapheal system in cooperation with centers in the hypothalamus and periaqueductal grey substance

7 **Motor control**
– responsible for activation of flexors and extensors, influences muscle tone, facial muscles and expression of emotions

8 **Pain control and transmission**
– slow pain information comes via the spinoreticular tract
– the pain is regulated and modulated at the level of the spinal cord via the raphespinal and caeruleospinal tract

This copy belongs to ali yaghoubi

The cerebellum is situated in the posterior cranial fossa, separated from the occipital lobes by the tentorium cerebelli. It communicates with the brainstem through the cerebellar peduncles. The cerebellum is **one of the main regulators of motor control**. During movements it receives **vast amounts of afferent information** from the spinal cord (proprioception and tactile sensation) and from the cerebral cortex. In cooperation with the cortex, basal nuclei, thalamus and motor nuclei of brainstem, the cerebellum is **involved in creation and control of movements**. It plays an integral role in the **coordination of movements and in body stability during standing as well as during movements** and is associated with motor memory.

Topography

- 1 **Ventrally:** brainstem
  - 1.1 **Fourth ventricle** (*ventriculus quartus*)
    – situated between the cerebellum and brainstem
  - 1.2 **Superior cerebellar peduncle** (*pedunculus cerebellaris superior*)
    – connection with the midbrain
  - 1.3 **Middle cerebellar peduncle** (*pedunculus cerebellaris medius*)
    – connection with the pons
  - 1.4 **Inferior cerebellar peduncle** (*pedunculus cerebellaris inferior*)
    – connection with the medulla oblongata
- 2 **Dorsally:** occipital lobes of telencephalon (*lobi occipitales*)
  - 2.1 **Tentorium cerebeli / cerebellar tentorium**
    – a duplication of the dura mater separating the cerebellum and occipital lobes

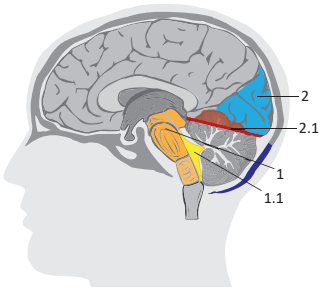

External features

Macroscopic classification:

- 1 **Vermis of cerebellum** (*vermis cerebelli*)
  – an unpaired ventral part in shape of a worm
  - 1.1 **Lingula** – the most ventral part of the vermis
  - 1.2 **Nodule** (*nodulus*) – the most dorsal part of the vermis
- 2 **Hemispheres of cerebellum** (*hemispheria cerebelli*)
  – paired cerebellar hemispheres
  - 2.1 **Tonsil of cerebellum** (*tonsilla cerebelli*)
    – the most caudal part nearby the foramen magnum

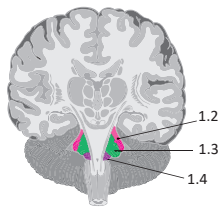

Frontal section of the brain

Superficial structure of the cerebellum:

4 **Body of cerebellum** (*corpus cerebelli*)
- 4.1 **Anterior lobe of cerebellum** (*lobus cerebelli anterior*)
- 4.2 **Posterior lobe of cerebellum** (*lobus cerebelli posterior*)
- 4.3 **Flocculonodular lobe** (*lobus flocculonodularis*)

- 5 **Folia of cerebellum** (*folia cerebelli*)
  – leaves of cerebellar cortex
  - 5.1 **Sulci of cerebellum** (*sulci cerebelli*)
    – shallow grooves separating the folia of cerebellum

6 **Cerebellar fissures** (*fissurae cerebelli*)
– deeper grooves separating the lobes of cerebellum
- 6.1 **Primary fissure** (*fissura prima*)
  – situated between the anterior and posterior lobe of cerebellum
- 6.2 **Posterolateral fissure** (*fissura posterolateralis*)
  – situated between the flocculonodular and posterior lobe

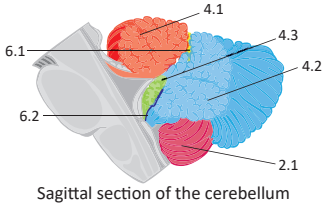

Sagittal section of the cerebellum

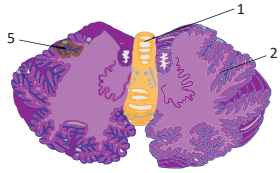

Cross-section of the cerebellum

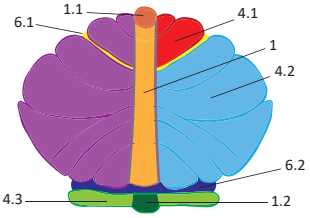

Scheme of the cerebellum

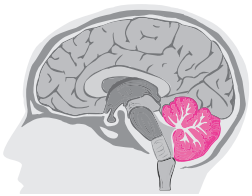

The pattern of grey and white matter seen on sagittal section of the cerebellum is known as the tree of life (*arbor vitae*).

The cerebellar peduncles have obsolete synonyms:
Superior cerebellar peduncle
– **brachium conjuctivum**
Middle cerebellar peduncle
– **brachium pontis**
Inferior cerebellar peduncle
– **corpus restiforme**

The cerebellar hemispheres are anatomically divided into 9 lobules (HII to HX).

The vermis of the cerebellum is divided into 10 components (I to X). They are usually referred to as numbered segments. Unlike the cerebral cortex this classification does not fully correspond to function and demonstrates significant interindividual variability.

Each climbing fibre terminates on only one Purkinje cell. Each neurone in the inferior olivary complex give rise to about 10 climbing fibres.

Clinical notes

Examination of cerebellar function:
1 **Taxis** is examined with the finger-to-nose and heel-to-shin test, which are performed with and without eye control.
Damage of neocerebellum leads to ipsilateral disorders of taxis
2 **Diadochokinesis** is examined by performing bilateral rapid antagonist movements (e.g. alternating pronationg and supination of both forearms). Symmetry, rhythm and speed of the movements are evaluated.
3 **Rebound phenomenon** is present in cerebellar disease. The patient holds their arms outstretched against a force applied by the examiner. When the examiner releases this force, the patient's arms move in the direction against the force above their original position.
4. **Retroflexion of the trunk** (gross asynergy) is examined in a standing patient. The examiner pulls the trunk of the patient dorsally. This is usually counteracted by contraction of the flexors of the legs. In cerebellar disease this is impaired and the patient falls.

Internal features

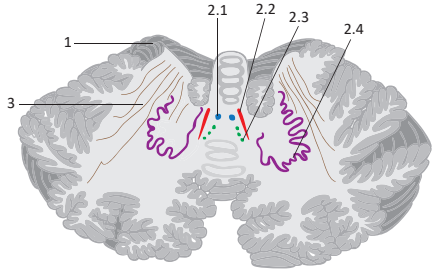

Cross-section of the cerebellum

Grey matter of the cerebellum

- 1 **Cerebellar cortex** (*cortex cerebelli*)
- 2 **Cerebellar nuclei** (*nuclei cerebellares*)
  - 2.1 **Fastigial nucleus / nucleus medialis cerebelli** (*nucleus fastigii / nucleus medialis cerebelli*) – terminal nucleus of vestibulocerebellum
  - 2.2 **Emboliform nucleus / anterior interpositus nucleus** (*nucleus emboliformis / nucleus interpositus anterior*) – terminal nucleus of spinocerebellum
  - 2.3 **Globose nucleus / posterior interpositus nucleus** (*nucleus globosus / nucleus interpositus posterior*) – terminal nucleus of spinocerebellum
  - 2.4 **Dentate nucleus / nucleus lateralis cerebelli** (*nucleus dentatus / nucleus lateralis cerebelli*)

White matter of the cerebellum

- 3 **White matter of cerebellum** – cerebellar tracts

Histological structure of the cerebellum – Eccles scheme

– cerebellar afferent tracts predominate (afferents:efferents ratio – 40:1)
– the disproportion is an explanation of the inhibitory function of the cerebellar cortex
– output is provided by Purkinje cells

Function connection of the cerebellar cortex

mossy fibers (afferent information) → stellate, basket, granule and Golgi cells, climbing and multilayerd fibers → **Purkinje cells** → **cerebellar nuclei** (efferent information)

Layers of the cerebellar cortex:

1 **Molecular layer** (*stratum moleculare*) – the superficial layer containing stellate, basket cells and parallel fibers
2 **Purkinje cell layer** (*stratum purkinjese*) – the central layer of piriform cells of Purkinje
3 **Granular layer** (*stratum granulosum*) – the deep layer containing granule cells and Golgi cells (large stellate neurons)

Cells

- 1 **Granule cells** (*Neura granulosa*)
  – **the only excitatory neurons of the cerebellar cortex** (its axons after T division form parallel fibers)
  – afferent information comes from mossy fibers
  – the axons of granular cells form synapses with basket, stellate and Golgi cells
- 2 **Golgi cells** (large stellate neurons, *neura stellata magna*)
  – **inhibitory neurons**
  – afferent information comes from mossy fibers and granule cells
  – the axons of Golgi cells participate in the glomerulus of cerebellum
- 3 **Stellate and basket cells** (*neura stellata et corbiformia*)
  – **inhibitory cells (GABA)**
  – afferent information comes from granule cells
  – axons form synapses with Purkinje cells
- 4 **Purkinje cells** (*neura purkinjensa*)
  – **inhibitory neurons**
  – afferent information comes from stellate and basket cells, from climbing and multilayered fibers
  – axons run into the cerebellar nuclei

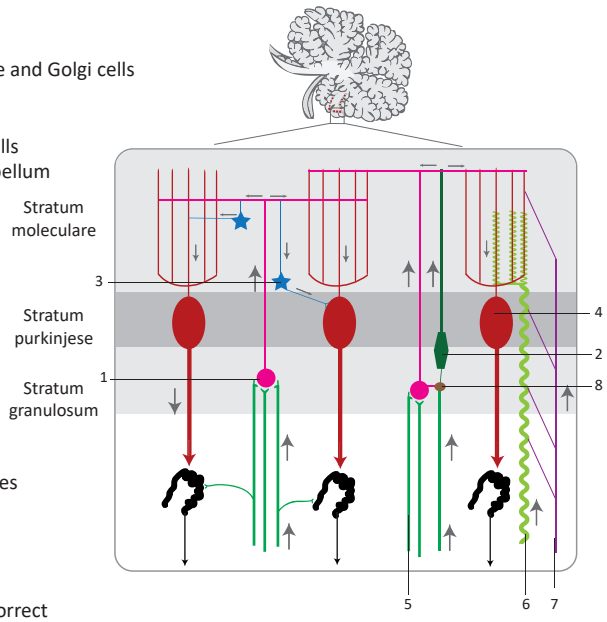

Fibers of the cerebellum

- 5 **Mossy fibers** (*neurofibrae muscosae*)
  – the most numerous afferent fibers from more different sources
  – terminate at granule cells
- 6 **Climbing fibers** (*neurofibrae ascendentes*)
  – the axons of cells from the inferior olivary complex
  – terminate at and activate dendrites of Purkinje cells
  – involved in motor control, responsible for signalization of incorrect motor patterns and for precise timing of movements and motor memory
- 7 **Multilayered fibers** (*neurofibrae multistratificatae*)
  – their main impact is modulatory – influence function of a majority of cortical neurons
  – afferent information comes from the locus caeruleus, raphe nuclei and hypothalamus

Glomerulus of cerebellum

- 8 **Glomerulus of cerebellum** (*glomerulus cerebelli*) – a complex network of synapses formed by mossy fibers, dendrites of granule cells and axons of Golgi cells in the granular layer of cerebellar cortex

This copy belongs to ali yaghoubi

Development

– the origin of the cerebellum is the metencephalic alar lamina
– its middle part is a base for the vermis of cerebellum
– the growth of the lateral part is a base for the hemispheres

Three parts according to the development:

1 **Archicerebellum**
2 **Paleocerebellum**
3 **Neocerebellum**

Classification according to the function and development

- 1 **Vestibulocerebellum** (*archicerebellum*)
  – **anatomically:** flocculonodular lobe
  – **functionally:** posture control in cooperation with the vestibular and static apparatus
- 2 **Spinocerebellum** (*paleocerebellum*)
  – **anatomically:** vermis and paravermal zone of hemispheres
  – **functionally:** participation in oculomotor and posture control
- 3 **Cerebrocerebellum** (*neocerebellum*)
  – **anatomically:** lateral zones of hemispheres
  – **functionally:** free movement control, fine movements coordination in cooperation with the neocortex

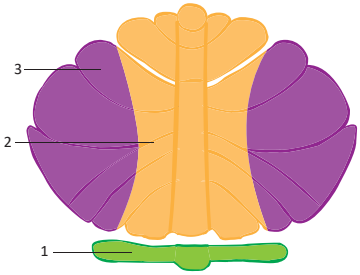

Scheme of the cerebellum

Vestibulocerebellum

Afferent information from the vestibular and static organ of the inner ear

– static and kinetic perception from hair cells of the maculae of utricle and saccule and ampullary crests (in semicircular ducts) of inner ear

- 1 **Direct information from the vestibular ganglion**
  – without interconnection via the primary vestibulocerebellar tract
  – mossy fibers to the flocculonodular lobe
- 2 **Indirect information from the vestibular nuclei**
  – via the secondary vestibulocerebellar tract
  – mossy fibers to the flocculonodular lobe

Efferent information runs to the vestibular nuclei

– from the fastigial nucleus and also directly from Purkinje cells of flocculonodular lobe

- 3 **Mainly to the lateral vestibular nucleus of Deiters** (*nucleus vestibularis lateralis*)
  – from this nucleus to the spinal cord (via the lateral vestibulospinal tract) and ascending projection to the nuclei of the brainstem

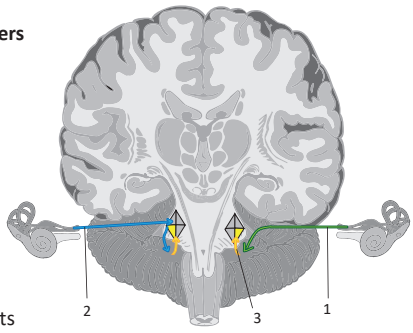

Function

– movement control and muscle tone control of extensor and postural muscles
– reflex control of ocular movements and coordination of eyes, head and neck movements via the medial longitudinal fasciculus and projection from the lateral vestibular nucleus (vestibulo-oculo-motor reflexes)

Arché is the Greek term for beginning.
Palaios is the Greek term age.

The archicerebellum and paleocerebellum are both phylogenetically old structures. The archicerebellum is the oldest part of the cerebellum and is developed in fish. The paleocerebellum developed in amphibians and reptiles.

The vestibulo-ocular reflex is one of the fastest reflex in the human body. It is able to adjust eye position in less than 10 ms .

The anterior spinocerebellar tract is also known as the double cross tract because it decussates twice.

Vestibulocerebellum function:
The vestibulo-ocular can be demonstrated by moving your head from side to side while focusing your eyes on one point. The eyes move in opposite directions to the head in order to remain fixed on one point. Supressing this reflex is not easy, unless you deliberately defocus your eyes so that they cannot fix on any point.

The collaterals of Purkinje cell axons from the flocculonodular lobe do not synapse in the fastigial nucleus. They run directly to the vestibular nuclei.

Neocerebellar activity:
Imagine a violinist practicing a new piece. At the beginning he/she uses the sheet music. Slowly, he/she improves until he/she is able to play with closed eyes and by memory.

The motor cortico-cerebello-cortical circuits decussate so that the right cerebral hemisphere influences the left cerebellar hemisphere and vice versa. The motor pyramidal tract is also decussated. Thus, the cerebellar hemisphere controls movements of the same side of the body.

Motor memory is involved in creation and imprinting of permanent motor circuits. Structures responsible for motor memory include premotor area (area 6), association areas, basal ganglia, hippocampus, and cholinergic nuclei. The cerebellum plays an important role in verbal working memory, primarily through connections between the Broca's motor speech area and the right cerebellar hemisphere. Injury to the cerebellum can lead to language disorders.

Spinocerebellum

Afferent information mainly from the spinal cord and trigeminal nerve

- 1 **From the spinal cord – posterior thoracic nucleus of Stilling-Clarke via the anterior spinocerebellar tract**
  - – kinetic proprioception from the trunk and lower limbs
  - – the tract decussates at the level of corresponding spinal segment and via the superior cerebellar peduncle, it enters the cerebellum where it decussates again and reaches the original side
  - – in the cerebellum it continues as mossy fibers terminating at granule and Golgi cells
- 2 **From the spinal cord – posterior thoracic nucleus of Stilling-Clarke via the posterior spinocerebellar tract**
  - – static proprioception from the upper limbs and superior part of the trunk
  - – the tract does not decussate, and enters the cerebellum via the inferior cerebellar peduncle
  - – in the cerebellum it continues as mossy fibers terminating at granule and Golgi cells
- 3 **From the spinal cord – spinal ganglion and cuneo-cerebellar tract**
  - – fine mechanoception, static proprioception from the upper limbs and superior part of the trunk
  - – the tract interpolates in the medulla oblongata – accessory cuneate nucleus
  - – in the cerebellum it continues as mossy fibers terminating at granule and Golgi cells
- 4 **From the brainstem – spinal nucleus of trigeminal nerve via the trigemonocerebellar tract**
  - – mechanoception, static and kinetic proprioception from the head
- 5 **From the brainstem – inferior olivary complex** (*complexus olivaris inferior*)
  - – control function in the Papez control cerebellar circuit
  - – the inferior olivary complex works as a precerebellar nucleus (getting information from the spinal cord, tegmentum of midbrain, red nucleus, vestibular nuclei, and cortex)
  - – axons enter the cerebellar cortex as climbing fibers and terminate at Purkinje cells
  - – impulses transmitted via this tract are responsible for motor timing and learning (e.g. adaptation of a step according to the height of stairs)

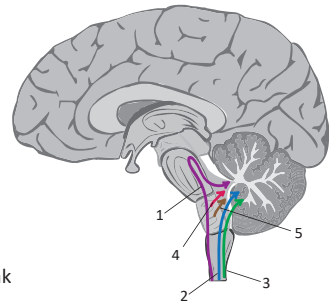

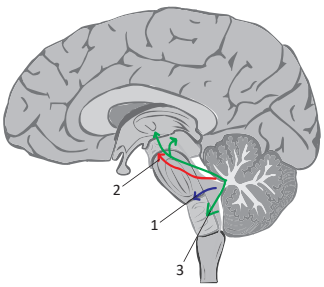

Efferent information to the reticular formation and red nucleus

– from the globose, emboliform and older part of dentate nucleus

- 1 **To the reticular formation** – and via the reticulospinal tract to the spinal cord
- 2 **To the red nucleus (magnocellular part)** – and via the rubrospinal tract to the spinal cord
- 3 **To the olivary nuclei, tectum of midbrain and motor nuclei of thalamus**

Function

– the spinocerebellum is responsible for motion control and control of proximal limbs flexors and extensor tone

Neocerebellum

Afferent information from the cerebral cortex

- 1 **From the primary and secondary motor areas**
- 2 **From all association areas**
  - – the corticopontocerebellar tract runs through the internal capsule and cerebral crura to the pontine nuclei where it interpolates
  - – it decussates and continues via the middle cerebellar peduncle to the cerebellar cortex
  - – in the cerebellum it continues as mossy fibers terminating at granule and Golgi cells

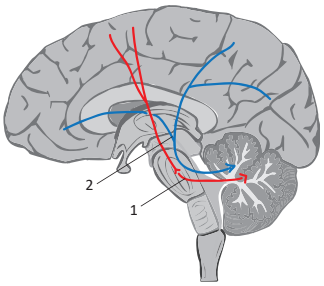

Efferents to the cerebral cortex (from the dentate nucleus)

- 1 **To the motor cortex** – via the thalamic motor nuclei (lateral ventral and anterior ventral nucleus)
  - – then from the cerebral cortex the axons run to the spinal cord (corticospinal tract) and to the brainstem to the cranial nerves motor nuclei (corticonuclear tract)
- 2 **To the basal nuclei**
- 3 **To the motor nuclei (structures) of brainstem**

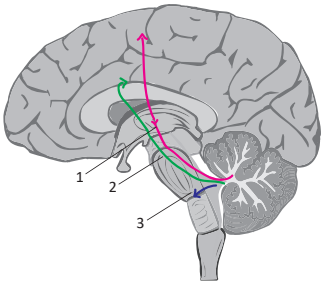

Function:

– the neocerebellum is responsible for fine movement planning, also starts and ends movement in the time frame, controls the alternation of fast and opposing movements
– diadochokinesis, e.g. pronation-supination or flexion-extension

This copy belongs to ali yaghoubi

Afferents

1 **From the vestibular organ to the vestibulocerebellum**
- 1.1 Primary vestibulocerebellar tract (*tractus vestibulocerebellaris directus*)
- 1.2 Secondary vestibulocerebellar tract (*tractus vestibulocerebellaris indirectus*)

2 **From the spinal cord to the spinocerebellum**
- 2.1 Anterior spinocerebellar tract (*tractus spinocerebellaris anterior*)
- 2.2 Posterior spinocerebellar tract (*tractus spinocerebellaris posterior*)
- 2.3 Cuneocerebellar tract (*tractus cuneocereballaris*)
- 2.4 Rostral spinocerebellar tract (*tractus spinocerebellaris rostralis*)
- 2.5 Trigeminocerebellar tract (*tractus trigeminocerebellaris*)
- 2.6 Spino-olivocerebellar tract (*tractus spinoolivocerebellaris*)

3 **From the cerebral cortex to the neocerebellum**
- 3.1 Corticopontocerebellar tract (*tractus corticopontocerebellaris*)

Efferents

– efferent information from the cerebellar cortex runs only via axons of Purkinje cells

– efferent information from the cerebellum is represented mainly by axons of cerebellar nuclei neurons and only a minority by axons of Purkinje cells in the vestibulocerebellum

1 **From the fastigial nucleus**
- – efferent nucleus of vestibulocerebellum, fibers run via the inferior cerebellar peduncle (juxtarestiform body) uncrossed to:
- 1.1 **Vestibular nuclei** (*nuclei vestibulares*)
- 1.2 Reticular formation (*formatio reticularis*)

2 **From the globose and emboliform nuclei**
- – efferent nuclei of spinocerebellum, fibers run via the superior cerebellar peduncle and decussate in the midbrain and continue to:
- 2.1 **Reticular formation** (*formatio reticularis*)
- 2.2 **Red nucleus** (*nucleus ruber*)
- 2.3 **Inferior olivary complex** (*complexus olivaris inferior*)
- 2.4 **Tectum of midbrain** (*tectum mesencephali*)
- 2.5 **Ventral lateral thalamic nucleus** (*nucleus ventralis lateralis thalami*)

3 **From the dentate nucleus**
- – efferent nucleus of neocerebellum, fibers run via the superior cerebellar peduncle and decussate in the decussation of superior cerebellar peduncles (decussatio pedunculorum cerebellarium superiorum) and continue into:
- 3.1 **Ventral lateral thalamic nucleus** (*nucleus ventralis lateralis thalami*) and primary motor cortex (area 4)
- 3.2 Red nucleus (*nucleus ruber*)
- 3.3 Reticular formation (*formatio reticularis*)
- 3.4 Nuclei of cranial nerves and pretectal area

The input to the cerebellum input is 40 times larger than its output. Afferent signals are processed in the cerebellar cortex, a response is formed and transmitted via Purkinje cells and cerebellar nuclei. The cerebellum uses this afferent information to ensure that intended movements are occurring correctly. It is able to adjust any mistakes to these movements.

Imagine 40 medical students who do not understand the function of the cerebellum properly. They all direct questions to one teacher. The teacher has to process all these 40 questions and give just one complex response that will satisfy all the students.

The cerebellum is one of the most sensitive parts of the brain to alcohol. The motor effects of alcohol (clumsiness, loss of balance, blurry vision) are caused by cerebellar dysfunction. A patient with a cerebellar disorder (e.g. stroke, tumour or a degenerative disease) may constantly experience these symptoms.

Clinical notes

From clinical point of view, the cerebellum is in divided into three zones, each with it's own associated symptoms:
1) **Vermal zone** – balance impairment, titubations and nystagmus.
2) **Paravermal zone** – impairment in speed modulation of movement, muscle strength and muscle tone.
3) **Lateral zone** – impairment in initiating movements, motor timing, ataxia, asynergy, dysmetry, rebound phenomena and kinetic tremor.

Disorders of the vestibulocerebellum and spinocerebellum manifest as gait disturbances, vertigo, nystagmus, titubation and falls.

Neocerebellar damage is characterised by ataxia, dysmetria, intention tremor (a tremor which increases in intensity during movement and is not present at rest), dysdiadochokinesis (impairment rapid repetitive movements), saccadic movements (disruption to the fluidity of movements), dysarthria, megaphonia and macrographia. Movements are fragmented and speech is saccadic (jerky and irregular).

Internal structure of the cerebellar peduncles

1 **Inferior cerebellar peduncle**
Afferents:
1.1 Posterior spinocerebellar tract (*tractus spinocerebellaris posterior*)
1.2 Olivocerebellar tract (*tractus olivocerebellaris*)
1.3 Vestibulocerebellar tract (*tractus vestibulocerebellaris*)
1.4 Rostral spinocerebellar tract (*tractus spinocerebellaris rostralis*)
1.5 Cuneocerebellar tract (*tractus cuneocerebellaris*)
1.6 Trigeminocerebellar tract (*tractus trigeminocerebellaris*)
1.7 Reticulocerebellar tract (*tractus reticulocerebellaris*)
Efferents:
1.8 Cerebelloreticular tract (*tractus cerebelloreticularis*)
1.9 Cerebellospinal tract (*tractus cerebellospinalis*)
1.10 Cerebello-olivary tract (*tractus cerebelloolivaris*)
1.11 Cerebellovestibular tract (*tractus cerebellovestibularis*)

2 **Middle cerebellar peduncles**
Afferents:
2.1 Corticopontocerebellar tracts (*tractus corticopontocerebellares*)

3 **Superior cerebellar peduncles**
Afferents:
3.1 Anterior spinocerebellar tract (*tractus spinocerebellaris anterior*)
3.2 Tectocerebellar tract (*tractus tectocerebellaris*)
Efferents:
3.3 Cerebellothalamic tract (*tractus cerebellothalamicus*)
3.4 Dentatorubral tract (*tractus dentatorubralis*)
3.5 Cerebellotegmental tract (*tractus cerebellotegmentalis*)
3.6 Cerebello-olivary tract (*tractus cerebelloolivaris*)
3.7 Cerebellovestibular tract (*tractus cerebellovestibularis*)

Cerebellar control circuit (of Papez)

– signal inputs from the inferior olivary complex gets information from many structures involved in motor control (spinal cord, cortex, reticular formation, tectum of midbrain or vestibular nuclei)
– inside the circuit, the entering impulses are compared with the efferent activity of cerebellum (mediated mainly via red nucleus)
– involved in motor control and participates in fast modification of motor patterns depending on changing conditions
● 1. from the **dentate nucleus**
● 2. via the **red nucleus** (parvocellular part)
● 3. to the **inferior olivary complex**
● 4. coming back to the **dentate nucleus**

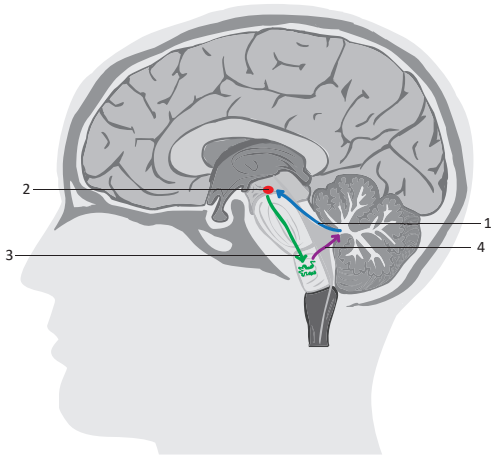

Cerebellar functions overview

1 Participates in **fine motor control**
2 Participates in **stability and gait control**
3 Responsible for **initiation, processing, direction and termination of movement pattern**
4 Regulates **muscle tone**
5 Participates in **motor memory of motor and speech patterns**

This copy belongs to ali yaghoubi

The diencephalon is a group of nuclei surrounding the third ventricle, which connects the brainstem to the telencephalon. It is involved in the processing of somatosensory, special sensory and motor information. According to the distribution and function of its nuclei, the diencephalon is divided into six parts: thalamus, metathalamus, hypothalamus, epithalamus, subthalamus and thalamus opticus. The diencephalon develops from the prosencephalon, an embryological structure that give rise to both the diencephalon and the telencephalon.

Topography

- 1 **Rostrally:** optic chiasma
- 2 **Rostrally:** frontal lobe
- 3 **Caudally:** midbrain
- 4 **Medially:** third ventricle
- 5 **Laterally:** internal capsule
- 6 **Laterally:** basal nuclei
- 7 **Basally:** cranial base
- 8 **Dorsally:** corpus callosum
- 9 **Dorsally:** septum pellucidum

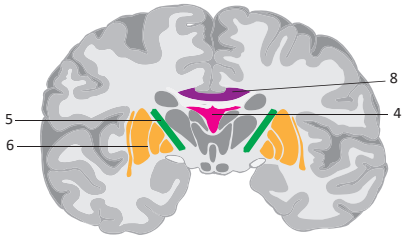

Frontal section of the brain

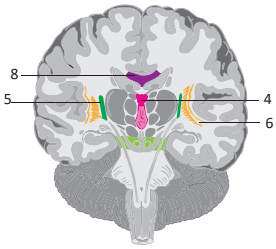

Frontal section of the brain

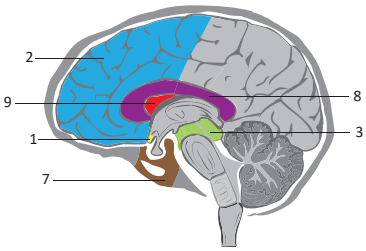

Sagittal section of the brain

Division

- 1 **Thalamus**
  – interconnection of afferent pathways to the cortex
- 2 **Metathalamus**
  – the caudal part of the thalamus containing the nuclei of the visual and auditory tracts
- 3 **Hypothalamus**
  – a control centre of autonomic and endocrine functions
- 4 **Epithalamus**
  – its main part is the pineal gland
- 5 **Subthalamus**
  – nuclei and tracts involved in motor and emotional neuronal patterns
- 6 **Thalamus opticus**
  – the basal part containing a part of the optic nerve, chiasma, and optic tract

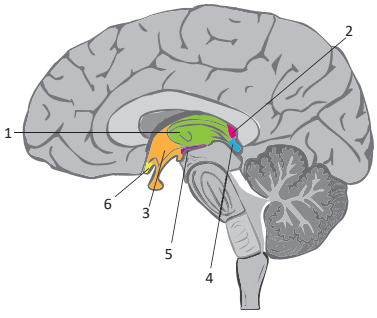

Sagittal section of the brain

Development

Somatosensory and sensory parts of the diencephalon
– thalamus, metathalamus and epithalamus
– are derived from the alar plate
– are located above the hypothalamic sulcus

Motor parts of the diencephalon
– hypothalamus and subthalamus
– are derived from the basal plate
– are situated below the hypothalamic sulcus

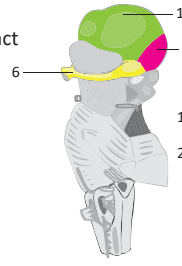

Brainstem and diencephalon, lateral view

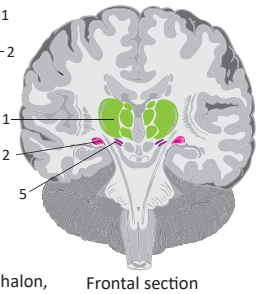

Frontal section of the brain



The pineal body and epiphysis cerebri are synonyms of the pineal gland.

Darkness stimulates melatonin production. Melatonin levels increase throughout the night.

Luys´ body (*corpus Luysi*) is an obsolete term for the subthalamic nucleus.

Zona incerta means "uncertain zone". Its function is not fully elucidated.

The hypothalamic sulcus is derived from the sulcus limitans and the third ventricle represents an enlargement of the central canal.

The metathalamus forms the dorsal part of the thalamus containing the auditory medial geniculate body (*corpus geniculatum mediale*) and the visual lateral geniculate body (*corpus geniculatum laterale*).

Habenula is a Greek term meaning a bridle. It is thus named because the stria medullaris of the thalamus resembles reins attached to the habenular trigones.

The H fields (Haubenfelder) are named according to the parable with a German helmet with a crest. Forel´s field H is formed by a fusion of the ansa lenticularis and lenticular fascicle.

The stria medullaris of the thalamus contains fibres from the amygdaloid body, hippocampal formation, hypothalamus, septum verum, preoptic area and olfactory tubercle.

From the developmental point of view, the diencephalon consists of the rostral diencephalon and the caudal diencephalon. The rostral diencephalon consists of the hypothalamus. The caudal diencephalon consists of the pretectum (including the pretectal area), the posterior commissure and the thalamus (including the epithalamus, metathalamus prethalamus, zona incerta, reticular nuclei of the thalamus and the subthalamus with the subthalamic nucleus). The preoptic area is considered to be a separate part.

The epithalamus is the caudal most part of the diencephalon. It consists of the **pineal gland** the paired **habenular nuclei**. The pineal gland controls circadian rhythm through the secretion of melatonin. The habenular nuclei form part of the limbic system circuits for the creation of emotional responses to sensory stimulation.

- 1 **Pineal gland** (*glandula pinealis*) – a neuroendocrine gland
  synthesizing the hormone called melatonin, it communicates reciprocally with the suprachiasmatic nucleus of hypothalamus
  – is involved in circadian and circannual biorhythms
  – has impact on sleep, vigilance, and sexual activity and its regulation
- 2 **Habenular trigone** (*trigonum habenulare*)
  – follows the stria medullaris of thalamus
  – the habenular nuclei are situated under it
- 3 **Habenular nuclei** (*nuclei habenulares*)
  – the nuclei of the limbic system localized in the habenular trigone
  – receive afferents from the amygdaloid body, hippocampal formation, septum verum, hypothalamus, and olfactory tubercle via the stria medullaris of thalamus
  – efferents goes to the interpeduncular nucleus, tectum of midbrain, thalamus, and reticular formation
  – represent a center for emotional integration of olfactory, somatosensory, and viscerosensory information
- 4 **Habenular commissure** (*commissura habenularum*)
  – a connection between the right and left habenular trigone
- 5 **Posterior commissure** (*commissura posterior*)
  – **Commissural fibers**: connecting the posterior thalamic nuclei, superior colliculus, and pretectal nuclei
  – **Decussation fibers**: projection fibers carrying information from the interstitial nucleus of Cajal and elliptic nucleus of Darkschewitsch then continue into the medial longitudinal fasciculus, which represents a tract of the vestibulo-oculo-motor reflexes

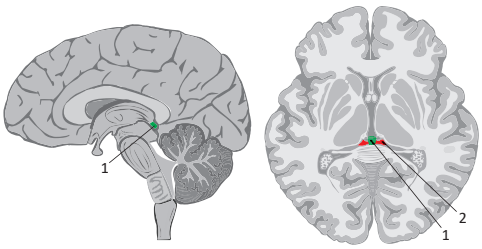

Sagittal and cross-section of the brain

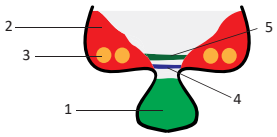

Scheme of the epithalamus (detail of the frontal section)

The subthalamus lies ventrally to the thalamus. It contains the subthalamic nucleus, which is part of the basal ganglia and the zona incerta, which is the most rostral part of the reticular formation. The largest white matter structure of the subthalamus is the pallido-thalamic tract.

Nuclei

- 1 **Subthalamic nucleus of Luys** (*nucleus subthalamicus*)
  – functionally it represents a component of the basal nuclei loops
  – receives afferents from the lateral globus pallidus and precentral gyrus
  – efferents go to the lateral and medial globus pallidus
- 2 **Reticular nuclei and zona incerta**
  – the nuclei are described as the reticular nuclei (*nuclei reticulares*) but they are not related to the ascending reticular activation system (ARAS)
  – receive afferents via the excitation collaterals from the specific thalamic nuclei
  – efferents are dominantly inhibitory (GABA-ergic) and go into the thalamus and basal nuclei
  – these nuclei are responsible for determining new impulses and distinguishing them from known stimuli, they are also involved in body temperature control

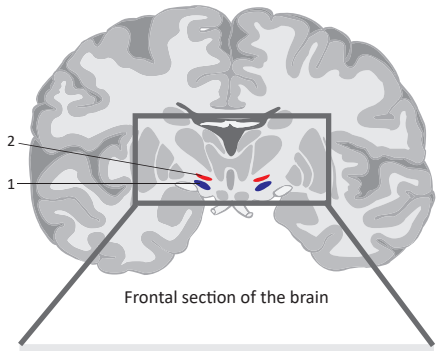

Frontal section of the brain

Tracts and pathways

- 3 **Thalamic fasciculus / Forel´s field H1** (*fasciculus thalamicus*)
  – the white matter between the thalamus and zona incerta containing the pallido-thalamic fibers
  – a part of the motor basal nuclei loops
- 4 **Lenticular fasciculus / Forel´s field H2** (*fasciculus lenticularis*)
  – the white matter between the zona incerta and subthalamic nucleus containing the pallido-thalamic fibers
- 5 **Ansa lenticularis / Forel´s field H** – the fibers running around the posterior part of the internal capsule containing the pallido-thalamic tracts
- 6 **Subthalamic fasciculus** (*fasciculus subthalamicus*)
  – contains connections of the globus pallidus and subthalamic nucleus

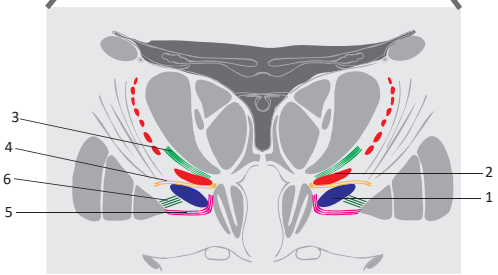

Frontal section of the diencephalon (detail)

This copy belongs to ali yaghoubi

The thalamus is the largest structure in the diencephalon. It is bound laterally by the internal capsule and medially by the third ventricle. It consists of a group of nuclei that have various functions. The main role of these nuclei is to **relay sensory information to the cortex**. Other nuclei are involved in motor circuits, the limbic system and the reticular formation.

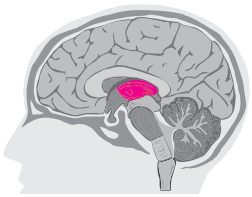

The optic nerve develops as a outpocketing of the diencephalon called the optic vesicle. That is why it is covered by meninges, unlike the proper cranial nerves.

The internal medullary lamina of the thalamus (*lamina medullaris medialis thalami*) contains connections between the thalamic nuclei and intralaminar thalamic nuclei. This plate of white matter divides different groups of nuclei.

Topography

- 1 **Rostrally:** columns of fornix, frontal horn of lateral ventricle and head of caudate nucleus
- 2 **Basally:** midbrain and its pretectal area, metathalamus
- 3 **Medially:** third ventricle
- 4 **Laterally:** internal capsule
- 5 **Ventrally:** hypothalamus and subthalamus
- 6 **Dorsally:** central part of lateral ventricle

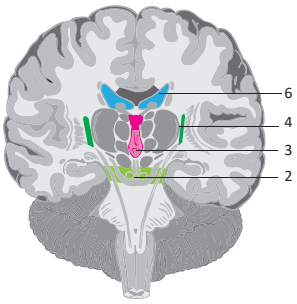

Frontal section of the brain

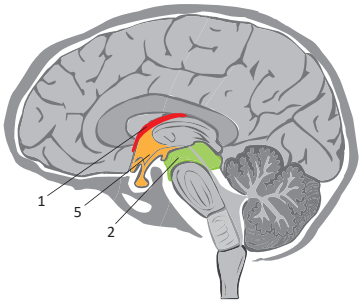

Sagittal section of the brain

External features

- 1 **Anterior tubercle** (tuberculum anterius)
  – a rostral narrowing with the anterior nuclei underneath
- 2 **Interthalamic adhesion** (*adhesio interthalamica*)
  – connecting the right and left thalamus
- 3 **Pulvinar** (*pulvinar thalami*)
  – a dorsal enlargement with the posterior nuclei underneath
- 4 **Stria terminalis**
  – containing fibers from the amygdaloid body to the hypothalamus, runs together with the superior thalamostriatic vein
- 5 **Choroid line** (*taenia choroidea*)
  – the attachment of the tela choroidea of lateral ventricle
- 6 **Lamina affixa**
  – the smooth superior surface of the thalamus covered by ependyma (localized between the choroid line and stria terminalis)
- 7 **Taenia thalami**
  – the attachment of the third ventricle roof situated between the medial and superior surface of the thalamus
- 8 **Stria medullaris of thalamus** (*stria medullaris thalami*)
  – containing fibers from the limbic system running to the habenular trigone (fibers run under the taenia thalami)

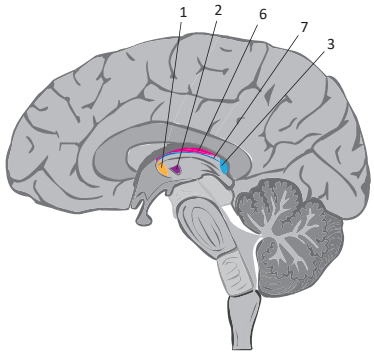

Sagittal section of the brain

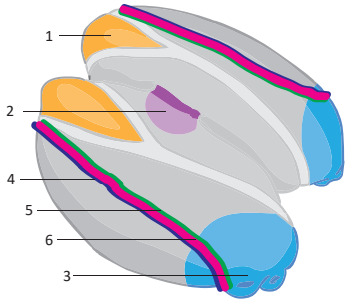

Scheme of the left and right thalamus, left view from above and behind

Clinical notes

Thalamic damage is usually caused by ischemic or hemorrhagic stroke. We distinguish the following thalamic syndromes according to their clinical manifestations:

Posterolateral thalamic syndromes – usually the contralateral somatosensory and sensory afferents are affected as well as pain perception as a result of damage in the thalamo-cortical and cortico-thalamic projection.

Dejerine-Roussy syndrome (central pain syndrome) is a result of damage in the ventroposterolateral and ventroposteromedial nuclei. It could lead to uncontrollable pain sensation usually without an appropriate response to analgetics or opioids. This disorder is caused by a dysfunction of the thalamo-cortical and cortico-thalamic feedback circuits.

Medial thalamic syndromes can manifest as thalamic neglect, impairment of consciousness, akinesis, anosognosia (the lack of awareness of one's own disability) and hypobulia (the lack of emotions).

Anterolateral thalamic syndromes usually manifest with contralateral paresis, uncoordinated movements and dysphagia.

Nuclear groups and thalamic white matter

- 1 **Anterior group**
- 2 **Medial group**
- 3 **Lateral group**
- 4 **Intralaminar and paraventricular nuclei**
- 5 **Rostral nuclei of reticular formation**
- 6 **Metathalamic nuclei**
- 7 **Internal medullary lamina of thalamus**
- 8 **External medullary lamina of thalamus**

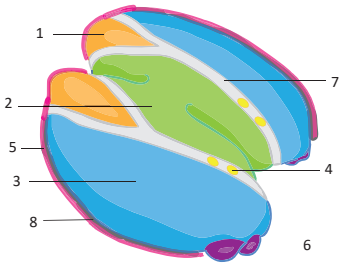

Scheme of the left and right thalamus, left view from above and behind

Anatomical classification of the nuclei

1 **Anterior group**
- 1.1 **Anterior nuclei** (*nuclei anteriores*) **„A“**
  – divided by two branches of the internal medullary lamina

2 **Medial group**
- 2.1 **Medial dorsal nuclei / dorsomedial nucleus** (*nucleus mediodorsalis*) **„MD“**

3 **Lateral group** – divided into the dorsal and ventral row

Dorsal group
- 3.1 **Lateral dorsal nucleus** (*nucleus lateralis dorsalis*) **„LD“**
- 3.2 **Lateral posterior nucleus** (*nucleus lateralis posterior*) **„LP“**
- 3.3 **Posterior nuclear complex** (*nuclei posteriors*) **„P“**

Ventral group
- 3.4 **Ventral anterior nucleus** (*nucleus ventralis anterior*) **„VA“**
- 3.5 **Ventral lateral complex** (*nucleus ventrales laterales*) **„VL“**
- 3.6 **Ventral posterolateral nucleus** (*nucleus ventralis posterolateralis*) **„VPL“**
- 3.7 **Ventral posteromedial nucleus** (*nucleus ventralis posteromedialis*) **„VPM“**

4 **Intralaminar and paraventricular nuclei**
- 4.1 **Intralaminar nuclei** (*nuclei intralaminares*) **„IL“**
- 4.2 **Paraventricular nuclei** (*nuclei paraventriculares*) **„PV“** and **Median nuclei** (*nuclei mediani*) **„MI“**

5 **Rostral nuclei of reticular formation**
- 5.1 **Reticular nucleus of thalamus** (*nucleus reticularis thalami*) **„R“**

6 **Metathalamic nuclei**
- 6.1 **Medial geniculate nuclei** (*nuclei corporis geniculati mediales*) **„CGM“**
- 6.2 **Lateral geniculate nuclei** (nuclei corporis geniculati laterales) **„CGL“**

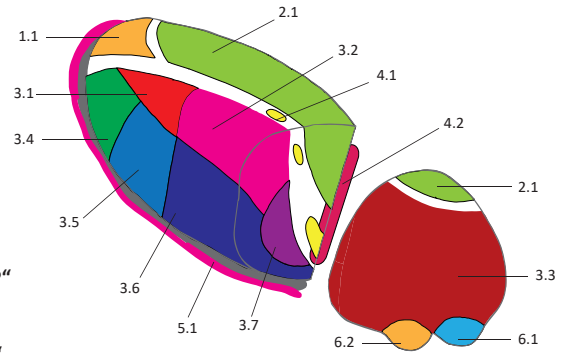

Scheme of the left thalamus, left view from above and behind

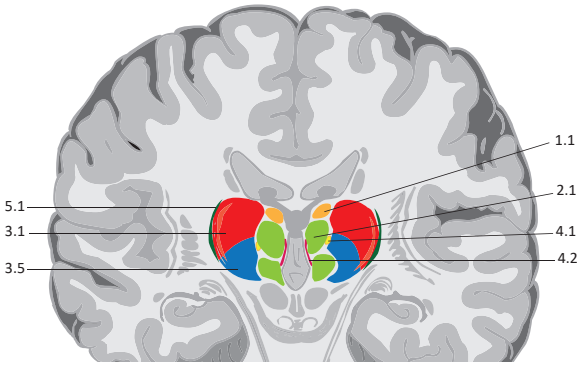

Frontal section of the brain

Functional classification

- 1 **Association** – responsible for integration of different stimuli
- 2 **Non-specific** – associated with the activity of the reticular formation
- 3 **Specific** – involved in motor, somatosensory and sensory tracts and circuits

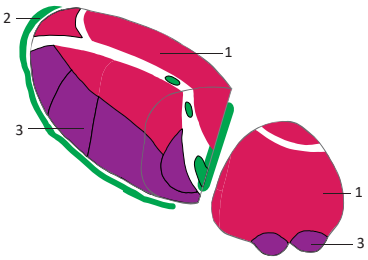

Scheme of the left thalamus, left view from above and behind

Function

1 **Interconnection point of all information** running to the cortex, except of olfactory stimuli
2 **Regulation of consciousness** (thalamo-cortical feedback)
3 **Impact on autonomic functions** (thalamus and hypothalamus interactions)
4 **Impact on emotions** – cheerfulness, sadness and anger (thalamus and limbic system interactions)
5 **Impact on motor function and regulation** (thalamus, cerebellum, basal nuclei, cortex and brainstem nuclei integration)

This copy belongs to ali yaghoubi

Association nuclei

Posterior nuclei (PO)
Lateral dorsal nucleus (LD)
Lateral posterior nucleus (LP)

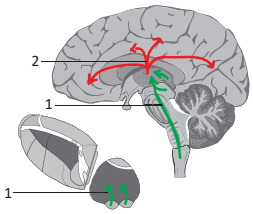

- 1 **Afferents**
  - – from the spinal cord (spinothalamic tract)
  - – superior colliculus (to LP and PO)
  - – pretectal area and geniculate bodies
- 2 **Efferents and reciprocal connections**
  - – to all the association areas
  - – to all the structures of the limbic system

  Funkce:
  - – the PO is responsible for the integration of visual, auditory, tactile and vestibulocochlear stimuli
  - – the LP and PO are responsible for focusing of attention onto objects in the periphery of visual field

Anterior nuclei (A)

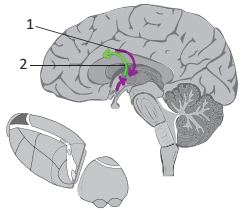

- 1 **Afferents**
  - – from the hypothalamus, hippocampus, and cingular gyrus
- 2 **Efferents**
  - – to the cingular gyrus (BA 23, 24, 32)

  Function: association with the limbic system circuits (repetitive circling intensifies emotions)

Medial nuclei (M) **/ Mediodorsal nuclei** (MD)

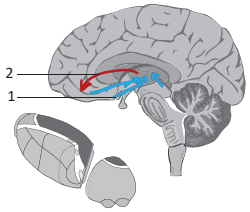

- 1 **Afferents**
  - – from the prefrontal areas, olfactory areas, amygdaloid body, hypothalamus, superior colliculus, and substantia nigra
- 2 **Efferents**
  - – to the prefrontal areas

  Function: regulation of cognitive processes and consolidation of memory (thinking, judgement, temper, and state of mind) and integration them with sensual stimuli

Nonspecific nuclei

Intralaminar nuclei (IL)
Median nuclei (MI) **/ Paraventricular nuclei**

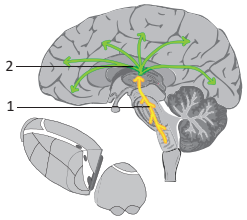

- 1 **Afferents**
  - – mostly from the reticular formation
  - – other thalamic nuclei, hypothalamus and limbic nuclei
- 2 **Efferents**
  - – are diffuse and run to all cortical areas

  Function: activation of the cortex, basal nuclei, and thalamic nuclei, involvement in the ascending reticular activation system,
  - – the IL nuclei are involved in slow pain processing and transmission

Reticular nucleus of thalamus (R)

– communicates with the zona incerta which represents a part of the reticular formation in the subthalamic region

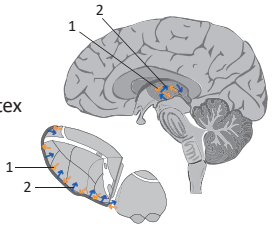

- 1 **Afferents**
  - – excitatory from the other thalamic nuclei and from the cortex
- 2 **Efferents**
  - – inhibitory to the other thalamic nuclei, midbrain
  - – only a minimal amount of information gets directly into the cortex

  Function: responsible for tuning of stimuli running between the thalamus and cortex
  - – suppresses activity of the other thalamic nuclei
  - – it represents the reticular formation nuclei in the thalamus, but it is not a part of the ARAS
  - – the important function is to distinguish new stimuli from habitual and familiar ones

Thalamic function can be compared an efficient and hard-working secretary delivering news to specialised areas of the brain cortex.

The VPL and VPM nuclei are collectively known as the ventrobasal complex (*nuclei ventrobasales*).

The sensory neurones in the nuclei of the thalamus are not randomly arranged. They have a somatotopic organisation, which means that specific areas of the body are represented in specific parts of the nuclei. The primary somatosensory cortex also has a similar somatotopic organisation, called the somatosensory homunculus.

Specific sensory nuclei have similar organization:

Retinotopic organisation refers is the representation of the visual on to the lateral geniculate body.

Tonotopic organisation refers to the representation of different frequencies of sound to different parts of the medial geniculate body.

An example of integration and processing of complex stimuli in the association nuclei of thalamus:
Imagine this situation: You are sitting in a superb, expensive restaurant. You have already chosen delicacies which are served by a congenial waiter/waitress. The atmosphere is lifted up by melodic music and bubbles from a beautiful aquarium containing exotic fish. The food looks great, the smell is amazing, and it tastes delicious. The association nuclei are responsible for this complex perception.

Specific sensory nuclei

Ventral posterolateral nucleus (VPL)

- 1 **Afferents** – from the spinal cord
  - – the medial lemniscus transmitting fine touch, vibration, and conscious proprioceptive information as well as tactile pressure, barognosis, graphestesia, stereognosis, kinesthesia, and two-point discrimination
  - – the spinothalamic tract carrying crude touch and itch, fast pain, and thermal information
- 2 **Efferents** – to the primary somatosensory area (BA 3, 1, 2) in the postcentral gyrus

  Function: somatosensory information from the trunk and limbs

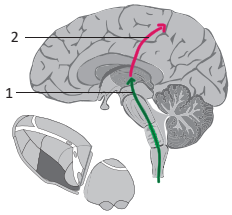

Ventral posteromedial nucleus (VPM)

- 1 **Afferents** – from the trigeminal nerve
  - – the trigeminal lemniscus and posterior trigemino-thalamic tract (mechanoperception) transmitting fine touch, vibration, and conscious proprioceptive information as well as tactile pressure, barognosis, graphestesia, stereognosis, kinesthesia, two-point discrimination and crude touch and itch, fast pain, and thermal information from the head.
- 2 **Efferents** – to the primary somatosensory area for the head (BA 3, 1, 2) in the postcentral gyrus

  Function: somatosensory information from the head
- 3 **Afferents** – from the gustatory nucleus (solitaire-thalamic tract)
- 4 **Efferents** – to the gustatory area (BA 43) in the inferior frontal gyrus (its opercular part)

  Function: sense of taste

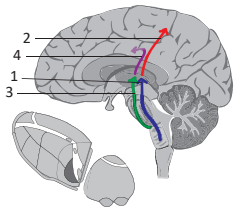

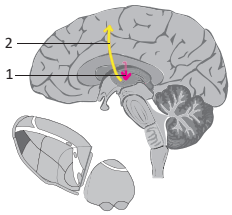

Specific motor nuclei

Anterior ventral nucleus (VA)

- 1 **Afferents** – mainly from the lobus pallidus, reticular formation, substantia nigra, and cerebellum
- 2 **Efferents** – to the preemptor area (BA 6) in the frontal gyri

  Function: motor circuits of basal nuclei and motor planning and control

Lateral ventral complex (VL)

- 1 **Afferents** – mainly from the cerebellum, globus pallidus, red nucleus, and substantia nigra
- 2 **Efferents** – to the primary motor area (BA 4) in the precentral gyrus

  Function: motor circuit of cerebellum, basal nuclei, and cortex

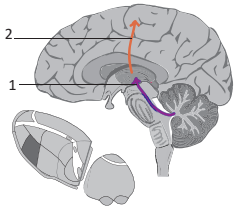

Specific sensory nuclei

Medial geniculate nuclei (CGM)

- 1 **Afferents** – from the auditory apparatus
  - – cochlear nuclei, superior olivary complex, inferior colliculi, and reciprocal connections with the primary auditory area
- 2 **Efferents** – to the primary auditory area (BA 41, 42) in the transverse temporal gyri (of Heschl) and superior temporal gyrus, with divisions to the inferior colliculi (centers of the brainstem auditory reflexes)

  Function: transmission of auditory information to the cortex

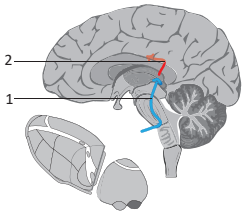

Lateral geniculate nuclei (CGL)

- 1 **Afferents** – from the visual apparatus
  - – from the cells of the retinal ganglion via the optic tract and reciprocal connections with the primary visual cortex (A 17)
- 2 **Efferents** – to the primary visual cortex (A 17) in the calcarine sulcus and its vicinity

  Function: transmission of visual information to the cortex

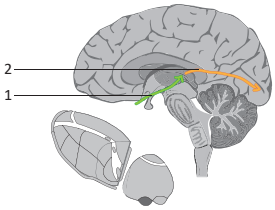

This copy belongs to ali yaghoubi

The hypothalamus lies underneath the thalamus. It contains various groups of nuclei with different functions. It contains nuclei that control the cardiovascular system and regulate body temperature, thirst and hunger. **Through the hypothalamo-hypophyseal axis, the hypothalamus has a strong influence over the endocrine system**. The hypothalamus also contains centres that **control behaviour** (anger, fury and sexual behaviour).

Topography

- 1 **Dorsally:** thalamus
  2 **Medially:** third ventricle
  3 **Laterally:** internal capsule
- 4 **Rostrally:** telencephalon
- 5 **Occipitally (caudally):** tegmentum of midbrain

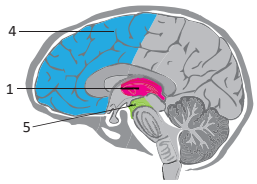

Sagittal section of the brain

External features

- 1 **Infundibulum** – a stalk connecting the hypothalamus and hypophysis
- 2 **Tuber cinereum** – an elevated spot on the base to which the infundibulum is attached
  2.1 **Median eminence** (*eminentia mediana*)
  – a part of the tuber cinereum situated behind the infundibulum (one of the circumventricular organs)
- 3 **Mammillary bodies** (*corpora mammillaria*)
  – oval tubercles between the tuber cinereum and posterior perforated substance
  – elevated by the homonymous nuclei situated underneath (part of the limbic system nuclei)
  4 **Posterior perforated substance** (*substantia perforata posterior*)
  – in the interpeduncular fossa
  – it forms a borderline between the hypothalamus and midbrain
  – central arteries pass via these perforations

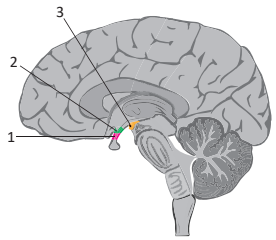

Afferents

- 1 **From the frontal association areas**
- 2 **From the hippocampus**
- 3 **From the amygdaloid body**
- 4 **From the visual tract**
- 5 **From the spinal cord and medulla oblongata**
  – directly or through the thalamus

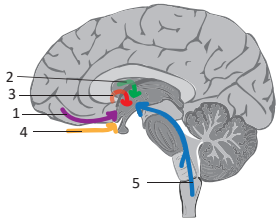

Efferents

- 6 **To the hypophysis**
- 7 **To the thalamus**
- 8 **To the limbic system**
- 9 **To the autonomic nuclei of brainstem and spinal cord**

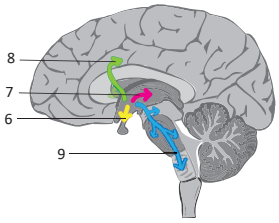

Functions

1 **Primary center of the autonomic nervous system**
– control function of the visceromotor brainstem and spinal cord centers, influencing the activity of sympathetic and parasympathetic and emotional reaction of the limbic system
2 **Primary centers of the endocrine functions**
– endocrine axis hypothalamus-hypophysis-endocrine glands
– synthesis of hormones important for metabolism, growth, sexual activity, lactation, water metabolism, stress reaction, and thyroid gland activity
3 **Vital function controlling**
– food, water and salt intake and homeostasis and homeostasis
– the centers of hunger, thirst, osmolality (concentration of solutes in blood plasma), thermoregulation, blood control, and heart rate activity are situated in the hypothalamus
4 **Influence on circadian rhythms, sexual behavior and reproduction**

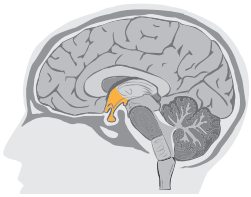

The neurones of the hypothalamus are organised into nuclei and areas.
Nuclei are clusters of densely packed neurones of a single type with well-demarcated borders.
Areas are formed by different types of neurones, which are diffusely organised and do not have strict borders.

The hypothalamus can be divided into the anterior, middle, and posterior hypothalamus.

The medial preoptic nucleus (*nucleus preopticus medialis*) and the anterior interstitial nuclei (*nuclei interstitials anteriores*) are important for sexual function and development. They contain a different number of neurones in males and females and their development depends on prenatal testosterone levels. They produce gonadotropin-releasing hormone (GnRH) and are responsible for the different secondary sex characteristics of males and females.

Oxytocin increases stimulates uterine contractions and milk ejection.

Hypothalamic functions:
Anterior hypothalamus:
fever, sleep, and alertness
Posterior hypothalamus:
decreases body temperature
Medial hypothalamus:
increases satiety
(ventromedial nucleus)
Lateral hypothalamus:
hunger, thirst, and anger

Hypothalamo-hypophyseal system
see page 523.

Clinical notes

The thermoregulatory centres are responsible for the shivering and fever.

Damage of the lateral hypothalamic zone (centre of hunger) can lead to the partial or complete loss of appetite.

Damage to the ventromedial nucleus can lead to compulsive eating (hyperphagia).

Classification into the zones

In the frontal plane (mediolateral direction):

- 1 **Periventricular zone** – close to the third ventricle (paraventricular nucleus, part of the preoptic nucleus, and posterior hypothalamic nucleus)
- 2 **Medial zone** (in the middle) – preoptic nucleus, anterior hypothalamic nucleus, supra-optic nucleus, suprachiasmatic nucleus, ventromedial nucleus, dorsomedial nucleus, arcuate nucleus, and mammillary nuclei
- 3 **Lateral zone** – nearby the internal capsule
  – part of the preoptic nucleus, supra-optic nucleus, and lateral tuberal nuclei

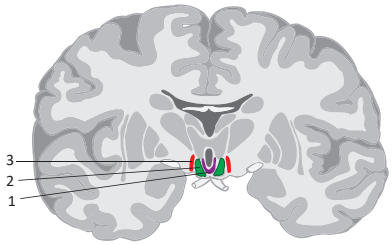

Frontal section of the brain

Classification according to units

In the sagittal plane (rostrocaudal direction):

1 **Anterior unit** – chiasmatic part
- 1.1 **Suprachiasmatic nucleus** (*nucleus suprachiasmaticus*) „SCH“
- 1.2 **Supra-optic nucleus** (*nucleus supraopticus*) „SO“
- 1.3 **Preoptic nucleus** (*nucleus preopticus*) „PO“
- 1.4 **Paraventricular nucleus** (*nucleus paraventricularis*) „PV“
- 1.5 **Anterior nuclei** (*nuclei anteriores*) „A“

2 **Middle unit** – tuberal part
- 2.1 **Dorsomedial nucleus** (*nucleus dorsomedialis*) „DM“
- 2.2 **Ventromedial nucleus** (*nucleus ventromedialis)* „VM“
- 2.3 **Arcuate nucleus** (*nucleus arcuatus*) „AR“

3 **Posterior unit** – mammillary part
- 3.1 **Posterior hypothalamic nucleus** (*nucleus hypothalamicus posterior*) „P“
- 3.2 **Mammillary nuclei** (*nuclei mammillares*) „M“
- 3.3 **Tuberomammillary nuclei** (*nuclei tuberomammillares*) „TM“

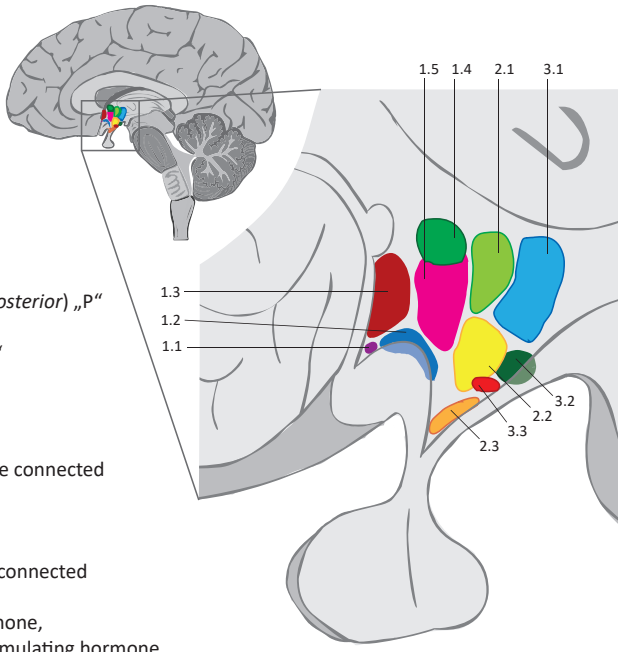

Sagittal section of the hypothalamus (detail)

Classification according to the function

1 **Nuclei synthesizing hormones of the neurohypophysis**
– the **supra-optic nucleus** (SO) and **paraventricular nucleus** (PV) are connected by the hypothalamo-hypophysial tract with the neurohypophysis
– synthesize antidiuretic hormone (ADH/vasopressin) and oxytocin

2 **Nuclei synthesizing hormones of the adenohypophysis**
– the arcuate nucleus, lateral tuberal nuclei, and preoptic area are connected by the tubero-infundibular tract with the adenohypophysis
– control of production of prolactin, somatotropin, luteinizing hormone, adrenocorticotropin, thyroid stimulating hormone, and follicle stimulating hormone

3 **Nuclei controlling activity of the sympathetic and parasympathetic system**
3.1 **Nuclei of mammillary body** (mammillary nuclei, M) – involved in the limbic system, centers controlling circulation, respiration centers in the brainstem, reflexes of the digestive tract (vomiting, swallowing and defecation), and reflexes associated with reproduction (erection, ejaculation)
– efferents run via the posterior longitudinal fasciculus to the reticular formation
3.2 **Medial preoptic nucleus** – decreasing of blood pressure and heart rate
3.3 **Dorsomedial nucleus** – increasing of blood pressure and heart rate
3.4 **Anterior hypothalamic nucleus** – thermoregulation and sweating, impact on thyroid gland activity (TSH production inhibition)
3.5 **Posterior hypothalamic nucleus** – increasing of blood pressure, mydriasis, thermoregulation and muscular shivering

4 **Circadian rhythms control** – suprachiasmatic nucleus (SCH)
– specific afferents from the retina via the retinohypothalamic tract, cooperates with the reticular formation (ARAS) and pineal gland (melatonin production)
– depending on the duration of the day and night, it controls and changes the activity of intrinsic clocks (biorhythms)
– according to variations in sunshine intensity, the activity of the central nervous system, limbic and endocrine system, sexual activity changes accordingly

5 **Nuclei involved in the sleep and awaking cycle**
5.1 **Anterior hypothalamic nucleus and lateral preoptic nucleus** – non-REM sleep
5.2 **Tuberomammillary nucleus** – producing histamine for structures of the central nervous system, it is involved in the sleep-wake cycle, is responsible for arousal reaction by histamine production

6 **Nuclei involved in food intake**
6.1 **Ventromedial nucleus** – center of satiety
6.2 **Dorsomedial nucleus** – involved in sleep regulation, food intake, hormonal axis (especially levels of corticoids), and in blood pressure and heart rate regulation

7 **Nuclei involved in sexual behavior** – medial preoptic nucleus and anterior interstitial nuclei

This copy belongs to ali yaghoubi

The telencephalon is the most rostral part of the brain. It develops from the prosencephalon and contains the highest number of neurons of any part of the brain. The surface of the hemispheres consists of the cortex and is folded into a **system of grooves and ridges**, termed sulci and gyri. The main functions of the telencephalon are **consciousness, sensation, voluntary movements and cognitive functions** (memory, concentration, etc.).

Brain hemispheres

Parts

1 **Pallium**
- 1.1 **Cortex cerebri** – the superficial part formed by neuronal bodies (*perikarya*)
- 1.2 **White substance of brain** (*corpus medullare telencephali*) – the internal portion mainly formed by myelinated fibers

2 **Subpallium**
- 2.1 **Basal ganglia** (*nuclei basales*) – nuclei located in the deep white substance of telencephalon

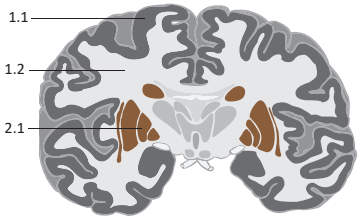

Frontal section of the brain

Surfaces of the telencephalon (*facies*)

- 1 **Facies inferior** – is in contact with the cranial base and in the occipital region in vicinity of the tentorium cerebelli
- 2 **Facies medialis** – is adjacent to the falx cerebri
- 3 **Facies superolateralis** – is the external surface of the hemispheres which is adjacent to the neurocranium

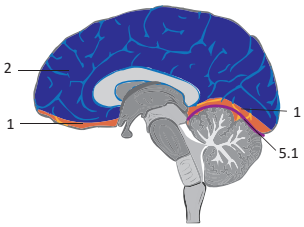

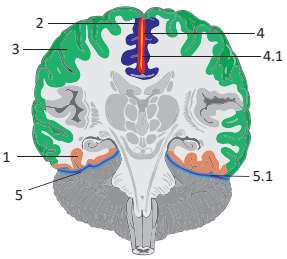

Sagittal and frontal section of the brain

Fissures (*fissurae*)

- 4 **Longitudinal fissure** (*fissura longitudinalis cerebri*) – separating the right and left hemisphere
  - 4.1 **Falx cerebri** – is a duplication of the dura mater inserted between the hemispheres
- 5 **Transverse fissure** (*fissura transversalis cerebri*) – separating the hemispheres of telencephalon and cerebellum
  - 5.1 **Tentorium cerebelli** – is a duplication of the dura mater inserted between the occipital lobes and cerebellum

Lobes (*lobi telencephali*)

- 1 **Frontal lobe** (*lobus frontalis*) – situated in front of the central sulcus, in vicinity to the frontal bone
  - 1.1 **Frontal pole** (*polus frontalis*) – the most rostral part of the telencephalon
- 2 **Parietal lobe** (*lobus parietalis*) – situated behind the central sulcus, in vicinity to the parietal bone
- 3 **Occipital lobe** (*lobus occipitalis*) – in vicinity to the occipital bone and tentorium cerebelli
  - 3.1 **Occipital pole** (*polus occipitalis*) – the caudal-most part of the telencephalon
- 4 **Temporal lobe** *(lobus temporalis*) – adjacent to the temporal bone
  - 4.1 **Temporal pole** (*polus temporalis*)
- 5 **Insular lobe** (*lobus insularis*) – is situated in the lateral cerebral fossa between the temporal, frontal, and parietal lobes

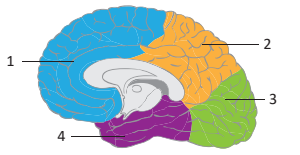

Median surface of the telencephalon

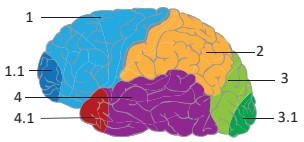

Lateral surface of the telencephalon

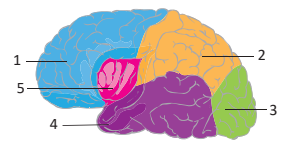

Lateral surface with the open lateral sulcus

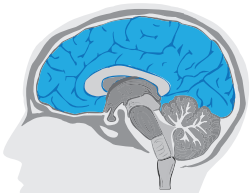

The surface area of the cerebral cortex of an adult brain is about 0.25 m^2.

Cerebrum is a synonym for telencephalon. Encephalon is a synonym for the brain (including cerebellum and brain stem).

Outstanding mathematicians have well-developed left angular gyri and cortex around the intraparietal sulcus.

For a detailed table describing sulci see page 488.

Clinical notes

Brain herniation is the displacement of brain tissue from its normal position. It occurs as a consequence of an expansive lesion in the cranial cavity, such as cerebral oedema, ischaemia, infection, haemorrhage or a tumour.

Subfalcine (cingulate) herniation occurs when the cingular gyrus is displaced under the margin of the falx cerebri. Clinical signs are impairment of consciousness and breathing, and pupillar miosis.

Transtentorial (uncinate) herniation occurs when the parahippocampal uncus herniates under the margin of tentorium cerebelli. Typical signs are usually ipsilateral mydriasis (caused by compression of the parasympathetic fibres of the oculomotor nerve), contralateral palsy, and impairment of consciousness. This type of herniation is most frequently caused by an epidural hematoma of the middle meningeal artery.

Tonsillar herniation occurs when the cerebral tonsils herniate through the foramen magnum, which can be caused by expansive processes in the posterior cerebral fossa. Tonsillar herniation is a life-threatening situation because it results in compression medulla oblongata, which compromises the cardiorespiratory centres. The most common clinical signs of this type of hernia are headache in the occipital region, diplopia, paresis or paralysis and ataxia. Consciousness rapidly deteriorates and death results from cardiorespiratory depression.

Sulci

Interlobar sulci (*sulci interlobares*)

- 1 **Central sulcus of Rolando** (*sulcus centralis*) – is situated between the frontal and parietal lobes
- 2 **Lateral sulcus of Sylvius** (*sulcus lateralis*) – separates the temporal, frontal, and parietal lobes, continues into the lateral cerebral fossa
- 3 **Parietooccipital sulcus** (*sulcus parietooccipitalis*) – is located between the parietal and occipital lobes
- 4 **Preoccipital incisure** (*incisura preoccipitalis*) – is located between the temporal and occipital lobes
- 5 **Calcarine sulcus** (*sulcus calcarinus*) – separates the primary and secondary visual cortices (on the medial surface of the occipital lobe)
- 6 **Circular insular sulcus of Reil** (*sulcus circularis insulae*) – circumscribes and separates the insular lobe at the bottom of the lateral cerebral fossa

Intergyral sulci

- 7 **Rhinal sulcus** (*sulcus rhinalis*) – separates the paleocortex and neocortex (on the inferior brain surface)
- 8 **Cingular sulcus** (*sulcus cinguli*) – separates the cingular gyrus from the frontal and parietal lobes (on the medial brain surface)
- 9 **Collateral sulcus** (*sulcus collateralis*) – separates the occipitotemporal and parahippocampal gyrus from the lateral occipitotemporal gyrus
- 10 **Sulcus of corpus callosum** (*sulcus corporis callosi*) – sulcus separating the corpus callosum and cingular gyrus

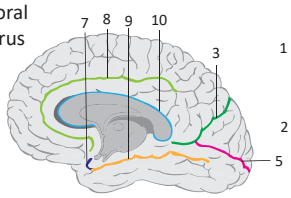

Medial surface of the telencephalon

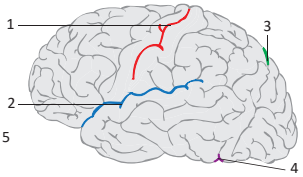

Lateral surface of the telencephalon

Lobes and gyri (Lobi et gyri)

1 **Frontal lobe** (*lobus frontalis*)

Superolateral surface (*facies superolateralis*):

- 1.1 **Precentral gyrus** (*gyrus precentralis*) – primary motor cortex
- 1.2 **Superior, medius and inferior frontal gyrus** (*gyrus frontalis superior, medius et inferior*) – motor and prefrontal cortex

Medial surface (*facies medialis*):

- 1.3 **Medial frontal gyrus** (*gyrus frontalis medialis*) – motor and prefrontal cortex

Inferior surface (*facies inferior*):

- 1.4 **Orbital gyri** (*gyri orbitales*) – prefrontal cortex
- 1.5 **Straight gyrus** (*gyrus rectus*) – prefrontal cortex
- 1.6 **Olfactory bulb** (*bulbus olfactorius*) – part of the rhinencephalon
- 1.7 **Olfactory tract** (*tractus olfactorius*) – part of the rhinencephalon
- 1.8 **Olfactory trigone** (*trigonum olfactorium*) – part of the rhinencephalon

2 **Parietal lobe** (*lobus parietalis*)

- 2.1 **Postcentral gyrus** (*gyrus postcentralis*) – primary somatosensory cortex
- 2.2 **Superior parietal lobule** (*lobulus parietalis superior*) – secondary somatosensory and association cortex
- 2.3 **Inferior parietal lobule** (*lobulus parietalis inferior*) – speech center of Wernicke in the dominant hemisphere, the association cortex for somatosensory and visual information
  - 2.3.1 **Supramarginal gyrus** (*gyrus supramarginalis*)
  - 2.3.2 **Angular gyrus** (*gyrus angularis*)
- 2.6 **Paracentral gyrus** (*gyrus paracentralis*) – part of the precentral and postcentral gyri
- 2.7 **Precuneus** – association cortex

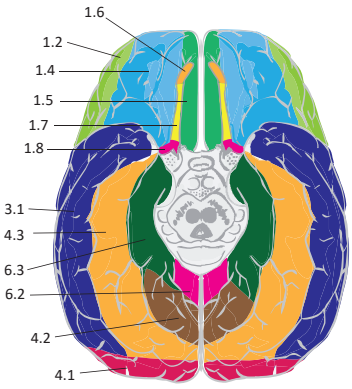

Inferior surface of the telencephalon

3 **Temporal lobe** (*lobus temporalis*)

- 3.1 **Superior, middle and inferior temporal gyrus** (*gyrus temporalis superior, medius et inferior*) – secondary olfactory cortex, limbic and association cortex
- 3.2 **Transverse temporal gyri of Heschl** (*gyri temporales transversi*) – primary auditory cortex
- 3.3 **Medial and lateral occipitotemporal gyrus** (*gyrus occipitotemporalis medialis et lateralis*) – limbic and association cortex

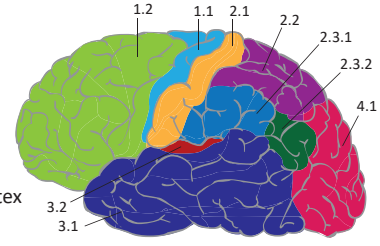

Lateral surface of the telencephalon

4 **Occipital lobe** (*lobus occipitalis*)

- 4.1 **Superior, middle and inferior occipital gyri** (*gyrus occipitalis superior, medius et inferior*) – primary visual and association cortex
- 4.2 **Medial occipitotemporal / lingual gyrus** (*gyrus occipitotemporalis medialis / gyrus lingualis*) – visual association cortex
- 4.3 **Lateral occipitotemporal / fusiform gyrus** (*gyrus occipitotemporalis lateralis / gyrus fusiformis*) – visual association cortex
- 4.4 **Cuneus** – primary and secondary visual cortex

5 **Insular lobe / Insula** (*lobus insularis*)

- 5.1 **Short gyri of insula** (*gyri insulares breves*) – limbic cortex
- 5.2 **Long gyrus of insula** (*gyrus insularis longus*) – limbic cortex

6 **Limbic lobe** (*lobus limbicus*)

- 6.1 **Subcallosal area/gyrus** (*area subcallosa*)
- 6.2 **Cingular gyrus** (*gyrus cinguli*)
- 6.3 **Parahippocampal gyrus** (*gyrus parahippocampalis*)
- 6.4 **Dentate gyrus** (*gyrus dentatus*)

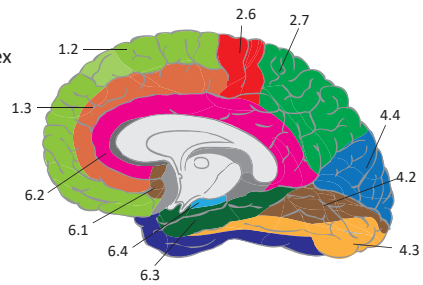

Median surface of the telencephalon

This copy belongs to ali yaghoubi

The cerebral cortex is composed of 3 to 6 layers of neurones. The number of layers corresponds to the phylogenetic age of the cortex. The youngest part is the neocortex, which consists of 6 layers of neurones and covers the majority of the surface area of the hemispheres.

Classification according to the origin

- 1 **Paleocortex**
  - phylogenetically the oldest part of the brain
  - cortex containing 3 layers of neurons
  - covering 1 % of the cortical surface,
  - it is composed of the rhinencephalon ("olfactory brain")
- 2 **Archicortex**
  - containing less than 6 cortical layers
  - covering almost 4 % of the cortical surface
  - it represents the limbic cortex and has close anatomical and synaptic connections with the paleocortex
- 3 **Neocortex**
  - phylogenetically the youngest part of the brain
  - containing 6 layers of neurons
  - covering 95 % of the cortical surface

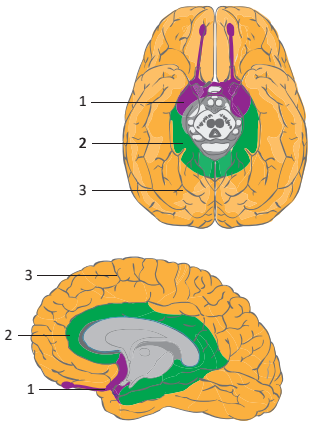

Inferior and medial surface of the telencephalon

Cortical layers

I **Molecular layer** (*lamina molecularis*)
- situated on the cortical surface, containing the fewest amount of neurons
- composed mainly of axons, dendrites, interneurons, and glial cells
- the layer is in contact with the pia mater via the superficial glial limiting membrane

II **External granular layer** (*lamina granularis externa*)
- contains stellate neurons which are responsible for association area connections

III **External pyramidal layer** (*lamina pyramidalis externa*)
- contains small pyramidal neurons and interneurons forming commissural tracts

IV **Internal granular layer** (*lamina granularis interna*)
- contains stellate neurons in which the majority of afferent fibers terminate
- dominates in the cortical somatosensory and sensory areas

V **Internal pyramidal layer** (*lamina pyramidalis interna*)
- contains larger pyramidal neurons (including the largest, pyramidal neurons of Betz)
- represents a layer of cortical efferentation and dominates in the motor areas

VI **Multiform layer** (*lamina multiformis*)
- situated in depth of the cortex and contains association interneurons

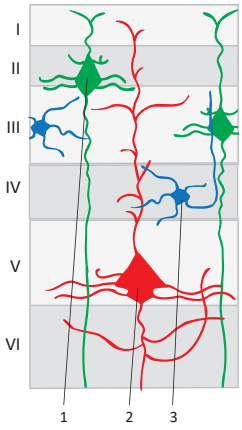

Cortical neurons

Pyramidal neurons (*neura pyramidalia*)
- 1**Neurons of the II and III layers**
  - axons form association and commissural tracts
- 2 **Neurons of the V layer**
  - axons transmit efferent impulses from the cortex (to the basal nuclei, nuclei of brainstem, and spinal cord)
  - this layer dominates in the agranular motor areas

Stellate neurons (*neura stellata*)
- 3 **Neurons of the II and IV layer of neocortex**
  - dominate in the granular somatosensory and sensory areas and represent interneurons receiving impulses from the thalamus, commissural, and association tracts

Allocortex is a collective term for paleocortex and archicortex..
Isocortex is a synonym for neocortex.

Mesocortex is a transitional form of cortex found between neocortex and allocortex. There are two types of mesocortex: peripaleocortex and periarchicortex. The **peripaleocortex** forms is found between the paleocortex and neocortex. The **periarchicortex** is located between the archicortex and neocortex.

Archicortex is responsible for instinctive and emotional reactions. In lower vertebrates these reactions are activated by olfactory stimuli. For animals with a well-developed sense of smell, olfactory stimuli are the most important afferents for their spatial orientation and play an important role in behaviour

The six-layered structure of neocortex differs in different functional areas.

The primary motor area forms only 60 % of the pyramidal tract. The rest of the fibres of the pyramidal tract come from premotor, association, and somatosensory areas**.**

Macroscopically, the two hemispheres appear very similar to each other. However, certain functions are be more dominant in one hemisphere than the other. Language is usually a function of the left hemisphere and spatial perception tends to be a function of the right hemisphere.

The two hemispheres communicate with each other through commissural fibres. However, they are able to function separately, which they do after corpus callosotomy, a surgical intervention performed in medically intractable severe epilepsy.

Functions of the right hemisphere: spatial recognition, recognition of faces, recognition of emotional content of speech, creativity and artistic ability
Functions of the left hemisphere: language (in almost 100 % of right-handed people and 70 % of left-handed), logical thinking,

The neocortex contains many different types of interneurone. These include spindle-like neurones (neura fusiformis), cells of Marinetti (neura pyramidalia inverse), horizontal cells of Cajal (neura horizontally), basket cells (neura corbiformia) and gliaform neurones (neura neuroglioformia).

The cortex is divided into distinct **functional areas** that have been discovered through electrical stimulation and clinico-pathological studies. When electrically stimulated, the **primary sensory areas** elicit somatic, visual, auditory, gustatory, olfactory and vestibular sensations. The **motor areas** produce muscle contraction when electrically stimulated. The remainder of the cortex is called **association cortex**. Each primary sensory area is associated with association sensory cortex. **Association sensory cortex** interprets information from primary sensory cortex to allow us to recognise an object, sound, taste or smell. Other association cortex plays a role in behaviour, communication and motor activity. The cortex can be further organised based on its regional histological structure into the 47 Brodmann areas.

Functional cortical areas

1 **Motor areas**
- 1.1 **Primary motor area** (BA 4)
- 1.2 **Premotor and supplementary motor area** (BA 6)
- 1.3 **Frontal eye field** (FEF, BA 8)

2 **Somatosensory areas**
- 2.1 **Primary somatosensory area** (BA 3, 1, 2)
- 2.2 **Association somatosensory area** (BA 5, 7)

3 **Sensory areas**
- 3.1 **Primary visual area** (BA 17)
- 3.2 **Visual association cortex** (BA 18, 19)
- 3.3 **Primary auditory area** (BA 41, 42)
- 3.4 **Auditory assocaition cortex** (BA 22)
- 3.5 **Gustatory area** (BA 43)
- 3.6 **Olfactory area** (BA 28)
- 3.7 **Vestibular area** (BA 2 – subdivision)

4 **Speech areas**
- 4.1 **Motor speech center / Broca's area** (BA 44, 45)
- 4.2 **Sensory speech center / Wernicke's area** (BA 22, 39, 40)

5 **Multifunctional areas**
- 5.1 **Insular cortex** (BA 13–16)

6 **Association areas**
- 6.1 **Frontal association areas** (BA 9–12, 46, 47)
- 6.2 **Parietal association areas** (BA 5, 7, 39, 40)
- 6.3 **Temporal association areas** (BA 20–22, 37, 38)
- 6.4 **Occipital association areas** (BA 18, 19)

7 **Limbic areas** (BA 23–36)

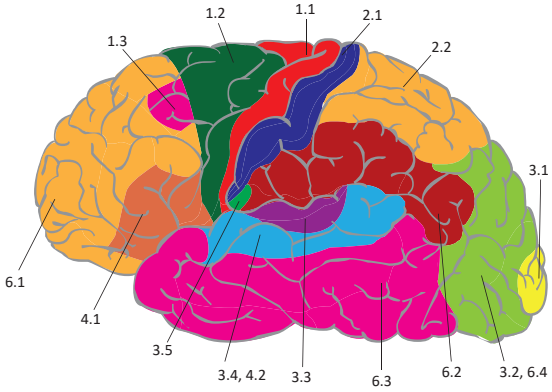

Lateral surface of the telencephalon

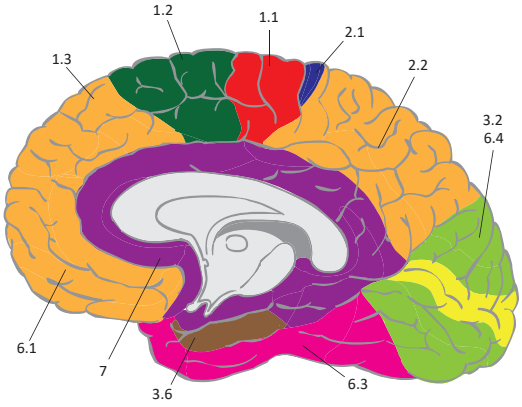

Medial surface of the telencephalon

Areas of Brodmann with functional overview

BA 3, 1, 2 – primary somatosensory areas
BA 4 – primary motor area
BA 5, 7 – secondary somatosensory areas
BA 5, 7, 39, 40 – association parietal areas
BA 6 – premotor and supplementary motor areas
BA 8 – frontal eye field
BA 9–12, 46, 47 – prefrontal association areas
BA 13–16 – insular cortex
BA 17 – primary visual area
BA 18, 19 – secondary visual area
BA 20–22, 37, 38 – associative temporal areas
BA 22, 39, 40 – Wernicke's area
BA 23–36 – limbic cortex
BA 41, 42, 22 – primary and secondary auditory areas
BA 43 – gustatory area
BA 44, 45 – Broca's area
BA 28 – olfactory cortex

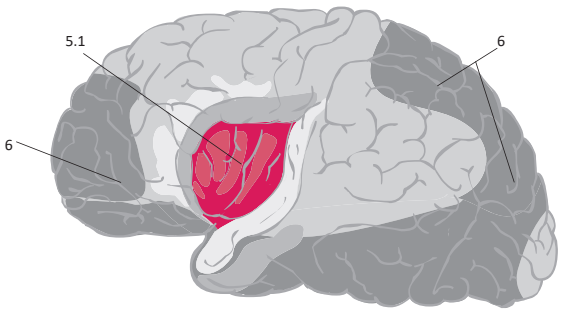

Lateral surface (open lateral sulcus)

This copy belongs to ali yaghoubi

Motor areas

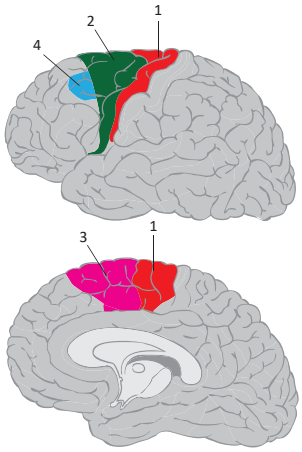

- 1 **Primary motor area** (BA 4, M1)
  Location: precentral gyrus
  Afferents: from the premotor and primary somatosensory areas and ventral lateral complex of thalamus
  Efferents: via the corticospinal tract to the motor nuclei of spinal cord and via the corticonuclear tract to the motor nuclei of brainstem
  Function: voluntary movements
- 2 **Premotor area** (BA 6, pM)
  Location: anterior part of the precentral gyrus and posterior parts of the frontal gyri
  Afferents: from the anterior ventral nucleus of thalamus and association areas
  Efferents: to the primary motor area, cerebellum, basal nuclei, reticular formation, and red nucleus
  Function: the area is involved in preparation of motor patterns and changes of motor patterns during movement
- 3 **Supplementary motor area** (BA 6, SMA)
  Location: on the medial surface of the frontal lobe (ventrally to the paracentral lobule)
  Afferents: from the anterior ventral nucleus of thalamus and association areas
  Efferents: to the primary motor area, cerebellum, basal nuclei, reticular formation, and red nucleus
  Function: the area is involved in preparation of motor patterns and changes of motor patterns during movement
- 4 **Frontal eye field** (BA 8, FEF)
  Location: middle frontal gyrus (is next to the pMA)
  Afferents: from the primary and secondary visual areas and dorsomedial nucleus of thalamus
  Efferents: to the tectum of midbrain and pretectal area, through the reticular formation to the nuclei of the n. III, n. IV and n. VI and cerebellum
  Function: voluntary and reflex movements of the eyes
  – the FEF is also involved in the oculomotor circuit of basal nuclei

Speech centers

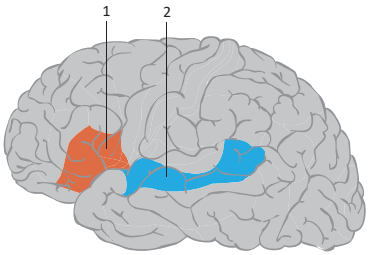

- 1 **Motor speech center of Broca** (BA 44, 45)
  Location: inferior frontal gyrus (triangular part)
  Interconnection: with the area of Wernicke and with motor and association areas
  Efferents: to the primary motor area, reciprocally to the area of Wernicke and to association areas
  Function: is involved in production of words, sentences, and written language
- 2 **Sensory center of Wernicke** (BA 22, 39, 40)
  Location: in the superior temporal gyrus and inferior parietal lobule
  Afferents: from the auditory and visual areas
  Interconnections: with the area of Broca via the arcuate fasciculus (*fasciculus arcuatus*)
  Functions: comprehension of speech and written language

The primary motor area is somatotopically organised. Different muscular groups correspond to different areas of the primary motor area.

Clinical notes

Damage to the premotor area does not result in paresis or paralysis. Instead, it results in the inability to execute complex movements. This is known as ideomotor apraxia. Such a patient is not able to imitate the use of tools (e.g. using a knife and fork or opening a door with a key).

Damage to the frontal eye field typically leads to deviation of the eye to the affected side.

Primary somatosensory area damage manifests as contralateral hypesthesia or anaesthesia (involvement of tactile and discriminative sensation). Pain and thermic sensation are typically spared, because they are processed at the level of the limbic system.

Damage to the primary visual area leads to cortical blindness.
Damage to the secondary visual area causes visual agnosia. Visual agnosia is a condition in which a patient cannot recognise the objects he/she sees.

Unilateral damage of the primary auditory area leads to a bilateral hearing impairment.
Damage to the anterior part of the primary auditory area affects low frequencies and damage to the posterior region leads to an affects higher frequencies.
Damage to the secondary auditory area results in the inability to interpret sounds and voices (perceptive aphasia).

Damage to Broca's area causes expressive (motor) aphasia. The patient is able to understand spoken and written language but speech is non-fluent and slow but meaningful.
Damage to Wernicke's area causes perceptive (sensory) aphasia. Despite a preserved ability to hear, the patient is unable to understand spoken and written language. The patient is usually able to produce fluent speech, which is typically unintelligible.

The arcuate fascicle interconnects Broca's area with Wernicke's area.
Damage of the arcuate fascicle causes conduction aphasia. Comprehension and spontaneous speech are preserved, but conversation and the ability to repeat words and sentences is disturbed.

Somatosensory areas

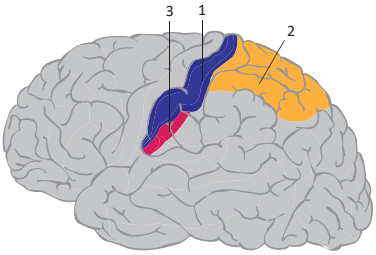

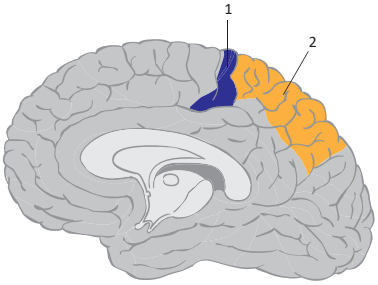

- 1 **Primary somatosensory area** (BA 3, 1, 2; S1)
  Location: postcentral gyrus and posterior part of the paracentral lobule
  Afferents: from the body (through the posterolateral ventral and posteromedial ventral nucleus of thalamus) and association nuclei of thalamus
  Efferents: to the primary motor area, secondary somatosensory area, and association areas
  Functions: somatosensory sensation
- 2 **Association somatosensory areas** (BA 5, 7)
  Location: parietal lobules
  Afferents: from the somatosensory and association cortical areas and thalamic nuclei (posterior and intralaminar nuclei)
  Efferents: reciprocal to the structures listed above
  Functions: analyze and integrate somatosensory afferentation and form spatial imagination of the body, perception of moving and orientation in space
- 3 **Secondary somatosensory area** (S2)
  Location: a small area in the postcentral gyrus, next to the lateral sulcus
  Afferents: from the primary somatosensory area and thalamus
  Functions: reacts to skin stimulation

Sensory areas

- 1 **Primary visual area** (BA 17; V1)
  Location: in the calcarine sulcus and adjacent cortex of the occipital lobe
  Afferents: from the lateral geniculate nuclei via the optic radiation
  Efferents: to the secondary visual area
  Functions: responsible for perception and realization of objects in the visual field
- 2 **Secondary visual area** (BA 18, 19; V2)
  Location: next to the primary visual area
  Afferents: from the primary visual area
  Efferents: to the pretectal area, premotor cortex, and frontal eye field (FEF)
  Function: detailed analysis of the visual field and objects
- 3 **Primary auditory area** (BA 41, 42; A1)
  Location: transverse temporal gyri of Heschl
  Afferents: from the medial geniculate nuclei via the acoustic radiation
  Efferents: to the secondary auditory area
  Function: responsible for perception and realization of tones, sounds, and voices
- 4 **Secondary auditory area** (BA 22; A2)
  Location: in the superior temporal gyrus next to the primary auditory area
  Afferents: from the primary auditory area and medial geniculate nuclei
  Efferents: to the association and speech areas
  Function: responsible for distinguishing, analyzing and perception of complex sounds,tones, and voices
- 5 **Gustatory area** (BA 43)
  Location: in the opercular part of postcentral gyrus and adjacent cortex of the insular lobe
  Afferents: from the nuclei of solitary tract via the thalamic ventral posteromedial nucleus
  Function: gustatory perception
- 6 **Olfactory area** (BA 28)
  Location: parahippocampal gyrus (entorhinal area)
  Afferents: from the olfactory bulb and lateral olfactory stria
  Interconnection: reciprocal with the orbitofrontal association cortex
  Function: responsible for perception and distinguishing of olfactory stimuli
- 7 **Vestibular area** (BA 2v)
  Location: a small region of the postcentral gyrus next to the lateral sulcus opposite to the auditory area in the superior temporal gyrus
  Afferents: ventral posteromedial nucleus of thalamus
  Function: perception of head position in respect to the rest of the body and head movements

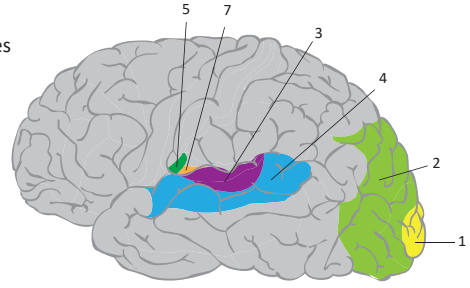

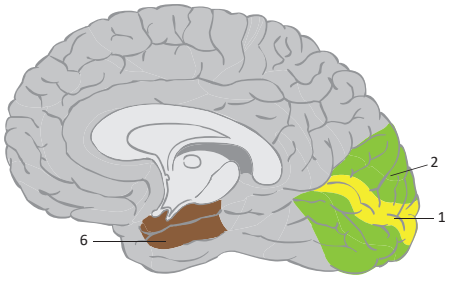

This copy belongs to ali yaghoubi

Multifunctional areas

- 1 **Insular areas** (BA 13–16)
  Location: in the insular lobe (usually 4 to 6 gyri)
  Afferents: from the ventral posteromedial, ventral posterolateral nucleus, and intralaminar nuclei of thalamus
  Efferents: to the frontal, parietal, and temporal lobes, cingular gyrus, amygdaloid body, entorhinal and periamygdalar area of olfactory cortex
  Functions:
  1 **Viscerosensory part** (ventral part of the insular lobe)
  – perception of gustatory stimuli, integration with olfactory perception and regulation of the immune system
  2 **Motor part** (middle part of the insular lobe)
  – influences respiratory movements and activity of the breathing muscles, activity of the articulation muscles and their association with speech production
  – influences gastrointestinal tract motility (peristalsis)
  3 **Vestibular part** (dorsal part of the insular lobe)
  – participates in perception of head position and movements

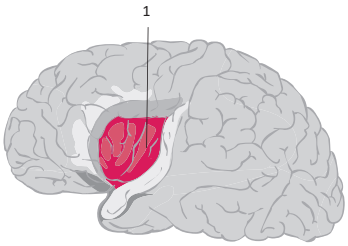

Association areas

– cover almost 75 % of the brain cortex

- 1 **Parietal association areas** (BA 5, 7, 39, 40)
  Location: superior and inferior parietal lobules (angular and supramarginal gyrus)
  Afferents: from the adjacent areas (somatosensory, auditory, and visual) and Wernicke's area
  Efferents: to the frontal lobe and remaining association areas
  Function: complex perception of stimuli and integration of sensory inputs
  – internal processes of brain and external outputs; participates in creation of a 3D map of surroundings, its activity is important for spatial orientation and fine motor timing

- 2 **Temporal association areas** (BA 20, 21, 22, 37, 38)
  Location: temporal lobe and occipitotemporal gyrus
  Afferents: mainly from the primary visual area (occipito-temporal projection)
  Function: distinguishing familiar and unfamiliar faces, objects, and animals

- 3 **Occipital association areas** (BA 18, 19)
  Location: occipital lobe
  Afferents: mainly from the primary visual area
  Function: detailed analysis and synthesis of visual stimuli (visual gnosia)

- 4 **Prefrontal areas** (BA 9–12, 46, 47)
  Location: prefrontal area of frontal gyri (rostral part), orbital gyri, straight gyrus (*gyrus rectus*), and cingulate gyrus
  Interconnection: reciprocal with almost all brain areas
  Function: cortical center of emotions, behavior, planning, ego, and personality
  – cortical center of creative thinking and complex memory circuits

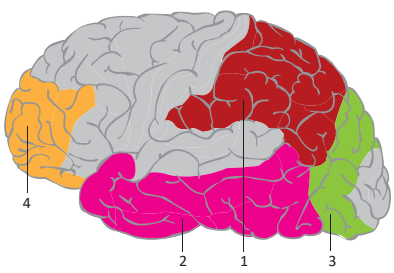

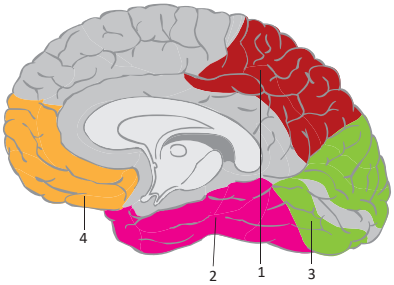

The ventral part of the insular cortex is responsible for perception of body temperature, pain, itching, touch, perception from viscera and muscles, perception of heart activity and rhythm, perception of the urinary bladder and stomach. It is also responsible for integration of auditory stimuli and motor activity. It is responsible for altering facial expression in response to a familiar song or voice.
The dorsal part of the insular cortex is responsible for emotions. It participates in regulation of sympathetic and parasympathetic tone and cooperates with the hypothalamus and reticular formation.

The majority of the basal nuclei has origin in the telencephalon (phylogenetically its basal part). In comparison, the globus pallidus and substantia nigra are of the diencephalic origin. The substantia nigra is pushed away from the telencephalon into the tegmentum of midbrain.

Nomenclature of the basal nuclei according to the origin:
Amygdaloid body – archistriatum
Pallidum – paleostriatum
Striatum – neostriatum

Clinical notes

Damage to the insular lobe can lead to an impairment of breathing (regularity, frequency or depth), impairment of heart rate, and inhibition or acceleration of peristalsis.

Damage to the parietal association cortex usually manifests as an inability to recognize objects held in the hand with the closed eyes (astereognosis).

Damage of the right parietal association cortex can result in neglect syndrome. A patient with neglect syndrome typically ignores the left half of his or her body, eats from the right half of a plate and draws only the right half of an object.

Massive damage of the temporal association areas typically results in the inability to distinguish the patient's own face or recognise and name colours.

Damage to the prefrontal cortex results in the loss of emotion.
Damage to the prefrontal cortex can lead to changes in mood and behaviour. Affected patients demonstrate inappropriate behaviour, increased irritability and aggression.

The basal ganglia are **grey matter structures located deep within the hemispheres and the brainstem**. According to their afferent and efferent connections, the basal ganglia are classified into **input, intrinsic and output nuclei**. The basal ganglia are **interconnected to form several different circuits**. They are predominantly involved in the **coordination and learned movement patterns execution**. However, they also play a role in learning, memory and behaviour.

Topography

- 1 **Rostrally:** white matter of frontal lobe
- 2 **Occipitally:** white matter of occipital lobe
- 3 **Medially:** diencephalon
- 4 **Basally:** white matter of temporal lobe
- 5 **Laterally:** insular lobe
- 6 **Lateral** ventricles

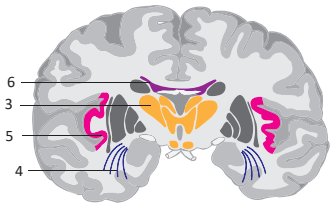

Frontal section of the brain

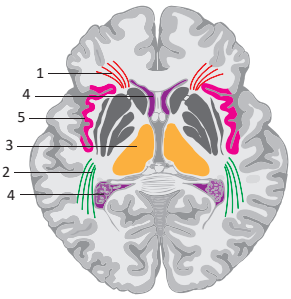

Cross-section of the brain

Principal nuclei

- 1 **Striatum** (*corpus striatum*)
  - 1.1 **Caudate nucleus** (*nucleus caudatus*)
  - 1.2 **Putamen**
- 2 **Globus pallidus**
  - 2.1 **Globus pallidus medial segment** (*globus pallidus medialis, pallidum internum*)
  - 2.2 **Globus pallidus lateral segment** (*globus pallidus lateralis, pallidum externum*)

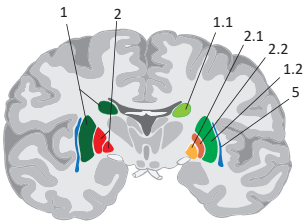

Frontal section of the brain

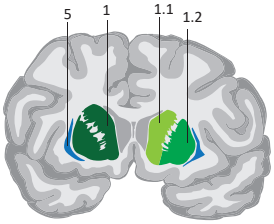

Frontal section of the brain

Other nuclei

Nuclei associated with the limbic system

- 3 **Amygdaloid body** (corpus amygdaloideum)
- 4 **Nucleus accumbens** (*nucleus accumbens*) – part of ventral striatum

Nucleus dominantly interconnected with the cortex

(outside of the basal nuclei circuits)

- 5 **Claustrum**

Nuclei functionally interconnected with the basal nuclei

- 6 **Subthalamic nucleus of Luys** (*nucleus subthalamicus*)
- 7 **Substantia nigra – reticular part** (*pars reticularis substantiae nigrae*)

Chemical nuclei interconnected with the basal nuclei

- 8 **Basal nucleus of Meynert** (CH4) – supplying acetylcholine
- 9 **Substantia nigra – compact part** (A9) (*pars compacta substantiae nigrae*) – supplying dopamine

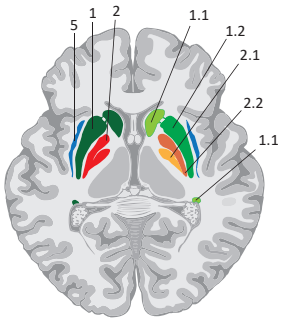

Cross-section of the brain

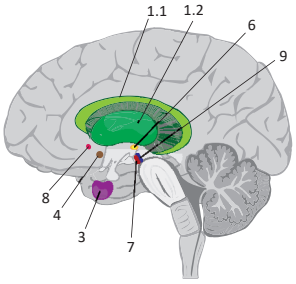

Left view of the basal ganglia

White matter distribution and basal nuclei

- 1 **Internal capsule** (*capsula interna*) – an important bundle of projections connecting the cortex and subcortical structures, situated laterally to the caudate nucleus and thalamus and medially to the globus pallidus
- 2 **External capsule** (*capsula externa*) – localized between the putamen and claustrum
- 3 **Extreme capsule** (*capsula extrema*) – localized between the claustrum and internal part of the insular lobe

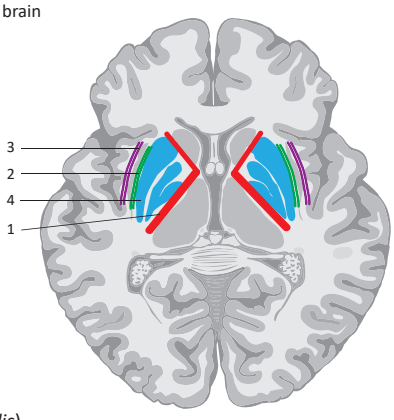

Cross-section section of the brain

Macroscopically visible nuclei

- 4 **Lentiform nucleus** (*nucleus lentiformis*) – visible on the transversal brain section
  - – formed by the globus pallidus (medially) and putamen (laterally)
  - – its parts are divided by the medial/internal medullary lamina (*lamina medullaris medialis*) between the medial and lateral globus pallidus and the lateral/external medullary lamina *(lamina medullaris lateralis)* between the lateral globus pallidus and putamen

This copy belongs to ali yaghoubi

Principal nuclei

1 **Corpus striatum / striatum**
– the nucleus is divided by the course of the internal capsule into the medial caudate nucleus and lateral putamen
– both nuclei are interconnected via the caudolenticular/transcapsular grey bridges (*pontes grisei caudatolenticulares,* an obsolete synonym is *striae*) which are responsible for the striped structure of the nucleus

1.1 **Caudate nucleus** (*nucleus caudatus*)
– localized next to the mediocaudally situated thalamus
– is divided into three parts:
- 1.1.1 **Head** (*caput*) – the largest part forming the lateral wall of the frontal horn of lateral ventricle
- 1.1.2 **Body** (*corpus*) – forms the lateral wall of the central part of the lateral ventricle
- 1.1.3 **Tail** (*cauda*) – a thin part which turns down and rostrally and forms the superior wall of the lateral ventricle's temporal horn

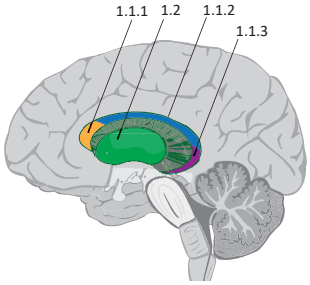

- 1.2 **Putamen**
  – located laterally to the internal capsule
  – it is bordered medially by the lateral medullary lamina of lentiform nucleus and laterally by the external capsule

2 **Globus pallidus / pallidum / paleostriatum**
– develops in the subthalamic region laterally to the internal capsule
– it is divided into the globus pallidus lateral segment and globus pallidus medial segment by the medial medullary lamina of lentiform nucleus

2.1 **Globus pallidus medial/internal segment** (*globus pallidus medialis, pallidum internum*)
– represents an output nucleus of the globus pallidus and of the basal nuclei
– it is connected with the motor nuclei of thalamus and brainstem

2.2 **Globus pallidus lateral/external segment** (*globus pallidus lateralis,pallidum externum*)
– represents an input nucleus of the globus pallidus and nucleus of the inner circuit of basal nuclei

Other nuclei

1 **Subthalamic nucleus of Luys** (*nucleus subthalamicus*)
– located in the subthalamus ventrolaterally to the zona incerta
– is involved in the indirect (activating) pathway of basal nuclei which is responsible for activation of the motor thalamic nuclei (output nuclei of the basal nuclei usually have inhibitory effect on the motor thalamus)
– via the activation of the motor thalamus the motor pattern proposed by the cortex and approved by the basal nuclei is processed

2 **Substantia nigra of Sömmering**
– located in the midbrain and pigmented by neuromelanin
– is involved in the motor circuits of basal nuclei and brainstem

2.1 **Compact part** (*pars compacta*) – is responsible for dopamine production and its transport via the nigrostriatal tract to the striatum

2.2 **Reticular part** (*pars reticularis*) – serves as an output nucleus, produces GABA and represents an important inhibitory nucleus involved in the motor circuits and oculomotor loop (inhibitory projection from the ventromedial part into the superior colliculus)
– is interconnected with the thalamus, reticular formation, and superior colliculus

3 **Amygdaloid body** (*corpus amygdaloideum / amygdala*) – a complex of nuclei located in the pole of temporal lobe, in front of the temporal horn of lateral ventricle
– functionally, it is involved in the limbic system

4 **Nucleus accumbens / striatum ventrale**
– is situated next to the septum verum and is involved in the circuits of the limbic system

5 **Claustrum** – a strip of grey matter situated between the external and extreme capsules
– interconnected reciprocally with cortical areas, but it is not involved in the circuits of the basal nuclei
– its exact function is not well described and understood, it is supposed to be involved in the association circuits of brain cortex

6 **Ventral tegmental area of Tsai** (*area ventralis tegmentalis)* – situated ventrally in the midbrain and producing dopamine for the striatum and nucleus accumbens

Fundus striati is a term for the frontobasal fusion of the putamen with head of caudate nucleus.

The basal nucleus of Meynert (*nucleus basalis*) is a structure situated beneath the lentiform nucleus. It extends ventrally to the head of the caudate nucleus and dorsally to the posterior border of thalamus. It consists of a group of diffusely scattered cholinergic neurons inside the innominate substance of Reichert (*substantia innominata*).

The basal ganglia can be thought of as a filter, which reduces the number of motor patterns entering the thalamus. When a motor pattern reaches the thalamus, it is processed and transmitted to the motor cortex. Then, the corticospinal and corticonuclear tracts transmit it to the motor nuclei of brainstem and spinal cord. The basal ganglia, cerebellum, and motor structures of the brainstem control the approved motor pattern and participate in muscle tone control. If the basal ganglia inhibit the transmission of the motor pattern to the thalamus, the motor pattern is not executed.

Clinical notes

The hypotonic-hyperkinetic syndrome is characterised by the occurrence of involuntary movements and a decreased in muscle tone.

Chorea is a result of putamen damage. Increased concentration of dopamine leads to involuntary movements resembling a dance.

Huntington's chorea is an autosomal dominant hereditary hyperkinetic syndrome associated with progressive dementia and impairment of behaviour.

Hemibalism is a clinical sign caused by damage of the subthalamic nucleus. It manifests abrupt involuntary movements of the contralateral side of the body that resemble throwing a shot put.

The hypertonic-hypokinetic syndrome is characterised by a decrease in motor activity and an increased muscle tone motor.

Parkinson disease is caused by lack of dopamine in the substantia nigra and disequilibrium in the basal nuclei caused by excess of acetylcholine. It manifests as muscle rigidity, hypokinesis, tremor, hypomimia (mask face), monotone speech, and other clinical signs (e.g. early loss of the sense of smell – anosmia or impairment of the sense of taste).

Classification according to the connections

1 **Input nuclei**
- 1.1 Striatum
- 1.2 Nucleus accumbens

2 **Inner nuclei**
- 2.1 Globus pallidus lateral segment
- 2.2 Subthalamic nucleus
- 2.3 Substantia nigra – compact part
- 2.4 Ventral tegmental area of Tsai

3 **Output nuclei**
- 3.1 Globus pallidus medial segment
- 3.2 Substantia nigra – reticular part

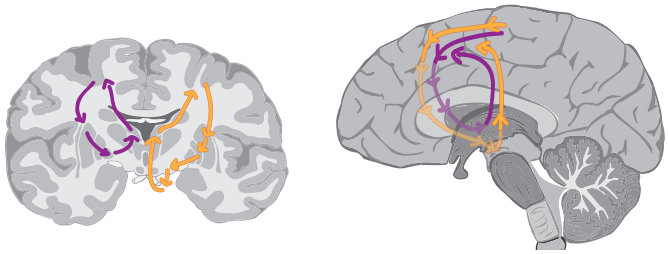

Major motor circuit (loop)

- **Simplified scheme of the direct circuit:**

1. originates in **the premotor and primary motor areas** (BA 6, 4) and **primary somatosensory area** (BA 3, 1, 2)
2. enters the **striatum**
3. continues to **the globus pallidus internal segment**
4. via **the motor nuclei of thalamus** returns back to the motor cortex (BA 6, 4)

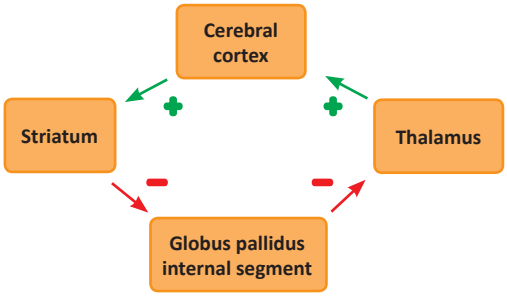

The direct circuit of basal nuclei

- **Simplified scheme of the indirect circuit:**

1. Origins in **the premotor and motor areas** (BA 6, 4) and **primary somatosensory area** (BA 3, 1, 2)
2. Enters **the striatum**
3. Continues to **the globus pallidus external segment**
4. Enters **the subthalamic nucleus**
5. Interconnects in **the globus pallidus internal segment** or **reticular part of substantia nigra**
6. Via **the motor nuclei of thalamus** returns back to the motor cortex (BA 6, 4)

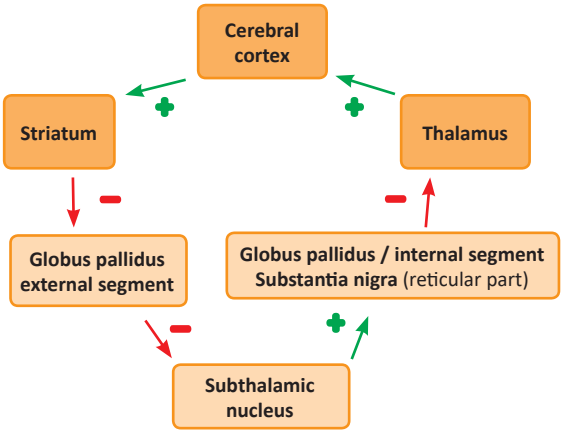

The indirect circuit of basal nuclei

Variants of the major circuit

1 **Sensory-motor loop** – head and limbs movements based on proprioception and touch information
2 **Oculomotor loop** – responsible for synchronization of head and eyes movements
3 **Association loop** – affects spatial memory and behavior, information comes from the prefrontal and orbitofrontal cortex and influences 3D memory (via the caudate nucleus) and synchronizes motor activity with changing conditions
4 **Limbic loop** – somatomotor and visceromotor expression of emotional state, has an impact on motor activity during positive and negative emotions (e.g. trembling of the body and voice during exams, aggressive and submissive posture, facial expressions, etc.)

excitatory neurotransmiter (glutamate)

inhibitory neurotransmiter (GABA)

Functions of the basal nuclei

1 Important in **motor activity and selection of motor patterns**
2 Its dominant role is **the inhibitory effect on motor activity**
3 The globus pallidus medial segment has a spontaneous inhibitory activity on the motor thalamus – is responsible for **filtering of information and selecting motor inputs** which, after processing, return to the cortex and then are transmitted via the corticospinal tract to the executive muscles
4 Represent **a functional generator of slow movements associated with body posture**
5 Have an impact on **muscle tone** together in cooperation with the cortical, subcortical and cerebellar structures
6 Involved in **motor learning and memory**

This copy belongs to ali yaghoubi

The white substance is composed of **a huge number of neuronal fibres** (tracts). **Association fibres** connect cortical areas within the same cerebral hemisphere. **Commissural fibres** interconnect the cortex of the two hemispheres. **Projection fibres** connect the cortex with subcortical structures.

Macroscopic features

Section at the level of the thalamus and basal ganglia:

- 1 **Semioval center** (*centrum semiovale*)
  – described on a CT of the brain

Section at the level of the thalamus and basal ganglia:

- 2 **Internal capsule** (*capsula interna*)
  – laterally to the caudate nucleus and thalamus, medially to the globus pallidus
- 3 **External capsule** (*capsula externa*)
  – laterally to the globus pallidus, medially to the claustrum
- 4 **Extreme capsule** (*capsula extrema*)
  – between the claustrum and insular lobe

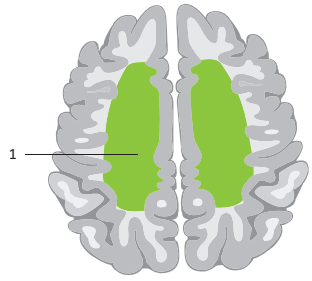

Cross-section (above the thalamus and basal nuclei)

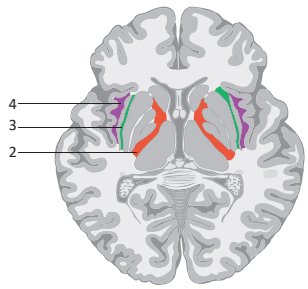

Cross-section at the level of the thalamus and basal nuclei

Association fibers

- 1 **Arcuate fibers** (*fibrae arcuatae cerebri*)
  – short tracts (U-fibers) interconnecting neighbouring gyri or areas in the same gyrus
- 2 **Superior longitudinal fasciculus** (*fasciculus longitudinalis superior*)
  – interconnects the frontal lobe with the parietal and occipital lobe
- 3 **Inferior longitudinal fasciculus** (*fasciculus longitudinalis inferior*)
  – interconnects the occipital and temporal lobe
- 4 **Arcuate fasciculus** (*fasciculus arcuatus*)
  – interconnects the Broca's area with Wernicke's area
  – winds around the insular lobe
  – lies deeply in the hemisphere and interconnects the frontal and temporal lobe
  – the fasciculus is crucial in the cooperation of the motor and sensory speech centres
- 5 **Uncinate fasciculus** (*fasciculus uncinatus*)
  – interconnects the orbitofrontal cortex and temporal lobe
- 6 **Vertical occipital fasciculus** (*fasciculi occipitales verticales*) – interconnects the posterior part of the parietal lobe with dorsal part of the temporal lobe (lateral occipitofrontal gyrus)
- 7 **Transverse occipital fasciculus** (*fasciculi occipitales horizontales*)
  – situated inside the occipital lobe
- 8 **Cingulum** – passes in the white substance of cingulate gyrus
  – interconnects the frontal and parietal lobe with the parahippocampal gyrus and with the adjacent part of the temporal lobe
  – is a component of the Papez circuit
- 9 **Superior occipitofrontal fasciculus** (subcallosal fasciculus) **and inferior occipitofrontal fasciculus** (*fasciculus occipitofrontalis superior/subcallosus et inferior*)
  – interconnects the frontal lobe with the temporal and occipital lobe
  – is separated from the superior longitudinal fasciculus by the fibers of corona radiata
  – passes deep in the white substance adjacent to the caudate nucleus

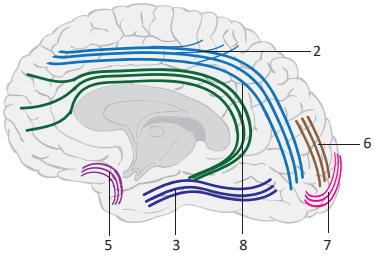

Medial surface of the telencephalon

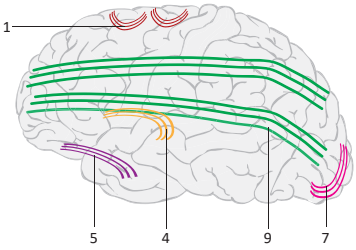

Lateral surface of the telencephalon

The corona radiata is a fan-like structure of nervous fibres in the telencephalon projecting into the cerebral cortex.

The projection fibres leave the hemispheres (or enter the hemispheres) via the internal capsule, apart from the olfactory pathway.

The habenular and posterior commissure do not belong to the hemispheric commissures.

The corpus callosum contains approximately 200 million nerve fibres.

Commissural fibers

1 **Corpus callosum**
– interconnects the neocortical gyri of both hemispheres
– a large fasciculus of bidirectional tracts
Parts in the sagittal section:
- 1.1 **Rostrum**
- 1.2 **Genu**
- 1.3 **Truncus**
- 1.4 **Splenium**

Parts in the cross-section:
- 1.5 **Minor/frontal forceps** (*forceps minor/frontalis*)
- 1.6 **Major/occipital forceps** (*forceps major/occipital*)

- 2 **Anterior commissure** (*commissura anterior*)
  2.1 **Anterior part** (*pars anterior*) – olfactory commissure
  – commissure of paleocortex
  2.2 **Posterior part** (*pars posterior*)
  – interconnects the temporal lobes
  – commissure of neocortex
- 3 **Commissure of fornix** (*commissura fornicis*)
  – interconnects the right and left fornix
  – commissure of archicortex

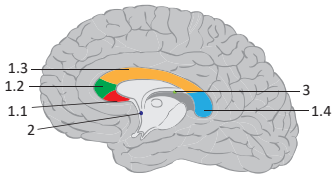

Medial surface of the telencephalon

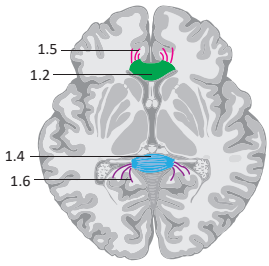

Cross-section of the brain

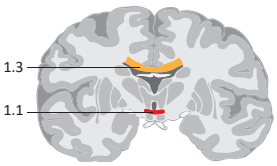

Frontal section of the brain

Projection fibers

1 **Short projection fibers** – such as the glutaminergic cortiostriatal tract running from the cortex to the striatum (an input nucleus of the basal ganglia)
2 **Long projection fibers** – ascending and descending tracts of the internal capsule
2.1 **Ascending tracts** – convey sensory afferent information
– such as the thalamic, optic, and acoustic radiation
2.2 **Descending tracts** – convey motor efferent information to the motor nuclei of brainstem and spinal cord

Internal capsule (*capsula interna*)

– is composed of the anterior limb (*crus anterius*), genu and posterior limb (crus posterius)
– contains particular fascicles or tracts

- 1 **Anterior limb** (*crus anterius*)
  - 1.1 **Anterior thalamic radiation** (*radiatio thalami anterior*)
    – a fascicle of bidirectional (reciprocal) connections between the cortex and thalamus
  - 1.2 **Frontopontine fibers** (*fibrae frontopontine*)
    – tracts passing from the frontal lobe to the pons and then to the neocerebellum
- 2 **Genu**
  - 2.1 **Corticonuclear fibers** (*fibrae corticonucleares*)
    – tracts passing to the nuclei of the cranial nerves in the brainstem
- 3 **Posterior limb** (*crus posterius*)
  - 3.1 **Corticospinal fibers** (*fibrae corticospinales*)
    – somatotopic arrangement of the pyramidal tract passing to the spinal motoneurons
  - 3.2 **Corticotectal fibers** (*fibrae corticotectales*)
  - 3.3 **Corticoreticular fibers** (*fibrae corticoreticulares*)
    – a tract interconnecting the cortex and reticular formation
  - 3.4 **Corticorubral fibers** (*fibrae corticorubrales*)
    – a tract interconnecting the cortex and red nucleus
  - 3.5 **Central thalamic radiation** (*radiatio thalami centralis*)
  - 3.6 **Posterior thalamic radiation** (*radiatio thalami posterior*)
    – corticothalamic and thalamocortical fibers
- 3.7 **Occipitopontine, temporopontine and parietopontine fibers** (*fibrae occipitopontinae, temporopontinae et parietopontinae*)
  – passing to the pontine nuclei and arcuate nucleus
  - 3.8 **Optic radiation** (*radiatio optica*) – fascicles of the optic pathway from the lateral geniculate nucleus into the occipital lobe
  - 3.9 **Acoustic radiation** (*radiatio acustica*) – fascicles of the auditory pathway from the medial geniculate nucleus into the temporal lobe

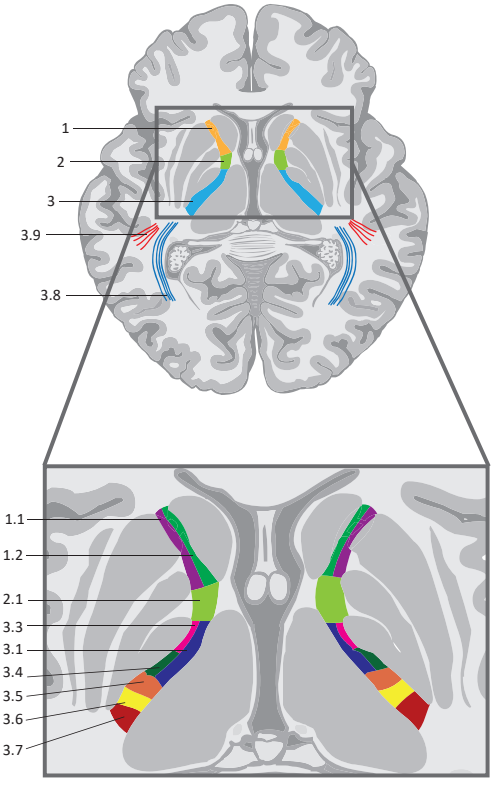

Cross-section of the brain (detail)

This copy belongs to ali yaghoubi

The limbic system consists of **cortical and subcortical structures**. **The cortical structures** are located predominantly on the medial aspect of the cerebral hemispheres. The subcortical structures are located in the basal ganglia, diencephalon, brainstem, and reticular formation. These structures are interconnected through various neural pathways and circuits. The limbic system is responsible for the control of **emotions and behaviour, motivation and memory**. It also **affects the autonomic and somatic nervous systems** as well as the **hypothalamus-hypophyseal axis**. The cortical structures of the limbic system can be classified histologically according to the number of cortical layers. The limbic system is further divided into functional zones based on its main connections.

Cortical regions – Limbic gyrus (*gyrus limbicus*)

1 **Neocortex**
- 1.1 **Subcallosal area** (*area subcallosa*)
- 1.2 **Cingulate gyrus** (*gyrus cinguli*)
- 1.3 **Parahippocampal gyrus** (*gyrus parahippocampalis*)

2 **Mesocortex** (transitional zone)
- 2.1 **Entorhinal and perirhinal cortex**
- 2.2 **Presubiculum**

3 **Archicortex**
- 3.1 **Hippocampal formation**
  - 3.1.1 Hippocampus proper
  - 3.1.2 Subiculum
  - 3.1.3 Dentate gyrus (*gyrus dentatus*)

4 **Paleocortex**
- 4.1 **Primary olfactory cortex**

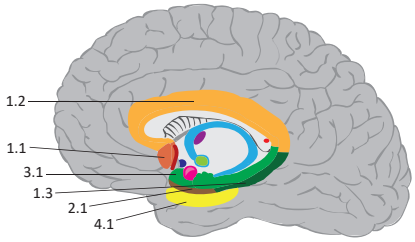

Medial aspect of the telencephalon with cortical structures

Subcortical structures

- 1 **Amygdaloid complex**
- 2 **Hypothalamus** – mammillary nuclei
- 3 **Thalamus** – anterior thalamic nucleus
- 4 **Epithalamus** – habenular nuclei
- 5 **Nucleus accumbens**
- 6 **Septal nuclei**
- 7 **Fornix**
- 8 **Reticular formation**

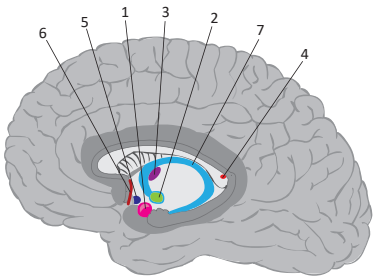

Medial aspect of the telencephalon with subcortical structures

Zones

- 1 **The most internal zone**
  - 1.1 Mammillary bodies (*corpora mammillaria*)
  - 1.2 Fornix
  - 1.3 Fimbria of hippocampus (*fimbria hippocampi*)
- 2 **Internal zone**
  - 2.1 Hippocampus proper
  - 2.2 Dentate gyrus (*gyrus dentatus*)
  - 2.3 Indusium griseum
- 3 **External zone**
  - 3.1 Subiculum, presubiculum, parasubiculum
  - 3.2 Entorhinal area (*area entorhinalis*)
  - 3.3 Parahippocampal gyrus (*gyrus parahippocampalis*)
  - 3.4 Uncus of parahippocampal gyrus (*uncus gyri parahippocampalis*)
  - 3.5 Cingulate gyrus (*gyrus cinguli*)
  - 3.6 Subcallosal area (*area subcallosa*)
- 4 **Neocortical paralimbic cortex**
  - 4.1 Insular lobe (*lobus insularis*)
  - 4.2 Pole of temporal lobe (*polus temporalis)*
  - 4.3 Orbitofrontal cortex

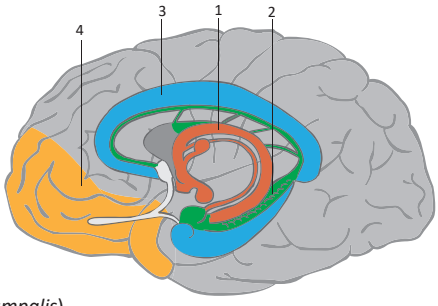

Scheme of the limbic system zones inside of the brain

The term limbus means edge or boundary. The limbic system refers to the group of structures that surround the border between the brainstem and hemispheres.

The limbic lobe forms a collar around the corpus callosum on the medial aspect of the hemisphere. The cortical structures of the limbic system (developmentally allocortex) are pushed towards the corpus callosum as the neocortex develops and expands.

The allocortex is a phylogenetically old, which comprises 4 % of the hemispheric surface. It consists of the paleocortex and archicortex.

The paleocortex is also called the rhinencephalon ("olfactory brain") and is formed by the olfactory nerve and its connections.

The archicortex is also called the "limbic cortex".

The mesocortex represents a transition between the archicortex and neocortex. It is formed by 6 layers, the same as the neocortex, but the microscopic structure and the distribution of its neurones resembles the archicortex.

The neocortex is phylogenetically the youngest type of cortex. It consists of 6 layers of neurones and is greatly developed in humans, forming 96 % of the hemispheric surface.

Hippocampus means a seahorse in Greek, as the shape of the hippocampal formation resembles a seahorse. The hippocampus is also called cornu ammonis due to its resemblance to the Egyptian deity Ammon.

In frontal section, the dentate gyrus has the shape of a letter C and seems to "bite" into the hippocampus proper from below.

The nucleus of stria terminalis (*nucleus striae terminalis*) connects to nucleus accumbens and the amygdaloid complex. It has a role in the long-term maintenance of fear and anxiety. The immediate fear and anxiety responses of the amygdaloid complex.

Cingulate gyrus

- 1 **Cingulate gyrus** (*gyrus cinguli*) – BA 23, 24, 25, 29, 30, 31
  Location: begins as the subcallosal area (*area subcallosa*) below the rostrum of corpus callosum (*rostrum corporis callosi*), turns around the corpus callosum dorsally and caudally, and further as a narrowing (isthmus gyri cinguli) into the temporal lobe, where it forms the parahippocampal gyrus (*gyrus parahippocampalis*)
  Afferents: from the association cortex of the temporal, parietal, and frontal lobes
  Efferents: feedback to cortical areas and subcortical structures (striatum, cerebellum, thalamus)
  Function: emotional reactions (anterior part), verbal memory and spatial orientation (posterior part)
  1.1 **Cingulum**
  – an important thick bundle leading into the parahippocampal gyrus
  – an essential part of the Papez circuit

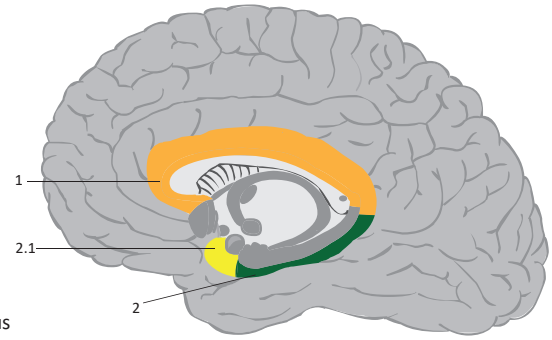

Medial aspect of the telencephalon

Parahippocampal gyrus

- 2 **Parahippocampal gyrus** (*gyrus parahippocampalis*)
  – formed by several Brodmann areas (entorhinal cortex, perirhinal cortex)
  – represents a continuation of the cingulate gyrus from the level of the splenium of corpus callosum
  - 2.1 **Uncus** – rostral part
    2.1.1 **Semilunar gyrus** (*gyrus semilunaris*) – the amygdaloid complex is located deep (i.e. superior) to the semilunar gyrus
    2.1.2 **Ambient gyrus** (*gyrus ambiens*) – rostral part
    2.1.3 **Dentate gyrus** (*gyrus dentatus*) – terminal part
  2.2 **Entorhinal cortex** (BA 28)
  – the inferior part of the uncus of parahippocampal gyrus
  – connects the neocortex with the hippocampal formation
  2.2 **Perirhinal cortex** (BA 35, 36)
  – along the rhinal sulcus and collateral sulcus
  Afferents: mainly from the association areas of the neocortex, prefrontal and olfactory cortex, hippocampal formation, amygdaloid complex, thalamus
  Efferents: predominantly to the hippocampal formation, also to the amygdaloid complex, thalamus (anterior nuclei), and ventral striatum
  Function: spatial memory and orientation, ability to recognize and differentiate between various objects

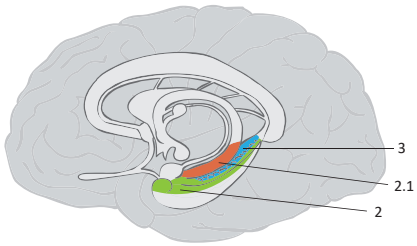

Hippocampal formation (hippocampus)

- 1 **Subiculum** – is situated on the upper side of the parahippocampal gyrus
- 2 **Hippocampus proper** (*cornu Ammonis, hippocampus proprius*)
  a lateral continuation of the subiculum forms a prominence (about 5 cm long) bulging into the temporal horn of lateral ventricle
  – is composed of four main sectors (CA1 to CA4)
  - 2.1 **Fimbria of hippocampus** (*fimbria hippocampi*)
    – a bundle leading to the fornix
    – connects the hippocampal formation with the rest of the limbic system
- 3 **Dentate gyrus** (*gyrus dentatus*)
  – located medially to the hippocampus proper
  – represents a continuation of the fasciolar gyrus (gyrus fasciolaris), which arises from the union of the longitudinal striae of corpus callosum (striae longitudinales corporis callosi)

Afferents: from the entorhinal cortex, thalamus, association areas of the neocortex (via the cingulate and parahippocampal gyrus)
Efferents: via the fornix into the hypothalamus and thalamus, via the entorhinal cortex to the neocortex
Neurotransmitter input: norepinephrine (from the locus caeruleus), acetylcholine (from the septal nuclei), serotonin (from the raphe nuclei of reticular formation)
Function: processes associated with long-term memory, participation in memory consolidation

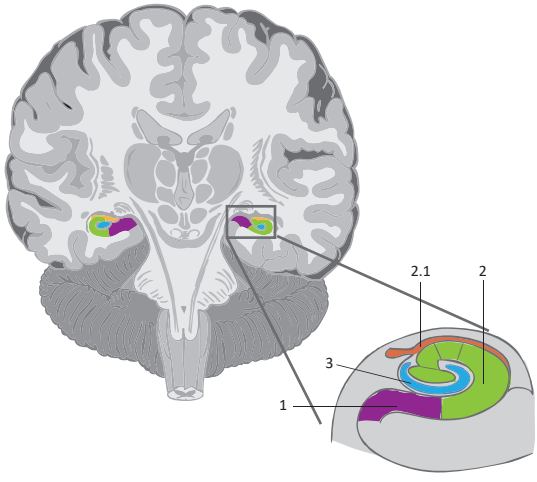

Frontal section of the telencephalon (detail)

This copy belongs to ali yaghoubi

Amygdaloid complex

- 1 **Amygdaloid complex** (*corpus amydgaloideum, amygdala*)
  - – a group of nuclei located in the pole of the temporal lobe, anterior to the temporal horn of lateral ventricle
  - – develops together with the basal ganglia but functionally represents a part of the limbic system

Structure:

1 **Corticocentromedial group of nuclei**
– developmentally younger nuclei connected to the cortex
2 **Basolateral group of nuclei**
– developmentally older nuclei connected to the olfactory cortex, hypothalamus, and brainstem nuclei

Afferents:

1 **from the association cortex**
2 f**rom the olfactory tract and lateral olfactory gyrus** (sense of smell)
3 **from the nuclei of solitary tract** (viscerosensory nuclei of cranial nerves) and insular lobe
4 **from the hippocampal formation, thalamus, and hypothalamus**

Efferents:

1 **To the insular lobe, entorhinal area, and septal nuclei**
2 **To the thalamus and hypothalamus** (via the stria terminalis and amygdalofugal bundle)
3 **To the motor cortex, premotor cortex, and basal ganglia** (affecting voluntary and involuntary movements)
4 **To the hippocampus** (related to memory retention processes)
5 **To the visceromotor nuclei of cranial and spinal nerves** (affects sympathetic and parasympathetic output and responses)

Neurotransmitter input: acetylcholine (from the basal nucleus of Meynert), norepinephrine (from the locus caeruleus) and dopamine (from the ventral tegmental area of Tsai)

Function: a center of emotions and fear
– retention and storage of memories associated with moments charged with emotions
– recognition and reactions to stimuli associated with negative experiences or unpleasant smells
– reactions to fear, such as freezing (paralysis), tachycardia, tachypnea, stomach cramps, release of stress hormones, and central increase of pain threshold
– activity of the amygdaloid complex is also related to pleasant emotions (such as love, desire, and addiction)

Other structures

2 **Fornix**
– connects the hippocampus with other components of the limbic system, and also the right and left hippocampus together
– arises from the fimbria of hippocampus on the floor of the lateral horn of lateral ventricle

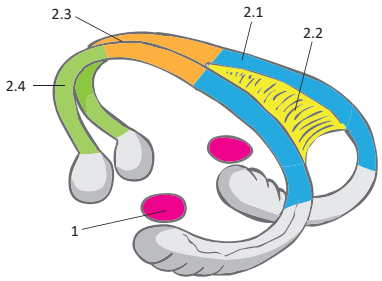

- 2.1 **Crus** – a paired „limb“
  - – a bundle following the outer edge of the pulvinar of thalamus
  - – as the paired crura reach the corpus callosum from below, converge, fuse and form the body of fornix (*corpus fornicis*)
- 2.2 **Commissure of fornix** (*commissura fornicis*)
  - – a connection between the right and left fornix
  - – a thin membrane spread between both crura, until they converge into the body of fornix
- 2.3 **Body** (*corpus*) – a single structure lying immediately below the corpus callosum
- 2.4 **Column** (*columna fornicis*)
  - – a paired „pillar“ arising from the body of fornix as it divides at its rostral end

3 **Nucleus accumbens** (*ventral striatum, striatum ventrale*)
– developmentally a part of the basal ganglia
– is adjacent to the septal nuclei and connected to the limbic system
– plays a crucial role in the mechanism of addiction, reward and satisfaction, fear or placebo effect
– sometimes it is referred to be a nucleus of addictions and desire

4 **Septal nuclei** (*septum verum*)
– are situated basally to the septum pellucidum (underlies the surface of the paraterminal gyrus)
– represent a center of reward and pleasure (hedony)

The Latin term for the medial forebrain bundle (MFB) is fasciculus medialis telencephali or fasciculus prosencephali medialis. When an experimental animal is presented with a bar, which when pressed stimulates the MFB via an electrode placed in its brain, the animal will prefer pressing the bar to feeding, which will lead to starvation.

In certain situations, the limbic system can bring out animal-like emotions in humans. Normally, the archicortex (which includes the limbic system cortex) is controlled and by the prefrontal cortex. The prefrontal cortex is the center of will, self-control, and social empathy. It allows the limbic system to exhibit what is socially appropriate in particular situation. In certain situations, this control can be weakened (alcohol consumption or emotional situations).

Stimulation of the amygdaloid complex increases attention and alertness. Bilateral lesions of the amygdala result in the loss of fear and anxiety (placidity), hyperphagia, hypersexuality, and visual agnosia. This group of symptoms is known as Klüver–Bucy syndrome. The amygdala is also involved in defensive reactions, fear and the fight-or-flight reaction.

The amygdaloid complex reinforces the retention of memories in the hippocampus during stressful and exciting moments. This explains why we remember important events, such graduation, marriage or the birth of a baby, for our whole life. Even years after the events, we are able to describe them in fine detail.

Stimulation of the septal nuclei in experimental animals causes the feelings of reward and euphoria. Lesions of the septal nuclei, on the other hand, elicit hyperactivity, anxiety and rage.

The fornix can be divided into the pars libera, which is a “free part” running downwards on the anterior wall of the third ventricle, and the pars tecta, which is a “hidden part” entering the hypothalamus and terminating in the mammillary bodies.

Clinical notes

The amygdalo-hippocampal complex is frequently affected in temporal lobe epilepsy. In such cases, it is atrophic (small in volume) and sclerotic (increased number of glial cells forming the equivalent of a scar in the brain).

Connections

1 **Fornix** – a connection between the hippocampus and mammillary bodies
2 **Mammillary bodies** (*corpora mammillaria*)
  2.1 **Mammillothalamic tract** (*tractus mammillothalamicus*)
    – connects the subcortical limbic structures with the anterior thalamic nuclei
    – further via the thalamocotical tract to the cingulate gyrus and prefrontal cortex
  2.2 **Mammillotegmental tract** (*tractus mammillotegmentalis*)
    – connects the mammillary nuclei with the tegmentum of midbrain and reticular formation
3 **Amygdalofugal pathways**
  3.1 **Stria terminalis of thalamus** (dorsal amygdalofugal pathway/bundle)
    – a mutual connection of the amygdala with the hypothalamus and septum verum
    – running around the thalamus and basal ganglia (forming an axonal arch)
    – affecting the hypothalamus-hypophyseal axis and autonomic nervous system
  3.2 **Ventral amygdalofugal pathway/bundle** – originates in the basolateral and central nuclei and runs directly to the thalamus (dorsomedial nucleus), hypothalamus, limbic cortex, septal nuclei, nucleus accumbens, and brainstem nuclei
4 **Stria medullaris of thalamus** (*stria medullaris thalami*)
  – connects the hypothalamus and septal nuclei with the habenular nuclei (*ncll. habenullares*)
  – runs along the dorsomedial aspect of the thalamus into the habenular region
  – after an interpolation in the habenular nuclei, the second neuron passes into the brainstem via the habenulointerpeduncular tract (tractus habenulointerpeduncularis)
5 **Anterior commissure** (*commissura anterior*) – facilitates a communication between both hemispheres
  – the anterior part interconnects the oflactory cortex; the posterior part interconnects the temporal lobes
6 **Longitudinal striae of corpus callosum, medial and lateral** (*striae longitudinales corporis callosi mediales et laterales*)
  – a connection between the septal nuclei plus subcallosal area and hippocampus via the dentate gyrus
7 **Posterior longitudinal fasciculus** (*fasciculus longitudinalis posterior/dorsalis*)
  – a visceromotor bundle situated in the brainstem reciprocally connecting the hypothalamic nuclei with autonomic sympathetic and parasympathetic nuclei
  – called the pathway of the „visceral brain“
  – controls involuntary, unconscious and spontaneous body processes (e.g. intestinal tract peristalsis)
  – there is no direct connection with the hypothalamus in this pathway
8 **Medial forebrain bundle** (MFB, *fasciculus medialis telencephali*) – reciprocally connects the cortical and subcortical limbic areas
  – runs from the midbrain through the hypothalamus into the prefrontal cortex

The Papez circuit

– connects the hypothalamus with the cortical and subcortical structures
– a shortened version of this circuit skips the hypothalamus

Brief description:

- 1. originates in the **hippocampus**
- 2. runs via the **fornix**
- 3. enters the **mammillary nuclei** in the hypothalamus
- 4. runs further via the **mammillothalamic tract**
- 5. enters the anterior **thalamic nucleus**
- 6. projects to the **cingulate gyrus** and **orbitofrontal association cortex**
- 7. runs via the **cingulum** (pathway within the cingulate gyrus)
- 8. into the **entorhinal cortex** (BA 28)
- 9. then the circuit terminates in the **subiculum** and **hippocampus**

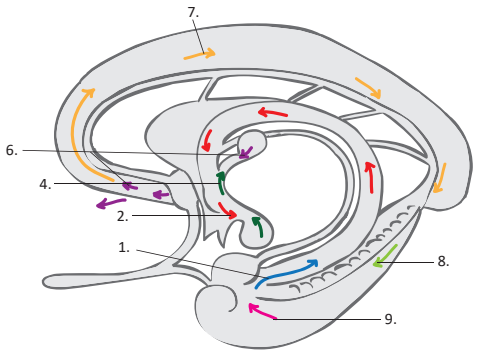

Collaterals of the main circuit:

1. to the **hypothalamus**
2. to the **nucleus accumbens**
3. to the **septal nuclei** and back to the hippocampus
4. from the hypothalamus via the habenular nuclei to the interpeduncular nucleus of midbrain
5. to the reticular formation and motor and autonomic nuclei in the brainstem and spinal cord

Functions of the limbic system

1. Is involved in **integration of sensory inputs**
2. Is involved in the processes essential for preservation of individual entity and species (**instinct of self-preservation, fight or flight response**, etc.)
3. Affects **food and water intake**
4. Affects **sexual behaviour, reproduction, and nurture**
5. Affects the **emotional aspect of behaviour and memory processes**
6. Affects the **autonomic nervous system, hormonal hypothalamic-hypophyseal axis** and **brainstem centres essential for life** (breathing and cardiovascular brainstem centres)

This copy belongs to ali yaghoubi

In contrast to the brainstem and its structures/centres which are almost completely developed at birth, **the structures of the limbic system develop extensively postnatally**. For a proper development, the limbic nuclei and other structures (amygdaloid complex, septal nuclei, hippocampus and cortex) **require appropriate emotional, social, perceptive** (sensory), **and cognitive** (including recognition and thinking) **stimulation** during the first years of life. The limbic system is „full of expectations". Appropriate and timely stimulation is required for a successful formation and **development of personality, behaviour, and emotions**. If the stimulation is insufficient, inappropriate or badly-timed, the development of neurons, synapses, and neuronal networks may be affected, leading to a loss of dendrites, neurons and neuroglia or even to an atrophy or hypertrophy of certain structures. The limbic system develops successively **in a predefined organized fashion**, which is responsible for the typical behavioural and emotional patterns seen in children of particular age. Maturation of the limbic system **begins in the amygdaloid complex, followed by the cingulate gyrus and septal nuclei**. These structures are responsible for social and interpersonal development. **The orbitofrontal and association cortex maturates as the latest**, and is very plastic up to the twenties.

First year of life

– appropriate and healthy emotional and sensory stimulation by the mother and family is essential
– in the first months of life the infants typically search for social contacts and respond to everyone
– stimulation of the limbic system represents some kind of a psychological exercise
– in the first months the children are not able to distinguish family from strangers visually
– nevertheless, the role of the family and proper stimulation is crucial

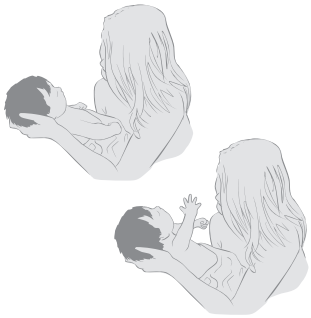

Emotional stimulation and stimulation of the senses of children by mother

Maturation of the amygdaloid complex

– an immature amygdaloid complex is responsible for the „**oral stage**" (exploring the world with lips and mouth) and social curiosity
– infants of this age are **not afraid of strangers**
– the amygdaloid complex typically reacts actively to seen faces
– the infants up to the 6th month smile and stare at everyone, **the mother is not their exclusive focus of interest**
– as the amygdaloid complex begins to maturate after the 6th month, **feelings of fear and mistrust appear**



Exploring objects by mouth and lips

Maturation of the cingulate gyrus

– develops slowly from the first year of life and during the toddler age
– **separation anxiety** is a prominent sign of maturation of the cingulate gyrus
– in the sixth to twelfth month of age the infant **focuses on the mother** and is not friendly to everyone
– the infant is **able to recognize familiar people** by their face, typical voice, and typical smell

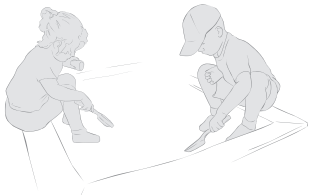

Children play with each other, but they do not share their toys

As the cingulate gyrus and the frontal lobe continue to develop, children start to learn by playing games in which they imitate adults (e.g. their parents, school teachers, doctors).

The child's colourful imagination emerges in the form of fairy tales. This fantasy period begins in the 3rd year of life and continues until puberty (when sexual functions start to mature).

The cingulum may be referred to as the centre of desire for social and emotional stimulation. It is responsible for emotional memories, attention, excitement, affection, love, fear, and happiness.

Separation anxiety is a function of the septal nuclei. Infants may wonder away from their mothers. However, losing the mother from sight leads to anxiety and causing the infant to return.

Animals with bilateral lesion of the septal nuclei search for animals they would usually avoid and come into a physical contact with them. Mice with such lesion approach cats or approach inanimate objects, as if they were their natural partners.

An immature amygdaloid complex is linked to the "oral stage" of development. Maturation of the septal nuclei leads to the "phallic stage" of Freudian psychosexual development. Electrical stimulati on of the septal nuclei leads to erection in experimental animals.

During adolescence and puberty, the limbic system is not yet firmly under the control of the neocortex and is strongly stimulated by risky behaviour, such as abusing drugs. This behaviour is typically admired and encouraged by peers of the same age. Respect and admiration for parents and other authorities, such as teachers is lost. During puberty, teenagers typically experience their first sexual encounters, which are typically stormy and instable. Puberty is also associated with the first attempts to leave the family nest and with the discovery forbidden behaviour (smoking, alcohol, drugs, fast driving etc.).

Maturation of the septal nuclei

– develop slowly
– maturate after the 3rd year of life and their development continues up to the pubescence
– the growing impact of the septal nuclei inhibits the activity of the amygdaloid complex
– contribute to the advances in social interaction – increased activity of the septal nuclei manifests as a suspicion towards and fear of strangers

Maturation of the prefrontal and orbitofrontal cortex

– executive functions of the prefrontal cortex develop slowly until the adulthood (25 years)
– imbalance in development and predominant activity of the limbic system is classically associated with risky behaviour of teenagers:
  – thinking and planning of future is short-term and often irrational
  – predominantly perceive, experience the world and self "here and now"
  – development of the prefrontal cortex in adolescence makes judgement increasingly sound
  – then the risky behaviour is replaced by a rational behaviour (a person maturates emotionally and mentally, begins to plan the future, family, looks for a stable partner and fully realizes the value of her/his life and her/his role in the world, searching for the meaning of life and fulfils own goals)

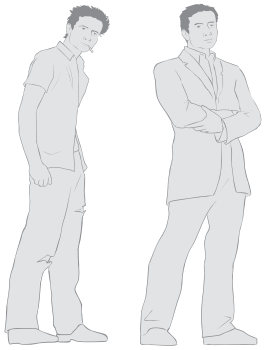

Transition from the risky teen behavior to a rationally thinking man

8.2 Impaired development of the limbic system

The septal nuclei are **highly vulnerable in the period between the 1st and 3rd year of age**: emotionally deprived or abused infants are shy. On the other hand, they can threaten or abuse their peers (due to the insufficient stimulation of the limbic structures in the critical emotional period). **Combative and aggressive behaviour is typical for infants who lacked the mother's care and love in the period critical for the limbic system development.**

Lesion of the amygdaloid complex

– lack of interest in interpersonal contacts and relations
  – they avoid contact with others and become loners
  – typical is an impaired ability to fall in and be in love
– some search for or induce themselves pain
  – probably as a result of insufficient stimulation in the critical period
  – their behaviour is inappropriate, disrespectful, and they are unable to adjust their manners to the context of a situation
– empathy is also impaired (inability to perceive emotions of others)
  – they are unable to recognize and understand the "body language", tone or timber of the voice, and facial expressions
– lesion of the amygdaloid complex may be associated with oral-stage fixation (obsession with oral stimulation)
  – excessive oral fixation can be seen in infants with developmental lesions of the brain (children with cerebral palsy or early postnatal meningitis or encephalitis)
– sometimes excessive masturbation or sexual deviation may appear



Inability to adapt behavior to a particular situation

Lesion of the septal nuclei

Septal hyperactivity – is associated with loss of interest in social contacts and closing oneself from others

Septal hypoactivity – in contrast to septal hyperactivity, it releases an excessive desire for social and physical contact, which is often linked to aggression, violent or eccentric behaviour



Extreme desire for physical contact

This copy belongs to ali yaghoubi

The sensory system includes perception of several senses – **tactile and pain sensation, position/posture sense**. **Superficial** (exteroceptive) **sensation** includes tactile and pain sensation (epicritic-discriminative, protopathic sensation – algesia, thermesthesia). **Deep** (proprioceptive) **sensation** includes position/posture sense, motion/movement sense, deep pressure and deep pain sensation. Stimuli are transmitted by different pathways (lemniscal or anterolateral system). All pathways converge in the thalamus and then continue to the sensory cortical areas. Their collaterals run to the reticular formation, nuclei of the brainstem, limbic system and cerebellum. The cerebellum requires continual information supply from peripheral receptors for its coordinating functions.

Perception

Somatosensory system

– tracts transmit information from the receptors of the skin, muscles, and tendons
– perikarya of the first order neurons are always located in the spinal ganglion or particular ganglion of the cranial nerve
– the first order neuron is invariably pseudounipolar:

1 **Protopathic sensibility**
  – receptors are free nerve endings and corpuscles of the skin
  – conducted by the spinothalamic tract
  – consists of pain, temperature, pressure and crude touch
2 **Epicritic sensibility**
  – touch, discriminative sensation (two-point discrimination)
  – is conducted by the evolutionarily younger projection pathways
3 **Proprioceptive sensation** – muscle, joint, and tendon sensation
  3.1 **Static proprioception**
  3.2 **Dynamic proprioception**

Receptors

1 **Free nerve endings** – pain and touch
2 **Corpuscles in the skin and within the wall of internal organs**
  – touch, tension, and pain
3 **Muscle spindles and tendon organs**
  – position/posture sense and motion/movement sense

Gamma loop

– gamma loop is responsible for the adaptation and regulation of muscle tone

1. **Activation of gamma loop** excites gamma motoneurons innervating muscle spindles
2. **Contraction of intrafusal fibres** irritates sensory endings of the same muscle spindles
3. **Information returns to the spinal cord** via the posterior root of the spinal nerve by a reflex arc (feedback circuits) and serves as feedback for muscle tone control and adaptation

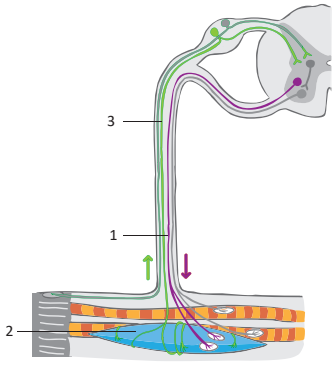

Scheme of the muscle, peripheral nerve, and spinal segment

Pain is an unpleasant sensory and emotional experience associated with current or potential tissue damage. There is no direct relationship between the intensity of the stimulus and the intensity of the perception of pain. Pain is always a subjective sensation.

Four components of pain:
1.**Sensory discriminative component (algognostic)** – awareness of pain (location, intensity, etc.)
2.**Affective-emotional component (algothymic)** – has an individual variability and can be influenced by upbringing or social habits (subjective perception and personal experience of pain)
3.**Autonomic component** – the ANS responses to pain by increasing heart rate and blood pressure. It can also respond with a syncopal reaction (fainting).
4.**Motor component** (fight, flight or fright response) – acts to relieve pain by changing the position of the body, mucular spasm, pain relieving positions, muscular spasms and distortions in the balance between agonists and antagonists resulting in.

The most common classification of pain fibres:
1. **Somatic** pain is carried by the poorly myelinated Aδ fibres (7–14 m/s), which ascend in the anterior and lateral spino-thalamic tracts
2. **Visceral** pain is carried by the unmyelinated C fibres (0, 5–3 m/s), which ascend in the spino-reticular tract
3. **The affective-emotional** component of pain travels in the spino-parabrachial tract to the limbic system.

Referred pain is a pain that originates in the internal organs, but is perceived on the surface of the body. It is hypothesised to result from information from visceral sensory fibres crossing over to somatic sensory neurons via spinal cord interneurones.

Phantom pain is a sensation related to a limb or an organ that is not physically part of the body. It typically occurs after limb amputation.

Dissociated sensory loss is the selective loss of specific sensory modality.

Somatosensory tracts

– transmits exteroceptive, proprioceptive, and interoceptive sensation into the CNS
– ascending information runs to the specific nuclei of the thalamus and, after interconnection, further to the primary somatosensory cortex (postcentral gyrus, BA 3, 2, 1)

Spinal somatosensory system:

– the first order neuron is a pseudounipolar neuron in the spinal ganglion
1 **Lemniscal system / medial lemniscus** – axons of the second order neuron, after decussating in the brainstem, resemble a white ribbon, and therefore are termed the medial lemniscus
– conducts mainly fine touch (fine skin sensation), vibration, and conscious proprioception
2 **Anterolateral system** – axons of the second order neuron pass through the anterior and lateral funiculus, and therefore it is termed the anterolateral system
– transmits mainly temperature, pain sensation, and crude touch (crude skin sensation)
2.1 **Spinothalamic tract**
2.2 **Spinoreticular tract**
2.3 **Spinotectal system**

Spinal tracts passing into the cerebellum:

– tracts convey somatosensory afferents to the cerebellum (position/posture sense and motion/movement sense, plus collaterals from the lemniscal and anterolateral system)
3.1 **Anterior spinocerebellar tract**
3.2 **Posterior spinocerebellar tract**
3.3 **Spino-cuneo-cerebellar tract**
3.4 **Spino-olivo-cerebellar tract**
3.5 **Rostral spino-cerebellar tract**

Somatosensory system of the cranial nerves:

– conveys sensation from the skin of the head, soft tissues, joints, bones of the skull, from mucous membranes of the oral and nasal cavities, pharynx, larynx, and cornea
– the first order neuron is a pseudounipolar neuron:
1 **Trigeminal nerve** – trigeminal ganglion and mesencephalic nucleus
2 **Glossopharyngeal nerve** – superior and inferior ganglion
3 **Vagus nerve** – superior and inferior ganglion
– the second order neuron is located in the principal and spinal nucleus of the trigeminal nerve, its axons form:
1 **Trigeminal lemniscus**
– conveys tactile, pain, and temperature impulses from the facial skin, mucous membranes, and eye, plus proprioceptive information from the facial and masticatory muscles
2 **Posterior/dorsal trigeminothalamic tract**
– receives signals from Meissner and Vater-Pacinian corpuscles (pressure and tactile discrimination sensation)
3 **Anterior/dorsal trigeminothalamic tract**
– transmits pain, temperature, and crude touch from the face, head, and neck (n. V, VII, IX, X)

Feedback control of afferentation (cortical control of subcortical structures):
1 Corticothalamic tract
2 Corticoreticular tract
3 Corticunuclear fibres
4 Corticobulbar tract
5 Corticospinal tract

Somatosensory homunculus

– the somatotopic arrangement of the primary somatosensory area (BA 3, 1, 2) is unequally distributed according to the density of afferents
– areas of the lip and hand occupy a significantly larger cortical surface than areas with lower concentration of receptors (back, lower extremities, etc.)

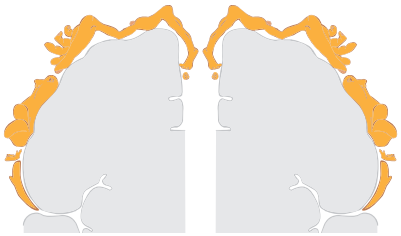

Scheme of homunculus on the frontal section through the postcentral gyrus

This copy belongs to ali yaghoubi

The sensory tracts of the brainstem represent a continuation of the spinal sensory tracts. According to their course in the white matter of the spinal cord, the sensory tracts are classified into the anterolateral and lemniscal system. The tracts of **the anterolateral system** cross the midline at the level of the spinal cord and their second order neuron (its perikaryon) is located at the posterior spinal roots. The system **transmits mainly pain, body temperature, and protopathic sensation**. The second order neuron (its perikaryon) of **the lemniscal system** is located in the gracile and cuneate nucleus. The tract crosses the midline at the level of the medulla oblongata. It **conveys mainly protopathic and discriminative sensation, vibratory sensation, and conscious proprioception**.

Somatosensory tracts:

- 1 **Medial lemniscus**
- 2 **Anterolateral system**
  - 2.1 **Spinothalamic tract** (*tractus spinothalamicus*)
  - 2.2 **Spinoreticular tract** (*tractus spinoreticularis*)
  - 2.3 **Spinotectal tract** (*tractus spinotectalis*)

Tracts passing to the cerebellum:

- 3 **Anterior spinocerebellar tract** (*tractus spinocerebellaris anterior*)
- 4 **Posterior spinocerebellar tract** (*tractus spinocerebellaris posterior*)
- 5 **Spino-olivo-cerebellar tract** (*tractus spino-olivo-cerebellaris posterior*)
- 6 **Spino-cuneo-cerebellar tract** (*tractus spino-cuneo-cerebellaris*)
- 7 **Rostral spino-cerebellar tract** (*tractus spino-cerebellaris rostralis*)

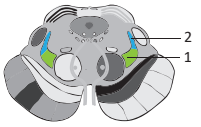

Rostral section of the mesencephalon

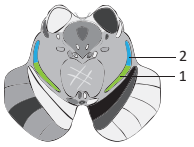

Caudal section of the mesencephalon

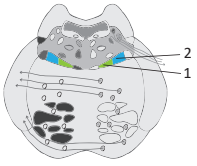

Rostral section of the pons

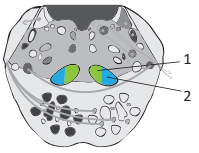

Caudal section of the pons

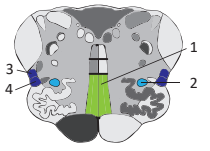

Rostral section of the medulla oblongata

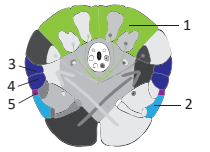

Caudal section of the medulla oblongata

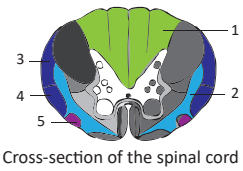

Cross-section of the spinal cord

We describe the following features of neuronal tracts:
– origin
– location and number of synapses
– termination
– course and decussation
– function

We use the following abbreviations when describing neuronal tracts:
O – origin
C – course and crossing
T – termination
F – function

The posterolateral tract of Lissauer is formed by axonal fibres from the spinal ganglia entering the posterior spinal root. The fibres are divided into ascending and descending fibres. The tract passes through one or two spinal segments before entering the gelatinous substance of Rolando.

Protopathic sensation includes evolutionary older quality of perception. It alerts animals to life or health danger.

The spino-bulbo-thalamo-cortical tract (*tractus spinobulbothalamocorticalis*), posterior column-medial lemniscus pathway (PCML), dorsal column-medial lemniscus pathway (DCML), dorsal white column-medial lemniscus system and lemniscal system are synonyms for the medial lemniscus system.

Clinical notes

Tabes dorsalis is a term used for demyelination of the posterior funiculus. It can be caused by syphilis, deficiency of vitamin B12 and some autoimmune diseases.

1 **Lemniscal system / medial lemniscus**

O: central branches of the pseudounipolar neurons in the spinal ganglion, enters the spinal cord via the posterior spinal root

C: three-neuron ascending tract
- – at the level of the spinal cord passes ipsilaterally (does not cross the midline)
- – runs to the gracile and cuneate nucleus in the medulla oblongata (where it interpolates at the second order neuron)
- – crosses at the decussation of the medial lemniscus and then continues contralaterally as the medial lemniscus
- – in the midbrain passes laterally and runs to the ventral posterolateral nucleus of the thalamus
- – after the interpolation to the third order neuron passes in the internal capsule to the cerebral cortex

T: the tract terminates in the primary somatosensory cortex (BA 3, 1, 2), during its course in the brainstem it emits collaterals to the cerebellum (spino-bulbo-cerebellar tract) and reticular formation (spino-bulbo-reticular tract)

F: transmits discriminative, vibration, and pressure sensation and static proprioception from muscles, tendons, and joints

– the tract has somatotopic arrangement and passes in two fascicles:
- 1.1 **Gracile fasciculus of Goll** (*fasciculus gracilis*) – medial fascicle
  - – contains ascending axons from the spinal ganglia corresponding to the sacral, lumbar, and caudal thoracic spinal segments (T7–S5)
- 1.2 **Cuneate fasciculus of Burdach** (*fasciculus cuneatus*) – lateral fascicle
  - – contains ascending axons from the spinal ganglia corresponding to the cranial thoracic and cervical spinal segments (C1–T6)

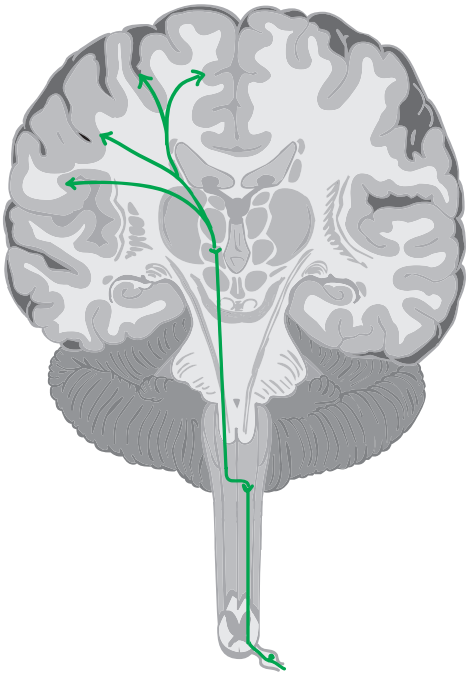

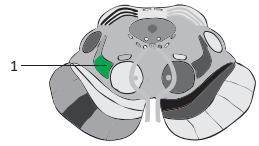

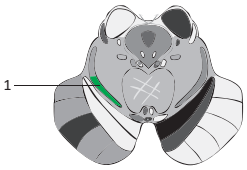

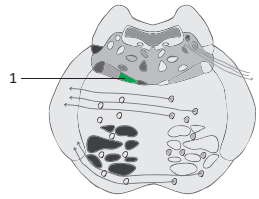

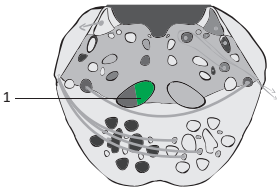

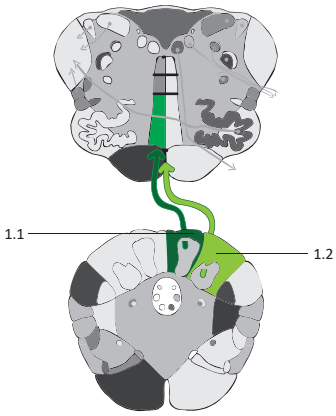

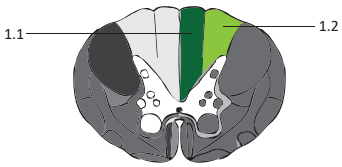

This copy belongs to ali yaghoubi

- 1 **Spinothalamic tract** (*tractus spinothalamicus*)
  - **O:** neuron axons of the layer I, II, IV-VI in the posterior horn of the spinal cord
  - **C:** three-neuron tract (pseudounipolar neuron, spinal cord, and thalamus), crosses the midline ventrally to the central canal (passes contralaterally), runs in the anterior and lateral funiculus, in the brainstem passes laterally and in the midbrain as the spinal lemniscus (component of the medial lemniscus)
  - **T:** interpolates in the ventral posterolateral nucleus of the thalamus and continues to the BA 3, 1, 2
  - **F:** transmits nociception, partially also crude touch and temperature sensation

- 2 **Spinoreticular tract** (*tractus spinoreticularis*)
  - **O:** neuron axons of the layer IV-VII in the posterior horn of the spinal cord
  - **C:** two-neuron tract which does not cross the midline (majority of fibers passes ipsilaterally), fibers pass mixed with those of the lateral spinothalamic tract
  - **T:** reticular formation of medulla oblongata, pons, and midbrain
  - **F:** transmits information about slow pain and is involved in the ascending reticular activating system (ARAS) which has an important role in maintaining of consciousness and modulating activity of many CNS structures, the third order neuron ("neuron of slow pain") is located in the intralaminar nuclei of the thalamus and its projections lead to the frontal and prefrontal cortex

- 3 **Spinotectal tract** (*tractus spinotectalis*) – rudimentary in human
  - **O:** neuron axons in the posterior horn of the spinal cord
  - **C:** two-neuron tract which crosses the midline (passes contralaterally)
  - **T:** superior colliculus of tectum and periaqueductal grey substance of midbrain
  - **F:** transmits tactile and proprioception information and integrates them with visual stimuli, serves for a coordination between head, neck, eye movements, and tactile stimuli

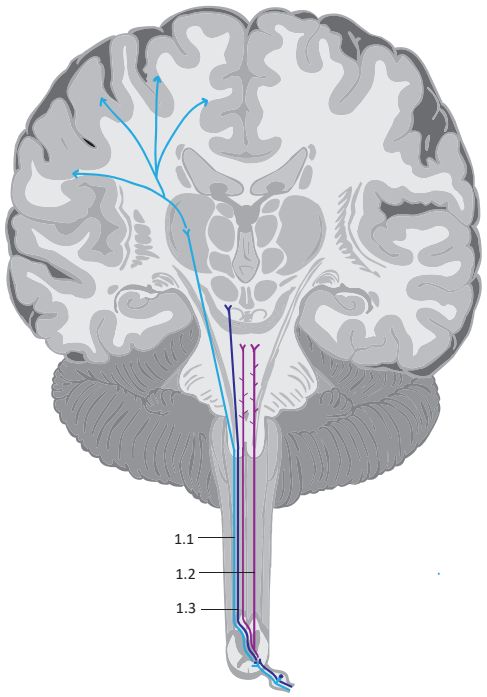

The (anterior and lateral) spinothalamic tract is also known as the neospinothalamic tract. **The spinoreticular tract** is also known as the paleospinothalamic tract. Together, these two tracts form the anterolateral system.

The spinomesencephalic tract is a part of the spinoreticular tract which terminates in the central grey substance. Its function is descending inhibition of pain at the spinal cord level (by activating the central grey substance and raphe nuclei via the raphespinal tract – performed by serotoninergic neurons).

The spinohypothalamic tract contains fibres that pass directly to the hypothalamus and fibres which pass indirectly to the hypothalamus via the reticular formation. Its fibres modulate the autonomic response to pain.

The rostral spinocerebellar tract has the same function as the anterior spinocerebellar tract. The tract passes uncrossed, enters the cerebellum via the superior and inferior cerebellar peduncles. However it's function in humans hasn't fully elucidated.

The nucleus of Stilling-Clarke is a huge nucleus located in spinal segments T10–T12. It receives fibres carrying proprioception information from the lower limb and the lower half of the trunk

Approximately 40% of the fibres of the corti-cospinal tract originate in the premotor cortex, supplementary motor area (BA 6), somatosensory area (postcentral gyrus, BA 3, 1, 2), association areas of the temporal lobe and the cingulate gyrus.

Clinical notes

Syringomyelia is a disorder in which a cyst or cysts are formed within the spinal cord, especially in the thoracic segments. The cysts are filled with cerebrospinal fluid and their expansion can cause compression of the spinothalamic tracts decussation. Symptoms depend on the location and cysts size.

Dissociated sensory loss in syringomyelia is a pathological condition resulting from the interruption of the decussating spinothalamic tract. Syringomyelia causes sensory loss of pain and temperature perception with preservation of fine touch. Typically, an impairment of epicritic sensation and less typically of protopathic sensation, vibratory sensation, sense of position and movements.

- 1 **Anterior spinocerebellar tract** (*tractus spinocerebellaris anterior*)
  - **O:** neuron axons of the segments T12-L5 (in lamina V, VI and VII)
  - **C:** two-neuron tract which crosses the midline at the level of the spinal cord (passes contralaterally), enters the cerebellum via the superior cerebellar peduncle and within the cerebellum again crosses the midline back to the original side – fibers cross the midline twice and get back to the original side
  - **T:** cerebellar cortex as mossy fibers
  - **F:** transmits mainly proprioception and mechanoreception (from joints, tendons, fasciae, and skin), dynamic proprioception from the lower limbs, lower half of the trunk and partially also tactile sensation

- 2 **Posterior spinocerebellar tract** (*tractus spinocerebellaris posterior*)
  - **O:** axons of neurons in the posterior thoracic nucleus of Stilling-Clarke in the segments C8-L3 (solely the lamina VII)
  - **C:** two-neuron tract which does not cross the midline (passes ipsilaterally), enters the cerebellum via the inferior cerebellar peduncle
  - **T:** cerebellar cortex as mossy fibers
  - **F:** transmits mainly proprioceptive information from the lower limb and lower half of the trunk to the spinal cerebellum

- 3 **Spino-olivocerebellar tract** (*tractus spinoolivocerebellaris*)
  - **O:** axons of neurons in the nucleus proprius of the posterior horn
  - **C:** three-neuron tract which crosses the midline (passes contralaterally), runs at the border between the anterior and lateral funiculus and enters the inferior olivary complex, after interpolation again crosses the midline and enters the cerebellum, via the inferior cerebellar peduncle
  - **T:** cerebellar cortex as climbing fibers and terminates at the cells of Purkinje
  - **F:** component of functional circuits between the spinal cord, cerebellum and inferior olive, participates in movement control and transmits information from proprioceptive receptors and mechanoreceptors

- 4 **Spinocuneocerebellar tract** (*tractus spinocuneocerebellaris*)
  - **O:** axons of neurons in the spinal ganglion
  - **C:** two-neuron tract passes ipsilaterally as a component of the cuneate fascicle, interpolates in the accessory cuneate nucleus, fibers of the cuneocerebellar tract enter the cerebellum via the inferior cerebellar peduncle
  - **T:** cerebellar cortex as mossy fibers
  - **F:** the accessory cuneate nucleus has a similar function as the posterior thoracic nucleus for proprioception from the upper limb and uppet half of the trunk – contributes to motor learning

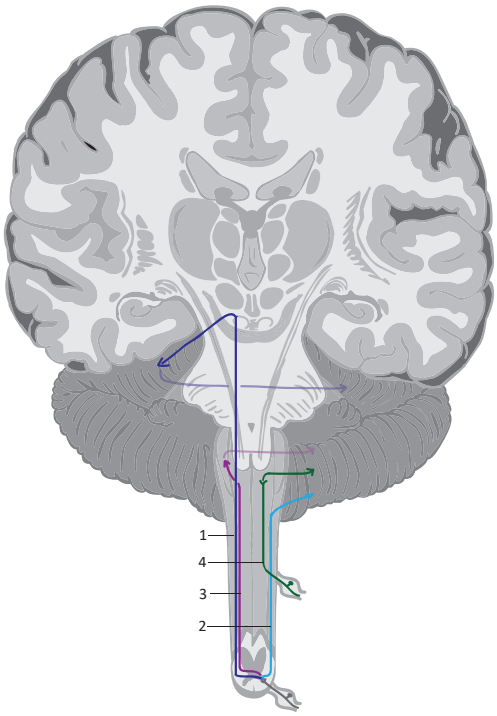

This copy belongs to ali yaghoubi

Voluntary motor control is the ability of an organism to perform a voluntary movement. **Postural motor control** is the ability to maintain an upright body position against gravity and to maintain balance and body position in space. **Motor control of fine, gross and oral motor skills.** They are necessary for standing and walking. Fine motor skills pertain to the ability to accurately move hands and feet. Oral motor skills refer to movements of the lips, cheeks, jaws and palate. These movements facilitate eating, speaking and swallowing.

Structures involved in motor control

- 1 **Somatosensory cortical areas**
  – provide information about the position of the head and body, tactile and pain sensation
- 2 **Association cortical areas**
  – provide complex information from all senses and memory
- 3 **Primary motor cortex**
  – sends instruction to motoneurons
  – has somatotopic arrangement
- 4 **Premotor cortex**
  – participates in preparation and initiation of movements via circuits in the basal ganglia cooperating with the motor cortex and cerebellum
- 5 **Supplementary motor cortex** – participates in preparation and modification of movements
- 6 **Cingulate gyrus** (a part of the limbic system)
  – maintains motor attention and motivation
- 7 **Superior and inferior parietal lobule**
  – participates in preparation of movement patterns and motor timing
- 8 **Basal ganglia**
  – maintains movement patterns via their circuits
  – generate all possible variants of movements
  – influence and adapt muscle tone depending on the motor task
- 9 **Cerebellum** – maintains movement patterns
  – participates in regulation of muscle tone
  – modifies fine and gross motor skills
- 10 **Reticular formation** – affects spinal motoneurons and motoneurons of the cranial nerves
  – participates in regulation of muscle tone
- 11 **Thalamus** – the ventral anterior nucleus and ventral lateral nuclei modulate communication between the cortex, basal ganglia, and cerebellum
- 12 **Tectum of midbrain** – participates in coordination of eye movements and coordination of the head and neck
- 13 **Vestibular nuclei**
  – participate in the balance and oculomotor reflexes
- 14 **Spinal motoneurons and motoneurons of cranial nerves**
  – transmit instructions into striated muscles

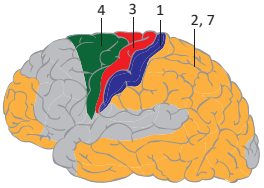

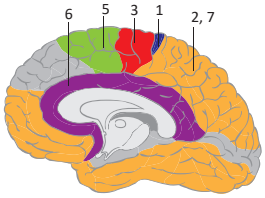

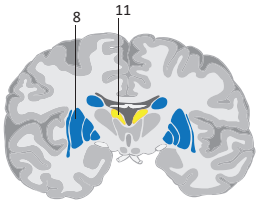

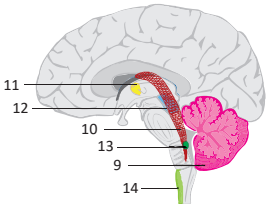

Motor homunculus

– the somatotopic arrangement of the primary motor area (BA 4), it is unequally distributed according to the fineness of movements and the number of neuromuscular units
– the muscles of the hand and muscles of speech organs occupy significantly larger areas of the cortex than the muscles of the trunk or proximal muscles of the limbs



Scheme of homunculus on the frontal section through postcentral gyrus

Mobility signifies all motor functions performed by skeletal and smooth muscles.

Motility is a sum of movements performed only by smooth muscles.

Sensory-motor control refers to the very close cooperation between the sensory and motor systems. The sensory-motor cortex refers to the primary somatosensory area together with the primary motor area (BA 3, 1, 2 + BA 4).

Posture means the maintainance of body position against gravity. It creates a support base (punctum fixum) for performing voluntary movements.

Postural stability is the ability to maintain the posture in order to avoid falling while moving.

Clinical notes

Brain plasticity refers to the ability of the brain react and adapt to changes. When when part of the brain is damaged, other parts can take over the lost functions. Physiotherapy is an essential tool that supports the process of plasticity.

Movements

1. **Planning of movement**
   1.1 the idea of movement is created in **the association cortex**
   1.2 **sensory areas** indicate the current position of the body
   1.3 **the limbic system** adds motivation and concentration
   1.4 **the cerebellum** informs about all possibilities of movements with regard to the position and current movements
   1.5 **motor areas** create a concept of movement and send it to the basal ganglia
2. **Movement programming**
   – in the basal ganglia
   2.1 the basal ganglia **receive all information**
   2.2 **select proper movement patterns**
   2.3 the cerebellum **informs** the basal ganglia **about stimuli** which were received; it participates also in a selection of ideal movement patterns
   2.4 **select an ideal movement pattern**
   2.5 **a concept is sent back** to the primary motor area
3. **Inputs of movement**
   3.1 **the primary motor area** sends an instruction to move via the corticospinal and cortinuclear tracts, other important is timing
   – in order to perform the movement at the right moment and proper sequence
4. **Movement performing**
   4.1 **the spinal motoneurons and motor nuclei of the cranial nerves** receive information and send it to the skeletal muscles
   4.2 **muscle spindles and Golgi tendon organs** re-inform the CNS about changes in muscles and tendons tension
   4.3 **proprioceptive receptors, vestibular organ and feedback from the visual pathway** inform the cerebellum about body position and moving in space
   4.4 **the cerebellum informs the primary motor area** which steadily modulates direction and quality of movements
   4.5 **the cerebellum also informs the subcortical structures** which modulate position of the body and muscle tone
5. **Movement control**
   5.1 **the cerebellum steadily controls** the whole movement pattern, its direction, velocity, preciseness, and ending
6. **Learning of movements**
   – frequent repetition and practising lead to learning and improvement
   – it leads to creation of new movement patterns or to modifying of old ones
   – in motor learning the cerebellum, basal ganglia (especially the striatum), motor and association cortex, and hippocampus are involved

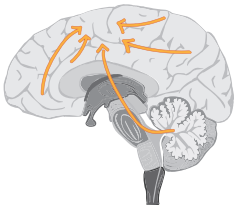

Planning of movement
„I want to hit the ball."

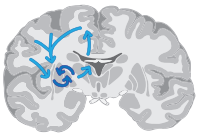

Movement programming
„Which is the best way how to hit the ball!"

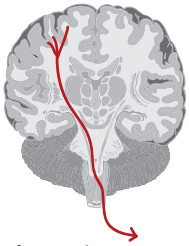

Performing the movement
„Step forward and play forehand."

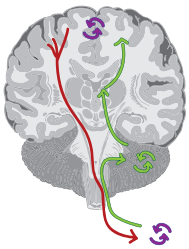

Control of movement
„Oh, the ball bounced differently than I had expected."

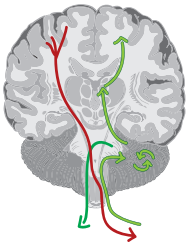

Change of movement
„Turn around, change the position of the center of gravity and play backhand."

Example of a voluntary movement (a tennis player)

1. **Planning of movement** – a tennis player watches the ball, holds and feels a racquet in the hand, maintains a position and wonders where and when the ball will hit the ground (top spin, bottom rotation, etc.)
   – he wants to hit the ball with the greatest force and precision
   – he recalls all similar strikes he has experienced in the past and makes plans
2. **Movement programming** – there is a possibility to play forehand or backhand, step forward or backward, play a one-handed or two-handed hit, etc.
   – the goal is to choose the most suitable movement from a large number of all possible movement patterns
3. **Inputs for movement programming** – when is the right time coming?, when to start the chosen movement pattern?
4. **Movement performance** – one lower limb steps out, the other goes into crouch, the upper limb with the racquet extends and the other flexes, etc.
5. **Movement control** – the ball hits the ground in a different angle and with an unexpected spin and the newly discovered information modifies the movement pattern (changing of the gravity center, limbs extension or flexion, etc.)
6. **Learning of new movement** – the brain remembers whether the ball was played
   – he realizes that the ball can hit the ground in a different angle than expected and for the next time the player will be prepared for such option and will choose another motor pattern



This copy belongs to ali yaghoubi

Motor tracts can be classified into two main systems: **the pyramidal and extrapyramidal systems**. From the functional point of view and according to their course, motor tracts can be classified into the **medial, lateral, and third systems**. **The medial system consists of the extrapyramidal tracts** (vestibulospinal, tectospinal, and the medial part of the reticulospinal tract). It enables **movements of the trunk**, and exerts a large amount of control over the epaxial back muscles. **The lateral system** is responsible for **movements of the extremities** through the pyramidal tract (corticospinal tract) and the rubrospinal tract. **The third system** is responsible for involuntary emotional movements and gamma loop activity. It is formed by the lateral part of the reticulospinal tract, the raphespinal tract and the caeruleospinal tract.

Motor tracts

Pyramidal tracts

- 1 **Corticospinal tract**
  (*tractus corticospinalis*)
  - 1.1 **Lateral corticospinal tract**
    (*tractus corticospinalis lateralis*)
  - 1.2 **Anterior corticospinal tract**
    (*tractus corticospinalis anterior*)
- 2 **Corticonuclear fibers**
  (*fibrae corticonucleares*)

Extrapyramidal tracts

- 3 **Lateral vestibulospinal tract**
  (*tractus vestibulospinalis lateralis*)
- 4 **Medial vestibulospinal tract**
  (*tractus vestibulospinalis medialis*)
- 5 **Reticulospinal fibers**
  (*fibrae reticulospinales*)
- 6 **Tectospinal tract**
  (*tractus tectospinalis*)
- 7 **Rubrospinal tract**
  (*tractus rubrospinalis*)
- 8 **Interstitiospinal tract**
  (*tractus interstitiospinalis*)
- 9 **Raphespinal tract and caeruleospinal tract**
  (*tractus raphespinalis et caeruleospinalis*)

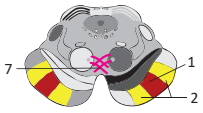

Rostral section of the mesencephalon



Caudal section of the mesencephalon

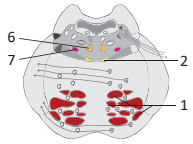

Rostral section of the pons

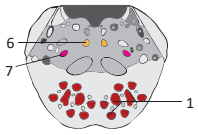

Caudal section of the pons

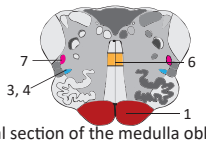

Rostral section of the medulla oblongata

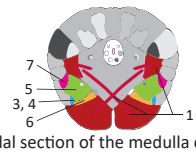

Caudal section of the medulla oblongata

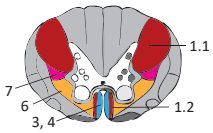

Cross-section of the spinal cord

We describe the following features of neuronal tracts:
– origin
– location and number of synapses
– termination
– course and decussation
– function

We use the following abbreviations when describing neuronal tracts:
O – origin
C – course and crossing
T – termination
F – function

Pyramidal cells are large neurones of motor cortex. They are the first order neurones of the corticospinal tract. Their axons create the pyramids of the medullar oblongata and terminate on alpha motor neurones of the anterior horn of the spinal cord

- 1 **Anterior and lateral corticospinal tract** (*tractus corticospinalis anterior et lateralis*)
  - **O:** mainly in neurons located in the cortical layers III and IV of the precentral gyrus – primary motor cortex (BA 4), some axons from the neurons of the premotor area (BA 6), primary somatosensory area (BA 3, 1, 2), and association somatosensory areas (BA 5, 7)
  - **C:** one-neuron tract descending within the internal capsule (its posterior limb), cerebral crus, basilar part of the pons (longitudinal pontine fibers) and elevating the pyramid at the border between the medulla oblongata and spinal cord
    – the majority of fibers crosses the midline (decussation of pyramid) and then descends crossed (80 %) and uncrossed (20 %)
  - **T:** the tract terminates at the motoneurons of the anterior spinal horn; a part of the fibers also terminates at the interneurons of the posterior spinal horn and participates in modification of afferentation
  - **F:** the tract transmits information for voluntary movements
    - 1.1 **Lateral corticospinal tract** (*tractus corticospinalis lateralis*)
      – lateral crossed tract
      – the tract has somatotopic arrangement and is formed mainly by the crossed fibers (only 10 % of the uncrossed fibers)
      F: influences mainly the distal muscles of the limbs
    - 1.2 **Anterior corticospinal tract** (*tractus corticospinalis anterior*)
      – anterior uncrossed tract
      C: the tract crosses the midline at the level of a corresponding spinal segment (or one/two segments cranially), its axons cross the midline in the anterior white commissure
      F: has an impact on the axial muscles and proximal muscles of the limbs

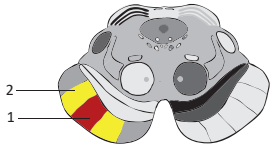

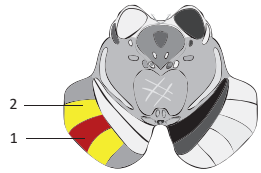

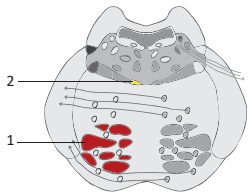

- 2 **Corticonuclear fibers** (*fibrae corticonucleares*)
  - **O:** in the precentral gyrus – motor cortex (BA 4) and in a part of the motor homunculus (cortical region of the head and neck)
  - **C:** one-neuron tract passing in close vicinity of the corticospinal tract (genu of internal capsule), then via the cerebral crus into the brainstem
  - **T:** the tract terminates in the motor nuclei of the brainstem for the head, face, and neck; the tracts for the brainstem nuclei pass on both sides with two exceptions: innervation of the inferior section of the motor nucleus of the facial nerve (inferior half of the face) and the nucleus of the hypoglossal nerve, both are controlled by the contralateral cortex
  - **F:** the fibers are responsible for voluntary movement control of the skeletal muscles of the head, face, and neck (nuclei of the V, VII, IX, X, XI and XII)

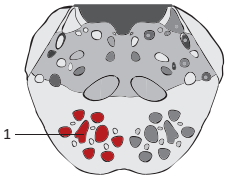

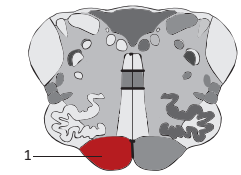

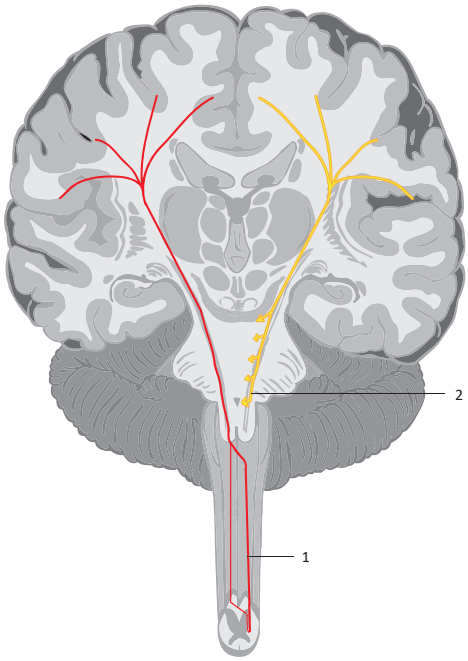

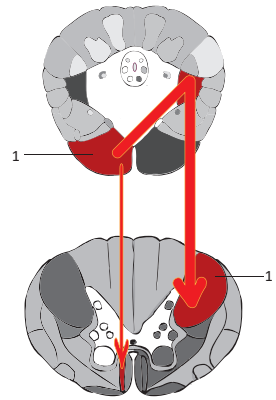

This copy belongs to ali yaghoubi

- 1 **Lateral vestibulospinal tract** (*tractus vestibulospinalis lateralis*)
  - **O:** axons of neurons in the lateral vestibular nucleus of Deiters
  - **C:** one-neuron tract which does not cross the midline (passes ipsilaterally)
  - **T:** the tract terminates at the spinal cord interneurons (in the layer VII and VIII) and also at spinal motoneurons
  - **F:** controls muscle tone of the back muscles and extensors – by that, it ensures maintaining of an upright body posture

- 2 **Medial vestibulospinal tract** (*tractus vestibulospinalis medialis*)
  - **O:** axons of neurons in the medial vestibular nucleus
  - **C:** one-neuron tract which passes both crossed and uncrossed as a part of the medial longitudinal fasciculus
  - **T:** terminates at the spinal cord interneurons (layer VII and VIII) and also at motoneurons in the cervical segments
  - **F:** stabilizes head position during walking and position changing, participates in coordination of head and eyes movements

- 3 **Reticulospinal fibers** (*fibrae reticulospinales*)
  - **O:** axons originating from the reticular formation of the pons and medulla oblongata
  - **C:** one-neuron tract passing crossed and uncrossed, axons originate in the same nuclei as the ARAS, then descend as a part of the extrapyramidal motor system
  - **T:** terminate at the spinal cord interneurons (in layer VII, VIII, IX)
  - **F:** activate extensors and flexors, control gamma loop and muscle tone, integrates cortical and cerebellar impact on somatomotor nuclei, integrates impact of the hypothalamus and limbic system on visceromotor nuclei and participates in pain reduction at the spinal cord level (DRIS – descending reticular inhibitory system)

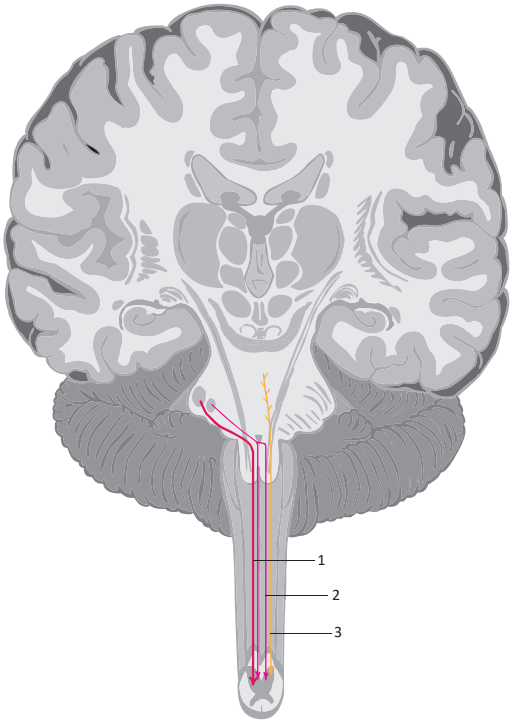

Deitersospinal tract is an obsolete term for the lateral vestibulospinal tract.

The rubrospinal tract is rudimentary in humans.

- 4 **Tectospinal tract** (*tractus tectospinalis*)
  - **O:** axons originating in the superior colliculus (of the tectum of the midbrain)
  - **C:** one-neuron tract crossing the midline in the posterior tegmental decussation (only a minor part passes uncrossed), in the brainstem it is located dorsolaterally and forms a part of the medial longitudinal fasciculus (this enables coordination of eyes, head, and neck movements)
  - **T:** terminates in the superior cervical segments (at neurons in the layer VI, VII, VIII)
  - **F:** it is responsible for reflex postural movements in a response to visual and auditory stimuli and also coordinates head and eyes movements in visual pursuing

- 5 **Rubrospinal tract** (*tractus rubrospinalis*)
  - **O:** axons originating in the red nucleus (its magnocellular part)
  - **C:** one-neuron tract crossing the midline at the level of the superior colliculus in the anterior tegmental decussation (passes contralaterally)
  - **T:** terminates in the cervical spinal segments (at neurons in the layer VI, VII, VIII)
  - **F:** controls mainly the motoneurons of the upper limbs, participates in activation of the flexors motoneurons and in inhibition of the extensors motoneurons

- 6 **Interstitiospinal tract** (*tractus interstitiospinalis*)
  - **O:** axons originating in the interstitial nucleus of Cajal
  - **C:** one-neuron tract which does not cross the midline (passes ipsilaterally); in the brainstem it represents a part of the medial longitudinal fasciculus
  - **T:** terminates in the cervical spinal segments (at interneurons in the layer VII and VIII)
  - **F:** responsible for control of nuchal muscles tone depending on vestibular and visual stimuli

- 7 **Raphespinal tract** (*tractus raphespinalis*)
  - **O:** axons originating in the raphe nuclei of the medulla oblongata reticular formation
  - **C:** one-neuron tract (passes both crossed and uncrossed)
  - **T:** the tract terminates at interneurons and motoneurons (in the layer I, II, V and VII)
  - **F:** central inhibition of pain (serotoninergic-enkephalinergic systems), has an impact on autonomic functions and represents a component of the third motor system (monoaminergic descending pathways together with the caeruleospinal tract)

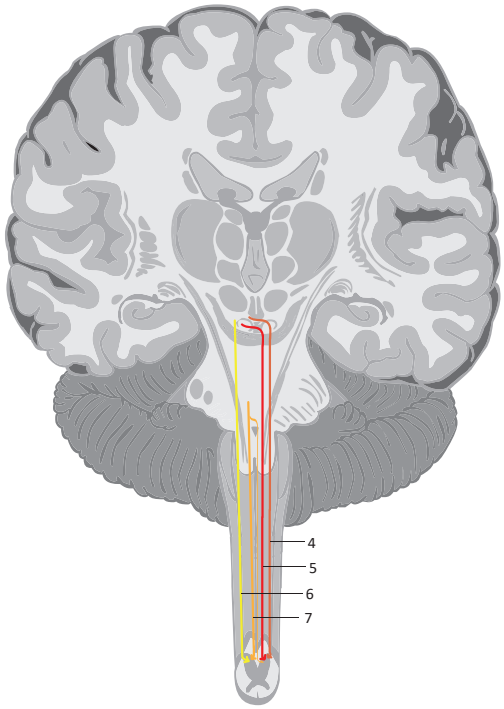

This copy belongs to ali yaghoubi

The visual pathway is a four-neurone tract. The first, second and third order neurones are located in retina. The fourth order neruones are located in the lateral geniculate body of the metathalamus. These neurones **relay visual information from the retina to the primary visual area** in the occipital lobe. Collaterals from the visual pathway are responsible for the **pupillary light reflex**, **coordinated eye movements** and contribute to **motor control of the whole body**. The hypothalamic collaterals have an important effect on **autonomic functions and circadian rhythm**.

Neurons of the visual pathway

1. **First order neuron:**
   rods and cones in the retina
2. **Second order neuron:**
   bipolar cells in the retina
   (cell bodies form the retinal ganglion)
3. **Third order neuron:**
   retinal ganglion cells in the retina
   (cell bodies form the optic ganglion)
4. **Fourth order neuron:**
   located in the lateral geniculate nuclei

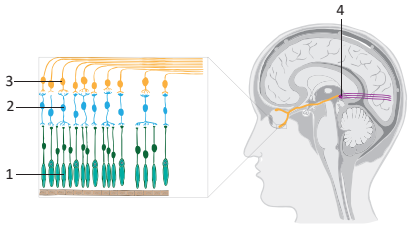

Course of the visual pathway

1 The first, second, and third order neurons are situated in the optic part of **the retina**
2 The visual pathway extends from the retina as the **optic nerve**
3 The right and left optic nerve fibers are partially crossed after passing via the optic canal; the **optic chiasma** is formed by a decussation of axons from the medial parts of the retina (temporal parts of the visual field) and subdivision of axons from the macula
4 The pathway continues as the **optic tract** (tractus opticus)
5 A majority of the visual pathway enters the l**ateral geniculate body** of the metathalamus
– lateral root (*radix lateralis*)
6 The pathway is interpolated at **the fourth order neuron**
7 Passes as the **optic radiation** and terminates in the primary visual area (BA 17)

Visual pathway collaterals

On the way to the lateral geniculate body the optic tract ramifies into:

8 **Medial root** (*radix medialis*) passes via the brachium of the superior colliculus into the layers of the superior colliculus (of the tectum of the midbrain)
– axons terminate in the pretectal nuclei responsible for pupillary reflex controlling
9 **Mesencephalic optic root** (*radix optica mesencephalica*)
– enters the pretectal nuclei (in the pretectal area)
10 **Hypothalamic optic root** (*radix optica hypothalamica*)
– enters the suprachiasmatic and paraventricular nucleus of the hypothalamus

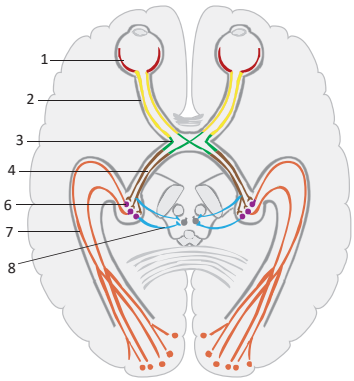

Course of the tract

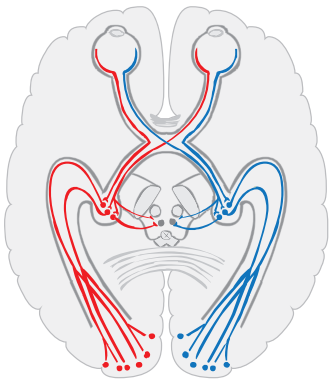
Partial crossing of the left and right visual tract

The blind spot (optic disc) of the retina is clinically referred to as the optic nerve papilla (papilla nervi optici) This part of the retina is insensitive to light. It is the site where retinal nerve fibres leave the eye to form the optic nerve.

The first, second, and third order neurones of the optic pathway are located in the retina. They are interconnected by amacrine and horizontal cells. These cells are interneurones, which process visual information at the level of the retina.

The lens is a converging lens, which inverts all objects in the visual field. This means that the medial part of the retina receives the temporal (lateral) half of the visual field and the lateral half of the retina is receives the nasal (medial) half of the visual field.

Collaterals of visual pathway that pass into the hypothalamus affects synapse on the suprachiasmatic and paraventricular nuclei. They transmit information on the intensity of daylight to the hypothalamus, which in turn affects the release of hormone, autonomic nervous system and production of melatonin

The consensual pupillary response is a result of the decussation of the pupillary reflex tracts. Light directed into one eye elicits a pupil constriction of the contralateral eye.

The optic radiation of Gratiolet (*fibrae geniculocalcarinae*) contains fibres passing from the cerebral cortex to the lateral geniculate nucleus. This feedback loop enables the cortex to filter out impulses coming from the retina.

The optic radiation splits into two parts: the inferior part, which is known as the loop of Meyer-Archambault, contains fibres from the inferior part of the retina (superior half of the visual field). This loop passes through the temporal lobe and loops around the inferior of horn of the lateral ventricle. The superior part is known as the loop of Baum. It contains fibres from the superior part of the retina (inferior half of the visual field) and passes straight through the parietal lobe into the occipital lobe.

Visual pathway details

1. **First order neuron:** photosensitive bipolar cells – rod cells (*neura bacillifera*) and cone cells (*neura conifera*)
   – dendrites are transformed into light-sensitive processes which convert visual stimuli into neural impulses
   – the cells react to light stimuli, are oriented to the choroid and embedded into the pigmented layer of the retina
   – axons head towards the eye center and form synapses with dendrites of bipolar cells
2. **Second order neuron:** bipolar cells are commonly termed the retinal ganglion
   – dendrites are connected with axons of photoreceptors and bipolar cells axons synapse with dendrites of the retinal ganglion cells
3. **Third order neuron:** retinal ganglion cells are commonly termed the optic ganglion
   – axons converge to the optic disc and form the optic nerve (*nervus opticus*)
   3.1 **Optic chiasma** (visual decussation) – is located on the superior surface of the sphenoid bone
      – fibers from the medial half of the retina and medial half of the macula decussate here
   3.2 **Optic tract** (optic bundle) – transmits information from both halves of the retinae
      – the right optic tract conveys information from the right halves of the retinae, i.e. from the left halves of the visual field
      – the left optic tract conveys information from the left halves of the retinae, i.e. from the right halves of the visual field
4. **Fourth order neuron:** a neuron in the lateral geniculate body
   – axons form the optic radiation, a component of the posterior limb of the internal capsule
   – the visual radiation terminates in the BA 17 of the occipital lobe

Pupillary light reflexes

Pathway of miosis and lens accommodation:

– an increase in light intensity activates this pathway (leads to miosis), lens accommodation is evoked by approaching objects and mediated by the parasympathetic part of the autonomic system

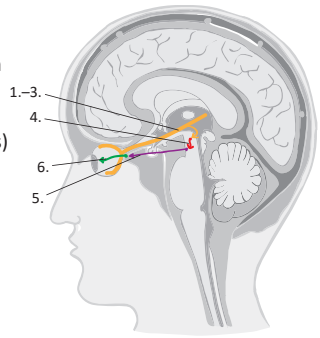

- 1.–3. **(First, second, and third) order neurons:** are located in the retina
  – the optic tract gives a collateral – mesencephalic optic root
- 4. **(Fourth) order neuron:** is situated in the pretectal nuclei (representing an interpolation for miosis)
  – in the interstitial nucleus of Cajal (representing an interpolation for accommodation)
- 5. **(Fifth) order neuron:** is situated in the posterior accessory nucleus of the oculomotor nerve of Edinger-Westphal
  – a parasympathetic nucleus, its axons passes via the oculomotor nerve to the ciliary ganglion
- 6. **(Sixth) order neuron:** in the ciliary ganglion
  – interpolation to the second parasympathetic neuron and via the short ciliary nerves information enter the eyeball
  – axons innervate the sphincter pupillae which leads to pupil narrowing (miosis) and the ciliary muscle which protrudes the lens (optic accommodation)

Pathway of mydriasis

– a decrease in light intensity activates this pathway (invokes mydriasis) and it is conducted via the sympathetic part of the autonomic system

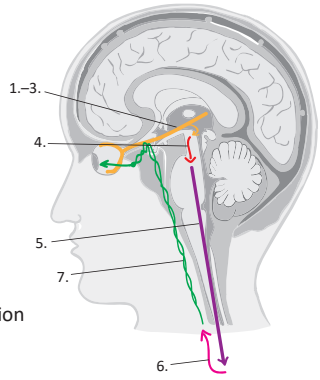

- 1.–3. **(First, second, and third) order neuron:** are situated similarly in the retina
  – the optic tract gives a collateral (mesencephalic optic root)
- 4. **(Fourth) order neuron:** in the pretectal nuclei
- 5. **(Fifth) order neuron:** neurons of the reticular formation in the midbrain and pons
  – via the reticulospinal tract into the cervical part of the spinal cord (intermediolateral nuclei)
- 6. **(Sixth) order neuron:** intermediolateral nucleus of C8 (ciliospinal centre of Budge)
  – a sympathetic nucleus in the lateral horn of the spinal segment C8
  – via the white ramus communicans of the C8 axons enter the stellate ganglion
  – but they only pass through this ganglion and interpolate as far as the superior cervical ganglion
- 7. **(Seventh) order neuron:** in the superior cervical ganglion
  – via the internal carotid nerve they enter the internal carotid plexus and ophthalmic plexus around arteries of the same name
  – Is responsible for inervation of the dilator papillae (mydriasis)

Pathway of convergence

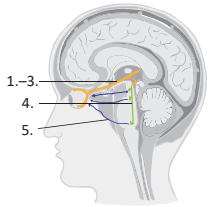

– objects approaching the eyes lead to activation of convergence process
– it is conducted by the parasympathetic part of the autonomic system

- 1.–3. **(First, second, and third) order neuron:** in the optic part of the retina
  – the optic tract gives a collateral – mesencephalic optic root
- 4. **(Fourth) order neuron:** in the interstitial nucleus of Cajal
  – axons pass via the medial longitudinal fasciculus into the nuclei of nerves moving the eyeball (both crossed and uncrossed fibers)
- 5. **(Fifth) order neuron:** in the nucleus of oculomotor, trochlear, and abducent nerve
  – enables convergent eye movements associated with accommodation on objects which are getting closer in the visual field

This copy belongs to ali yaghoubi

The vestibular pathway is a three-neurone pathway, which transmits information about the **position and motion of the head**. It is responsible for the **perception of position and linear and angular acceleration of the head**. The vestibular nuclei are involved in the **coordination of eye movements** through their connection with the medial longitudinal fasciculus. Projections from the vestibular nuclei to the spinal cord **control extensor muscle tone** and facilitate spinal reflexes.

Neurons of the vestibular pathway

1. **First order neuron:** bipolar cells of vestibular ganglion
2. **Second order neuron:** in the vestibular nuclei
3. **Third order neuron:** in the ventral posteromedial nucleus of thalamus (VPM)

Course of the vestibular pathway

- 1 dendrites of bipolar cells originate **in the vestibular organ of the inner ear**
- 2 perikarya of bipolar cells are located in the vestibular ganglion situated at the fundus of **the internal acoustic meatus**
- 3 axons from the ganglion pass as the **vestibular nerve** and then as a component of the vestibulocochlear nerve
- 4 the axons terminate in the **medial, superior, inferior, and lateral vestibular nucleus** where the pathway interpolates to the second order neuron
- 5 axons from the vestibular nuclei **pass crossed and uncrossed** to the thalamus
- 6 the pathway is interpolated to the third order neuron in the **posterior ventral nuclei of the thalamus**

7 projections from the thalamus run to the **vestibular area** (BA 2v)

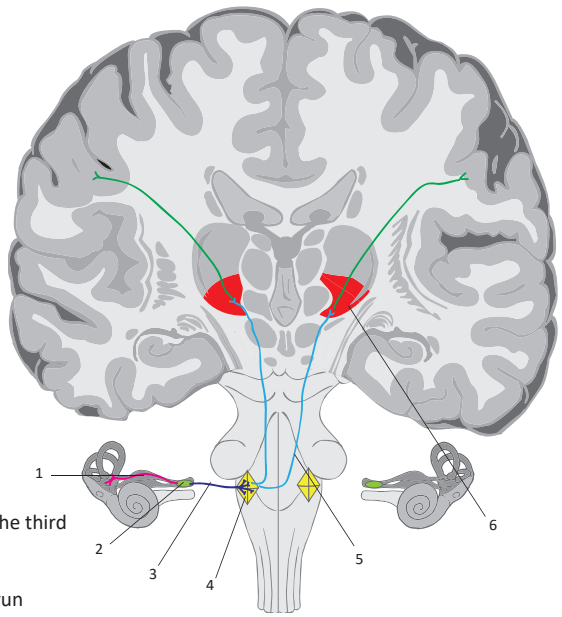

Pathway details

1. **(First) order neuron:** bipolar cells in the vestibular ganglion
   – dendrites are stimulated by signals from sensory cells (hair cells) in the macula of the utricle and saccule (macula utriculi et sacculi) and also in the ampullary crests of the semicircular canals (*cristae ampullares ductuum semicircularium*)
   – axons and collaterals run straight to the cerebellum as the primary vestibulocerebellar tract (*tractus vestibulocerebellaris directus*) and to the vestibular nuclei
2. **(Second) order neuron:** in the vestibular nuclei
   2.1 **Superior and medial vestibular nucleus** – axons passing to the cerebellum as the secondary vestibulocerebellar tract (*tractus vestibulocerebellaris indirectus*), to the spinal cord as the vestibulospinal tract, to the motor nuclei (reticular formation, red nucleus) and basal nuclei (globus pallidus)
   – this is how the vestibular system is involved in motor control systems
   2.2 **Lateral and inferior vestibular nucleus** – axons pass to the nuclei of the oculomotor nerves (via the medial longitudinal fasciculus) and to the thalamus
3. **(Third) order neuron:** in the posterior ventral nuclei of the thalamus, projecting into the cortical vestibular subregions (BA 2, 6, 3) and so-called parieto-insular vestibular cortex (PIVC)

Fibres from the vestibulocochlear nerves terminate in all vestibular nuclei except the lateral vestibular nucleus.

Fibres from the cerebellum terminate in all vestibular nuclei.

The inferior vestibular nucleus plays a role of an integrating vestibular nucleus. It receives collaterals from the spinal tracts and cerebellum.

Uncrossed projections from the vestibular nuclei are inhibitory. The lateral vestibular nucleus is an exception: both ascending and descending fibres of the lateral vestibulospinal tract are excitatory.

Clinically used eponyms of vestibular nuclei:
Nucleus of Bechterew
– superior vestibular nucleus
Nucleus of Roller
– inferior vestibular nucleus
Nucleus of Schwalbe
– medial superior vestibular nucleus
Nucleus of Deiters
– lateral vestibular nucleus

The interstitial nuclei in the auditory pathway process auditory information. They filter out noise and fine-tune ascending impulses. They are involved in identification of sound source. Propagation of neuronal signals is delayed on the side not facing the source of the sound. The auditory cortex is able to analyse individual situation accurately and efficiently thanks to this ingenious pre-processing.

Collaterals from fibres from the anterior cochlear nucleus pass to the superior olivary nucleus on both sides. A slight delay from the opposite side can help reveal the location of source of sound.

Decussating fibres from the anterior cochlear nucleus to the contralateral superior olivary nucleus form the trapezoid body. Groups of neurones within this decussation are known as the nuclei of the trapezoid body.

Clinical notes

Damage of the auditory pathway between the second and fourth order neurones does not cause deafness. It results in difficulties in identifying the location of a source of sound and distinguishing sounds and noises in the background.

The auditory pathway is a four-neuron tract transmitting auditory stimuli from the auditory organ in the inner ear to the nuclei of the brainstem and thalamus. After interpolation in the thalamus, the information is processed in the primary auditory area.

Neurons of the auditory pathway

- **1. (First) order neuron:**
  bipolar cells in the cochlear ganglion
- **2. (Second) order neuron:**
  in the cochlear nuclei of the brainstem
- **3. (Third) order neuron:**
  in the inferior colliculus of the midbrain
- **4. (Fourth) order neuron:**
  in the medial geniculate nuclei of the metathalamus

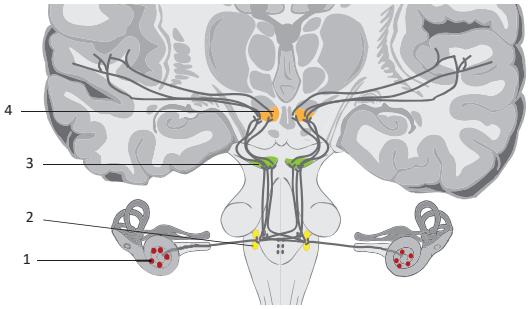

Course of the auditory pathway

1 dendrites of bipolar cells are situated **in the inner ear (organ of Corti)**

2 perikarya of bipolar cells located **in the spiral canal of the cochlea** (cochlear ganglion)

3 axons run as the **cochlear nerve** and then as a component of the **vestibulocochlear nerve**

4 the vestibulocochlear nerve terminates in the **anterior and posterior cochlear nucleus** and the auditory pathway is interpolated to the second neuron

5 a majority of axons **decussate (also run partially uncrossed)** and form the **lateral lemniscus** running to the inferior colliculi of the tectum of the midbrain

6 **interstitial nuclei** are incorporated in the course of the lateral lemniscus (nuclei of lateral lemniscus)

7 the pathway is interpolated to the 3rd neuron in the **inferior colliculus nuclei**

8 then the pathway runs via the **brachium of the inferior colliculus** to the metathalamus

9 the pathway is interpolated to the fourth neuron in the **medial geniculate nuclei**

10 the pathway passes via the **acoustic radiation** and terminates in the **primary auditory area** (BA 41, 42) located in the transverse temporal gyri of Heschl

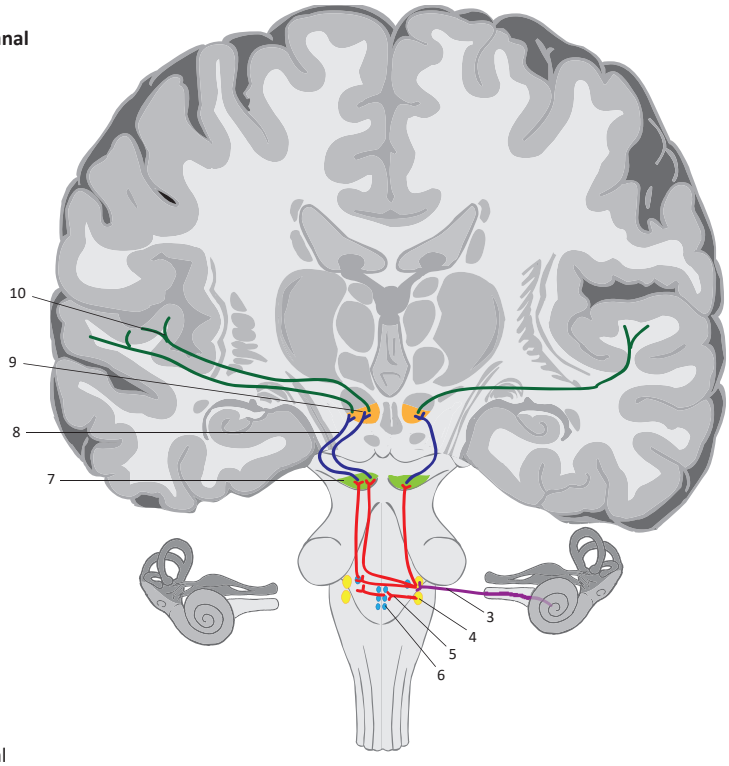

Pathway details

1. **(first) order neuron:** bodies of bipolar cells are situated in the cochlear ganglion
   – dendrites of the bipolar cells begin at the base of hair cells and react to mechanical waves of endolymph and basal lamina (mechanoelectric transduction)
2. **(second) neuron:** is situated in the anterior and posterior cochlear nucleus (topographically under the acoustic tubercle of the rhomboid fossa)
   – axons form the lateral lemniscus, interstitial nuclei (trapezoid body, nucleus of lateral lemniscus, superior olivary nuclei) are incorporated in the lateral lemniscus
   – a majority of the axons cross the midline and enter the contralateral lateral lemniscus, a minority of the axons does not decussate
3. **(Third) order neuron:** situated in the inferior colliculus of the tectum of the midbrain
   – axons run to the medial geniculate body
4. **(Fourth) order neuron:** situated in the medial geniculate nuclei of the metathalamus
   – axons form the acoustic radiation which is a part of the internal capsule posterior limb
   – the auditory pathway terminates in the primary auditory area (BA 41, 42) – transverse temporal gyri of Heschl

This copy belongs to ali yaghoubi

The olfactory pathway is a two-neuron tract, which does not decussate. Olfactory stimuli are detected in the **specialised olfactory mucosa**, which is **located in the roof of the nasal cavity**. The olfcactory pathway is phylogenetically old and bypasses the thalamus. The entorhinal cortex is not responsible for the conscious recognition of smell; this is a function of the neocortex, which receives **projections from the entorhinal cortex**.

Neurons of the olfactory pathway

1. **(First) order neuron:** bipolar olfactory neurons in the olfactory region of the nasal cavity
2. **(Second) order neuron:** mitral cells in the olfactory bulb

Course of the olfactory pathway

- 1 **first-order neuron** is located in the mucosa of the **olfactory region of the nasal cavity**
- 2 from the mucosa the pathway travels via the **olfactory nerves** (*fila olfactoria*) which pass through the cribriform foramina (in the cribriform plate of the ethmoid bone) and then enter the olfactory bulb (*bulbus olfactorius*)
- 3 second-order neuron is located in the **olfactory bulb** which lies on the ventral surface of the frontal lobe
- 4 the pathway continues as the **olfactory tract** to the olfactory trigone
- 5 then some fibres continue to the **medial stria** (to the contralateral olfactory bulb) and other to the **lateral stria** (to the olfactory cortex)

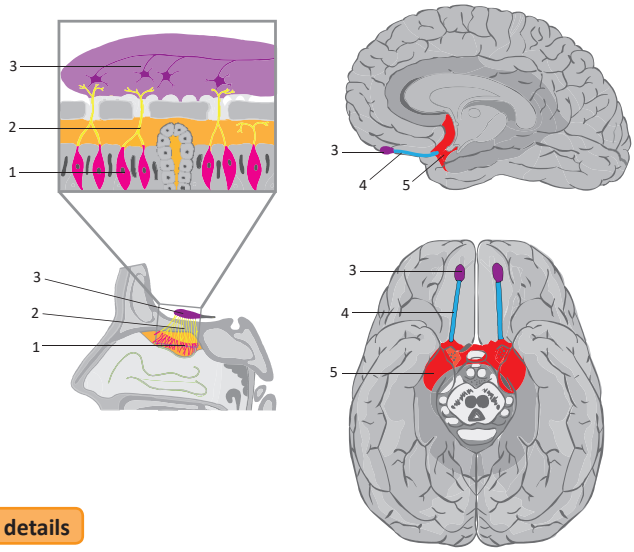

Pathway details

1. **(First) order neuron:** bipolar olfactory neurons in the olfactory region of the nasal cavity mucosa
   1.1 **Olfactory nerves** (*fila olfactoria*) – axons of the bipolar olfactory neurons which pass via the cribriform foramina in the cribriform plate of the ethmoid bone and enter the olfactory bulb (*bulbus olfactorius*)
2. **(Second) order neuron:** mitral cells in the olfactory bulb
   2.1 **Olfactory tract** – is formed dominantly by axons of mitral cells
   – the pathway continues to the olfactory trigone and then divides into two white striae
   2.1.1 **Medial stria** (*stria olfactoria medialis*) – a thinner white band
   – continues via the anterior commissure to the contralateral olfactory bulb and to the septum verum
   2.1.2 **Lateral stria** (*stria olfactoria lateralis*) – a well-marked white band
   – goes to the amygdaloid body and to the primary olfactory cortex (piriform cortex, periamygdaloid cortex, and a part of the parahippocampal gyrus)
   – from the olfactory cortex the fibers run to the hypothalamus, nuclei of the amygdaloid body, hippocampus and to the secondary olfactory cortex (entorhinal cortex - BA 28) and the dorsolateral nucleus of the thalamus
   – from the thalamus to the orbitofrontal cortex (BA 11, 12, 47)
   – transmits the olfactory information to the structures of the limbic system

Projections from the amygdaloid body to the orbitofrontal cortex enable the perception of olfactory stimuli.

The olfactory tract contains collaterals which pass to the anterior olfactory nucleus. These axons pass through the medial stria and then to the olfactory tubercle, which is situated in the anterior perforated substance.

The medial and lateral olfactory gyri are narrow bands of grey matter located next to the medial and lateral stria.

Axons of the second-order neurones of the gustatory pathway accompany the uncrossed somatosensory fibres of the trigeminal nerve from the oral cavity. They travel in the posterior trigeminothalamic tract (*tractus trigeminothalamicus posterior*).

The geniculate ganglion is situated in the geniculum of the facial canal at the border between the labyrinthine and tympanic segment.

Gustatory fibres synapsing in the amygdaloid body, hypothalamus and other parts of the limbic system participate in the emotional factor of food intake.

The gustatory pathway is a three-neuron tract and is defined as **an uncrossed one.** It is responsible for perception of taste. Gustatory information is processed in the taste buds located on the surface of the tongue, pharynx, and palate. Taste receptor cells form synapses with dendrites of the cranial nerves (n. V, VII, IX, X). The pathway terminates in the gustatory cortical area which has an important role in food identification.

Neurons of the gustatory pathway

1. **(First) order neuron:** is located in the ganglia of the cranial nerves (n. VII, IX, X)
2. **(Second) order neuron:** is located in the nuclei of the solitary tract
3. **(Third) order neuron:** is located in the ventral posteromedial nucleus of the thalamus

Course of the gustatory pathway

- 1 dendrites of the first-order neuron form synapses with **taste receptor cells** (within the taste buds)
  2 the pathway runs to the three ganglia of the cranial nerves depending on the location of the taste buds
  - 2.1 **geniculate ganglion** and then via the **facial nerve**
    - 2.1.1 to the geniculate ganglion – sensory information is transmitted from the tongue via the **chorda tympani**
    - 2.1.2 to the geniculate ganglion – sensory information is transmitted from the palate via the **greater petrosal nerve**
  - 2.2 **superior and inferior ganglion** of **glossopharyngeal nerve**
  - 2.3 **superior and inferior ganglion** of **vagus nerve**
- 3 the second order neuron is located in the **nuclei of the solitary tract** (in the rostral part termed the gustatory nucleus)
- 4 axons join the central tegmental tract, **run ipsilaterally and enter the thalamus**
- 5 axons interpolates in the **ventral posteromedial nucleus of the thalamus**
  6 the pathway terminates at the **gustatory area** (BA 43) **in the inferior part of the postcentral gyrus and in the insular lobe**

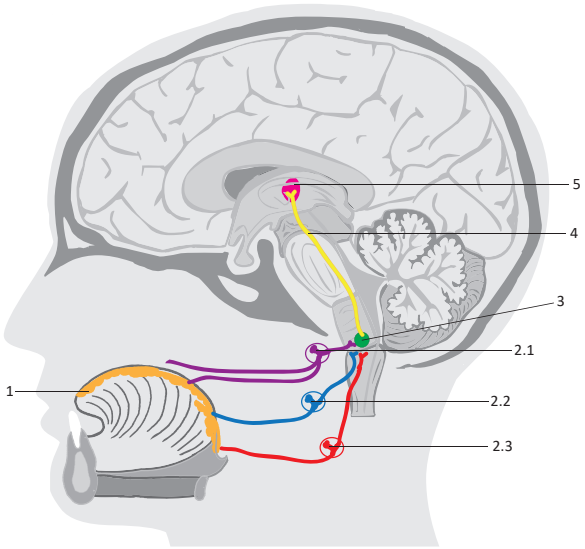

Pathway details

1. **(First) order neuron:** a pseudounipolar neuron with perikaryon located in the ganglia of the cranial nerves (n. VII, IX, X)
   – axons of the first-order neuron enter the brainstem within appropriate nerves and form the solitary tract
   1.1 **Facial nerve** – transmits taste information from the anterior two-thirds of the tongue dorsum
   – from the tongue the sensory fibers run as a part of the lingual nerve and then via the chorda tympani to the facial nerve
   – from palate the sensory fibres run in the palatine nerves, then in the nerve of the pterygoid canal and finally in the greater petrosal nerve to the geniculate ganglion of the n. VII
   1.2 **Glossopharyngeal nerve** – transmits taste information from the posterior one-third of the tongue (including also the vallate papillae) and from the isthmus of fauces
   – the superior and inferior ganglion of glossopharyngeal nerve in the area of the jugular foramen
   1.3 **Vagus nerve** – transmits taste information from the epiglottis and epiglottic valleculae
   – the superior and inferior ganglion of vagus nerve in the area of the jugular foramen
2. **(Second) order neuron:** in the nuclei of the solitary tract
   – branches into the reticular formation and limbic system structures
3. **(Third) order neuron:** in the ventral posteromedial nucleus of the thalamus
   3.1 **To the gustatory area (BA 43)** – the inferior part of the postcentral gyrus in the parietal lobe
   3.2 **To the insular lobe** – taste information has an effect on the control centres of digestive system motility and secretory activity

This copy belongs to ali yaghoubi

The ventricular system of the brain consists of four interconnected **fluid-filled ventricles lined** with ependyma. These are the two lateral ventricles, the third ventricle and the fourth ventricle. The **lateral ventricle**s communicate with the third ventricle through the interventricular foramina (of Monro). The **third ventricle** is in turn connected to the fourth ventricle via the cerebral aqueduct (acqueduct of Sylvius). The **fourth ventricle** communicates with the subarachnoid space via three openings and narrows caudally to form the central canal of the spinal cord. **Circumventricular organs** are areas of the ventricular system devoid of the **blood-brain barrier**. They are richly vascularized with fenestrated capillaries. Certain **substances in the blood can pass directly into brain at these places**.

Composition

- 1 **Right lateral ventricle** (*ventriculus lateralis dexter*)
- 2 **Left lateral ventricle** (*ventriculus lateralis sinister*)
- 3 **Third ventricle** (*ventriculus tertius*)
- 4 **Fourth ventricle** (*ventriculus quartus*)

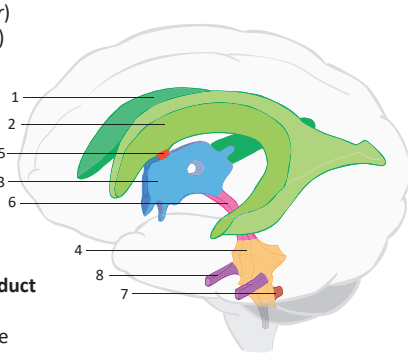

Communications

- 5 **Interventricular foramen of Monro** (*foramen interventriculare*)
  – a paired communication between the third and lateral ventricles
- 6 **Aqueduct of midbrain of Sylvius / cerebral aqueduct** (*aqueductus mesencephali / aqueductus cerebri*)
  – a canal connecting the third and fourth ventricle
  – the narrowest part of the ventricular system
- 7 **Median aperture of fourth ventricle / foramen of Magendie** (*apertura mediana ventriculi quarti*)
  – an unpaired dorsal communication between the fourth ventricle and subarachnoid space (posterior cerebellomedullary cistern)
- 8 **Lateral apertures of fourth ventricle / foramina of Luschka** *(aperturae laterales ventriculi quarti*) – a paired lateral communication between the fourth ventricle and subarachnoid space (pontocerebellar cistern)

Circumventricular organs (CVOs)

Sensory organs:

- 1 **Area postrema** – in the caudal part of the fourth ventricle
  – a chemoreceptor and osmoreceptor (registering the pH changes)
  – is connected to the autonomic centers in the brainstem and participate in activation of the vomiting centre
- 2 **Vascular organ of lamina terminalis** (*organum vasculosum laminae terminalis*)
  – in the rostral part of the third ventricle (triangular recess)
  – an osmoreceptor participating in water intake and sodium consumption
  – contains e.g. receptors for angiotensin
- 3 **Subfornical organ** (*organum subfornicale*)
  – in the rostral part of the third ventricle (triangular recess, rostrally to the fornix)
  – an osmoreceptor participating in blood pressure regulation and in energy homeostasis (together with the hypothalamus)

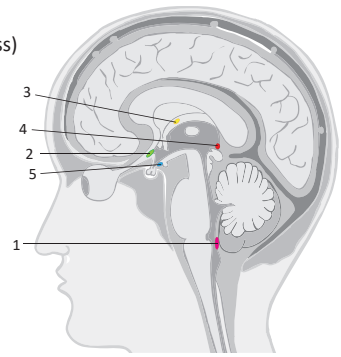

Secretory organs:

- 4 **Subcommissural organ** (*organum subcommissurale*)
  – in the occipital part of the third ventricle (above the opening of the aqueduct of the midbrain)
- 5 **Median eminence** (*eminentia mediana*)
  – in the inferior part of the hypothalamus (near the third ventricle)
  – the major cell type in the mass of the median eminence are specialized ependymal cells known as tanycytes
  – creates a passage

The ventricles develop from the neural canal (cavity of the neural tube) which expands to some areas of the brain. Other segments of the neural canal (canalis neuralis) do not expand and form the aqueduct of the midbrain and central canal (of the spinal cord).

The tela choroidea of the third ventricle is a duplication of the pia mater and forms the roof of the third ventricle. It is attached to the stria medullaris of the right and left thalamus. The tela choroidea featuring the choroid plexus is divided into two parts and those parts enter the lateral ventricles via the interventricular foramina.

The lamina terminalis is an embryonic vestige of the unpaired telencephalon impar (medianum). The area in front of the lamina terminalis is termed septum.

Choroidal enlargement is a projection of the choroid plexus from the central part into the posterior horn of the lateral ventricle. It has an important role in production of cerebrospinal fluid.

The superficial layer of the white matter, termed alveus, merges with the fimbria of the hippocampus (which then joins in the crus of the fornix). It also serves as an insertion for the tela choroidea of the lateral ventricle. The other margin of the tela choroidea is attached to the choroid line located on the roof of the inferior horn of the lateral ventricle, near the tail of the caudate nucleus.

The cerebral lobes during brain development gradually form an U-shape circle around the insular lobe, therefore the insular lobe is located deep within the lateral fossa. That is why the lateral ventricle interferes to all cerebral lobes except of the insular one.

The circumventricular organs are specialized structures in the brain characterized by their extensive vasculature and lack of a normal blood-brain barrier. They participate significantly in neuroendocrine interactions.

The subcommissural organ produces a protein called SCO-spondin. Long molecule of the SCO-spondin makes a part of Reissner's fiber, a thread-like structure passing through the aqueduct of the midbrain to the terminal ventricle. The molecule enables a stable throughput. SCO-spondin synthesis defect can be associated with development of internal hydrocephalus.

Lateral ventricle

– a paired ventricle located in the hemispheres of the telencephalon, its horseshoe shape is a result of the development

Parts:

- 1 **Frontal/anterior horn** (*cornu frontale/anterius*) – the choroid plexus is absent
- 2 **Central part / body** (*pars centralis*) – middle part
- 3 **Atrium** – an enlarged dorsal end of the central part
  bifurcates into the occipital and temporal horn
  – the choroid enlargement (*glomus choroideum*) is located here
- 4 **Occipital/posterior horn** (*cornu posterius/occipitale*) – the choroid plexus is absent
- 5 **Temporal/inferior horn** (*cornu inferius/temporale*)

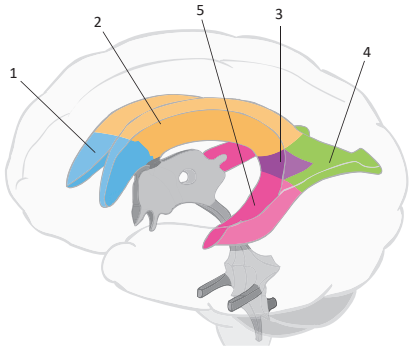

Borders:

1 **Frontal/anterior horn** – in the frontal lobe
- 1.1 **Cranially:** corpus callosum
- 1.2 **Medially:** septum pellucidum
- 1.3 **Laterally:** head of caudate nucleus

2 **Central part** – located above the thalamus
- 2.1 **Cranially:** corpus callosum
- 2.2 **Medially:** tela choroidea of lateral ventricle
- 2.3 **Laterally:** caudate nucleus

3 **Occipital/posterior horn** – in the occipital lobe
- 3.1 **Cranially:** calcarine sulcus protrudes in the ventricle as a calcarine spur
- 3.2 **Medially:** collateral sulcus protrudes in the ventricle as a collateral eminence
- 3.4 **Laterally:** fibers of corpus callosum (tapetum)

4 **Temporal/inferior horn** – in the temporal lobe
- 4.1 **Medially:** tela choroidea of lateral ventricle
- 4.2 **Caudally:** collateral eminence
- 4.3 **Mediocaudally:** hippocampus
- 4.4 **Laterally:** fibers of corpus callosum (tapetum)

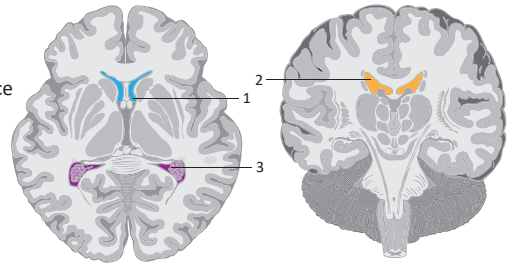

Third ventricle

– an unpaired space located between the left and right thalamus and hypothalamus

Borders:

- 1 **Laterocranially:** right and left thalamus interconnected
  by the interthalamic adhesion in 80% of cases
- 2 **Laterocaudally:** right and left hypothalamus
- 3 **Roof:** tela choroidea of third ventricle
  3.1 **Choroid plexus** – vascular plexus producing cerebrospinal fluid
- 4 **Frontally:** lamina terminalis

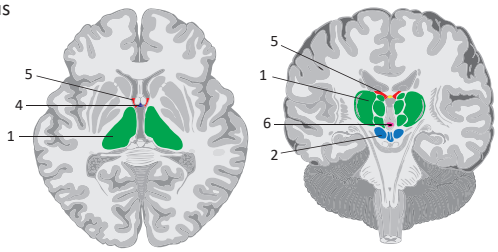

Communications:

- 5 **Interventricular foramen of Monro** (*foramen interventriculare*)
  – laterocranially, communication between the lateral ventricles
- 6 **Opening of aqueduct of midbrain** (*apertura aqueductus mesencephali*)
  – occipitally, communication with the fourth ventricle

Fourth ventricle

– an unpaired pyramidal space between the brainstem (pons and medulla oblongata) and cerebellum

- 1 **Tela choroidea of fourth ventricle** – glial membrane in the caudal part of the fourth ventricle
  - 1.1 **Choroid plexus** – vascular plexus producing cerebrospinal fluid

Borders:

- 2 **Floor:** rhomboid fossa (*fossa rhomboidea*)
- 3 **Roof:**
  - 3.1 **Superior medullary velum** (*velum medullare superius*)
    – a plate of the white matter between the superior cerebellar peduncles
  - 3.2 **Fastigium** – lies in the midline, the dorsal apex of the ventricle
  - 3.3 **Inferior medullary velum** (*velum medullare inferius*)
    – a plate of the white matter between the inferior cerebellar peduncles

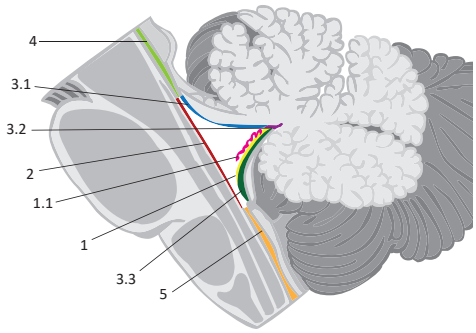

Communications:

- 4 **Aqueduct of midbrain of Sylvius** (*aqueductus mesencephali*)
  – a communication with the third ventricle
- 5 **Central canal** (*canalis centralis*) – caudally, cul-de-sac in the spinal cord
- 6 **Median aperture of fourth ventricle / foramen of Magendie**
  (*apertura mediana ventriculi quarti*)
  – an unpaired dorsal communication between the fourth ventricle
  and subarachnoid space (posterior cerebellomedullary cistern)
- 7 **Lateral apertures of fourth ventricle / foramina of Luschka** (*aperturae laterales ventriculi quarti*)
  – a paired lateral communication between the fourth ventricle and subarachnoid space (pontocerebellar cistern)

This copy belongs to ali yaghoubi

Cerebrospinal fluid (CSF) is a yellowish or colorless transparent fluid which is **produced by plasma transudation in the choroid plexuses** and partially by leaking of interstitial fluid into the ventricles. The fluid creates a **metabolic environment for neurons of the spinal cord and brain**. It is involved in transition of substances which participate in the communication between the parts of the CNS. It provides a **basic mechanical protection** to the nervous tissue. **The nervous tissue lacks lymphatic drainage.** The cerebrospinal circulation is similar to the circulation of lymph. It o**riginates from capillary blood** into the ventricular system. Then it is **drained into the subarachnoid space** and **returns in the dural venous sinuses** to the venous system. **Cisterns** represent extensions of the subarachnoid space containing cerebrospinal fluid, vessels, and nerves. The majority of cerebrospinal fluid is found in the cisterns around the brainstem and cerebellum.

Production and circulation of cerebrospinal fluid

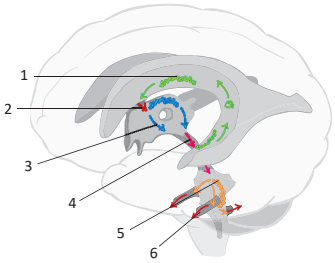

1. **Lateral ventricles** – production of CSF
2. **Interventricular foramen of Monro** – flow of CSF
3. **Third ventricle** – production and flow of CSF
4. **Aqueduct of midbrain** – flow of CSF
5. **Fourth ventricle** – production and flow of CSF
6. **Median aperture of Magendie and lateral apertures of Luschka of the fourth ventricle** – drainage of CSF to the subarachnoid space
7. **Subarachnoid space** – flow of CSF
8. to **the dural venous sinuses** (especially to the superior sagittal sinus)
   - 8.1 **Arachnoid granulations** – projections of the arachnoid providing one-way absorption of CSF to the venous system

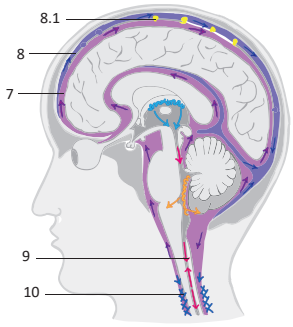

Flow of CSF into the spinal cord

9. **to the central canal** – from the fourth ventricle
10. **to the internal vertebral venous plexuses** – absorption of CSF to the venous system

Cisterns

Infratentorial group:

Caudal basal cisterns:

1 **Premedullary, prepontine** and **interpeduncular cistern** – ventral to the brain stem

Lateral basal cisterns:

2 **Lateral cerebellomedullary and cerebellopontine cistern** – extends into the cerebellopontine angle

3 **Cistern of the internal acoustic meatus** and **cisterna ambiens** – are located around lateral sides of the mesencephalon

Dorsal caudal cisterns:

4 **Posterior cerebellomedullary, superior cerebellar** and **quadrigeminal cisterns / cistern of great cerebral vein**

Supratentorial group:

Rostral basal cisterns:

5 **Hypophysial, chiasmatic cistern, cistern of lamina terminalis** – are rostral to the third ventricle

Rostral lateral cisterns:

6 **Carotid, olfactory cistern, cistern of lateral cerebral fossa, cistern of central sulcus**

Rostral dorsal cisterns:

7 **Pericallosal cistern** – is located around the corpus callosum

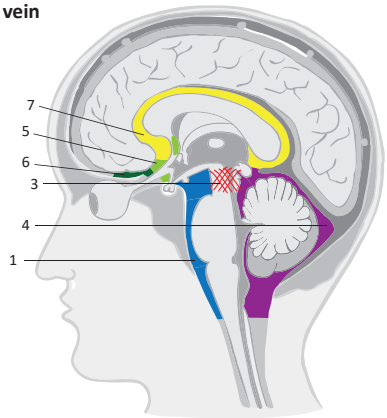

Cistern in the vertebral canal:

8 **Lumbar cistern** – from the conus medullaris to S2 – lumbar puncture is performed here

Daily production of cerebrospinal fluid is approximately 500 ml. The amount of CSF in the ventricular system is 150 ml on average. Only one-fourth of the volume is contained in the cerebral spaces (ventricles and central canal). The majority of the CSF volume fills the subarachnoid space and cisterns (extracerebral location).

Buoyant force exerts upward on the brain immersed in CSF (the brain is buoyed up more than 30x). That is why the immersed brain, which weights 1500 g, exerts equal force on the skull base as weighing 50 g. CSF washes the whole brain and mechanically protects the brain from an injury.

Pachymeninx is a synonym of the dura mater. **Leptomeninx** includes both the pia mater and arachnoid mater.

The Virchow-Robin spaces are perivascular canals surrounding perforating arteries in the parenchyma of the brain (and spinal cord) and perivascular glial limitating membrane. They are interconnected with the subarachnoid space, enable absorption of CSF and can be seen on MRI.

Clinical notes

Lumbar puncture is a procedure performed to collect a sample of CSF from the subarachnoid space of the vertebral canal. The most frequently used spot for the puncture is between the spinous processes of the third and fourth lumbar vertebra – a risk of damage of the spinal cord is not an issue in this position. The needle penetrates into the extension of the subarachnoid space (lumbar cistern) where only the cauda equina passes.

Hydrocephalus is a pathological state caused by an accumulation of CSF. It can result from an increased production of CSF, reduced absorption of CSF, or occlusion in the ventricular system.

Clinical differences in the manifestation of hydrocephalus:
In infants, hydrocephalus that develops prior to suture closure often results in the enlarged, sometimes a massive head. In adults, the ventricles enlarge to handle the increased volume of CSF, thus compressing the brain from within and eventually damaging or destroying the brain tissue (atrophy). The typical symptoms are decreased mental functions (damage to the white matter fibers and metabolic changes of cortical neurons), disorientation, and urinary incontinence.

The meninges comprise **three layers of connective tissue** that cover the spinal cord and brain. **The dura mater** is the most external layer. **The arachnoid mater** is located under the dura mater and the **pia mater** lies on the surface of the brain and spinal cord. In certain areas, **the dura mater forms folds**, which separate different parts of the brain and **contain venous sinuses**. **The arachnoid mater** is a non-vascular non-innervated fibrous membrane. It sends delicate fibres to the pia mater, which resemble a spider's web. **The pia mater** is the innermost layer of the meninges. It extends into the sulci and gyri of the brain and forms the tela choroidea.

Meninges of the brain

- 1 **Cranial dura mater** (*dura mater cranialis*) – it merges with the periosteum of the internal table of the calvaria, especially in the area of sutures
  – the dural venous sinuses are located between the periosteum and dura mater
- 2 **Cranial arachnoid mater** (*arachnoidea mater cranialis*)
  - 2.1 **Arachnoid granulations of Pacchioni** (*granulationes arachnoideae*) – projections of the arachnoid mater protruding into the dural venous sinuses, allow absorption of cerebrospinal fluid into venous blood
- 3 **Cranial pia mater** (*pia mater cranialis*)

Spaces in the skull bordered by the meninges

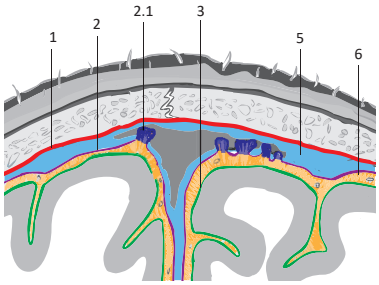

4 **Epidural space** (*spatium epidurale*)
– a virtual space located between the periosteum and dura mater
– under physiological conditions the space does not exist
– can be created when haemorrhage of the middle meningeal artery or rupture of the dural venous sinus occurs

- 5 **Subdural space** (*spatium subdurale*)
  – a virtual space located between the dura mater and arachnoid mater
  – under physiological conditions the space is just a tiny slit between the meninges
  – can be created by haemorrhage of bridging veins
- 6 **Subarachnoid space** (*spatium subarachnoideum*) – contains the cerebral arterial circle of Willis
  – a real space located between the arachnoid mater and pia mater filled with cerebrospinal fluid
  6.1 **Subarachnoid cisterns** (*cisternae subarachnoideae*) – enlarged spaces (cisterns)

Duplications of the dura mater

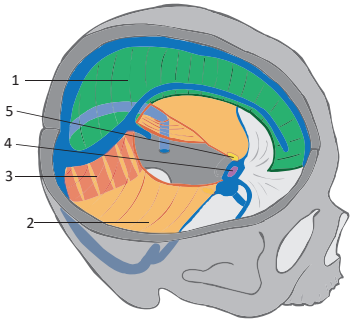

- 1 **Falx cerebri / cerebral falx** *(falx cerebri)* – is positioned in the longitudinal cerebral fissure
  – passes from the crista galli of the ethmoid bone and frontal crest of the frontal bone along the groove for the superior sagittal sinus to the internal occipital protuberance
- 2 **Tentorium cerebelli /*cerebellar tentorium*** *(tentorium cerebelli)*
  – interferes between the cerebellum and occipital lobes
  2.1 **Tentorial notch / incisura of tentorium** *(incisura tentorii)* – the brainstem, oculomotor, trochlear nerve, and posterior cerebral arteries pass via the notch
- 3 **Falx cerebelli / cerebellar falx** *(falx cerebelli)*
  – is a continuation of the falx cerebri and inserts between the hemispheres of the cerebellum
- 4 **Diaphragma sellae / sellar diaphragm** (*diaphragma sellae*) – bridges over the hypophysial fossa
  – the infundibulum of the neurohypophysis passes via the diaphragmatic aperture (foramen of Pacchioni)
- 5 **Trigeminal cave / cavity of Meckel** (*cavum trigeminale*) – a cavity inside the dura mater at the level of the trigeminal impression near the apex of the petrous bone, containing the trigeminal ganglion

Meninges of the spinal cord

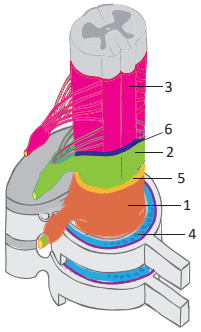

- 1 **Spinal dura mater** (*dura mater spinalis*) – is not attached to the periosteum (endorrhachis)
  1.1 **Dural sac** (*saccus durae matris spinalis*) –an extension of the dura mater within the vertebral canal from the foramen magnum down to the sacral bone, terminates as the dural part of the filum terminale (coccygeal ligament) at the level of the vertebra Co1
- 2 **Spinal arachnoid mater** (*arachnoidea mater spinalis*)
- 3 **Spinal pia mater** (*pia mater spinalis*) – the denticular ligaments extends from the spinal pia mater

Spaces in the vertebral canal bordered by the spinal meninges

- 4 **Epidural space** (*spatium epidurale*) – a real space located between the vertebral periosteum and dura mater
  – contains fibrous septa, loose connective tissue, adipose tissue, and venous plexuses (internal vertebral venous plexuses)
- 5 **Subdural space** (*spatium subdurale*) - a virtual space (tiny slit) located between the dura mater and arachnoid mater
- 6 **Subarachnoid space / leptomeningeal space** (*spatium subarachnoideum / spatium leptomeningeum*) – a real space located between the arachnoid mater and pia mater filled with cerebrospinal fluid, contains the denticular ligament and spinal arteries

This copy belongs to ali yaghoubi

Two pairs of arteries provide the blood supply of the brain: the two internal carotid and the two vertebral arteries. These arteries branch at the base of the brain and anastomose to **form the circle of Willis**. The circle of Willis provides a continuous supply of oxygen to the brain, moderates pulse waves and allows blood that enters from either of the vertebral or carotid arteries to supply any part of the brain.

- 1 **Vertebral artery** (*a. vertebralis*) – enters the skull via the foramen magnum
  – a branch of the subclavian artery, it ascends through the transverse processes of C6–C1
  - 1.1 **Posterior inferior cerebellar artery** „PICA" (*a. cerebelli posterior inferior*)
    – a paired branch supplying the inferior surface of the cerebellum and a part of the medulla oblongata
- 2 **Basilar artery** (*a. basilaris*) – an unpaired artery formed by a terminal junction of two vertebral arteries at the caudal margin of the pons
  – passes in the basilar sulcus on the ventral surface of the pons
  – sends small branches for the medulla oblongata, pons, inner ear, and cerebellum
  – bifurcates into the paired posterior cerebral artery
  - 2.1 **Anterior inferior cerebellar artery** „AICA" (*a. cerebelli anterior inferior*)
    – a paired branch for the cerebellum
  - 2.2 **Superior cerebellar artery** „SCA"(*a. cerebelli superior*)
    – a paired branch for the cerebellum
  - 2.3 **Posterior cerebral artery** „PCA" (*a. cerebri posterior*) – the strongest paired terminal branch, supplying especially the occipital lobe and parahippocampal gyrus
    - 2.3.1 **Posterior communicating artery** „Pcom" *(a. communicans posterior*) – forms an anastomosis between the posterior cerebral artery and internal carotid artery
- 3 **Internal carotid artery** „ICA", (*a. carotis interna*)
  – a branch of the common carotid artery, gives no branches in the neck
  – enters the skull via the carotid canal in the petrous bone, loops in the cavernous sinus, passes through the dura mater and branches in its last part (*pars cerebralis*), the ophthalmic and cerebral arteries
  – bifurcates into terminal branches: anterior and middle cerebral artery
  - 3.1 **Anterior cerebral artery** „ACA" (*a. cerebri anterior*)
    - 3.1.1 **Anterior communicating artery** „Acom" (*a. communicans anterior*)
      – a short connection between the anterior cerebral arteries dividing the ACA into the precommunicating (A1) and postcommunicating (A2) segment
  - 3.2 **Middle cerebral artery** „MCA" (*a. cerebri media*)
    – represents a continuation of the internal carotid artery and is the strongest cerebral artery with the largest area of blood supply
  - 3.3 **Ophthalmic artery** (*a. ophthalmica*) – supplies the orbit, lacrimal gland, external muscles of the eyeball, eyeball, and nasal cavity
  - 3.4 **Anterior choroidal artery** (*a. choroidea anterior*)
    – supplies the choroid plexus of the third and lateral ventricle
  - 3.5 **Inferior hypophysial artery** (*a. hypophysialis inferior*)
    – from the cavernous part of the ICA, supplies the neurohypophysis
  - 3.6 **Superior hypophysial artery** (*a. hypophysialis superior*)
    – from the cerebral part of the ICA
    – supplies the adenohypophysis, anterior hypothalamus, and infundibulum

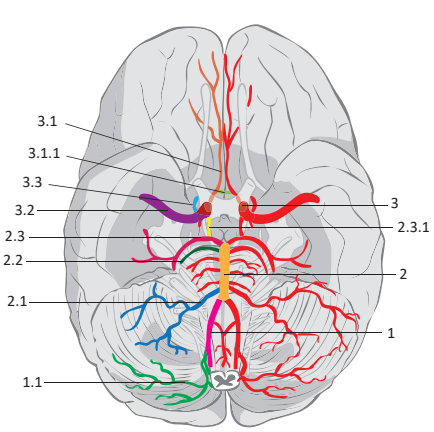

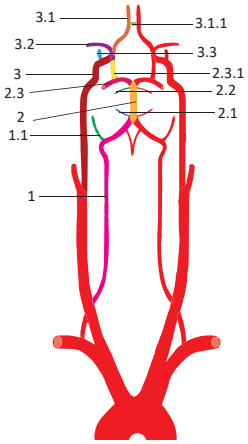

Carotid syphon (*siphon caroticum*) is the term for the sinuous course of the internal carotid artery. In the cavernous part, the convexity is oriented dorsocranially, in the cerebral part the convexity is oriented ventrally.

The posterior communicating artery can be absent in up to one-fifth of cases.

Cerebral arteries are divided into segments which are denoted by terms and abbreviations (A1–A5, M1–M4, and P1–P4). They are important in vascular interventions.

Clinical notes

Occlusion of the anterior cerebral artery causes contralateral paresis predominately in the contralateral lower limb.

Occlusion of the middle cerebral artery causes a malfunction of the facial muscles and contralateral paresis in the contralateral upper and lower limb and contralateral loss of sensation.

Occlusion of the posterior cerebral artery causes cortical homonymous hemianopsia – impairment in the contralateral visual field.

Rupture of aneurysm causes haemorrhage into the subarachnoid space.

The recurrent artery of Heubner is a branch of the anterior communicating artery or of the anterior cerebral artery. The artery supplies the head of the caudate nucleus, anterior limb of the internal capsule, anterior part of the lentiform nucleus, thalamus, hypothalamus, rhinencephalon, and septum verum. Occlusion of the recurrent artery usually causes contralateral paresis of the muscles of the head and upper limb (so-called hemiparesis with faciobrachial predominance).

Arteria haemorrhagica of Charcot is a clinical term for the artery belonging to a group of the anterolateral central arteries and to their lateral striate branches (clinically termed the lenticulostriate arteries). Rupture of the artery causes bleeding and mechanical damage of the fibers of the internal capsule. The arteries originate from the circle of Willis or from the anterior choroid artery, alternatively from the segment M1 of the middle cerebral artery. They supply the striatum, pallidum, and internal capsule. Damage of the artery damage typically causes contralateral paresis.

Course of the internal carotid artery

The course of the ICA is divided into four segments:

- 1 **Cervical part** (*pars cervicalis*) – no branches
  - – the carotid sinus is the extended origin of the ICA containing baroreceptors in its wall
- 2 **Petrous part** (*pars petrosa*) – passes via the carotid canal of the petrous bone
  - – the caroticotympanic arteries are small branches for the mucosa of the tympanic cavity
- 3 **Cavernous part** (*pars cavernosa*) – passes within the cavernous sinus
  - – small branches for the hypophysis, trigeminal ganglion, and dura mater
- 4 **Cerebral part** (*pars cerebralis*) – small branches for the hypophysis, an important branch for the eye and orbit (ophthalmic artery), and laterally to the optic chiasm it bifurcates into the terminal branches (anterior and middle cerebral artery)

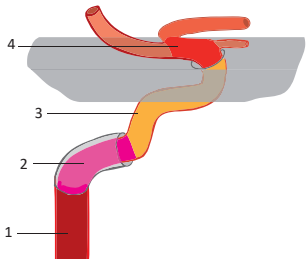

Cerebral arterial circle of Willis (*circulus arteriosus cerebri*)

– an arterial circle at the base of the brain
– is formed by the terminal branches of the internal carotid and vertebral arteries and by their connections
– it operates as a collateral circulation in case of occlusion of one source artery
– participates together with the S-shaped course of the internal carotid in pressure regulation of the blood flow in the brain

- 1 **Anterior cerebral arteries**
  - 1.1 **Anterior communicating artery**
    - – an unpaired connection between the paired anterior cerebral artery
- 2 **Middle cerebral arteries**
- 3 **Posterior cerebral arteries**
- 4 **Posterior communicating arteries** – a paired connection between the middle and posterior cerebral artery

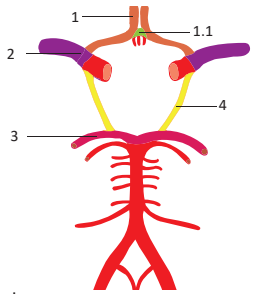

Central arteries

– small arteries extending either directly from the cerebral arterial circle or from the initial segment of the cerebral arteries
– embedded to the brain base

- 1 **Anteromedial central arteries** (*aa. centrales anteromediales*)
  - – supply the anterior part of the striatum, preoptic area, and anterior part of the hypothalamus
- 2 **Anterolateral central arteries** (*aa. centrales anterolaterales*)
  - – supply the putamen, globus pallidus, head and body of the caudate nucleus, anterior part of the internal capsule
  - – clinically termed as "perforators" or "perforating arteries"
- 3 **Posteromedial central arteries** (*aa. centrales posteromediales*)
  - – supply the posterior part of the thalamus and hypothalamus, subthalamus, globus pallidum, tegmentum of the midbrain
- 4 **Posterolateral central arteries** (*aa. centrales posterolaterales*)
  - – supply the posterior part of the thalamus, geniculate bodies, pineal gland, internal capsule, tectum of the midbrain

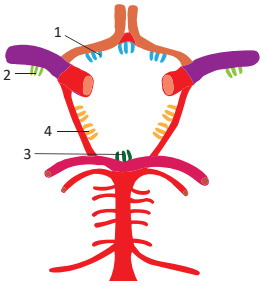

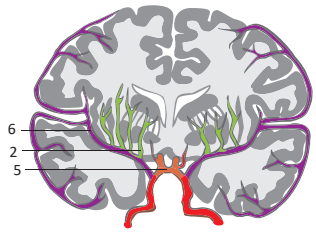

Frontal section of the brain

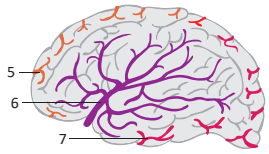

Lateral surface of the telencephalon

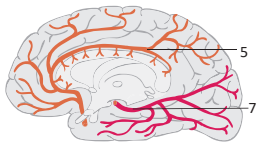

Medial surface of the telencephalon

Cortical arteries (*arteriae corticales*)

- 5 **Anterior cerebral artery** (*a. cerebri anterior*)
  - – runs ventrally, winds the corpus callosum from the external side, terminates at the splenium of the corpus callosum
  - – supplies the inferior surface of the frontal lobe, superior frontal gyrus, superior 1/4 of the precentral gyrus and postcentral gyrus, cingulate gyrus, and precuneus
- 6 **Middle cerebral artery** (*a. cerebri media*)
  - – the strongest branch of the internal carotid artery
  - – passes laterally and horizontally to the lateral cerebral fossa
  - – gives numerous branches supplying the insular lobe, orbital gyri, extreme capsule, claustrum, external capsule
  - – on the hemispheric convexity it supplies the middle and inferior frontal gyrus, majority of the precentral and postcentral gyrus, parietal lobe, anterior part of the occipital lobe, middle and superior temporal lobe, pole of the temporal lobe, and uncus of the parahippocampal gyrus
- 7 **Posterior cerebral artery** (*a. cerebri posterior*)
  - – it winds the cerebral crus and gets to the medial surface of the temporal and occipital lobe
  - – supplies the medial and interior surface of the temporal and occipital lobe including the parahippocampal gyrus and area of the calcarine sulcus

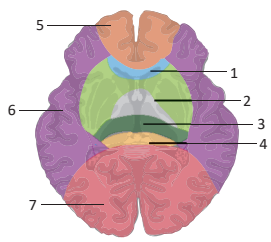

Cross-section of the brain

This copy belongs to ali yaghoubi

The veins of the brain are not equipped with valves and pass in the subarachnoid space, with some of them passing under ependyma. They are classified into two groups, **the supratentorial** (superficial and deep) and **infratentorial group**. **The superficial cerebral veins collect blood from the cerebral cortex and drain into the venous sinuses. The deep cerebral veins drain blood from the diencephalon and deep parts of the hemispheres into the great cerebral vein.** The infratentorial veins drain blood from the cerebellum and brainstem into the venous sinuses. Eventually, all the blood is **drained into the superior bulb of the internal jugular vein**. Blood from the venous sinuses can also **flow out by emissary veins into the extracranial veins of the head**.

Deep veins of the brain (*venae profundae cerebri*)

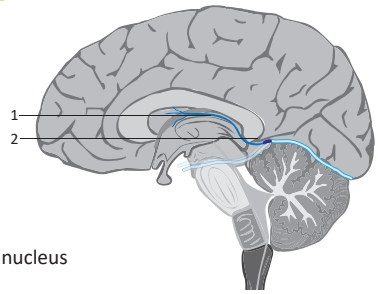

- 1 **Internal cerebral vein** (*v. interna cerebri*)
  - a paired vein located above the roof of the third ventricle, in the telondiencephalic fissure
  - collects blood from the basal ganglia, internal capsule, septum, choroid plexus and from parts of the white matter of the hemispheres
  - is formed by the confluence of three veins:
  - 1.1 **Anterior vein of septum pellucidum** (*v. anterior septi pellucidi*) – drains blood from the septum pellucidum and head of the caudate nucleus
  - 1.2 **Superior choroid vein** (*v. choroidea superior*) – drains blood from the choroid plexus of the lateral ventricle
  - 1.3 **Superior thalamostriate vein** (*v. thalamostriata superior*) – drains blood from the thalamus, striatum, and internal capsule (lies under the stria terminalis of the thalamus)
- 2 **Great cerebral vein of Galenos** (*v. magna cerebri*) – a large, short, unpaired vein
  - is formed by a union of the right and left internal cerebral vein under the splenium of the corpus callosum
  - the basilar vein empties into the great cerebral vein
  - enters the quadrigeminal cistern (cistern of great cerebral vein) and drains into the straight sinus

Superficial veins of the brain (*venae superficiales cerebri*)

- 1 **Superior cerebral veins** (vv. *cerebri superiores*) – collect blood from the superior part of the hemispheric convexity and empty into the superior sagittal sinus
- 2 **Superficial middle cerebral vein** (v. *cerebri media superficialis*)
  - a visible vein begins close to the supramarginal gyrus, runs along the lateral cerebral sulcus and drains into the sphenoparietal or cavernous sinus
  - 2.1 **Superior anastomotic vein of Trolard** (v. *anastomotica superior*)
    - a connection between the superficial middle cerebral vein and superior cerebral veins (superior sagittal sinus)
  - 2.2 **Inferior anastomotic vein of Labbé** (v. *anastomotica inferior*) – a connection between the superficial middle cerebral vein and inferior cerebral veins (transverse sinus)
- 3 **Deep middle cerebral vein** (v. *cerebri media profunda*)
  - accompanies the middle cerebral artery at the base of the lateral cerebral fossa
  - drains the insular lobe and empties into the basal vein

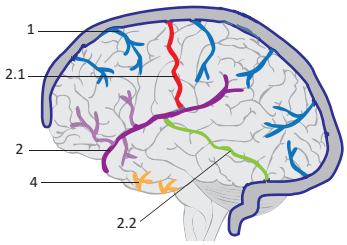

- 4 **Inferior cerebral veins** (vv. *cerebri inferiores*)
  - drain the inferior part of the hemispheric convexity and inferior surface of the hemisphere
  - empty into the transverse, superior petrosal, and inferior petrosal sinus
- 5 **Basal vein of Rosenthal** (v. *basalis*)
  - originates by the confluence of the deep middle cerebral vein, anterior cerebral vein, and small inferior thalamostriate veins at the level of the anterior perforated substance
  - collects blood from the inferior surface of the frontal lobe and adjacent parts of diencephalon
  - encloses the cerebral crura, passes via the ambiens cistern and drains into the great cerebral vein

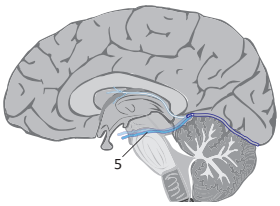

Original venous plexuses are preserved around the spinal cord as the vertebral venous plexuses. In the cranial cavity the plexuses have not disappeared but have transformed into the sinuses of the dura mater.

The infratentorial veins are the cerebellar veins accompanying homonymous arteries. They drain into the great cerebral vein in the midline and laterally into the nearest venous sinuses (superior petrosal, transverse, sigmoid sinus).

The textbook pattern of the confluence of the sinuses arrangement occurs in only 10 % of cases.

The Willis chords are transverse columns segregating the lumen of the sinuses, especially in the superior sagittal sinus.

The central nervous system does not contain lymphatic vessels. The lymphatic system is substituted by the flow of interstitial fluid along the throbbing extracranial cerebral arteries and also via the cribriform plate of the ethmoid bone and by the circulation of cerebrospinal fluid.

The bridging veins are the terminal segments of the superficial cerebral veins.

The emissary veins connect the sinuses of the dura mater, diploic veins, and extracranial veins.

Clinical notes

A spread of infection from the face and orbit can happen intracranially by venous anastomoses. Purulent processes of the upper lip can spread by the deep facial vein or pterygoid plexus, inflammatory processes from the orbit by the superior ophthalmic vein into the cavernous sinus.

Dural venous sinuses thrombosis is one form of stroke. The thrombosis is often complicated by a haemorrhage resulting from blood stasis and oedema. The typical sudden symptoms are headache, weakness, visual impairment, motor and perceptual disorder.

Selective catheterization of the inferior petrosal sinus: A catheter is introduced into the internal jugular vein. The inferior petrosal sinus represents the nearest catheterization point for blood sampling from the pituitary gland. The sampling is used for the diagnosis of ACTH-secreting and growth hormone-producing hypophysial adenomas (endocrinology, oncology).

The **dural venous sinuses** are enclosed **between the two original sheets of the ectomeninx**. **The walls of the dural venous sinuses consist of a layer of endothelium and a sheet of dura mater.** The sinuses are not typical veins; **they lack valves and are not able to collapse when they are damaged.** The sinuses have numerous tributaries from the brain, meninges, and cranial bones. They communicate with the extracranial veins through the emissary veins.

- 1 **Confluence of sinuses** (*confluens sinuum*)
  - the confluence is located near the internal occipital protuberance
  - is formed by connection of the superior sagittal, straight, and occipital sinus
  - 1.1 **Superior sagittal sinus** (*sinus sagittalis superior*)
    - passes in the midline within the superior margin of the falx cerebri
    - originates in front of the crista galli and terminates in front of the internal occipital protuberance, where it opens into the confluence of the sinuses
    - arachnoid granulations of Pacchioni are projections which bulge into the sinuses and by which cerebrospinal fluid is absorbed into the venous system
  - 1.2 **Straight sinus** (*sinus rectus*)
    - is located at the junction of the falx cerebri and tentorium cerebelli
    - originates as a confluence of the inferior sagittal sinus and great cerebral vein
    - 1.2.1 **Inferior sagittal sinus** (*sinus sagittalis inferior*)
      - passes within the inferior margin of the falx cerebri
      - opens into the straight sinus in the site of the falx cerebri insertion into the tentorium cerebelli
  - 1.3 **Occipital sinus** (*sinus occipitalis*)
    - originates near the foramen magnum
    - passes upwards in front of the internal occipital crest and opens into the confluence of the sinuses or the terminal segment of the transverse sinus
  - 1.4 **Marginal sinus** (*sinus marginalis*)
    - a paired sinus passing around the foramen magnum
    - caudally it is connected with the internal vertebral venous plexuses, dorsally with the occipital sinus, and ventraly with the basilar plexus
- 2 **Transverse sinus** (*sinus transverus*)
  - a paired sinus located in the groove for the transverse sinus
  - laterally it continues as the sigmoid sinus
  - 2.1 **Sigmoid sinus** (*sinus sigmoideus*)
    - a paired sinus, a continuation of the transverse sinus
    - the superior bulb of the internal jugular vein originates as a confluence of the sigmoid and inferior petrosal sinus at the level of the jugular foramen
- 3 **Basilar plexus** (*plexus basilaris*)
  - a venous sinus located on the clivus of the occipital bone
  - interconnects the cavernous and both inferior petrosal sinuses
  - communicates with the system of the internal vertebral venous sinuses
- 4 **Cavernous sinus** (*sinus cavernosus*)
  - passes from the superior orbital fissure to the apex of the petrous bone
  - the internal carotid artery passes within the cavernous sinus together with the oculomotor, trochlear, abducens, ophthalmic, and maxillary nerve
  - the superior ophthalmic vein empties into the sinus
  - the right and left sinus are interconnected by the anterior and posterior intercavernous sinus (*sinus intercavernosus anterior et posterior*)
  - 4.1 **Sphenoparietal sinus** (*sinus sphenoparietalis*)
    - medially drains into the cavernous sinus
    - courses along the posterior margin of the lesser wing of the sphenoid bone
  - 4.2 **Superior petrosal sinus** (*sinus petrosus superior*)
    - interconnects the cavernous and sigmoid sinus
    - coursing along the superior margin of the petrous bone
  - 4.3 **Inferior petrosal sinus** (*sinus petrosus inferior*)
    - a connection of the cavernous sinus to the jugular foramen
    - gives an origin to the internal jugular vein by a confluence with the sigmoid sinus

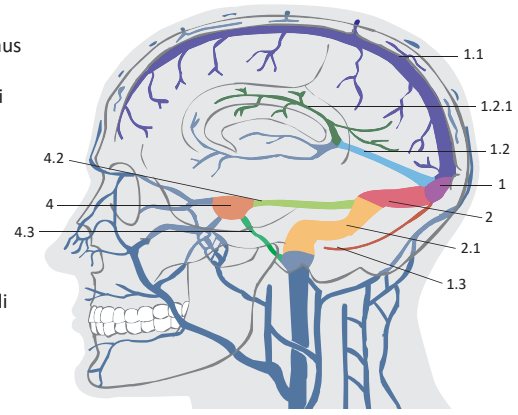

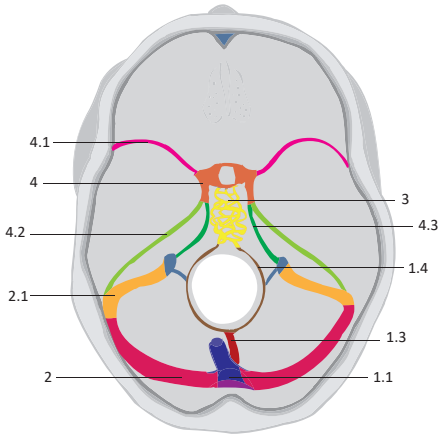

Venous sinuses at the cranial base, superior view

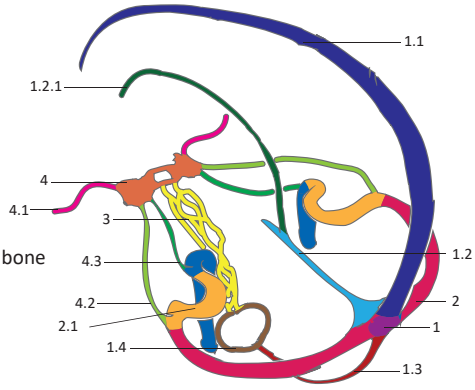

Scheme of the venous sinuses, left view from behind

This copy belongs to ali yaghoubi

The spinal cord receives blood from **three arteries**, which run longitudinally along its entire length. These are the anterior and the two posterior longitudinal spinal arteries. The **longitudinal spinal arteries** are fed by radicular arteries, which travel with the spinal nerve roots to reach the spinal cord. The **spinal veins form random interconnected longitudinal trunks** and drain into the epidural plexuses (internal vertebral venous plexuses). Venous blood is then drained into the **external vertebral venous plexuses** and then into the veins along the vertebral column.

Sources of the spinal cord blood supply

1 **Cervical part of spinal cord** – vertebral artery (*arteria vertebralis*), ascending and deep cervical artery (*a. cervicalis ascendens et profunda*)
2 **Thoracic part of spinal cord** – deep cervical artery (*a. cervicalis profunda*), supreme intercostal artery (*a. intercostalis suprema*), posterior intercostal arteries (*aa. intercostales posteriores*), and subcostal artery *(a. subcostalis)*
3 **Lumbar part of spinal cord** – lumbar arteries (*aa. lumbales*), iliolumbar artery (*a. iliolumbalis*)
4 **Sacral part of spinal cord** – lateral sacral arteries (*aa. sacrales laterales*)

Arteries of the spinal cord

- 1 **Anterior and posterior radicular artery** (*a. radicularis anterior and posterior*)
  - pass along the anterior and posterior root of the spinal nerve
  - drain into the longitudinal trunks – spinal arteries
  - participate in the blood supply of the meninges, vertebrae and intervertebral discs
  - 1.1 **Arteria radicularis magna of Adamkiewicz**
    - a clinical term of the largest spinal branch
    - it usually enters the intervertebral foramen at the level of T9–T11, in 65 % of cases on the left side
    - supplies the lumbosacral enlargement and inferior two-thirds of the spinal cord
- 2 **Anterior spinal artery** (*a. spinalis anterior*) – a paired branch of the vertebral artery before the origin of the basilar artery
  - both initially fuse into an unpaired trunk
  - descends superficially in the anterior median fissure
  - gives 5-8 branches supplying the anterior 2/3 of the spinal cord
  - 2.1 **Sulcocommisural arteries** (*aa. sulcocommisurales*)
    - branches of the anterior spinal artery into the anterior median fissure supplying the central part of the spinal cord
- 3 **Posterior spinal artery** (*a. spinalis posterior*)
  - each artery originates individually as a branch of the posterior inferior cerebellar artery
  - descends in the posterolateral sulcus
  - usually bifurcates during its course
  - gives branches supplying the posterior 1/3 of the spinal cord

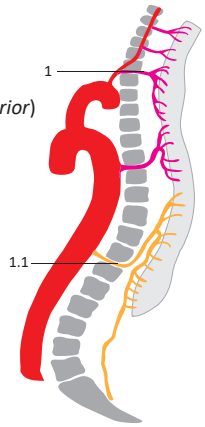

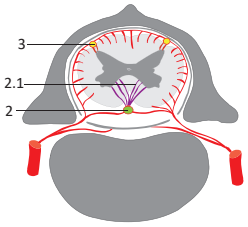

Cross-section of the spinal cord and vertebrae

Veins of the spinal cord

- 1 **Internal vertebral venous plexuses** (*plexus venosi vertebrales interni*)
  - the plexuses are located in the epidural space
  - blood is drained to the external vertebral venous plexuses along the roots of the spinal nerves and through the vertebral bodies
- 2 **External vertebral venous plexuses** (*plexus venosi vertebrales externi*)
  - are located around the vertebral bodies and arches
  - are connected with the veins around the vertbral column
- 3 **Basivertebral veins** (*vv. basivertebrales*)
  - pass through the vertebral bodies, which are richly vascularized
  - connect the internal and external vertebral plexuses

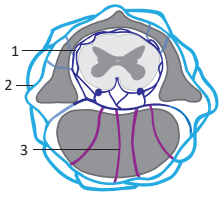

Cross-section of the spinal cord and vertebrae

The vasocorona is the spinal arterial ring - peripheral arteries ramify from it and participate in the blood supply of the spinal cord white matter. The arterial ring enables a collateral circulation.

There are arterio-arterial anastomoses between the branches of the cerebral (and spinal) arteries. They are clinically termed the leptomeningeal or pial anastomoses. They serve as emergency backdoors and enable to create a sufficient collateral circulation in acute ischemic condition (e.g. stroke).

Clinical notes

The arteria radicularis magna of Adamkiewicz can be damaged during aortic aneurysm surgeries at the level of the transition from the thoracic to the lumbar part of the vertebral column (complication of the surgery). Insertion of an artificial material can cause a discontinuance of the blood flow to the spinal cord, which results in paraplegia (paralysis of both lower limbs).

The vertebral venous plexuses (clinically termed as the Batson venous plexus) are not equipped with valves and blood can flow in both directions depending on the pressure gradient. They serve as cavo-caval anastomoses and also provide a possible route for spread of infection and cancer metastases to the vertebral bodies.

Parkinson syndrome (hypokinesia, rigidity and tremor) is caused by a decreased concentration of dopamine in the striatum. An additional feature is an increased concentration of acetylcholine in the circuits of the basal ganglia.

Alzheimer disease is characterized by decreased concentration of acetylcholine in the cerebral cortex which is caused by neuronal degeneration of the basal nucleus and by atrophy of the posterior part of the cingulate gyrus and temporoparietal cortex. There are also noticeable changes which can be visualized by imaging techniques (MRI, PET, SPECT).

Neuronal tracts use **various neurotransmitters** to transmit information in the central nervous system. Neurotransmitters are able to **stimulate, inhibit and modify** the various functions of the central nervous system. Some are **produced in anatomically defined nuclei**, which may be referred to by their anatomical names or by abbreviations pertaining to the neurotransmitters they produce (A, B, Ch).

Neurotransmitters

There is a large amount of neurotransmitters produced in the CNS:
1 **Amino acids** – glutamate, aspartate, GABA (γ-amino butyric acid), glycine, serine
2 **Amines** – dopamine, norepinephrine, epinephrine, histamine, serotonin
3 **Peptides** – somatostatine, substance P, orexigenic/anorexigenic peptides, cholecystokinin, endorphins/dynorphins
4 **Others** – acetylcholine, ATP (adenosinetriphosphate), adenosine, anadamide (endogenous cannabinoid neurotransmitter)

Monoaminergic system

– is composed of neuron groups located predominantly in the nuclei of the reticular formation
– axons of the neurons form collaterals to numerous structures of the brain
– is divided into the catecholaminergic and serotoninergic system

1 **Catecholaminergic system**
1.1 **Noradrenergic system**
– produces norepinephrin
– nuclei are termed A1–A7
– is located only in the reticular formation of the medulla oblongata and pons
– participates in autoregulation of the brain arteries
– participates in modulation of neuronal circuits activity at all levels of the CNS
– is a part of the ascending reticular activating system (ARAS)
● A7 **Locus caeruleus**
– descending fibers pass to the anterior and posterior horns of the spinal cord, nuclei of the brainstem, and cerebellum
– ascending fibers pass to the hypothalamus, thalamus, neocortex, hippocampus, and amygdaloid body

1.2 **Dopaminergic system** – produces dopamine
– nuclei are termed A8–A10
– projections from dopaminergic neurons modulate dynamics of reward and punishment system reactions and participate in perception of reality
– influences sleep and consciousness, attention, memory, and ability to learn
– the tubero-infundibular projection (from the arcuate nucleus) inhibits production of prolactine (it is connected with milk production and also has an impact on sexual functions and libido).
A8 **Area retrorubralis**
– supplies dopamine to the hippocampal formation
● A9 **Substantia nigra – compact part**
– supplies dopamine to the striatum (nigrostriatal dopamine system) and maintains the proper function of the basal ganglia
● A10 **Ventral tegmental area of Tsai** (*area ventralis tegmentalis*)
– axons in three directions: mesolimbic, mesocortical, and tuberoinfundibular system
– supplies dopamine to the prefrontal and primary motor cortex, amygdaloid body and to other parts of the limbic system, hypothalamus and area postrema, striatum and nucleus accumbens

2 **Serotoninergic system**
– produces serotonin (system of mood and anxiety)
– nuclei are termed B1–9
– a majority of neurons are positioned in the raphe nuclei of the reticular formation
– supplies dopamine to the spinal cord, brainstem, cerebellum, thalamus, hypothalamus, cortical areas, and limbic system
– the activity of the neocortex and limbic system causes mood changes and behavioral disorders
– in the posterior horn of the spinal cord it influences transmission of pain impulses and modifies sensory inputs

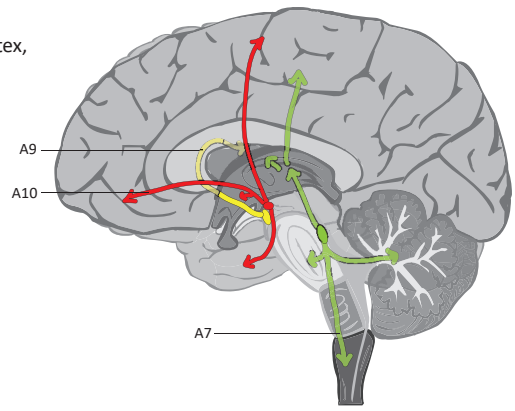

This copy belongs to ali yaghoubi

Other systems

3 **Cholinergic system** – produces acetylcholine
– nuclei are termed Ch1– Ch6
– nuclei are positioned in the brainstem and telencephalon
- Ch1 **Septum verum / medial septal nucleus**
  – supplies acetylcholine to the hippocampus and amygdaloid body
- Ch2 and Ch3 **Cholinergic system of the limbic system**
- Ch4 **Basal nucleus of Meynert** (*nucleus basalis*)
  – is positioned in the innominate substance of Reichert (*substantia innominata*)
  – is represented by disseminated groups of cells supplying acetylcholine to the cortex, amygdaloid body, and hippocampus

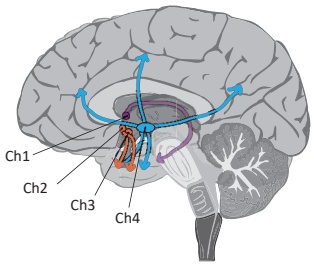

– acetylcholine has an excitatory influence on the subcortical and cortical structures of the brain
– it affects behavior and cognitive functions (consciousness, memory, and ability to learn)
– the nucleus Ch5 and Ch6 are parts of the ascending reticular activating system (ARAS)
– neurons of Ch5 participate in the extrapyramidal motor system
– neurons of Ch6 are closelly connected with the limbic system circuits

4 **Histaminergic system** – produces histamine
– a majority of nuclei are positioned in the posterior hypothalamus
– histamine affects transmission of pain, motor system, thermoregulation, biorhythms (arousal reaction), intake of food and water, and release of neuropeptides in the CNS
- 4.1 **Tuberomamillary nucleus** (*nucleus tuberomammillaris*)
  – supplies histamine to the brain and spinal cord
  – is connected with the sleep-wake cycle
  – participates in awakening by production and supply of histamine

5 **Glutamatergic system** – produces glutamate (Glu)
– glutamate is the main excitatory neurotransmitter in the CNS
– affects the majority of projection, commissural, and associative pathways
- 5.1 **Subthalamic nucleus** (*nucleus subthalamicus*) – glutamatergic nucleus of basal ganglia
  5.2 **Glutamatergic neurons of the cortex and cerebellum**

6 **GABAergic system** – produces gamma-aminobutyric acid (GABA)
– GABA is the main inhibitory neurotransmitter in the CNS
– affects the majority of the cortical and subcortical structures

Only a third of tracts and pathways are myelinated in newborns. Progressive myelination dwindles by the end of the 18th month but continues until the 6th year. The cerebellar and association tracts and projections from the prefrontal cortex are the last to myelinate.

Primitive reflexes are actions originating from the CNS exhibited by healthy infants. In neurologically intact adults, they are suppressed as the frontal lobes develop when the child transitions normally through child development.

Some of primitive reflexes hold a survival value (rooting reflex helps a breastfed infant find mother's nipple; suckling reflex in feeding; grasping reflex helps the infant hold to the mother during transport - see the way chimpanzees young ones hold to the fur at the sides of their mothers trunk). They usually disappear between 4–6 months.

The reappearance of the primitive reflexes may be attributed to certain neurological conditions, e.g. dementia, traumatic lesions, strokes. Examining primitive reflexes allows us to assess the frontal lobe function – therefore, if they are not suppressed properly, we speak of frontal release signs, indicative of frontal areas dysfunction.

18 Psychomotor development

The first year of life is a pivotal period in the postnatal development of the nervous system. **During the first year of life motor functions, senses, speech and emotions develop at a rapid rate**. Evaluation of the progress of psychomotor functions is a useful way to assess the development of the central nervous system.

Milestones of the nervous system development

1. **Presence and gradual disappearance of the congenital reflexes**
   (sequence of the reflexes and time of physiological vanishing)
   1.1 Searching reflex – until the 3rd month
   1.2 Sucking reflex – until the 4th month
   1.3 Grip reflex of upper extremity – until the 4th month
   1.4 Grip reflex of lower extremity – until the 12th month
   1.5 Moro reflex – until the 4th month
   1.6 Walking automatism – until the 3rd month
2. **Development of gross motor functions**
   – development of postural function, coordination, gait, and walking
3. **Development of fine motor functions**
   – coordination of upper extremity movements and development of grasping
4. **Development of speech functions, visual tract, and cortex, development of senses, social interaction, and emotions**

Clinical notes

A clumsy grasp from the ulnar side of the palm can be visible in individuals with developmental brain disorders, e.g. as a consequence of brain hypoxia/asphyxia during delivery (child onset brain palsy).

Development and dominance of motor groups in the first year

1. **First flexion period** (until the 6th week)
   – a period of flexors dominance, mainly of the upper extremities which are phylogenetically better developed in the prenatal period (because of the fetal circulation and higher oxygenation and nutrition support for the developing brain and upper extremities)
2. **First extension period** (until the 4th month)
   – an important period before progressive development of voluntary motor activity
3. **Second flexion period** (until the 9th month)
   – an important period before progressive development of gait and walking
4. **Second extension period**
   – a period of progressive development of gait and walking



First flexion period



First extension period

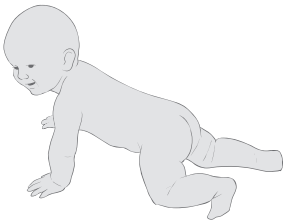

Second flexion period



Second extension period

1st month

Muscle tone: is higher, typically a dominance of flexors (because of the dominating activity of the extrapyramidal system),
– typical is a strong grasp reflex of the upper and lower extremities (both represent phylogenetically old reflexes serving for grasping of mother's body in primates)

Motor functions:
– reflexes dominate
– motor functions are symmetrical on both sides of the body
– movements of the upper extremities resemble swimming (crawl technique)
– movements of the lower extremities resemble kicking
– sequential development of the diencephalon and basal nuclei leads to disappearance of these motor patterns
– "**Fencing position**": stimulation of the nuchal muscles and vestibular apparatus during head rotation towards the right side causes extension of the right-sided limbs and flexion of the left-sided one (so called asymmetrical tonic nuchal reflexes with an important role of the reticular formation)
– **thumb position:** the thumb is flexed in the palm and overlapped by other fingers

Vision: slight strabismus is usually present which is normal
– the newborn is not able to fix subject (the visual tract and lens accommodation are immature)
– eye movements are possible only in a horizontal direction (the centre for these movements is in the paramedial part of the pontine reticular formation)
– the newborn is only able to see large objects close to the eyes

Other senses: the sense of smell is relatively well developed, and as for the sense of taste, the newborn prefers sweet foods

Emotions: the newborn calms down in reaction to the mother's voice; crying dominates in negative emotions



Position on the abdomen

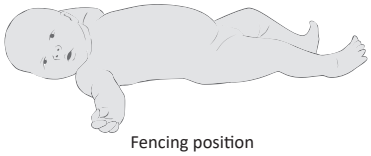

Fencing position

2nd month

Muscle tone: decreases, it is a period of **physiological hypotonia** which disappear at the end of the first year

Motor functions:
– the infant is able to elevate both lower limbs, in prone position is able to elevate the head for a while (increased activity of the nuchal muscles)
– typical is a dominant activity of the extrapyramidal system which is essential for physiological development of posture and ability to actively use the upper limbs, thumbs, and fingers
– **thumb position:** the thumbs change their position into abduction and the palms are opened

Vision: the newborn is able to fix subject in the visual field which is still narrower than in adults

Emotions: this is a period of smiling and typically reacts to the emotions of others (postnatal limbic system developments begins)

Speech: long vowels like "aaa" or "eee"

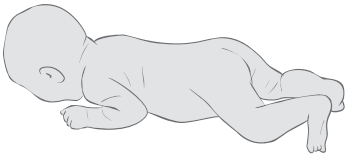

Resting on the forearms, head in the median position

This copy belongs to ali yaghoubi

3rd month

Motor functions:
– the baby watches the surroundings with an interest, turns the head in the direction of stimuli
– the asymmetrical tonic nuchal reflexes disappear as well as the fencing position
– **in prone position, the baby is in a position colloquially called "tummy time":** a position with an elevated head and supported by the forearms

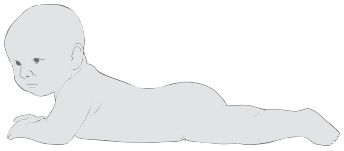

Position with an elevated head and supported by the forearms

– **"vision-hands-mouth"** coordination appears and high concentration of receptor areas (lips, tongue, sense of smell) are involved in stimulation of the CNS
– **Fine motor functions:** development of voluntary grasp (at the beginning the grasp is primitive, starting from the ulnar side)

Vision: refinement of lens accommodation, convergence, and vertical eye movements appear – this is caused by maturation of the oculomotor nerves, brainstem visual tract, and centre of vertical eyes movements in the rostral reticular formation (midbrain and pretectal area)
Speech: crooning and humming

4th month

Motor functions:
– the baby typically grasps toys by both hands
– the grasp is still immature, starting from the ulnar side of the hand (also, the lower extremities can be involved, e.g. drinking from a bottle)



Lower extremities can be involved in grasping objects

Vision: continuation of maturation (enlargement of the visual field and improvement in color perception)
– the baby prefers red color (perception of colors depends on maturation of cones, synthesis of visual pigments, and myelination of the visual tract)
– a possible explanation of red colour preference lies in its stimulation effect on the brain centers and limbic structures (red color is associated with danger)

Emotions: development of a relationship between the baby and mother (first feelings and affections), the baby is able to recognize his/her mother

5th month

Muscle tone: adaptation of muscle tone according to the centre of gravity and supporting body points (depending on development and myelination of the spinobulbar and spinoreticular tract)



Grasping with one hand

Motor functions: the baby is able to pass toy from one hand to another; the 5th month is a time of the first and successful attempts to make a turn from supine to prone position
– the baby is also able to grasp objects in prone position by letting go of one hand

6th month

Motor function: the baby is able to sit with support (by involving flexors) but **is not able to sit independently**
– from the position of "tummy time" the baby proceeds to extend the upper limbs (pivoting)
– the grasp also improves (the fingers are involved and sometimes the thumb in the opposite position is used)



Pivoting

Vision: myelination of the visual tract proceeds
Speech: is unintelligible, the baby babbles (which serves as stimulation for the auditory and speech cortical centers)
Emotions: the baby is able to recognize familiar persons and is afraid of unfamiliar persons and objects

The peak of visual acuity (6/6) is typically reached around the 5th or 6th year.

The first steps and attempts of walking appear usually around the 9th month.

7th month
Motor function:
– **in prone position, the baby resembles a "plane"**:
is able to release the head, trunk, and upper limbs, in the middle of the 7th month is also able to roll and later to creep and crawl on all four limbs
– actively sits up which enables release of the upper limbs for motor activity
– improvement of grasping and thumb functions

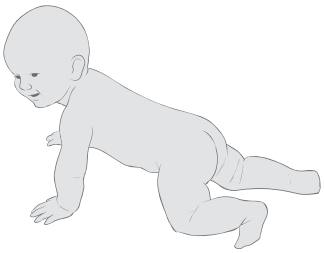

Beginning of crawling on all fours

8th month
Motor functions:
– visible improvement of rolling, crawling on all four limbs, and sitting up
– the baby is able to stand with support and tries to release one hand for grasping
– the grasp moves to the fingertips (at the beginning, it resembles grasping with pliers or scissors, later tweezers)
Vision: the baby prefers light colors
Speech: doubles syllables like "ma-ma", "pa-pa" and imitates sounds and gestures
Emotions:
– active mobility enables leaving the mother – "period of first separation"
– in case of loneliness (especially when the mother is not present) the baby experiences and expresses negative emotions such as anxiety, fear, sadness, and restlessness
– on the other hand, it reacts by smiling when hearing its name or familiar voices or sounds

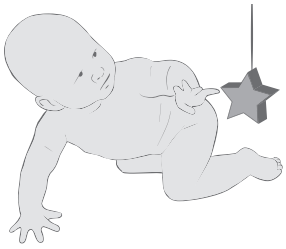

Crawling and grasping objects resembling grasping with tweezers

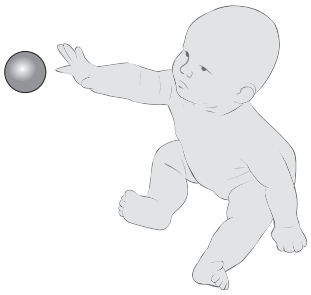

Ability to sit actively and grasping with one hand

9th month
Motor functions: baby is able to sit up actively, crawling is faster and better coordinated
– some babies prefer shuffling on their bottoms which represents also a physiological type of mobility
– the baby is able to stand up with support and the 9th month also represents a period of the first clumsy steps (without support the baby falls on its bottom at the beginning)
– the grasp is almost perfect and the baby is able to drop a toy
– typically responds to heard inducements such as: "Bye-bye" or hand-clapping

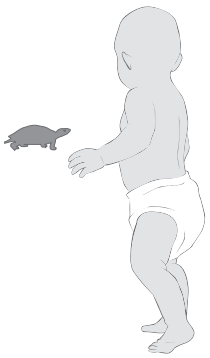

Beginning of walking (ipsilateral locomotor pattern)

10th and 11th months
Motor functions: improvement of walking and gait
– the baby is able to release the upper extremities and moves in space (development and maturation of visual and special coordination and orientation skills)
Speech: the baby typically uses up to 2 intelligible words



Walk forward (bipedal locomotor pattern)

12th month
Motor functions: the baby is able to stand up without any support and is able to walk (gait is still primitive with a broad base, steps are short, less clumsy but without typical step swing, the upper extremities serve for balancing)
– crucial is maturation of the cerebellar functions and tracts myelinization
Fine motor control: the baby is able to eat with a spoon and drink from a cup
– the upper extremities serve for grasping functions and the lower extremities have supporting functions
Speech: the baby reacts to stimuli such as: "Show me something." "Give me."
– actively uses minimally 2 intelligible words

This copy belongs to ali yaghoubi

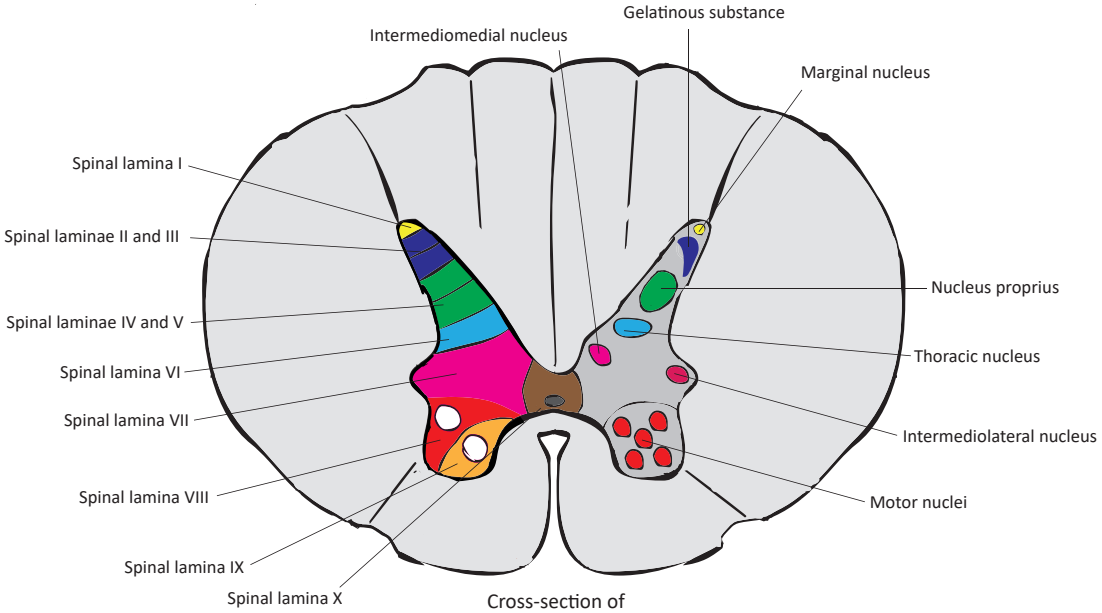

Cross-section of the spinal cord at the level of the eighth cervical segment

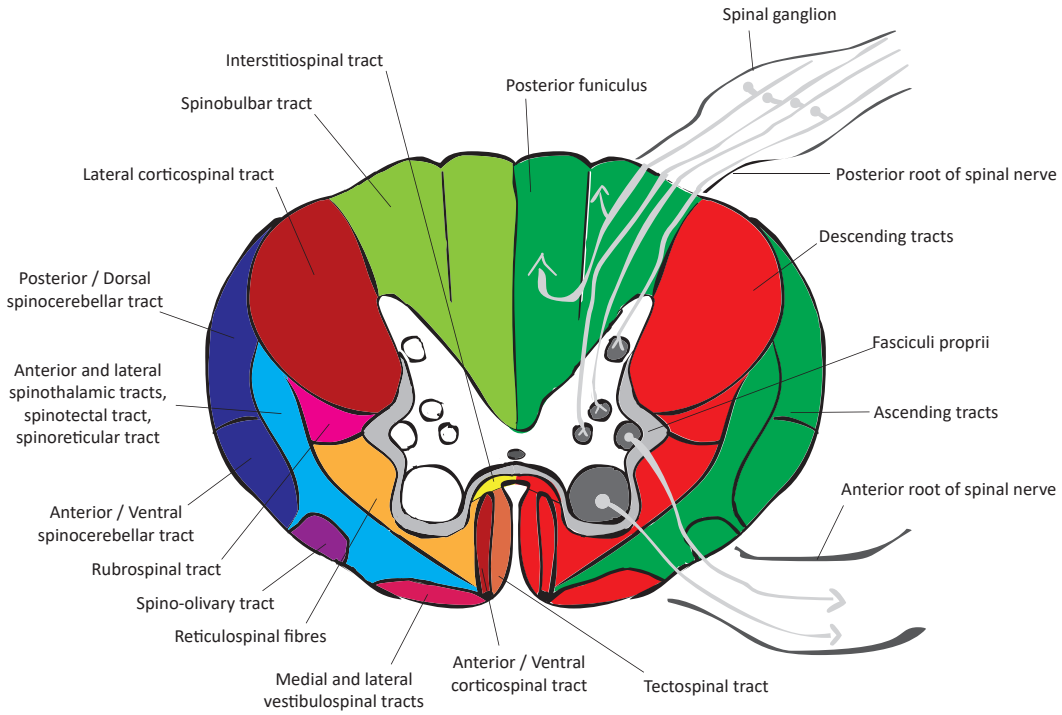

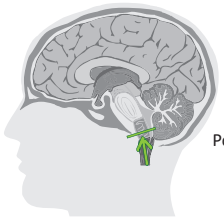

Caudal section

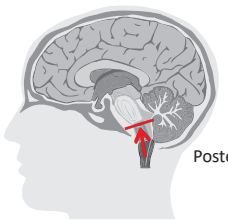

Rostral section

This copy belongs to ali yaghoubi

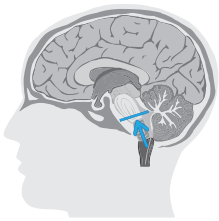

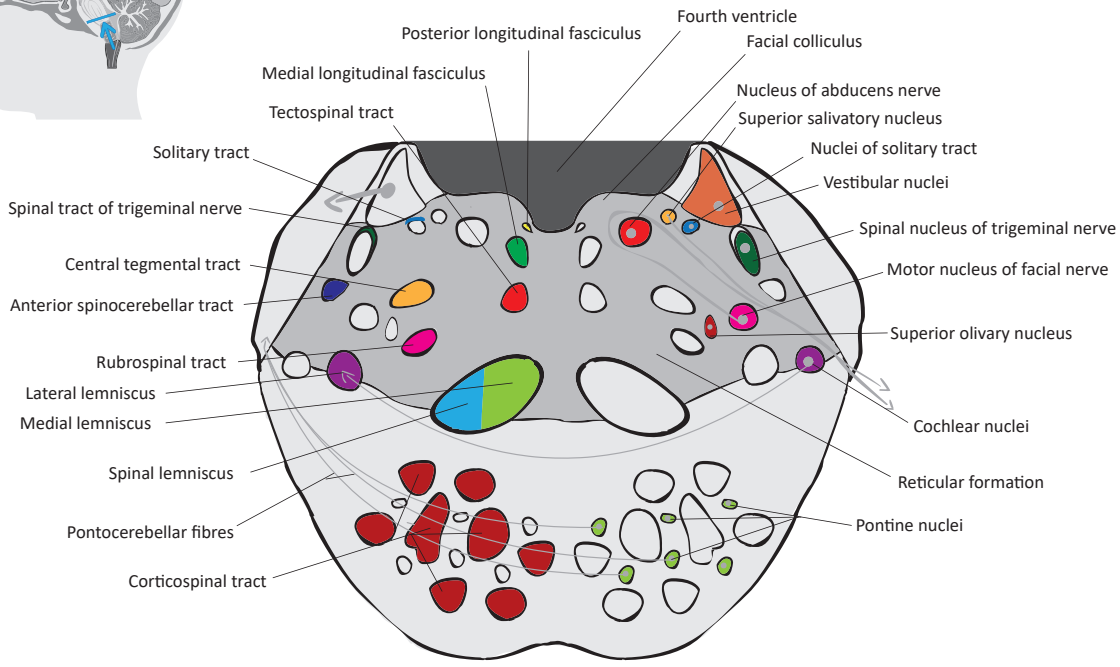

Caudal section

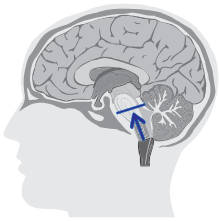

Rostral section

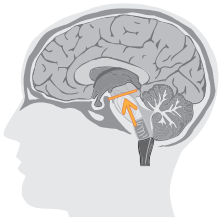

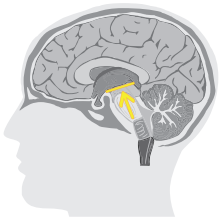

This copy belongs to ali yaghoubi

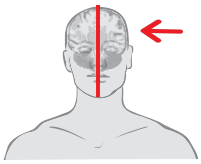

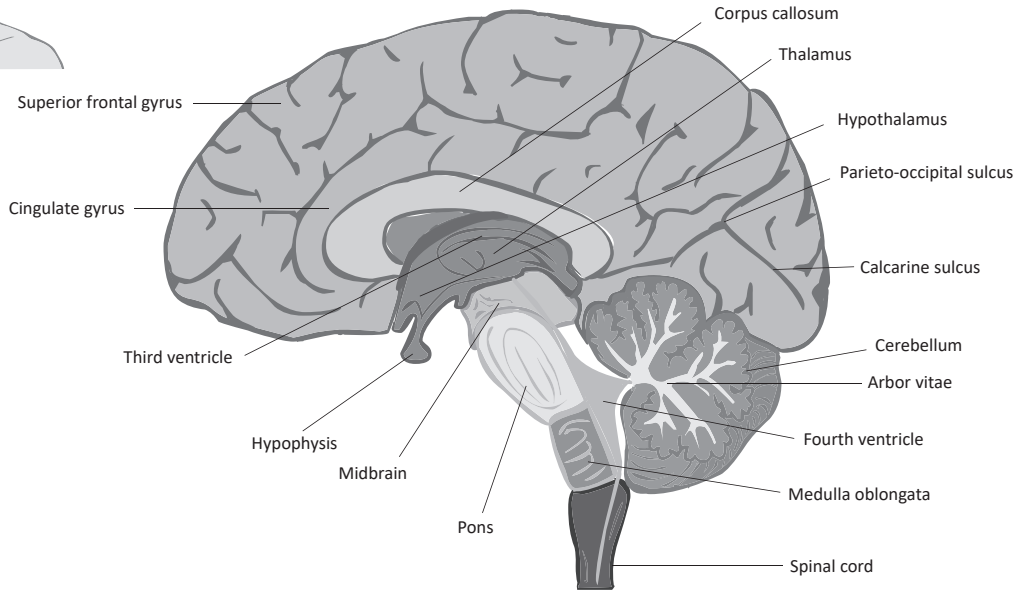

Sagittal section of the brain

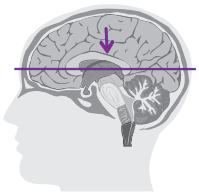

Cross-section of the brain

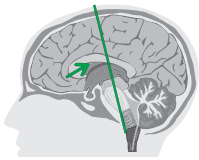

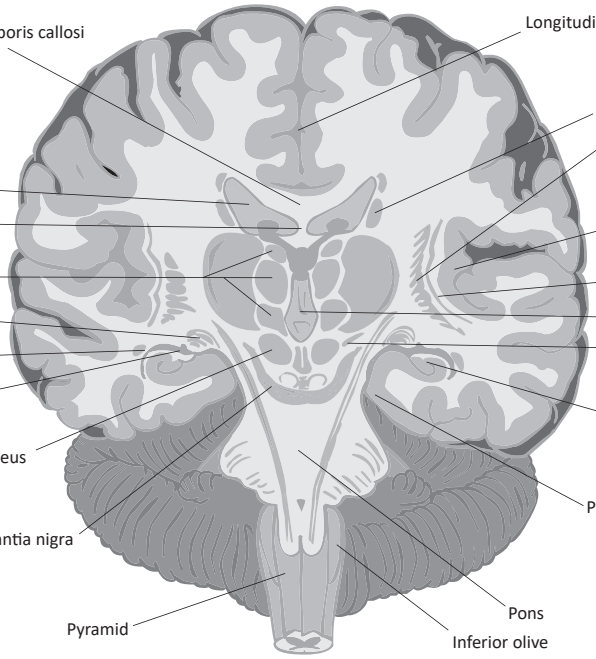

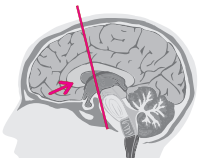

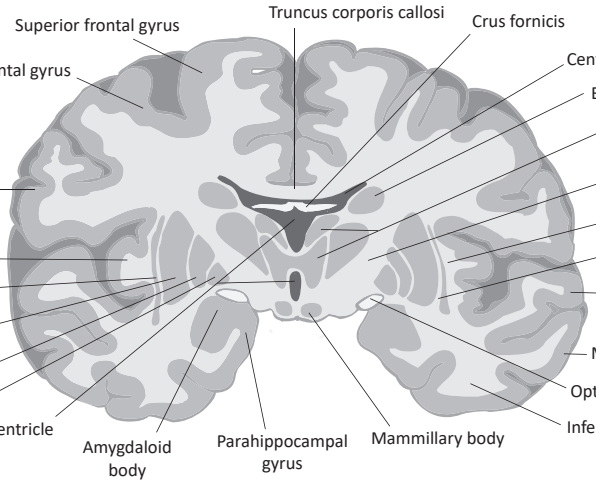

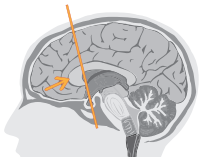

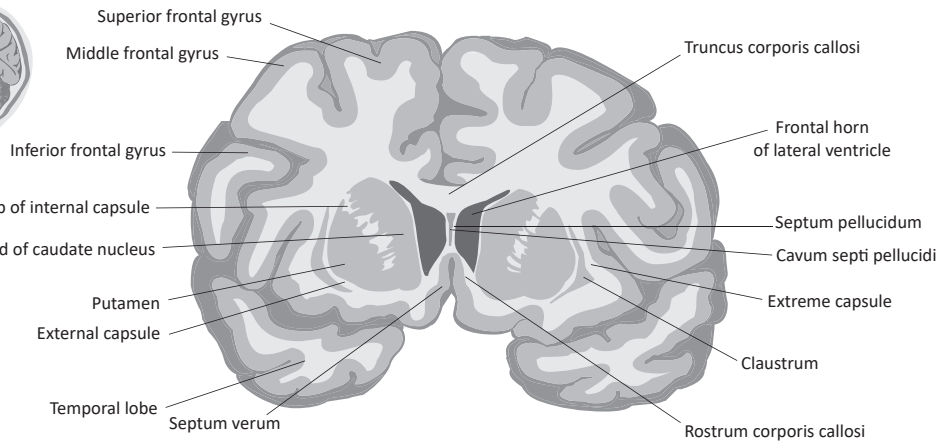

This copy belongs to ali yaghoubi

Sulcus	Location
Sulcus frontalis superior et inferior	a furrow between the gyrus frontalis superior and medius, or the gyrus frontalis medius and inferior
Sulcus precentralis	a furrow in front of the gyrus precentralis
Sulcus olfactorius	a furrow separating the gyrus rectus and gyri orbitales on the inferior surface of the frontal lobe
Sulci orbitales	a furrow located between the gyri orbitales on the inferior surface of the frontal lobe
Sulcus rhinalis	a furrow separating the paleocortex from the neocortex
Sulcus collateralis	a furrow separating the gyrus occipitotemporalis medialis and gyrus parahippocampalis from the gyrus occipito-temporalis lateralis which is located laterally.
Sulcus cinguli	a furrow separating the gyrus cinguli from the frontal and parietal lobe on the medial surface of the hemiphere.
Sulcus corporis callosi	a furrow separating the corpus callosum from the gyrus cinguli
Sulcus hippocampalis	a furrow separating the gyrus dentatus from the gyrus parahippocampalis
Sulcus temporalis superior et inferior	a furrow separating the gyrus temporalis superior and medius, or the gyrus temporalis medius and inferior
Sulcus circularis insulae	a furrow separating the lobus insulae from the neighbouring lobes on the undersurface of the fossa lateralis cerebri
Sulcus intraparietalis	a furrow separating the lobulus parietalis superior from the lobulus parietalis inferior
Sulcus parietooccipitalis	a furrow separating the lobus parietalis from the lobus occipitalis, a distinctive groove on the medial surface of the hemisphere, it coincides with the sulcus calcarinus and also passes to the superolateral surface
Sulcus occipitalis transversus	a furrow of the occipital lobe that is parallel to the sulcus parietoocipitalis
Sulcus occipitalis lateralis	a furrow on the lateral surface of the occipital lobe
Incisura preoccipitalis	a furrow located approximately 5 cm in front of the polus occipitalis, the border between the temporal and occipital lobe
Sulcus subparietalis	a furrow separating the precuneus of temporal lobe from the gyrus cinguli
Sulcus occipitotemporalis	a furrow separating the gyrus occipitotemporalis lateralis from the gyrus temporalis inferior

21.1 Scheme of the cranial nerves nuclei

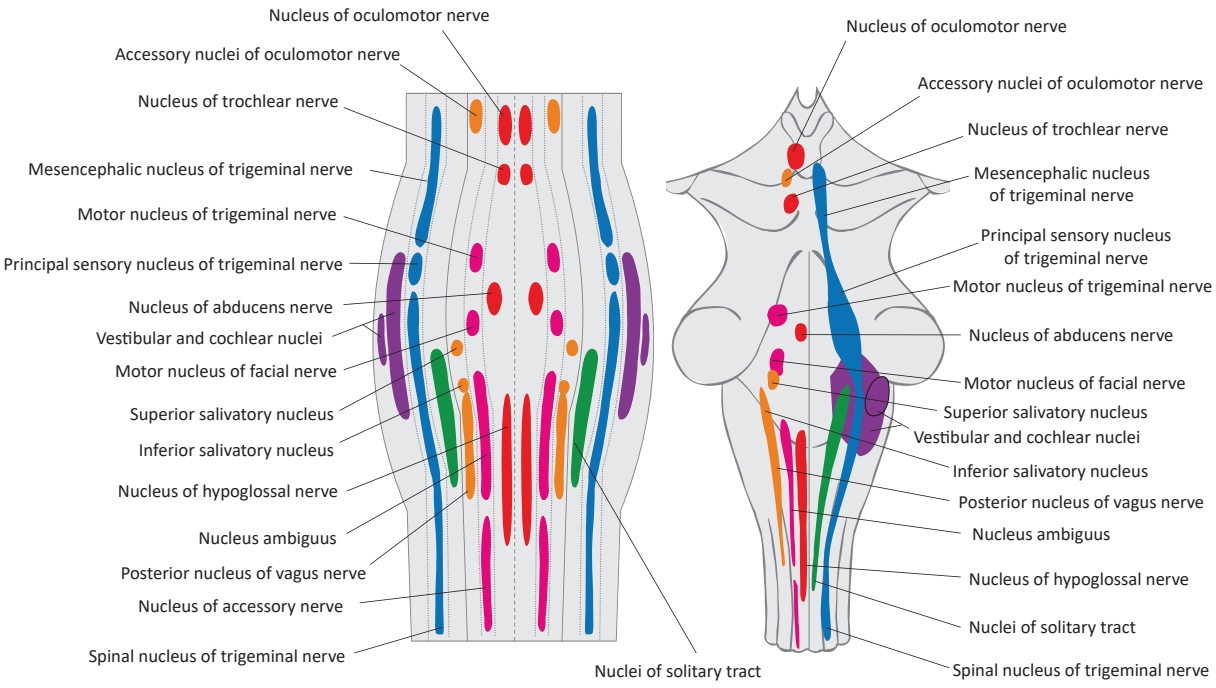

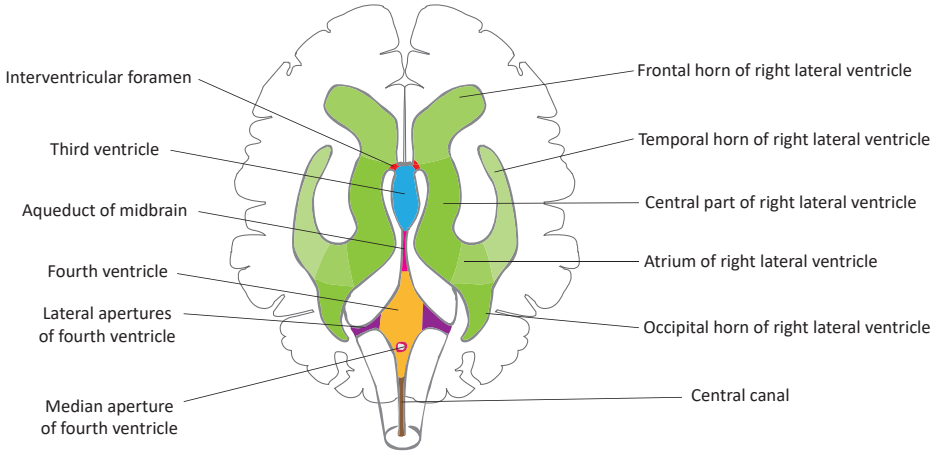

Scheme of the ventricular system

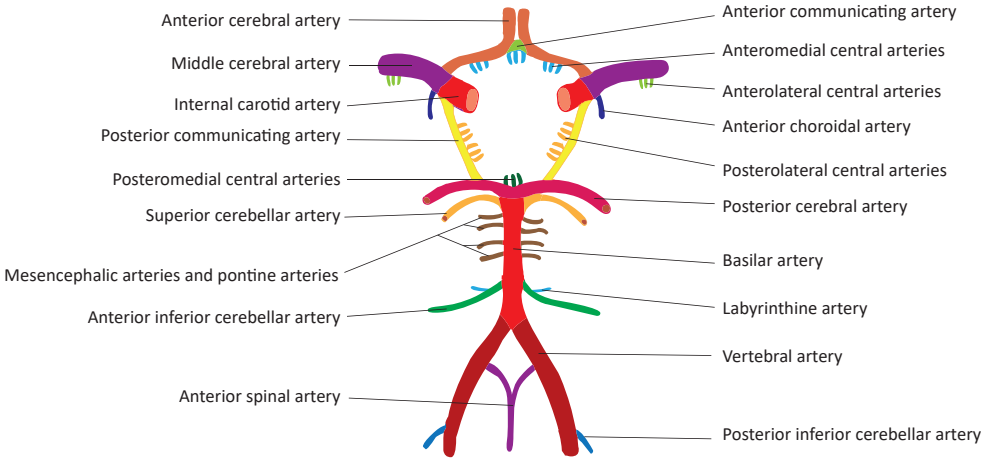

Scheme of the cerebral arteries

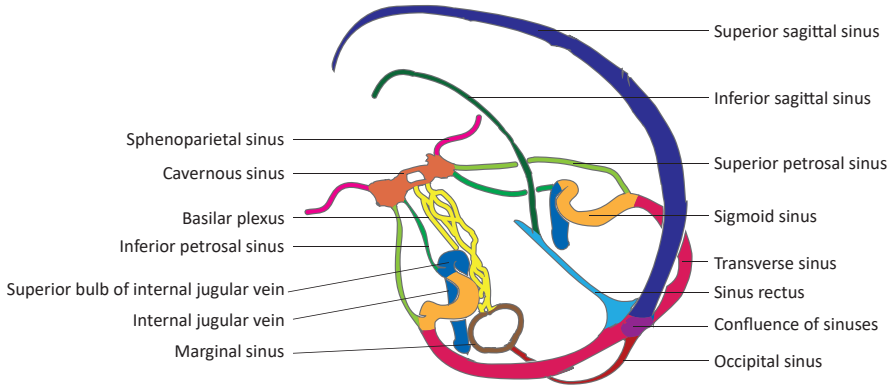

Scheme of the venous sinuses

This copy belongs to ali yaghoubi

1. – order neuron

Lemniscal system

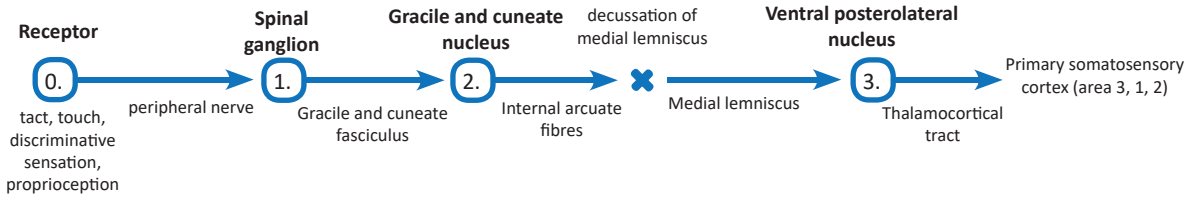

Spinothalamic fibres

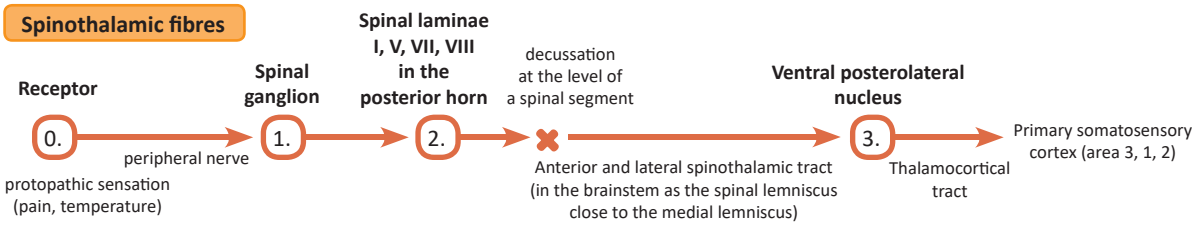

Spinoreticular fibres

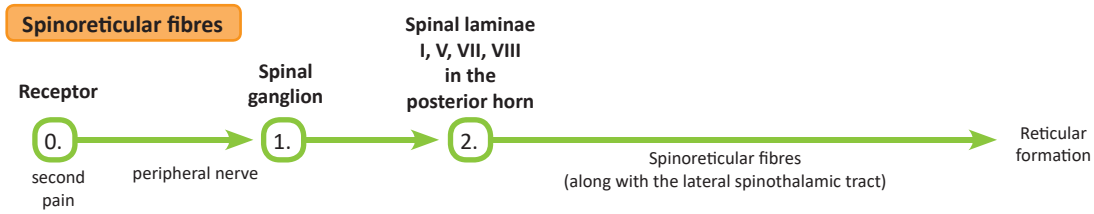

Spinotectal tract

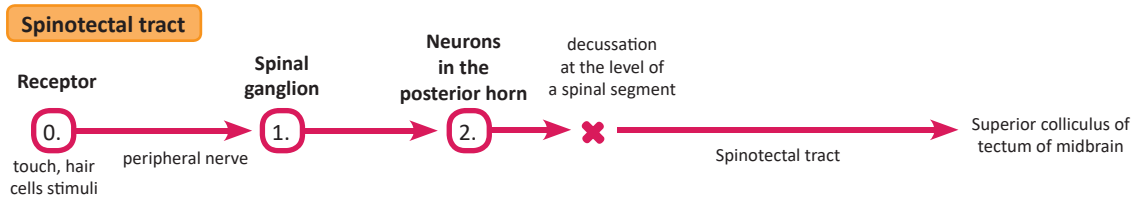

Anterior spinocerebellar tract

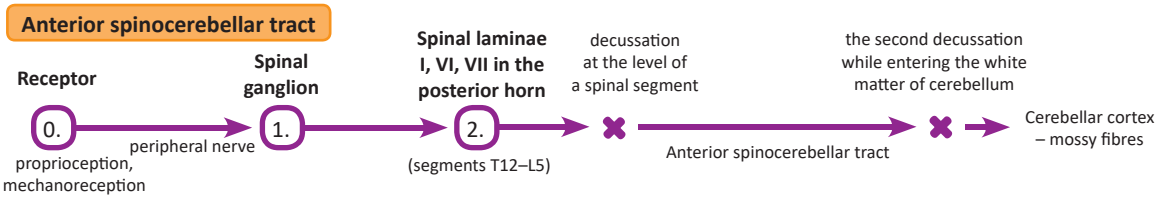

Posterior spinocerebellar tract

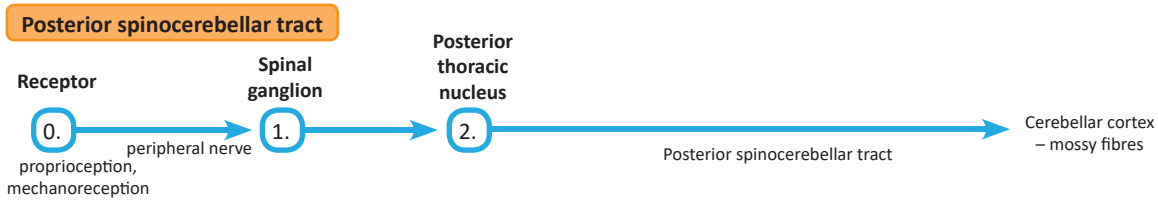

Spinoolivocerebellar tract

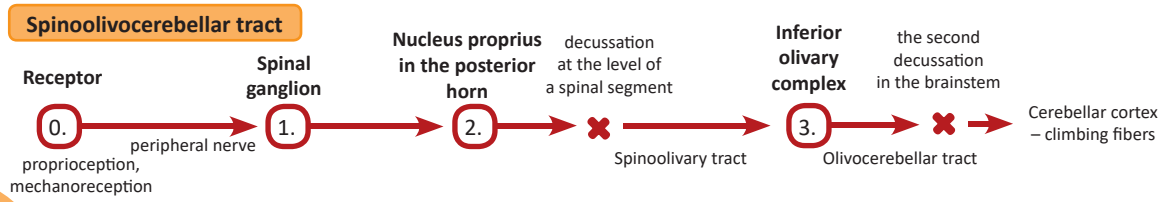

1. – order neuron

Visual tract with accessory branches

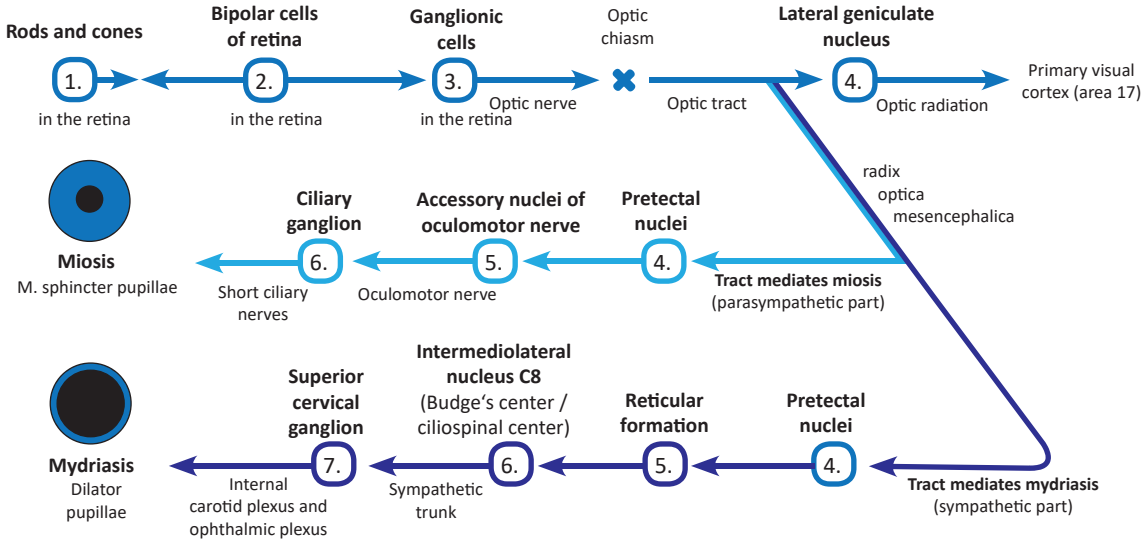

Auditory tract

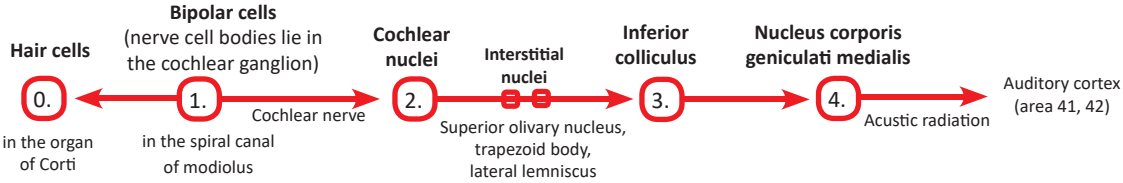

Vestibular tract

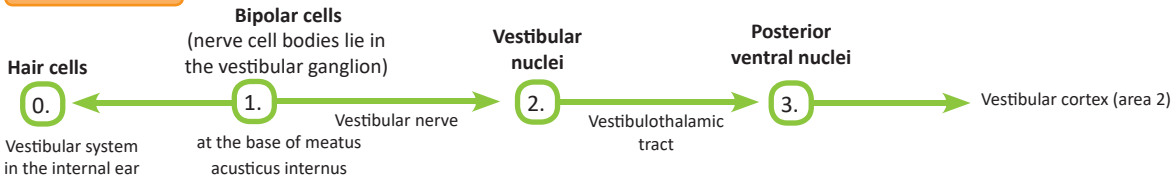

Gustatory tract

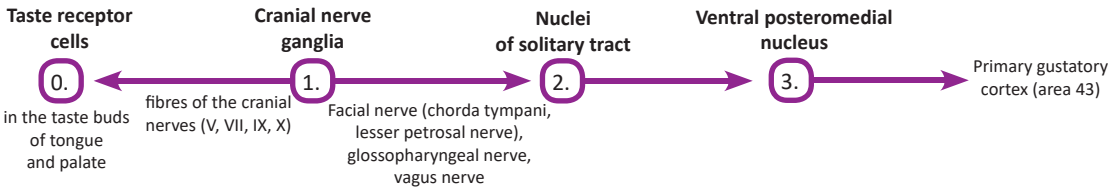

Olfactory tract

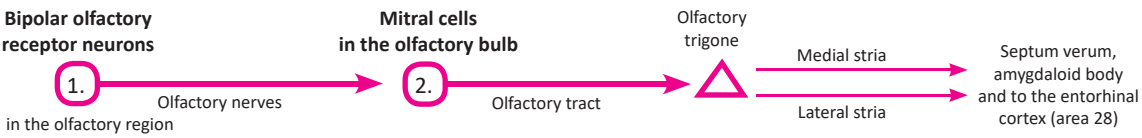

This copy belongs to ali yaghoubi

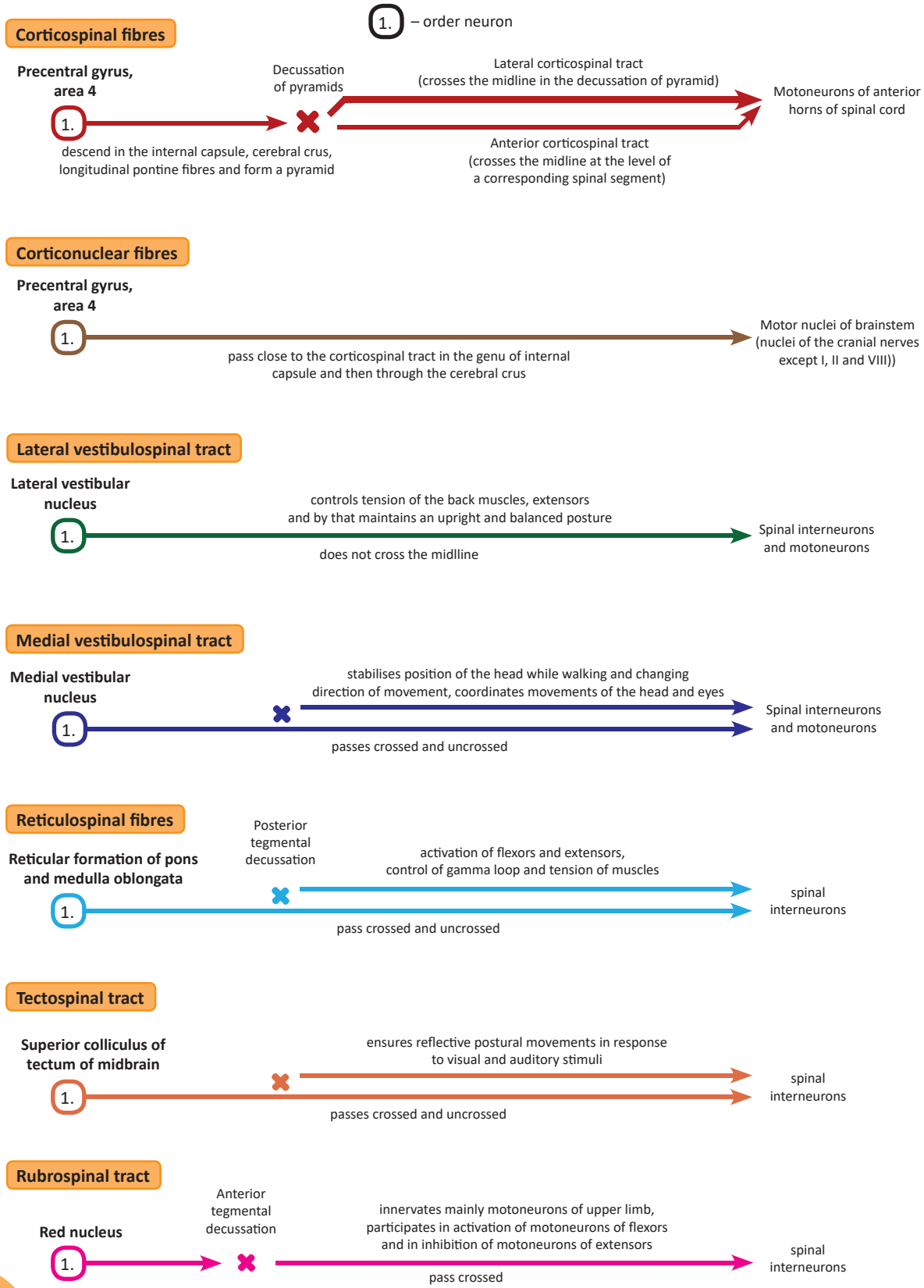
1. – order neuron
Corticospinal fibres
Precentral gyrus, area 4
1.
descend in the internal capsule, cerebral crus, longitudinal pontine fibres and form a pyramid
Decussation of pyramids
Lateral corticospinal tract (crosses the midline in the decussation of pyramid)
Motoneurons of anterior horns of spinal cord
Anterior corticospinal tract (crosses the midline at the level of a corresponding spinal segment)
Corticonuclear fibres
Precentral gyrus, area 4
1.
pass close to the corticospinal tract in the genu of internal capsule and then through the cerebral crus
Motor nuclei of brainstem (nuclei of the cranial nerves except I, II and VIII))
Lateral vestibulospinal tract
Lateral vestibular nucleus
1.
controls tension of the back muscles, extensors and by that maintains an upright and balanced posture
does not cross the midlline
Spinal interneurons and motoneurons
Medial vestibulospinal tract
Medial vestibular nucleus
1.
stabilises position of the head while walking and changing direction of movement, coordinates movements of the head and eyes
passes crossed and uncrossed
Spinal interneurons and motoneurons
Reticulospinal fibres
Reticular formation of pons and medulla oblongata
1.
Posterior tegmental decussation
activation of flexors and extensors, control of gamma loop and tension of muscles
pass crossed and uncrossed
spinal interneurons
Tectospinal tract
Superior colliculus of tectum of midbrain
1.
ensures reflective postural movements in response to visual and auditory stimuli
passes crossed and uncrossed
spinal interneurons
Rubrospinal tract
Red nucleus
1.
Anterior tegmental decussation
innervates mainly motoneurons of upper limb, participates in activation of motoneurons of flexors and in inhibition of motoneurons of extensors
pass crossed
spinal interneurons

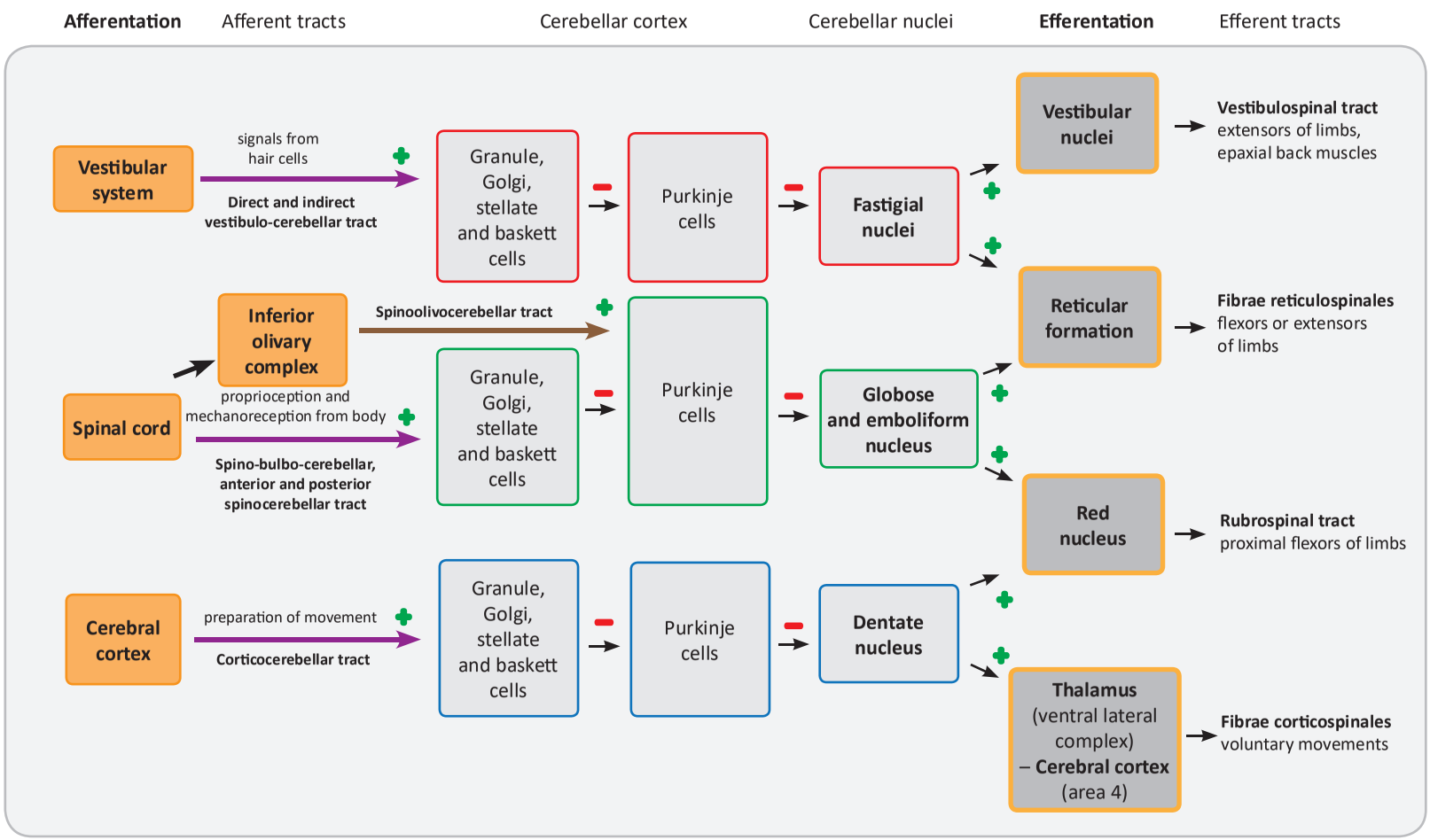

This copy belongs to ali yaghoubi

I. General structure and development of the central nervous system

1. Describe the different principal types of astrocytes. (p. 390)
2. Describe the functions of astrocytes which are in contact with capillaries. (p. 390, 391)
3. List four differences between oligodendrocytes and Schwann cells. (p. 390)
4. Name the glial cells which have considerably limited ability to regenerate. (p. 390)
5. Describe ependymal cells, their position and function. (p. 391)
6. Explain the term hematoencephalic barrier and think about the location of other similar hematoorganic barriers in the body. (p. 390)
7. Name the three brain vesicles from which the brain develops. (p. 392)
8. Describe the topographical relationship between the sulcus limitans and original alar, basal plate. (p. 392)
9. Describe the developmental difference between the basal and alar plate. (p. 392)
10. Describe the development of the nervous system from the bilaminar germ disc phase. (p. 392, 393)

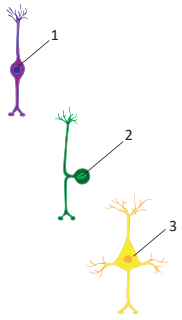

Describe the types of neurons

II. Spinal cord

11. Name the spinal nuclei where the central branches of the pseudounipolar neurons of the peripheral nervous system terminate. (p. 401)
12. Name the fasciculus containing only ascending spinal tracts. (p. 399)
13. Name the somatosensory and viscerosensory spinal nuclei which create pairs "nucleus – pathway". (p. 401)
14. Describe the functional relationship between the ncl.intermediolateralis and ncl.intermediomedialis. (p. 401)
15. Describe the position and function of the ncl.apicalis and substantia gelatinosa. (p. 401)
16. Name the three spinal pathways that start in the ncl.proprius. (p. 401)
17. List the two segments where the posterior thoracic nucleus is located in and name the pathways that originate in the nucleus. (p. 401)
18. Name motoneurons of extrafusal muscle fibres. (p. 399)
19. Explain the physiological role of the gamma loop. (p. 450)
20. Name the fasciculus through which the tractus spinobulbaris passes. (p. 400)
21. Give all examples of the spinal pathways which do not cross the midline at the level of the spinal medulla and pass ipsilaterally. (p. 453–455)
22. Name the ascending cerebellar pathway going through the pedunculus cerebellaris superior. (p. 455)
23. Name the nucleus which is an analogue of the posterior thoracic nucleus for proprioception from the upper limbs. (p. 455)

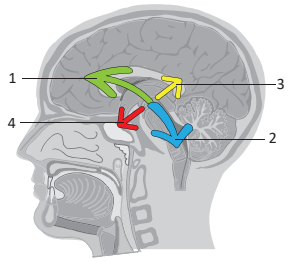

Describe the brain directional terms

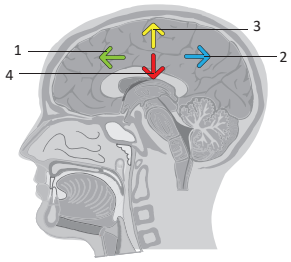

Describe the directional terms in the telencephalon

III. Medulla oblongata

24. Identify all of the nuclei located in the medulla oblongata. (p. 404, 405)
25. Name the seven ascending pathways passing through the medulla oblongata. (p. 404, 405)
26. Describe the two pathways interconnecting the ncl.gracilis and the ncl.cuneatus. (p. 404, 405)
27. Name the pathway which decussates in the decussatio pyramidum. (p. 404, 405)
28. Name the three paired structures connecting the brainstem and cerebellum. (p. 418)
29. Characterise the lemniscal pathways. (p. 404)
30. Describe the location of the decussation lemniscorum in the brain stem. (p. 404, 405)

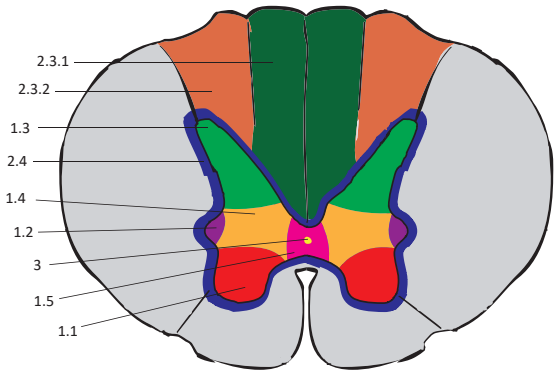

Describe the parts of the spinal segment

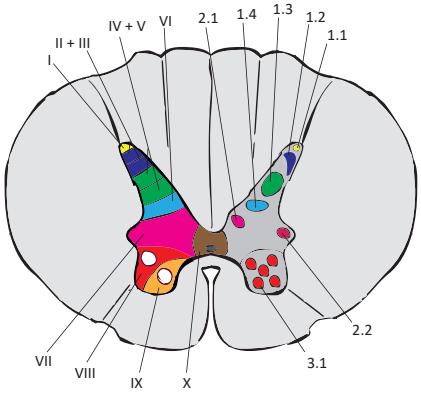

Describe the Rexed's laminae and spinal nuclei

IV. Pons

31. Give three examples of the cranial nerves extending from the horizontal groove between the pons and medulla oblongata. (p. 406–407)
32. Describe the pathways connecting the cortex, pons, and cerebellum. (p. 406–407)
33. Name two (main and intralaminar) nuclei that the lemniscus lateralis protrudes from. Which sensory information does it carry? (p. 407–465)
34. Name the muscle which is disabled when a lesion of the nervus abducens occurs. Describe the clinical symptoms of the palsy. (p. 406, 410)
35. Give all four examples of the cranial nerves which have autonomic nuclei. (p. 410)
36. Give all four examples of the nuclei which belong to the trigeminal nerve and their location in the brainstem. (p. 410)

V. Midbrain

37. List the two nerves extending from the mesencephalon. (p. 408–410)
38. Define the border between the tectum and tegmentum. (p. 408)
39. Describe the connection between the colliculus superior, inferior and nuclei of the metathalamus. (p. 408–410)
40. Name the sensory pathways passing through the brachium colliculi superioris and inferioris. (p. 429)
41. Name all five pathways passing through the crus cerebri. (p. 409)
42. Describe the course of the tractus rubrospinalis at the level of the brainstem and spinal cord. (p. 407, 409, 460)
43. Describe the nucleus/ nuclei of the mesencephalon which have/has a projection to the circuits of the basal nuclei including neurotransmitters. (p. 408–410)
44. Define the term periaqueductal gray and describe its functions. (p. 412)
45. Describe the organization of the reticular formation in the mesencephalon (p. 414, 415)

VI. Reticular formation

46. Define the reticular formation, its functions and connections. (p. 414, 416, 417)
47. Describe the organization of the nuclei located in the reticular formation. (p. 414, 415)
48. Name and describe the position of the control centres located in the formatio reticularis at the level of the brainstem. (respiratory center, the centet for vasomotor control, the center of defensive reflexes, etc.) (p. 417)
49. Describe the role of the ascending reticular activating system (ARAS). (p. 417)
50. List the nuclei and the neurotransmitters of the reticular formation with an inhibitory effect. (p. 415, 417, 477)
51. Name the horizontally positioned group of nuclei with the most abundant afferent and efferent connections to the structures of the central nervous system. (p. 415)
52. Name the chemical nuclei of the reticular formation synthesizing dopamine and other catecholamines. (p. 415, 477)
53. Describe the role and integration of the nuclei reticullares precerebellares. (p. 415)

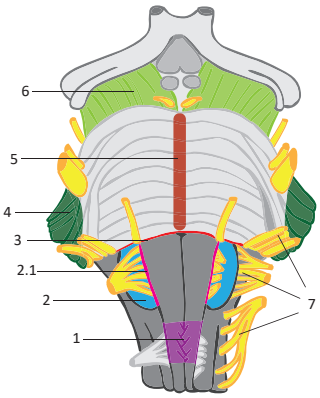

Describe the ventral surface of the brainstem

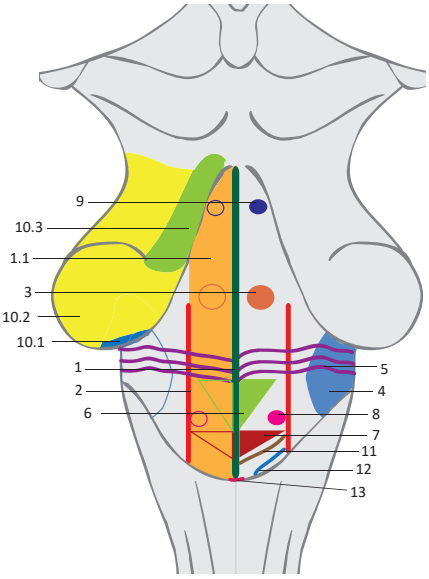

Describe the floor of fourth ventricle (rhomboid fossa)

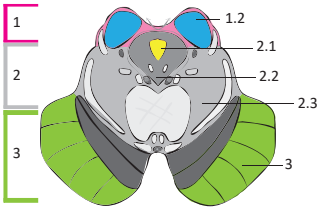

Příčný řez v úrovni coliiculus inferior

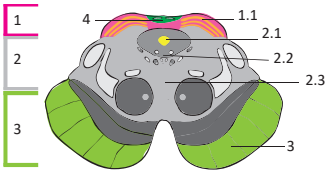

Describe the structure of the midbrain

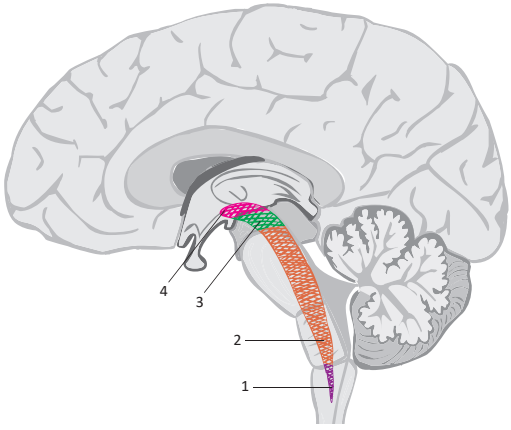

Desribe the parts of the reticular formation

This copy belongs to ali yaghoubi

VII. Cerebellum

54. Name the cerebellar structures made up of gray matter. (p. 419)
55. List the cerebellar nuclei and describe their position in white matter. (p. 417)
56. Describe the connection of the cerebellar nuclei to the cerebellar efferents. (p. 422)
57. Describe the archicerebellum. (p. 420)
58. Give the differences between the climbing fibres and mossy fibres. (p. 419)
59. Name the parts of the cerebellum which form the neocerebellum and list their functions. (p. 421)
60. Explain the term diadochokinesis or more precisely its disorder – adiadochokinesis. (p. 422)
61. Describe the cerebellar glomerulus (its location, dendrites and axons forming the glomerulus). (p. 419)
62. Describe the position and function of Purkinje cells and their effect on axonal synapses. (p. 419)
63. Explain the circuitry of the cerebellar cortex by Eccles. (p. 419)
64. Give a description and explain the integration of the lobus flocculonodularis. (p. 419)

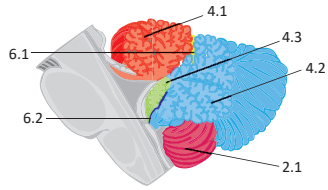

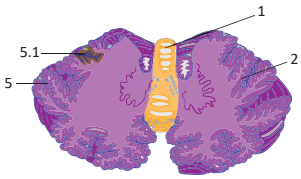

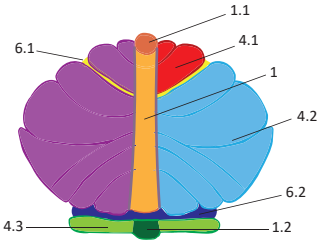

Describe the parts of the cerebellum

VIII. Diencephalon

65. List the three parts of the diencephalon which derive from the alar plate and describe their position. (p. 424)
66. List the two parts of the diencephalon which derive from the basal plate and describe their position. (p. 424)
67. List five structures forming the epithalamus. (p. 425)
68. Characterise the metathalamus. (p. 424)

IX. Thalamus

69. Name the nuclei which belong to the anterior nuclear group. (p. 427–429)
70. Name the nuclei which belong to the midline nuclear group. (p. 427–429)
71. Describe seven nuclei which belong to the lateral nuclear group. (p. 427–429)
72. List functions and integrations of the nuclei posteriores thalami. (p. 428)
73. Describe the position of the thalamic motor nuclei. (p. 429)
74. Name two somatosensory nuclei of the thalamus. (p. 429)
75. Name the thalamic nucleus which is involved in processing of gustatory information. (p. 429, 467)
76. Describe the connection between the nucleus ventralis anterior, cortex, and basal ganglia. (p. 429)
77. Describe the difference between the nucleus ventralis lateralis and nucleus ventralis posterolateralis from the functional point of view. (p. 429)
78. Describe integration and function of the intralaminar nuclei. (p. 428)
79. What is the function of the association nuclei of the thalamus? (p. 428)

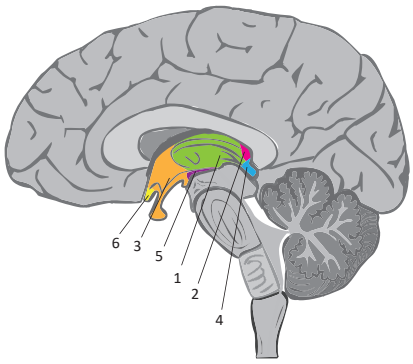

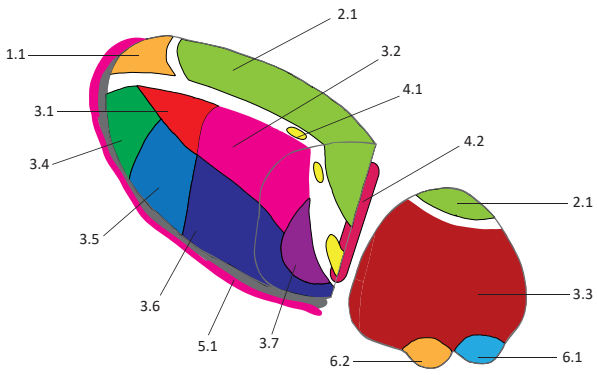

Describe the parts of the thalamus

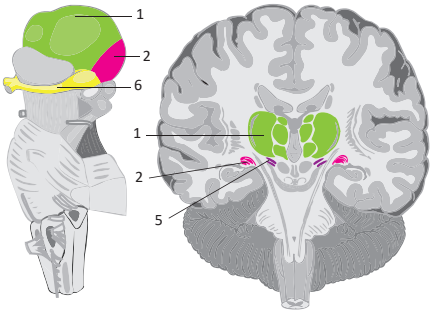

Describe the parts of the diencephalon

X. Hypothalamus

80. Describe the hypothalamus-pituitary axis and its importance. (p. 430–431)
81. Describe the topographical relationship between the fossa hypophysialis, sinus sphenoidalis, and chiasma opticum. (p. 430)
82. Topographically describe the location of the two nuclei secreting oxytocin. (p. 431)
83. Name the nucleus or nuclei which participate in blood pressure regulation. (p. 431)
84. Describe the three nuclei secreting liberins and statins which are interconnected by the tractus tubero-infundibularis with the capillaries of the hypophyseal portal system. (p. 431)
85. Name the nucleus involved in maintaining circadian rhythms. (p. 431)
86. Name the nucleus which is most commonly associated with satiety and also the nucleus called the feeding centre of the brain. (p. 431)
87. Describe the nuclei involved in the thermoregulation. (p. 431)

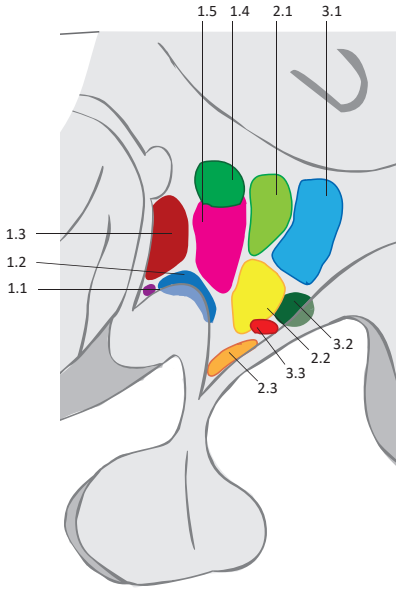

Describe the nuclei of the hypothalamus

XI. Cerebral cortex

88. Describe and name the location of the primary motor cortex. (p. 433)
89. Describe the topographical and functional relationship between the primary motor cortex and primary somatic sensory cortex. (p. 433)
90. Describe the location and function of the supplementary motor area and premotor cortex. Compare them with the primary motor cortex. (p. 436)
91. Describe the location and function of the frontal eye field (FEF). (p. 436)
92. Describe the location, function and also projections to the Broca's area. (p. 436)
93. Name the associative tract connecting the Broca's area with the Wernicke's area. (p. 436)
94. Which hemisphere is the language centre commonly located? What clinical importance does it have? (p. 436)
95. Describe the difference between damage to Broca's area and Wernicke's area. Consider language abilities. (p. 436)
96. Explain why the somatic sensory cortex is called granular? (p. 434)
97. Define neglect syndrome and describe its neuroanatomical principle. Which are the damaged cortical areas? (p. 438)
98. Describe the primary visual cortex. (p. 438)
99. Describe the secondary visual cortex and its location. (p. 437)
100. Describe the role of the occipital-temporal and occipital-parietal visual projections. (p. 438)
101. List the associative visual areas. (p. 438)
102. Explain the functional relationship between the area 41, 42 and area 22. (p. 437)
103. Describe the location of the gustatory area (cortex). (p. 437)
104. Describe the structures of the allocortex and neocortex involved in olfactory perception. (p. 434, 437)
105. Describe the function of the area 28. (p. 437)
106. Describe the associative neocortex and its location in cerebral lobes. (p. 438)
107. Describe the higher nervous functions which take place in the neuronal nets of the frontal lobe. (p. 438)

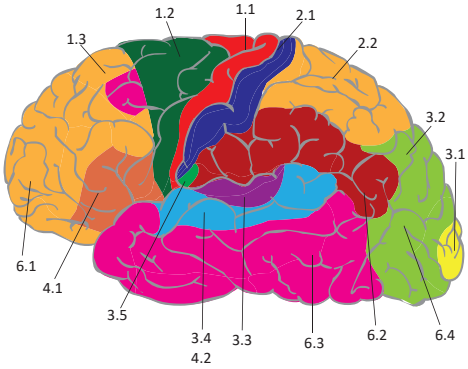

Describe the cerebral cortex functional areas

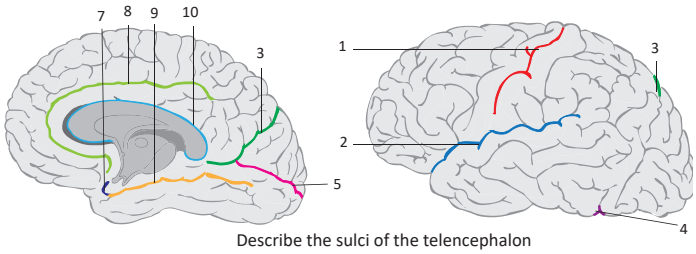

Describe the sulci of the telencephalon

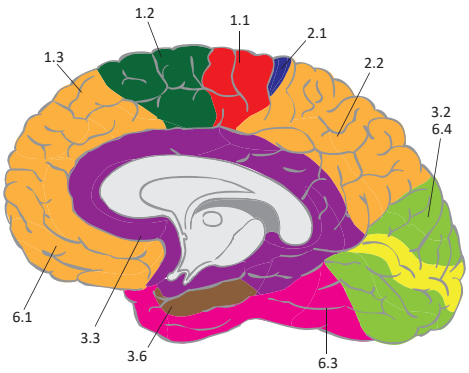

Describe the cerebral cortex functional areas

This copy belongs to ali yaghoubi

XII. Basal ganglia

108. What are the basal ganglia, explain their development and location. (p. 439)
109. List the basal ganglia which represent the input nuclei of the complex circuitry of the basal ganglia. (p. 440, 441)
110. List the basal ganglia which represent the output nuclei of the complex circuitry of the basal ganglia. (p. 440, 441)
111. Simply characterise the circuits of the basal ganglia system and their functions. (p. 441)
112. Describe the process of activation of motor response. How is the activity of the motor thalamic nuclei inhibited? (p. 440)
113. Describe the functional relationship between the globus pallidum and nucleus subthalamicus. (p. 440)
114. Describe syntopy of the external capsule, internal capsule extreme capsule, and also their relationships to particular basal ganglia. (p. 439)

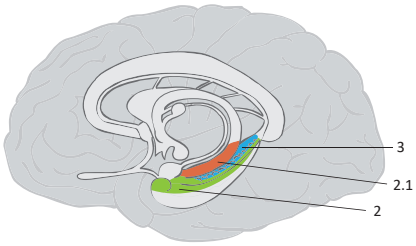

XIII. Limbic system

115. Explain the terms " allocortex, paleocortex, archicortex, mesocortex, and neocortex." (p. 440)
116. Delinate the Papez circuit. (p. 447)
117. Name the structures of the limbic system involved in the mechanisms of storing memory traces. (p. 445, 446)
118. Describe the corpus amygdaloideum and its topographical relationship to the hippocampus. (p. 446)
119. Describe the structure which interconnects the hippocampus and nuclei mamillares. (p. 446)
120. What are the nuclei belonging to the septum verum. (p. 446)

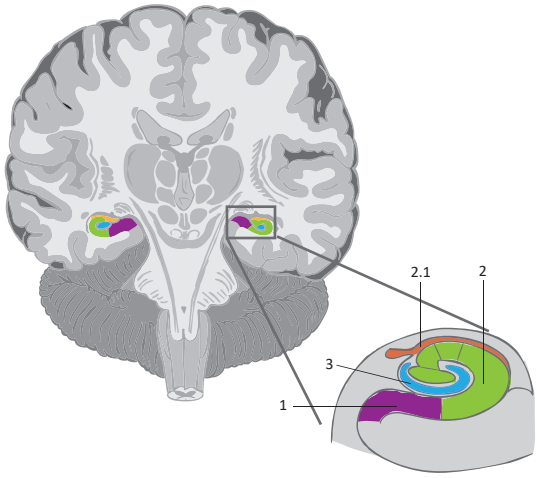

Describe the parts of the hippocampal formation

XIV. Motor pathways

121. List and describe eight descending motor pathways. (p. 458)
122. Name the nuclei of the brainstem where extrapyramidal tracts/pathways begin. (p. 460, 461)
123. Name the pathways responsible for gross motor skills of the epaxial muscles. (p. 460, 461)
124. Name the nuclei where the tractus vestibulospinalis medialis and lateralis begin. (p. 460)
125. List the basic differences between a reflex and targeted motor skills. (p. 457)
126. Describe the importance and the course of the tractus tectospinalis through the brainstem and spinal cord. (p. 461)

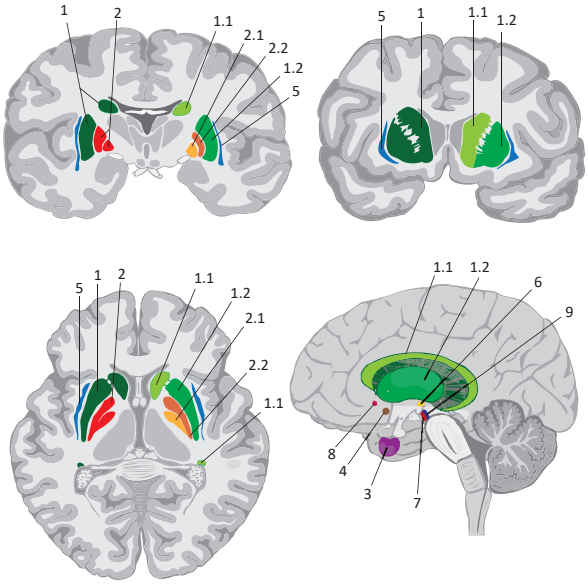

Describe the basal nuclei

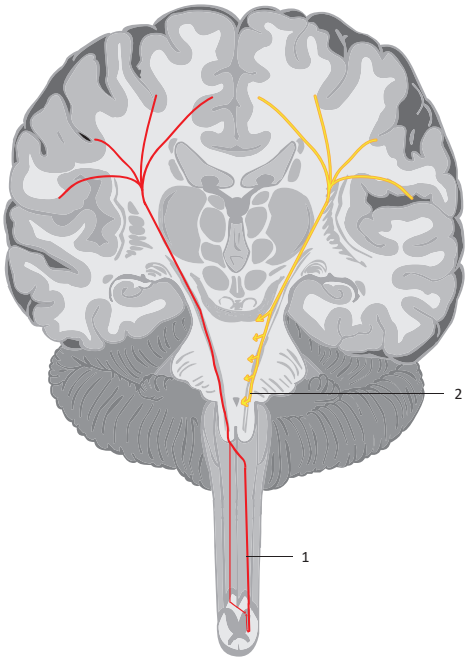

Describe motor pathways

XV. Meninges

127. Describe the content of the canalis spinalis from the level of the endorhachis to the pia mater spinalis. (p. 398)
128. Name the spaces located between the meninges and their content. (p. 398)
129. Describe the cauda equina, muscle groups and the cutaneous area innervated by respective nerves. (p. 398)
130. List the spinal cord segments and their topographical location related to vertebrae compressed in conus medullaris syndrome or epiconus syndrome.(p. 398)

XVI. Cerebrospinal fluid

131. Describe the production, drainage, and absorption of cerebrospinal fluid. (p. 470)
132. Describe the ways cerebrospinal fluid is drained in the ventricular system. (p. 470)
133. Give an anatomical and functional description of the granulationes arachnoideales. (p. 470)
134. List the cisterns in the subarachnoid space and their relationship to the brainstem and telenecephalon. (p. 470)
135. Name and describe an anatomical cause of disorder of CSF flow. (p. 470)
136. Describe the space with the physiological absence of the epidural space. (p. 470)
137. What kind of arterial haemorrhage is manifested as epidural hematoma? (p. 471, 472)

XVII. Blood supply

138. List the arteries involved in the blood supply of the spinal cord. (p. 476)
139. Describe the system of the spinal arteries. (page. 476)
140. Describe the system of the plexus venosi vertebrales and their location. (p. 476)

XVIII. Chemical system of the brain

141. List the inhibitory neurotransmitters of the central nervous system. (p. 477, 478)
142. List the nuclei producing monoamine neurotransmitters. (p. 477)
143. Describe the serotonergic system of the brain. (p. 477)
144. List the nuclei and projections of the cholinergic system. (p. 478)

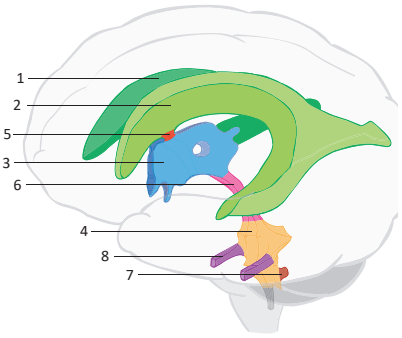

Describe the parts of the ventricular system

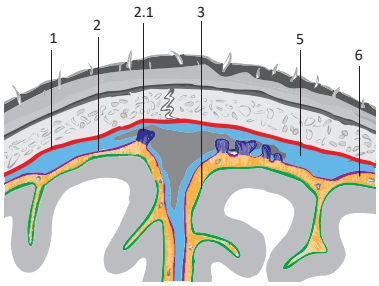

Describe the meninges and the space bordered by them

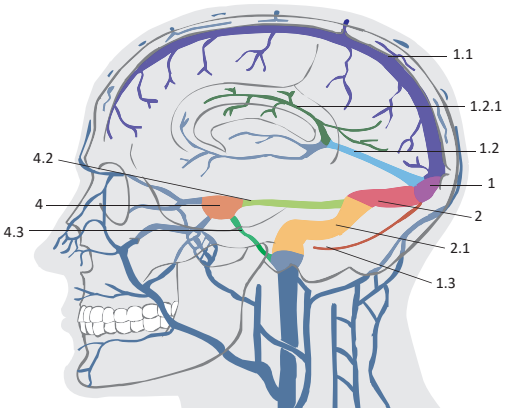

Describe the venous sinuses

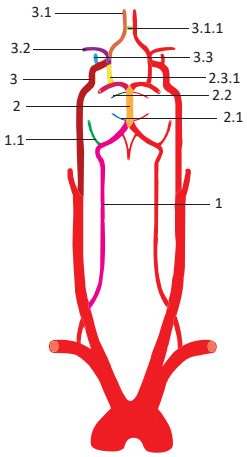

Describe the arteries of the brain and spinal cord

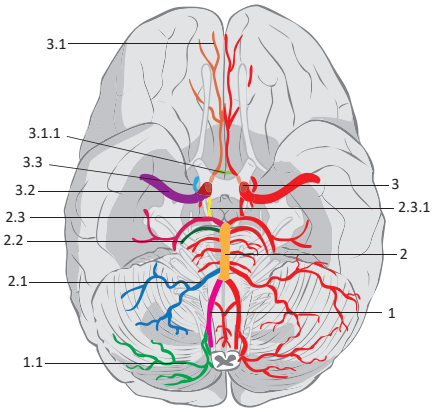

Describe the arteries of the brain and spinal cord

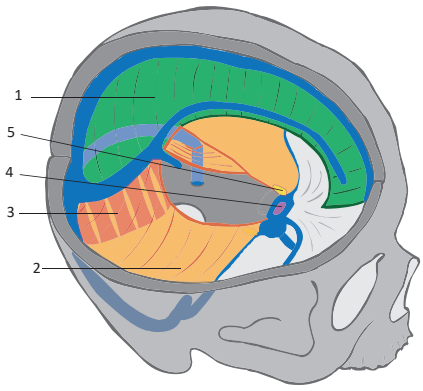

Describe the duplicatures of the dura mater

This copy belongs to ali yaghoubi

We would like to **thank the following anatomists, clinicians and medical students** for their invaluable help, devotion and feedback in the preparation of this chapter.

Anatomists

Assoc. prof. Václav Báča, MD, PhD – Department of Anatomy, Third Faculty of Medicine, Prague, Czech Republic
Prof. Hans J. Ten Donkelaar, MD, PhD – Radboud University Nijmegen Medical Center, Nijmegen, Netherlands
Prof. Darina Kluchová, MD, PhD – Department of Anatomy, Pavol Jozef Šafárik University, Košice, Slovakia
Assoc. prof. Ayhan Cömert, MD – Ankara Üniversitesi Tıp Fakültesi Anatomi Anabilim Dalı, Turkey

Clinicians

Prof. Robert Kuba, MD, PhD – First Department of Neurology, St. Anne's Faculty Hospital, Brno, Czech Republic
Marek Čierný, MD – Neurology Department, University Hospital and Masaryk University in Brno
Aravind Ganesh, MD – Department of Neurology, Foothills Medical Centre and University of Calgary, Calgary, Canada

Medical students

Linda Kašičková
Shannon Motsuka, MSc.
Daniel Slovák
Maxwell Cameron

References

1. DONKELAAR, H. Clinical neuroanatomy: brain circuitry and its disorders. Berlin: Springer, 2011. 834 p. ISBN 978-3-642-19134-3.
2. FIX, J. D. High-yield neuroanatomy. 4th Ed. Philadelphia: Lippincot Williams & Wilkins, 2009. 160 p. ISBN 978-0-7817-7946-3.
3. KIERNAN, J. and N. RAJAKUMAR. Barr's the human nervous system: an anatomical viewpoint. 10th Ed. Philadelphia: Lippincott Williams & Wilkins, 2014. 448 p. ISBN 978-1-4511-7327-7.
4. KOUKOLÍK, F. and L. HOUDEK. Lidský mozek. 3rd ed. Praha: Galén, 2012. 400 p. ISBN 9788072627714.
5. LANZ, T. and W. WACHSMUTH. Praktische Anatomie. 7 bands. Berlin: Springer, 2003, 3658 p. ISBN 978-3-540-40571-9.
6. MILLS, S. E. Histology for pathologists. 4th Ed. Philadelphia: Lippincot Williams & Wilkins, 2012. 1328 p. ISBN-13: 978-1-4511-1303-7.
7. MOORE, K. L.; DALLEY, A. F. and A. AGUR. Clinically oriented anatomy. 7th Ed. Philadelphia: Lippincot Williams & Wilkins, 2014. 1139 p. ISBN 978-1-4511-1945-3.
8. NETTER, F. H. Atlas of Human Anatomy. Professional Edition. 6th Ed. Oxford: Elsevier. 2014. 640 p. ISBN 978-1-455-75888-3.
9. NIEUWENHUYS, R.; VOOGD, J. and C. HUIJZEN. The human central nervous system: A Synopsis and Atlas. 4th Ed. Berlin: Springer, 2007. 967 p. ISBN 978-3-540-34684-5.
10. NOLTE, J: Nolte's The Human Brain: An Introduction to its Functional Anatomy With Student Consult Online Access. 6th Ed. Philadelphia: Mosby/Elsevier, 2008, 79 p. ISBN 978-0-323-04131-7.
11. OVALLE, W. K. and P. C. NAHIRNEY. Netter's Essential Histology: with Student Consult Access. 2nd Ed. Philadelphia: Saunders/Elsevier, 2013. 493 p. ISBN-13: 978-1-4557-0631-0.
12. ROHEN, J. W. LUTJEN-DRECOLL, E. and C. YOKOCHI. Color Atlas of Anatomy: A Photographic Study of the Human Body. 7th Ed. Stuttgart: Lippincot Williams & Wilkins, 532 p. ISBN 978-1-58255-856-1.
13. ROWLAND, L. P. and T. A. PEDLEY. Merritt's neurology. 12th Edition. Philadelphia: Lippincot Williams & Wilkins , 2010. 1216 p. ISBN 978-0-7817-9186-1.
14. SNELL, R. S. Clinical Neuroanatomy. 7th Edition. Philadelphia: Lippincot Williams & Wilkins, 2009, 560 p. ISBN 978-0-7817-9427-5.
15. WILLIAMS, P. L., ed. Gray´s Anatomy: the anatomical basis of medicine and surgery. 38th Ed. New York: Churchill Livingstone, 1995, 2092 p. ISBN 0-443-05717-6.

Memorix Anatomy

13 Senses and skin

David Kachlík
Radovan Hudák
Ondřej Volný
Adam Whitley



Senses	502
Internal environment – Interoceptors	502
Olfactory organ	503
Gustatory organ	503
Organ of hearing and balance	504
Visual organ	508
Touch, pain, proprioception	514
Skin / Integument	515
Breast and mammary gland	517
Review questions and figures	518
Acknowledgements and references	520

This copy belongs to ali yaghoubi

A **sense** is the ability of an organism to **accept and interpret signals from the the external or internal environment**. **Exteroceptors** detect signals from the **external environment**, such as the concentration of certain chemical substances in a medium, light and vibration of particles in air. Exteroceptors provide the senses of smell, taste, vision, hearing, touch and pain. **Interoceptors** monitor the internal environment of the organism. They include osmoreceptors, chemoreceptors, baroreceptors and proprioceptors and pain and tactile receptors located within internal organs, muscles, fasciae and vessels. **The perception of balance** requires signals from both exteroceptors (in the vestibular organ) and interoceptors (proprioceptors providing information on the position of the body).

Senses and their organs

1 **Vision** – eye
2 **Hearing** – outer, middle and inner ears
3 **Balance** – inner ear
4 **Taste** – tongue, palate
5 **Touch, pain, proprioception** – skin, muscles
6 **Internal environment** – organs, fasciae

1.1 Internal environment – Interoceptors

In contrast with exteroceptors, **interoceptors monitor the internal environment of an organism**. They include: **chemoreceptors** that monitor the blood acidity (pH) and the level of blood oxygen and carbon dioxide, **osmoreceptors** that monitor the osmotic pressure of blood and **baroreceptors** that monitor blood pressure. In a broader sense, interoceptors include receptors of proprioception, which provide information on the position of the body and touch and pain receptors in the internal organs, muscles, fasciae and vessels.

1 **Chemoreceptors**
- 1.1 **Carotid body** (*glomus caroticum*)
  – is located at the carotid bifurcation
  – monitors the blood oxygen level
- 1.2 **Area postrema**
  – is located on the floor of the fourth ventricle
  – monitors blood pH

2 **Osmoreceptors**
- 2.1 **Vascular organ of lamina terminalis** (*organum vasculosum laminae terminalis*)
  – is located on the rostral wall of the third ventricle
  – monitors the osmolality of plasma
- 2.2 **Supraoptic and paraventricular nuclei of hypothalamus** (*nucleus supraopticus et paraventricularis hypothalami*)
  – are located inside the hypothalamus
  – monitor the osmolality of plasma

3 **Baroreceptors**
- 3.1 **Carotid sinus** (*sinus caroticus*)
  – is located at the beginning of the internal carotid artery
- 3.2 **Paraaortic bodies** (*corpora aortica / glomera aortica*)
  – are located within the aortic arch
- 3.3 **Atrial baroreceptors / atrial volume receptors**
  – are located within the wall of the right atrium

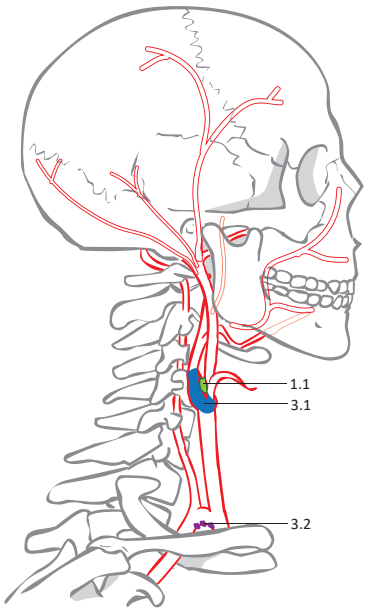

Senses and skin

The olfactory part of the nasal mucosa occupies an area of approximately 5cm².

The vomeronasal organ / Jacobson's organ *(organum vomeronasale)* is a rudimentary organ on the inferior and anterior margin of the nasal septum. It is a chemosensory organ for pheromones.

Around 5000 taste buds are present on the mucosa of the tongue. The majority of them are located within the vallate papillae (250 on each vallate papilla) and the foliate papillae. A few are situated in the fungiform papillae.

Umami is a Japanese term meaning palatable or delicious. The taste of unami is mediated by natrium glutamate.

The supraoptic and paraventricular nuclei of the hypothalamus contain osmoreceptors. Their stimulation evokes the feeling of thirst and the secretion of antidiuretic hormone.

Olfaction is closely related to taste perception. Receptors of these senses are rather similar. These senses are fused in lower animal species.

Clinical notes

Objective olfactometry is an examination in which individual smells are tested with one nostril and both eyes closed. A reduced perception of olfaction is termed hyposmia and an elevated perception of smell is called hyperosmia. An abnormal sensation of smell is termed parosmia. An inappropriate smell of faeces is called cacosmia.

The olfactory part of the nasal mucosa (*regio olfactoria*) is located on the **roof of the nasal cavity, the nasal septum and the superior nasal concha**. Olfactory mucosa is composed of **olfactory cells and glands**. The sense of olfaction (smell) is perceived by the detection of chemicals dissolved in air or fluid (usually at low concentrations).

Structures

- 1 **Olfactory part of nasal mucosa** – specialised olfactory epithelium
- 2 **Olfactory cells** – bipolar neurons
- 3 **Olfactory nerves** (*fila olfactoria*) – bundles of axons from the olfactory cells passing through the cribriform plate (*lamina cribrosa ossis ethmoidalis*) to the olfactory bulb
  - 3.1 **Olfactory bulb** (*bulbus olfactorius*) – location of synapses between the olfactory nerves with the 2nd order neurons of the olfactory pathway
- 4 **Olfactory glands / glands of Bowman** (*glandulae olfactoriae*) – produce mucus that covers the olfactory mucosa – are able to concentrate and dissolve the chemicals that are perceived in the sense of olfaction
- 5 **Basal epithelial cells** – stem cells which differentiate into olfactory cells
- 6 **Supporting epithelial cells** – tall cells located between the olfactory cells

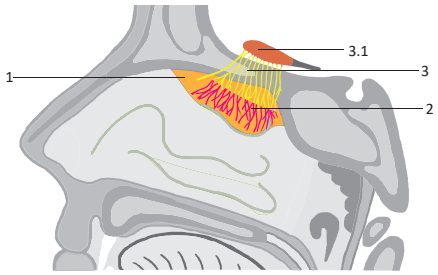

Sagittal section of the nasal cavity showing the olfactory part of the nasal mucosa

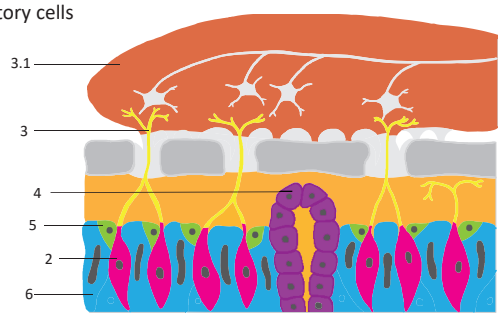

The olfactory mucosa and nerve in detail

Taste buds are the **receptor cells** of the gustatory organ. The majority of the taste buds are situated in the **mucosa of** the **lingual vallate papillae**. However, they are also found in the mucosa of the soft palate, posterior wall of the pharynx, glosso-epiglottic folds and epiglottis. Free nerve endings can also operate as gustatory receptors. **Five principal types of taste** are distinguished: sweet, salty, acid, bitter and umami. Each taste bud is able to perceive each type of taste individually and in combinations.

Structures

- 1 **Vallate papilla** (*papilla vallata*)
  - 1.1 **Vallum of papilla** (*vallum papillae*) – the external wall (similar to a rampart)
  - 1.2 **Groove of papilla** (sulcus papillae) – its walls contain the taste buds and orifices of serous salivary glands opening to the base
- 2 **Taste bud** (*gemma gustatoria / caliculus gustatorius*)
  - 2.1 **Taste pore** (*porus gustatorius*) – a superficial pit over the taste bud
- 3 **Gustatory glands / von Ebner's glands** (*glandulae gustatoriae*) – small serous salivary glands – produce saliva that dissolves the chemicals of taste and rinses the taste buds



A section through the vallate papillae

Innervation

- **VII Chorda tympani** – provides taste for the dorsum of the tongue – a branch from the facial nerve – its impulses travel partially together with the lingual nerve to the tongue
- **IX Glossopharyngeal nerve** – povides taste for the root of the tongue and vallate papillae
- **X Vagus nerve** – provides taste for the epiglottic valleculae

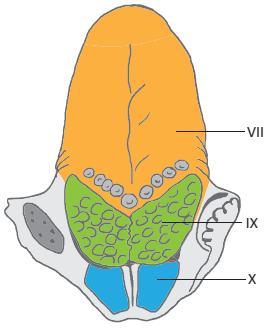

Sensory innervation of the tongue

This copy belongs to ali yaghoubi

The **ear** (**auris**) is a complex sensory organ. It is divided into three parts: the external ear, middle ear and internal ear. The **external ear** consists of the auricle, the external acoustic meatus, and the tympanic membrane. The **middle ear** consists of the tympanic cavity, which houses the tympanic membrane and auditory ossicles. The **internal ear** consists of the bony and membranous labyrinths. All three parts of the ear are involved in the perception of sound. The perception of balance, position and angular movements of the head are all functions of the vestibulum in the inner ear.

Principal parts of the ear

1 **External ear** (*auris externa*)
- 1.1 **Auricle/pinna** (*auricula*)
- 1.2 **External acoustic meatus** (*meatus acusticus externus*)
- 1.3 **Tympanic membrane** (*membrana tympanica*)

2 **Middle ear** (*auris media*)
- 2.1 **Tympanic cavity** (*cavitas tympani*)
- 2.2 **Auditory ossicles** (*ossicula auditus*)
- 2.3 **Pharyngotympanic tube / auditory tube / Eustachian tube** (*tuba auditiva*)

3 **Internal ear** (*auris interna*) – consists of the bony and membranous labyrinth
- 3.1 **Cochlear part** – consists of the bony and membranous cochlea
- 3.2 **Vestibular part** – consists of the vestibule containing the utricle and saccule and three semicircular canals containing the three semicircular ducts
- 3.3 **Internal acoustic meatus** (*meatus acusticus internus*)
- 3.4 **Vestibulocochlear nerve** (*nervus vestibulocochlearis, n. VIII*)

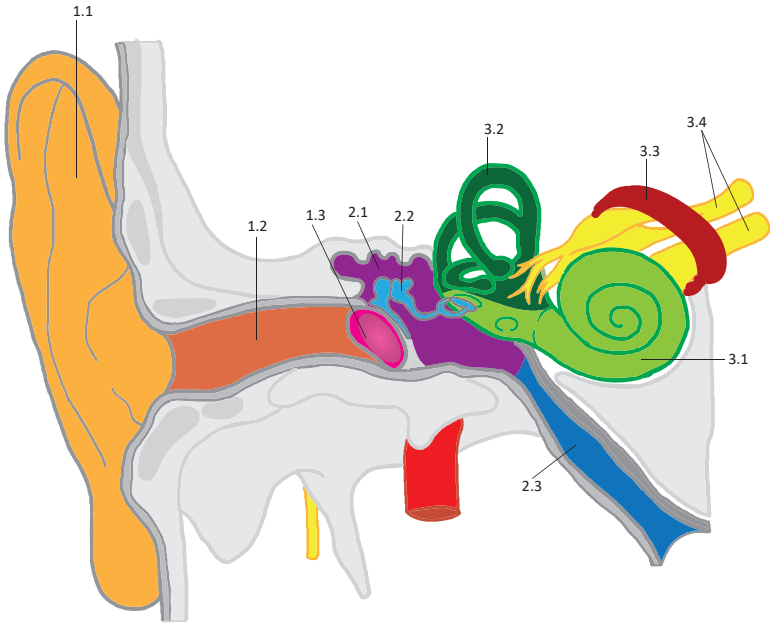

Frontal section of the principal parts of the ear

The ear is called **us (otos)** in Greek.

The intrinsic muscles of the external ear are rudimentary in humans. This group of muscles includes the tragicus, antitragicus, helicis major, helicis minor, oblique muscle of the auricle *(m. obliquus auriculae),* transverse muscle of the auricle *(m. transverses auriculae*) and the pyramidal muscle of the auricle *(m. pyramidalis auriculae)*. All are innervated by the facial nerve.

Hairs of the tragus *(tragi)* are hairs growing in the external acoustic meatus after the 30th year of age.

Dimensions and positions of the tympanic membrane (approximately)
– **size**: 9x10 mm
– **thickness**: 0,1 mm
– **surface**: 55 mm^2
– **declination**:
50° in the sagittal plane
– **inclination**:
45° in the transverse plane

The clinical synonyms for the light reflex in the otoscopic examination are: cone of light, light reflex, Politzer's luminous cone, red reflex and Wilde's triangle.

The flaccid part / Shrapnell membrane *(pars flaccida)* is a part of the tympanic membrane, 5 mm^2 large, located between the anterior and posterior mallear folds.

Clinical notes

Othematoma is a haematoma of the auricle located between the skin and elastic cartilage of the auricle accompanied with oedema.

The dorsocaudal part of the external acoustic meatus is innervated by the vagus nerve (auricular branch). This area is called the zone of Ramsay-Hunt. In herpes zoster infection, blisters can appear in this zone (herpes zoster oticus).

Bezold's triad of the tympanic membrane:
– mallear prominence
– mallear stria
– light reflex

Otitis media / mesotitis is term that refers to inflammation of the middle ear. Its treatment can involve myringotomy, which is an incision of the tympanic membrane (a form of paracentesis). The incision is made in the lower posterior quadrant as no anatomical structures are located in this region and so the risks of complications are minimal.

External ear

Auricle/pinna (*auricula*)

– is composed of elastic cartilage and skin adhering to the underlying perichodrium (firmly on the ventral surface and loosely on the dorsal surface)

Parts:

- 1 **Helix** – an elevated arched margin of the auricle located on the dorsal and cranial aspect
- 2 **Antihelix** – an elevated eminence of cartilage, located ventral to the helix,
  – bifurcates ventrocranially into the the two crura (limbs) of the antihelix (*crura antihelicis*)
- 3 **Scapha** – a narrow groove between the helix and antihelix on the anterior surface of the auricle
- 4 **Concha of auricle** (*concha auriculae*) – a depression on the anterior surface of the auricle
  – its upper part (cymba conchae) is located between the helix and antihelix
  – its inferior part (cavity of concha) serves as the entrance of the external acoustic meatus
- 5 **Tragus** – a process in front of the concha that partially covers the entrance of the external acoustic meatus
- 6 **Antitragus** – a process below the concha facing the tragus
  – partially covers the entrance of the external acoustic meatus
- 7 **Intertragic notch** (*incisura intertragica*) – a notch between the tragus and antitragus
- 8 **Lobule of auricle** (*lobulus auriculae*) – the earlobe, does not contain cartilage

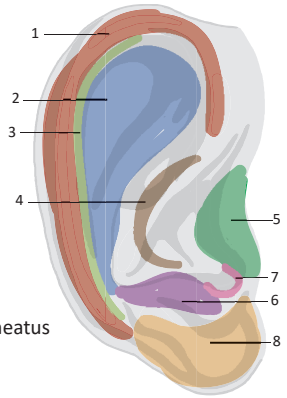

Parts of the auricle

Ligaments: anterior, superior and posterior ligaments of the auricle (*lig. auriculare anterius, superius, posterius*)

Muscles: auricularis anterior, superior and posterior and temporoparietalis

Motor innervation: facial nerve

Sensory innervation:

- 1 **Superior anterior two thirds** – anterior auricular branches of auriculotemporal nerve
- 2 **Superior posterior** – lesser occipital nerve
- 3 **Concha of auricle** – auricular branch of vagus nerve
- 4 **Inferior** – great auricular nerve

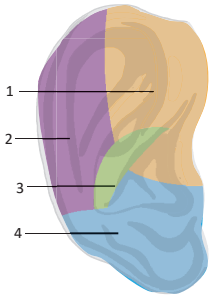

Somatosensory innervation of the auricle

External acoustic meatus (*meatus acusticus externus*)

– has a waved shape, runs ventromedially, then medially and then again ventromedially
– both meati are directed ventrally (at an angle of 160°) and caudally (cranially convex)
– has a length of approximately 22 mm
– the anterior wall is in close proximity to the parotid gland and temporomandibular joint

Parts:

- 1 **External acoustic pore / aperture** (*porus acusticus externus*)
- 2 **Cartilaginous external acoustic meatus** (*meatus acusticus externus cartilaginous*)
  – the external cartilaginous 2/3 of the meatus
  – hyaline cartilage opens ventrally with the tragal lamina (*lamina tragi*) and caudally through the notches of Santorini (*incisurae*)
  – the skin of the meatus is firmly attached to the perichondrium
  – the most narrow spot is at the transition of the bony part to the cartilaginous part (the *isthmus*), foreign bodies can get stuck here
- 3 **Bony external acoustic meatus** (*meatus acusticus externus osseus*)
  – the internal bony 1/3 of the meatus
  - 3.1 **Tympanic sulcus and notch** (*sulcus tympanicus et incisura tympanica*)
    – a circular groove with a cranial notch
  4 **Ceruminous glands** (*glandulae ceruminosae*) – apocrine glands
  – produce cerumen, which has a protective function

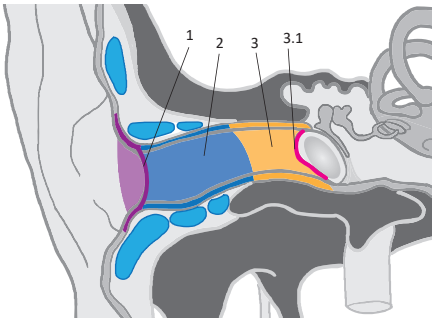

Frontal section of the external acoustic meatus

Sensory innervation:

1 **Auricular branch of vagus nerve**

2 **Nerve to external acoustic meatus** (*n. meatus acustici externi*) from the auriculotemporal nerve

Tympanic membrane / eardrum (*membrana tympanica / myrinx*)

– a thin fibrous plate inserted in the tympanic sulcus and notch
– has a thickened margin called the fibrocartilaginous ring (*anulus fibrocartilagineus*)

Otoscopic view – a view of the tympanic membrane from the external acoustic meatus

- 1 **Umbo of tympanic membrane** (*umbo membranae tympanicae*)
  – a convex centre elevated by the tip of the handle of the malleus
- 2 **Mallear stria** (*stria mallearis*) – a fibrous band elevated by the handle of the malleus
- 3 **Mallear prominence** (prominetia mallearis) – is located cranially on the tympanic membrane
  – an elevation formed by the lateral process of the malleus
- 4 **Anterior and posterior mallear fold** (*plica mallearis anterior et posterior*)
  – folds of mucosa stretched between the mallear prominence and encompassing the pars flaccida
- 5 **Light reflex** – an area of reflected light on the inferior posterior quadrant of the tympanic membrane
- 6 **Pars tensa** – a large, tended part of the tympanic membrane
- 7 **Pars flaccida of Shrapnell** – an upper, relaxed small part of the tympanic membrane, located cranially between the mallear folds

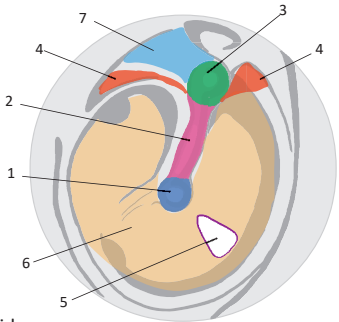

Otoscopic view of the right tympanic membrane

This copy belongs to ali yaghoubi

Middle ear (*auris media*)

Tympanic cavity (*cavitas tympani*)

Borders and structures:

1 **Lateral wall / membranous wall** (*paries membranaceus*): the tympanic membrane

2 **Medial wall / labyrinthine wall** (*paries labyrinthicus*):
- 2.1 **Promontory** (*promontorium*) – an elevation formed by the cochlea of the inner ear
- 2.2 **Oval window** (*fenestra vestibuli*) – connects to the base of the stapes – the attachement of the anular ligament of the stapes (*ligamentum anulare stapediale*)
- 2.3 **Round window** (*fenestra cochleae*) – is closed by the secondary tympanic membrane

3 **Roof / tegmental wall** (*paries tegmentalis*)

4 **Floor / jugular wall** (*paries jugularis*)
- 4.1 **Tympanic canaliculus** (*canaliculus tympanicus*) – contains the tympanic nerve and anterior tympanic vessels

5 **Posterior wall – mastoid wall** (*paries mastoideus*)
- 5.1 **Aditus to mastoid antrum** (*aditus ad antrum mastoideum*) – the entrance to the mastoid cells
- 5.2 **Prominence of lateral semicircular canal** (*prominentia canalis semicircularis lateralis*) – an elevation formed by the lateral semicircular canal of the inner ear
- 5.3 **Prominence of facial canal** (*prominetia canalis n. facialis*) – an elevation formed by the second bend of the facial canal
- 5.4 **Pyramidal eminence** (*eminentia pyramidalis*) – a conical bony prominence – contains the stapedius
- 5.5 **Canaliculus for chorda tympani** (*canaliculus chordae tympani*) – a some bony canal for the chorda tympani and posterior tympanic vessels

6 **Anterior wall / carotid wall** (*paries caroticus*)
- 6.1 **Musculotubal canal** (*canalis musculotubarius*) – a bony canal divided by a septum into:
  - 6.1.1 **Canal for tensor tympani** (*semicanalis m. tensoris tympani*) – cranial half canal, tensor tympani inserts onto the malleus handle of the malleus
  - 6.1.2 **Canal for auditory tube** (*semicanalis tubae auditivae*) – caudal half canal, an air communication between the tympanic cavity and nasopharynx
- 6.2 **Petrotympanic fissure** (*fissura petrotympanica*) – contains the chorda tympani, anterior mallear ligament of the malleus and anterior tympanic vessels
- 6.3 **Canal for lesser petrosal nerve** (*canalis nervi petrosi minoris*) – contains the lesser petrosal nerve (n. IX) and superior tympanic vessels
- 6.4 **Caroticotympanic canaliculi** (*canaliculi caroticotympanici*) – contains homonymous arteries and sympathetic nerves

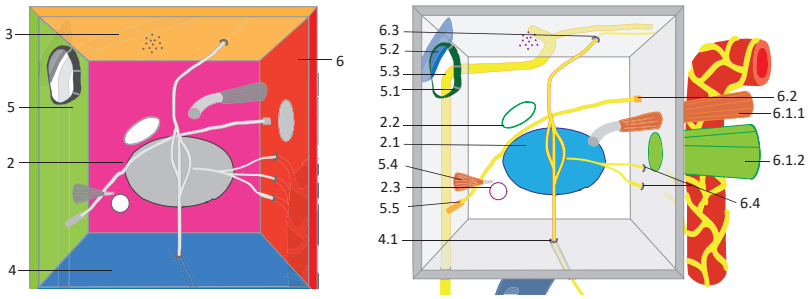

Scheme of the tympanic cavity: lateral view after removal of the tympanic membrane

Auditory ossicles (*ossicula auditus*)

1 **Malleus** – the hammer
- 1.1 **Handle of malleus** (*manubrium mallei*)
- 1.2 **Head of malleus** (*caput mallei*)
  - 1.2.1 **Anterior and lateral processes** (*processus anterior et lateralis*)
- 1.3 **Neck of malleus** (*collum mallei*)

2 **Incus** – the anvil
- 2.1 **Body of incus** (*corpus incudis*)
- 2.2 **Short limb** (*crus breve*)
- 2.3 **Long limb** (*crus longum*)
- 2.4 **Lenticular process** (*processus lenticularis*)

3 **Stapes** – the stirrup
- 3.1 **Head of stapes** (*caput stapedis*)
- 3.2 **Anterior and posterior limbs** (*crus anterius et posterius*)
- 3.3 **Base of stapes, Footplate** (*basis stapedis*)

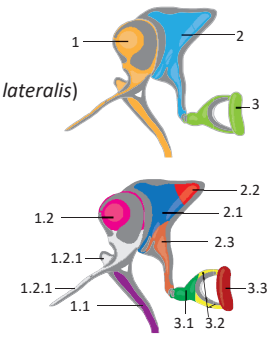

The auditory tube / Eustachian tube has two parts: a lateral bony part and a medial cartilaginous part. Its function is to equalise the air pressure between the pharynx and tympanic cavity. The auditory tube is more horizontal, shorter and wider in children.

The tympanic cavity has a sand-glass shape extending in the epitympanium and caudally as the hypotympanic recess.

The epitympanic recess / attic *(epitympanum / epitympanon / atticus)* is the cranial extension of the tympanic cavity above the upper margin of the tympanic membrane containing the head of the malleus and body of the incus. It can be approached from outside via a bony wall called the scutum.

Muscles of the tympanic cavity:
1 **Stapedius**: innervated by the facial nerve
2 **Tensor tympani:** innervated by the trigeminal nerve

Endolymph is produced in the stria vascularis, flows into the membranous labyrinth and drains via the endolymphatic duct inside the vestibular canaliculus to the endolymphatic sac, where it is absorbed into the venous blood.
Perilymph fills the bony labyrinth.

Arterial supply of the internal ear: labyrinthine artery (from the anterior inferior cerebellar artery).
Venous drainage of the internal ear: labyrinthine veins, vein of the vestibular aqueduct, vein of the cochlear aqueduct (into the inferior petrosal sinus).

Clinical points

Otorrhea is secretion from the ear.

Otitis media / mesotitis is the most common disease of the middle ear. It is a septic inflammation that occurs most commonly in infants and toddlers. It presents with a painful ear, headache, and even a perforated eardrum.

Otosclerosis is characterised by excessive ossification around the middle ear. In adulthood, ossification can involve the oval window and anular ligament of the stapes and the tympanostapedial syndesmosis can change into a synostosis. The stapes loses its ability to move within the oval window resulting in an impairment of hearing.

Hypertrophy of the pharyngeal tonsil can affect ventilation in the tympanic cavity, predisposing to secondary chronic mesotitis.

Internal ear / vestibulocochelar organ (*auris interna / organum vestibulocochleare*)

Osseous labyrinth (*labyrinthus osseus*)

- 1 **Vestibule** (*vestibulum*)
  - 1.1 **Oval window** (*fenestra vestibuli*)
  - 1.2 **Elliptical and spherical recess** (*recessus ellipticus et sphericus maculae cribrosae*)
  - 1.3 **Internal opening of vestibular canaliculus** (*apertura interna canaliculi vestibuli*)
- 2 **Semicircular canals** (*canales semicirculares*) – consist of the bony, ampulla and limb
  - 2.1 **Anterior semicircular canal** (*canalis semicircularis anterior*)
    – perpendicular to the long axis of the petrous part of the temporal bone
    - 2.1.1 **Common bony limb** (*crus osseum commune*)
      – a common limb for the anterior and posterior semicircular canals
  - 2.2 **Posterior semicircular canal** (*canalis semicircularis posterior*
    – is parallel to the long axis of the petrous part of the temporal bone
  - 2.3 **Lateral semicircular canal** (*canalis semicircularis lateralis*) – oriented 30° to the horizontal plane and contains the simplex bony limb (*crus osseum simplex*)
- 3 **Cochlea** – cupula and basis of the cochlea (2 ¾ of the cochlea threads)
  - 3.1 **Round window** (*fenestra cochleae*)
  - 3.2 **Scala vestibuli**
  - 3.3 **Helicotrema** – a narrow transition from the scala vestibuli to the scala tympani in the cochlear cupula
  - 3.4 **Scala tympani**
  - 3.5 **Osseous spiral lamina** (*lamina spiralis ossea*)
    – a bony crest projecting into the spiral canal of the cochlea
  - 3.6 **Internal opening of cochlear canaliculus** (*apertura interna canaliculi cochleae*)
  - 3.7 **Modiolus** – is located within the spiral canal (*canalis spiralis modioli*)
    – contains the cochlear ganglion and longitudinal canals
- 4 **Internal acoustic meatus** (*meatus acusticus internus*)
- 5 **Perilymphatic space** (*spatium perilymphaticum*)

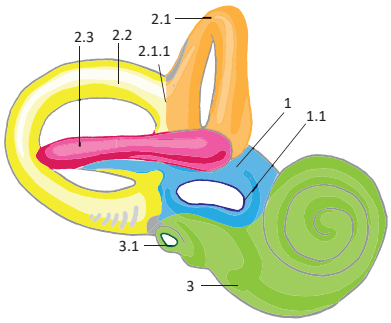

Lateral view of the osseous labyrinth

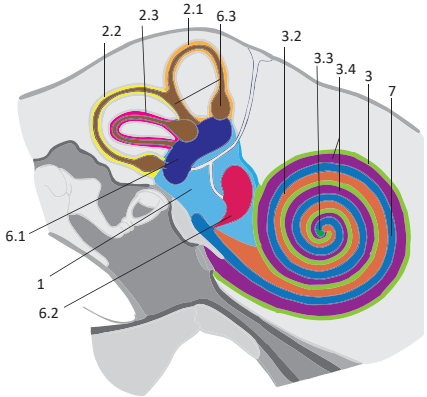

Section of the inner ear

Membranous labyrinth (*labyrinthus membranaceus*)

– surrounds the endolymphatic space (*spatium endolymphaticum*)

- 6 **Vestibular labyrinth** (*labyrinthus vestibularis*)
  - 6.1 **Utricle** (*utriculus*) – contains the macula of utricle, which is composed of the otolithic membrane (*membranae statoconiorum*) resting on top of special sensory cells
    – otolithic membranes contains otoliths (*otoconia*), which are crystals of $CaCO_3$ is responsible for the perception of linear horizontal movements
  - 6.2 **Saccule** (*sacculus*) – contains the macula of the saccule
    – is responsible for the perception of linear vertical movements
  - 6.3 **Anterior, lateral and posterior semicircular ducts** (*ductus semicircularis anterior, lateralis, posterior*)
    – contain ampullar crests (*cristae ampullares*) with the ampullar cupula (*cupula ampullaris*)
    – are responsible for perception of acceleration, deceleration and rotational movements of the head
- 7 **Cochlear labyrinth** (*labyrinthus cochlearis*) – scala media, cochlear duct (*ductus cochlearis*)
  - 7.1 **Vestibular surface / Reissner's membrane** (*paries / membrana vestibularis*)
  - 7.2 **External surface** (*paries externus*) – stria vascularis, spiral prominence, vas prominens (production of endolymph)
  - 7.3 **Tympanic surface, spiral membrane** (*paries tympanicus, membrana spiralis*)
    – its fibrous part is the basilar membrane (*lamina basilaris*)
  - 7.4 **Tectorial membrane** (*membrana tectoria*) – gelatinous tissue surrounding the hair of sensory cells (cochlear hair cells)
  - 7.5 **Spiral organ of Corti** (*organum spirale*) – the proper auditory organ (contains sensory cochlear hair cells)

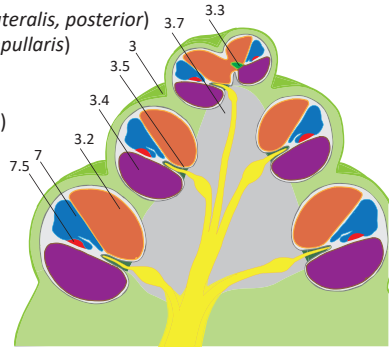

Section of the bony labyrinth

Internal acoustic meatus (*meatus acusticus internus*)

- 1 **Internal acoustic opening** (*porus acusticus internus*)
- 2 **Fundus of internal acoustic meatus** (*fundus meatus acustici interni*)
  - 2.1 **Transverse crest** (*crista transversa*)
  - 2.2 **Vertical crest** (*crista verticalis*)
- 3 **Passage for the facial and vestibulocochlear nerves and labyrinthine vessels**
  - 3.1 **Facial area** (*area n. facialis*) – facial nerve
  - 3.2 **Cochlear nerve** (*area cochlearis*) – tractus spiralis foraminosus – cochlear nerve
  - 3.3 **Superior vestibular area** (*area vestibularis superior*) – utriculo-ampullary nerve
  - 3.4 **Inferior vestibular area** (*area vestibularis inferior*) – saccular nerve
  - 3.5 **Foramen singulare** – posterior ampullary nerve

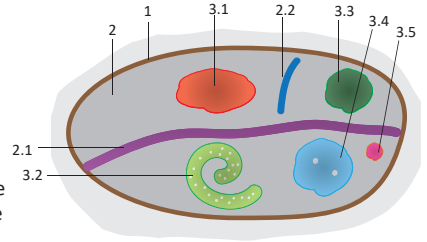

Fundus of the right internal acoustic meatus, medial view

This copy belongs to ali yaghoubi

The organ of vision is the **eyeball, which is located inside the orbit**. The eyeball is almost spherical and can be likened to two unequal hemispheres, one inside the other. The bigger hemispheres is the **sclera** (radius 12mm) and the smaller hemisphere is the **cornea** (radius 8mm). The eyeball houses the biconvex lens and contains three chambers: the **anterior and posterior chambers** filled with aqueous humour and the **postremal chamber** filled with the vitreous body. The **accessory structures of the eye** include the eyelids, eyebrows, lacrimal apparatus, conjunctiva and the extra-ocular muscles.

Eyeball (*bulbus oculi*)

- 1 **Anterior pole** (*polus anterior*)
- 2 **Posterior pole** (*polus posterior*)
- 3 **Meridians** (*meridiani*)
- 4 **Equator**
- 5 **Optic axis** (*axis opticus*) – connects the anterior and posterior poles of the eyeball
- 6 **Visual axis** (*linea visus*) – connects the centre of the viewed object to the macula
  - 6.1 **Macula** (*macula lutea*)
    - – the area of highest visual acuity
    - – located temporal to the optic axis
- 7 **Optic disc** (*discus nervi optici*)
  - – the area where the optic nerve leaves the eyeball

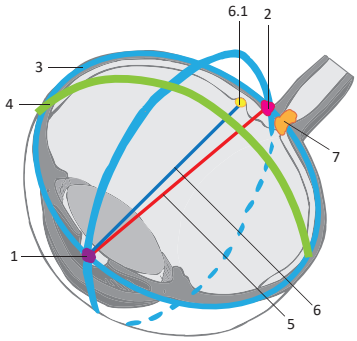

Eyeball with orientation points and lines

Basic parts of the eyeball

Layers of the eyeball

1 **Fibrous layer of eyeball** (*tunica fibrosa bulbi*) – the outer layer
- 1.1 **Sclera**
- 1.2 **Cornea**

2 **Vascular layer of eyeball** (*tunica vasculosa bulbi / uvea*) – the middle layer
- 2.1 **Choroid** (*choroidea*)
- 2.2 **Ciliary body** (*corpus ciliare*)
- 2.3 **Iris**
  - 2.3.1 **Pupil** (*papilla*)

3 **Inner layer of eyeball** (*tunica interna bulbi / retina*) – the nervous layer
- 3.1 **Optic part of retina** (*pars optica*) – contains photoreceptors
- 3.2 **Nonvisual retina** (*pars caeca*) – a blind part of retina, not containing any photoreceptors

Contents of the eyeball

- 4 **Vitreous body** (*corpus vitreum*)
- 5 **Lens**
- 6 **Chambers of eyeball** (*camerae bulbi*)

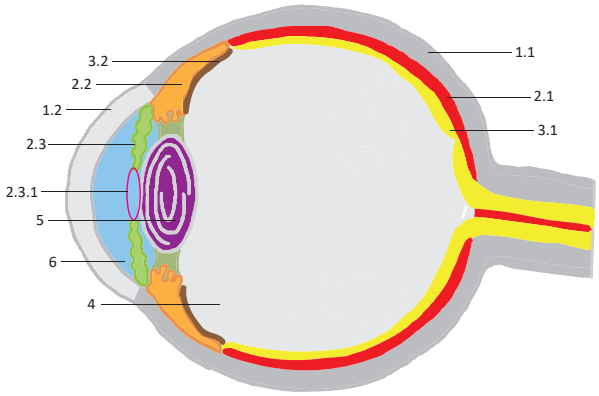

Sagittal section of the eyeball

The eyeball is approximately 25 mm long in its ventrodorsal dimension and 23.5 mm high in its craniocaudal dimension.

Ophthalmos is the Greek term for eye.
Keras (keratos) is the Greek term for cornea.
Koré is the Greek term for pupil.
Fakos is the Greek term for lens.

The pupil is analogous in function to the lens hood of a camera.

Isocoria means symmetrical pupils.
Anisocoria means asymmetrical pupils (one is wider than the other).

Bruch's membrane *(complexus basalis)* is composed of five layers. From outside to inside, the layers are: the basal lamina of the choriocapillary layer, an outer layer of collagen, a layer of elastic fibres, an inner layer of collagen and the basal lamina of the pigmented epithelium. By means of passive traction on the ciliary body, Bruch's membrane contributes to the flattening of the lens.

The orbit see page 532.

Clinical notes

Keratoplasy usually refers to corneal transplantation. The cornea can be transplanted between two unrelated individuals and is one of the most successful transplantation procedures.

The pupillary light reflex is one of the basic reflexes examined in neurology and acute care.

The direct response is a constriction of the pupil in response to light shone in the ipsilateral eye.

The consensual response is a constriction of a pupil in response to light being shone in the contralateral eye. It is physiological.

The cornea is the most sensitive tissue of the human body. When the cornea is touched, the corneal reflex results in a contraction of the orbicularis oculi causing the eye to blink.

The corneoscleral junction *(corneal limbus / limbus corneae)* is the transition between the cornea and sclera. Hyperemia of this area may signify blood congestion inside the eyeball.

CCT refers to central corneal thickness and is approximately 555 µm at the corneal vertex *(vertex corneae)*. Towards the limbus the thickness of the cornea increases up to 1 mm.

Fibrous layer of eyeball (*tunica fibrosa bulbi*) – outer fibrous layer

Sclera

1 **Trabecular tissue** (*reticulum trabeculare*) – dense connective tissue
2 **Episcleral layer** (*lamina episcleralis*), **substantia propria, suprachoroid lamina** (*lamina fusca*) – layers of the sclera
3 **Lamina cribrosa of sclera** – the exit for the optic nerve
4 **Scleral venous sinus / Schlemm's canal** (*sinus venosus sclerae /canalis Schlemmi*)
5 **Sulcus sclerae** – a groove located at the corneoscleral junction

Cornea

– posseses a physiological astigmatism: the cornea has a vertical diameter of 11mm and a horizontal diameter of 12mm
– has an optical power of ±43 dioptres
– somatosensory innervation is provided by the branches of the ophthalmic nerve
1 **Corneoscleral junction / corneal limbus** (*limbus corneae*)
– a shallow groove at the transition between the sclera and cornea
2 **Corneal vertex** (*vertex corneae*) – the thinnest and ventral-most part of the cornea (555 µm)

Structure

1 **Corneal epithelium** (*epithelium anterius*) – stratified squamous non-keratinising epithelium
– has an extensive regeneration ability (6-day cycle)
2 **Anterior limiting lamina of Bowman** (*lamina limitans anterior*)
3 **Substantia propria** – if injured produces scars, which cause corneal opacity
4 **Posterior limiting lamina / Descemet's membrane** (*lamina limitans posterior*)
5 **Endothelium of anterior chamber** (*epithelium posterius*) – simple flat epithelium

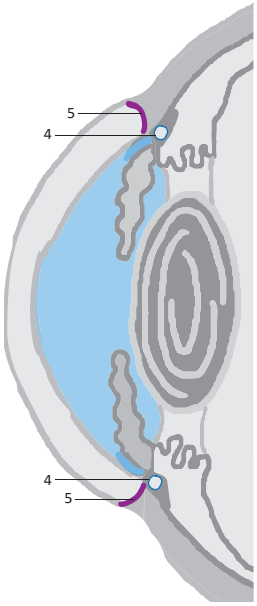

Fibrous layer of the eyeball

Vascular layer of eyeball (*tunica vasculosa bulbi / uvea*) – middle vascular layer

Choroid (*choroidea*)

– provides nutrition to the rods and cones of the retina
– the dark color of blood and the heavy pigmentation form a dark background for the visual receptors
– its elastic tension acts to slightly flatten the lens and so ensures that the lens can focus on distant objects in resting state
– **layers of the choroid:** suprachoroid lamina (*lamina suprachoroidea, lamina fusca sclerae*), perichoroidal space (*spatium perichoroideum*), vascular lamina (*lamina vasculosa*), capillary lamina (*lamina choroidocapillaris*), basal complex / Bruch's membrane *(complexus basalis*)

Ciliary body (*corpus ciliare*)

– produces aqueous humor, forms a muscular ring that is triangular in shape on cross-section
1 **Ciliary ring** (*orbiculus ciliaris / pars plana / anulus ciliaris*) – the outer non-folded pigmented part
2 **Corona ciliaris** / ciliary crown (*pars plicata*) – the inner folded part with processes
2.1 **Ciliary folds and processes** (*plicae et processus ciliares*) – enlarge the surface of the ciliary body
3 **Ciliary muscle** (*musculus ciliaris*) – smooth muscle
– its contraction relaxes the ciliary zonule, which causes the lens to thicken and focus on near objects
3.1 **Meridional, radial, circular and longitudinal fibres** (*fibrae meridionales, radiales, circulares, longitudinales*)
3.2 **Ciliary zonule of Zinn** (*zonula ciliaris*)
– a complex of the lenticular ligaments that attach to the ciliary body

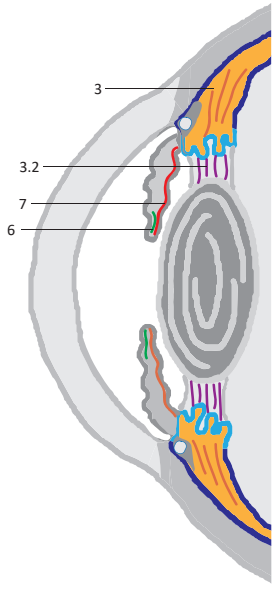

Vascular layer of the eyeball

Iris

– is a muscular ring that is narrow and rectangular in shape on cross-section
– is rich in melanocytes
– the number of melanocytes and amount of melanin determines the colour of the eyes
4 **Ciliary and pupillary margins** (*margo ciliaris et pupillaris*) – the outer and inner margins
5 **Greater and lesser rings of iris** (*anulus iridis major et minor*) – concentric circles on outer surface cover the dilator (greater) and sphincter (lesser) muscles
5.1 **Radial fold** (*plica radians*) – a serrate line on the anterior surface
6 **Sphincter pupillae** (*musculus sphincter pupillae*)
– smooth muscle that constricts the pupil, producing miosis
7 **Dilator pupillae** (*musculus dilatator pupillae*)
– smooth muscle that widens the pupil, producing mydriasis

Pupil (*pupilla*) – a circular opening (2.5 – 4.5 mm) in the middle of the iris
1 **Miosis** – constriction of the pupil in reponse to light
– functions to protect the retina from excessive light
2 **Mydriasis** – dilation of the pupil in response to a lack of light
– increases the amount of light reaching the retina

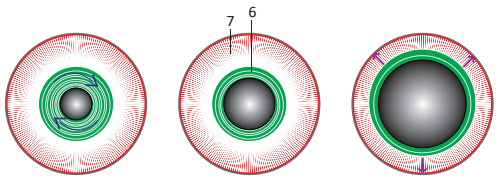

Miosis Normal Mydriasis

This copy belongs to ali yaghoubi

Inner layer of eyeball (*tunica interna bulbi / retina*) – nervous layer

- 1 **Nonvisual retina** (*pars caeca*) – a blind part, not containing any photoreceptors
  - 1.1 **Ciliary and iridial parts of retina** (*pars ciliaris et iridica retinae*)
    - – parts covering the ciliary body and iris
- 2 **Ora serrata** – the border between the nonvisual and optic part
- 3 **Optic part of retina** (*pars optica*) – is composed of 10 layers

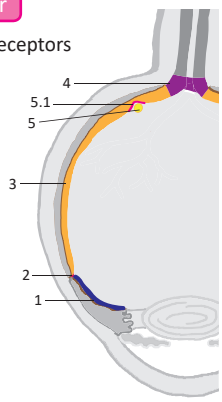

Nervous layer of the eyeball

Optic part of the retina

- 4 **Optic disc** (*discus nervi optici*)
  - – a spot without photoreceptors
  - – the place where the optic nerve leaves the eyeball and the central retinal vessels (*arteria et vena centralis retinae*) enter
- 5 **Macula** (*macula lutea*)
  - – the superficial layers of the retina divert around the macula
  - – the spot of the sharpest visual acuity (macular vision)
  - – located temporal (lateral) to the optic disc
  - 5.1 **Central fovea** (*fovea centralis*)
    - – contains only cones and no rods
- 6 **Pigmented layer** (*stratum pigmentosum*)
- 7 **Neural layer** (*stratum nervosum*)
  - – **photoreceptors – rods and cones** (*neura bacillifera et conifera*)
  - – **transmitting neurons** (retinal bipolar and retinal ganglion cells)
  - – **associative neurons (interneurons)** (horizontal and amacrine cells)
  - – **supporting cells** (radial glial cells, radial cells of Müller)

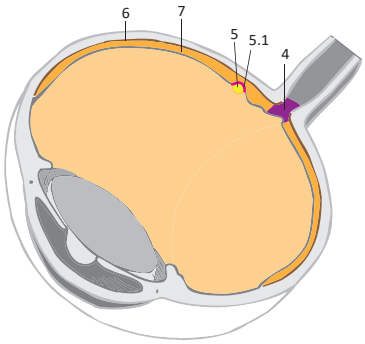

Nervous layer of the eyeball

Layers of the retina:

7.1 **Layer of rods and cones** (*stratum bacillorum conorumque*)
7.2 **Outer limiting membrane** (*stratum limitans externum*)
7.3 **Outer nuclear layer** (*stratum nucleare externum*)
7.4 **Outer plexiform layer** (*stratum plexiforme externum*)
7.5 **Inner nuclear layer** (*stratum nucleare internum*)
7.6 **Outer plexiform layer** (*stratum plexiforme internum*)
7.7 **Ganglionic layer** (*stratum ganglionicum*)
7.8 **Layer of nerve fibers** (*stratum neurofibrarum*)
7.9 **Inner limiting membrane** (*stratum limitans internum*)

Lens

- 1 **Ciliary body** (*corpus ciliare*)
  - – holds the lens in position via the ciliary zonule
  - 1.1 **Ciliary zonule of Zinn** (*zonula ciliaris*)
    - – the suspensory ligaments (apparatus) of the lens that attach it to the ciliary body
  - 1.2 **Ciliary muscle** (*musculus ciliaris*)
    - – is responsible for lens accommodation
- 2 **Capsule of lens** (*capsula lentis*)
  - – a transparent glassy layer of the lens
- 3 **Lens substance** (*substantia lentis*)
  - – consists of the cortex and nucleus

4 **Anterior and posterior poles** (*polus anterior et posterior*)
5 **Axis and equator**

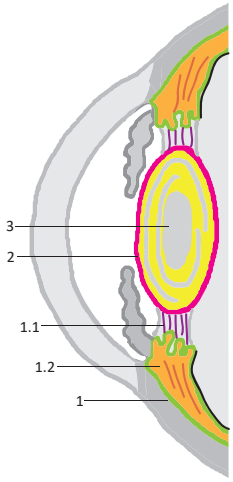

Lens and ciliary body

Vitreous body (*corpus vitreum*)

– transparent noncellular substance, is 98% water like a gel
– is located in the postremal (vitreous) chamber between the posterior surface of the lens and the retina
– is produced prenatally with no ability of regeneration
– when injured, it leaks out and is replaced with aqueous humour

The optic papilla *(papilla nervi optici)* is a clinical term for the optic disc.

Hyalos is the Greek term for the vitreous body.

The average value of intra-ocular pressure is 16 mmHg, but varies throughout the day from 10 to 21 mmHg. Daily production of aqueous humor is approximately 3 ml in each eyeball. The chambers of the eyeball contain approximately 0.2–0.3 ml of aqueous humor.

Measurements of the lens
Diameter: 9–10 mm
Thickness: 3.7–4.4 mm
Optic power: 15–20 dioptres

The cornea and lens are avascular. The eyeball possesses no lymph vessels. The lymph function is provided by the aqueous humor.

Clinical notes

Papilloedema means swelling of the optic disc. It is caused by increased intracranial pressure (intracranial hypertension) and is possible to see during examination of the fundus by ophthalmoscopy (aka fundoscopy).

The retina is not firmly attached to the choroid and thus it is liable to detachment *(amotio)*.

The retinal vessels and macula are prone to being affected by systemic disease such as diabetes and hypertension.

Lesions of branches of the central retinal artery can arise in hypertension, atherosclerosis and diabetes. They can cause impaired vision or even blindness.

Glaucoma is characterised by chronic and progressive atrophy of the optic nerve. It is usually caused by increased intraocular pressure.

Cataract is a clouding (opacification) of the lens. The affected lens can be replaced by surgery. To replace the lens: an incision is made in the capsule of the lens, the opaque content is aspirated and an artificial lens is inserted into the lens.

Pseudophakia is a term for an artificial lens inserted into the eye.

Veins of the orbit have a different course than the arteries. They interconnect with the veins of the face and the intracranial venous sinuses. Such anastomoses allow spread of infection from the face into the brain via the orbit.

Chambers of eyeball (*camerae bulbi*)

- 1 **Anterior chamber** (*camera anterior*) – is located between the posterior surface of the cornea and the anterior surface of the iris
- 2 **Posterior chamber** (*camera posterior*)
  - – is located between the posterior surface of the iris, ciliary body and the anterior surface of the lens
  - – communicates with the anterior chamber through the pupil

  3 **Aqueous humour** (*humor aquosus*)
  - – an intra-ocular transparent noncellular fluid
  - – nourishes the cornea, lens and vitreous body
  - **Production and flow of aqueous humour**
    1. produced in the ciliary body
    2. secreted into the posterior chamber
    3. passes through the pupil
    4. fills the anterior chamber
    5. enters the iridocorneal angle (*angulus iridocornealis*) and via the spaces of Fontana (*reticulum trabeculare*)
    6. is absorbed into the **canal of Schlemm** (scleral venous sinus, *sinus venosus sclereae*)
    7. drains through the aqeuous venules and then the scleral veins into the episcleral veins
- 4 **Postremal chamber / vitreous chamber** (*camera postrema / camera vitrea*)
  - – is located between the posterior surface of the lens and the retina
  - – contains the vitreous body

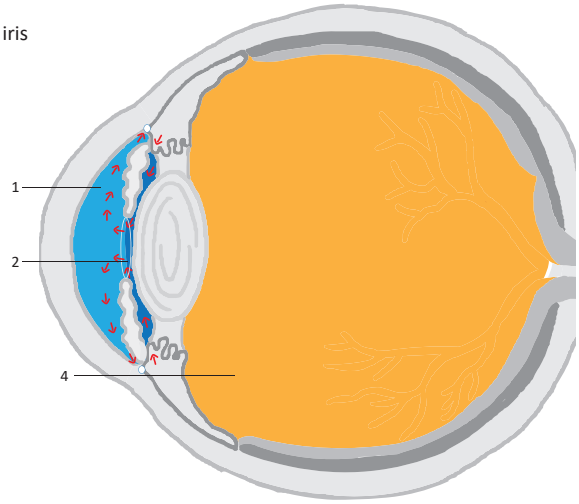

Chambers of the eyeball

Blood supply

Arterial supply: ophthalmic artery (from the internal carotid artery)

1 **Central retinal artery** (*arteria centralis retinae*) – supplies the retina (except photoreceptors)
- 1.1 **Retinal blood vessels** (*vasa sanguinea retinae*)
  - – vessels of the eyeball fundus (*fundus oculi*)
- 1.2 Superior and inferior temporal retinal arterioles (*arteriola temporalis retinae superior et inferior*)
- 1.3 Superior and inferior nasal retinal arterioles (*arteriola nasalis retinae superior et inferior*)
- 1.4 Superior, middle and inferior macular arterioles (*arteriola macularis superior, media et inferior*)

2 **Lacrimal artery** (*arteria lacrimalis*)
- 2.1 Lateral palpebral arteries (*arteriae palpebrales laterales*)

3 **Short posterior ciliary arteries** (*arteriae ciliares posteriores breves*)
- – supply the choroid and photoreceptors
- 3.1 Cilioretinal artery (*arteria cilioretinalis*) (10–33 %)
  - – a variant accessory artery supplying the macula

4 **Long posterior ciliary arteries** (*arteriae ciliares posteriores longae*)
- – supply the ciliary body and iris

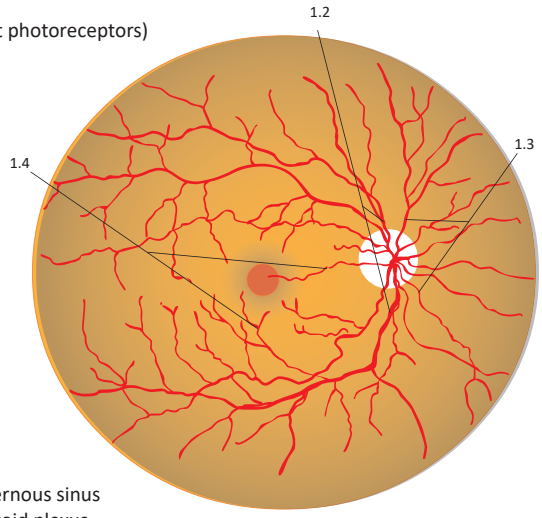

Arteries of the right ocular fundus

Venous drainage:

1 **Superior ophthalmic vein** (*vena ophthalmica superior*) – flows into the cavernous sinus
2 **Inferior ophthalmic vein** (*vena ophthalmica inferior*) – flows into the pterygoid plexus
3 **Angular vein** (*vena angularis*) – into the facial vein

Veins of the eyeball correspond to the arteries excluding:

1 **Scleral veins**
2 **Canal of Schlemm / scleral venous sinus** (*sinus venosus sclereae*) – flows into the scleral veins and then to the anterior ciliary veins
3 **Vorticose veins** (*venae vorticosae*) – usually four in the four quadrants of the eyeball, collect blood from the choroid

Innervation

Special sensory: the optic nerve terminates lateral geniculate body of the diencephalon
– the visual pathway continues to cortical area 17 in the occipital lobe
Somatosensory: ophthalmic nerve (first branch of the trigeminal nerve)
– **cornea:** long ciliary nerves
– **surrounding area:** lacrimar nerve, frontal nerve, nasociliary nerve and infraorbital nerve
Sympathetic innervation of the dilatator pupillae: short ciliary nerves (arising from the ciliary ganglion), postganglionic sympathetic fibers originates in the superior cervical ganglion (do not interconnect in the ciliary ganglion in comparison with the parasympathetic fibers)
Parasympathetic innervation of the sphincter pupillae and ciliary muscle: short ciliary nerves, which synapse at the ciliary ganglion (preganglionic fibres form a component of the inferior branch of the oculomotor nerve)

This copy belongs to ali yaghoubi

The conjunctiva covers the sclera on the external part of the eyeball (the white of the eye). It is reflected onto the internal surface of the eyelids and thus **allows smooth eyelid movements on surface of the eyeball**. The conjunctiva and lacrimal apparatus form an **important part of the immune system of the eye** as they contain extensive lymph tissue and produce mucus. **The lacrimal glands produce tears**, which clean the outer surface of the eyeball. Tears are drained via the nasolacrimal duct into the nasal cavity. **The extra-ocular muscles** are striated muscles that produce very fine eye movements.

Parts

- 1 **Ligamentous apparatus** (*apparatus ligamentosus*)
- 2 **Eyelids** (*palpebrae*)
- 3 **Eyebrow** (*supercilium*)
- 4 **Conjunctiva** (*tunica conjunctiva*)
- 5 **Lacrimal apparatus** (*apparatus lacrimalis*)
- 6 **Muscular apparatus** (*apparatus muscularis*)

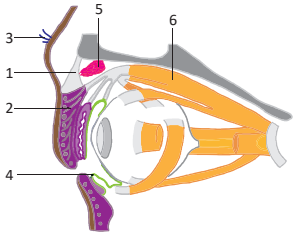

Structures of the orbit

Ligamentous apparatus (*apparatus ligamentosus*)

- 1 **Periorbit** (*periorbita*) – the periosteum of the orbit
- 2 **Orbital septum** (*septum orbitale*) – a fibrous plate enclosing the orbit ventrally and extending into the eyelids
- 3 **Fascial sheath of eyeball / capsule of Tenon** (*vagina bulbi*) – a fibrous cover of the eyeball
- 4 **Suspensory ligament of eyeball** (*lig. suspensorium bulbi*) – a caudal strengthened band of the fascial sheath of the eyeball
- 5 **Episcleral space** (*spatium episclerale*) – a space between the eyeball and its fascial sheath filled with loose connective tissue
- 6 **Retrobulbar fat / orbital fat body** (*corpus adiposum orbitae*) – a fat pad inside the orbit
- 7 **Muscular fasciae** (*fasciae musculares*) – fasciae of the extra-ocular muscles

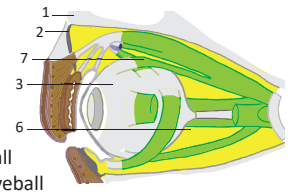

Ligamentous apparatus

Eyelids (*palpebrae*)

- 1 **Superior eyelid / upper eyelid** (*palpebra superior*)
  - 1.1 **Superior tarsus** (*tarsus superior*) – a thick (10 mm) plate of connective tissue in the upper eyelid
  - 1.2 **Superior tarsal muscle of Müller** (*musculus tarsalis superior*)
- 2 **Inferior eyelid / lower eyelid** (*palpebra inferior*)
  - 2.1 **Inferior tarsus** (*tarsus inferior*) – a thick (5 mm) plate of connective tissue in the lower eyelid
  - 2.2 **Inferior tarsal muscle** (*musculus tarsalis inferior*)
- 3 **Medial and lateral palpebral ligaments** (*ligamentum palpebrale mediale et laterale*)
- 4 **Lateral and medial eye angle** (*angulus oculi medialis et lateralis*)
- 5 **Levator palpebrae superioris** (*musculus levator palpebrae superioris*)
- 6 **Eyelashes** (*cilia*)
- 7 **Palpebral part of orbicularis oculi** (*pars palpebralis m. orbicularis oculi*)
- 8 **Glands** – three types of glands
  - 8.1 **Tarsal glands of Meibom** (*glandulae tarsales*) – holocrine sebaceous glands
  - 8.2 **Ciliary glands** (*glandulae ciliares*) – apocrine glands
  - 8.3 **Sebaceous gland of Zeis** (*glandulae sebaceae*) – holocrine sebaceous glands

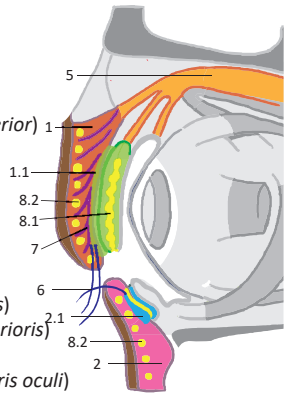

Eyelids

Conjunctiva (*tunica conjunctiva*)

– is composed of stratified columnar epithelium
– contains goblet cells, large amount of lymphoid tissue and the conjunctival glands of Wolfring (*glandulae conjunctivales*)

- 1 **Bulbar conjunctiva** (*tunica conjunctiva bulbi*) – converts into the corneal epithelium on the ventral surface of the eyeball
- 2 **Palpebral conjunctiva** (*tunica conjunctiva palpebrarum*) – the conjunctiva on the dorsal surface of the eyelid
- 3 **Superior conjunctival fornix** (*fornix conjunctivae superior*) – contains the openings of the lacrimal gland ducts
- 4 **Inferior conjunctival fornix** (*fornix conjunctivae inferior*)
- 5 **Conjunctival sac** (*saccus conjunctivalis*) – a space between the conjunctiva and cornea

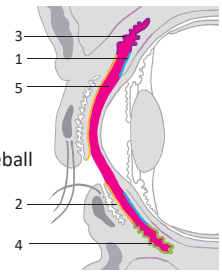

Conjunctiva

Blefaron is the Greek term for eyelid.

The orbitalis / orbital muscle *(musculus orbitalis)* is a smooth muscle located in the inferior orbital fissure.

Terminology of directions of eye movements
Nasal (medial): towards the nose
Temporal (lateral): towards the temporal region

Saccadic eye movements can be observed when reading or when shifting focus from one object to another.

Rapid eyes movements characterise the rapid eye movement phase (REM) of the sleep cycle.

The suspensory ligament of the eyeball holds the eyeball as if it was in a hammock.

The palpebral part of the orbicularis oculi is innervated by the facial nerve.

The superior and inferior tarsal muscles are smooth muscles.

Clinical notes

Chalazion is inflammation of the tarsal glands. It presents as a yellow and often painful lump on the internal surface of the eyelid.

Hordeolum is inflammation of the outer eyelid glands located at the eyelid margin.

Palsy of the facial nerve manifests as an impairment in function of the orbicularis oculi, which causes an inability to close the palpebral fissure (lagophthalmus). This can lead to desiccation of the conjunctiva (xerophthalmia), which can gravely endanger the acuity of vision by predisposition to inflammation and ulceration of the cornea.

Conjunctivitis is inflammation of the conjunctiva. It can have allergic and infectious aetiologies.

Epiphora is an overflow of tears onto the face.

Strabism / squint / heterotropia / strabismus is a symptom of extra-ocular muscle palsy.

Muscular apparatus (*apparatus muscularis*)

Extra-ocular muscles / extrinsic muscles of the eyeball (*musculi externi bulbi oculi*)

- 1 **Superior rectus** (*musculus rectus superior*) – nasocranial movement
- 2 **Inferior rectus** (*musculus rectus inferior*) – nasocaudal movement
- 3 **Medial rectus** (*musculus rectus medialis*) – nasal movement
- 4 **Lateral rectus** (*musculus rectus lateralis*) – temporal movement
- 5 **Superior oblique** (*musculus obliquus superior*) – temporocaudal movement
  - its tendon winds around the cartilaginous trochlea (trochlear spine, *spina trochlearis*)
- 6 **Inferior oblique** (*musculus obliquus inferior*) – tempocranial movement
- 7 **Levator palpebrae superioris** (*musculus levator palpebrae superioris*) – elevates the upper lid
  - located above the superior rectus and inserts in the superior tarsus

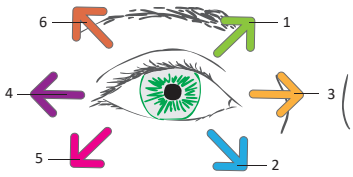

Directions of eye movements controlled by the extra-ocular muscles

Muscle origins

- 8 **Common tendinous ring of Zinn** (*anulus tendineus communis*)
  - the common origin of the rectus muscles, superior oblique muscles and levator palpebrae superioris
- 9 **Inferior wall of the orbit, medially**
  - is located lateral to the posterior lacrimal crest
  - the origin of the inferior oblique

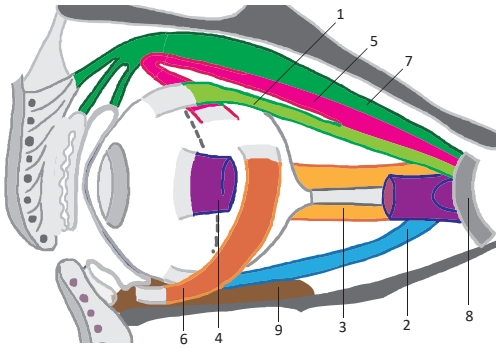

Muscle insertions:

1 **Insertions ventral to the eyeball equator** (rectus muscles)
– move the eyeball in the direction of the muscle insertion

2 **Insertions dorsal to the eyeball equator** (obliquus muscles)
– move the eyeball opposite to the direction of the muscle insertion

Muscle innervation

III **Oculomotor nerve** – superior, inferior and medial rectus, inferior oblique, levator palpebrae superioris

IV **Trochlear nerve** – superior oblique

VI **Abducens nerve** – lateral rectus

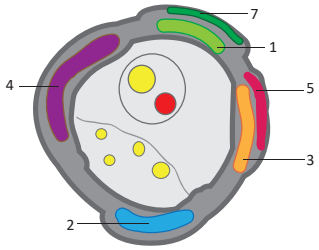

Common tendinous ring, right orbit

Eyeball movements

Movements of one eyeball (individual):

1 **Around the vertical axis:**
- 1.1 **Adduction** – nasal movement
- 1.2 **Abduction** – temporal movement

2 **Around the horizontal axis:**
- 2.1 **Elevation** – cranial movement
- 2.2 **Depression** – caudal movement

3 **Around the center:**
- 3.1 **Intorsion** – nasal rotation of the superior eyeball margin
- 3.2 **Extorsion** – temporal rotation of the superior eyeball margin

Combined eye movements

4 **Version** – both eyes moving synchronously and symmetrically in the same direction

5 **Vergence** – simultaneous movements of both eyes in the opposite direction
- 5.1 **Divergence** – simultaneous outward movement of both eyes away from each other
- 5.2 **Convergence** – simultaneous inward movement of both eyes toward each other

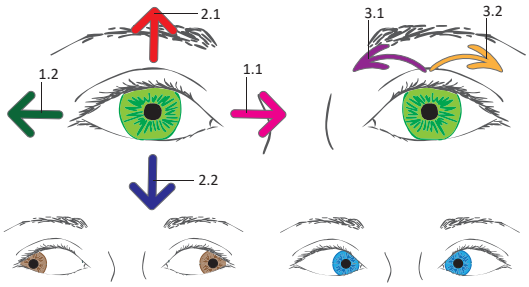

Eye divergence **Eye convergence**

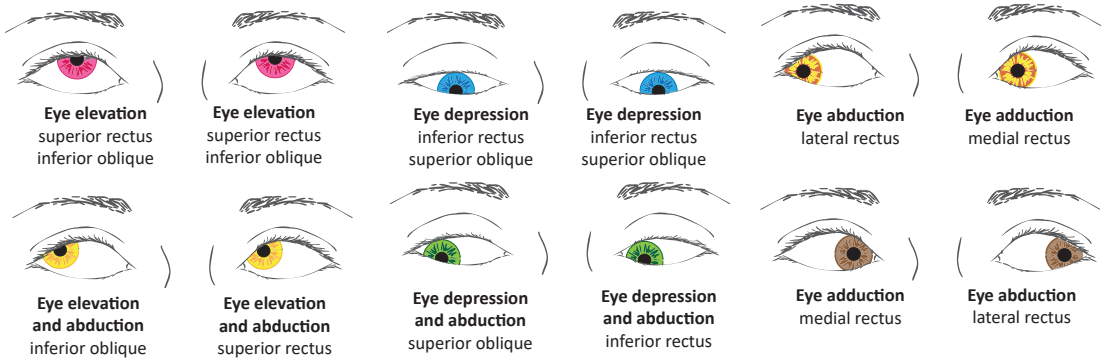

This copy belongs to ali yaghoubi

Lacrimal apparatus (*apparatus lacrimalis*)

- 1 **Lacrimal gland** (*glandula lacrimalis*) – a tuboalveolar serous gland with myoepithelial cells
  - – divided into two parts by the course of the levator palpebrae superioris
    - 1.1 **Orbital part** (*pars orbitalis*)
    - 1.2 **Palpebral part** (*pars palpebralis*)
    - 1.3 **Excretory ducts** (*ductuli excretorii*)
      - – 12 to 15 individual ducts
    - 1.4 **Accessory lacrimal ducts of Krause** (*glandulae lacrimales accessoriae*)
- 2 **Lacrimal pathway** (*rivus lacrimalis*)
- 3 **Lacus lacrimalis / lacrimal lake** (*lacus lacrimalis*)
  - 3.1 **Lacrimal caruncle** (*caruncula lacrimalis*)
    - – an elevation of the conjunctiva at the medial angle of the eye
  - 3.2 **Lacrimal papilla** (*papilla lacrimalis*)
    - – an elevation at the palpebral margin
- 4 **Superior and inferior lacrimal punctum** (*puctum lacrimale superius et inferius*)
  - – origins of the lacrimal canaliculi
- 5 **Superior and inferior lacrimal canaliculus** (*canaliculus lacrimalis superior et inferior*)
  - – canals draining tears into the lacrimal sac
- 6 **Lacrimal sac** (*saccus lacrimalis*)
  - – canaliculi join and open into the lacrimal sac
- 7 **Nasolacrimal duct** (*ductus nasolacrimalis*)
  - – is located inside the bony nasolacrimal canal
  - – opens into the inferior nasal meatus
    - 7.1 **Lacrimal fold of Hasner** (*plica lacrimalis*)
    - 7.2 **Inferior nasal meatus of nasal cavity** (*meatus nasi inferior cavitatis nasi*)

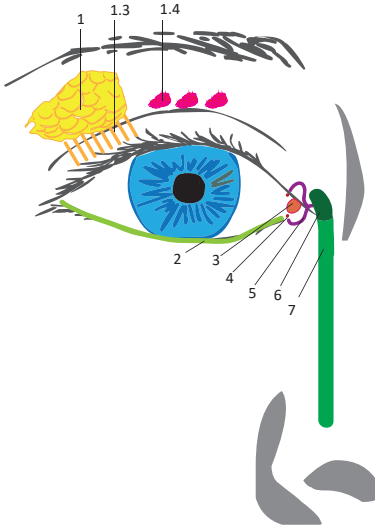

Lacrimal apparatus of the right eye

Dakryon is the Greek term for tear.

The tear film *(irroratio lacrimarum)* is a thin layer of liquid covering the conjunctiva and cornea. A lack of tear film is found in the dry eye syndrome.

Lacrima (tear) is a watery fluid.

In newborns, the lacrimal canaliculi may not be patent until the 3rd month after birth. An obstruction of the nasolacrimal duct causes epiphora. The excretory lacrimal ducts contain small folds (plicae), sometimes wrongly termed valvulae.

Cutis is the Latin term for skin. **Derma** is the Greek term.

Skin thickness: 0.5–4 mm

Skin types according to structure and location:
Thin skin (hairy skin) lacks the stratum lucidum. The epidermis is 75–150 µm thick.
Thick skin (smooth non-hairy skin) is found on the palms and soles. The epidermis is 400–800 µm thick.

Dermal ridges and skin sulci in the palms and soles are arranged in longitudinal papillary lines. In fingertips, they form unique patterns called dermatoglyphs and are implicated in dactyloscopy (fingerprint indentification).

The whole epidermis regenerates every 15–30 days (skin of the back every 28 days and of the head every 14 days). Acceleration of epidermal cell proliferation occurs in a disease called psoriasis vulgaris.

Cutaneous striae *(striae cutaneae, striae distensae)* are tears in the reticular layer of the dermis, which typically occur during growth, gravidity and obesity.

1.6 Touch, pain, proprioception – Tactus, nociceptio, proprioceptio

It is important to classify the **sense of touch** into two point discrimination, tension, pressure and vibrations and to differentiate it from the **sense of pain** (nociception). Both senses are perceived by identical receptors. **Perception depends on the intensity of stimulation**.

Exteroceptors

1 **Epidermis**
- 1.1 **Free nerve ending** (*terminatio neuralis libera*)
- 1.2 **Tactile meniscus of Merkel** (*meniscus tactilis*)

2 **Dermis**
- 2.1 **Tactile corpuscle / Meissner's corpuscle** (*corpusculum ovoideum*)
- 2.2 **Bulbous corpuscle / Ruffini corpuscle** (*corpusculum sensorium tactile*)

3 **Subcutaneous tissue** (*hypodermis*)
- 3.1 **Lamellar corpuscle / Pacinian corpuscle** (*corpusculum lamellosum*)

4 **Interoceptors**
- 4.1 **Free nerve ending** (*terminatio neuralis libera*)

5 **Proprioceptors**
- 5.1 **Muscle spindle** (*fusus neuromuscularis*)
  - – situated in striated muscles (few in the extra-ocular muscles, none in the lingual muscles)
  - – composed by a fibrous capsule and intrafusal muscular fibers
  - – innervated by γ-motoneurons (γ-loops)
  - – sensory anulospiral (center) and flower spray ending (periphery)
- 5.2 **Golgi tendon organ** (*organum sensorium tendinis*)

Clinical notes

During surgical operations, it is useful to direct incisions along the tension lines. This provides the optimal functional and cosmetic effects.

The direction of collagen fibres determins the relaxed skin tension lines of Langer (RSTL). Making incisions along these lines minimises the extent of enlargement of the surgical wound by skin tension.

Lines of maximal extensibility (LME) are perpendicular to the relaxed skin tension lines. They show the direction the skin can be maximally stretched. This is useful when planning skin flaps.

The skin is the **largest organ** of the human body. Its function are **protection against the external environment**, **thermoregulation** (via its the sweat glands and regulation of its blood flow), **excretion** (sweating and insensible water loss), **absorption** (of medications), **immunity**, **metabolism** (vitamin D metabolism from ergosterol) and **expression of emotions and mental states** (via vasoactivity and sweat production). It is composed of the **epidermis** and **dermis** and is continuous with the underlying **hypodermis** (subcutaneous tissue). The appendages of the skin include the hair, nails and skin glands.

Macroscopic features of the skin

1 **Skin sulci** (*sulci cutis*) – skin grooves bordering rhomboid skin areas
2 **Skin areas** (*areae cutis*) – are formed by traction of the elastic and collagen fibres of the dermis
– correspond to the tension lines
3 **Tension lines / cleavage lines** (*lineae distractiones*) – are located in the direction of the dermal fibril bundles and are perpendicular to the direction of the highest traction
– correspond to wrinkles on the surface of the skin
4 **Dermal ridges / papillar ridges** (*cristae cutis*) – tactile ridges on the palm and sole
5 **Tactile elevations** (*roruli tactiles*)
– elevated areas in the hand that are rich in sensory nerve endings
– 1 thenar, 1 hypothenar, 3 interdigital and 5 terminal tactile elevations
6 **Tension lines of Langer / cleavage lines** (*lineae distractionis*)
– flexion grooves at joints, on the palms and wrinkles
– include the mentolabial, nasolabial, suprapalpebral, infrapalpebral, gluteal and inguinal grooves, genitofemoral and intergluteal (natal) groove

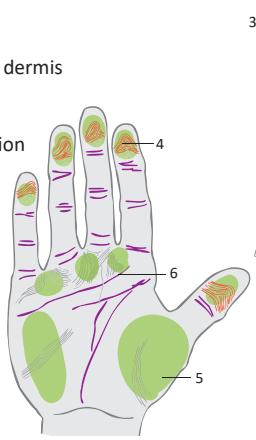

Tactile pads within the hand

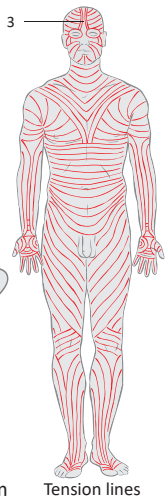

Tension lines

Histological structures

1 **Epidermis**
1.1 **Layers:** stratum basale (basal cells layer), st. spinosum, st. granulosum, st. lucidum, st. corneum, st. disjunctum
1.2 **Cells:**
1.2.1 **Keratinocytes** – migrate from the stratum basale to the surface, where they lose their nuclei and are shed
1.2.2 **Melanocytes** – cells of neuroectodermal origin that produce melanin, which protects agains UV radiation (cells transfer their melanin to keratinocytes)
1.2.3 **Langerhans cells** – dendritic cells of the immune system
– originate in the bone marrow and present antigens to lymphocytes
1.2.4 **Merkel cells** – cells of neuroectodermal origin, posses tactile receptors (discs of Merkel)
2 **Dermis** (*corium*) – is composed of connective tissue and contains capillaries, skin appendages and tactile receptors
2.1 **Papillary layer** (*stratum papillare*) – is composed of collagenous and elastic fibres that form the dermal papillae that project into the epidermis forming the epidermal ridges
2.2 **Reticular layer** (*stratum reticulare*) – is composed of collagen fibres forming rhomboid loops
3 **Subcutaneous tissue** (*hypodermis* / *tela subcutanea*) **–** is composed mainly of adipose tissue with a variable thickness (thickest in the abdomen, buttocks and thigh)
3.1 **Fatty layer** (*panniculus adiposus*)
3.2 **Fibrous layer** (*stratum fibrosum*)
3.3 **Membranous layer** (*stratum membranosum*) – fibrous thickenings
3.4 **Loose connective tissue** (*textus connectivus laxus*)
3.5 **Skin ligaments** (*retinacula cutis*)
3.6 **Subcutaneous synovial bursae** (*bursae synoviales subcutaneae*)

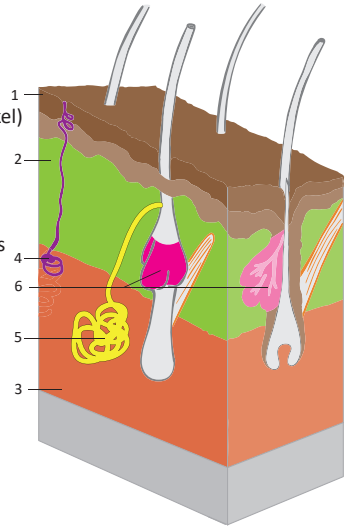

Section of the skin

Skin glands

4 **Eccrine sweat glands** (*glandulae sudoriferae merocrinae/eccrinae*)
– simple, coiled, tubulous, merocrine glands that secrete the fluid outside of hair follicles
– are located everywhere except the lips, internal surface of the prepuce, glans penis and nail beds, are in the palm, sole and forehead
– secrete sweat (sudor) – play a role in thermoregulation and are innervated by cholinergic nerve fibres
5 **Apocrine sweat glands** (*glandulae sudoriferae apocrinae*) – become completely functional at puberty (controlled by androgens)
– open into hair follicles, are located in the axilla, perineal region and labia minora
– produce a viscous secretion without any smell (the aromatic smell is caused by bacteria), are innervated by adrenergic fibres
5.1 **Mammary gland** (*glandula mammaria*), **areolar glands of Montgomery** (*glandulae areolares*)
5.2 **Ciliary glands of Moll** (*glandulae ciliares*) – located in the eyelids
5.3 **Ceruminous glands** (*glandulae ceruminosae*) – located in the external acoustic meatus (producing cerumen)
5.4 **Nasal sweat glands** (*glandulae sudoriferae nasales*) – located in the nasal vestibule
5.5 **Circumanal glands** (*glandulae circumanales*) – located around the anus
6 **Sebaceous glands** (*glandulae sebaceae*) – holocrine, alveolar glands, produce the sebum
– situated everywhere except the palms and soles
– open into hair follicles, independently on the hair follicles on the lips, glans penis, prepuce, labia minora, eyelids

This copy belongs to ali yaghoubi

Appendages of the skin

Hairs (*pili*)

- 1 **Follicle** (*folicullus*) – a hair sheath formed by invaginated epidermis
- 2 **Hair shaft** (*stipes/scapus*)
- 3 **Hair root** (*radix*)
- 4 **Hair bulb** (*bulbus*) – an derivative of the stratum germinativum that is composed of replicating cells
  - the dermal papilla / papilla of the hair follicle (*papilla dermalis pili*) is situated at the base of the hair bulb
- 5 **Cortex**
- 6 **Medulla**
- 7 **Arrector pili muscle** (*musculus arrector pili*)
  - smooth muscle that inserts into the hair follicle
  - functions to erects the hair
- 8 **Sebaceous glands** (*glandulae sebaceae*)
  - open into the hair follicles
  - produce sebum, an oily secretion, that waterproofs the skin

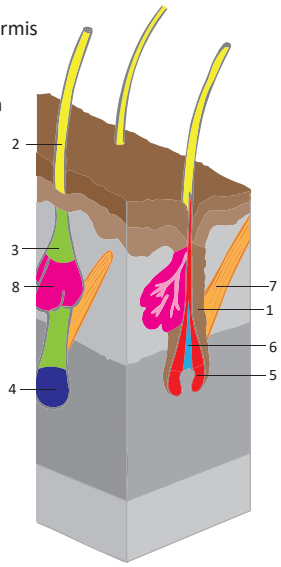

Section of the skin

Types of hair:

1 **Primary hair** – disappears before birth
– appears between the 4th and 6th months of intrauterine life
1.1 **Downy hair** (*lanugo*)
2 **Secondary hair**
2.1 **Hairs** (*pili*) – replaces downy hair
2.2 **Scalp hairs** (*capilli*)
2.3 **Eyebrows** (*supercilia*)
2.4 **Eyelashes** (*cilia*) – form one row on the lower eyelid, but multiple rows on the upper eyelid
3 **Tertiary hair** – appear in puberty (dark stiff hairs)
3.1 **Axillary hairs** (*hirci*) – is situated in the axilla
3.2 **Pubic hairs** (*pubes*) – is situated in the pubic area
3.3 **Beard** (*barba*) – is situated on the face
3.4 **Hairs of tragus** (*tragi*) – is situated in the external meatus
3.5 **Hairs of vestibule of nose** (*vibrissae*)
– situated in the nasal vestibule
3.6 **Sinuous hairs** – long tactile hairs in the eyebrows, face, forearm and wrist (appear after the 30th year of age)

Nail (*unguis*)

1 **Body** (*corpus*)
- 1.1 **Nail plate** (*lamina unguis*)
- 1.2 **Lateral border** (*margo lateralis*)
- 1.3 **Free border** (*margo liber*) – the distal margin

2 **Nail root** (*radix unguis*)
3 **Nail matrix** (*matrix unguis*) – nail grows from the matrix
- 3.1 **Lunule** (*lunula*) – the part of the nail matrix shining through the nail plate
- 3.2 **Hidden border** (*margo occultus*) – the proximal border at the nail matrix

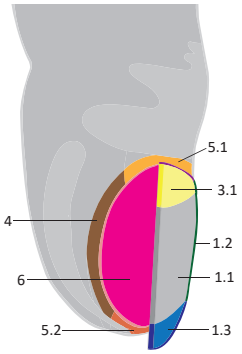

Parts of the nail

- 4 **Proximal and lateral nail fold** (*vallum proximale et laterale*) – skin folds surrounding the nail
- 5 **Perionyx** – the skin surrounding the nail
  - 5.1 **Eponychium** – the skin proximally covering the nail matrix
  - 5.2 **Hyponychium** – the skin distally under the nail free margin
- 6 **Nail bed** (*lectulus*) – the dermal base of the nail
  – capillaries shine through the nail bed ("a window for blood oxygenation")

Blood supply

Arterial supply: at the boundary of the subcutaneous tissue and dermis: cutaneous plexus
within the dermis: subpapillary plexus (*plexus subpapillaris*)
Venous drainage: cutaneous plexus, subpapillary plexus
Lymphatic drainage: superficial (subpapillary) and deep cutaneous network

Innervation

Somatosensory (touch and pain): free nerve endings and corpuscles
Sympathetic: for vessels, it is represented by adrenergic postganglinic vasomotor fibers
– **for sweat glands** by cholinergic nerve fibers

The angiosome is an area tissue supplied by one vessel. Angiosomes are interconnected by arteries of small caliber or by arterio-arterial anastomoses.

Hairs are present everywhere on the skin except on the palms, soles, lips, glans penis, glans clitoridis and labia minora. Hair grows at a speed about 0.4 mm per day. About 100 hairs are physiologically shed per day.

Onychos is the Greek term for nail.

The thickness of the nail is 0.5–1.5 mm. Nails grow at a speed of 0.1 mm per day.

Breast size in Europe is given by the circumference of the thorax just below the breast in the inframammary fold and by a numeric code determining the difference between the circumference measured over the nipple and the circumference below the breast (AA-I).

Mastos is the Greek term for breast. **Mammilla** is the clinically term for nipple.

Clinical notes

Knowledge of the blood supply and innervations of the skin is essential for skin flap surgery. A skin flap surgery is a transfer of certain skin areas to cover defects.

Alopecia means a loss of hair.

It is necessary to remove the axillary lymph nodes when performing mastectomy for advanced breast tumours. Only level 1 and level 2 nodes (according to Berg's classification) are dissected. Level 3 nodes are left as they lie close to the axillary neurovascular bundle and so carry a high risk of complications such as lymphoedema of the upper extremity.

The insertion of the suspensory ligaments (retinaculum) of the breast to the skin gives an explanation as to why skin sometimes retracts over breast tumours.

Accessory breast tissue can be found at any point along the course of the mammary crest. This condition is known as polymastia. The most common form accessory breast tissue takes is a supernumery nipple (polythelia).

The areolomammilar complex is a term for the areola and nipple. Sensory nerves approach from above, which is why surgical incisions are performed below the lower border of the areola.

The breast is a paired organ located on the thorax. **The areola** is a pigmented area of skin located at the apex of the breast. The **nipple is located in the centre of the areola** and serves as a opening of the lactiferous ducts. The mammary gland and **fat tissue** are located inside the breast. The mammary gland is the **largest skin gland** and **produces milk for the newborn**. The mammary gland is derived from the mammary crest in both sexes and is located between the 3rd and 6th intercostal spaces. The weight of the breast increases during puberty and lactation. The usual of the breast is 150 g but can increase to up to 300–800 g during lactation .

Structure

- 1 **Areola** (*areola mammae*) – a circular pigmented area around the nipple
  - 1.1 **Nipple** (*papilla mammaria*) – contains the openings of the lactifeours ducts
    – contains smooth muscle responsible for its erectility
  - 1.2 **Areolar tubercles / tubercles of Montgomery** (*tubercula areolaria*)
    – small elevation made by the areolar glands
  - 1.3 **Areolar glands / glands of Montgomery** (*glandulae areolares*)
    – small apocrine glands
- 2 **Mammary gland** (*glandula mammaria*)
  – a compound tuboalveolar apocrine gland
  - 2.1 **Axillary process** (*processus axillaris*) – a gland projection towards the axilla
  - 2.2 **Lobes of mammary gland** (*lobi glandulae mammariae*)
    – 15–20 lobes that are subdivided into lobules
  - 2.3 **Lobules of mammary gland** (*lobuli glandulae mammariae*)
    – lobules composed of alveoli
  - 2.4 **Lactiferous ducts** (*ductus lactiferi*) – ducts of the mammary gland
    - 2.4.1 **Lactiferous sinuses** (*sinus lactiferi*) – the widened terminal portions of the lactiferous ducts
- 3 **Suspensory ligaments of breast / Cooper's ligament**
  (*ligamenta suspensoria mammae / retinaculum cutis mammae*)
  – a fibrous network inserting into the pectoral fascia and dermis of the skin over the breast
- 4 **Adipose layer / mammary fat pad** (*stratum adiposum mammae / corpus adiposum mammae*)
  – is located both in front and behind the gland
  – the volume of fat determines the size of the breast

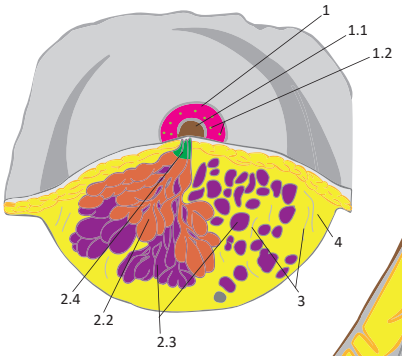

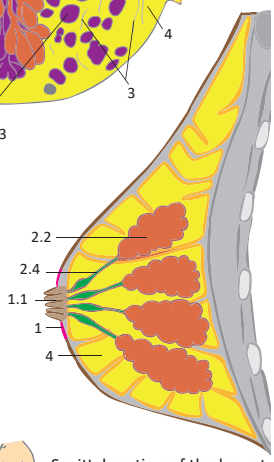

Sagittal section of the breast

Breast development and shapes

1. **Mammary crest** *(crista mammaria)*
   – is formed within the 1st month of intrauterine life
   – extends from the anterior axillary line down to just above the groin
2. **Mammary gland base** – is present at birth
3. **Breast enlargement during puberty** – is classified by Tanner stages M1 to M5
   3.1 **Mamma puerilis/neutralis**
   3.2 **Mamma areolata**
4. **Adult mamma**
   4.1 **Mamma disciformis** – small flat breast
   4.2 **Mamma hemispheroidea** – hemispherical breast
   4.3 **Mamma piriformis** – pear-shaped breast that is typical for middle-aged women
   4.4 **Mamma pendula** – flabby breast of elderly women caused by loss of fat tissue



Mamma disciformis



Mamma hemispheroidea



Mamma piriformis

Blood supply and innervation

Arterial supply: mammary branches (rami mammarii)
– internal, superior and lateral thoracic artery, intercostal arteries (2–4)
Venous drainage: internal and lateral thoracic vein
Lymphatic drainage: starts as the subareolar plexus of Sappey

- 1 **Axillary lymph nodes**
  - 1.1 **Node of Sorgius** – is a sentinel lymph node of the mammary gland
    – is the most caudal of the pectoral lymph nodes
    – is located at the 2nd/3rd origin of the serratus anterior
- 2 **Parasternal lymph nodes**
- 3 **Supraclavicular lymph nodes**
- 4 **Contralateral axillary lymph nodes**

Sensory innervation: intercostal nerves (4–6) – nipple (dermatome T4)
Autonomic innervation: periarterial plexuses

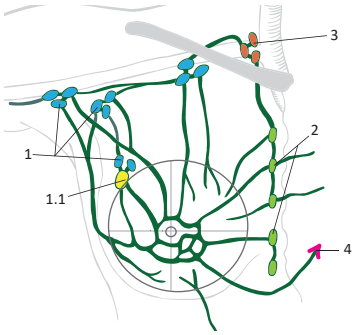

Lymphatic drainage of the breast

This copy belongs to ali yaghoubi

I. Senses (in general) and the internal environment

1. State the receptors according to their individual stimuli. (p. 502)
2. Explain how receptors monitor the internal environment. (p. 502)
3. List the 6 individual senses and sensory organs of their perception. (p. 502)
4. State the chemoreceptors location in the body and specify their function. (p. 502)
5. Clarify the difference between the carotid and para-aortic body. (p. 502)
6. Describe and give the locations of the receptors within the cerebral ventricles walls. (p. 502)

II. Olfactory organ

7. Describe the olfactory organ. (p. 503)
8. State the pathway of olfactory cells axons to the brain. (p. 503)
9. Explain why the olfactory mucosa includes glands. (p. 503)

III. Gustatory organ

10. Describe the localization of the taste buds. (p. 503)
11. Classify the 5 types of taste. (p. 503)
12. State three nerves involved in the transmission of gustatory stimuli and specify which parts of the tongue they innervate. (p. 503)

IV. The organs of audition and balance

13. State two functions of the ear. (p. 504)
14. Specify the type of cartilage found in the auricle. (p. 505)
15. Describe the structural base of the umbo of the tympanic membrane. (p. 505)
16. Describe the anatomy of the auditory ossicles in the middle ear. (p. 506)
17. Explain the function of the auditory tube. (p. 506)
18. Describe the muscles of the tympanic cavity and state their innervations. (p. 506)
19. State the two openings in the vestibule of the osseous labyrinth. (p. 507)
20. Explain the different function of the utricle and saccule. (p. 507)
21. State the 5 structures passing through the internal acoustic meatus. (p. 507)
22. Define the term otoconia. (p. 507)

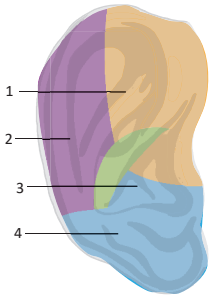

Describe the somatosensory innervation of the auricle

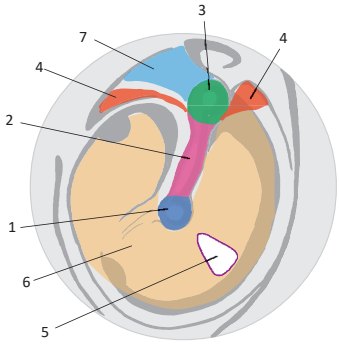

Describe the structure of the tympanic membrane from otoscopic view

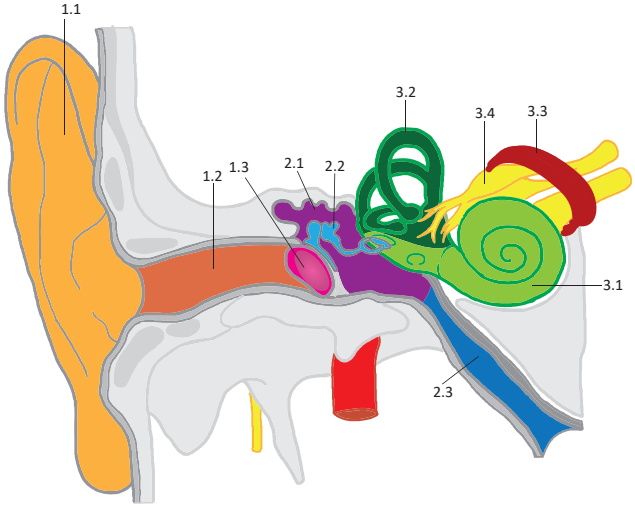

Describe the structure of the ear

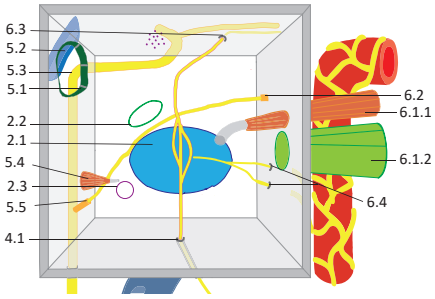

Describe the structures within the tympanic cavity

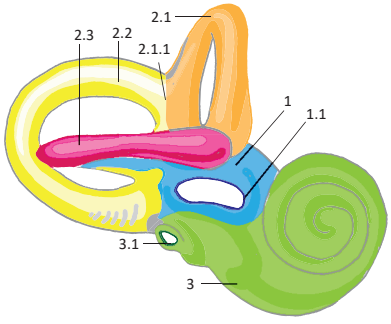

Describe the structure of the bony labyrinth

V. Visual organ

23. Describe the eyeball structure (using geographical terminology). (p. 508)
24. Describe the difference between the optic and visual axes. (p. 508)
25. Describe both the structural and functional differences between the optic disc and macula. (p. 508)
26. State the three chambers of the eye and their contents. (p. 511)
27. Describe the production and flo of the aqueous humor. (p. 511)
28. Explain the principles of the corneal and papillary reflex. (p. 508)
29. State the differences between the external and internal corneal epithelium. (p. 509)
30. Describe the structure and function of the ciliary body. (p. 509)
31. State the two muscles forming the iris. (p. 509)
32. State the 4 types of retinal neurons. (p. 510)
33. State the average value of intra-ocular pressure. (p. 510)
34. State the optic power of the lens and cornea. (p. 509, 510)
35. State the 3 arteries supplying the macula. (p. 511)

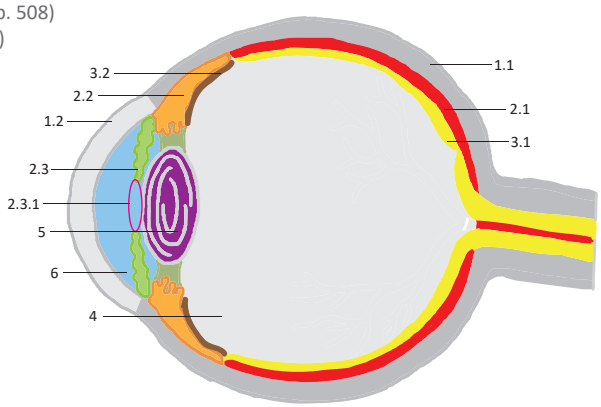

Describe the structure of the eyeball

VI. Accessory visual structures

36. State the 6 accessory visual structures. (p. 512)
37. State the three types of glands located in the eyelids. (p. 512)
38. State the 5 parts of the eyeball covered with the conjunctiva. (p. 512)
39. Draw a scheme of the eyeball movements of the individual extra-ocular muscles. (p. 513)
40. Explain the terms divergence and convergence (of the eye). (p. 513)
41. State the 6 extra-ocular muscles and specify their innervation. (p. 513)
42. Describe the production, circulation and drainage of tears. (p. 514)

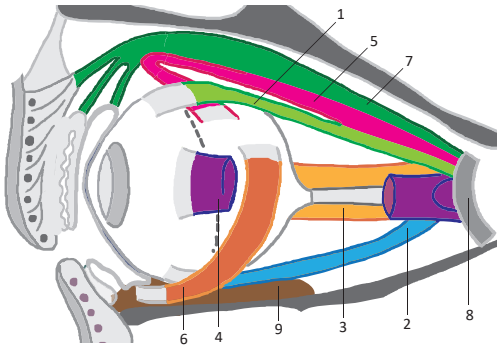

Describe the eye muscles

VII. Integumentum (Skin)

43. State the 7 functions of the skin. (p. 515)
44. Explain the clinical significance of the skin tension lines. (p. 515)
45. State and describe the three types of the skin glands. (p. 515)
46. Classify the types of hair and specify their location. (p. 516)
47. Explain how and from where the nail grows. (p. 516)

VIII. Breast and mammary gland

48. State which type of gland the mammary gland is. (p. 517)
49. State the 4 types of adult breast. (p. 517)
50. State the lymph node groups draining the breast. (p. 517)

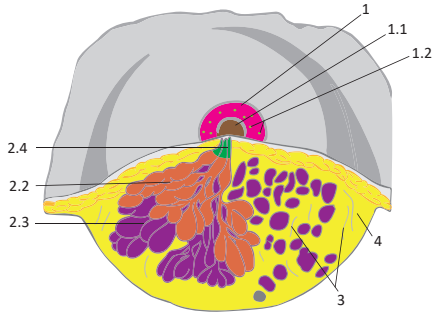

Describe the structure of the breast

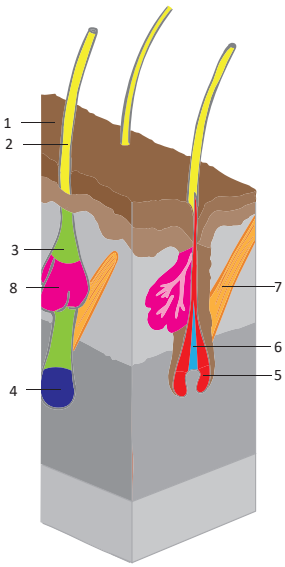

Describe the composition of the skin and its derivates

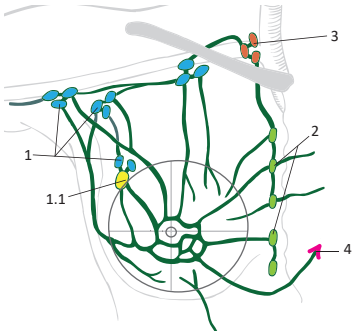

Describe the lymphatic drainage of the breast

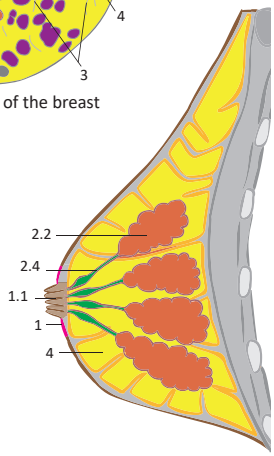

Describe the structure of the breast

This copy belongs to ali yaghoubi

We would like to thank the following **anatomists, physicians and medical students** for their invaluable help, devotion and feedback in the preparation of this chapter.

Anatomists

Assoc. prof. Nihal Apaydın, MD – Department of Anatomy, Faculty of Medicine, Ankara University, Ankara, Turkey
Assoc. prof. Václav Báča, MD, PhD – Department of Anatomy, Third Faculty of Medicine, Prague, Czech Republic
Assoc. prof. Květuše Lovásová, VDM, PhD – Department of Anatomy, Pavol Jozef Šafárik University, Košice, Slovakia
Pavel Šnajdr, MD, PhD – Department of Anatomy, First Faculty of Medicine, Charles University, Prague, Czech Republic

Clinicians

Dale Kalina, MD – Department of Internal Medicine, University of Saskatchewan, Canada

Medical students

Linda Kašičková
Adéla Kuklová

4 References

1. LANZ, T. and W. WACHSMUTH. Praktische Anatomie. 7 bands. Berlin: Springer, 2003, 3658 p. ISBN 978-3-540-40571-9.
2. MILLS, S. E. Histology for pathologists. 4th Ed. Philadelphia: Lippincot Williams & Wilkins, 2012. 1328 p. ISBN-13: 978-1-4511-1303-7.
3. MOORE, K. L.; DALLEY, A. F. and A. AGUR. Clinically oriented anatomy. 7th Ed. Philadelphia: Lippincot Williams & Wilkins, 2014. 1139 p. ISBN 978-1-4511-1945-3.
4. NETTER, F. H. Atlas of Human Anatomy. Professional Edition. 6th Ed. Oxford: Elsevier. 2014. 640 p. ISBN 978-1-455-75888-3.
5. NOLTE, J: Nolte's The Human Brain: An Introduction to its Functional Anatomy With Student Consult Online Access. 6th Ed. Philadelphia: Mosby/Elsevier, 2008, 79 p. ISBN 978-0-323-04131-7.
6. OVALLE, W. K. and P. C. NAHIRNEY. Netter's Essential Histology: with Student Consult Access. 2nd Ed. Philadelphia: Saunders/Elsevier, 2013. 493 p. ISBN-13: 978-1-4557-0631-0.
7. ROHEN, J. W. LUTJEN-DRECOLL, E. and C. YOKOCHI. Color Atlas of Anatomy: A Photographic Study of the Human Body. 7th Ed. Stuttgart: Lippincot Williams & Wilkins, 532 p. ISBN 978-1-58255-856-1.
8. SNELL, R. S. Clinical anatomy by regions. 9th Ed. Philadelphia: Lippincott Williams & Wilkins, 2012. 768 p. ISBN 978-1-60913-446-4.
9. SNELL, R. S. Clinical Neuroanatomy. 7th Edition. Philadelphia: Lippincot Williams & Wilkins, 2009, 560 p. ISBN 978-0-7817-9427-5.
10. WILLIAMS, P. L., ed. Gray´s Anatomy: the anatomical basis of medicine and surgery. 38th Ed. New York: Churchill Livingstone, 1995, 2092 p. ISBN 0-443-05717-6.

Memorix Anatomy

14 Endocrine system



Jakub Miletín
David Kachlík
Radovan Hudák
Ondřej Volný
Adam Whitley

General overview 522
Diffuse neuroendocrine system 522
Pituitary gland 523
Pineal gland 524
Endocrine component of the pancreas 524
Thyroid and parathyroid gland 525
Adrenal gland 526
Summary of the endocrine glands and hormones 527
Review questions and figures 527
Acknowledgements and references 528

This copy belongs to ali yaghoubi

The phylogenetically old endocrine system is defined by its ability to secrete **hormones**, which are chemical messengers that regulate the activity of cells by acting on specific receptors. Both the endocrine system and central nervous system are responsible for controlling and coordinating the functions of organs. However, the endocrine system acts through the secretion of hormones and the CNS by action potentials. Hormone signaling is slower than the transmission of impulses in the nervous system. Therefore, hormones act primarily to regulate long-term metabolic changes and maintain **homeostasis**. The endocrine system consists of **endocrine glands** and the cells of the **diffuse neuroendocrine system (DNES)**. Endocrine glands are also called ductless glands. They secrete hormones directly into the blood stream, rather than through ducts, which is typical for exocrine glands. The diffuse neuroendocrine system is formed by isolated cells dispersed throughout organs not considered to be endocrine glands. Their products are termed tissue hormones and are transported locally by the extracellular fluid, lymph and blood.

Endocrine glands

- 1 **Hypophysis / pituitary gland** (*hypophysis, glandula pituitaria*)
  - 1.1 **Adenohypophysis** (anterior lobe)
  - 1.2 **Neurohypophysis** (posterior lobe)
- 2 **Pineal gland / pineal body** (*glandula pinealis, corpus pineale*)
- 3 **Thyroid gland** (*glandula thyroidea*)
- 4 **Parathyroid gland** (*glandula parathyroidea*) – usually 4 glands
- 5 **Endocrine part of the pancreas** – pancreatic islets of Langerhans
- 6 **Suprarenal/adrenal glands** (*glandulae suprarenales*)
- 7 **Gonads** – ovaries and testes

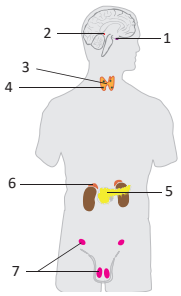

2 Diffuse neuroendocrine system (DNES) and paraganglia

The DNES is formed by **neuroendocrine cells** scattered throughout the epithelium of all organs not considered to be endocrine glands. It is responsible for producing numerous **peptides** that act both as **neurotransmiters and as hormones**. They have a wide variety of functions that include the regulation of intestinal movement and the secretion of digestive enzymes in the digestive system and regulation of the development and function of the respiratory system. **Paraganglia** form a part of the neuroendocrine system. They are formed by clusters of cells originating from the neuroectoderm in the proximity of the **large vessels, sympathetic ganglia and autonomic nerves**.

Paraganglia

- 1 **Carotid body** (*glomus caroticum*)
  - – is located at the carotid bifurcation (at level C4)
  - – a chemoreceptor
  - – contains chromophobe cells
- 2 **Organ of Zuckerkandl** (*paraganglion aorticum abdominale*)
  - – is located at the origin of the inferior mesenteric artery
  - – consists of chromaffin cells similar to the medulla of the adrenal gland
- 3 **Aortic body** (*glomus aorticus/supracardiacum*)
  - – a chemoreceptor located in the aortic arch
- 4 **Coccygeal body / Luschka's body** (*glomus coccygeum*) – is located in front of the coccygeal apex
- 5 **Jugular body** (*glomus jugulare*)
  - – is located in the superior bulb of the internal jugular vein
- 6 **Tympanic body** (*glomus tympanicum*)
  - – is situated within the wall of the tympanic cavity

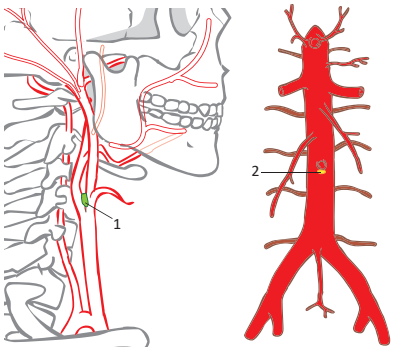

Paraganglia in proximity to large arteries

The hypophysis is attached to a piece of dura mater called the sellar diaphragm *(diaphragma sellae)* at the hypophysial fossa *(sella turcica)*. The sellar diaphragm contains an opening (the foramen of Pacchioni) for the pituitary stalk.

Herring's bodies *(corpuscula neurosecretoria)* are synonyms for the secretory granules in the hypothalamohypophysial tract.

The adenohypophysis is derived from Rathke's pouch, which is a pouch of ectoderm originating from the roof of the stomodeum in the third week of development. Small cavities (Rathke's follicles) may persist between the distal and intermediate parts as remnants of this pouch. A tumour called a craniopharyngioma can emerge in this area.

The carotid sinus is the enlarged beginning of the internal carotid artery. Baroreceptors that register changes in the blood pressure are located within the wall of the carotid sinus.

Testis see page 240.
Ovary see page 250.
Hypothalamus see page 430.

Clinical notes

Carcinoid tumors originate from the cells of the gastrointestinal diffuse neuroendocrine system. They are one of the most common neuroendocrine tumors of the gastrointestinal tract. Carcinoids often produce serotonin and histamine, the overproduction of which leads to the carcinoid syndrome, which is characterised by flushing, diarrhoea, bronchoconstriction and cardiac changes.

Massage of the carotid sinuses can lead to a decrease in heart rate via activation of the vagus nerve. This can be used as the first-line treatment of tachycardia.

Adenohypohyseal tumours can manifest with bitemporal heteronymous hemianopsia as a result of compression of the optic chiasm. Pituitary surgery can be performed through the nasal cavity and sphenoidal sinus. This is termed transsphenoidal surgery. The traditional surgical approach can be replaced by radiotherapy with Leksell´s gamma knife.

Craniopharyngeoma is a tumour derived from the residual embryonic tissue of Rathke's pouch. It can manifest as a functional lesion of the pituitary gland or as a visual field impairment from compression of the optic chiasm.

The pituitary gland is a small gland located in the **hypophyseal fossa** of the **sphenoid bone** *(sella turcica)*. The pituitary stalk connects the pituitary gland to the hypothalamus. The hypothalamus controls the activity of the pituitary gland. The hypophysis and hypothalamus form the **hypothalamohypophysial system/axis,** which is responsible for the majority of hormonal regulation and is also closely related to **the autonomic nervous system**. The anterior part of the pituitary gland is called **adenohypophysis** and is derived from the roof of the stomodeum (ectoderm). The posterior part, termed **neurohypophysis,** represents a pouch of the diencephalon at the base of the third ventricle (derived from the neuroectoderm).

Structure

1 **Adenohypophysis (anterior lobe)**
- 1.1 **Pars distalis** – the major part of the anterior lobe
- 1.2 **Pars intermedia** – a strip of hypophyseal tissue at the border with the posterior lobe
- 1.3 **Pars tuberalis** – a layer surrounding the stalk of the posterior lobe

2 **Neurohypophysis (posterior lobe)**
- 2.1 **Infundibulum** – the stalk of the posterior lobe
- 2.2 **Neural lobe** – the posterior lobe itself

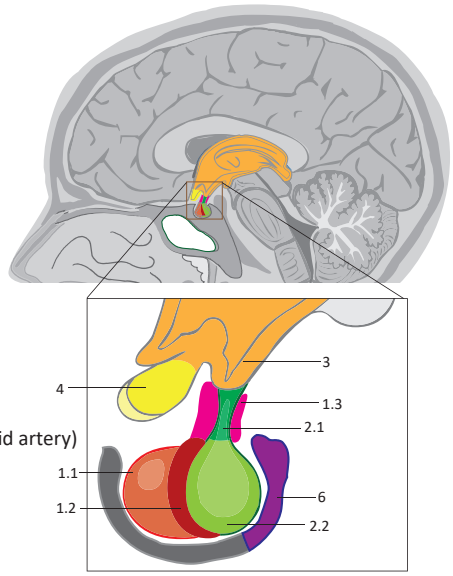

Close-up of a sagittal section of hypothalamus and hypophysis

Syntopy

- 3 **Cranially:** hypothalamus (median eminence, tuber cinereum)
- 4 **Ventrocranially:** optic chiasm
- 5 **Ventrocaudally:** sphenoid sinus
- 6 **Dorsally:** dorsum sellae, basilar artery and pons
- 7 **Laterally:** cavernous sinus (with 3rd, 4th, 5th and 6th cranial nerves and internal carotid artery)

Histological structure

Anterior lobe (adenohypophysis)

1 **Pars distalis**
- 1.1 **Chromophobe cells** – stem cells or hormone secreting cells
- 1.2 **Chromaffin cells** – somatotrophs, mammotrophs, gonadotrophs, thyreotrophs, corticotrophs (named according to the target gland)

2 **Pars intermedia** – corticotrophs

3 **Pars tuberalis** – gonadotrophs or thyreotrophs

Posterior lobe (neurohypophysis)

1 **Axons of neuroendocrine neurons** – the cell bodies are positioned in the supraoptic and paraventricular nuclei of the hypothalamus
– the hypothalamohypophysial tract transports secretory granules to the hypophysis

2 **Pituicytes** – glial cells

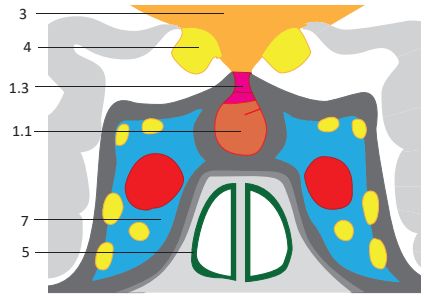

Frontal section of the hypophysis and cavernous sinus

Functional connections with the hypothalamus

Anterior lobe (adenohypophysis)

1. hormones are secreted in **the arcuate nucleus** (parvocellular part) of the hypothalamus and stimulate or inhibit cells of the adenohypophysis
2. hormones are carried via axonal transport to **the median eminence** where there are released into capillaries during a process called neurosecretion
3. the **portal system of the hypophysis transmits hormones** to the chromaffin cells
4. **secretion of hormones into the blood stream**

Posterior lobe (neurohypophysis)

1. **neuroendocrine secretion from axons of the hypothalamohypophysial tract** (supraoptic and paraventricular nucleus) to the drainage area of the inferior hypophysial artery

Blood supply

Arterial blood supply:

- 1 **Superior hypophysial artery** (a branch of the internal carotid artery) – supplies the infundibulum and median eminence
- 2 **Portal system of the hypophysis** – originates from the spiral arteries in the pituitary stalk and continues to the second capillary bed in the adenohypophysis
- 3 **Trabecular artery** – supplies the pars distalis of the anterior lobe
- 4 **Inferior hypophysial artery** (branch of the internal carotid artery) – supplies the posterior lobe

Venous drainage:

- 5 **Hypophysial veins** (into the cavernous sinus)

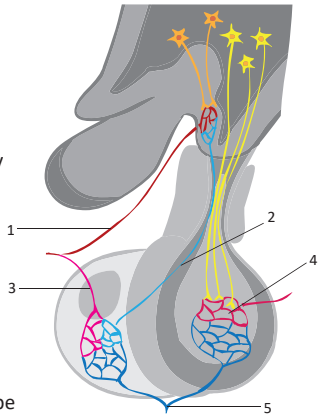

Scheme of the hypothalamohypophysial system (sagittal section)

This copy belongs to ali yaghoubi

The pineal gland is an unpaired oval-shaped organ. It is part of epithalamus, which is located the diencephalon. The pineal gland is connected to the habenular commisure by its stalk and is positioned in the quadrigeminal cistern rostral the superior colliculi of the midbrain. **Melatonin, the pineal hormone, is secreted primarily in darkness** and is involved in **the control of circadian rhythm**. Information about light from the retina is transmitted to the pineal gland by a branch of the visual pathway that passes through the hypothalamus.

Syntopy

- 1 **Pineal gland**
- 2 **Cranially:** corpus callosum
- 3 **Caudally:** quadrigeminal plate
- 4 **Rostrally:** third ventricle
- 5 **Dorsolaterally:** quadrigeminal cistern
- 6 **Dorsally:** great cerebral vein

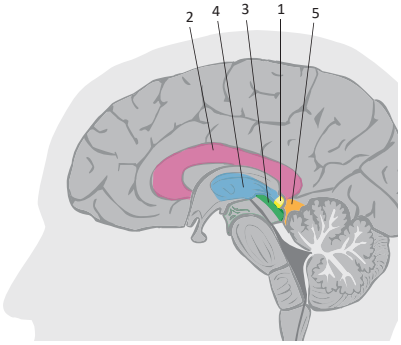

Sagittal section of the brain

Histological structure

1 **Pia mater** – is located on the surface of the gland
– emits septa inside the gland, which contain vessels and unmyelinated nerve fibres
2 **Pinealocytes** – the melatonin secreting cells
3 **Interstitial cells** – specific astrocytes of the pineal gland

Phylogenetically, the pineal gland represents a remnant of the neuroepiphysis. In some vertebrates, the neuroepiphysis is composed of the pineal gland and the parapineal body situated at the surface of the head and serves as a receptor for light intensity and the day-night cycle. Thus, it is called the parietal eye or pineal eye.

The islets of Langerhans develop in the third month of intrauterine development and insulin secretion begins in the fifth month. The islet diameter is approximately 0.1–0.5 mm and the total number of islets is about one million. The islets of Langerhans constitute 2–3 % of the total weight of the pancreas.

Pyramidal lobe / Lalouette's pyramid *(lobus pyramidalis)* is present in 25–50 % of cases.

Tubercle of Zuckerkandl *(tuberculum dorsale)* is the most dorsal structure of the thyroid lobes.

Thyroid ima artery / thyroid artery of Neubauer *(arteria thyroidea ima)* is present in 2 % of cases. It commonly extends from the aortic arch and supplies the inferior part of the thyroid gland. There is a risk of injury to this artery during tracheostomy.

5 Endocrine component of pancreas– pancreatic islets

The endocrine component of the pancreas is composed of clusters of endocrine cells termed **islets of Langerhans**. The islets of Langerhans **are scattered throughout the pancreas** with the highest density in the pancreatic tail. The islets of Langerhans are richly vascularised by fenestrated capillaries and are covered by fibrous capsules. **The endocrine part of the pancreas is responsible predominantly for insulin and glucagon production and for controlling the concentration of glucose in the blood (glycaemia).**

Histological structure

A-cells – are located in the periphery of the islets
– produce glucagon
B-cells – constitute the main component of the islets
– produce insulin
D-cells – the minority of cells
– are located in the periphery of the islets and produce somatostatin
D1 cells – produce a peptide similar to vasoactive intestinal peptide
PP-cells – produce vasoactive intestinal peptide (VIP) and pancreatic peptide (PP)
EC-cells – produce substance P and serotonin

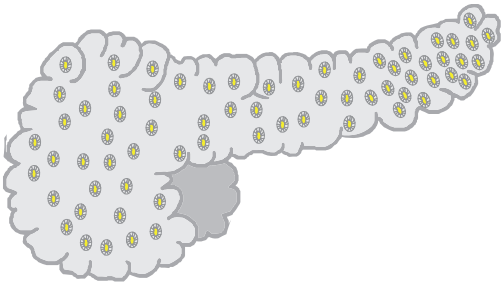
Pancreas with the islets of Langerhans

Clinical notes

Brain sand *(acervulus cerebri)* is a term for calcium deposits in the pineal gland. It can be used as an anatomical landmark in radiological studies.

Pineal gland cysts can compress the cerebral aqueduct, resulting in hydrocephalus.

Diabetes mellitus type 1 occurs as a result of the autoimmune destruction of B-cells mediated by autoantibodies. It is possible to transplant the islets of Langerhans. An emulsion is injected (instilled) into the portal vein and the islets are implanted in the liver.

Goitre *(struma)* is a term for an enlarged thyroid gland.

During thyroidectomy, the surgical procedure to resect the thyroid gland, the recurrent laryngeal nerve can be harmed and the parathyroid glands can be accidentally removed. Injury of the recurrent laryngeal nerve leads to dysphonia, an impairment in voice production. Removal of all parathyroid glands can manifest as severe and life-threatening hypocalcaemia.

The thyroid gland is composed of two lobes connected by an isthmus. The thyroid gland is situated **in front of the trachea** and the isthmus is located **at the level of the second to fourth tracheal rings**. However, in some cases, the thyroid can be located behind the manubrium of the sternum. **Two parathyroid glands are usually positioned on the medial side of each lobe.** Howevever, the location and number of the parathyroid glands can vary. **The gland is supported by thickened strips of the surrounding fibrous tissue**, especially around the vessels. **The thyroid gland secretes the hormones triiodothyronine, thyroxine (tetraiodothyronine), calcitonin and pro-calcitonine. The parathyroid glands produce parathormone.**

Structure

1 **Thyroid gland** (*glandula thyroidea*)
- 1.1 **Right lobe** (*lobus dexter*)
- 1.2 **Left lobe** (*lobus sinister*)
- 1.3 **Isthmus**
- 1.4 **Pyramidal lobe** (*lobus pyramidalis*)

2 **Parathyroid glands** (*glandulae parathyroidae*)

Syntopy

3 **Cranially:** cricothyroid muscle and thyroid gland
4 **Caudally:** trachea, unpaired thyroid plexus, brachiocephalic veins
5 **Ventrally:** infrahyoid muscles
6 **Laterally:** internal carotid artery, internal jugular vein
7 **Medially from lobes:** the inferior part of the larynx, trachea
8 **Dorsomedially from lobes:** recurrent laryngeal nerve (in the tracheooesophageal sulcus)

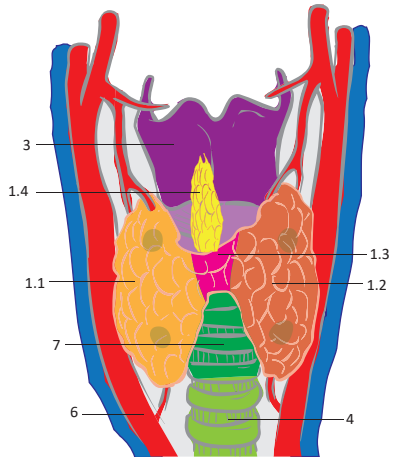

Thyroid gland, anterior view

Histological structure

Thyroid gland

1 **Capsule** – is divided into two sheets, the venous plexus is situated between them
1.1 **Capsula propria** – is located on the surface of the gland and emits fibrous septa
1.2 **Capsula externa** – is continuous with the pretracheal layer of the cervical fascia
2 **Lobules** – contain the colloid-filled thyroid follicles
3 **Follicular cells** – produce triiodothyronine (T3) and thyroxine (T4) hormones
4 **Parafollicular cells (C cells)** – produce calcitonin

Parathyroid glands

1 **Fibrous capsule**
2 **Parenchymal tissue**
3 **Chief cells** – produce parathormone
4 **Oxyphil cells**

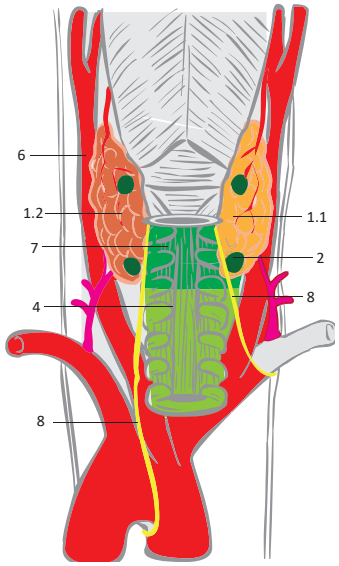

Thyroid gland, posterior view

Blood supply

Arterial blood supply:
– **thyroid gland:** superior thyroid artery (from the external carotid artery)
– **thyroid and parathyroid gland:** inferior thyroid artery (from the thyrocervical trunk)

Venous drainage:
– superior thyroid vein (to the internal jugular vein)
– middle thyroid vein (to the internal jugular vein)
– inferior thyroid vein, veins on both sides are form the unpaired thyroid plexus (to the left brachiocephalic vein)

Lymphatic drainage:
– subcapsular plexus (to the deep cervical lymph nodes)

Innervation

Sympathetic innervation:
– cervical ganglia (nerves entering the gland along arteries)

Parasympathetic innervation:
– **thyroid gland:** superior and recurrent laryngeal nerve (both from the vagus nerve)
– **parathyroid gland:** recurrent laryngeal nerve (from the vagus nerve)

This copy belongs to ali yaghoubi

The adrenal gland is a paired organ. The right adrenal gland is triangular in shape and the left adrenal gland is semilunar-shaped. **The adrenal glands are positioned on the upper poles of the kidneys (retroperitoneally) at the level of T11–T12**. The right adrenal gland is situated more caudally than the left one. **Fixation of the adrenal glands is provided by vessels**. The adrenal veins leave the glands through the hilum, which is situated on the anterior surface. The adrenal gland is covered by a thin capsule which emits septa into the gland. On cross section, the gland consists of cortex and medulla. **The cortex produces mineralocorticoids, glucocorticoids and androgens. The medulla is responsible for catecholamine secretion.**

Syntopy

- 1 **Cranially:** diaphragm, subhepatic space
- 2 **Caudally:** upper pole of the kidney
- 3 **Ventrally on the right side:** liver
- 4 **Ventrally on the left side:** stomach
- 5 **Ventrally on both sides:** prerenal layer of the renal fascia, perirenal fat capsule
- 6 **Dorsally:** perirenal fat capsule, retrorenal layer of the renal fascia, pararenal fat body, diaphragm, costodiaphragmatic recess
- 7 **Medially on the right side:** inferior vena cava
- 8 **Medially on the left side:** abdominal aorta
- 9 **Laterally:** pararenal fat body

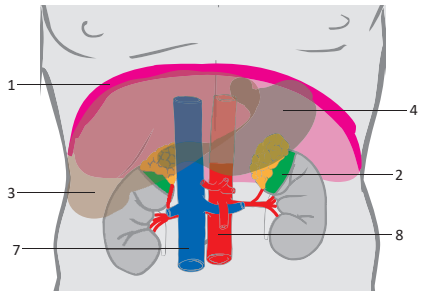

Syntopy of the adrenal glands, anterior view

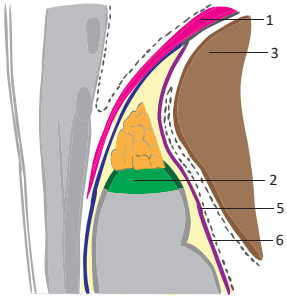

Syntopy of the right adrenal gland in the sagittal section of the body

Histological structure

Cortex

1 **Zona glomerulosa** – groups of polyedric cells
– produces mineralocorticoids
2 **Zona fasciculata** – parallel fascicles
– produces glucocorticoids
3 **Zona reticularis** – spatial arrangement of fascicles
– produces androgens

Medulla

1 **A cells** – produce epinephrine
2 **N cells** – produce norepinephrine
3 **Ganglion cells**

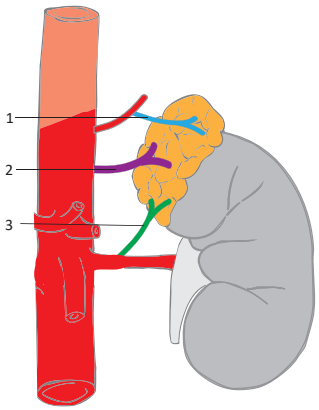

Anterior view of the aorta, left kidney and adrenal gland

Blood supply and innervation

Arterial blood supply:

- 1 **Superior adrenal/suprarenal artery** – from the inferior phrenic artery
- 2 **Middle adrenal/suprarenal artery** – from the abdominal aorta
- 3 **Inferior adrenal/suprarenal artery** – from the renal artery

Venous drainage:

– suprarenal veins (on the right side into the inferior vena cava, on the left into the left renal vein)

Lymphatic drainage: lumbar nodes and posterior mediastinal nodes

Sympathetic and parasympathetic part of the autonomic nervous system, sensory:

– adrenal/suprarenal plexus

The accessory suprarenal glands / Marchand´s adrenals can be present anywhere along the path of the descent of the gonads.

Cortical and medullar arteries originate from the subcapsular plexus (formed by the suprarenal arteries). Veins are not present in the cortex and blood is drained into the capillaries of the medulla. This arrangement is important for the regulation of epinephrine secretion.

Fascia of Toldt is an eponym for the prerenal layer of the renal fascia (Gerota's fascia).

Fascia of Zuckerkandl is the retrorenal layer of the renal fascia (Gerota's fascia).

Clinical notes

Phaeochromocytoma is a tumour of the adrenal medulla that causes an irregular secretion of catecholamines, which manifests as paroxysms of hypertension and tachycardia .

Cushing syndrome is a term for the collection of symptoms caused by high levels of glucocorticoids. This syndrome is most commonly caused by iatrogenic administration of cortisol but may also be a manifestation of a pituitary adenoma.

Conn's syndrome is a term for a hyper-functioning adrenal cortex causing an increased production of mineralocorticoids (hyperaldosteronism).

Addison's disease is a term for a hypo-functioning adrenal cortex with insufficient production of glucocorticoids (hypocorticalism).

Tissue or organ	Hormones
Brain	endorphins, enkephalins, dynorphin, serotonin
Hypothalamus	thyrotropin-releasing hormone, gonadotropin-releasing hormone, growth hormone-releasing hormone, corticotropin-releasing hormone, somatostatin, dopamine
Adenohypophysis	somatotropin, prolactin, adrenocorticotropic hormone, thyroid-stimulating hormone, luteinizing hormone, follicle-stimulating hormone
Neurohypophysis	oxytocin, vasopressin
Epiphysis	melatonin
Thyroid gland	triiodothyronine, thyroxine (tetraiodothyronine), calcitonin
Parathyroid gland	parathormone
Heart	atrial natriuretic factor
Stomach, intestine	gastrin, ghrelin, cholecystokinin, IGF, motilin, neuropeptide Y, somatostatin, serotonin
Liver	IGF, thrombopoietin
Islets of Langerhans	glucagon, insulin, somatostatin, pancreatic polypeptide
Kidneys	calcitriol (the active form of vitamin D3), erythropoietin, serotonin
Adrenal cortex	aldosterone, cortisol, dihydroepiandrosterone, androstenedione
Adrenal medulla	epinephrine, norepinephrine, dopamine
Testes	testosterone
Ovarian follicle	estrogens (estradiol, estrone, estriol)
Corpus luteum	gestagens (progesterone), estrogen (estradiol, estrone, estriol), androstenedione
Placenta	gestagens (progesterone), estrogen (estradiol, estrone, estriol), human chorionic gonadotropin (hCG), human placental lactogen / chorionic somatomamotropin (HCP hPL), hACTH
Skin	calciferol, cholecalciferol (provitamin D)
Adipose tissue	leptin, adiponectin

9 Review questions and figures

I. General part

1. Explain the pathway of hormones from their place of origin to their targeted structures. (p. 522)
2. Name the seven endocrine glands. (p. 522)

II. Diffuse neuroendocrine system

3. Define the term paraganglia. (p. 522)
4. Explain the relationship between the carotid body and carotid sinus (p. 522)
5. Define the location of the Organ of Zuckerkandl. (p. 522)

III. Pituitary Gland

6. Describe the structure of the pituitary gland. Name the two lobes and their parts. (p. 523)
7. Name the structures surrounding the hypophysis. (p. 523)
8. Name the hormones produced in the adenohypophysis. (p. 523)
9. Explain the term "portal system of the hypophysis" and state its function. (p. 523)

IV. Pineal Gland

10. Describe the position of the pineal gland and the structures in its proximity. (p. 524)
11. Name the hormone/s produced in the pineal gland. (p. 524)

V. Endocrine components of the pancreas

12. Describe the location of the islets of Langerhans in the pancreas. (p. 524)
13. Name the cell types in the islets of Langerhans. (p. 524)

VI. Thyroid and parathyroid gland

14. Name the parts of the thyroid gland. (p. 525)
15. Draw the relationship of the thyroid gland to the recurrent laryngeal nerve. (p. 525)
16. Name the arteries and veins of the thyroid gland and describe the blood supply of the parathyroid glands. (p. 525)
17. Specify the cell types of the thyroid gland and name the secreted hormones. (p. 525)

VII. Adrenal gland

18. Name all the layers of the adrenal cortex. (p. 526)
19. Name the arteries supplying the adrenal gland. (p. 526)

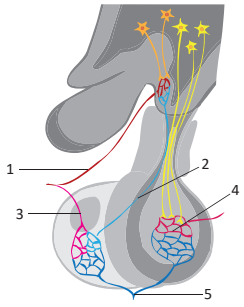

Describe the blood supply of the hypophysis

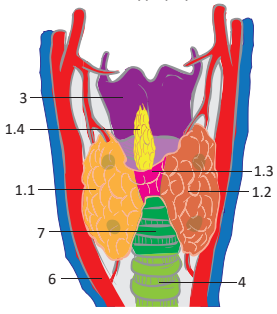

Describe the structure and syntopy of the thyroid gland

This copy belongs to ali yaghoubi

We would like to **thank the following anatomists, physicians and medical students** for their invaluable help, devotion and feedback in the preparation of this chapter.

Anatomists

Assoc. prof. Nihal Apaydın, MD – Department of Anatomy, Faculty of Medicine, Ankara University, Ankara, Turkey
Prof. Susana N. Biasutto, MD – Faculty of Medical Sciences, National University of Córdoba, Argentina

Clinicians

Aravind Ganesh, MD – Department of Neurology, Foothills Medical Centre and University of Calgary, Calgary, Canada

Medical students

Adéla Kuklová
Linda Kašičková

10 References

1. AGUR, A. M. R. and A. F. DALLEY. Grant's Atlas of Anatomy. 13th Ed. Philadelphia: Lippincot Williams & Wilkins, 2012, 888 p. ISBN 978-1-60831-756-1.
2. GEMSENJAEGER, E. Atlas of thyroid surgery. New York: Thieme, 2009. 184 p. ISBN 978-3-13-145031-9.
3. NETTER, F. H. Atlas of Human Anatomy. Professional Edition. 6th Ed. Oxford: Elsevier. 2014. 640 p. ISBN 978-1-455-75888-3.
4. ROHEN, J. W. LUTJEN-DRECOLL, E. and C. YOKOCHI. Color Atlas of Anatomy: A Photographic Study of the Human Body. 7th Ed. Stuttgart: Lippincot Williams & Wilkins, 532 p. ISBN 978-1-58255-856-1.
5. SCHWARTZ, T. H. and V. K. ANAND. Endoscopic pituitary surgery: endocrine, neuro-ophthalmologic, and surgical management. 1st Edition. New York: Thieme, 2012, 384 p. ISBN 978-1-60406-347-9.
6. SNELL, R. S. Clinical anatomy by regions. 9th Ed. Philadelphia: Lippincott Williams & Wilkins, 2012. 768 p. ISBN 978-1-60913-446-4.
7. SNELL, R. S. Clinical Neuroanatomy. 7th Edition. Philadelphia: Lippincot Williams & Wilkins, 2009, 560 p. ISBN 978-0-7817-9427-5.
8. WILLIAMS, P. L., ed. Gray´s Anatomy: the anatomical basis of medicine and surgery. 38th Ed. New York: Churchill Livingstone, 1995, 2092 p. ISBN 0-443-05717-6.

Memorix Anatomy

15 Topography

Jakub Miletín
David Kachlík
Radovan Hudák
Ondřej Volný

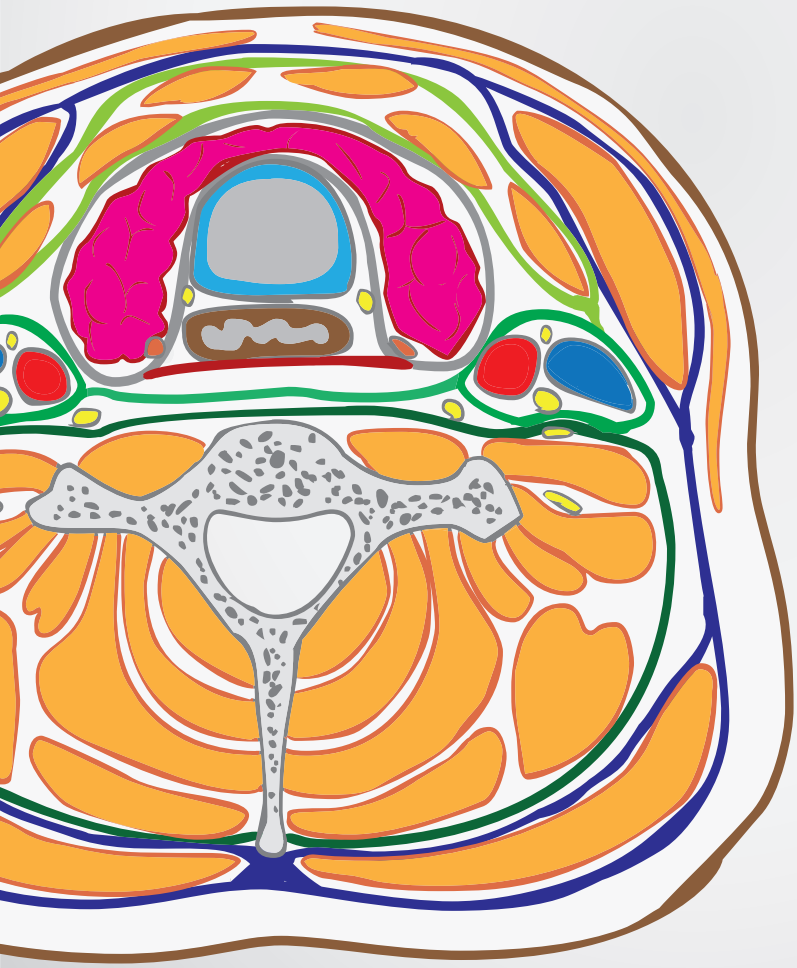

Topography of the head 530
Topography of the neck 542
Topography of the thorax 548
Topography of the abdomen 554
Topography of the pelvis 564
Topography of the back 568
Topography of the upper limb 570
Topography of the lower limb 578
Sections 586
Review questions and figures 595
Acknowledgements and references 600

This copy belongs to ali yaghoubi

The head contains a series of interconnected topographical regions. These regions can be divided into those of the **splanchnocranium** and those of the **neurocranium**. They may be classified as **open regions**, which are in direct contact with the external environment and **closed regions**, which are not. The pterygopalatine fossa connects to all the main regions of the skull and therefore can be considered their centre. The neurocranium consists of the cranial cavity and the orbits. Anatomically, the middle ear cavities and orbits are considered to be part of the neurocranium. However, clinically and practically they belong to the splanchnocranium.

Topographical regions of the head

- 1 **Neurocranium**
  - 1.1 **Orbit**
  - 1.2 **Cavernous sinus**
  - 1.3 **Internal acoustic meatus / internal ear canal**
  - 1.4 **Tympanic cavity**
  - 1.5 **Cranial cavity**
    - 1.5.1 **Anterior cranial fossa**
    - 1.5.2 **Middle cranial fossa**
    - 1.5.3 **Posterior cranial fossa**
  - 1.6 **Temporal fossa**
  - 1.7 **External acoustic meatus**

- 2 **Splanchnocranium**
  - 2.1 **Oral cavity**
  - 2.2 **Nasal cavity**
  - 2.3 **Paranasal sinuses**
  - 2.4 **Pterygopalatine fossa**
  - 2.5 **Infratemporal fossa**

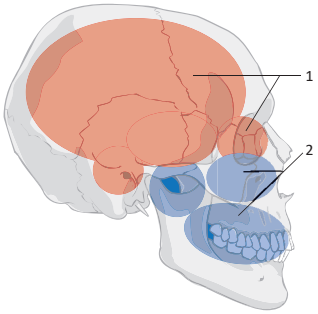

Scheme of the topographical regions of the skull

Main passages of the skull

1 **Cribriform plate**
2 **Superior orbital fissure and optic canal**
3 **Foramen rotundum**
4 **Foramen ovale**
5 **Pterygomaxillary fissure and pterygoid canal**
6 **Inferior orbital fissure**
7 **Sphenopalatine foramen**
8 **Ethmoidal foramina**
9 **Semilunar hilus**
10 **Palatine foramina**
11 **Incisive canal**

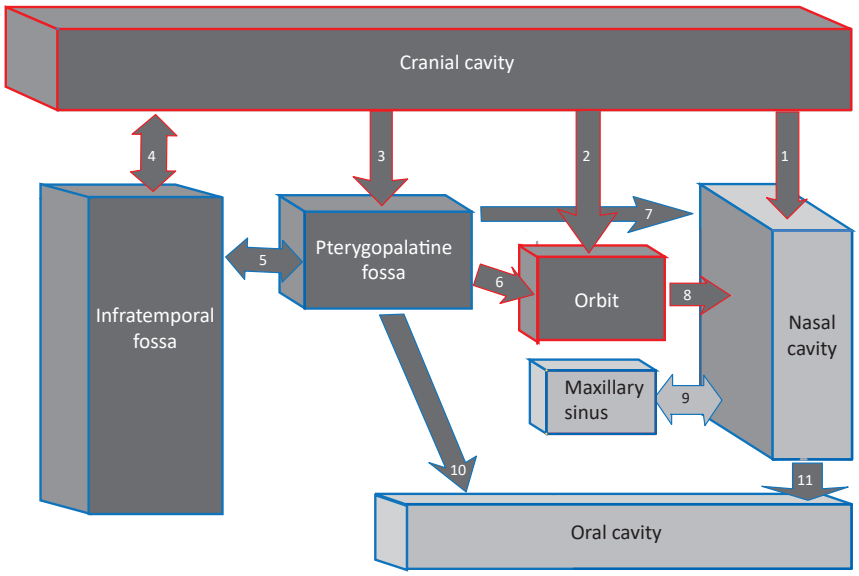

- **Closed spaces**
- **Open spaces**

Scheme of the topographical regions of the skull and the passages between them

Topography

The superficial muscular-aponeurotic system (SMAS) is a plane of fibromuscular tissue that covers the mimetic muscles and anchors them to the skin via fibrous septa. It is continuous with the epicranial aponeurosis superiorly and the platysma inferiorly. It is manipulated in the facelift surgery.

The epicranial aponeurosis is firmly attached to the skin, but not to the underlying periosteum from which it is separated by the subgaleal loose connective tissue.

The subgaleal loose connective tissue allows the scalp to be easily removed from the skull, a process known as scalping.

The epicranial aponeurosis is held under tension. This means that a transverse cut, parallel to the direction of its fibres, will cause the scalp to gape (the wound to widened).

A mnemonic for the layers of the scalp:
S: skin
C: connective tissue
A: aponeurosis
L: loose connective tissue
P: periosteum

Clinical notes

Infection may spread directly from the middle ear cavity, nasal cavity or paranasal sinuses to the neurocranium causing meningitis. Alternatively infection may reach the neurocranium from a distal source via the blood or may be directly implanted in the neurocranium following head trauma.

Three types of bleeding in the scalp commonly occur as manifestations of birth trauma. They are differentiated by the location of the bleeding in the scalp.
A subgalear haematoma is bleeding between the periosteum and the epicranial aponeurosis (in the subgaleal area). The bleeding crosses the sutures. Its insidious nature can lead this type of bleeding to be very extensive and may lead to exsanguination of the baby.
Caput succedaneum is a subcutaneous collection of serosanguineous fluid.
A cephalhaematoma is a subperiostal hematoma of the skull. The bleeding is confined between the periosteum and the skull and so does not cross the sutures.

The scalp is formed from several layers of different types of tissue. Most superficial is the **skin**, which is thick and covered with hair. Beneath the **subcutaneous tissue** lies the **epicranial aponeurosis**, a flattened tendon providing attachments of the occipitofrontalis and the temporoparietalis. The **subgaleal connective tissue** lies underneath the epicranial aponeurosis and allows it to move smoothly over the periosteum. The **calvaria** (skullcap) lies under the scalp and the cranial dura mater is located on its internal surface.

Layers of the scalp

- 1 **Skin**
- 2 **Subcutaneous tissue**
- 3 **Epicranial aponeurosis** (*galea aponeurotica*)
- 4 **Subgaleal connective tissue**
- 5 **Pericranium**

Calvaria and dura mater

- 6 **Calvaria**
  - 6.1 **External table** (*lamina externa calvariae*)
  - 6.2 **Diploe**
  - 6.3 **Internal table** (*lamina interna calvariae*)
- 7 **Cranial dura mater** *(dura mater cranialis)*
- 8 **Subcutaneous neurovascular bundles**
- 9 **Superior sagittal sinus**
  - 9.1 **Emissary veins**
  - 9.2 **Diploic veins**
  - 9.3 **Arachnoid granulations of Pacchioni**

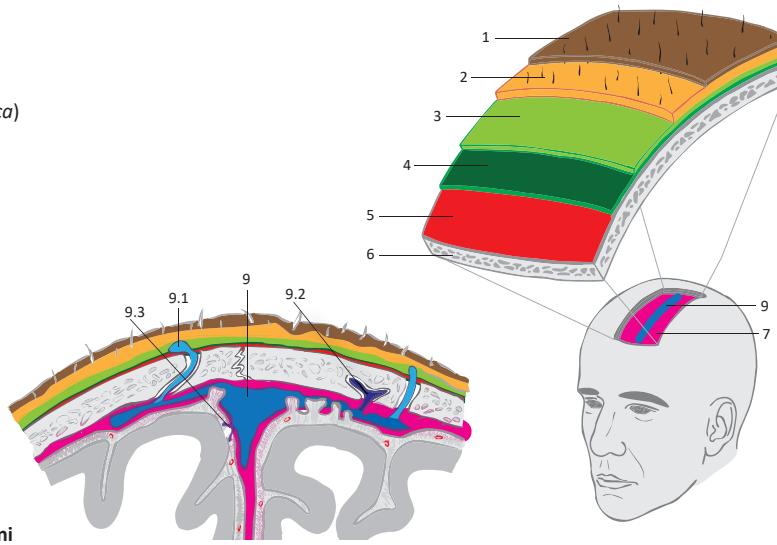

Frontal section through the scalp and calvaria

1.2 Layers of the cheek

The cheek consists of a number of layers of different types of tissue from the skin of the face to the mucous membrane of the oral vestibule. The cheek contains **facial muscles**, **glands** and **nerves**. The facial muscle layer is well developed in the cheek. It consists of several muscles, which converge just laterally to the angle of the mouth forming a structure called the **modiolus**.

- 1 **Skin**
- 2 **Subcutaneous tissue**
  - 2.1 **Facial muscles**
  - 2.2 **Facial artery and vein**
  - 2.3 **Transverse facial artery and vein**
  - 2.4 **Buccal branches of facial nerve**
  - 2.5 **Buccal fat pad of Bichat**
  - 2.6 **Buccal nerve**
  - 2.7 **Buccal artery and vein**
  - 2.8 **Parotid duct**
- 3 **Muscular layer**
  - 3.1 **Buccinator**
  - 3.2 **Pterygomandibular raphe**
  - 3.3 **Pharyngeal wall**
- 4 **Submucous tissue**
  - 4.1 **Bucal glands**
- 5 **Mucous membrane**

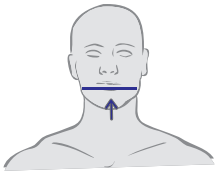

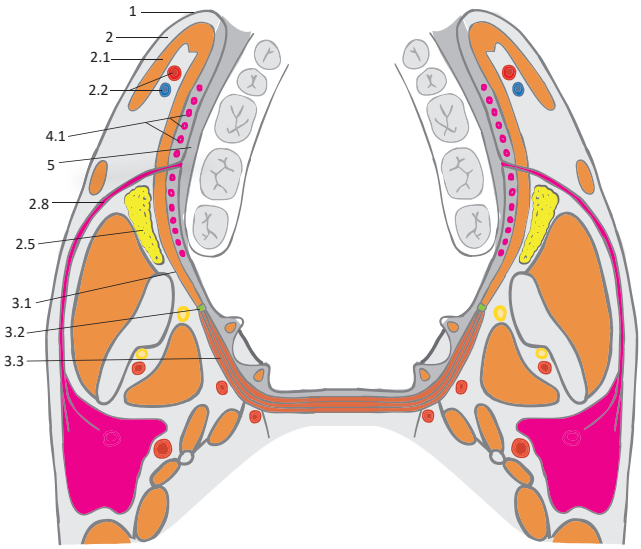

Transverse section through the oral cavity at the level of vertebral C2

This copy belongs to ali yaghoubi

The orbit (eye socket) is a bony case that provides **support** and **mechanical protection** for the eye and its accessory structures. It is a four-sided pyramid, with the base projecting forwards. The walls of the orbit have different thicknesses. The lateral wall and roof are thicker and the medial wall and floor are thinner. The **orbital septum** extends from the periosteum of the orbit to the fibrous layer of the eyeball. It separates the **orbit proper** from the **palpebral region**.

Boundaries

Cranially:
- 1 **Frontal bone – the orbital part**
- 2 **Sphenoid bone – the lesser wing**

Medially:
- 3 **Maxilla – the frontal process**
- 4 **Lacrimal bone**
- 5 **Ethmoidal bone – the orbital plate**
- 6 **Sphenoid bode – the lesser wing**

Laterally:
- 7 **Zygomatic bone – the orbital surface**
- 8 **Sphenoid bone (greater wing) – the orbital surface**

Caudally:
- 9 **Maxilla (body) – the orbital surface**
- 10 **Zygomatic bone – the orbital surface**
- 11 **Palatine bone – the orbital process**

Ventrally:
Orbital opening (*aditus orbitalis*)

Dorsally:
Orbital apex (*apex orbitalis*)

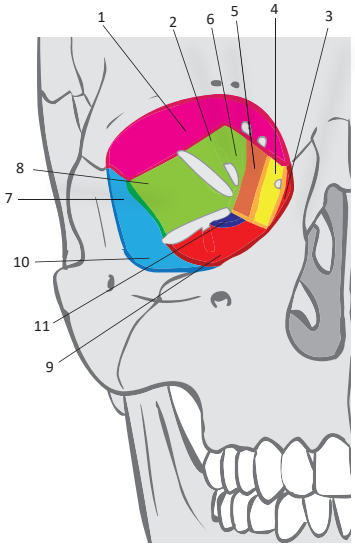

Passages

- 1 **Superior orbital fissure**
  - 1.1 Oculomotor nerve
  - 1.2 Nasociliary nerve (branch of n. V1)
  - 1.3 Abducent nerve
  - 1.4 Trochlear nerve
  - 1.5 Frontal nerve (branch of n. V1)
  - 1.6 Lacrimal nerve (branch of n. V1)
  - 1.7 Superior ophthalmic vein
- 2 **Inferior orbital fissure**
  - 2.1 Zygomatic nerve (branch of n. V2)
  - 2.2 Nervus infraorbitalis (branch of n. V2)
  - 2.3 Infraorbital artery (branch of the maxillary artery)
  - 2.4 Inferior ophthalmic vein
- 3 **Optic canal**
  - 3.1 Optic nerve
  - 3.2 Ophthalmic artery
  - 3.3 Ophthalmic plexus
- 4 **Frontal and supraorbital foramina**
  - 4.1 Supraorbital nerve (branch of n. V1)
  - 4.2 Supraorbital artery and vein (branch of the ophthalmic artery)
- 5 **Anterior and posterior ethmoidal foramina**
  - 5.1 Anterior and posterior ethmoidal artery and vein (branch of the ophthalmic artery and tributary of ophthalmic veins)
  - 5.2 Anterior and posterior ethmoidal nerve (branch of n. V1)
- 6 **Zygomaticoorbital foramen**
  - 6.1 Zygomatic nerve (branch of n. V2)
- 7 **Infraorbital groove and canal**
  - 7.1 Infraorbital nerve (branch of n. V2)
  - 7.2 Infraorbital artery (branch of the maxillary artery)
  - 7.3 Infraorbital vein (tributary of the inferior ophthalmic vein)
- 8 **Nasolacrimal canal**
  - 8.1 Nasolacrimal duct

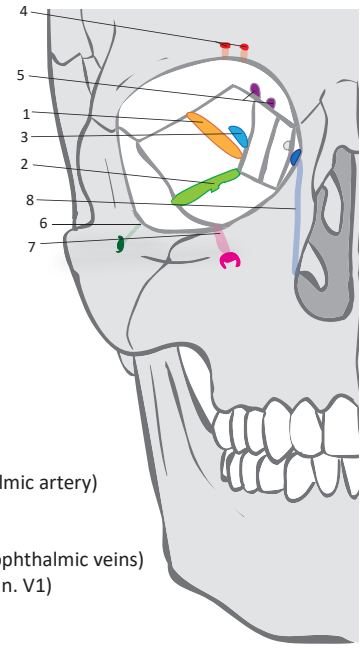

Topography

Lamina papyracea is an obsolete term used for the medial wall of the orbit. It is very thin and liable to fracture.

The orbital septum *(septum orbitale)* is a thick fibrous connection between the periosteum of the orbit and the fascia of the eyeball.

The orbital fat body *(corpus adiposum orbitae)* is a fat pad located behind the eyeball.

The orbit and the pterygopalatine fossa communicate through the inferior orbital fissure.

The orbitalis muscle *(musculus orbitalis)* is a smooth muscle closing the lateral part of the inferior orbital fissure.

The nasolacrimal canal is a pathway from the orbit to the inferior nasal meatus, through which the nasolacrimal duct passes.

Clinical notes

Blow-out fractures are fractures of the floor of the orbit caused by direct hits to the eyeball, typically caused by a ball or a fist. The rectus lateralis muscle may become trapped by the fracture fragments causing diplopia (double vision) and impaired eye movements. A pathological communication may be formed between the orbit and the maxillary sinus. This can lead to orbital emphysema (air in the orbit). The margin of the orbit is not affected, disguising the severity of the condition.

In older age, the orbital fat pad prolapses into the eyelids. This increases the work of eyelid movements and is cosmetically unpleasant. It can be corrected by surgical extraction of the prolapsed adipose tissue and removal of some of the eyelid skin (blepharoplasty).

The venous system of the eye communicates with the venous system of the face and the pterygopalatine fossa. This allows inflammation in the orbit to spread easily.

Levels

- 1 **Upper level** – between the ceiling of the orbit and the levator palpebrae superioris
- 2 **Middle level** – between the rectus superior and a virtual plane at the level of the optic nerve
- 3 **Bottom level** – between a virtual plane at the level of the optic nerve and the floor of the orbit

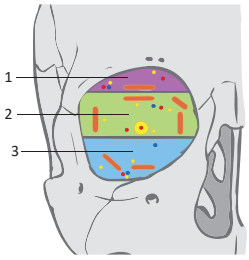

Right orbit, front view

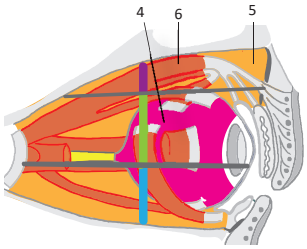

Sagittal section of the right orbit, lateral view

In all the levels

- 4 **Eyeball** (*bulbus oculi*)
- 5 **Retrobulbar fat / orbital fat pad** (*corpus adiposum orbitae*)
- 6 **Extraocular muscles** (*musculi externi bulbi oculi*) – the oculomotor muscles and levator palpebrae superioris

Upper level

- 1 **Lacrimal nerve, artery and vein**
- 2 **Lacrimal gland – the orbital part**
- 3 **Frontal nerve**
  - 3.1 **Supra-orbital nerve**
  - 3.2 **Supratrochlear nerve**
- 4 **Supraorbital artery and vein**
- 5 **Supratrochlear artery and vein**
- 6 **Trochlear nerve**
- 7 **Levator palpebrae superioris**

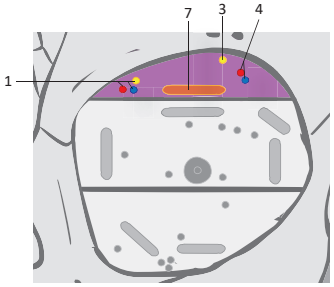

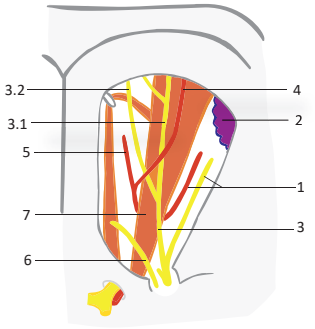

Right orbit, superior view

Middle level

- 1 **Superior rectus**
- 2 **Lateral rectus**
- 3 **Medial rectus**
- 4 **Superior oblique**
- 5 **Optic nerve, central retinal artery and vein**
- 6 **Nasociliary nerve**
- 7 **Oculomotor nerve** (and its branches)
- 8 **Abducent nerve**
- 9 **Ciliary ganglion**
- 10 **Ophthalmic artery and its sympathetic plexus**
- 11 **Superior ophthalmic vein**
- 12 **Lacrimal gland – the palpebral part**

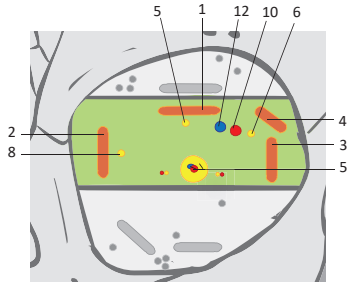

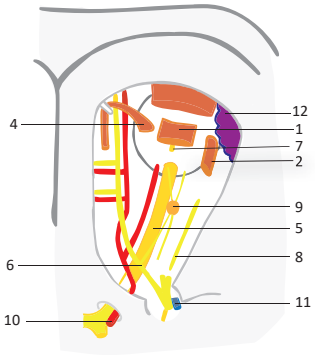

Right orbit, superior view

Lower level

- 1 **Inferior rectus**
- 2 **Inferior oblique**
- 3 **Oculomotor nerve** (and its branches)
- 4 **Infraorbital nerve**
- 5 **Zygomatic nerve**
- 6 **Infraorbital artery and vein**
- 7 **Inferior ophthalmic vein**
- 8 **Orbitalis / orbital muscle**
- 9 **Lacrimal sac**

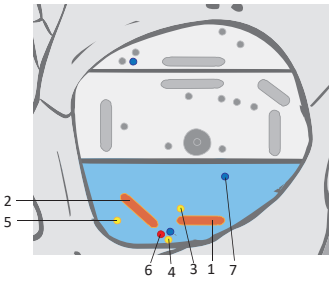

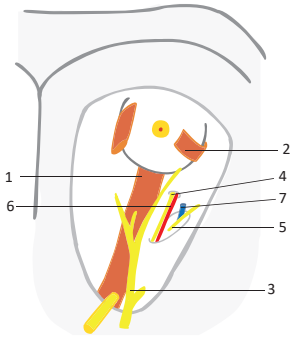

Right orbit, superior view

This copy belongs to ali yaghoubi

1.4 Common tendinous ring – Anulus tendineus communis

The common tendinous ring *(anulus tendineus communis)*, also know as the annulus of Zinn, is a fibrous ring encircling the opening of the optic canal and the medial part of the superior orbital fissure at the apex of the orbit. It serves as the origin of all the extra-ocular muscles except for the inferior oblique.

Contents

- 1 **Optic nerve**
- 2 **Ophthalmic artery**
- 3 **Sympathetic ophthalmic plexus**
- 4 **Oculomotor nerve**
  – both branches
- 5 **Abducent nerve**
- 6 **Nasociliary nerve**

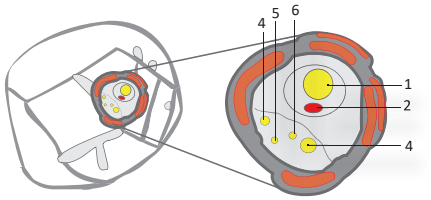

The common tendinous ring viewed from inside the right orbit

1.5 Cavernous sinus – Sinus cavernosus

The cavernous sinus is a paired dural venous sinus. It is bound ventrally by the **superior orbital fissure**, dorsally by the **apex of the petrous part of the temporal bone** and medially by the **hypophyseal fossa**. It interconnects several other dural venous sinuses and veins. It develops from a venous plexus around the internal carotid artery and **represents the only place in the body where an artery passes through a vein**.

Content

In the whole sinus:
- 1 **Venous blood**

Centrally:
- 2 **Internal carotid artery** – with the sympathetic internal carotid plexus around it

Running vertically through the sinus:
- 3 **Abducent nerve**

Descending in the lateral wall:
- 4 **Oculomotor nerve**
- 5 **Trochlear nerve**
- 6 **Ophthalmic nerve**
- 7 **Maxillary nerve**

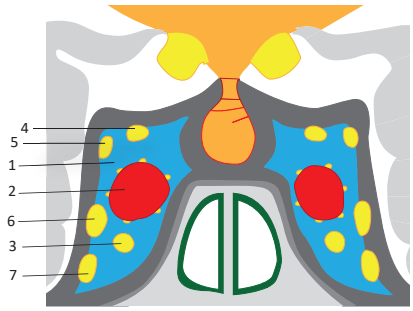

Frontal section through the pituitary gland and cavernous sinus

1.6 Internal acoustic meatus – Meatus acusticus internus

The internal acoustic meatus is a canal located inside the temporal bone. It extends from the internal acoustic opening in the posterior cranial fossa to the fundus of the acoustic meatus. The fundus of the internal acoustic meatus is divided by a transverse and a vertical crest into **four quadrants** and transmits two **cranial nerves (facial and vestibulocochlear nerve)**.

Superior anterior quadrant
- 1 **Facial nerve area** (*area nervi facialis*) – facial nerve

Inferior anterior quadrant
- 2 **Cochlear area** (*area cochlearis*) – cochlear nerve

Superior posterior quadrant
- 3 **Superior vestibular area** (*area vestibularis superior*)
  – utriculoampullary nerve
  (part of vestibular nerve)

Inferior posterior quadrant
- 4 **Inferior vestibular area**
  – saccular nerve (part of vestibular nerve)
- 5 **Foramen singulare** – posterior ampullary nerve from the vestibular nerve

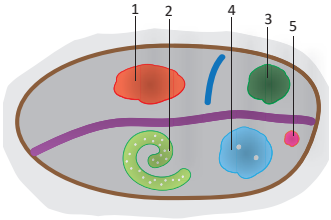

Scheme of the right internal acoustic meatus

Topography

The internal acoustic meatus contains the labyrinthine artery and veins as well as cranial nerves VII and VIII.

The upper part of the tympanic cavity is the widest part and is termed the epitympanic recess (*recessus epitympanicus, atticus, epitympanon*).

The middle ear cavity consist of tympanic cavity, mastoid antrum, mastoid cells, tympanic cells and the auditory tube.

Clinical notes

A cavernous sinus thrombosis is a medical emergency, usually occurring as complication of an infection of the face. The thrombosis can compress the nerves of the cavernous sinus (causing strabismus) and cause ischaemic damage to the brain.

The cavernous sinus is interconnected with the splanchnocranial venous riverbed by a system of venous connections. These connections may provide a way for infections to enter the neurocranium via the bloodstream.

An aneurysm of the internal carotid artery inside the cavernous sinus may compress its neighbouring nerves (the optic chiasma on the medial side and cranial nerves III, IV, V and VI on the lateral side) causing peripheral neurological symptoms.

The tympanic cavity is a small space inside the petrous part of the temporal bone. It is often schematically depicted as a cube. Its six walls are described with terms derived from the major structures of the area. The tympanic cavity houses the **three auditory ossicles**. The **auditory tube** and **mastoid antrum** both open into the tympanic cavity. The mastoid antrum connects the tympanic cavity to the mastoid air cells. The **eardrum** (tympanic membrane) separates the tympanic cavity from the external auditory meatus.

Boundaries

1 **Laterally: Membranous wall**
– tympanic membrane
2 **Medially: Labyrinthine wall**
– the ventrobasal surface of the petrous part of the temporal bone
3 **Ceiling: Tegmental wall**
– part of the anterior surface of the petrous part of the temporal bone
4 **Floor: Jugular wall**
– part of the inferior surface of the petrous part of the temporal bone
5 **Dorsally: Mastoid wall** – mastoid process
6 **Ventrally: Carotid wall**
– the posterior wall of the carotid canal

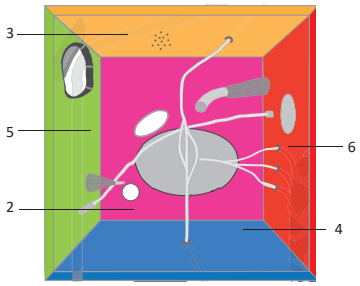

Scheme of the right tympanic cavity, lateral view after removal of the tympanic membrane

Features

1 **Laterally**
1.1 **Tympanic membrane / eardrum**
2 **Medially – labyrinthine wall**
2.1 **Promontory** – a hollow convexity in the middle of the wall, formed by the first turn of the cochlea
2.2 **Oval window** (*fenestra vestibuli*) – a communication with the bony labyrinth (vestibule)
2.3 **Round window** (*fenestra cochleae*) – a communication with the bony labyrinth (scala tympani)
3 **Ceiling – tegmental wall**
3.1 **Canal for lesser petrosal nerve** – contains the lesser petrosal nerve (a continuation of the tympanic nerve) and superior tympanic vessels
3.2 **Epitympanic recess** – an extension of the tympanic cavity above the eardrum containing the head of the malleus and the body of the incus
4 **Floor – jugular wall**
4.1 **Tympanic canaliculus** – contains the tympanic nerve and inferior tympanic vessels
5 **Dorsally – mastoid wall**
5.1 **Aditus to mastoid antrum**
– leads to the mastoid antrum and mastoid cells
5.2 **Prominence of lateral semicircular canal**
5.3 **Prominence of facial canal**
5.4 **Pyramidal eminence** – contains the stapedius muscle
5.5 **Tympanic aperture of canaliculus for chorda tympani**
6 **Ventrally – carotid wall**
6.1 **Musculotubal canal**
6.1.1 **Tensor tympani**
6.1.2 **Auditory tube of Eustachio**
6.2 **Petrotympanic fissure** – contains the chorda tympani and anterior tympanic vessels
6.3 **Caroticotympanic canaliculi**
– contains the caroticotympanic nerves and vessels

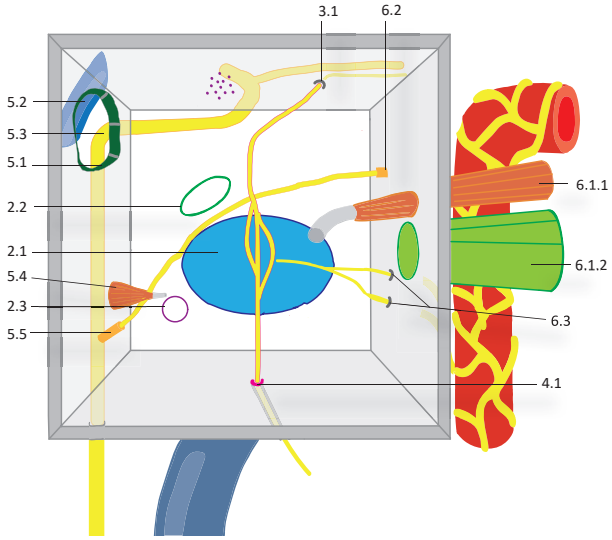

Content

1 **Auditory ossicles**
2 **Stapedius**
3 **Tensor tympani**
4 **Chorda tympani** – branch of n. VII
5 **Tympanic nerve** – branch of n. IX
6 **Tympanic plexus**
7 **Caroticotympanic nerves and small arteries**
8 **Lesser petrosal nerve** – the continuation of the tympanic nerve
9 **Tympanic arteries and veins** – anterior, posterior, superior and inferior

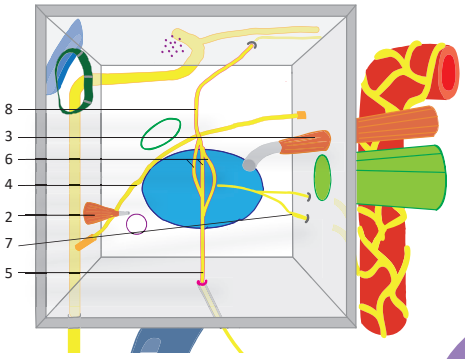

This copy belongs to ali yaghoubi

The nasal cavity is a segmented **air-filled space** located behind the nose. It consists of the **nasal vestibule** and the **bony nasal cavity**. It is divided into left and right parts by the **nasal septum**. The lateral walls of the nasal cavity are the medial walls of the orbits. The **nasal conchae** project into the nasal cavity from the lateral wall.

Boundaries

1 **Ceiling**
- 1.1 **Septal nasal cartilage** – lateral process
- 1.2 **Nasal bone**
- 1.3 **Nasal part of frontal bone**
- 1.4 **Cribriform plate of ethmoidal bone**
- 1.5 **Body of sphenoid bone**

2 **Floor**
- 2.1 **Incisive bone**
- 2.2 **Palatine process of maxilla**
- 2.3 **Horizontal plate of palatine bone**

3 **Lateral wall**
- 3.1 **Nasal bone**
- 3.2 **Frontal process of maxilla**
- 3.3 **Nasal surface of maxilla**
- 3.4 **Inferior nasal concha**
- 3.5 **Lacrimal bone**
- 3.6 **Ethmoidal labyrinth**
- 3.7 **Perpendicular plate of palatine bone**
- 3.8 **Medial plate of pterygoid process of sphenoid**

4 **Nasal septum**
- 4.1 **Bony part**
  - 4.1.1 **Vomer**
  - 4.1.2 **Perpendicular plate of ethmoidal bone**
- 4.2 **Cartilaginous part**
  - 4.2.1 **Septal nasal cartilage**
- 4.3 **Membranous part**
- 4.4 **Cutaneous part**

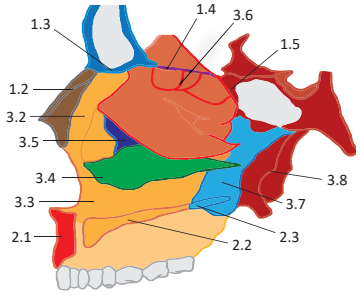

Oblique section of the nasal cavity

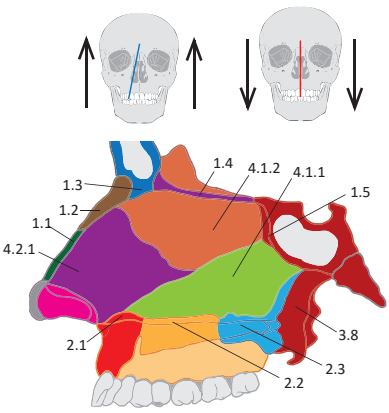

Sagittal section of the nasal cavity

Nasal conchae and meatuses

Conchae

1 **Superior nasal concha**
2 **Middle nasal concha**
3 **Inferior nasal concha**

Meatuses and openings of the paranasal sinuses

4 **Superior nasal meatus** – is located between the ceiling of the nasal cavity and middle nasal concha
- 4.1 **Sphenoidal sinus**
- 4.2 **Posterior ethmoidal cells**

5 **Middle nasal meatus** – is located between the middle and inferior nasal concha
- 5.1 **Anterior and middle ethmoidal cells**
- 5.2 **Frontal sinus**
- 5.3 **Maxillary sinus**

6 **Inferior nasal meatus** – is located between the inferior nasal concha and the floor of the nasal cavity
- 6.1 **Nasolacrimal duct**

7 **Common nasal meatus** – is located between the medial edges of the nasal conchae and the nasal septum

8 **Nasopharyngeal meatus** – is located between the dorsal edges of the nasal conchae and the choanae

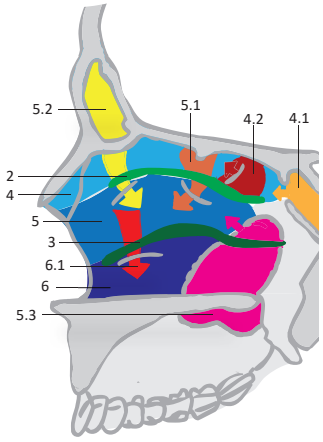

The location of the paranasal sinuses and their openings

Topography

The conchae are clinically referred to as the turbinates.

The maxillary sinus (antrum of Highmore) opens into the nasal cavity through the semilunar hiatus.

The canal of Dorello *(canalis nervi abducentis)* contains the abducent nerve as it passes through the cranial dura mater.

The ethmoidal bulla *(bulla ethmoidalis)* is formed by ethmoidal air cells bulging into the middle nasal meatus. The middle ethmoidal cells open on or near to it.

The zygomaticotemporal branch of the zygomatic nerve emerges from the zygomatic bone through the zygomaticotemporal foramen.

The nasal conchae are covered by a highly vascularized epithelium, which warms the air passing into the lungs.

Physiological deviation of the nasal septum is a common condition, present to some degree in almost every human being.

Clinical notes

Leakage of cerebrospinal fluid from the nose is called nasal liquorrhoea. A fracture of the roof of the nasal cavity can cause cerebrospinal fluid to leak into and out of the nose, which the patient may recognise as a runny nose. This condition is associated with a high risk of central nervous system infections.

Kiesselbach's plexus (*locus Kiesselbachi*) is located on the nasal septum. It contains a high density of capillaries and is the most common source of epistaxis (nasal bleeding).

An oral-antral communication is a pathological opening of the maxillary sinus into the oral cavity. It may occur as a result of a tooth extraction, especially of canines with long roots.

The internal surface of the cranial base, also known as the intracranial surface, can be observed after removing the calvaria and the brain. It is divided into **three cranial fossae**. It contains passages for the cranial nerves and vessels supplying the brain and impressions for the dural venous sinuses.

Subdivisions and boundaries

Subdivisions

- 1 **Anterior cranial fossa** (*fossa cranii anterior*)
- 2 **Middle cranial fossa** (*fossa cranii media*)
- 3 **Posterior cranial fossa** (*fossa cranii posterior*)

Boundaries

- 4 **Ventral border of the anterior cranial fossa** – the squamous part of the frontal bone
- 5 **Border between the anterior and middle cranial fossa** – the posterior margins of the lesser wings of the sphenoid bone, anterior clinoid processes and jugum sphenoidale
- 6 **Border between the middle and posterior cranial fossa** – the superior border of the petrous part of the temporal bone and the dorsum sellae
- 7 **Dorsal border of the posterior cranial fossa** – the squamous part of the occipital bone

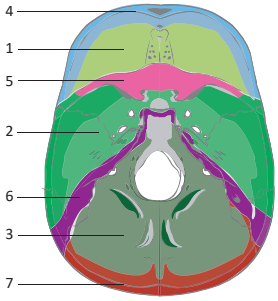

Internal surface of the cranial base

Passages and content

1 **Anterior cranial fossa** – contains the frontal lobes of the telencephalon
- 1.1 **Cribriform foramina** – contain the olfactory nerves and anterior ethmoidal nerve and vessels, the anterior meningeal artery and vein

2 **Middle cranial fossa** – contains the temporal lobes of the telencephalon
- 2.1 **Optic canal** – contains the optic nerve with the central retinal artery and vein, ophthalmic artery and plexus
- 2.2 **Superior orbital fissure** – contains the oculomotor, trochlear, ophthalmic and abducent nerves and the superior ophthalmic vein
- 2.3 **Foramen rotundum** – contains the maxillary nerve
- 2.4 **Foramen ovale** – contains the mandibular nerve and venous plexus of foramen ovale
- 2.5 **Internal aperture of carotid canal** – contains the internal carotid artery
- 2.6 **Foramen spinosum** – contains the middle meningeal artery and vein and the meningeal branch of the mandibular nerve
- 2.7 **Hypophysial fossa** – contains the pituitary gland and its vessels

3 **Posterior cranial fossa** – contains the cerebellum and the brainstem
- 3.1 **Internal acoustic opening** – contains the facial nerve, vestibulocochlear nerve and the labyrinthine artery and veins
- 3.2 **Jugular foramen** – contains the glossopharyngeal, vagus and accessory nerves, the origin of the internal jugular vein (superior bulb), and the posterior meningeal artery
- 3.3 **Hypoglossal canal** – contains the hypoglossal nerve and the venous plexus of the hypoglossal canal
- 3.4 **Foramen magnum** – contains the spinal cord and its meninges, vertebral arteries, spinal roots of the accessory nerve, spinal arteries, venous interconnection, and ligaments
- 3.5 **Dural venous sinuses** – include the plexuses (inferior petrous sinus, marginal sinus, sigmoid sinus, transverse sinus, occipital sinus and confluence of sinuses

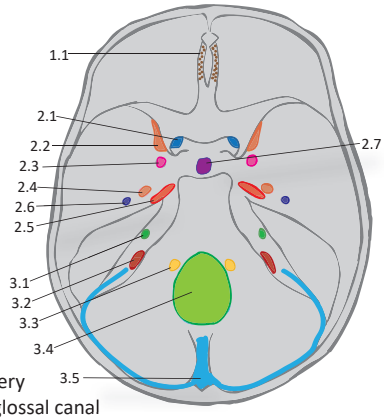

1.10 Temporal fossa – Fossa temporalis

The temporal fossa is located on the lateral aspect of the skull. It contains the **temporalis** and several vessels and nerves.

Boundaries

- **1 Laterally:** zygomatic arch and temporal fascia
  2 **Cranially:** superior temporal line
  3 **Ventrally:** zygomatic bone – temporal surface
  4 **Caudally:** sphenoidal bone (greater wing) – infratemporal crest
- 5 **Medially:** temporal bone – squamous part, sphenoidal bone – temporal surface of greater wing

Content

- 6 **Temporalis**
- 7 **Temporal nerves**
- 8 **Anterior and posterior deep temporal arteries and veins**
- 9 **Middle temporal artery and vein**
  10 **Zygomaticotemporal branch of zygomatic nerve**

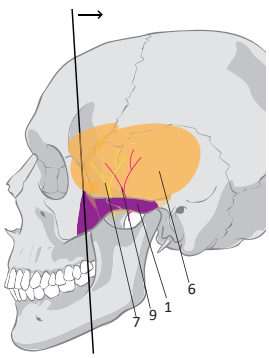

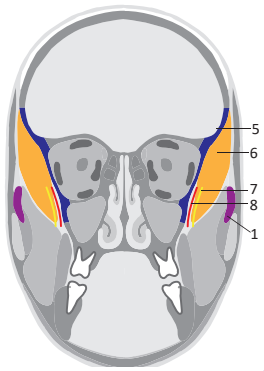

Frontal section of the head

This copy belongs to ali yaghoubi

The infratemporal fossa is an extracranial space located deep to the ramus of the mandible. It contains the **masticatory muscles**, branches of the **mandibular nerve** and **maxillary artery** and the **venous pterygoid plexus**. It also contains part of the **parotid gland** and part of the **buccal fat pad**.

Boundaries

- 1 **Cranially:** sphenoidal bone – infratemporal surface of the greater wing, temporal bone – squamous part
- 2 **Ventrally:** maxillary tuberosity
- 3 **Dorsally:** continues as the prestyloid space
- 4 **Medially:** sphenoidal bone – lateral plate of pterygoid process
- 5 **Laterally:** ramus of mandible

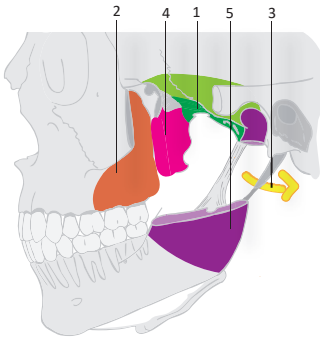

Passages

- 1 **Foramen ovale**
  - 1.1 Mandibular nerve
  - 1.2 Venous plexus of foramen ovale
- 2 **Foramen spinosum**
  - 2.1 Middle meningeal artery and vein
  - 2.2 Meningeal branch of the mandibular nerve
- 3 **Mandibular foramen**
  - 3.1 Inferior alveolar nerve
  - 3.2 Inferior alveolar artery and vein
- 4 **Pterygomaxillary fissure**
  - 4.1 Maxillary artery
  - 4.2 Venous tributaries to the pterygoid plexus
- 5 **Petrotympanic fissure**
  - 5.1 Chorda tympani
  - 5.2 Anterior tympanic artery and vein
  - 5.3 Anterior ligament of malleus
- 6 **Foramen lacerum / sphenopetrosal synchondrosis**
- 7 **Foramen petrosum**
  - 7.1 Lesser petrosal nerve
- 8 **Alveolar foramina of maxillary tuberosity**
  - 8.1 Posterior superior alveolar branches of the maxillary nerve
  - 8.2 Posterior superior alveolar arteries and veins

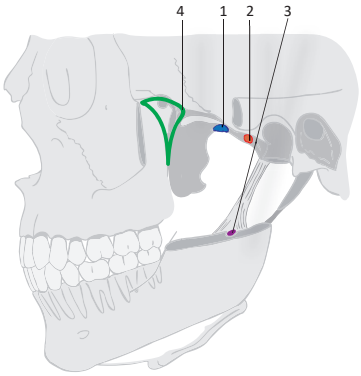

Lateral view of the left infratemporal fossa (ramus of mandible removed)

Content

- 1 **Medial pterygoid**
- 2 **Lateral pterygoid**
- 3 **Temporalis** (insertion)
- 4 **Maxillary artery**
  - 4.1 **Middle meningeal artery**
  - 4.2 **Inferior alveolar artery**
  - 4.3 **Buccal artery**
  - 4.4 **Deep temporal arteries**
  - 4.5 **Anterior tympanic artery**
  - 4.6 Muscular branches of its pterygoid part
- 5 **Pterygoid plexus**
- 6 **Otic ganglion, lesser petrosal nerve**
- 7 **Mandibular nerve**
  - 7.1 **Auriculotemporal nerve**
  - 7.2 **Inferior alveolar nerve**
  - 7.3 **Lingual nerve**
  - 7.4 **Buccal nerve**
  - 7.5 Muscular branches
- 8 **Chorda tympani**
- 9 **Buccal fat pad (of Bichat)**

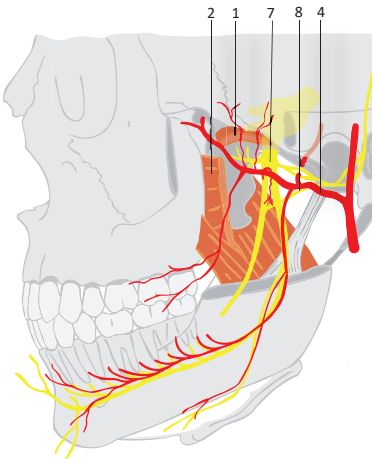

Topography

The vaginal process of the sphenoidal bone and sphenoidal process of the palatine bone form the palatovaginal canal which connects the pterygopalatine fossa to the nasal cavity and contains the pharyngeal branches of the maxillary artery and the pharyngeal nerve from the pterygopalatine ganglion.

Clinical notes

Ligation is a surgical technique of closing a tube, such as a blood vessel or duct, by tying a thread around it.

The maxillary artery can be ligated in the pterygopalatine fossa and can be accessed through the maxillary sinus. This method is know as transantral maxillary artery ligation and is indicated in intractable epistasis (nasal bleeding).

The pterygopalatine fossa is a gap between the posterior wall of the maxilla and the pterygoid process. It has the shape of a **narrow pyramid** with its **apex pointing downwards**. Its medial wall is formed by the perpendicular plate of the palatine bone, which separates it from the nasal cavity. On the lateral side it opens into the infratemporal fossa via the pterygomaxillary fissure. It contains the **maxillary nerve** and its branches, the **pterygopalatine ganglion**, the terminal branches of the **maxillary artery** and the **pterygoid venous plexus**.

Boundaries

- 1 **Cranially:** sphenoid bone – maxillary surface of greater wing
- 2 **Ventrally:** maxilla – infratemporal surface
- 3 **Dorsally:** sphenoidal bone – pterygoid process
- 4 **Medially:** palatine bone – perpendicular plate
- 5 **Laterally:** pterygomaxillar fissure
  – connects the pterygopalatine fossa to the infratemporal fossa
- 6 **Caudally:** continues as the greater palatine canal

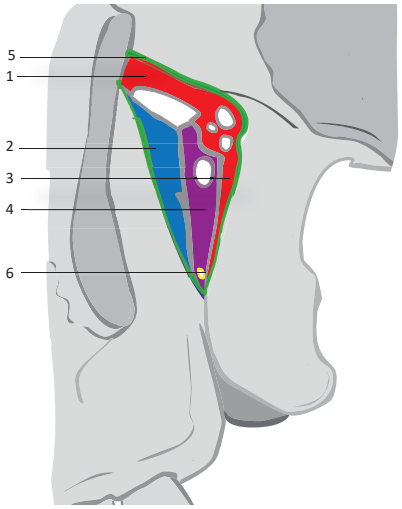

Left pterygopalatine fossa after the removal of zygomatic arch

Passages and content

From the cranial cavity

- 1 **Foramen rotundum**
  1.1 Maxillary nerve

To the orbit

- 2 **Inferior orbital fissure**
  2.1 Zygomatic nerve
  2.2 Infraorbital nerve and artery
  2.3 Inferior ophthalmic vein
  2.4 Orbitalis

To the palate

- 3 **Greater palatine canal**
  3.1 Greater palatine nerve
  3.2 Descending palatine artery and vein
  4 **Lesser palatine canals**
  4.1 Lesser palatine nerves
  4.2 Lesser palatine arteries and veins
- 5 **Pterygoid canal (Vidian canal)**
  5.1 Nerve of pterygoid canal
  5.2 Artery and vein of pterygoid canal

To the nasal cavity

- 6 **Sphenopalatine foramen**
  6.1 Sphenopalatine artery and vein
  6.2 Medial and lateral superior posterior nasal branches of the maxillary nerve

From the infratemporal fossa

- 7 **Pterygomaxillar fissure**
  7.1 Maxillary artery
  7.2 Tributaries of the pterygoid plexus

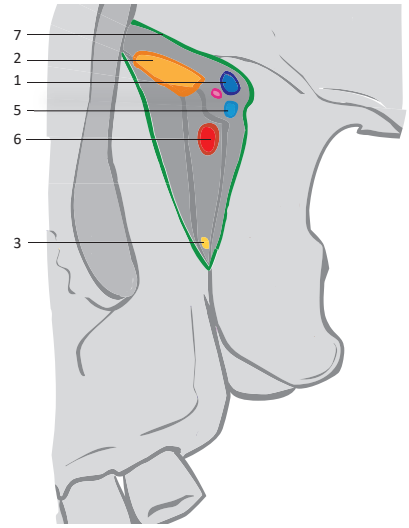

Content

- 1 **Pterygopalatine ganglion and pterygopalatine nerves**
- 2 **Maxillary nerve**
  - 2.1 **Zygomatic nerve**
  - 2.2 **Infraorbital nerve**
  - 2.3 **Posterior superior alveolar nerves**
- 3 **Nerve of pterygoid canal** – formed by the union of the the greater and deep petrosal nerves
- 4 **Greater palatine nerve**
  5 **Maxillary artery**
  5.1 **Infraorbital artery**
  5.2 **Sphenopalatine artery**
  6 **Tributaries to the pterygoid venous plexus**

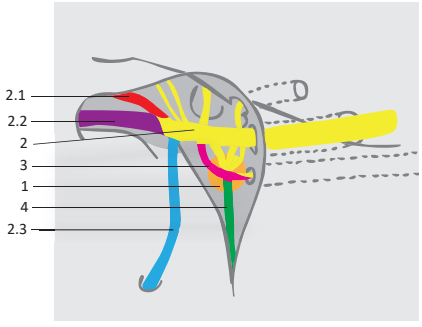

Nerves of the pterygopalatine fossa

This copy belongs to ali yaghoubi

The infratemporal fossa is topographically divided into **smaller spaces without specific borderlines**, the exception is **the retrostyloid space, which is** separated from the infratemporal fossa by **the styloid septum**. **The retrostyloid space** can be added to the topographical spaces of the neck as well.

Subdivisions

1 **Pterygomandibular space**
2 **Parapharyngeal space**
- 2.1 **Prestyloid space**
- 2.2 **Retrostyloid space**

- 3 **Retropharyngeal space**

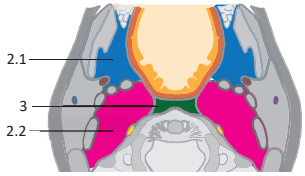

Transverse section at the level of C1

1.14 Pterygomandibular space – Spatium pterygomandibulare

The pterygomandibular space is located **between the pterygoids and the ramus of the mandible**.

Boundaries

Cranially: Lateral pterygoid
Medially: Medial pterygoid – lateral surface
Laterally: Ramus of mandible – medial surface

Content

- 1 **Lingual nerve and chorda tympani**
- 2 **Inferior alveolar nerve**
- 3 **Inferior alveolar artery and vein**

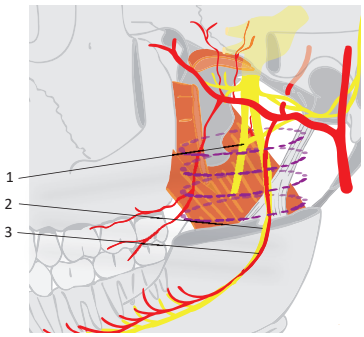

Left pterygomandibular space after removal of the ramus of the mandible

1.14 Parapharyngeal space – Spatium parapharyngeum

The parapharyngeal space is located lateral to the pharynx. It contains vessels, nerves and abundant reticular fibrous tissue and lymphatics. It is divided into two parts by the styloid septum. These two parts are called the prestyloid and retrostyloid spaces. **The prestyloid space** communicates with the **submandibular space** and the **infratemporal fossa**. **The retrostyloid space** communicates caudally with the **paravisceral space of the neck**. The **styloid septum** is a myofascial plate extending between the inner surface of the sternocleidomastoid and the buccopharyngeal fascia.

Styloid septum (*septum styloideum*)

- 1 **Stylopharyngeus**
- 2 **Styloglossus**
3 **Styloid process** and stylohyoid ligament
- 4 **Stylohyoid**
- 5 **Posterior belly of digastric**
- 6 **Sternocleidomastoid**

- 7 **Fascia of these muscles**

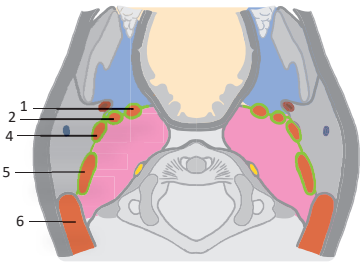

Transverse section at the level of vertebra C1

Topography

The retropharyngeal space is divided by the frontally oriented intercarotid fascia into an anterior part and a posterior part. The anterior part is sometimes termed as the retropharyngeal space proper. The posterior part is clinically referred to as the "danger space". It allows rapid spread of inflammation to the medinastinum, resulting in a life threatening condition called acute medinastinitis.

Spatium lateropharyngeum, spatium pharyngeum laterale and spatium parapharyngeum are synonyms of the parapharyngeal space.

Clinical notes

An inferior alveolar nerve block is performed by injecting a local anaesthetic near the mandibular foramen in the pterygomandibular space

The retropharyngeal space is used as a surgical approach to the cervical vertebral column.

Swollen retropharyngeal nodes of Rouviere can be seen in children during examination of the throat.

The prestyloid space is a narrow gap between the upper part of the pharynx, medial pterygoid and styloid septum. Its contents include the **deep part of the parotid gland** and the **external carotid artery** and its terminal branches.

Boundaries

Cranially: sphenoidal bone – infratemporal surface of greater wing and temporal bone – squamous part
Caudally: continues as the submandibular space
Ventrally: continues as the infratemporal fossa
Dorsaly: styloid septum
Medially: pharynx and buccopharyngeal fascia
Laterally: medial pterygoid

Content

- 1 **External carotid artery** (bifurcating into the maxillary artery and superficial temporal artery)
- 2 **Ascending palatine artery**
- 3 **Retromandibular vein** (within the parotid gland)
- 4 **Facial nerve** – its branches
- 5 **Parotid gland**

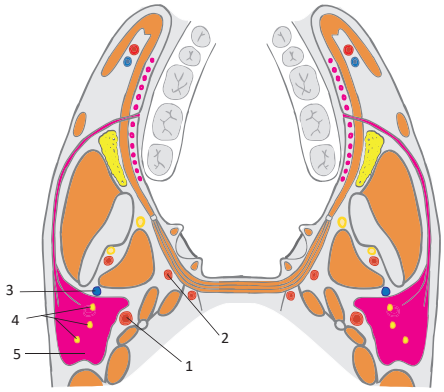

Transverse section at the level of vertebra C2

1.16 Retrostyloid space – Spatium retrostyloideum

The retrostyloid space is a topographical area delimited by the upper part of the pharynx, the prevertebral layer of the cervical fascia and the styloid septum. Its contents include vessels supplying the brain (**internal carotid artery** and **internal jugular vein**) and **cranial nerves IX–XII**.

Boundaries

Cranially: temporal bone – petrous part
Caudally: continues as the carotid space
Ventrally: styloid septum
Dorsally: prevertebral layer of cervical fascia
Medially: continues as the retropharyngeal space
Laterally: sternocleidomastoid

Content

1 **Internal carotid artery**
2 **Internal jugular vein**
3 **Glossopharyngeal nerve**
4 **Vagus nerve and superior laryngeal nerve**
5 **Accessory nerve**
6 **Hypoglossal nerve and deep ansa cervicalis**
7 **Sympathetic trunk and superior cervical ganglion**
8 **Ascending pharyngeal artery**
9 **Pharyngeal venous plexus and pharyngeal veins**
10 **Internal carotid plexus, deep petrosal nerve**

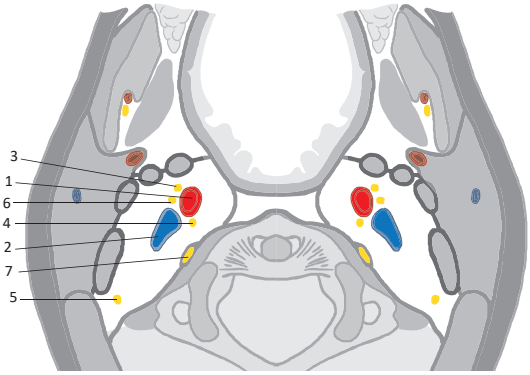

Transverse section at the level of vertebra C1

1.17 Retropharyngeal space – Spatium retropharyngeum

The retropharyngeal space is a gap-like **space between the posterior wall of the pharynx and the prevertebral layer of the cervical fascia**.

Boundaries

Cranially: cranial base – the occipital bone
Caudally: continues into the mediastinum
Ventrally: posterior wall of the pharynx
Dorsally: prevertebral layer of cervical fascia
Laterally: continues as the retrostyloid space

Content

1 **Pharyngeal plexus** – nervous plexus
2 **Retropharyngeal lymph nodes of Rouvière**
3 **Ascending pharyngeal artery** – pharyngeal branches
4 **Pharyngeal veins and pharyngeal venous plexus**

This copy belongs to ali yaghoubi

The neck is bordered cranially by the **inferior margin of the mandible** and caudally by the two **clavicles**. The **jugular notch** is located at the caudal margin of the midline of the neck. The neck contains many important structures: organs of the respiratory tract, the thyroid and parathyroid glands, the upper part of the gastrointestinal tract, the vessels supplying the head and neck, and the cervical vertebral column with the spinal cord.

Organ projections according to the cervical vertebrae

C3: hyoid bone
C4: laryngeal prominence,
bifurcation of common carotid artery
C5: thyroid cartilage
and vocal cords
C6: cricoid cartilage,
pharyngo-oesophageal transition,
laryngo-tracheal transition
C7: thyroid gland – isthmus

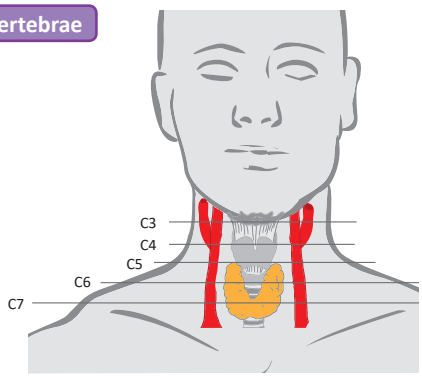

2.1 Regions of the neck – Regiones cervicales

The course of the sternocleidomastoid divides the neck into three regions: **anterior cervical region, lateral cervical region and sternocleidomastoid region**. These are further divided **by the certain cervical muscles into triangles**.

Boundaries

1 **Anterior cervical region** (*regio cervicalis anterior*)
- 1.1 **Cranially:** mandible
- 1.2 **Caudally:** sternum – jugular notch
- 1.3 **Laterally:** sternocleidomastoid

2 **Sternocleidomastoid region**
(*regio sternocleidomastoidea*)
– is bordered by the margins
of the sternocleidomastoid

3 **Lateral cervical region** (*regio cervicalis lateralis*)
- 3.1 **Ventrally:** sternocleidomastoid
- 3.2 **Dorsally:** trapezius
- 3.3 **Caudally:** clavicle

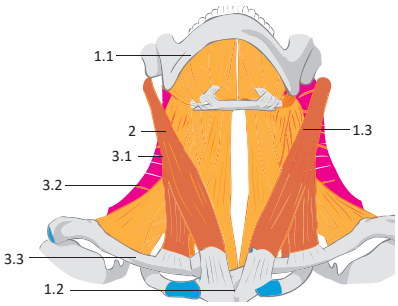

Ventral part of the neck
without the platysma

Division

1 **Anterior cervical region** (*regio cervicalis anterior*)
- 1.1 **Submental triangle**
- 1.2 **Submandibular triangle**
- 1.3 **Carotid triangle**
- 1.4 **Muscular/omotracheal triangle**

2 **Sternocleidomastoid region**
(*regio sternocleidomastoidea*)
- 2.1 **Lesser supraclavicular fossa**
- 2.2 **Scalenovertebral triangle**

3 **Lateral cervical region** (*regio cervicalis lateralis*)
- 3.1 **Omoclavicular triangle**
- 3.2 **Omotrapezoid triangle**

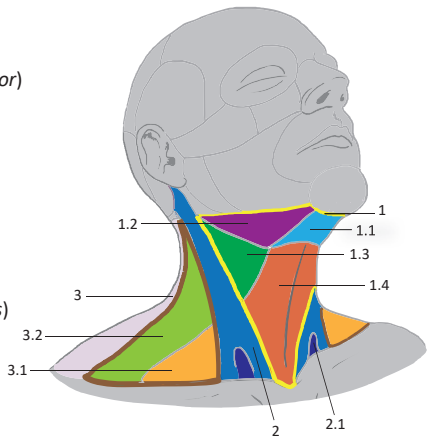

The superior root of the deep cervical ansa *(radix superior ansae cervicalis profundae)* is a term used for the nerve fibres from spinal segments C1 and C2 that join the hypoglossal nerve. After passing into the carotid triangle they separate from the hypoglossal nerve. They then descend ventrally and innervate the infrahyoid muscles after which they join the inferior root *(from spinal segments C2 and C3)*, forming a loop called the deep cervical ansa *(ansa cervicalis profunda)*.

The carotid sheath *(vagina carotica)* surrounds the cervical neurovascular bundle. It is connected to the pretracheal layer of the cervical fascia.

The laryngeal prominence *(prominentia laryngea)* is also called the Adam's apple *(pomum Adami)*.

The triangle of the lingual artery *(Pirogov's triangle)* is bordered ventrally by the posterior margin of the mylohyoid, caudally by the posterior belly of the digastric, and cranially by the arch of the hypoglossal nerve. Its floor is formed by the hyoglossus and it contains the lingual artery and veins. It is a site for ligation of the lingual artery.

The angle of Béclard *(angulus Beclárdi)* is formed by the greater horns of the hyoid bone and the stylohyoid. It is used to locate the lingual artery and veins.

Clinical notes

The carotid triangle is a site used for examination of the carotid arteries. Here, the carotid arteries can be easily palpated, auscultated and visualised by ultrasound.

The carotid triangle can be used to surgically approach the carotid arteries. This is done during carotid endarterectomy, a procedure to reduce atherosclerotic narrowing of the carotid arteries.

The submandibular triangle is a paired space between the body of the mandible and both bellies of the digastric. It contains the **submandibular gland** and **facial vessels**. Deeper, it contains the **lingual artery** and **hypoglossal nerve**.

Boundaries

- 1 **Cranially:** body of mandible – inferior margin
- 2 **Medially:** digastric – anterior belly
- 3 **Laterally:** digastric – posterior belly
- 4 **Bottom:** mylohyoid and hyoglossus

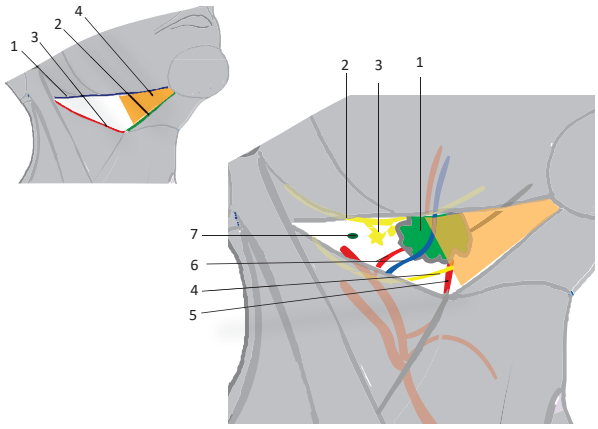

Content

- 1 **Submandibular gland**
  - 1.1 **Submandibular duct**
- 2 **Lingual nerve**
- 3 **Submandibular ganglion**
- 4 **Hypoglossal nerve**
- 5 **Lingual artery and vein**
- 6 **Facial artery and vein** – including submental and glandular branches and tributaries
- 7 **Submandibular lymph nodes**

2.1.2 **Carotid triangle** – Trigonum caroticum

The carotid triangle is a paired space situated ventral to the sternocleidomastoid. The **branches of the external carotid artery** and structures inside the **carotid sheath** (common carotid artery, internal jugular vein, vagus nerve and superior root of deep ansa cervicalis) are located in this region. This space **continues cranially** to the **parapharyngeal space** and **caudally** to the **scalenovertebral triangle**.

Boundaries

- 1 **Cranially:** digastric – posterior belly
- 2 **Laterally:** sternocleidomastoid
- 3 **Caudally:** omohyoid – superior belly

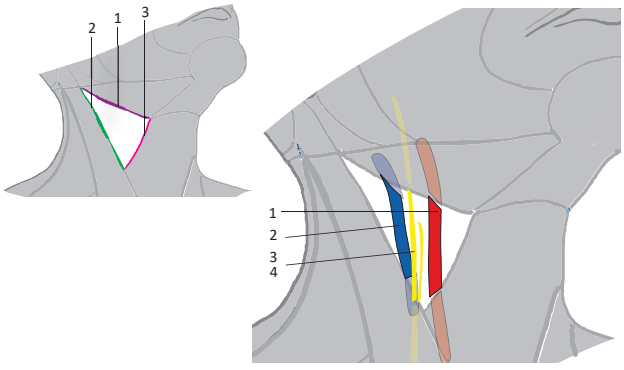

Content

Inside the carotid sheath

- 1 **Common carotid artery** – situated medially
  – continues as the internal carotid artery from the C4 level upward
- 2 **Internal jugular vein** – situated laterally
- 3 **Superior root of deep ansa cervicalis** – situated ventrally
- 4 **Vagus nerve** – situated dorsally

Outside the carotid sheath

- 5 **External carotid artery**
  - 5.1 **Superior thyroid artery**
    – the first branch
    – runs caudally to the omotracheal triangle
  - 5.2 **Lingual artery**
    – the second branch
    – runs cranially to the submandibular triangle
  - 5.3 **Facial artery**
    – the third branch
    – runs cranially to the submandibular triangle
- 6 **Veins** – facial vein, retromandibular vein, lingual vein, superior thyroid vein
- 7 **Arch of hypoglossal nerve** *(arcus nervi hypoglossi)*
- 8 **Sympathetic trunk and superior cervical ganglion**
- 9 **Accessory nerve**
- 10 **Lateral group of the deep cervical lymph nodes**

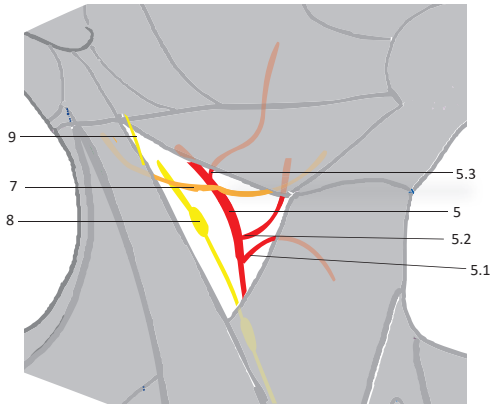

This copy belongs to ali yaghoubi

2.1.3 **Submental triangle** – Trigonum submentale

The submental triangle is a small **space between the anterior bellies of both digastrics**. It **contains lymph nodes** responsible for draining of the anterior part of the tongue.

Boundaries

- 1 **Laterally:** digastric – anterior belly
- 2 **Ventrally (cranially):** mandible – body
- 3 **Caudally:** hyoid bone – body
- 4 **Floor:** mylohyoid

Content

- 5 **Mylohyoid nerves**
- 6 **Submental arteries and veins**
- 7 **Submental lymph nodes**

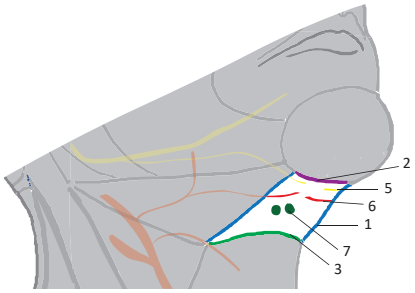

2.1.4 **Muscular/omotracheal triangle** – Trigonum musculare/omotracheale

The muscular (or omotracheal) triangle is a **paired space situated in the middle of the neck.** The two muscular triangles form a region **containing the organs of the neck and infrahyoid muscles**.

Boundaries

- 1 **Cranially:** hyoid bone – the body
- 2 **Cranially and laterally:** omohyoid – the superior belly
- 3 **Caudally and laterally:** sternocleidomastoid
- 4 **Medially:** anterior median line
- 5 **Caudally:** sternum – the manubrium (its jugular notch)

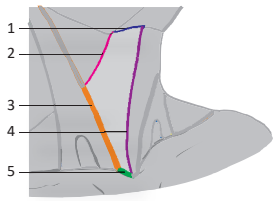

Content

- 1 **Larynx / trachea** (borderline at the level of C6)
- 2 **Pharynx / oesophagus** (borderline at the level of C6)
- 3 **Thyroid gland and parathyroid glands**
- 4 **Recurrent laryngeal nerve**
- 5 **Superior laryngeal nerve**
- 6 **Superior thyroid artery and vein**
- 7 **Inferior thyroid artery and vein**
- 8 **Sternohyoid and sternothyroid**
- 9 **Thyrohyoid**
- 10 **Middle thyroid vein**
- 11 **Jugular venous arch and anterior jugular vein**

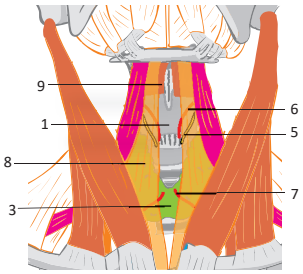

2.1.5 **Lesser supraclavicular fossa** – Fossa supraclavicularis minor

The lesser supraclavicular is a tiny cutaneous pit **formed by both origins of the sternocleidomastoid**, situated cranial to the sternoclavicular joint. **The dome of pleura is located deep in this region.**

Boundaries and content

- 1 **Medially:** sternocleidomastoid – sternal part
- 2 **Laterally:** sternocleidomastoid – clavicular part
- 3 **Caudally:** sternoclavicular joint
- 4 **In the depth:** dome of pleura

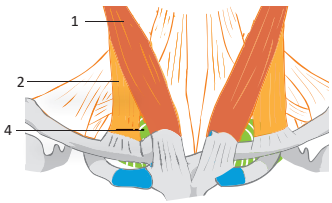

Topography

The mylohyoids are connected in the mid-line by the mylohyoid raphe *(raphe mylohyoidea)*.

The muscular triangle can be further divided into infrahyoid, laryngeal, thyroideal and suprasternal regions.

The subclavian vein passes superficial to the anterior scalene muscle. It does not pass through the scalene fissure.

The major supraclavicular fossa *(fossa supraclavicularis major)* is a skin depression overlying the omoclavicular triangle.

Clinical notes

Thoracic outlet syndrome is caused by compression of the subclavian vessels and/or brachial plexus, most frequently in the scalene fissure. Variants in anatomical structures, such as cervical rib, anomalous insertions of the middle and anterior scalene muscles and supernumerary scalene muscles are common culprits of this syndrome. Thoracic outlet syndrome may be acquired; it can occur as a consequence of neck trauma or repetitive neck or arm movements.

An interscalene block is performed by administering local anaesthetic into the scalene fissure. This produces a blockade of the roots of the brachial plexus allowing surgery to be performed on the upper extremity. It is usually indicated in shoulder surgery.

The omoclavicular triangle is a region located just above the clavicle, lateral to the sternocleidomastoid. Deep in this region, the **supraclavicular part of the brachial plexus** and **subclavian vessels** are located.

Boundaries

- 1 **Cranially:** omohyoid – inferior belly
- 2 **Caudally:** clavicle
- 3 **Ventrally:** sternocleidomastoid – posterior margin

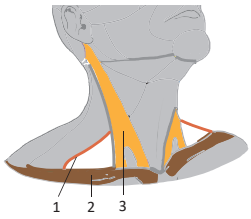

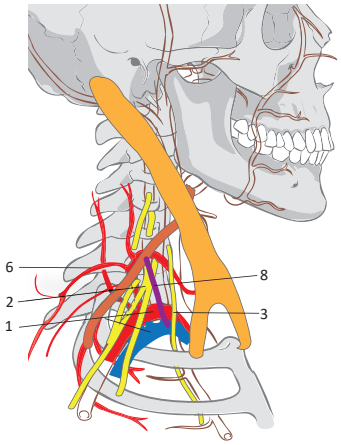

Content

1 **Subclavian artery and vein**
2 **Brachial plexus**
3 **Phrenic nerve**
4 **Supraclavicular nerves**
5 **Ascending cervical artery and anterior vertebral vein**
6 **Transverse cervical artery and veins**
7 **Suprascapular artery**
8 **External jugular vein**
9 **Venous angle**
9.1 **Opening of the thoracic duct on the left side**
9.2 **Opening of the right lymphatic duct on the right side**
10 **Supraclavicular lymph nodes**

2.1.7 **Omotrapezoid triangle** – Trigonum omotrapezium

The omotrapezoid triangle is a cranial part of the lateral neck region **containing the accessory nerve, nerves of the cervical plexus and accessory lymph nodes.**

Boundaries

- 1 **Caudally:** omohyoid – inferior belly
- 2 **Ventrally:** sternocleidomastoid – posterior margin
- 3 **Dorsally:** trapezius – anterior margin

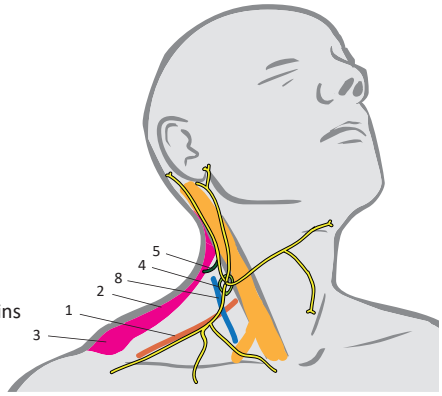

Content

4 **Nervous point** (*punctum nervosum*) – lesser occipital nerve, great auricular nerve, transverse cervical nerve, supraclavicular nerves
5 **Accessory nerve**
6 **Phrenic nerve**
7 **Supraclavicular part of the brachial plexus**
8 **External jugular vein** and its tributaries – transverse cervical and suprascapular veins
9 **Transverse cervical artery** and **suprascapular artery**
10 **Deep cervical artery and vein**
11 **Ascending cervical artery and anterior vertebral vein**

2.2 **Scalene fissure** – Fissura scalenorum

The scalene fissure is **a gap between the anterior and middle scalene muscles,** located deep in the lateral cervical region. **The brachial plexus and subclavian artery pass through** this osteomuscular space.

Boundaries

- 1 **Ventrally:** anterior scalene
- 2 **Dorsally:** middle scalene
- 3 **Caudally:** first rib

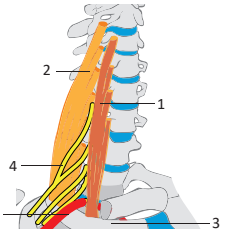

Scalene fissure of the right side of the neck

Content

4 **Brachial plexus**
5 **Subclavian artery**

This copy belongs to ali yaghoubi

The scalenovertebral triangle is located deep in the neck, medial to the scalene muscles. It contains the subclavian vessels and the roots of the brachial plexus.

Boundaries

- 1 **Caudally:** dome of pleura
- 2 **Dorsally:** longus colli
- 3 **Laterally:** anterior scalene
- 4 **Medially:** trachea, oesophagus, thyroid gland
- 5 **Ventrally:** sternocleidomastoid

Content

- 6 **Subclavian artery** (intrascalenic part)
- 7 **Subclavian vein**
- 8 **Brachial plexus**
- 9 **Sympathetic trunk**
  - 9.1 **Stellate ganglion and ansa subclavia**
- 10 **Vagus nerve**
- 11 **Cervical cardiac nerves**
- 12 **Venous angle**
- 13 **Right lymphatic duct** on the right side
- 14 **Thoracic duct** on the left side
- 15 **Deep cervical lymph nodes**

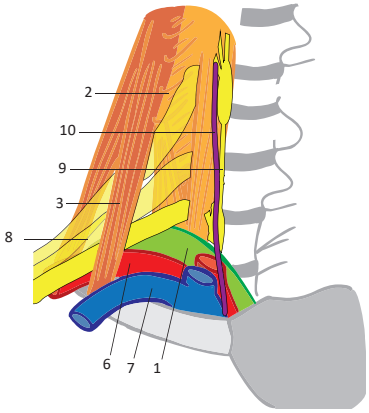

Deep structures of the right side of the neck, ventrolateral view

2.2 Spaces of the neck

The three sheets of the cervical fascia divide the neck into three major spaces. These spaces are more accurately considered to be layers and they are not similar to the superficial neck triangles. The spaces of the neck are continuous with the spaces of the head and the superior mediastinum.

- 1 **Suprasternal space** (*spatium suprasternale*)
  - – is located between the superficial and pretracheal layers
  - – caudal border: manubrium of sternum
  - – does not communicate with the mediastinum (it is a closed space)
  - – **content:** jugular venous arch
- 2 **Visceral space** (*spatium viscerale*)
  - – is located between the pretracheal and prevertebral layers
  - – communicates with the superior mediastinum
  - – **content:** pharyngo–oesophageal transition (C6 level) and laryngo–tracheal transition (C6 level)
  - – the visceral space has three subdivisions:
    - 2.1 **Previsceral space** (*spatium previscerale*)
      - – is located between the cervical organs and the pretracheal layer
      - – **content:** the thyroid gland within its capsule
    - 2.2 **Paravisceral space** (*spatium paraviscerale*)
      - – is located lateral to the cervical organs
      - – a continuation of the cranially located parapharyngeal space
      - – **content:** nerves and vessels within the carotid sheath
    - 2.3 **Retrovisceral space** (*spatium retroviscerale*)
      - – is located between the cervical organs and the prevertebral layer
      - – a continuation of the cranially located retropharyngeal space

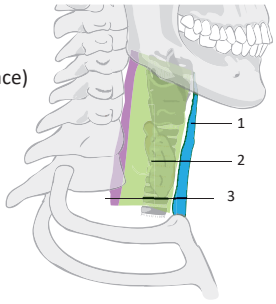

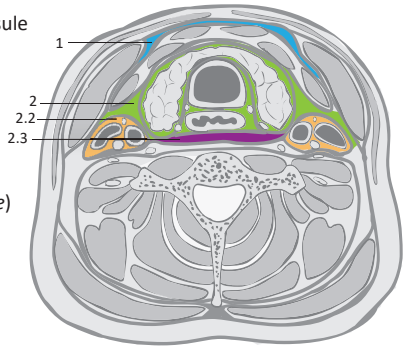

Transverse section of the neck at the level of vertebra C6

Topography

Unlike the triangles of the neck, which are just tools for comprehension of the neck topography and syntopy, the spaces between the cervical fasciae describe the connections between the regions of the head and mediastinum.

The platysma is a subcutaneous muscles. It inserts into the skin and is located superficial to the cervical fascia.

The phrenic nerve passes on the anterior surface of the anterior scalene with the ascending cervical artery and the anterior vertebral vein.

The suspensory ligament of the thyroid gland *(ligamentum suspensorium glandulae thyroideae)* is a fibrous band attached to the hyoid bone. It is a remnant of the thyroid gland's descent during its development and is continuous with the pretracheal layer of the cervical fascia.

The alar fascia *(fascia alaris)* is an obsolete term for the intercarotid fascia.

The danger space is bound cranially by the occipital bone, ventrally by the intercarotid fascia and dorsally by the prevertebral layer of the cervical fascia. It descends to the level of the diaphragm.

Clinical notes

The visceral space of the neck is continuous caudally with the superior posterior mediastinum.

The cervical fascia has three main layers. **The superficial layer** is located under the platysma. It envelops both the trapezius and sternocleidomastoid. **The pretracheal layer** ensheathes the infrahyoid muscles and is connected to the superficial layer. **The carotid sheath** is derived from the pretracheal layer and contains the cervical neurovascular bundle and the deep cervical ansa. The intercarotid fascia interconnects the two carotids sheaths. **The prevertebral layer** covers the deep neck muscles.

- 1 **Skin**
  2 **Subcutaneous tissue**
- 3 **Platysma**

- 4 **Superficial layer** *(lamina superficialis)*
  – covers the entire surface of the neck
  – encloses:
    - 4.1 **Sternocleidomastoid**
    - 4.2 **Trapezius**
      4.3 **External branch of accessory nerve**

- 5 **Pretracheal layer** *(lamina pretrachealis)*
  – borders:
    – laterally: omohyoid
    – cranially: attaches to the hyoid bone
    – caudally : attaches to the inner surface of the sternum
  – encloses:
    - 5.1 **Infrahyoid muscles**
- 6 **Carotid sheath** (*vagina carotica*)
  – derived from the pretracheal layer
  – the right and left carotid sheaths are interconnected by the frontally oriented intercarotid fascia (*fascia intercarotica*)
  – envelops the cervical neurovascular bundle:
    - 6.1 **Common carotid artery** – situated medially
      – continues cranially as the internal carotid artery
    - 6.2 **Internal jugular vein** – situated laterally
    - 6.3 **Vagus nerve** – situated dorsally
    - 6.4 **Superior root of deep ansa cervicalis** – situated ventrally

- 7 **Prevertebral layer** *(lamina prevertebralis)*
  – encloses:
    - 7.1 **Sympathetic trunk**
    - 7.2 **Deep muscles of the neck** (longus colli, longus capitis)
    - 7.3 **Scalene muscles**

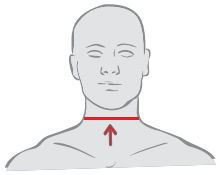

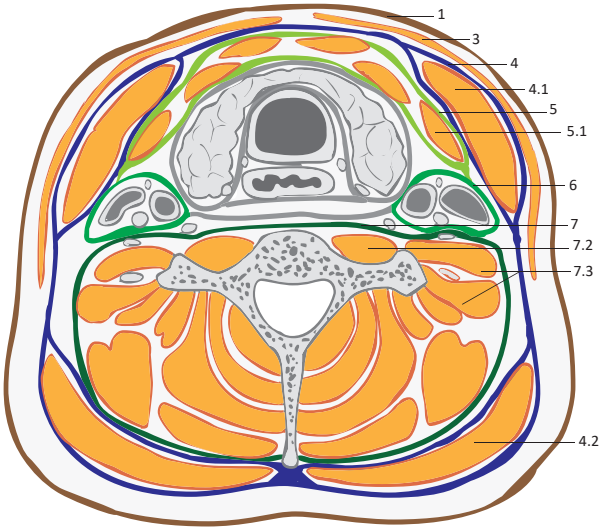

Transverse section of the neck at the level of vertebra C6

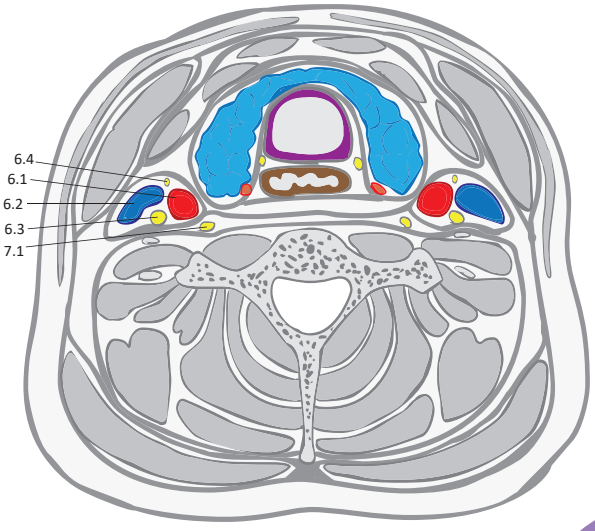

Transverse section of the neck at the level of vertebra C6

This copy belongs to ali yaghoubi

The thorax can be divided into the two pleuropulmonary regions and the mediastinum. The pleuropulmonary regions are bound by parietal pleura. The mediastinum is located between them. The pleural cavity is an isolated space. It does not communicate with the mediastinum. The lungs communicate with the mediastinum at the hilum of the lung.

Boundaries

- 1 **Cranially:** superior thoracic aperture (*apertura thoracis superior*)
  - – is formed by a virtual plane at the level of vertebra T1, the 1st rib and the upper margin of the sternum
  - – communicates with the visceral space of the neck
- 2 **Caudally:** inferior thoracic aperture (*apertura thoracis inferior*)
  - – bordered by vertebra T12 dorsally, xiphosternal joint cranially, costal cartilages of 7th–10th ribs ventrolaterally and 11th–12th ribs dorsolaterally
  - – enclosed by the diaphragm
  - – communicates with the abdominal cavity through the openings of the diaphragm
- 3 **Ventrally:** sternum
- 4 **Dorsally:** vertebral column (T1–T12)
- 5 **Laterally:** ribs and intercostal muscles

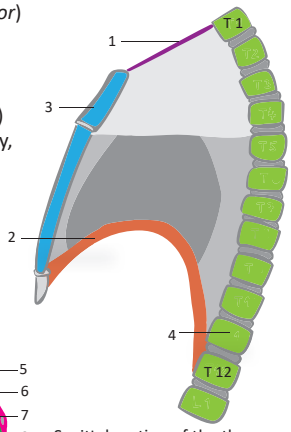

Sagittal section of the thorax

Division

- 6 **Mediastinum**
- 7 **Right pleural cavity** and right lung
- 8 **Left pleural cavity** and left lung

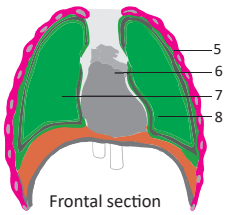

Frontal section

The cephalic vein perforates the clavipectoral fascia in the infraclavicular oval fossa and drains into the axillary vein.

The external intercostal membrane replaces the external intercostal muscles in the ventral third of the intercostal spaces.

The internal intercostal membrane replaces the internal intercostal muscles in the dorsal third of the intercostal spaces.

The first rib is not palpable. The second rib is palpable under the clavicle.

In men, the nipples are located at the level of the fourth intercostal space

3.1 Layers of the thoracic wall

The layers of the thoracic wall differ in different regions. A section through the thoracic wall of a man is described below. **The pectoral muscles and their fascia are shown external to the thoracic wall itself.**

- 1 **Skin**
- 2 **Subcutaneous tissue**
  - – the thoracoepigastric veins run in this layer
- 3 **Pectoral fascia**
  - – encloses the pectoralis major
- 4 **Clavipectoral fascia**
  - – located under the pectoralis major
  - – spreads between the clavicle, coracoid process, costal cartilages and pectoralis minor
  - – encloses the pectoralis minor and subclavius
- 5 **Thoracic fascia**
  - – the superficial fascia of all ribs and intercostal spaces
- 6 **Intercostal space**
- 7 **Parietal fascia of thorax / endothoracic fascia**
  - – lines the inner surface of the thoracic cavity
  - 7.1 **Suprapleural membrane / fascia of Sibson**
    - – a thicker fascia at the pleural cupula
- 8 **Parietal pleura**

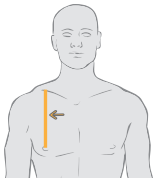

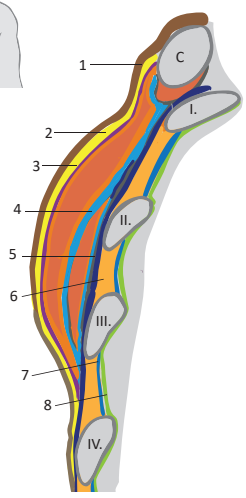

Sagittal section of the male thorax

Clinical notes

Pleural drainage is a vacuum-assisted evacuation of fluid or air from the pleural cavity.

Thoracocentesis (pleural tap) is performed above the cranial margin of a rib. This ensures that the needle passes through the lower part of the intercostal space, avoiding the intercostal neurovascular bundle.

A breast implant can be placed either between the mammary gland and the pectoral fascia or between the pectoralis major and the pectoralis minor. The position under the gland is appropriate for bigger implants. However, the position under the muscle will provide a more natural appearance.

Intercostal spaces are located between adjacent ribs. They contain **three layers of intercostal muscles**. From superficial to deep these are the **external intercostal muscles**, **internal intercostal muscles** and the **innermost intercostal muscles**. **The intercostal neurovascular bundle runs between the internal and innermost intercostal muscles**. It passes just below the lower margin of the rib in the costal groove.

Content

- 1 **External intercostal muscles**
- 2 **Internal intercostal muscles**
- 3 **Intercostal neurovascular bundle** (listed in a craniocaudal direction)
  - 3.1 **Anterior and posterior intercostal vein**
  - 3.2 **Anterior and posterior intercostal artery**
  - 3.3 **Intercostal nerve**
- 4 **Collateral neurovascular bundle**
  - 4.1 **Collateral branch of posterior intercostal artery**
  - 4.2 **Collateral branch of intercostal nerve**
    - – runs in the inferior and posterior part of the intercostal space
- 5 **Innermost intercostal muscles**

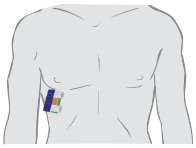

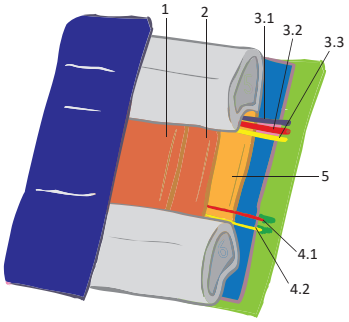

3.3 Organ projections on the thoracic wall

Physical examination of the thorax includes inspection, palpation, percussion and auscultation. It requires a deep understanding of positions of thoracic organs and their projection onto the thoracic wall.

Organ projections according to the thoracic vertebrae

T2 – Thymus
T3 – Arch of aorta
T4 – Sternal angle
– Border of the superior and inferior mediastinum
– Tracheal bifurcation
T8 – Domes of diaphragm
– Caval opening
T10 – Oesophageal hiatus
T12 – Aortic hiatus

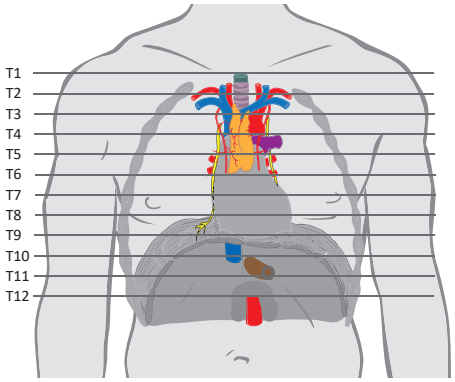

Organ projections according to the thoracic vertebrae

Outlines and projections of the pleura

Upper border:
- **Lesser supraclavicular fossa** (*fossa supraclavicularis minor*)
  – the top of the pleural cupula

Ventral border:
– travelling caudally from the cupula of the pleura to the 2nd rib, the medial margins of the parital pleura converge towards the midline, forming the **superior interpleural area** (*area interpleuralis superior*)
– between the 2nd and 4th ribs the medial margins of the parietal pleurae follow the parasternal line
– caudally from the 4th rib, the medial margins of the parietal pleurae diverge, forming the **inferior interpleural area** (*area interpleuralis inferior*)
– the medial margin of the right parietal pleura continues straight down to the 6th rib
– on the left side, it arches laterally towards the cartilage of the 6th rib

Lower border:
– from the 6th rib, the borders continue to diverge and cross the following lines:
- 7th rib – midclavicular line
- 8th rib – anterior axillary line
  9th rib – midaxillary line

Dorsal border:
- 10th rib – posterior axillary line
- 11th rib – scapular line
- 12th rib (often even 2 cm lower) — paravertebral line
  – the lowest point

Parietal pleura Visceral pleura

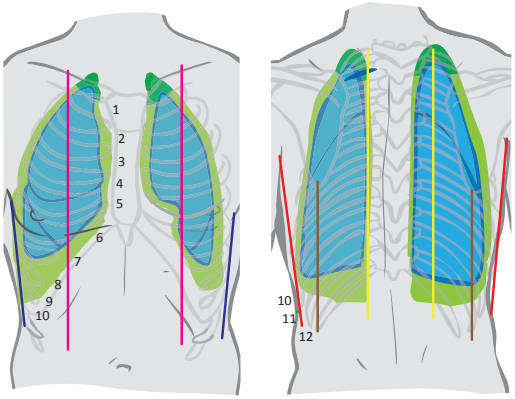

Ventral and dorsal borders of the pleura with lines of the human body

This copy belongs to ali yaghoubi

The mediastinum is space in the thoracic cavity located between the **pleural cavities laterally,** the **diaphragm caudally** and the **superior thoracic aperture cranially**. Anatomically, it is divided into a superior and inferior division by a transverse plane at the level of vertebra T4. **The inferior mediastinum** is then further divided into the **anterior**, **middle** and **posterior inferior mediastinum** by the pericardial sac. Clinically, the mediastinum is divided by the **bronchopericadial membrane** into the anterior and posterior division.

Anatomical division

- 1 **Superior mediastinum** (*mediastinum superius*)
  - – bound cranially by the superior thoracic aperture, caudally by a transverse plane passing through vertebra T4, ventrally by the manubrium and dorsally by the vertebral column
- 2 **Inferior mediastinum** (*mediastinum inferius*)
  - – bound cranially by a transverse plane at the level of vertebra T4 and caudally by the diaphragm
  - – the inferior mediastinum is further divided by the pericardium into three subdivisions:
    - 2.1 **Anterior inferior mediastinum** (*mediastinum inferius anterius*)
      - – between the body of the sternum and the pericardium
    - 2.2 **Middle inferior mediastinum** (*mediastinum inferius medium*)
      - – bound by the pericardium and contains the heart
    - 2.3 **Posterior inferior mediastinum** (*mediastinum inferius posterius*)
      - – located between the dorsal aspect of the pericardium and the vertebral column

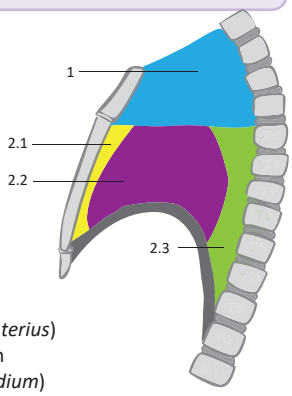

Sagittal section of the mediastinum

Clinical division

1 **Anterior mediastinum** (*mediastinum anterius*)
- – located between the sternum and the bronchopericardial membrane
  - 1.1 **Superior anterior mediastinum** (*mediastinum anterius superius*)
    - – bound superiorly by the superior thoracic aperture and inferiorly by a transverse plane at the level of vertebra T4
  - 1.2 **Inferior anterior mediastinum** (*mediastinum anterius inferius*)
    - – bound superiorly by a transverse plane at the level of vertebra T4 and inferiorly the diaphragm

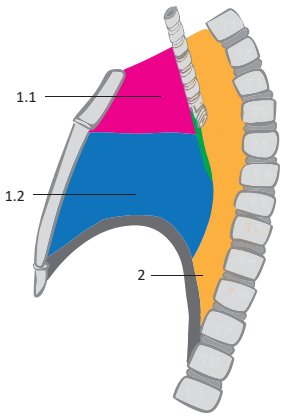

- 2 **Posterior mediastinum** (*mediastinum posterius*)
  - – located between the bronchopericardial membrane and the vertebral column
- **Bronchopericardial membrane** (*membrana bronchopericardiaca*)
  - – a membranous plate spread between the bronchi and pericardium separating the anterior and posterior mediastinum

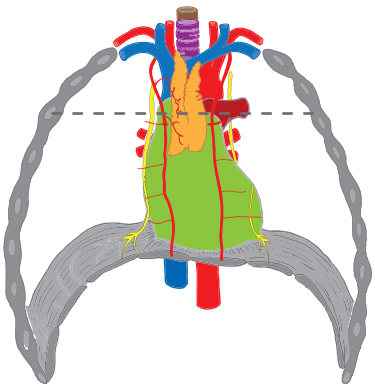
Structures of the anterior mediastinum, anterior view

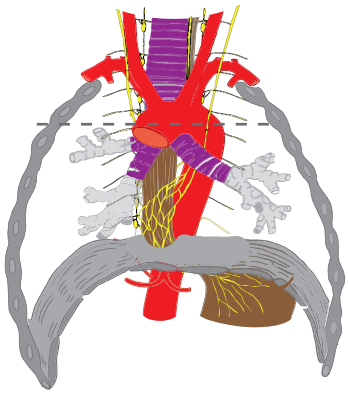
Structures of the posterior mediastinum, anterior view

Topography

The division of the mediastinum is more theoretical than anatomical. It is divided by virtual planes and incomplete anatomical structures (the bronchopericardial membrane).

The clinical division of the mediastinum is based on the continuation of the mediastinum with the cervical regions and the retroperitoneum.

Clinical notes

Surgical interventions in the mediastinum are very difficult due to the large number of vitally important structures in a relatively small space. The most commonly performed surgeries in the mediastinum are corrections of aortic aneurysms and operations of the oesophagus, lungs and heart.

Inflammation of the medinastinum is called mediastinitis. It can be caused by the spread of infection from the cervical region or may occur following thoracic injury or perforation of the oesophagus, which can be a complication of an endoscopic procedure. It is a life-threatening situation requiring immediate treatment (evacuation of pus and antibiotic therapy).

Superior mediastinum (content is described ventrodorsally)

- 1 **Thymus** and its vessels and lymphatic drainage
- 2 **Origin of the sternothyroid and sternohyoid**
- 3 **Internal thoracic artery and vein** and their branches and tributaries
- 4 **Superior vena cava** and its tributaries
- 5 **Phrenic nerves and pericardiacophrenic vessels**
- 6 **Aortic arch** and its branches
- 7 **Trachea** to its bifurcation
- 8 **Oesophagus**
- 9 **Vagus nerve**
  - 9.1 **Cardiac branches**
  - 9.2 **Left recurrent laryngeal nerve**
- 10 **Right and left sympathetic trunk**
- 11 **Cardiac nerves** from sympathetic trunk
- 12 **Azygos vein and accessory hemi-azygos vein**
- 13 **Thoracic duct**
- 14 **Tracheobronchial and paratracheal lymph nodes**
- 15 **Juxtaoesophageal nodes**
- 16 **Longus colli**

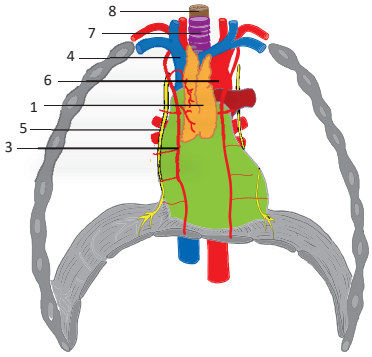

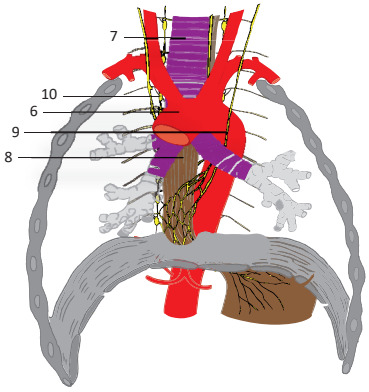

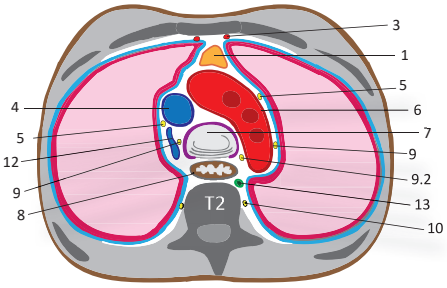

Transverse section at the level of T2 (inferior view)

Anterior inferior mediastinum

- 1.1 **Internal thoracic artery and vein** and their branches and tributaries
- 1.2 **Sternopericardiac ligaments**
- 1.3 **Parasternal and prepericardial lymph nodes**
- 1.4 **Transversus thoracis**

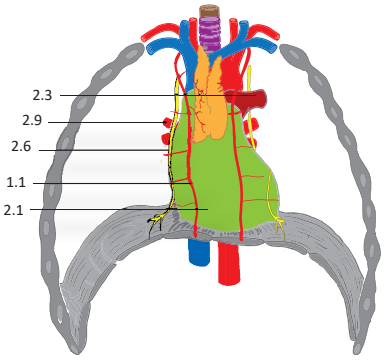

Middle inferior mediastinum

- 2.1 **Heart in the pericardium**
- 2.2 **Ascending aorta**
- 2.3 **Pulmonary trunk**
- 2.4 **Superior vena cava**
- 2.5 **Inferior vena cava**
- 2.6 **Phrenic nerves**
- 2.7 **Pericardiacophrenic vessels**
- 2.8 **Cardiac plexus**
- 2.9 **Pulmonary veins**
- 2.10 **Main bronchi**
- 2.11 **Lateral pericardial lymph nodes**

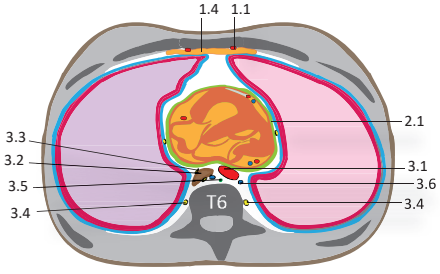

Transverse section at the level of T6 (inferior view)

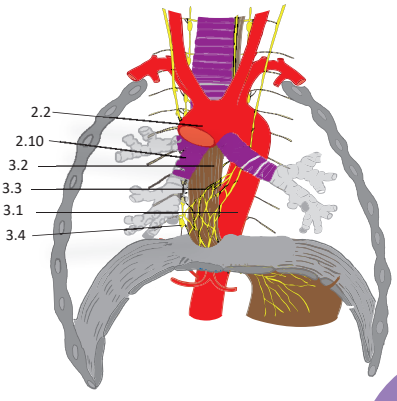

Posterior inferior mediastinum

- 3.1 **Thoracic aorta**
- 3.2 **Oesophagus**
- 3.3 **Oesophageal plexus**
  – the anterior and posterior vagal trunk from both vagus nerves
- 3.4 **Sympathetic trunk, n. splanchnicus major, minor et imus**
- 3.5 **Thoracic duct**
- 3.6 **Azygos vein, hemi-azygos and accessory hemi-azygos vein** and its tributaries
- 3.7 **Prevertebral and juxtaoesophageal lymph nodes**

This copy belongs to ali yaghoubi

The oesophagus, trachea and aorta pass very close to each other in the mediastinum. The trachea is located ventral to the oesophagus. The aorta is initially located in front of the trachea, then it arches backwards and to the left. Below the level of vertebra T4 it is located dorsal to the oesophagus.

- 1 **Oesophagus**
  - 1.1 **Cervical part** (*pars cervicalis*) – is located in the visceral space of the neck
    - – begins at the level of vertebra C6, where it is attached to the pharynx
    - – the trachea is located ventral and the vertebral column dorsal to the oesophagus
  - 1.2 **Thoracic part** (*pars thoracica*)
    - – begins after passing through the thoracic inlet
    - – it passes through the superior and then posterior inferior mediastinum
    - – beneath the level of vertebra T4 the aorta passes dorsal to the oesophagus
    - – the heart and pericardium are located ventral to the oesophagus
    - – the vagus nerves run on its lateral sides and form the oesophageal plexus
    - – in the posterior inferior mediastinum the right vagus nerve moves to the posterior surface of the oesophagus forming the posterior vagal trunk and the left vagus nerve moves to the anterior surface of the oesophagus forming the anterior vagal trunk
    - – the oesophagus and vagal trunks pass through the oesophageal hiatus of the diaphragm at the level of vertebra T10 to reach the abdominal cavity
  - 1.3 **Abdominal part** (*pars abdominalis*) – short part travels from the oesophageal hiatus of the diaphragm to the cardia of the stomach at the level of vertebra T11
- 2 **Trachea**
  - 2.1 **Cervical part** (*pars cervicalis*) – is located in the visceral space of the neck
    - – the cervical part of the trachea begins at the level of vertebra C6 where it is attached to the larynx
    - – the thyroid and parathyroid glands are ventral and the oesophagus dorsal to the trachea
  - 2.2 **Thoracic part** (*pars thoracica*) – passes through the superior mediastinum
    - – at the level of vertebra T4 it bifurcates into the main bronchi
    - – the aortic arch is located on the left side of the trachea at the level of the tracheal bifurcation
- 3 **Aorta**
  - 3.1 **Ascending aorta** – the first part of the aorta, located inside the pericardium
  - 3.2 **Arch of aorta** – arches through the superior mediastinum towards the vertebral column
    - – is located to the left of the trachea and oesophagus
    - – the left recurrent laryngeal nerve passes under the aortic arch

Other structures

- 4 **Thyroid gland** – located ventrolateral to the trachea
- 5 **Vagus nerve**
  - 5.1 **Right vagus nerve**
    - 5.1.1 **Right recurrent laryngeal nerve** – runs under the right subclavian artery
      - – then it runs in a groove between the trachea and the oesophagus
    - 5.1.2 **Posterior vagal trunk**
  - 5.2 **Left vagus nerve**
    - 5.2.1 **Left recurrent laryngeal nerve**
      - – runs under the aortic arch
      - – then passes in a groove between the trachea and oesophagus
    - 5.2.2 **Anterior vagal trunk**

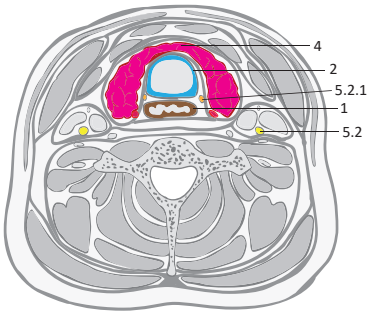

Transverse section at the level of C6

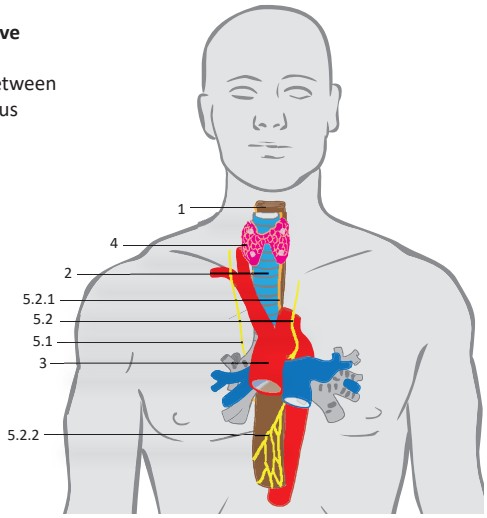

Clinical notes

The triangle of Kilian (Kilian's dehiscence) is located between the cricopharyngeal and thyropharyngeal parts of the inferior pharyngeal constrictor. The triangle of Laimer is located between the cricopharyngeal part of the inferior pharyngeal constrictor and the superior margin of the longitudinal muscle fibers of the oesophagus. Both these sites represent weakened areas where diverticula may occur. Zenker's diverticulum occurs in the triangle of Kilian. Laimer's diverticulum occurs in the triangle of Laimer. Diverticula occurring in these areas are typically "false" diverticula. A true diverticulum involves an out-pocketing of all layers of the wall of an organ, whereas a false diverticulum involves only the mucosa and submucosa.

The pyramidal lobe of the thyroid gland is present in about 40% of cases. It is located in the site where a tracheostomy is performed. Care must be taken when performing this procedure because the thyroid gland may profusely bleed if injured.

The diaphragm is the **main muscle of respiration** and is an important **postural muscle**. It separates the abdominal and thoracic cavities and, via its apertures, enables the passage of organs, vessels and nerves between these two cavities.

Apertures and the structures they transmit

- 1 **Caval opening** (*foramen venae cavae*) – at the level of vertebra T8
  - 1.1 **Inferior vena cava**
  - 1.2 **Right phrenic nerve** and its phrenicoabdominal branches
- 2 **Oesophageal hiatus** (*hiatus oesophageus*) – at the level of vertebra T10
  - 2.1 **Oesophagus**
  - 2.2 **Vagus nerve** – the anterior and posterior vagal trunks
- 3 **Aortic hiatus** (*hiatus aorticus*) – at the level of vertebra T12
  - 3.1 **Aorta**
  - 3.2 **Thoracic duct**
- 4 **Lumbar part** (*pars lumbalis*)
  – the muscular part, perforated by nerves and veins
  - 4.1 **Right and left sympathetic trunk**
  - 4.2 **Greater, lesser and least splanchnic nerve**
  - 4.3 **Azygos and hemi-azygos vein**
- 5 **Costal part** (*pars costalis*)
  - 5.1 **Left phrenic nerve** and its phrenicoabdominal branches
- 6 **Sternocostal triangle** (*trigonum sternocostale*)
  - 6.1 **Internal thoracic artery and vein**
    – runs ventrally in the sternocostal triangle
    – after passing through the diaphragm these vessels are termed the superior epigastric artery and veins

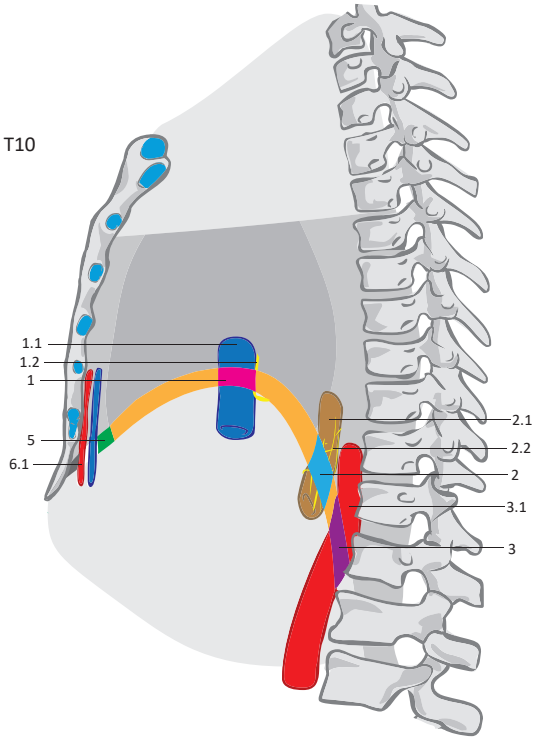

Sagittal section of the diaphragm

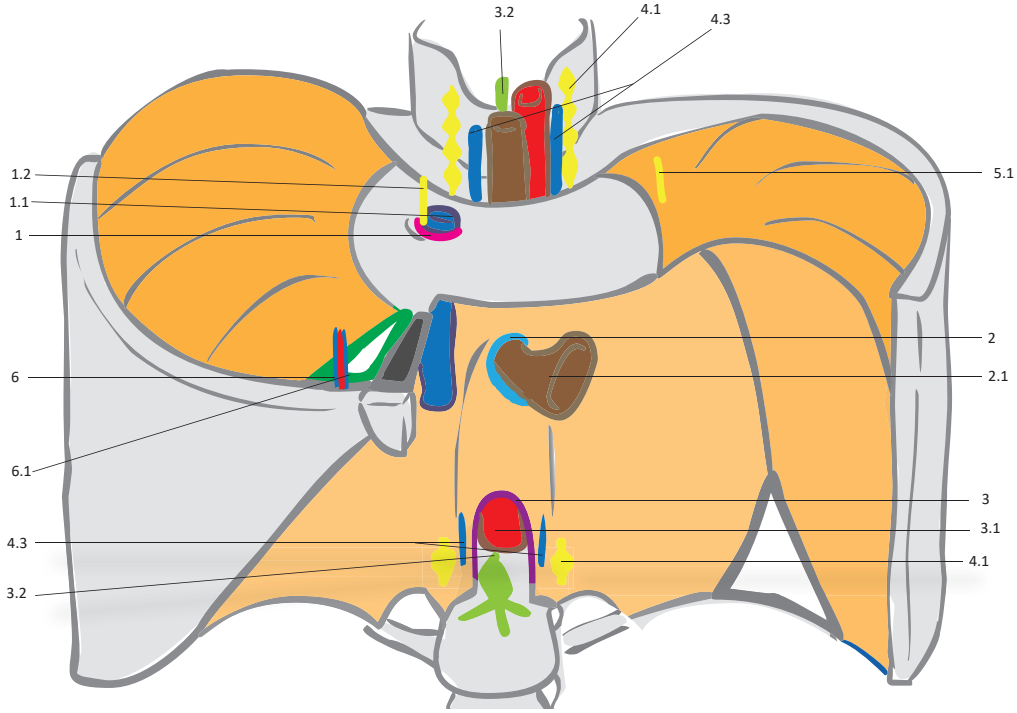

View of the diaphragma from the front (after removing the thoracic wall and part of the abdominal wall)

This copy belongs to ali yaghoubi

Abdominal topography describes the structure of the abdominal wall and the topographical regions within the abdomen. It describes the **peritoneal cavity** and **retroperitoneal space**, which is the space behind the peritoneum. **The surface of the abdomen** is divided by three horizontal and two vertical imaginary lines into **nine regions**.

Regions

Clinical and anatomical terms

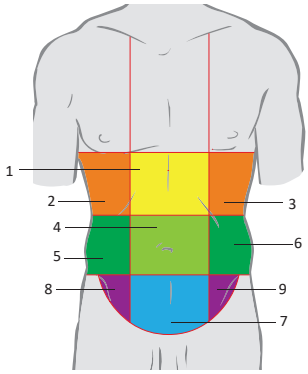

- 1 **Epigastrium** (*regio epigastrica*)
- 2 **Right hypochondrium** (*regio hypochondriaca dextra*)
- 3 **Left hypochondrium** (*regio hypochondriaca sinistra*)
- 4 **Umbilical/central region** (*regio umbilicalis*)
- 5 **Right lumbar region** (*regio lateralis dextra*)
- 6 **Left lumbar region** (*regio lateralis sinistra*)
- 7 **Hypogastrium / suprapubic region** (*regio pubica*)
- 8 **Right iliac region** (*regio inguinalis dextra*)
- 9 **Left iliac region** (*regio inguinalis sinistra*)

Lines

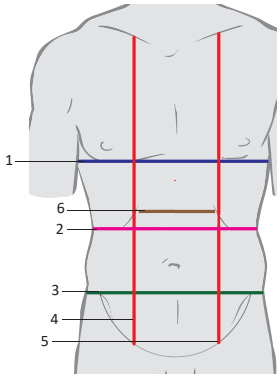

- 1 **Xiphosternal line** (*linea xiphosternalis*)
  – a horizontal line passing through the xiphosternal synchondrosis
- 2 **Subcostal line** (*linea subcostalis*)
  – a horizontal line passing through the lowest points of the costal arches
- 3 **Interspinous line** (*linea interspinosa*)
  – a horizontal line passing through the anterior superior iliac spines
- 4 **Left midclavicular line** (*linea medioclavicularis sinistra*)
  – a vertical line passing through the middle of the left clavicle
- 5 **Right midclavicular line** (*linea medioclavicularis dextra*)
  – a vertical line passing through the middle of the right clavicle
- 6 **Transpyloric line** of Addison (*linea transpylorica*)
  – a horizontal line between the sternal ends of the 9th ribs

Organ projection on the anterior abdominal wall

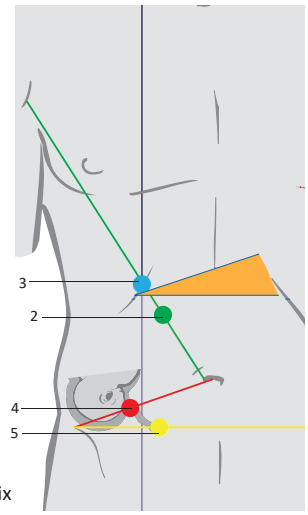

- 1 **Labbé triangle**
  – the projection of the stomach (it touches the abdominal wall)
  – is formed by the transpyloric line, the left costal arch and a line connecting the 9th rib cartilage on the right with the 8th rib cartilage on the left
- 2 **Desjardin's point**
  – the projection of the major duodenal papilla
  – is located on a line connecting the umbilicus to the apex of the right axilla, appoximately 6–7 cm from the umbilicus
- 3 **Murphy's point**
  – the projection of the fundus of the gallbladder (it touches the abdominal wall)
  – an intersection of the right costal arch and right midclavicular line
- 4 **McBurney' point** – the projection of the cecal ostium of the vermiform appendix from
  – is located one-third of the distance from anterior iliac spine to the umbilicus (line of Monro)
- 5 **Lanz' point** – the projection of the tip of a vermiform appendix in the pelvic position
  – at the border of the right and middle thirds of the interspinous line

6 **Point of Sonnenberg** – a projection of the vermiform appendix in the pelvic cavity (only in case of its pelvic position)
  – an intersection of the interspinous line and lateral margin of the right rectus abdominis

The abdominal region can be easily divided into four quadrants by two perpendicular lines crossing the umbilicus.

The spinoumbilical line of Monro (*linea spinoumbilicalis*) is a connection of the right superior anterior iliac spine and umbilicus.

The semilunar area (space) of Traube is a place under the left costal arch, in which the fundus of the stomach can be found.

The extraperitoneal fascia (*fascia extraperitonealis*) is a layer of reticular fibrous tissue between the peritoneum and parietal abdominal fascia. Its thickness varies a lot, it is thick and filled with adipose tissue on the back (pararenal fat pad), but thin and fibrous on the abdomen, mostly at the linea alba.

The abdominal fasciae page 130.

Clinical notes

Peritoneocentesis (a kind of paracentesis) is performed by inserting a needle through the abdominal wall into the peritoneal cavity. It is performed between the left and middle thirds of a line connecting the umbilicus to the left anterior superior iliac spine (linea spinumbilicalsi sinistra). If performed under ultrasound guidance, it may be done at a different site.

Tender palpation at McBurney's point is a sign of acute appendicitis.

Traube's sign is recognised by dull percussion in the Traube's space. It implies enlargement of the spleen.

The ventrolateral abdominal wall is formed by number of layers which need to be cut when opening the abdominal cavity (laparotomy). Following laparotomy, it is necessary to close them in the proper anatomical position.

- 1 **Skin and subcutaneous tissue**
  - 1.1 **Fatty layer** (*panniculus adiposus*) – contains subcutaneous veins
  - 1.2 **Fascia of Camper** – composed of fine fibrous fibers within subcutaneous fat
- 2 **Fascia of Scarpa** (*fascia subcutanea abdominis*)
  – a membranous layer of subcutaneous tissue (*stratum membranosum telae subcutaneae*)
  – separates the subcutaneous and deep fatty layer
- 3 **Deep fatty layer** – thinner than the superficial fatty layer
- 4 **Superficial abdominal fascia** – the fascia of the external oblique
- 5 **External oblique**
- 6 **Internal oblique**
- 7 **Transversus abdominis**
- 8 **Transversalis fascia** – part of the parietal abdominal fascia
- 9 **Parietal peritoneum**

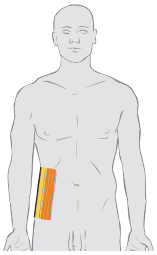



Section of the abdominal wall

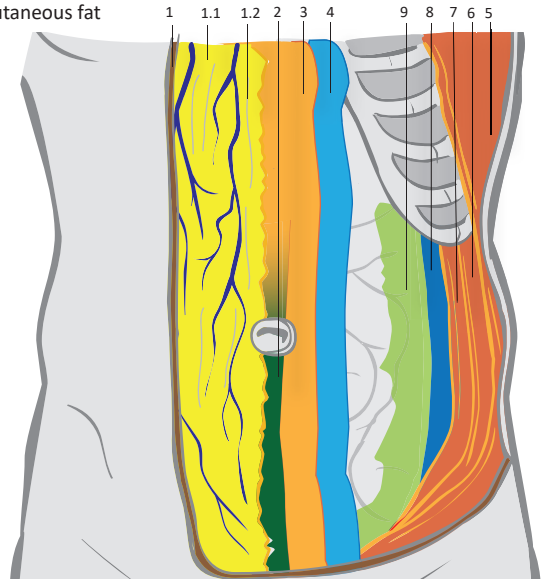

Layers of the abdominal wall

4.1.1 **Rectus sheath** – Vagina musculi recti abdominis

The rectus sheath is a fibrous structure that envelops the rectus abdominis. It is formed by the aponeuroses of the lateral abdominal wall muscles and consists of an anterior and a posterior lamina. The posterior lamina is deficient below the umbilicus; its inferior margin forms the arcuate line (of Douglas). The fibres of the aponeuroses forming the rectus sheath decussate in the midline forming the linea alba, which extends form the xiphoid process to the pubic symphysis.

Above the umbilicus (structures listed in a ventrodorsal direction)

- 1 **Anterior layer of rectus sheath** (*lamina anterior vaginae musculi recti abdominis*)
  - 1.1 **Aponeurosis of the external oblique**
  - 1.2 **Aponeurosis of the internal oblique** – the anterior part
- 2 **Rectus abdominis** and epigastric vessels
- 3 **Poserior layer of rectus sheath** (*lamina posterior vaginae musculi recti abdominis*)
  - 3.1 **Aponeurosis of the internal oblique** – the posterior part
  - 3.2 **Aponeurosis of the transversus abdominis**
- 4 **Transversalis fascia**

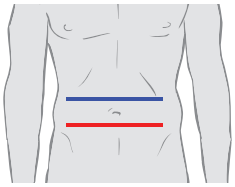

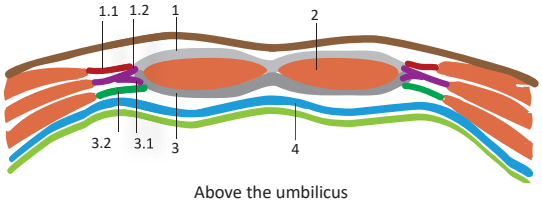

Above the umbilicus

Below the umbilicus (structures listed in a ventrodorsal direction)

- 1 **Rectus sheath** (*vagina musculi recti abdominis*)
  - 1.1 **Aponeurosis of the external oblique**
  - 1.2 **Aponeurosis of the internal oblique**
  - 1.3 **Aponeurosis of the transversus abdominis**
- 2 **Rectus abdominis**
  3 **Pyradmidalis** – a short muscles, located ventral to the rectus abdominis in the lower part of the anterior abdominal wall
- 4 **Transversalis fascia**

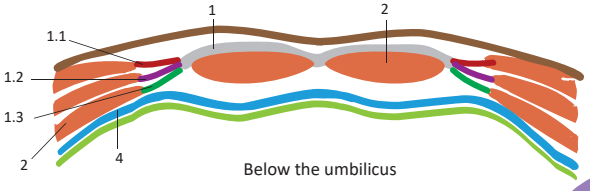

Below the umbilicus

This copy belongs to ali yaghoubi

The inguinal canal is a 4–5cm long **passageway through the anterior abdominal wall in the region of the groin**. It passes ventrocaudally from its entrance at the deep inguinal ring in the transveralis fascia, through to the superficial inguinal ring in the aponeurosis of the external oblique. The inguinal canal **allows communication between the subperitoneal space and the subcutaneous tissue of the groin**. During development, the **testes descend through the inguinal canal** to reach their definitive position in the scrotum. In males, **the spermatic cord** is located in the inguinal canal. In females, inguinal canal transmits **the round ligament of the uterus**, which attaches to the labia majora and holds the urerus in anteversion and anteflexion.

Boundaries

Canal

- 1 **Inguinal canal** (*canalis inguinalis*)
  - 1.1 **Deep inguinal ring** (*anulus inguinalis profundus*) – entrance
  - 1.2 **Superficial inguinal ring** (*anulus inguinalis superficialis*) – exit

Walls

- 2 **Ventrally:** aponeurosis of the external oblique
- 3 **Dorsally:** transversalis fascia
  – covers the gap between the fused inferior margins of internal oblique and transversus abdominis and the inguinal ligament
- 4 **Cranially:** the inferior margins of internal oblique and transversus abdominis
  – the inferior margins of the aponeuroses of the internal oblique and transversus abdominis fuse medially to form the inguinal falx, also known as the conjoint tendon (*falx inguinalis, tendo conjuctivus*), which runs along the lateral margin of the rectus abdominis and inserts on the pecten pubis
- 5 **Caudally:** inguinal ligament of Poupart

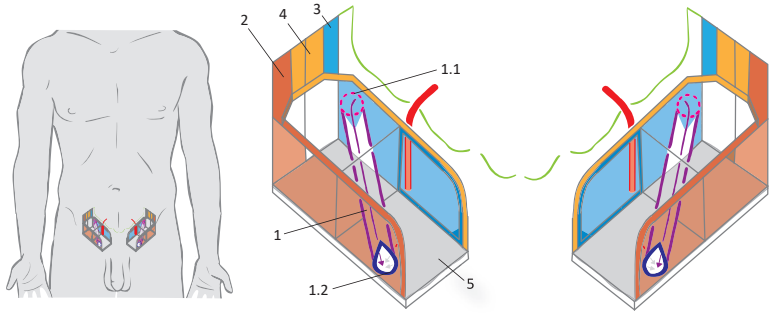

Scheme of the boundaries of the inguinal canal

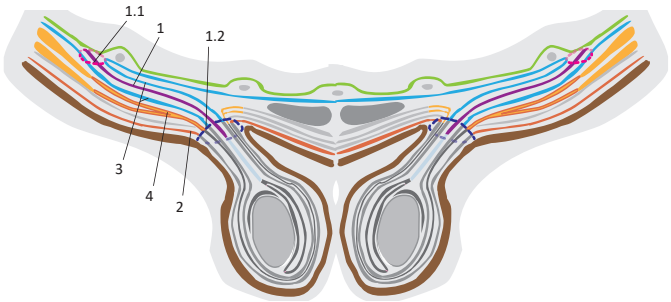

Schematic frontal section of the inguinal canal

Content

In males:
1 Spermatic cord
2 Ilioinguinal nerve
3 Genital branch of genitofemoral nerve

In females:
1 Round ligament of uterus
2 Ilioinguinal nerve
3 Genital branch of genitofemoral nerve

Topography

The iliopubic tract of Thomas (*tractus iliopubicus*) is a thickened band of the transversalis fascia in its intersection into the area of the inguinal canal. It follows the inguinal canal via the deep layers and forms the inferior edge of the deep inguinal ring on one side and the medial edge of the femoral canal on the other side. It serves as a good structure for orientation during laparoscopic inguinal and femoral hernia surgeries.

The interfoveolar ligament (*ligamentum interfoveolare*) can contain muscle bundles.

The inguinal ligament is not a real ligament but rather a thickening of the aponeurosis of the external oblique.

The ilioinguinal nerve does not enter the inguinal canal through the deep inguinal ring. It descends into the inguinal canal via its superior wall and exits through the superficial inguinal ring.

Clinical notes

Cryptorchidism refers to undescended testes. Undescended testes are often located in the inguinal canal.

Layers (from outside to inside)

- 1 **Superficial inguinal ring** (*anulus inguinalis superficialis*)
  - an aperture in the aponeurosis of the external oblique
    - 1.1 **Medial crus** (*crus mediale*) – the medial fibrous margin of the ring
    - 1.2 **Lateral crus** (*crus laterale*) – the lateral fibrous margin of the ring
    - 1.3 **Intercrural fibers** (*fibrae intercrurales*)
      - fibers strengthening the aponeurosis on the craniolateral margin of the ring
  - 2 **Space under the inguinal falx**
    - 2.1 **Inguinal falx / conjoint tendon of Henle** (*falx inguinalis / tendo conjunctivus*)
      - the caudal fused margin of the internal oblique and transversus abdominis
    - 2.2 **Interfoveolar ligament of Hesselbach** (*ligamentum interfoveolare*)
      - passes ventral to the inferior epigastric vessels
- 3 **Deep inguinal ring** (*anulus inguinalis profundus*)
  - is formed by the transveralis fascia, as it extends into the inguinal canal as the internal spermatic fascia
  - is bound laterally by the interfoveolar ligament and inferior epigastric vessels

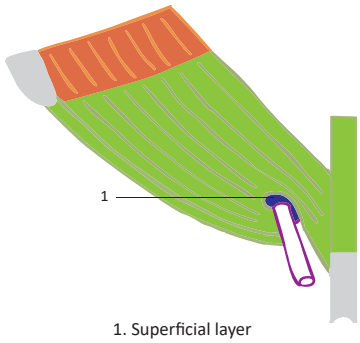

1. Superficial layer

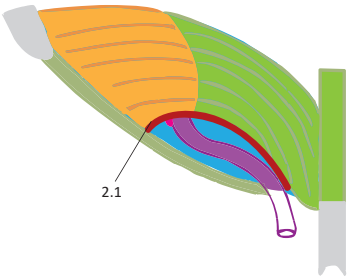

2nd layer

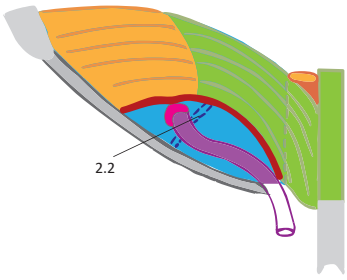

3rd layer

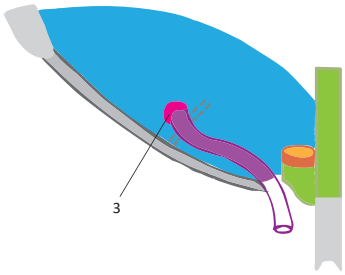

4. Deep layer

Boundaries of the openings of the inguinal canal

1 **Superficial inguinal ring** (*anulus inguinalis superficialis*)
- an aperture in the aponeurosis of the external oblique
- projects to the medial inguinal fossa on the internal surface of the abdominal wall

- 1 **Mediocranially:** medial crus (*crus mediale*)
  - inserts on the pubic tubercle and partially continues on the opposite side as the reflected ligament of Colles (*ligamentum reflexum*)
- 2 **Laterocaudally:** lateral crus (*crus laterale*)
  - blends into the inguinal ligament
- 3 **Laterally:** intercrural fibers *(fibrae intercrurales)*
  - pass between the medial and lateral crura
- 4 **Medially:** reflected ligament of Colles (*ligamentum reflexum*)
  - inserts on the linea alba
  - a continuation of the medial crus on the contralateral side

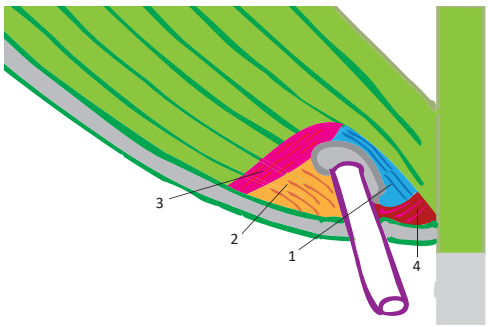

Boundaries of the superficial inguinal ring

2 **Deep inguinal ring** (*anulus inguinalis profundus*)
- it is not a real aperture but a site of a funnel-like drawing of the transversalis fascia into the inguinal canal, the fascia continues as the internal spermatic fascia

- 1 **Cranially:** inferior margin of the transversus abdominis
- 2 **Caudally:** inguinal ligament (*ligamentum inguinale*)
- 3 **Medially:** interfoveolar ligament (*ligamentum interfoveolare*)
  - the transversalis fascia – thickened because of a pulling of the ductus deferens / round ligament of the uterus
  - the inferior epigastric vessels pass behind it
- 4 **Lateral:** angle in which bundles of the transversus abdominis begin from the inguinal ligament

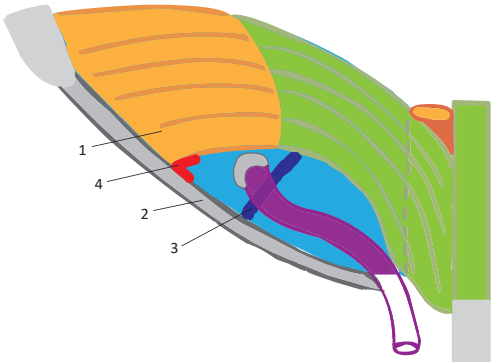

Boundaries of the deep inguinal ring

This copy belongs to ali yaghoubi

The **internal surface of the anterior abdominal wall** is lined by parietal peritoneum and is decorated by **five folds** and **six depressions**.

Folds

- 1 **Median umbilical fold** (*plica umbilicalis mediana*)
  – an unpaired fold formed by the median umbilical ligament (a remnant of the urachus)
- 2 **Medial umbilical fold** (*plica umbilicalis medialis*)
  – a paired fold formed by the medial umbilical ligament
- 3 **Lateral umbilical fold** (*plica umbilicalis lateralis*)
  – a paired fold formed by the inferior epigastric vessels

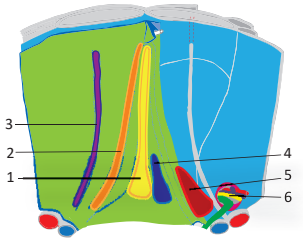

Anterior abdominal wall, posterior view

Depressions

- 4 **Supravesical fossa** (*fossa supravesicalis*)
  – between the median and medial umbilical folds
- 5 **Medial inguinal fossa / inguinal triangle of Hesselbach** (*fossa inguinalis medialis / trigonum inguinale*)
  – between the medial and lateral umbilical folds
- 6 **Lateral inguinal fossa / deep inguinal ring** (*fossa inguinalis lateralis / anulus inguinalis profundus*)
  – laterally to the lateral umbilical fold

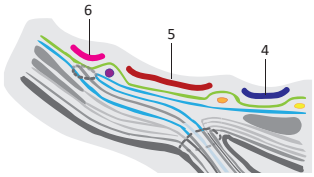

Schematic frontal section of the inguinal canal

4.3.1 Common sites of hernia

In the areas where **the abdominal wall is thinner** it is possible for the **abdominal structures to go through** (prolapse). **Hernia** is an outpouching of the parietal peritoneum through a preformed or secondarily established opening. **A hernia defect** is a canal or ring between the abdominal wall and the **hernial sac**, formed by the parietal peritoneum and pathological connective tissue. **Hernia can contain** the intestines, omentum and other abdominal organs.

Herniae and their passages

1 **Inguinal**
- 1.1 **Direct** – pass directly through the medial inguinal fossa and the superficial inguinal ring
  – it is possible to feel the pulse of the inferior epigastric artery
  – are acquired (develop after birth)
  – may enter the scrotum in men (scrotal hernia)
- 1.2 **Indirect** – pass through the lateral inguinal fossa and the superficial inguinal ring
  – it is not possible to feel the pulse on the inferior epigastric artery
  – can be congenital or acquired
  – in men, it can pass through the inguinal canal into the scrotum (scrotal hernia)

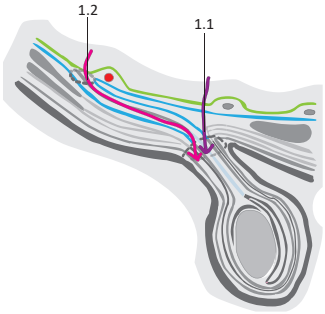

Schematic frontal section of the inguinal canal

- 2 **Femoral** – pass through the femoral canal to the saphenous opening and occur more frequently in women
- 3 **Umbilical** – pass through the umbilical ring to the subcutaneous tissue
- 4 **Epigastric** – occur through the linea alba and/or linea semilunaris, in which the muscle layers are missing
- 5 **Obturator** – pass through the obturator foramen

6 **Lumbar** – pass through the inferior or superior lumbar triangles

- 7 **Hiatal sliding** – the cardia (or another part of the stomach) passes through the oesophageal hiatus of the diaphragm

8 **Hiatal paraesophageal** – the fundus of the stomach passes through the oesophageal hiatus of the diaphragm, into the mediastinum

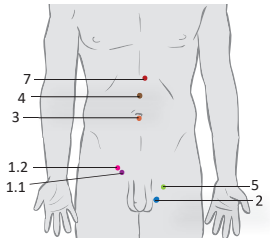

Topography

The urachus is the remnant of the allantois, an embryonic structure which connects the urinary bladder to the umbilial cord. The urachus obliterates in the intrauterine period and forms a single fibrous band called the median umbilical ligament (the cord of the urachus, *chorda urachi*).

The paired umbilical artery obliterates early after birth and forms a fibrous band called the medial umbilical ligament. It is also known as the occluded part of the umbilical artery (pars occlusa arteriae umbilicalis) and is also known as the cord of the umbilical artery (*chorda arteriae umbilicalis*).

Secondarily retroperitoneal organs are derived from the gastrointestinal tube and migrate during intrauterine development to the retroperitoneal space. Around them and the peritoneum proper, we can find loose fasciae (remnants of their original mesenteries or peritoneal covers).

Inguinal hernias in women pass close to the labia majora (labial hernia).

Internal abdominal hernias are much less common than external hernias. They do not pass through the abdominal wall. They are located within the abdominal cavity and pass into recesses (pouches) of peritoneum.

Clinical notes

The anterior and posterior layer of the renal fascia of Gerota fuse together laterally and cranially, they fuse medially with adventitia of large abdominal vessels. Therefore, an inflammation in the renal surroundings usually spreads caudally.

The loose connective tissue of the retroperitoneal space continues smoothly into the connective tissue of the pelvis and lower limbs. It forms an extensive topographical area from the diaphragm to as low as the popliteal fossae. In this cavity, inflammatory processes can spread (tuberculosis in the past).

Abdominal organ prolapse is a condition when the organs protrude from the abdominal wall through a disruption in the peritoneum. The hernia sac is not present.

Hernia can pass through postsurgical scars anywhere in the abdominal wall.

The abdominal cavity is a large region, **bordered cranially by the diaphragm**. **Caudally it is continuous with the lesser pelvis** at the linea terminalis. The greater pelvis belongs to the abdominal cavity, but the lesser pelvis contains its own cavity, the pelvic cavity, which is continuous with the abdominal cavity. The abdominal cavity contains the **peritoneal cavity, the intraperitoneal organs, the retroperitoneal space and the preperitoneal space**.

Boundaries

- 1 **Cranially:** diaphragm
- 2 **Caudally:** continues as the pelvic cavity – beneath the linea terminalis
- 3 **Ventrally:** rectus abdominis
- 4 **Dorsally:** quadratus lumborum
- 5 **Laterally:** transversus abdominis and internal oblique

Divisions

- 5 **Peritoneal cavity** (*cavitas peritonealis*)
- 6 **Retroperitoneal space** (*spatium retroperitoneale*) – a space behind the peritoneum
- 7 **Preperitoneal space** (*spatium preperitoneale*) – a space in front of the peritoneum

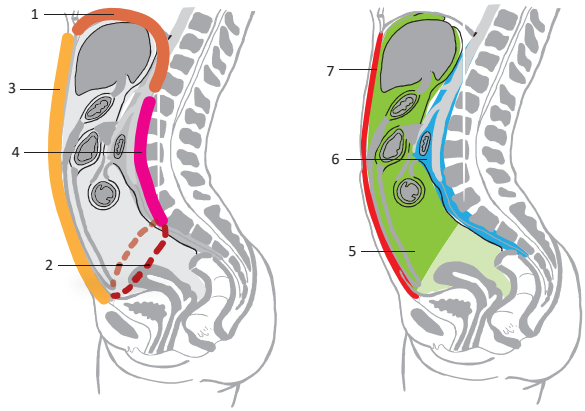

Sagittal section of the female body

4.5 Retroperitoneal space – Retroperitoneum

The retroperitoneal space is located **in the dorsal part of the abdominal cavity behind the peritoneum**. It is filled with loose connective and **contains organs, vessels and nerves**. It **communicates cranially with the posterior inferior mediastinum** through the apertures of the diaphragm and it **continues caudally as the subperitoneal space of the pelvic cavity**.

Boundaries

1 **Ventrally:** parietal peritoneum
2 **Dorsally:** parietal abdominal fascia (*fascia endoabdominalis*)
3 **Cranially:** connected with the posterior inferior mediastinum
4 **Caudally:** continous with the subperitoneal space

Content

1 **Primary retroperitoneal organs:**

- 1.1 **Suprarenal glands**
- 1.2 **Kidneys** and their covers
- 1.3 **Ureters**
- 1.4 **Abdominal aorta** and its branches
- 1.5 **Inferior vena cava** and its tributaries
- 1.6 **Sympathetic trunks** and their branches
- 1.7 **Abdominal aortic plexus** (autonomic plexus)
- 1.8 **Lumbar plexus**
- 1.9 **Cisterna chyli, lumbar trunks and lumbar lymph nodes**

2 **Secondary retroperitoneal organs:**

- 2.1 **Duodenum** (all parts expect for the ampulla / duodenal cap)
- 2.2 **Pancreas** (head, body)
- 2.3 **Ascending colon**
- 2.4 **Descending colon**

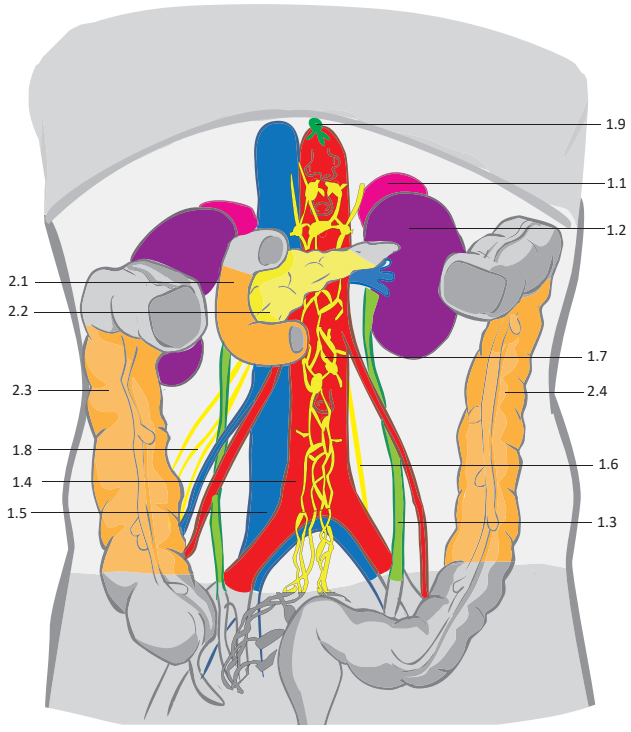

Retroperitoneal organs, posterior view

This copy belongs to ali yaghoubi

The whole peritoneal cavity is **filled with intraperitoneal organs**. Physiologically, it is not a real cavity, it is a system of communicating spaces among organs and their mesenteries. In the phase of adhesions and fixations (10th–40th week of intrauterine development) **peritoneal pouches and folds** are formed. They create the topography of the peritoneal cavity. **The transverse mesocolon divides the cavity into the supramesocolic and inframesocolic part**. **The mesenteric root divides the inframesocolic cavity into the left and right paracolic space**.

Supramesocolic part

Content:

- 1.1 **Liver**
- 1.2 **Gallbladder and cystic duct**
- 1.3 **Oesophagus** (abdominal part)
- 1.4 **Stomach**
- 1.5 **Duodenum** (ampulla / duodenal cap)
- 1.6 **Pancreas** (tail)
- 1.7 **Spleen**

Supplying artery:

– Coeliac trunk

Inframesocolic part

Content:

- 2.1 **Jejunum**
- 2.2 **Ileum**
- 2.3 **Caecum**
  - 2.3.1 **Vermiform appendix**
- 2.4 **Transverse colon**
- 2.5 **Sigmoid colon**
- 2.6 **Rectum** (upper 1/3)

Supplying artery:

– Superior mesenteric artery

– Inferior mesenteric artery

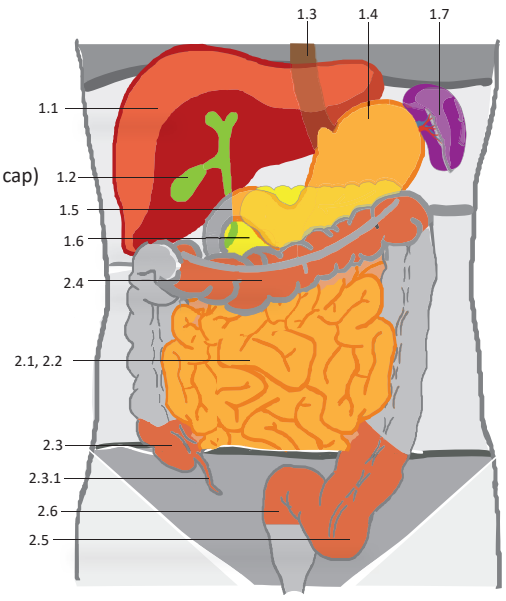

Peritoneal cavity, anterior view

4.6.1 Root of the transverse mesocolon – Radix mesocoli transversi

The root of the transverse mesocolon projects on both kidneys, on the descending part of the duodenum and on the head and body of the pancreas. It divides the peritoneal cavity into **the supramesocolic and inframesocolic part**.

- 1 **Root of transverse mesocolon**
  - 1.1 **Right kidney**
  - 1.2 **Duodenum**
    – descending part
  - 1.3 **Pancreas**
    – head and body
  - 1.4 **Left kidney**

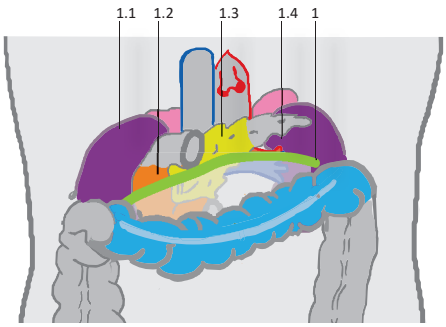

Transverse colon with transverse mesocolon, anterior view

Topography

Peritoneal pouches and folds are formed in the phase of adhesions and fixations, which takes place during the 10th–40th weeks of intrauterine development.

The subhepatic space is located around the porta hepatis and the organs lying on the visceral surface of the liver (gallbladder and biliary tract). Tumors in this area often present with painless jaundice (icterus) and often have a fatal prognosis.

The subphrenic space is an area between the diaphragmatic surface of the liver and inferior surface of the diaphragm. Pathological processes in this area may present with the phrenic sign: pain radiating into the right shoulder (sensory fibres of the phrenic nerve reach the inferior surface of the diaphragm).

The omental bursa (lesser sac) is formed by the rotation of the stomach during the 7th and 8th weeks of intrauterine development.

The retroinguinal space of Bogros (*spatium retroinguinale*) is part of the preperitoneal space. It is bound ventrally by the transversalis fascia and dorsally by the parietal peritoneum. Medially it contains the external iliac vessels and femoral nerve.

The retropancreatic membrane of Treitz is a fibrous membrane stretched between the pancreas and the great vessels (abdominal aorta and inferior vena cava).

The omental (epiploic) foramen is a narrow (3 cm diameter) vertical slit connecting the greater and lesser sacs.

Clinical notes

Perforation of the gastrointestinal tube in the abdomen results in peritonitis (inflammation of the peritoneal cavity) and accumulation of air in the peritoneal cavity. Air in the peritoneal cavity (pneumoperitoneum) can be recognized on native X-rays as crescent-shaped air bubbles under the diaphragm.

During laparoscopic surgery a pneumoperitoneum is produced by pumping gas into the peritoneal cavity. This gives the surgeon more room to operate and allows better visualisation of the abdominal organs.

In each fold of the peritoneum pathological structures can be found (inflammation, tumors, exudation, blood, etc.). It is therefore necessary to inspect them all during surgery.

The omental bursa (lesser sac) is a **horizontally oriented space in the abdominal cavity**. It is located behind the stomach and **communicates physiologically with the rest of the peritoneal cavity (greater sac)** on the right via the **omental foramen**. The omental bursa can serve as extra space enabling changes in the size and shape of the stomach.

Boundaries

1 **Ventrally:**
- 1.1 **Stomach**
- 1.2 **Lesser omentum**
- 1.3 **Gastrocolic ligament**

2 **Dorsally:**
- 2.1 **Parietal peritoneum**
- 2.2 **Pancreas** (behind the peritoneum)
- 2.3 **Duodenum** (in the middle)

3 **Cranially:**
- 3.1 **Caudate lobe of liver**
- 3.2 **Left diaphragmatic vault**

4 **Caudally:**
- 4.1 **Transverse colon**
- 4.2 **Transverse mesocolon**
- 4.3 **Greater omentum**

5 **Left side:**
- 5.1 **Spleen**
- 5.2 **Gastrophrenic ligament**
- 5.3 **Gastrosplenic ligament**
- 5.4 **Splenorenal ligament**
  (contains the splenic vessels and tail of the pancreas)
- 5.5 **Phrenicosplenic ligament**
- 5.6 **Splenocolic ligament**

6 **Right side:**
- 6.1 **Omental foramen of Winslow**
  – the entrance to the omental bursa has boundaries:
  Cranial: caudate lobe of liver
  Caudal: superior part of duodenum
  Ventral: hepatoduodenal ligament
  Dorsal: inferior vena cava
  – organs and vessels are covered by reflected ligaments and peritoneum

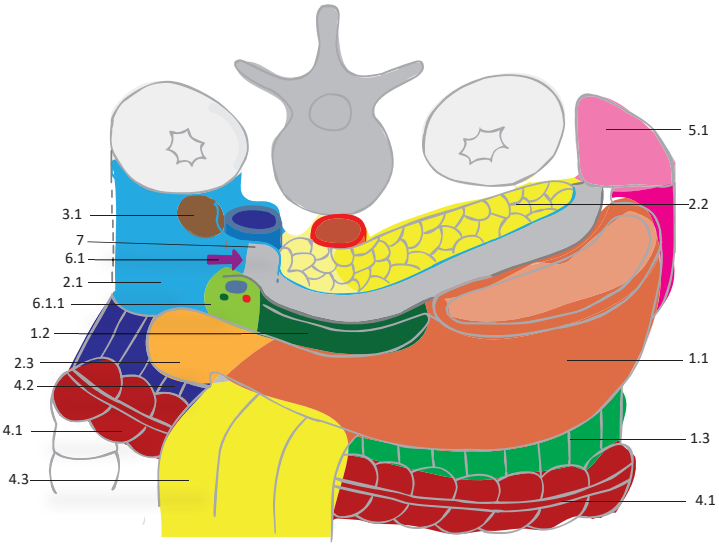

Schematic transverse section of the peritoneal organs and omental bursa, section at the level L2, anterior superior view

Parts and recesses

7 **Vestibule**
– the entry part of the omental bursa, under the caudate lobe of the liver and in front of the inferior vena cava

8 **Isthmus**
– a narrowing at the omental tuberosity of the pancreas, bordered by two peritoneal folds (hepatopancreatic and gastropancreatic fold)

9 **Superior recess**
– extends cranially from the vestibule between the inferior vena cava and the oesophagus

10 **Splenic recess**
– extends to the left towards the splenic hilum

11 **Inferior recess**
– extends between the anterior and posterior layers of and greater omentum

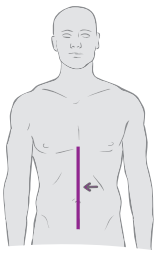

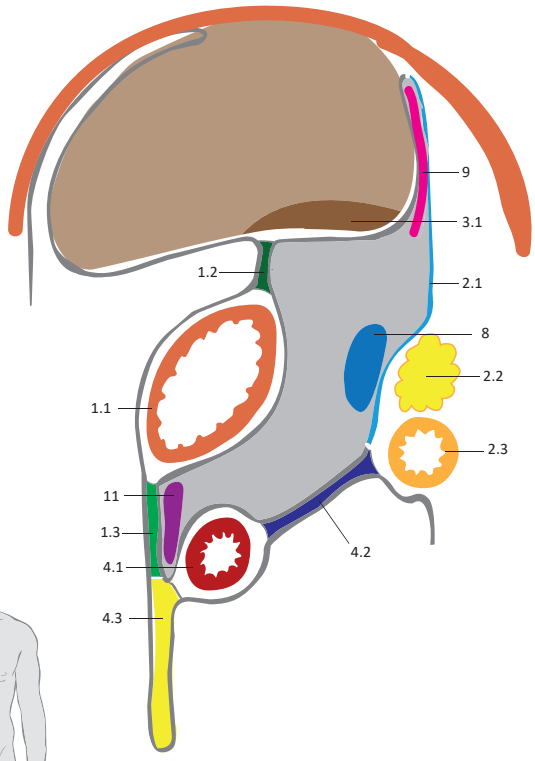

Schematic sagittal section of the peritoneal organs and omental bursa, left view

This copy belongs to ali yaghoubi

The hepatoduodenal ligament forms the right part of the lesser omentum. It extends **from the duodenum to the porta hepatis**. It **contains the hepatic artery proper, portal vein and common bile duct**. **The cystohepatic triangle (triangle of Calot)** is a space between the liver and biliary tract. It can be used to find and ligate the cystic artery when performing a cholecystectomy (the surgical removal of the gallbladder).

- 1 **Hepatoduodenal ligament** (*ligamentum hepatoduodenale*)
  - 1.1 **Hepatic artery proper** – medially
  - 1.2 **Bile duct** – laterally
  - 1.3 **Portal vein** – dorsally
- 2 **Cystohepatic triangle of Calot** (*trigonum cystohepaticum*)
  Content: cystic artery and vein
  Boundaries:
  - 2.1 **Cranially:** liver (porta hepatis, quadrate lobe)
  - 2.2 **Medially:** common hepatic duct
  - 2.3 **Laterally:** cystic duct

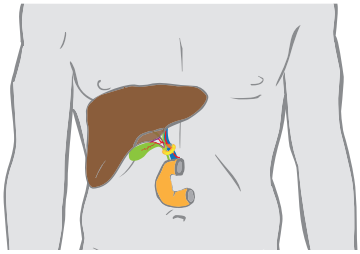

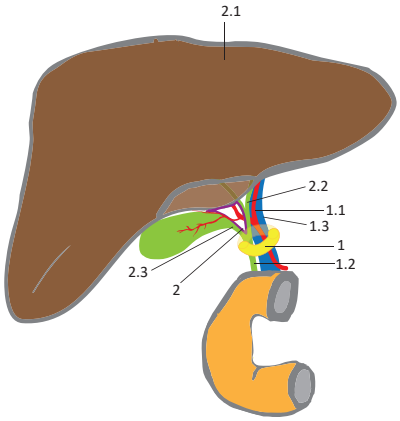

Liver, gallbladder and duodenum, anterior view

4.6.4 Paracolic spaces

The inframesocolic compartment of the peritoneal cavity is divided **by the root of the mesentery into the left and right paracolic spaces**. The right paracolic space is closed caudally but the left paracolic space is open caudally to the pelvic cavity.

- 1 **Right paracolic space**
  - 1.1 **Transverse mesocolon**
  - 1.2 **Root of mesentery**
  - 1.3 **Ascending colon**
- 2 **Left paracolic space**
  - 2.1 **Transverse mesocolon**
  - 2.2 **Root of mesentery**
  - 2.3 **Descending colon**

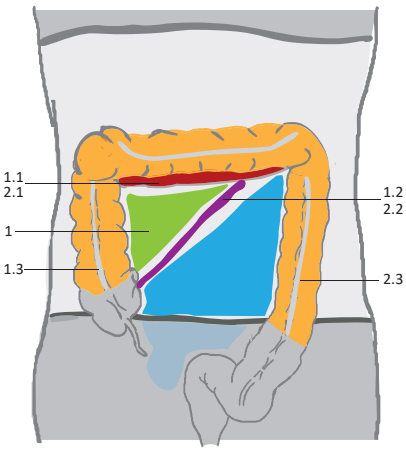

Colon and paracolis spaces, anterior view

Topography

The greater omentum is formed not by two, but by four layers of peritoneum. So it is, in fact, not a duplication but a quadruplication of peritoneum. It merges with the gastrocolic ligament. It is wide and hangs freely, full of vessels and adipose tissue and functions to enlarge the surface of the peritoneum. It hangs down in front of the intestines like an apron.

The lesser omentum and falciform ligament of the liver are remnants of the ventral mesentery (ventral mesogastrium). They are duplications of peritoneum.

Ileocecal fold ("bloodless fold of Treves") extends from the ventrocaudal aspect of the ileum to the mesoappendix.

Clinical notes

The right subhepatic recess (space of Morison) is the deepest space of the supramesocolic part of the peritoneal cavity in a patient lying down (supine position). It is necessary to remove blood and fluid that accumulates in this space during surgery.

Peritonitis is inflammation of peritoneum. It often occurs as a complication of inflammation of abdominal organs, such as appendicitis or cholecystitis.

Due to the extensive absorptive surface of the peritoneum, toxins released from bacteria in peritonitis are rapidly absorbed. This can lead to the rapid development of sepsis and septic shock.

The peritoneum is able to cordon off foci of inflammation in the peritoneal cavity by forming adhesions. Adhesions mechanically restrict the functions of the abdominal organs. They also worsen orientation in the abdominal cavity, making surgery more difficult. Adhesions are also formed after abdominal and pelvic surgeries.

The lesser sac can be surgically approach in three ways. The upper approach through the lesser omentum does not carry a risk of bleeding but provides only limited access to the lesser sac. Dissection of the gastrocolic ligament carries a risk of bleeding from the gastroomental vessels and their branches but provides a larger view of the lesser sac. The lower approach through the transverse mesocolon necessitates ligation of the middle colic vessels but provides a larger view of the lesser sac. The lesser sac is most commonly approach through the gastrocolic ligament.

The mesenteries are **duplications of peritoneum connecting parietal to visceral peritoneum**. Each intraperitoneal organ has its own **mesentery**, which holds it in its proper position and through which vessels and nerves pass to the intraperitoneal organs. **The mesenteries of the stomach are called the omenta**. **The lesser omentum** is stretched between the lesser curvature of the stomach and the visceral surface of the liver. **The greater omentum** hangs down from the greater curvature of the stomach like an apron over the transverse colon (to which it is attached) and the loops of small intestine. **Recesses** are spaces in the peritoneal cavity, which are formed by to the movements and rotations of the organs during their development.

Mesenteries and peritoneal ligaments

1 **Liver**
- 1.1 **Falciform ligament of liver**
- 1.2 **Left and right coronary ligament**
- 1.3 **Left and right triangular ligament**

2 **Stomach**
- 2.1 **Gastrophrenic ligament**
- 2.2 **Gastrosplenic ligament**
- 2.3 **Gastrocolic ligament**
- 2.4 **Hepatogastric ligament**

3 **Spleen**
- 3.1 **Phrenosplenic ligament**

4 **Oesophagus**
- 4.1 **Hepato-oesophageal ligament**

5 **Duodenum** (superior part)
- 5.1 **Hepatoduodenal ligament**

6 **Jejunum and ileum**
- 6.1 **Mesentery** (its insertion is called the root of the mesentery)

7 **Caecum**
- 7.1 **Mesocaecum** (a vascular fold of the caecum of Treves)

8 **Vermiform appendix**
- 8.1 **Meso-appendix**

9 **Transverse colon**
- 9.1 **Transverse mesocolon**

10 **Sigmoid colon**
- 10.1 **Sigmoid mesocolon**

11 **Rectum** (upper 1/3)
- 11.1 **Mesorectum**

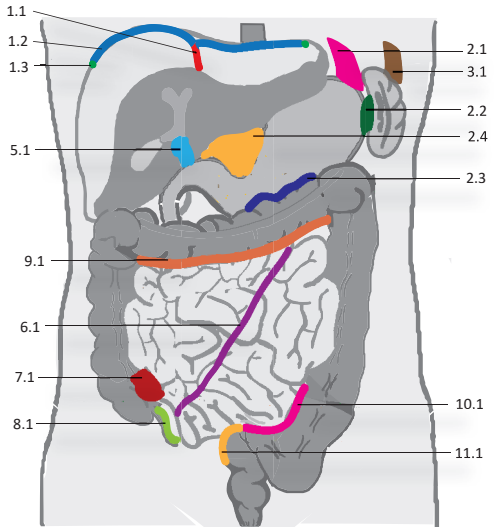

Schematic picture of the mesenteries and peritoneal ligaments

Omenta

1 **Lesser omentum** (*omentum minus*)
- 1.1 **Hepato-oesophageal ligament**
- 1.2 **Hepatogastric ligament**
- 1.3 **Hepatoduodenal ligament**

2 **Greater omentum** (*omentum majus*)

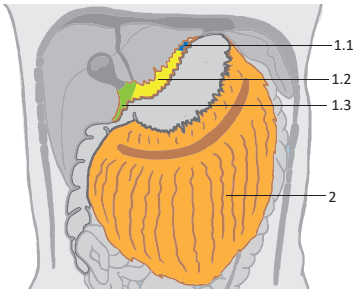

Schematic picture of the omenta

Recesses

1 **Supramesocolic part:**
- 1.1 **Left and right subphrenic spaces**
  (*recessus subphrenicus dexter et sinister*)
  – between the diaphragm and diaphragmatic surface of the liver
  – divided into the left and right part by the falciform ligament of the liver
- 1.2 **Left and right subhepatic spaces**
  (*recessus subhepaticus dexter et sinister*)
  – between the liver and posterior abdominal wall
  – divided into the left and right part by the inferior vena cava

2 **Inframesocolic part:**
- 2.1 **Superior and inferior duodenal fossa**
- 2.2 **Paraduodenal recess**
- 2.3 **Retroduodenal recess**
- 2.4 **Superior and inferior ileocaecal recess**
- 2.5 **Retrocaecal recess**
- 2.6 **Intersigmoid recess of Treitz**
- 2.7 **Paracolic gutters** (*sulci paracolici*)

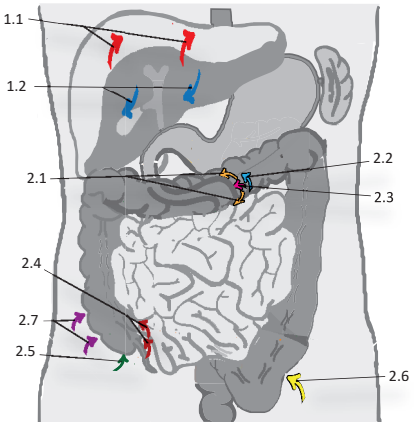

Schematic picture of the recesses

This copy belongs to ali yaghoubi

The lesser pelvis occupies the most caudal part of the abdominopelvic cavity. It is **separated from the greater pelvis by the linea terminalis**. Caudally it is closed by pelvic diaphragm. It is divided into two cavities by the peritoneum: **the peritoneal cavity of pelvis and the subperitoneal space** (located under the peritoneum).

5.1 Peritoneal cavity of the pelvis – Cavitas peritonealis pelvis

The peritoneal cavity of the pelvis is a subcomponent of the peritoneal cavity. Cranially, it **fluently continues into the abdominal peritoneum cavity**. The linea terminalis pelvis forms the borderline between the pelvic and abdominal parts of the peritoneal cavity. The subperitoneal organs are located below the pelvic peritoneum.

Organs

- 1 **Rectum** (aboral one third)
- 2 **Uterus** (cranial majority)
- 3 **Uterine tube**
- 4 **Ovary**
- 5 **Vagina** (posterior fornix)

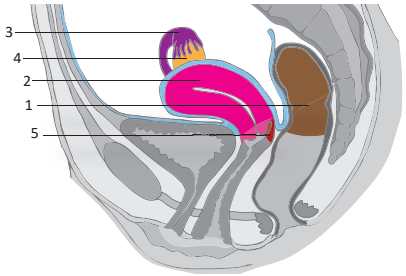

Sagittal section of the female pelvis

Spaces and structures

Common in men and women

- 1 **Paravesical fossa** (*fossa paravesicalis*)
  - – is located lateral to the urinary bladder
  - – deepens as the urinary bladder fills
- 2 **Pararectal fossa** (*fossa pararectalis*)
  - – laterally to the rectum

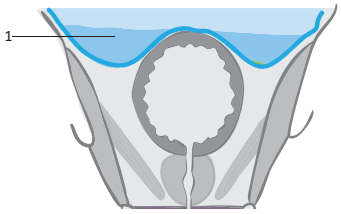

Frontal section of the male pelvis

Man:

- 3 **Rectovesical pouch of Proust** (*excavatio rectovesicalis*)
  - – a space between the rectum and urinary bladder
  - – the deepest part of the peritoneal cavity in a standing man
  - – it touches the seminal glands

Woman:

- 4 **Vesicouterine pouch** (*excavatio vesicouterina*)
  - – a space between the uterus and urinary bladder
- 5 **Rectouterine pouch of Douglas** (*excavatio rectouterina*)
  - – a space between the uterus and rectum
  - – the deepest part of the peritoneal cavity in a standing woman
  - – it touches the posterior fornix of the vagina representing access into this peritoneal space
- 6 **Broad ligament of uterus** (*ligamentum latum uteri*)
  - – a frontally positioned duplication of peritoneum separating the paravesical and pararectal fossae
- 7 **Ovarian fossa / fossa of Waldeyer** (*fossa ovarica*)
  - – a space between the external and internal iliac vessels and the ureteric fold
  - – the ovary is located in this space in nulliparous women
- 8 **Fossa of Claudius**
  - – a space between the internal iliac vessels and the sacrum, dorsal and caudal to the ovarian fossa
  - – the position of the ovary in multiparous women is very variable and may be located here

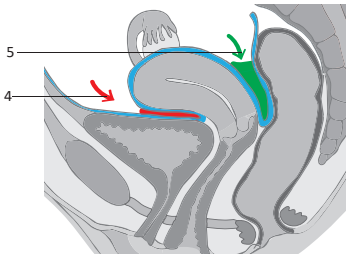

Sagittal section of the female pelvis

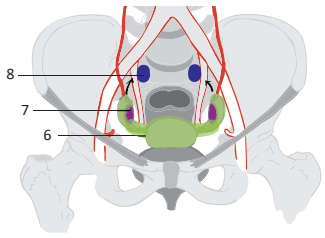

Female pelvis, anterior view

The linea terminalis is a line on the bony pelvis that topographically separates the greater and lesser pelvis. It runs from the upper edge of the symphysis, over the pecten pubis, iliopubic eminence, arcuate line and promontory and then back on the other side of the pelvis.

As the testis descends it drags part of the peritoneal cavity with it. This protrusion of the peritoneal cavity is called the vaginal process (processus vaginalis). It loses its communication, after which it is called the tunica vaginalis. The tunica vaginalis consists of two sheets: parietal lamina (periorchium), derived from parietal peritoneum, and visceral lamina (epiorchium), derived from visceral peritoneum. Orchium is a Greek term for testis.

The term Space of Proust is not commonly used in the clinical medicine. Instead, the term Pouch of Douglas is incorrectly used for both genders.

The fascia of Denonvilliers is a term for the genital plate of the visceral pelvic fascia.

Clinical notes;

Fluid (blood, peritoneal exudate, etc.) tends to collect in the rectouterine pouch, as it is the deepest part of the peritoneal cavity (in a standing woman). The rectouterine pouch can be accessed via the posterior fornix of the vagina to drain this fluid. Similarly, a peritoneal dialysis catheter can be placed here to insert and drain the dialysate.

Collection of fluid in the rectouterine/rectovesical pouch can be examined per rectum. In women, this can be aided by pressing the posterior wall of the vagina.

The rectouterine pouch can be visualised by ultrasound through the posterior wall of the vagina.

The rectoprostatic fascia is not usually noticeable. It forms during dissection or pathological processes. Inflammation in the pelvis spreads via this fascia.

We can approach the urinary bladder from the preperitoneal space without opening the peritoneal cavity.

The subperitoneal space is **bordered cranially by the peritoneum** and **caudally by the pelvic floor**. It is **continuous with the retroperitoneal space and the spaces of the lower limbs**. The walls of the pelvic cavity and the subperitoneal organs are **covered by the pelvic fascia**. The parietal and visceral layers of the pelvic fascia merge into each other at the tendinous arch of the pelvic fascia.

Organs

- 1 **Urinary bladder**
- 2 **Ureter** (pelvic part)
- 3 **Ductus deferens**
- 4 **Prostate**
- 5 **Vagina**
- 6 **Rectum** (aboral two thirds)

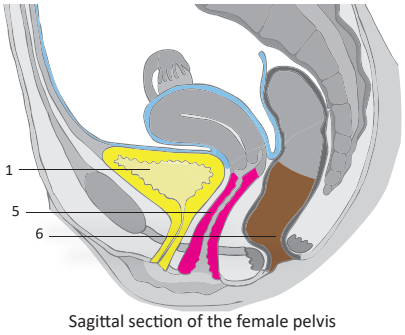

Sagittal section of the female pelvis

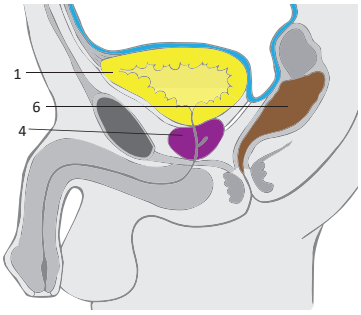

Sagittal section of the male pelvis

Spaces and structures

Pelvic fascia (*fascia pelvis*)
– has three main parts which converge in the tendinous arch of the pelvic fascia (*arcus tendineus fasciae pelvis*) situated caudally, close to the pelvic floor

- 1 **Parietal pelvic fascia** (*fascia pelvis parietalis*) – covers the pelvic cavity walls
- 2 **Investing pelvic fascia** (*fascia pelvis investiens*) – covers the subperitoneal organs
- 3 **Visceral pelvic fascia** (*fascia pelvis visceralis*) – fan-shaped and spread out between the parietal and investing pelvic fasciae
  – the visceral branches of the internal iliac artery accompanied by veins pass through it
  – it has three plates (sheets)
  - 3.1 **Vesical (anterior) plate** (*lamina vesicalis*)
    – covers the urinary bladder
    – runs over the urinary bladder into a space called the preperitoneum (in front of the peritoneum)
    – forms the vesicoumbilical fascia of Delbet situated between the medial umbilical ligaments (cords remaining after the umbilical arteries)
    – ventrally, in the direction of the pubic symphysis, there is the retropubic space of Retzius which contains the pudendal plexus of Santorini
  - 3.2 **Genital (middle) plate** (*lamina genitalis*)
    – covers the uterus, prostate and seminal vesicles
    – divides the subperitoneal space into the anterior paravesical area and posterior pararectal area
    – its posterior part is thick (fibrous genital plate)
    – in the sagittal plane it forms the rectovesical septum in men and the rectovaginal septum in women
    – in women, it contains the uterine artery
    – in men the retroprostatic fascia
    – in women the rectovaginal fascia
  - 3.3 **Rectal (posterior) plate / perirectal fascia** (*lamina rectalis*)
    – covers the rectum
    – it is separated from the sacrum by the presacralis fascia of Waldeyer
    – transmits the sacral splanchnic nerves

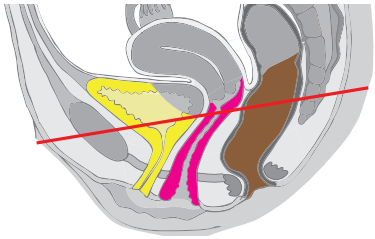
Level of the transverse section

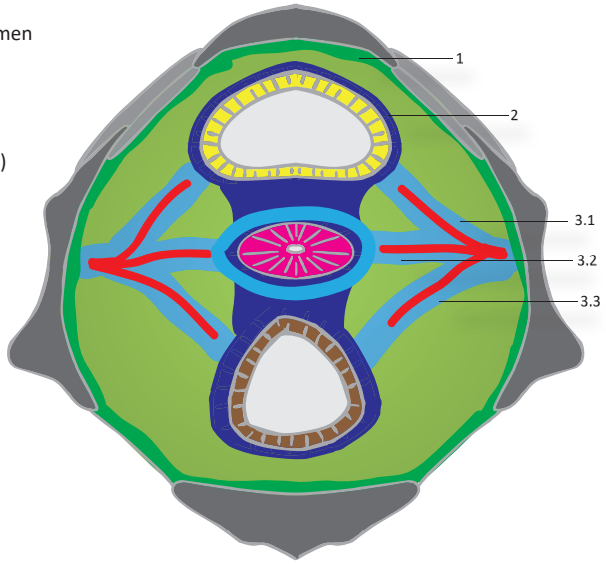

Transverse section of the female pelvis

This copy belongs to ali yaghoubi

The perineal region is located **caudally to the pelvic floor**. It contains the **external genitals and perineal muscles** and is composed of **urogenital triangle and anal triangle**.

Divisions

- 1 **Urogenital triangle** (*trigonum urogenitale*)
  – situated ventrally
  - 1.1 **Ventrally:** pubic symphysis
  - 1.2 **Dorsally:** a line connecting the left and right ischial tuberosities
  - 1.3 **Laterally:** ischiopubic ramus
  - 1.4 **Floor** (cranially)**:** perineal membrane
- 2 **Anal triangle** (*trigonum anale*)
  – situated dorsally
  - 2.1 **Ventrally:** a line connecting the left and right ischial tuberosities
  - 2.2 **Dorsally:** coccyx
  - 2.3 **Laterally:** sacrotuberous ligament and gluteus maximus

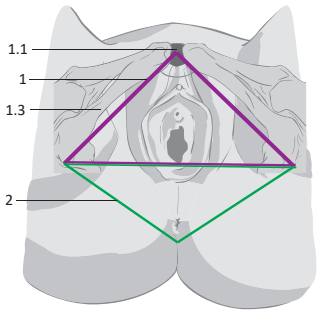

Female perineal region
inferior view

5.4 Urogenital triangle – Trigonum urogenitale

The urogenital triangle contains the deep transverse perineal muscle and the perineal body.

Content

Man:
- 1 **Paired crus of penis and paired ischiocavernosus**
- 2 **Unpaired bulb of penis and unpaired bulbospongiosus**
- 3 **Paired bulbo-urethral glands of Cowper**

Woman:
- 1 **Paired crus of clitoris and paired ischiocavernosus**
- 2 **Paired bulb of vestibule and paired bulbospongiosus**
- 3 **Paired greater vestibular glands of Bartholin and lesser vestibular glands**

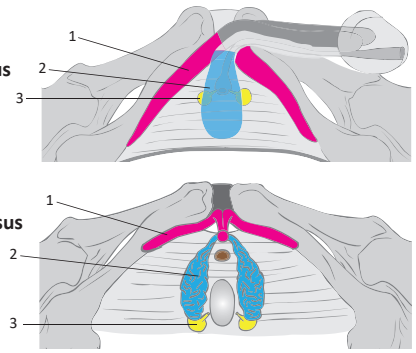

Male and female urogenitale triangle,
inferior view

Structures

1 **Urogenital diaphragm** (*diaphragma urogenitale*)
– encloses the hiatus urogenitalis of the pelvic floor
– it consists of the perineal muscles and their fascias, deep transverse perineal muscles blends with the perineal membrane

2 **Superficial perineal fascia of Colles** (*fascia perinei superficialis*)
– a membranous layer of the subcutaneous layer (*stratum membranosum telae subcutaneae*)
– it is formed by dense subcutaneous fibrous tissue representing a continuation of the subcutaneous abdominal fascia of Scarpa
– across the area as dorsal as the line formed by the superficial transverse perineal muscle

3 **Deep perineal space** (*saccus profundus perinei / spatium profundum perinei*)
– a space between the superficial perineal fascia and urogenital floor (perineal membrane)
– contains the crus penis and bulbus penis in men
– contains the crus clitoridis and bulbus vestibuli in women
– contains the ischiocavernosus and bulbospongiosus in both genders
– contains the glandula bulbourethralis and terminal branches of the internal pudendal vessels and pudendal nerve

4 **Between the pelvic floor and urogenital diaphragm**
– the pubic recess of the ischio-anal fossa (*recessus pubicus fossae ischioanalis*) projects ventrally from the ischio-anal fossa towards the pubic symphysis
– in its lateral wall is the pudendal canal of Alcock (*canalis pudendalis*)
– the space on the one side does not communicate with the space on the other side (it is a cul-de-sac)

Topography

Fascia of Colles is the continuation of fascia of Scarpa over the urogenital diaphragm. It continues in the scrotum as dartos fascia. It is delimited dorsally by the superficial transverse perineal muscle and does not cover the anal triangle.

The perineum is ventrally demarcated by the posterior side extenral genital organs (scrotum/posterior commissure of the labia majora) and dorsally by the ventral side of the anus. The perineum and perineal muscles are on page 256.

The subcutaneous perineal pouch (*saccus subcutaneus perinei*) is a space filled with adipose tissue in the subcutaneous layer of the perineum. It is bordered by the fascia of Colles superficially (caudally) and the perineal fascia of Gallaudet in the depth (cranially).

The urogenital diaphragm is an obsolete term for a fibro-muscular plate formed by the perineal membrane, the superficial and deep transverse perineal muscles, the ischiocavernosus and the bulbospongiosus. Recent anatomical nomenclature does not use this term anymore. However, this term is widely used in clinical practice and therefore is used in this text.

Clinical notes

Blood and fluid from the abdominal wall can spread under fascia of Scarpa into the perineum and scrotum. The fluid will not spread further than the superficial transverse perineal muscle, as the (deep) perineal fascia (of Gallaudet) is firmly attached to it. Surgical drains are often placed in the perineum.

An episiotomy is a cut through the perineum. It is performed to prevent tearing of the perineum, a complication of childbirth that may damage the external anal sphincter causing incontinence.

Perianal inflammation may spread into the ischio-anal fossa. It can sometimes penetrate the skin around the anus and form anal fistulas.

A pudendal block is method of local anaesthesia to block the pudendal nerve. The anaesthetic is injected into the pudendal canal either through the skin (at the midpoint on a line between the anus and ischial tuberosity) or through vaginal wall and sacrospinous ligament. It is performed during deliveries and urological surgeries.

The ischio-anal fossa is a **paired space filled by adipose tissue surrounding the anus**. The **two fossae communicate with each other dorsally behind the anus**. Ventrally there is a blind anterior recess (pubic recess) that extends as far as the posterior surface of the pubis. The ischioanal fossae form a space that **allows the pelvic floor to span out during defecation and parturition**.

Boundaries

Medio-cranially:
- 1 **External anal sphincter**
- 2 **Inferior fascia of the pelvic diaphragm**

Laterally:
- 3 **Ischial tuberosity**
- 4 **Obturator fascia**

Dorsally:
- 5 **Inferior margin of the gluteus maximus**
- 6 **Sacrotuberous ligament**

Caudally:
- 7 **Passes into the anal triangle**

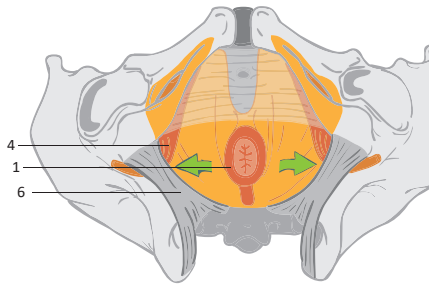

Arrows pointing to the right and left ischioanal fossa

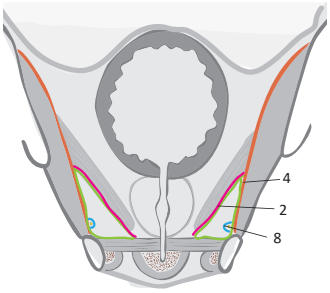

Frontal section of the male pelvis at the level of the prostatic part of the urethra

Content

- 8 **Pudendal canal of Alcock** (*canalis pudendalis*)
- 9 **Fat body of ischioanal fossa** (*corpus adiposum fossae ischioanalis*)

5.6 Pudendal canal – Canalis pudendalis

The pudendal canal of Alcock is located on the **lateral wall of the ischioanal fossa**. It is formed by the fascia of the obturator internus and **contains a neurovascular bundle** that supplies the external genital organs, caudal parts of the rectum and the vagina.

Boundaries

- 1 **Laterally:** obturator internus
- 2 **From other sides:** duplication of the obturator internus fascia

Content

- 3 **Internal pudendal artery and veins**
- 4 **Pudendal nerve** – running medially

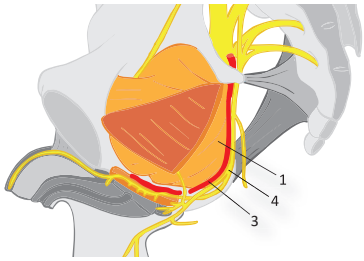

Right half of male pelvis, viewed from the left

5.7 Layers of the scrotum

The scrotum is a protrusion of the abdominal wall that contains the paired testis, epididymidis and a part of the ductus deferens. The structure of the wall of the scrotum is similar to the abdominal wall, from which it is derived.

Layers of the scrotum and the corresponding layers of the abdominal wall

- 1 **Skin**
- 2 **Dartos fascia** – subcutaneous abdominal fascia of Scarpa
- 3 **External spermatic fascia** – superficial abdominal fascia
- 4 **Cremaster and cremasteric fascia** – internal oblique and transversus abdominis
- 5 **Internal spermatic fascia** – tranversalis fascia
- 6 **Parietal layer of tunica vaginalis** (*periorchium*) – parietal peritoneum
- 7 **Visceral layer of tunica vaginalis** (*epiorchium*) – visceral peritoneum

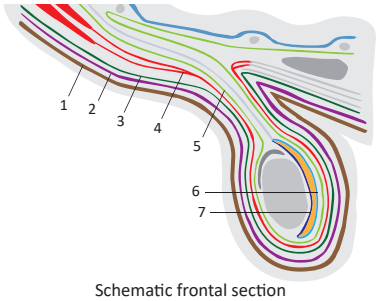

Schematic frontal section of the inguinal canal and scrotum

This copy belongs to ali yaghoubi

The back contains large groups of muscles, such as the girdle muscles and the postural muscles. Several **topographical spaces are located within these groups of muscles**. The **vertebral canal** is located deeply in the back, inside the vertebral column and contains the spinal cord and its vessels and meninges.

6.1 Vertebral canal – Canalis vertebralis

The vertebral canal is a space created by the vertebral foramina of the vertebral column. It is an isolated part of the human body that **encloses the spinal cord, its vessels and meninges** and mechanically protects it from trauma.

Communications

1 **Foramen magnum** – the transition between the vertebral canal and the cranial cavity
2 **Intervertebral foramina** – for the spinal nerves (cervical, thoracic, lumbar nerves), spinal branches of adjacent arteries and intervertebral veins
3 **Anterior and posterior sacral foramina** – the anterior and posterior branches of the sacral nerves
4 **Sacral hiatus** – for the fifth sacral and coccygeal nerve

Boundaries

- 1 **Ventrally:** posterior longitudinal ligament
- 2 **Dorsally:** vertebral arches and ligamenta flava
- 3 **Laterally:** vertebral pedicles

Content

- 4 **Spinal cord**
- 5 **Rootlets**
  - 5.1 **Anterior root of spinal nerve**
  - 5.2 **Posterior root of spinal nerve**
- 6 **Spinal dura mater**
- 7 **Spinal arachnoid mater**
- 8 **Spinal pia mater**
- 9 **Denticulate ligament**
- 10 **Anterior spinal artery** (unpaired artery) and **posterior spinal arteries** (one or two arteries)
- 11 **Anterior and posterior internal vertebral venous plexus**
- 12 **Anterior and posterior spinal veins**

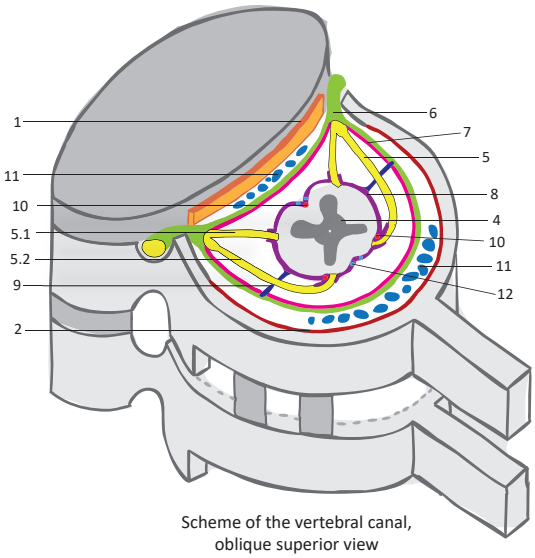

Scheme of the vertebral canal, oblique superior view

Topography

The spinal canal is a synonym for the vertebral canal.

The lumbar tetragon of Krause (*tetragonum lumbale*) can be found when the twelfth rib is a part of the superior lumbar triangle borderlines.

The extent of the lumbar triangles strongly depends on the muscle development.

Clinical notes

A suboccipital puncture is occasionally performed instead of a lumbar puncture. The needle must be carefully led along the nuchal ligament so as not to harm the vertebral artery.

Lumbar herniae are a rare form of hernia. They occur through the lumbar triangles, usually after a trauma.

The intervertebral disc can herniate dorsally or laterally. Dorsal herniation of the intervertebral disc may compress the spinal cord or the cauda equina. Lateral intervertebral disc herniation can cause compression of the spinal nerve rootlets.

The suboccipital triangle is a topographical space **created by the suboccipital muscles**. **The suboccipital nerve is located in this triangle** and innervates the suboccipital muscles. The greater occipital nerve is a cutaneous nerve that passes over the suboccipital triangle superficially. The vertebral artery lies deep within the suboccipital triangle where it passes over the posterior arch of the atlas before traversing the foramen magnum to enter the cranial cavity.

Boundaries

- 1 **Medially:** rectus capitis posterior major
- 2 **Laterally:** obliquus capitis superior
- 3 **Caudally:** obliquus capitis inferior
- 4 **Bottom:** posterior atlanto-occipital membrane and posterior arch of the atlas

Content

- 5 **Vertebral artery (atlantic part)**
- 6 **Suboccipital nerve**
- 7 **Greater occipital nerve**

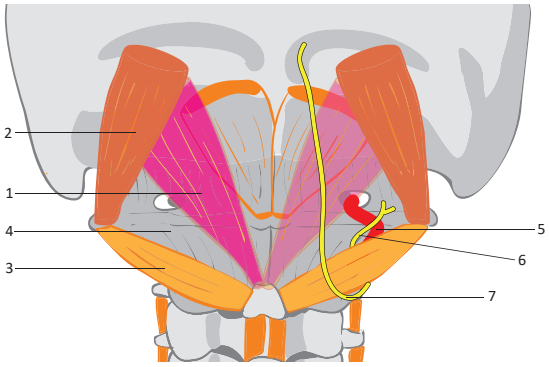

Suboccipital triangle and muscles, posterior view

6.3 Superior and inferior lumbar triangles – Trigonum lumbale superius et inferius

The superior and inferior lumbar triangles are the spaces bound by the back muscles. These areas **represent weak parts of the lumbar body wall**.

- 1 **Superior lumbar triangle of Grynfeltt and Lesshaft** (*trigonum lumbale superius*)
  Boundaries:
  - 1.1 **Cranially:** serratus posterior inferior
  - 1.2 **Medially:** iliocostalis lumborum
  - 1.3 **Laterally:** internal oblique
  - 1.4 **Floor:** transversus abdominis
  - 1.5 **Roof:** latissimus dorsi

  Deep content:
  - 1.6 **Subcostal nerve**
  - 1.7 **Subcostal artery and vein**
  - 1.8 **Iliohypogastric nerve**

- 2 **Inferior lumbar triangle of Petit** (*trigonum lumbale inferius*)
  Boundaries:
  - 2.1 **Caudally:** iliac crest (about 2–3 cm)
  - 2.2 **Medially:** latissimus dorsi
  - 2.3 **Laterally:** external oblique
  - 2.4 **Bottom:** internal oblique

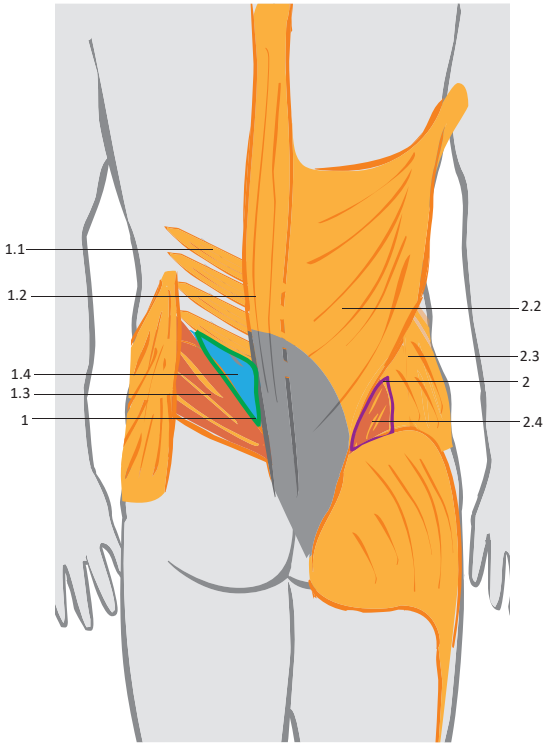

Male back, posterior view

This copy belongs to ali yaghoubi

The upper extremity contains a series of interconnected topographical spaces, through which vessels and nerves travel from the shoulder to the hand. Vessels and nerves usually travel together as **neurovascular bundles**. The topographical spaces are filled with loose connective tissue, which allows the spread of infection.

7.1 Topography of the shoulder – Regio deltoidea

After passing through the scalene fissure, the subclavian artery and brachial plexus enter the axilla. The subclavian artery becomes the axillary artery as it enters the axilla. It gives off branches, which travel to the surrounding topographical regions.

7.1.1 Suprascapular and spinoglenoid notches – Incisura scapulae et spinoglenoidalis

The suprascapular notch is located on the superior margin of the scapula. It is bridged by the superior transverse scapular ligament. **The suprascapular nerve** passes under this ligament and the **suprascapular artery and vein** typically pass above it. **The spinoglenoid notch** is located between the spine of the scapula and the neck of the scapula. It is covered by the inferior transverse scapular ligament. **The suprascapular nerve, artery and vein** pass through it.

1 **Suprascapular notch**
Boundaries:
- 1.1 **Cranially:** superior transverse scapular ligament

Content:
- 1.2 **Suprascapular nerve**

2 **Spinoglenoid notch**
Boundaries:
- 2.1 **Laterally:** rim of the glenoid cavity
- 2.2 **Medially:** spine of scapula
- 2.3 **Dorsally:** inferior transverse scapular ligament

Content:
- 2.4 **Suprascapular nerve**
- 2.5 **Suprascapular artery and vein**

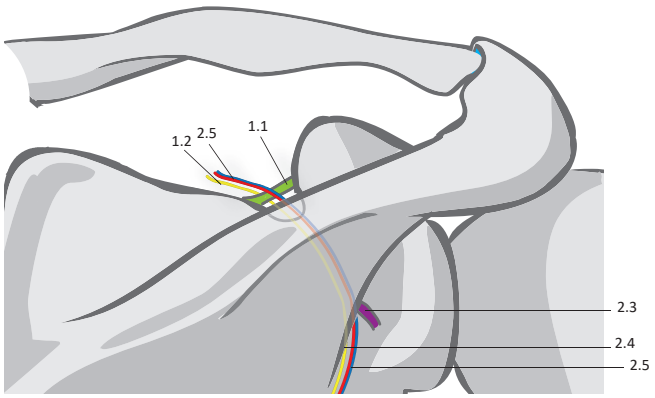

Right pectoral girdle, posterior view

Topography

The axillary suspensory ligament is the lateral part of the clavipectoral fascia. It is attached to the skin of the axilla.

The shoulder is a collective term for the glenohumeral, acromioclavicular and sternoclavicular joints. It represents a functional connection between the scapula and thorax. Movements of the shoulder require simultaneous movements of all these joints.

Langer's axillary arch (axillopectoralis muscle) is a variably present band of muscle fibres that originate from the lateral part of latissimus dorsi and insert into either the pectoralis major tendon or on the coracoid process. It passes below the vessels and nerves of the axilla, which it may compress causing neurological symptoms.

Clinical notes

The superior transverse scapular ligament may ossify (and turn the notch into the scapular foramen) and compress the suprascapular nerve. This may lead to weakening and atrophy of the innervated muscles.

Supraclavicular block is a method of local anaesthesia that blocks the trunks of the brachial plexus. Local anaesthetic is injected above the clavicle into the brachial plexus under ultrasound guidance. If performed correctly it allows complete anaesthesia of the brachial plexus.

An axillary block is an anaesthetic procedure to block the terminal branches of the brachial plexus. The musculocutaneous nerve separates proximally from the brachial plexus and thus is commonly missed by this technique.

Axillary lymph node dissection is a surgical procedure to remove the axillary lymph nodes. These nodes are typically affected by metastasis of a breast carcinoma. In severe cases, the pectoralis minor has to be removed. The cutaneous nerves of the arm and forearm and intercostobrachial nerve are in close proximity to the axillary lymph nodes are often damaged during this procedure. This results in hypesthesia or complete anaesthesia of the areas that they innervate.

The axilla has the shape of a quadrilateral pyramid with the shoulder joint at its apex. It contains **lymph nodes**, the **axillary vessels** and the **brachial plexus**.

Boundaries

Proximally:
1 **Glenohumeral joint**

Ventrally:
- 2 **Pectoralis major**
- 3 **Pectoralis minor**

Dorsally:
- 4 **Scapula and subscapularis**
- 5 **Latissimus dorsi and teres major**

Medially:
- 6 **Thoracic wall** and serratus anterior

Laterally:
- 7 **Humerus** and the following muscles:
  – coracobrachial
  – biceps brachii
  – long head of triceps brachii

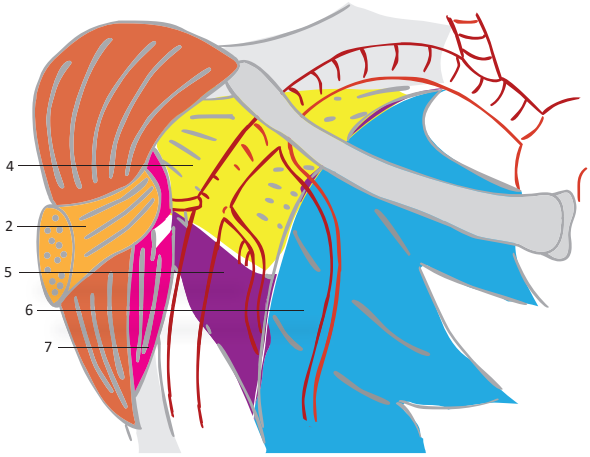

Right axilla, anterior view (pectoralis minor cut)

Content

- 1 **Axillary artery** and its branches
  - 1.1 **Superior thoracic artery**
  - 1.2 **Thoraco-acromial artery**
  - 1.3 **Lateral thoracic artery**
  - 1.4 **Subscapular artery**
    - 1.4.1 **Circumflex scapular artery**
    - 1.4.2 **Thoracodorsal artery**
  - 1.5 **Subscapular branches**
  - 1.6 **Anterior circumflex humeral artery**
  - 1.7 **Posterior circumflex humeral artery**
- 2 **Axillary vein** and tributary veins
  – deep veins correspond in terminology and course with arteries
  - 2.1 **Cephalic vein**
  - 2.2 **Thoraco-epigastric veins**
- 3 **Brachial plexus** – the infraclavicular part
  - 3.1 **Lateral fascicle**
    - 3.1.1 **Musculocutaneous nerve**
    - 3.1.2 **Median nerve** (lateral root)
  - 3.2 **Medial fascicle**
    - 3.2.1 **Ulnar nerve**
    - 3.2.2 **Median nerve** (medial root)
    - 3.2.3 **Medial cutaneous nerve of arm**
    - 3.2.4 **Medial cutaneous nerve of forearm**
  - 3.3 **Posterior fascicle**
    - 3.3.1 **Axillary nerve**
    - 3.3.2 **Radial nerve**
- 4 **Brachial plexus** – the supraclavicular part
  - 4.1 **Thoracodorsal nerve**
  - 4.2 **Long thoracic nerve**
  - 4.3 **Medial and lateral pectoral nerves**
- 5 **Intercostobrachial nerves**
- 6 **Axillary lymph nodes**

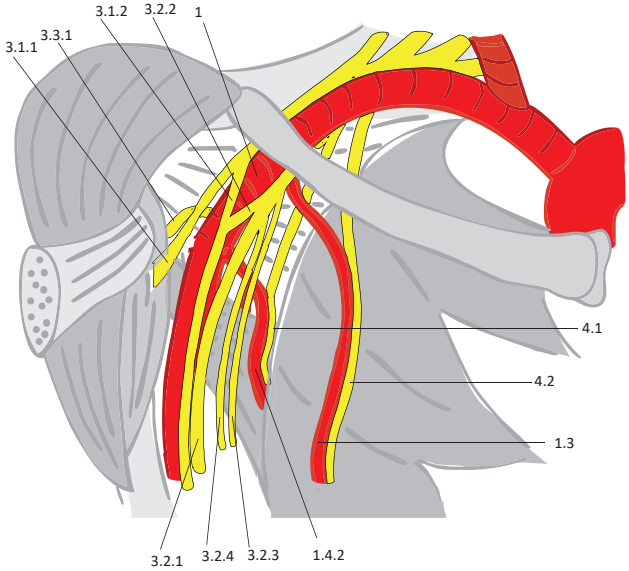

This copy belongs to ali yaghoubi

The triangular and quadrangular spaces open into the posterior aspect of the axilla. **The triangular space** is located medial to the long head of the triceps brachii and contains the circumflex scapular vessels. **The quadrangular space** is located lateral to the long head of the triceps brachii and contains the posterior circumflex humeral vessels and axillary nerve.

- 1 **Triangular space** (*foramen omotricipitale*)
  Boundaries:
  - 1.1 **Cranially:** teres minor
  - 1.2 **Caudally:** teres major
  - 1.3 **Laterally:** long head of the triceps brachii

  Content:
  - 1.4 **Circumflex scapular artery**
  - 1.5 **Circumflex scapular veins**

- 2 **Quadrangular space** (*foramen humerotricipitale*)
  Boundaries:
  - 2.1 **Cranially**: teres minor
  - 2.2 **Caudally:** teres major
  - 2.3 **Medially:** long head of the triceps brachii
  - 2.4 **Laterally:** humerus (surgical neck)

  Content:
  - 2.5 **Axillary nerve**
  - 2.6 **Posterior circumflex humeral artery**
  - 2.7 **Posterior circumflex humeral veins**

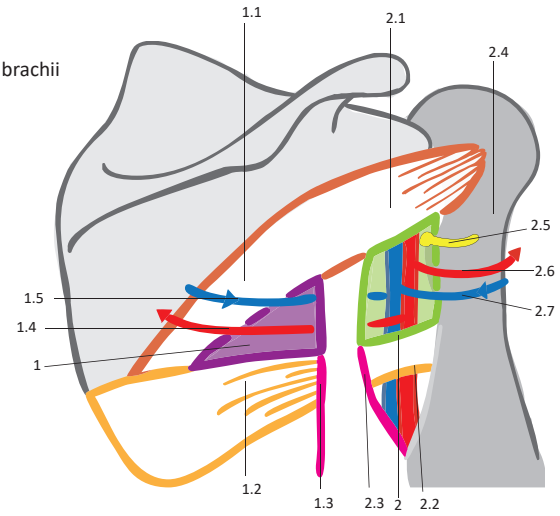

Schematic enlarged triangular and quadrangular space, posterior view

7.1.4 **Clavipectoral triangle** – Trigonum clavipectorale/deltopectorale

The clavipectoral triangle opens into the ventral aspect of the axilla. It is bordered by the caudal margin of the clavicle, the medial margin of the deltoid and the lateral margin of pectoralis major. It continues distally as the deltopectoral groove. Superficially, on the skin, it forms the **infraclavicular oval fossa** (of Mohrenheim).

Boundaries

- 1 **Proximally:** clavicle
- 2 **Medially:** pectoralis major
- 3 **Laterally:** deltoideus

Content

- 4 **Cephalic vein**
- 5 **Branches of the thoraco-acromial artery**
- 6 **Pectoral nerves**

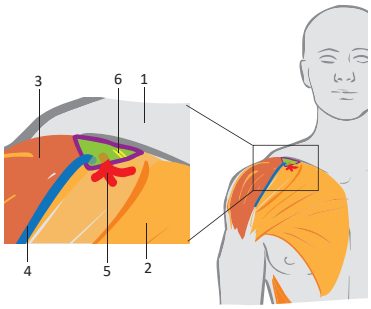

Topography

The brachial artery can be palpated just above the cubital fossa medial to the biceps brachii tendon. The same spot is used for auscultation when taking blood pressure.

The cephalic vein isn't usually located in the lateral brachial groove. It is more often located medial to it on the ventral side of the arm.

The arcade of Struthers is a variably present fibrous band passing through the medial intermuscular septum and crossing the ulnar nerve. It is present in 70% of cases and may, but only rarely, compress the ulnar nerve.

The borders of the omotricipitale and humerotricipitale triangles are formed by three muscles each beginning with the letter T:
– musculus Triceps brachii
– musculus Teres major
– musculus Teres minor

Clinical notes

The axillary nerve can be injured by a fracture of the surgical neck of the humerus.

The radial nerve can be injured by a fracture of the shaft of the humerus. The radial nerve may also be harmed during reduction and internal fixation of such fractures.

The arm is divided by the medial and lateral intermuscular septa into two osteofascial compartments: **the anterior and posterior compartments of the arm**. The medial and lateral bicipital grooves are located above the junctions of the medial and lateral intermuscular septa with the brachial fascia. Superficial veins run in both grooves and distally are joined by the cutaneous nerves of the forearm.

Parts

- 1 **Anterior compartment of arm**
  (*compartimentum brachii anterius*)
  – the anterior group of the arm muscles
- 2 **Posterior compartment of arm**
  (*compartimentum brachii posterius*)
  – the posterior group of the arm muscles
- 3 **Medial intermuscular septum of arm**
  – structures passing anteriorly:
  - 3.1 **Brachial vein and artery**
  - 3.2 **Musculocutaneous nerve**
  - 3.3 **Median nerve**
  - 3.4 **Ulnar nerve** (only in the proximal half of the arm)
- 4 **Medial bicipital groove**
  – contains:
  - 4.1 **Basilic vein**
  - 4.2 **Medial cutaneous nerve of forearm**
- 5 **Lateral bicipital groove**
  – passing superficially and ventrall to it:
  - 5.1 **Cephalic vein**

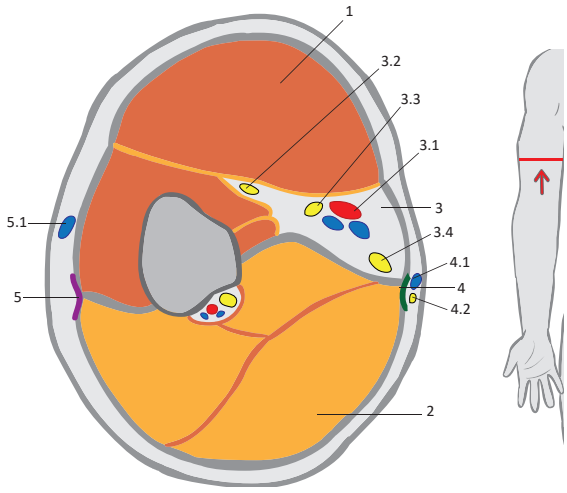

Transverse section of the right arm, distal view

7.2.1 **Radial canal** – Canalis nervi radialis

The radial canal is a space located on the posterior surface of the humerus bordered by the radial groove on the humerus and the medial and lateral heads of the triceps brachii. It contains the radial nerve and the deep brachial vessels.

Boundaries

- 1 **Floor:** radial groove
- 2 **Proximally and laterally:** lateral head of triceps brachii
- 3 **Distally and medially:** medial head of triceps brachii

Content

- 4 **Radial nerve**
- 5 **Profunda brachii artery**
- 6 **Deep veins of arm**

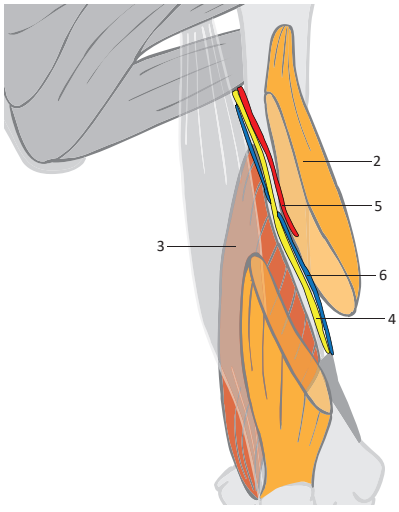

Anterior view of the right arm
(lateral head of the triceps brachii cut)

This copy belongs to ali yaghoubi

The neurovascular structures, which were in close proximity to each other in the arm, diverge from each other at the elbow. The ulnar nerve passes to the posterior compartment of the arm by piercing the medial intermuscular septum. It then travels through the ulnar groove and cubital canal. **The median nerve** remains anterior to the medial intermuscular septum. It enters the cubital fossa with the brachial artery. **The radial nerve** pierces the lateral intermuscular septum to travel in the anterior compartment of the arm. It enters the cubital fossa by passing between the brachialis and brachioradialis.

7.3.1 Cubital fossa – Fossa cubitalis

The cubital fossa is a bordered by the insertions of the upper arm muscles and the origins of the forearm muscles. It contains a network of superficial veins, branches of the brachial artery and the median and radial nerves. **The radial nerve** enters the cubital fossa between the brachialis and brachioradialis and divides into the deep and superficial branches of the radial nerve. **The superficial branch** travels with the radial artery. **The deep branch** travels through the **supinator canal** to reach the dorsal part of the forearm. **The median nerve** runs distally through the **pronator canal** and then between the flexor digitorum superficialis and flexor digitorum profundus in the anterior compartment of the forearm. It then passes through the carpal tunnel to reach the hand.

Boundaries

- 1 **Cubital fossa**
- 2 **Proximally:** biceps brachii
  – distal end of the muscle belly
- 3 **Laterally:** brachioradialis
- 4 **Medially:** pronator teres
- 5 **Bottom:** brachialis

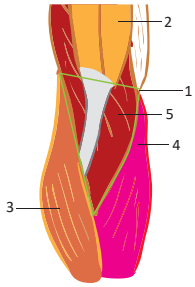

Superficial content

- 1 **Cephalic vein**
- 2 **Basilic vein**
- 3 **Median cubital vein**
- 4 **Median antebrachial vein**
- 5 **Perforator cubital vein**
- 6 **Medial cutaneous nerve of forearm**
- 7 **Lateral cutaneous nerve of forearm**
- 8 **Superficial cubital lymph nodes**

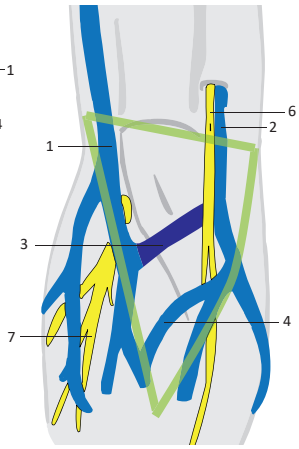

Right cubital fossa, anterior view

Deep content

- 1 **Brachial artery** and its terminal branches
  - 1.1 **Radial artery**
  - 1.2 **Ulnar artery**
- 2 **Brachial** veins and their tributaries
  - 2.1 **Radial veins**
  - 2.2 **Ulnar veins**
  - 2.3 Perforator cubital vein
- 3 **Median nerve**
- 4 **Radial nerve** and its branches
  - 4.1 **Superficial branch**
  - 4.2 **Deep branch**
- 5 **Deep cubital lymph nodes**

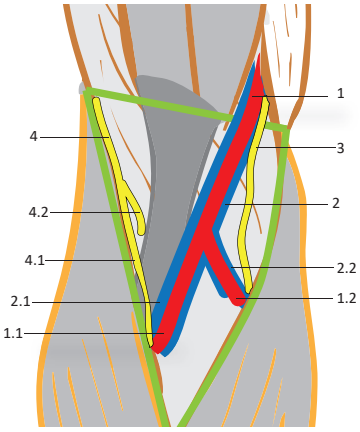

Right cubital fossa, anterior view

Topography

The elbow is a collective term for the elbow joint, its surrounding muscles and soft tissue.

A mnemonic for the structures passing laterally to the medial epicondyle of the humerus:
MAT (mediolaterally)
1. **M**edian nerve
2. brachial **A**rtery
3. biceps brachii **T**endon

The bellies of the flexors and extensors of the fingers are located in the forearm. This allows the hand to generate great strength.

Distally in the arm, the ulnar nerve is joined by the superior collateral artery and vein.

The neurovascular bundle of the posterior interosseous nerve and vessels is responsible for supplying the whole posterior compartment of the forearm.

Struthers' ligament originates from a variable bony prominence called the supracondylar process and attaches to the medial epicondyle of the humerus. It is present in only 1.5% of cases. The median nerve and brachial vessels may run under this structure and be compressed by it.

The arcade of Frohse is a thickened fibrous band at the proximal part of the supinator canal. It lines the superficial layer of the supinator muscle and may compress the deep branch of the radial nerve.

Clinical notes

Nerve entrapment syndromes are caused by excessive pressure on peripheral nerves. Nerves are especially liable to compression in tight spaces, such as in the carpal tunnel and pronator, supinator and cubital canals.

The superficial veins in the cubital region are used for venepuncture. Venepuncture is the process of acquiring intravenous access, which is necessary for taking venous blood samples and administering intravenous medication.

Volkmann's contracture is a pathological permanent contraction of the flexors of the hand, caused by ischaemia. This may lead to entrapment syndromes of the ulnar, median and radial nerves in their respective canals.

The pronator canal is a space bounded proximally by the two heads of the pronator teres and distally by the heads of the flexor digitorum superficialis. **The median nerve passes through this space** as it travels from the cubital fossa to reach the anterior compartment of the forearm, where it lies between the flexor digitorum superficialis and the flexor digitorum profundus. **The cubital canal** is the space between the two heads of the flexor carpi ulnaris. **It contains the ulnar neve. The supinator canal** is the space between two layers of the supinator muscle. **The deep branch of the radial nerve** goes through this canal to reach the posterior compartment of the forearm. The entrance is usually formed by the arcade of Frohse, which may cause an entrapment syndrome of the deep branch of the radial nerve.

- 1 **Pronator canal** (*canalis pronatorius*)
  Boundaries:
  - 1.1 **Pronator teres** – humeral head
  - 1.2 **Flexor digitorum superficialis** – radial head
  - 1.3 **Pronator teres** – ulnar head
  - 1.4 **Flexor digitorum superficialis** – humero-ulnar head

  Content:
  - 1.5 **Median nerve**
- 2 **Cubital canal** (*canalis cubitalis*)
  Boundaries:
  - 2.1 **Flexor carpi ulnaris** – humeral head
  - 2.2 **Flexor carpi ulnaris** – ulnar head

  Content:
  - 2.3 **Ulnar nerve**
- 3 **Supinator canal** (*canalis supinatorius*)
  Boundaries:
  - 3.1 **Superficial part of supinator**
  - 3.2 **Deep part of supinator**

  Content:
  - 3.3 **Deep branch of radial nerve**

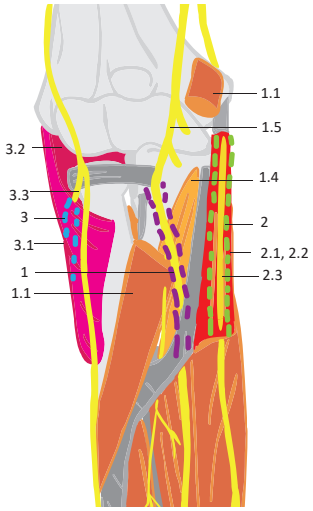

Anterior view of the proximal right forearm

7.4 Topography of the forearm – Regio antebrachialis

The forearm is divided by the **antebrachial fascia** and **interosseous membrane** into **three osteofascial compartments**. The anterior compartment communicates with the midpalmar space via the carpal tunnel.

- 1 **Anterior compartment of forearm**
  (*compartimentum antebrachii anterius*)
  – the anterior group of forearm muscles (flexors), divided into four layers
  - 1.1 **Ulnar nerve, artery and veins**
    – a neurovascular bundle located between the flexor carpi ulnaris and the flexor digitorum superficialis and profundus
  - 1.2 **Median nerve**
    – lies between the flexor digitorum profundus and the flexor digitorum superficialis
  - 1.3 **Anterior interosseous nerve, artery and vein**
    – a neurovascular bundle located ventral to the interosseous membrane
- 2 **Posterior compartment of forearm**
  (*compartimentum antebrachii posterius*)
  – the posterior group of forearm muscles, divided into two layers
  - 2.1 **Posterior interosseous nerve, artery and veins**
    – neurovascular bundle dorsal to the interosseous membrane
- 3 **Lateral compartment of forearm**
  (*compartimentum antebrachii laterale*)
  – the lateral group of forearm muscles, divided into two layers
  - 3.1 **Superficial branch of radial nerve, radial artery and veins**
    – a neurovascular bundle located under the brachioradialis in the middle third of the forearm

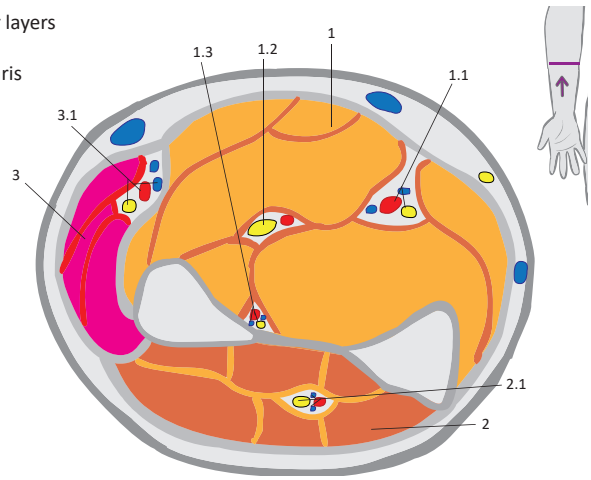

Transverse section of the right forearm, distal view

This copy belongs to ali yaghoubi

The wrist is a collective term for the **carpal bones, radiocarpal, mediocarpal, intercarpal** and **carpometacarpal joints** and the **surrounding muscles and soft tissue**. The neurovascular bundles alter their course as they enter the wrist and travel into the hand.

1 **Ulnar neurovascular bundle**
– enters the palm through the ulnar canal (Guyon's canal)
2 **Median nerve** – enters the palm by passing under the flexor retinaculum
– passes between tendons of the flexor carpi radialis and palmaris longus
– it is the most superficial of the structures in the carpal tunnel
– the tendons of the flexor digitorum profundus pas under the median nerve as it enters the carpal tunnel
3 **Superficial branch of radial nerve, radial artery and veins**
– nerve branches run to the posterior part of the hand over tendons of the abductor pollicis longus, extensor pollicis longus and brevis
– the artery is situated deeper in the anatomical snuff box (*foveola radialis*), then penetrates the muscle of the first interphalangeal space and enters the space of Guiot

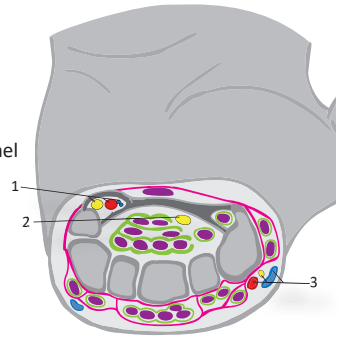

Transverse section of the right wrist, proximal view

7.5.1 Anatomical snuff box – Foveola radialis

The anatomical snuff box is a superficially very well visible socket situated between the tendons of the thumb extensors.

Boundaries

- 1 **Proximally:** extensor retinaculum
- 2 **Anteriorly:** tendons of extensor pollicis brevis and abductor pollicis longus (they are in a joint sheath)
- 3 **Dorsally:** extensor pollicis longus

Content

Superficial structures:
- 4 **Cephalic vein**
- 5 **Superficial branch of radial nerve**

Deep structures:
- 6 **Radial artery** and its dorsal carpal branch for the dorsal carpal arch
- 7 **Radial veins**

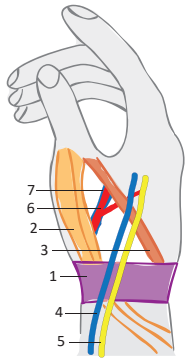

7.5.2 Ulnar canal – Canalis ulnaris

The ulnar canal (Guyon's canal) is a passage through the split layers of the flexor retinaculum located on the medial side of the wrist.

Boundaries

- 1 **Medially:** pisiform bone
  2 **Laterally:** hamulus (hook) of hamate bone
- 3 **Dorsally:** flexor retinaculum
- 4 **Superficially:** palmaris brevis and part of flexor retinaculum

Content

- 5 **Ulnar artery**
- 6 **Ulnar veins**
- 7 **Ulnar nerve**

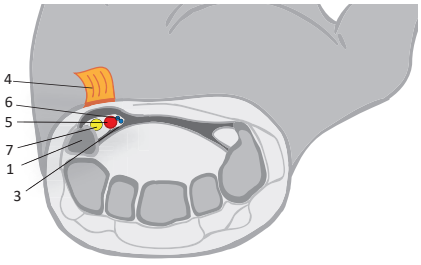

Transverse section of the right wrist, proximal view

The space of Parona is a deep area located distal to the origin of the flexor digitorum profundus, between flexor's tendons and the pronator quadratus. It communicates with the midpalmar space of the hand through the carpal canal.

The anatomical snuffbox is sometimes referred to by its French name fossa la tabatière. This name is derived from the use of this region for taking snuff (powdered tobacco).

The space of Guiot is a gap between the first dorsal interosseus and the adductor pollicis. The radial artery enters this area through the gap between the two heads of the first dorsal interosseous muscle.

The deep branches of both the ulnar vessels and nerve separate from the main neurovascular bundle just distally from the ulnar canal and continue into the depth of the palm.

The radial artery runs superficially in the distal part of the forearm and can be used for diagnostic and therapeutic catheterisation. The ulnar artery can be used as well. Limitations are its deeper location, close relation to the ulnar nerve and its distance from the bone (compression is needed after the procedure).

Clinical notes

The median nerve gives off a motor branch (clinically termed the recurrent branch) for majority of the thenar muscles. It can be harmed in carpal tunnel syndrome surgery.

The space of Parona and the carpal canal can be used for getting into the middle area of the palm (e.g. for drainage). The use of this approach minimises the risk of nerve and vessel damage.

The carpal tunnel is formed by the carpal bones and a thick ligament called the flexor retinaculum. These walls do not allow expansion of this space. This causes the median nerve to be more susceptible to compression as it courses through the carpal tunnel. **Compression of the median nerve in the carpal tunnel is known as carpal tunnel syndrome** and is the most common entrapment syndrome. The carpal canal is subdivided by a fibrous septum into two subspaces: the smaller radial region and the larger ulnar region.

Boundaries

- 1 **Medially:** ulnar eminence of the wrist
- 2 **Laterally:** radial eminence of the wrist
- 3 **Dorsally:** bones of the wrist
- 4 **Frontally:** flexor retinaculum

Content

Ulnar part

- 5 **Median nerve**
- 6 **Tendon of flexor pollicis longus**
- 7 **Tendons of flexor digitorum superficialis**
- 8 **Tendons of flexor digitorum profundus**

Radial part

- 9 **Tendon of flexor carpi radialis**

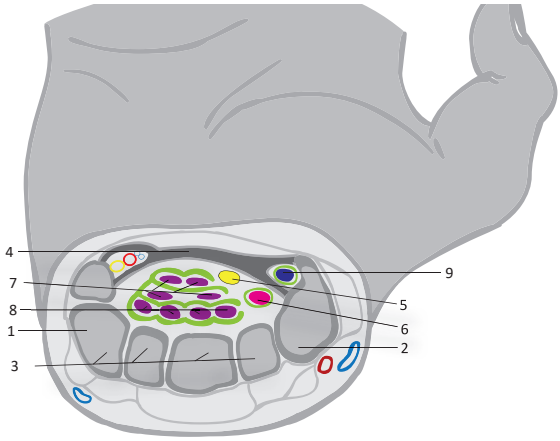

Transverse section of the right wrist, proximal view

7.6 Topography of the hand – Regio manus

The hand is a part of the upper limb situated distally from the wrist. **The regions of the hand** include the palm, dorsum of the hand and the five digits. The palm is further divided into three main regions by the thenar and hypothenar septa. It has a slight concave shape, due to the hypothenar and thenar eminences. This prevents compression of its nerves and vessels during firm hand grasps.

Content

- 1 **Thenar eminence** – formed by the thenar muscles
- 2 **Hypothenar eminence** – formed by the hypothenar muscles
- 3 **Midpalmar space** (*spatium palmare medium*)
  – structures listed from superficial to deep:
  - 3.1 **Palmar aponeurosis**
  - 3.2 **Superficial palmar arch**
  - 3.3 **Median nerve** and its branches
  - 3.4 **Ulnar nerve** and its superfical branches
  - 3.5 **Tendons of flexor digitorum superficialis**
  - 3.6 **Tendons of flexor digitorum profundus**
    - 3.6.1 **Lumbricals**
  - 3.7 **Arterial deep palmar arch**
  - 3.8 **Ulnar nerve** and its deep branch
  - 3.9 **Palmar and dorsal interossei**

Septa

- 4.1 **Thenar septum of *Kanaveli***
  – is the most significant septum
  – is attached to the third metacarpal bone
  – separates the thenar eminence from the midpalmar space
- 4.2 **Hypothenar septum**
  4.3 **Septum extending from the palmar aponeurosis**

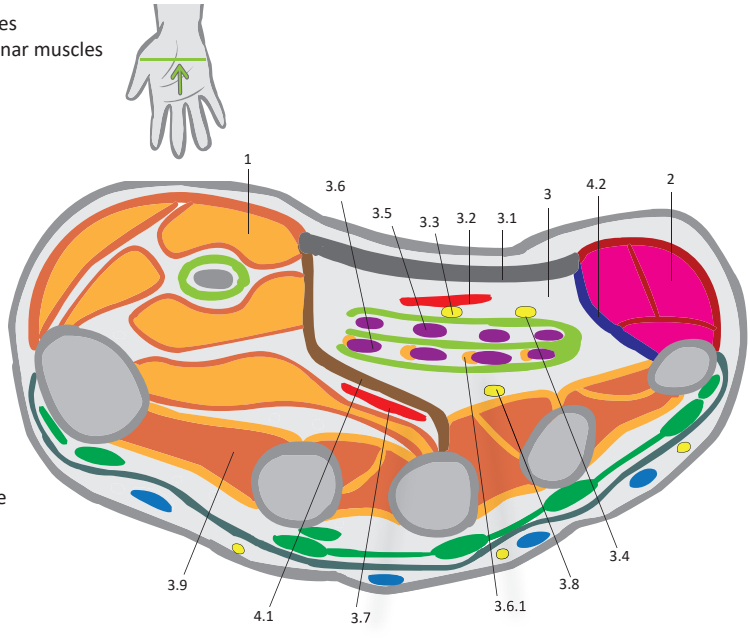

Transverse section of the right hand, distal view

This copy belongs to ali yaghoubi

The vessels and nerves that supply the lower limb come **from the subperitoneal space of the lesser pelvis**. The femoral vessels travel through a long topographical canal that connects the retroperitoneal and subperitoneal spaces to the popliteal fossa.

8.1 Topography of the hip – Regio coxae

The subperitoneal space communicates with the anterior compartment of the thigh through the **vascular and muscular spaces**, with the posterior compartment of the thigh through the **greater and lesser sciatic foramina** and with the medial compartment of the thigh through the **obturator canal**.

8.1.1 Greater and lesser sciatic foramina – Foramen ischiadicum majus et minus

The greater sciatic foramen is bordered by the greater sciatic notch and the sacrospinous and sacrotuberous ligaments. **The piriformis muscle passes through this opening dividing it into the suprapiriform and infrapiriform foramina**. Several structures pass through these foramina, including **nerves from the sacral plexus, the superior and inferior gluteal vessels and the internal pudendal vessels**. **The lesser sciatic foramen** is an opening between the lesser sciatic notch and the sacrotuberous ligament. The **pudendal nerve, internal pudendal vessels** and the tendon of the obturator internus pass through it.

1 **Greater sciatic foramen** (*foramen ischiadicum majus*)
Boundaries:
- 1.1 **Ventrolaterally:** hip bone – greater sciatic notch
- 1.2 **Dorsomedially:** sacrotuberous ligament
- 1.3 **Caudally:** sacrospinous ligament

Divisided by piriformis into
- 1.4 **Suprapiriform foramen** – above the muscle
- 1.5 **Infrapiriform foramen** – under the muscle

2 **Lesser sciatic foramen** (*foramen ischiadicum minus*)
Boundaries:
- 2.1 **Ventrolaterally:** hip bone – lesser sciatic notch
- 2.2 **Dorsomedially:** sacrotuberous ligament

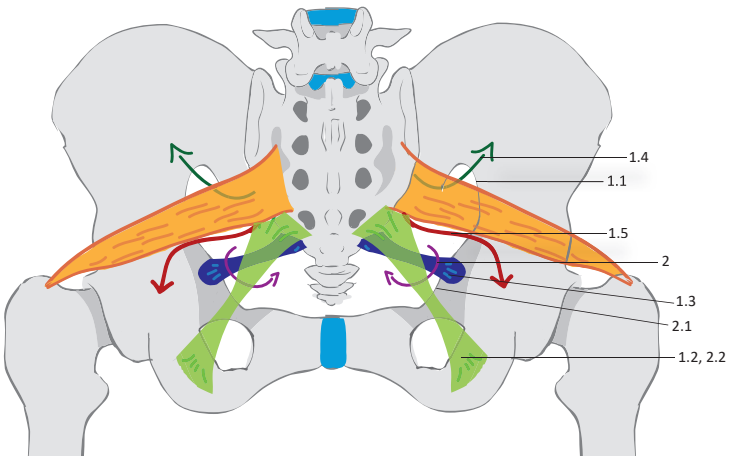

Pelvis, posterior view

The inguinal groove (*sulcus inguinalis*) is a skin crease marking the border between the inguinal region and anterior femoral region. It is located about 3–4 cm distal to the inguinal ligament.

The intergluteal/anal cleft (*crena analis/interglutealis*) is a vertical line between the two buttocks, separating the right and left gluteal regions. It deepens from the sacral and coccygeal bones towards the anus.

The gluteal groove (*sulcus glutealis*) is an arched horizontal line between the gluteal and posterior femoral regions.

The genitofemoral groove (*sulcus genitofemoralis*) separates the perineal region (the external genital organs – scrotum and labia majora) from the medial femoral region.

The femoral canal (*canalis femoralis*) runs from the femoral ring (anulus femoralis) in the medial part of the vascular space to the saphenous opening on the anterior aspect of the thigh. It is conical in shape and about 2 cm long.
Borders:
ventrocranially – inguinal ligament
dorsally – pectineal ligament
medially – lacunar ligament
laterally – common femoral vein
Contents:
– lymphatic vessels of the lower limb
– lymph node of Cloquet

Clinical notes

Meralgia paresthetica is a condition caused by compression of the lateral cutaneous nerve of the thigh in the muscular space. This leads to paresthesia on the ventrolateral aspect of the thigh.

A femoral hernia descends through the vascular space into the thigh, where it can reach the subcutaneous tissue. Other forms of herniation into the lower limb (obturator, suprapiriform and infrapiriform herniae) are quite rare.

The piriformis muscle can compress the nerves and vessels passing through the suprapiriform and infrapiriform foramina, causing entrapment syndromes. It most commonly compresses the sciatic nerve.

The suprapiriform and infrapiriform foramina are openings **connecting the subperitoneal space of the pelvis to the posterior compartment of the thigh**. The suprapiriform foramen contains the superior gluteal nerve and vessels. The sciatic nerve and other nerves from the sacral plexus and their accompanying vessels pass through the infrapirifrom foramen.

- 1 **Suprapiriform foramen** (*foramen suprapiriforme*)
  - **Boundaries:**
    - 1.1 **Ventrolaterally:** hip bone – greater sciatic notch
    - 1.2 **Dorsomedially:** sacrotuberous ligament
    - 1.3 **Caudally:** piriformis
  - **Content:**
    - 1.4 **Superior gluteal nerve**
    - 1.5 **Superior gluteal artery and veins**
- 2 **Infrapiriform foramen** (*foramen infrapiriforme*)
  - **Boundaries:**
    - 2.1 **Cranially:** piriformis
    - 2.2 **Ventrolaterally:** hip bone – greater sciatic notch
    - 2.3 **Dorsomedially:** sacrotuberous ligament
    - 2.4 **Caudally:** sacrospinal ligament
  - **Content:**
    - 2.5 **Sciatic nerve**
    - 2.6 **Pudendal nerve**
    - 2.7 **Inferior gluteal nerve**
    - 2.8 **Posterior femoral cutaneous nerve**
    - 2.9 **Inferior gluteal artery and veins**
    - 2.10 **Internal pudendal artery and veins**
- 3 **Lesser sciatic foramen** (*foramen ischiadicum minus*)
  - **Content:**
    - 3.1 **Pudendal nerve**
    - 3.2 **Internal pudendal artery and veins**
    - 3.3 **Obturator internus** – its insertion tendon

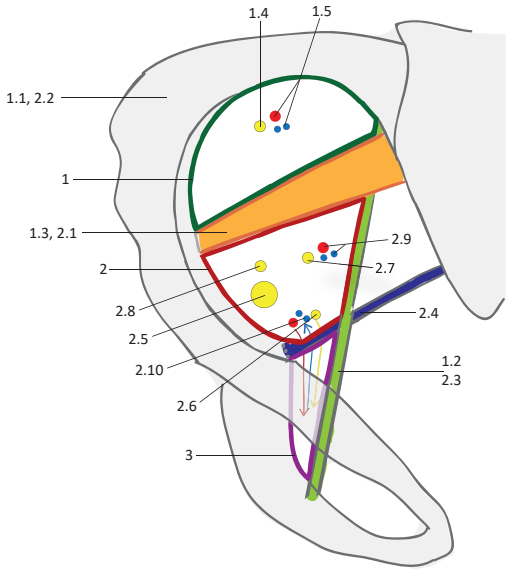

Left half of the pelvis, posterior view

8.1.3 **Vascular and muscular space** – Lacuna vasorum et musculorum

The area under the inguinal ligament is divided by a fibrous band (the iliopectinal arch) into two spaces: **the vascular space and the muscular space**. **The vascular space** is obturated by femoral septum and contains the femoral artery and common femoral vein. **The muscular space** contains the iliopsoas muscle with the femoral nerve on its medial side.

- 1 **Vascular space** (*lacuna vasorum*)
  - **Boundaries:**
    - 1.1 **Ventrally:** inguinal ligament (of Poupart)
    - 1.2 **Laterally:** iliopectineal arch
    - 1.3 **Medially:** lacunar ligament (of Gimbernat)
    - 1.4 **Dorsally:** superior pubic ramus and pectineal ligament (of Cooper)
  - **Content** (mediolaterally)**:**
    - 1.5 **Proximal deep inguinal lymp node of (Cloquet)**
    - 1.6 **Common femoral vein**
    - 1.7 **Femoral artery**
    - 1.8 **Femoral branch of genitofemoral nerve**
- 2 **Muscular space** (*lacuna musculorum*)
  - **Boundaries:**
    - 2.1 **Ventrally:** inguinal ligament (of Poupart)
    - 2.2 **Dorsally:** ilium
    - 2.3 **Medially:** iliopectineal arch
  - **Content** (mediolaterally)**:**
    - 2.4 **Femoral nerve**
    - 2.5 **Iliopsoas**
    - 2.6 **Lateral cutaneous nerve of thigh**

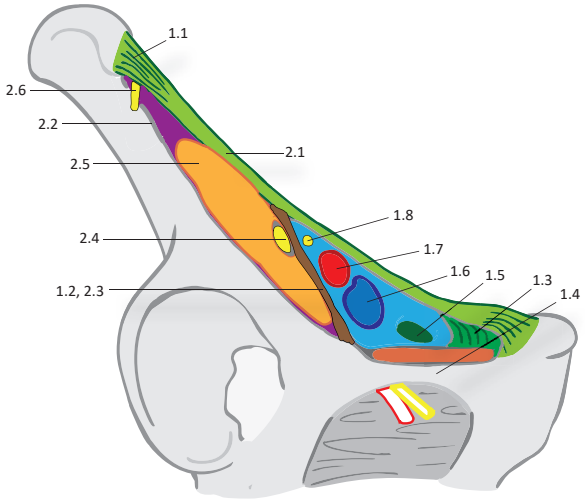

Anterior view of the right half of the pelvis

This copy belongs to ali yaghoubi

The obturator canal is formed in the area of the obturator groove where the obturator foramen is not fully covered by the obturator membrane. **The obturator nerve and vessels** pass through this canal.

- 1 **Obturator canal**
  Content:
  - 1.1 **Obturator nerve**
  - 1.2 **Obturatory artery and veins**

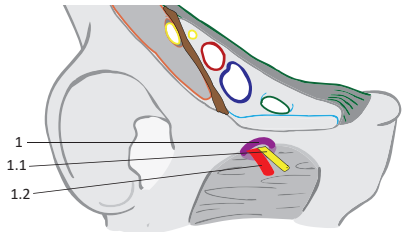

Anterior view of right half of the pelvis

8.2 Topography of the thigh – Regio femoris

Muscular fasciae divide the thigh into **three osteofascial spaces**: the anterior, posterior and medial compartments.

- 1 **Anterior compartment of thigh** (*compartimentum femoris anterius*)
  – contains the anterior group of thigh muscles
  - 1.1 **Femoral nerve** – branches in the iliopectineal fossa
    - 1.1.1 **Saphenous nerve** – the terminal branch of the femoral nerve
      – travels with the femoral atery and vein through the adductor canal
      – reaches the subcutaneous tissue after passing through the vasto-adductor membrane
  - 1.2 **Femoral artery** – - gives off most of its branches within the iliopectineal fossa
    – travels through the adductor canal and adductor hiatus to reach the popliteal fossa
    - 1.2.1 **Profunda femoris artery** (deep artery of thigh)
      – runs between the muscles of the medial thigh
  - 1.3 **Femoral vein** – the continuation of the popliteal vein after passing through the adductor hiatus
    – passes through the adductor canal
    – joins the profunda femoris vein in the iliopectineal fossa to form the common femoral vein, which receives the great saphenous vein
    - 1.3.1 **Great saphenous vein** – runs in the subcutaneous tissue on the medial side of the thigh
- 2 **Posterior compartment of thigh** (*compartimentum femoris posterius*)
  – contains the posterior group of thigh muscles
  - 2.1 **Sciatic nerve** – courses between the posterior thigh muscles to reach the popliteal fossa, where it bifurcates (in most cases)
  - 2.2 **Posterior cutaneous nerve of thigh**
    – runs in the subcutaneous tissue (in the distal part it runs with the cranial extension of the small saphenous vein)
- 3 **Medial compartment of thigh** (*compartimentum femoris mediale*)
  – contains the medial group of thigh muscles
  - 3.1 **Obturator nerve, artery and veins**
    – supply the proximal part of the medial side of the thigh



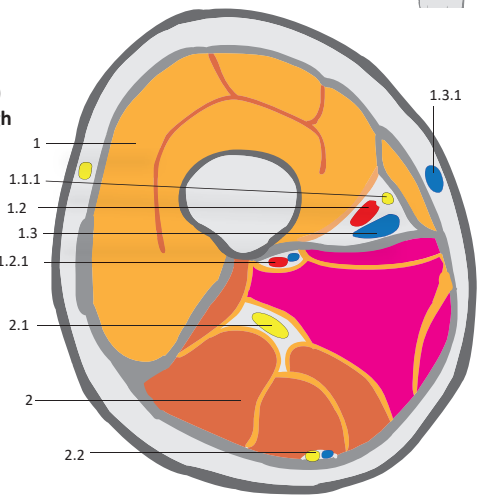

Transverse section of the right thigh, distal view

Topography

The greater fossa of Scarpa is an obsolete term for the femoral triangle. **The lesser fossa of Scarpa** is an obsolete term for the iliopectineal fossa.

The sciatic nerve can be found in the posterior compartment of the thigh in a groove between the biceps femoris and the semimembranosus and semitendinosus muscles.

A long innominate space filled with loose connective tissue spreads from the cranial base through the mediastinum and retroperitoneal space to the posterior compartment of the thigh and terminates in the popliteal fossa.

The adductor canal is covered by the belly of the sartorius muscle. An obsolete term for the adductor canal is the subsartorial canal.

The perforating vein of adductor canal / perforator of Dodd (*vena perforans canalis adductorii*) pierces the deep fascia to enter the adductor canal. It connects the great saphenous vein to the profunda femoris vein.

The lymph node of Cloquet-Rosenmüller (*nodus lymphoideus inguinalis profundus proximalis*) is the most proximal node located within the vascular space.

Mnemonic for the structures in the vascular space:
CLOVAN (mediolateral):
CLOquet-Rosenmüller lymph node,
Vena femoralis communis,
Arteria femoralis,
Nervus genitofemoralis (femoral branch).

Clinical notes

The popliteal artery is a very elastic vessel. This predisposes it to forming an aneurysm.

After it leaves the vascular space the femoral artery is located close to the skin. This position facilitates it use for diagnostic and therapeutic catheterization.

The femoral triangle is a large **superficial region** formed by the femoral muscles and inguinal ligament. **The iliopectineal fossa** is located within it between the pectineus and iliopsoas. **The femoral triangle and iliopectineal fossa** communicate proximally with the muscular and vascular spaces. Distally, they continue as the **adductor canal**, which leads to the **popliteal fossa**. Superficially, this region is covered by the cribiform fasica (part of the fascia lata). The great saphenous vein passes through the saphenous opening within this fascia to empty into the common femoral vein.

- 1 **Femoral triangle**
  Boundaries:
  - 1.1 **Proximally:** inguinal ligament
  - 1.2 **Medially:** adductor longus
  - 1.3 **Laterally:** sartorius
- 2 **Iliopectineal fossa**
  Boundaries:
  - 2.1 **Medially:** pectineus
  - 2.2 **Laterally:** iliopsoas

Common content

- 3 **Femoral nerves** and its branches
- 4 **Femoral artery** and its branches
- 5 **Common femoral vein** and its branches
  - 5.1 **Saphenous opening**
    – an opening in the fascia lata (cribriform fascia) for the great saphenous vein
  - 5.2 **Subinguinal venous confluence**
    – tributary veins join the great saphenous vein
- 6 **Obturator nerve** and its branches
- 7 **Obturator artery** and vein
- 8 **Femoral branch of genitofemoral nerve**
- 9 **Lateral cutaneous nerve of thigh**
- 10 **Deep and superficial inguinal lymph nodes**

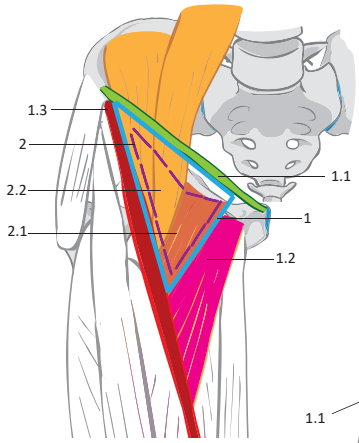

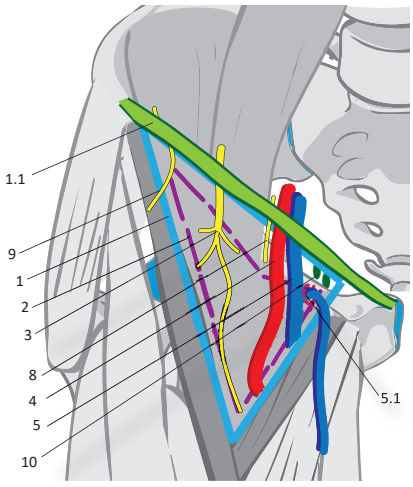

Proximal part of the right thigh, anterior view

8.2.2 **Adductor canal** – Canalis adductorius

The adductor canal (of Hunter) connects the femoral triangle to the popliteal fossa. It is located **between the anterior and medial compartments of the thigh** and is covered superficially by the vasto-adductor membrane. It ends distally between the two insertions of the adductor magnus, which form the adductor hiatus. **The femoral vessels pass through the adductor canal**, after leaving it they become the popliteal vessels. The saphenous nerve and saphenous branch of the descending genicular artery perforate the vasto-adductor membrane to enter the subcutaneous tissue.

Boundaries

- 1 **Medially:** adductor longus
- 2 **Laterally:** vastus medialis
- 3 **Ventrally:** vasto-adductor membrane
- 4 **Dorsally:** adductor magnus

Content

- 5 **Femoral artery and vein**
- 6 **Saphenous nerve**

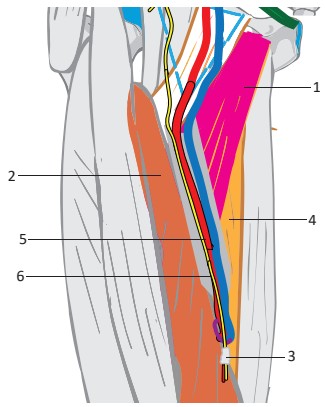

Right thigh, anterior view

This copy belongs to ali yaghoubi

The adductor hiatus opens into the **popliteal fossa**, an **area located behind the knee joint containing the sciatic nerve and the popliteal artery, vein and lymph nodes**. The bifurcation of the sciatic nerve is usually located here. Its branches join the branches of the popliteal artery, thus forming the neurovascular bundles of the leg, which leave the popliteal fossa via the openings in the fascia of the individual leg compartments. Because the **popliteal artery enters from the adductor canal, it is the most deeply located structure** in the popliteal fossa. **The sciatic nerve is located most superficially**. The popliteal vein lies between them. The **small saphenous vein runs subcutaneously**; it pierces the crural fascia and empties into the popliteal vein.

Boundaries

- 1 **Medioproximally:** semimembranosus and semitendinosus
- 2 **Lateroproximally:** biceps femoris
- 3 **Mediodistally:** gastrocnemius – medial head
- 4 **Laterodistally:** gastrocnemius – lateral head
- 5 **Bottom** (ventrally)**:** popliteus

Content

- 6 **Sciatic nerve**
  - 6.1 **Tibial nerve**
  - 6.2 **Common fibular nerve**
- 7 **Popliteal artery** and its branches
- 8 **Popliteal vein** and its tributary veins

9 **Popliteal lymph nodes**

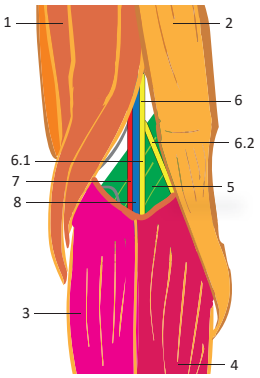

Right popliteal fossa, posterior view

8.3 Topography of the leg – Regio cruris

The crural fascia divides the leg into **three osteofascial regions: the anterior, posterior and lateral compartments of the leg.**

- 1 **Anterior compartment of leg** (*compartimentum cruris anterius*)
  – anterior group of muscles of leg
  - 1.1 **Anterior tibial vessels and deep fibular nerve**
    – anterior tibial artery and veins go through an opening in the interosseous membrane of the leg (middle tibiofibular ligament)
    – deep fibular nerve emerges from the fibular canal through an opening in the anterior intermuscular septum of the leg
- 2 **Posterior compartment of leg** (*compartimentum cruris posterius*)
  – posterior group of muscles of leg
  - 2.1 **Posterior tibial vessles and tibial nerve**
    – neurovascular bundle courses under the tendinous arch of the soleus and between the deep and superficial muscles of posterior group of the leg
  - 2.2 **Fibular vessels**
    – run in the musculofibular canal that lies between the shaft of the fibula and flexor hallucis longus
- 3 **Lateral group of muscles of leg** (*compartimentum cruris laterale*)
  – lateral group of muscles of leg
  – does not contain a neurovascular bundle
  - 3.1 **Superficial fibular nerve**
    – descends between the fibular muscles and pierces to the subcutaneous tissue in the distal part of the lateral compartment



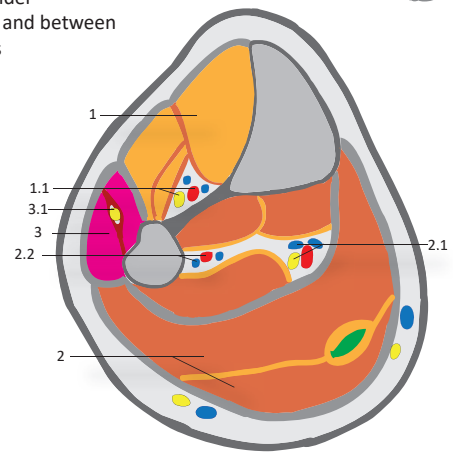

Transverse section of the right leg, distal view

Topography

The anterior tibial vessels pass through the anterior compartment of the leg. They are anchored to the bone by fibrous loops called vincula. This makes them susceptible to being damaged by leg fractures.

The sciatic nerve bifurcates into two branches in the popliteal fossa. However, it may bifurcate more proximally; sometimes as proximally as the infrapiriform foramen. When this happens, some portions of the nerve may perforate the piriformis muscle.

Mnemonic for the structures in the popliteal fossa:
Mediolaterally – AVEN
Arteria poplitea,
VEna poplitea,
Nervus tibialis.
From superficial to deep
(when the structure is damaged):
Hurts (nerve),
Flows (vein),
Sprays (artery).

Mnemonic:
lateral malleolus structures – **SAPASUFI**:
vena **SA**phena **PA**rva,
nervus **SU**ralis,
Tendons of musculus **FI**bularis longus and brevis (in a common tendinous sheath)

Clinical notes

It is necessary to know the course of each neurovascular bundle of the leg as they can be damaged by fractures and during the reduction and internal fixation of fracture fragments (osteosynthesis).

Tarsal tunnel syndrome is an entrapment syndrome of the tibial nerve where it passes behind the medial malleolus through the tarsal canal (*canalis malleolaris*).

The fibular canal transmits **the deep fibular nerve into the anterior compartment of the leg**. **The tendinous arch of the soleus** is a fibrous arch at the origin of the soleus. It attaches to the dorsal surfaces of the fibula and tibia. The posterior tibial vessels and tibial nerve run under it. **The musculofibular canal (of Hyrtl)** is a narrow slit-like space located in the posterior compartment of the leg between the shaft of the fibula and the flexor hallucis longus.

- 1 **Fibular canal** (*canalis fibularis*)
  Boundaries:
  1.1 **Entrance:** the fibular hiatus between the fibularis longus and soleus
  1.2 **Exit:** the anterior intermuscular septum of the leg
  Content:
  - 1.3 **Common fibular nerve**
    – bifurcates here into the deep and superficial fibular nerve
  - 1.4 **Deep fibular nerve**
    – continues in the canal to the anterior compartment of the leg

- 2 **Tendinous arch of soleus** (*arcus tendineus musculi solei*)
  Content:
  - 2.1 **Tibial nerve**
  - 2.2 **Posterior tibial artery and veins**

- 3 **Musculofibular canal of *Hyrtl*** (*canalis musculofibularis*)
  Boundaries:
  3.1 **Laterally:** Shaft of fibula
  3.2 **Medially:** Flexor hallucis longus
  Content:
  - 3.3 **Fibular artery and veins**

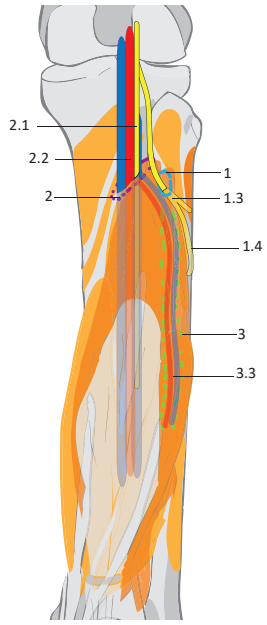

Posterior view of the right leg

8.4 Topography of the ankle – Regio tarsalis

The tibial nerve and posterior tibial vessels pass through the **tarsal canal (*canalis malleolaris*)** to reach the sole of the foot. The deep fibular nerve and anterior tibial vessels travel under the extensor retinacula to reach the dorsum of the foot. The superficial fibular nerve travels over the extensor retinacula to reach the dorsum of the foot.

8.4.1 Lateral retromalleolar space

The structures behind the lateral malleolus are located both superficially (vein and nerve) and deeply (tendons) to the fibular retinacula.

Boundaries

- 1 **Laterally:** Superior and inferior fibular retinacula
- 2 **Ventrally:** Lateral malleolus
- 3 **Dorsally:** Calcaneal tuberosity

Content

Superficially to the retinacula
- 4 **Small saphenous vein**
- 5 **Sural nerve**

Under the retinacula
- 6 **Fibularis brevis**
  – tendon (in a common tendinous sheath)
- 7 **Fibularis longus**
  – tendon (in a common tendinous sheath)



Lateral view of the right foot

This copy belongs to ali yaghoubi

The tarsal tunnel/canal is a topographical space in the medial retromalleolar **space located behind the medial malleolus**. Its contents are covered by the flexor retinaculum.

Boundaries

- 1 **Medially:** flexor retinaculum
- 2 **Ventrally:** medial malleolus
- 3 **Dorsally:** calcaneal tuberosity

Content

- 4 **Tibialis posterior**
  – tendon (in its own tendinous sheath)
- 5 **Flexor digitorum longus**
  – tendon (in its own tendinous sheath)
- 6 **Posterior tibial artery and veins**
- 7 **Tibial nerve**
- 8 **Flexor hallucis longus**
  – tendon (in its own tendinous sheath)

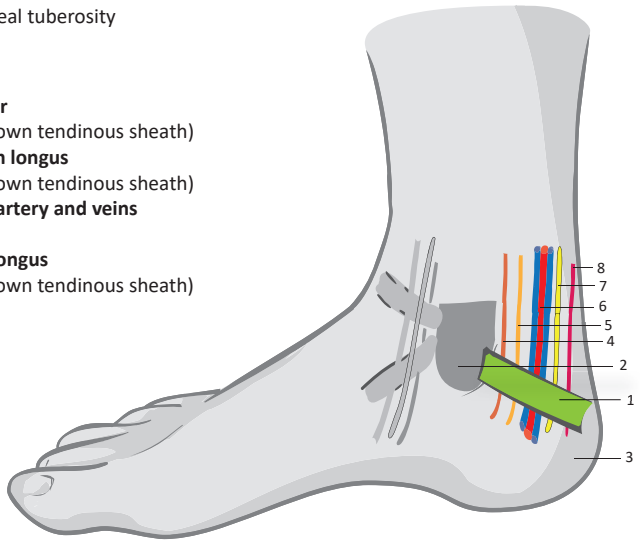

Right foot, medial view

8.4.3 Structures in front of of the medial malleolus

The structures located **in front of the medial malleolus** pass both superficially (vein and nerve) and deeply (tendon) to the extensor retinacula.

Boundaries

- 1 **Ventrally:** superior and inferior extensor retinaculum
- 2 **Dorsally:** medial malleolus

Content

Superficially to the retinacula

- 3 **Great saphenous vein**
- 4 **Saphenous nerve**

Under the retinacula

- 5 **Tibialis anterior**
  – tendon (in a separate tendinous sheath)

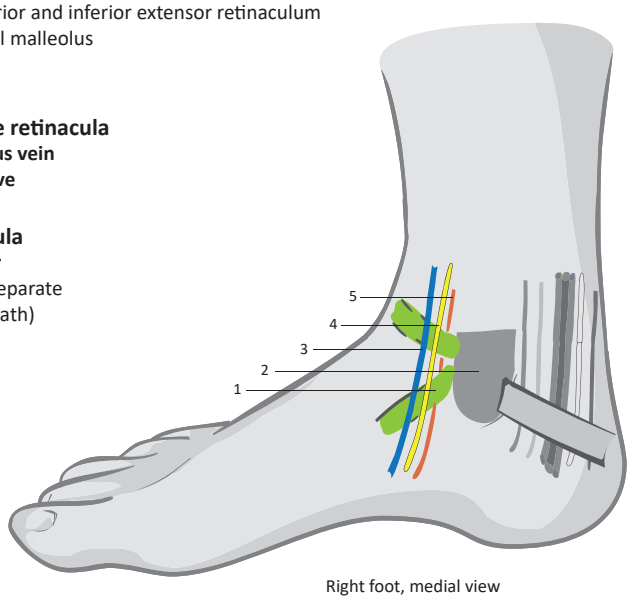

Right foot, medial view

Topography

Triangle of Kager is a translucent area seen on a lateral X-ray of the ankle. It is formed by the flexor hallucis longus ventrally, the Achilles tendon dorsally and the calcaneus distally. It contains adipose tissue, which produces the translucency on the X-ray.

A mnemonic for the structures in the tarsal canal (ventro-dorsal) – TIDIVANEH:
TIbialis posterior tendon
Flexor **DI**gitorum longus tendon
VAsa tibialis posteriora,
Tibial **NE**rve
Fexor **H**allucis longus tendon

A mnemonic for the structures in front of the medial malleolus – SAMANTA:
Vena **SA**phena **MA**gna
Saphenous **N**erve
Tibialis **A**nterior tendon

Clinical notes

Morton's neuroma / Morton's metatarsalgia is a benign tumor of a common plantar digital nerve. It causes pain in the region supplied by the affected nerve.

Loss of the plantar arch is typical in chronic diabetes. It is one of the factors in the pathogenesis of the diabetic foot syndrome.

Due to the arched shape of the foot, there is only a small amount of tissue between the skin and the bones on the dorsum of the foot. **The sole**, however, is relatively thick and is composed of a number of layers. The medial neurovascular bundle of the foot is located superficially, whereas the lateral one is much deeper. The lateral neurovascular bundle runs deeply, which prevents it from being compressed during standing and walking.

8.5.1 **Dorsum of the foot** – Dorsum pedis

The dorsum of the foot contains a thin layer of subcutaneous tissue, almost completely devoid of fat. Within this tissue lies a network of superficial veins and nerves. Underneath the subcutaneous tissue, the tendons of the long muscles of the foot are located. Deeper still, we find the bellies of the short muscles.

1 **Subcutaneous tissue**
- 1.1 **Dorsal venous arch of foot** and dorsal venous network of foot
- 1.2 **Intermediate and medial dorsal cutaneous nerve** – branches of the superficial fibular nerve
- 1.3 **Lateral dorsal cutaneous nerve** – branch of the sural nerve

2 **Extensor digitorum longus and extensor hallucis longus** – tendons

3 **Deep fibular nerve** and its branches

4 **Dorsalis pedis artery and vein** – its branches and tributary veins
- 4.1 **Dorsal metatarsal arteries and veins**

5 **Extensor digitorum brevis and extensor hallucis brevis** – bellies and tendons

6 **Tarsal and metatarsal bones**
- 6.1 **Dorsal interossei of foot**

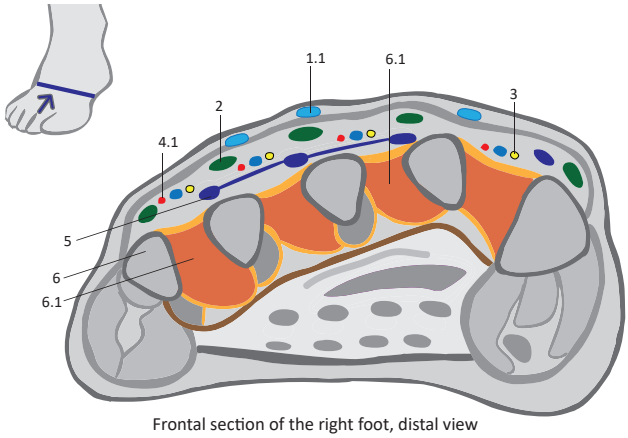

Frontal section of the right foot, distal view

8.5.2 **Sole** – Planta

The sole has a concave shape that is formed by the **longitudinal and transverse arches of the foot**. This shape gives the **foot flexibility of movement and prevents compression of the neurovascular bundles of the foot**. The foot is divided by fascial septa into three regions. These septa are derived from the fascia of the muscles of the 1st and 5th digits.

1 **Skin and subcutaneous tissue**

2 **Plantar aponeurosis**

3 **Flexor digitorum brevis**

4 **Neurovascular bundle**
- 4.1 **Medial plantar artery**
- 4.2 **Medial plantar vein**
- 4.3 **Medial plantar nerve**

5 **Muscles**
- 5.1 **Quadratus plantae**
- 5.2 **Flexor digitorum longus** – four tendons
- 5.3 **Lumbricals**
- 5.4 **Flexor hallucis longus** – tendon

6 **Adductor hallucis** – transverse head

7 **Neurovascular bundle**
- 7.1 **Plantar arch** (supplied mainly by the lateral plantar artery)
- 7.2 **Deep plantar venous arch**
- 7.3 **Lateral plantar nerve – deep branch**

8 **Plantar interosseous fascia**

9 **Tarsal and metatarsal bones**
- 9.1 **Plantar interossei**

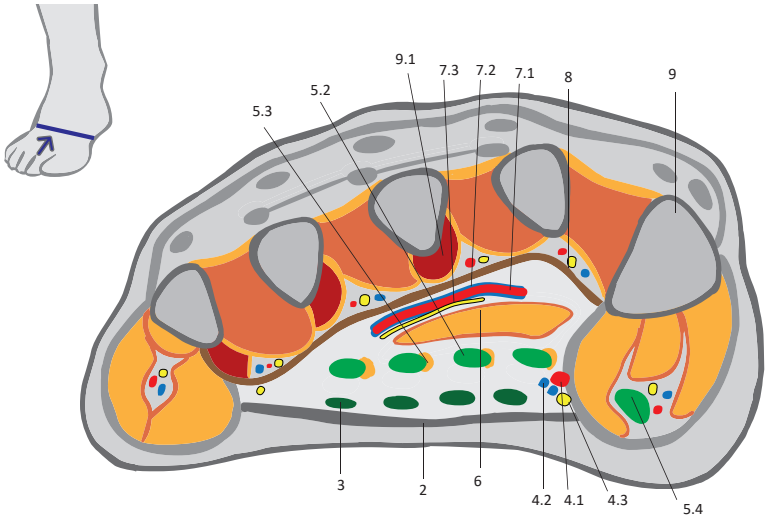

Frontal section of the right foot, distal view

This copy belongs to ali yaghoubi

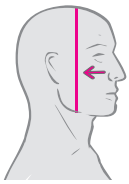

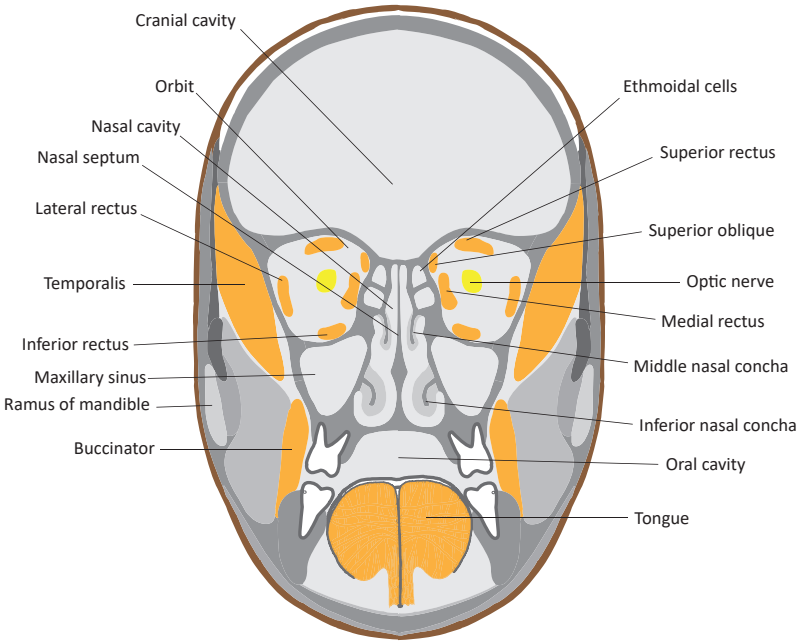

Frontal section of the head

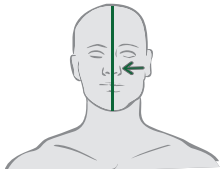

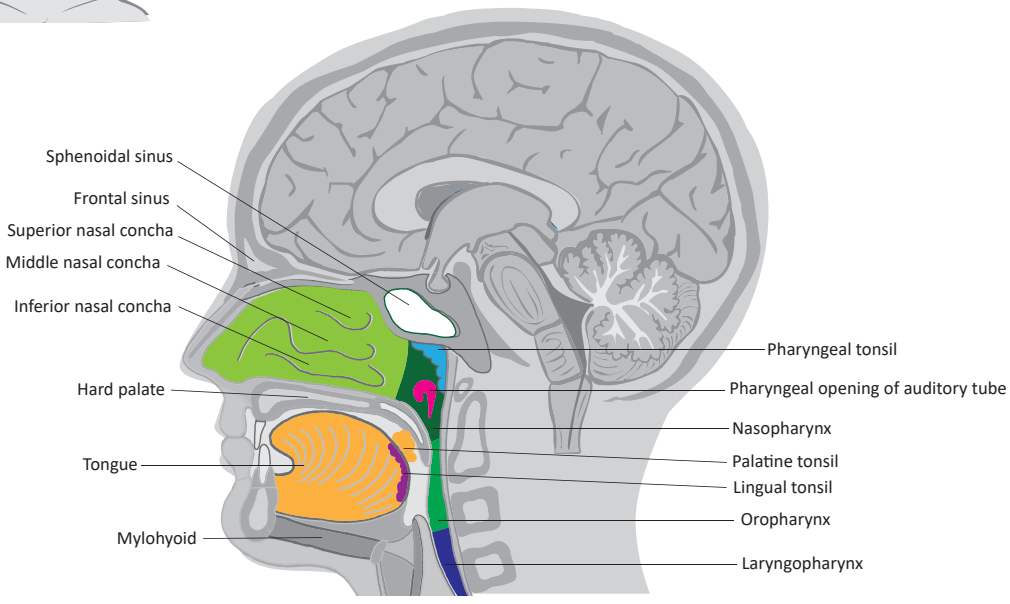

Median section of the head

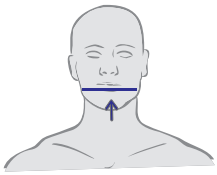

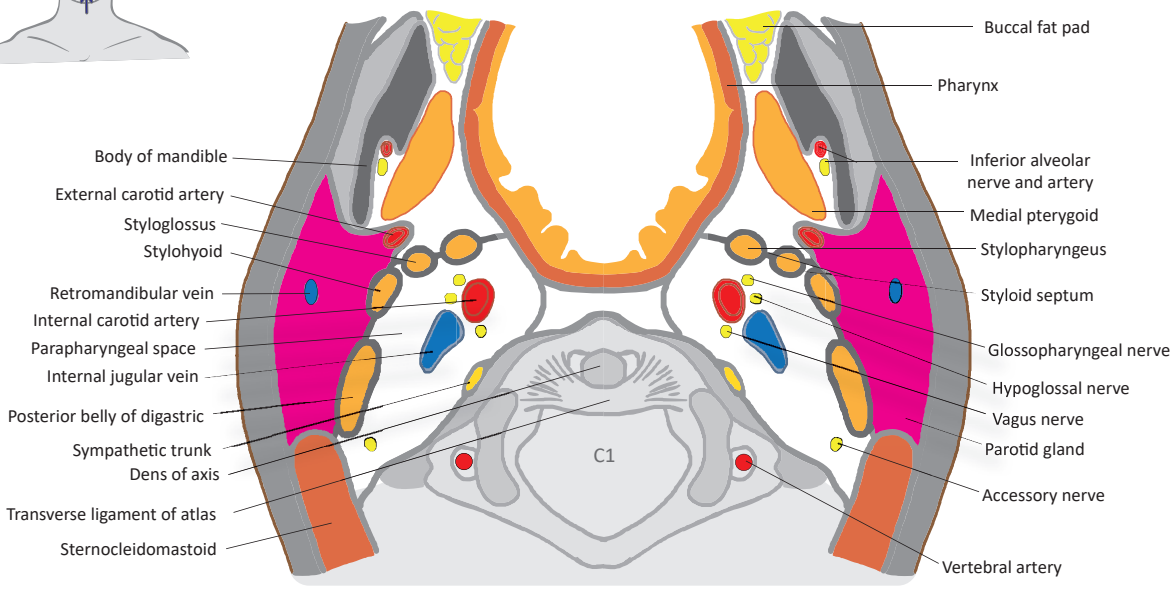

Transverse section of the neck at the level of vertebra C1

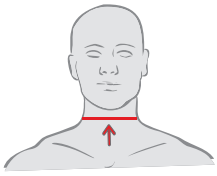

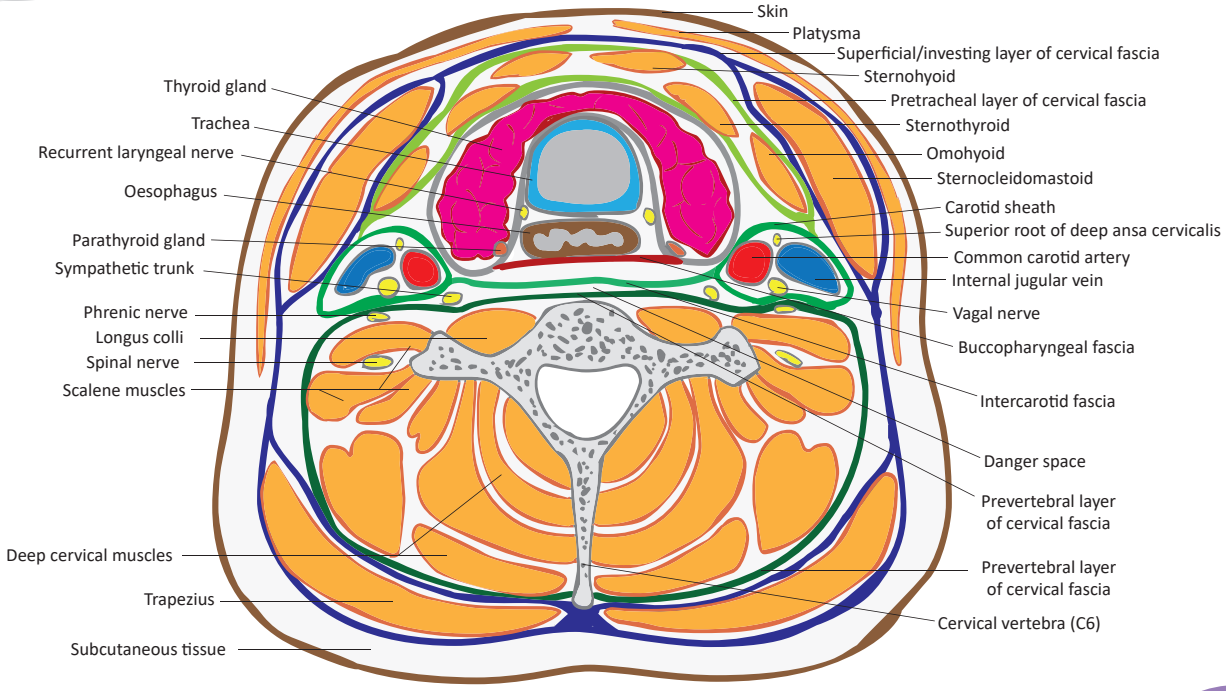

Transverse section of the neck at the level of vertebra C6

This copy belongs to ali yaghoubi

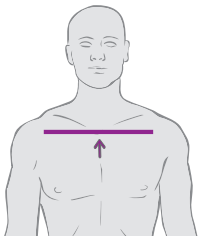

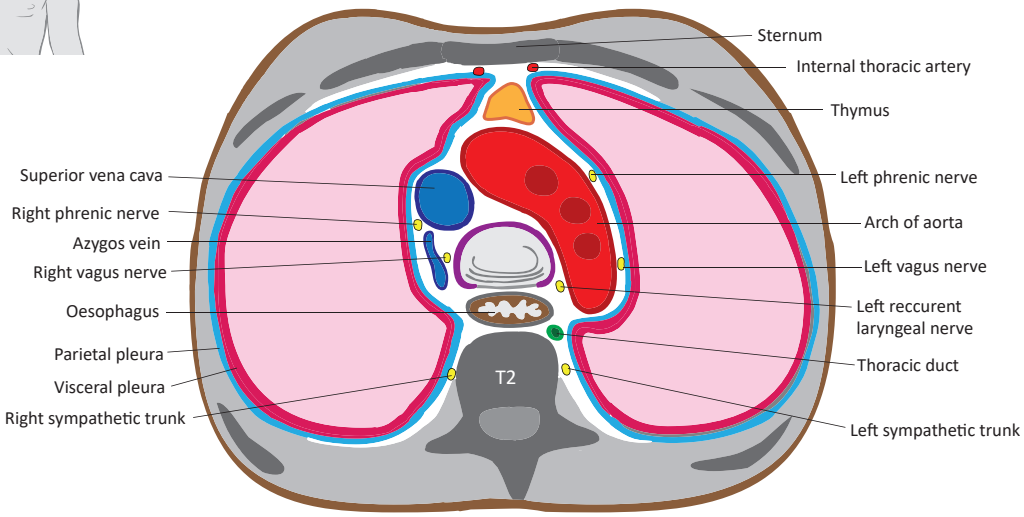

Transverse section of the thorax at the level of vertebra T2

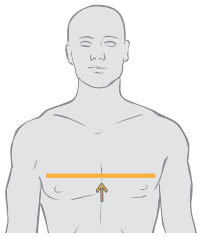

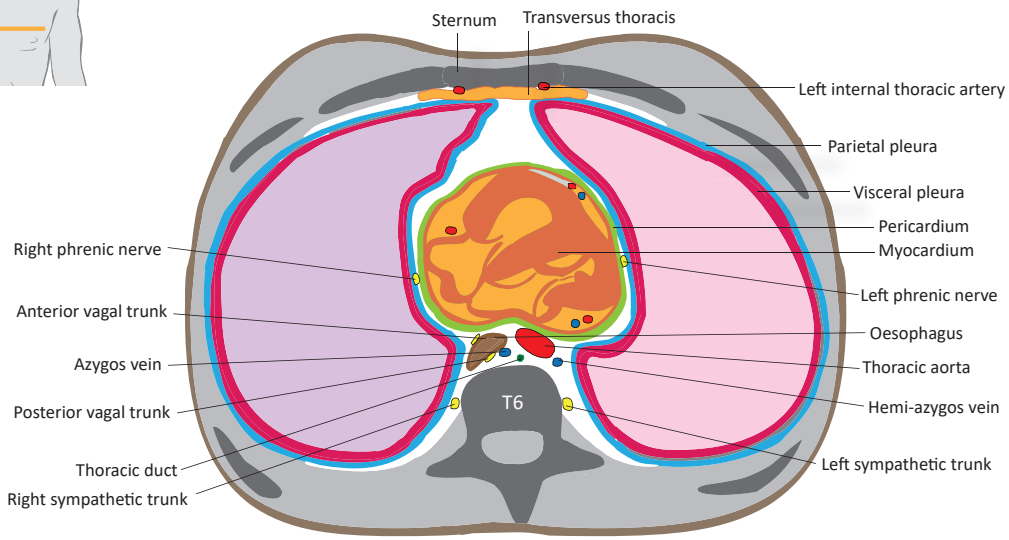

Transverse section of the thorax at the level of vertebra T6

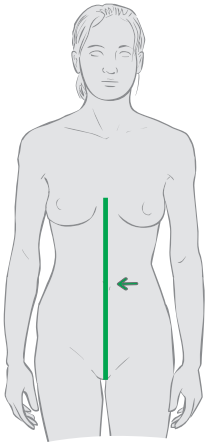

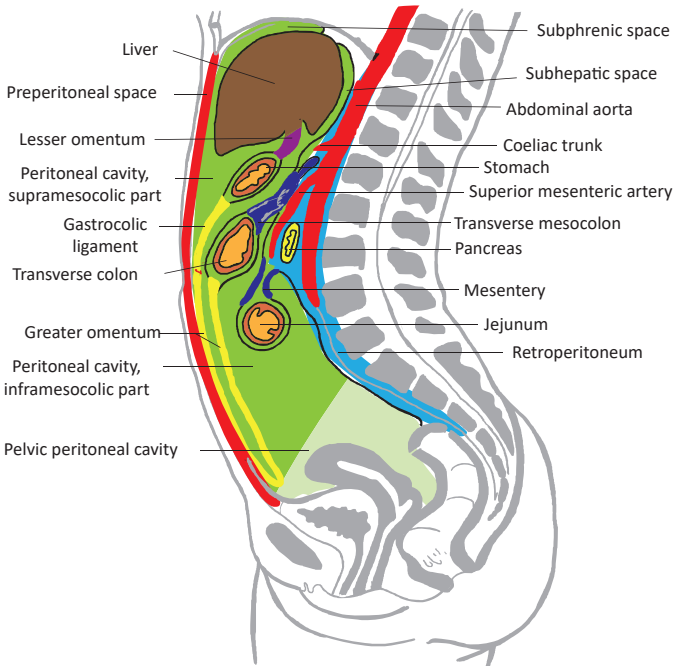

Median section of the female body

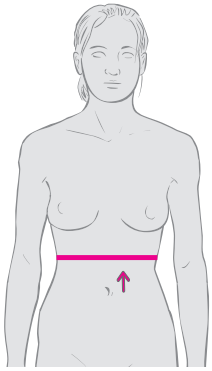

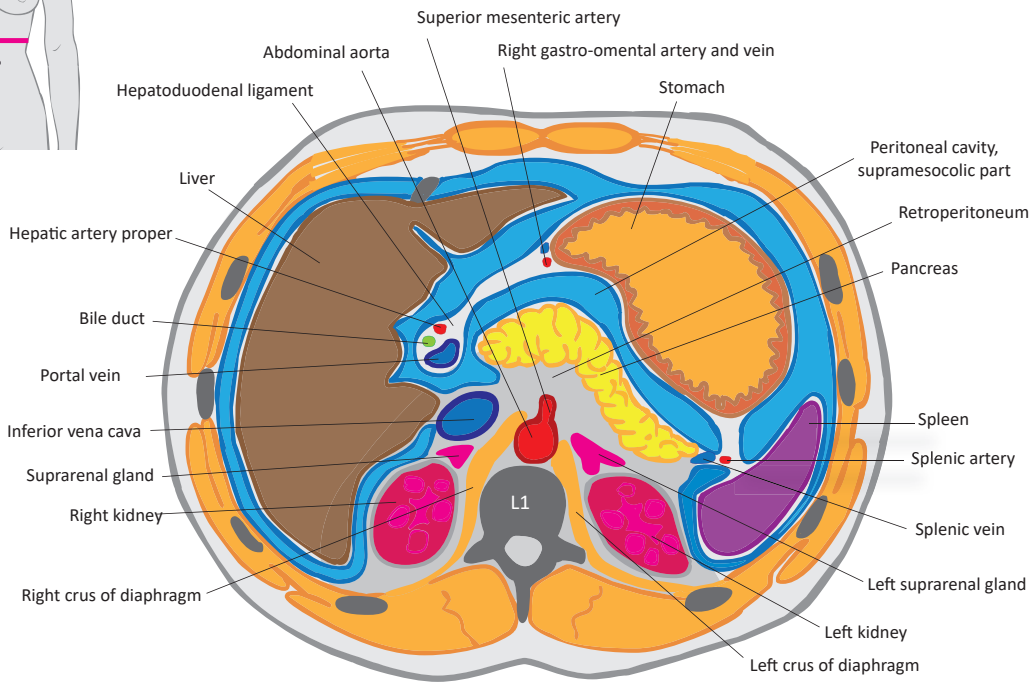

Transverse section of the abdomen at the level of vertebra L1

This copy belongs to ali yaghoubi

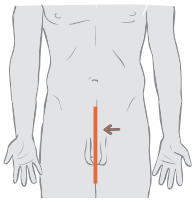

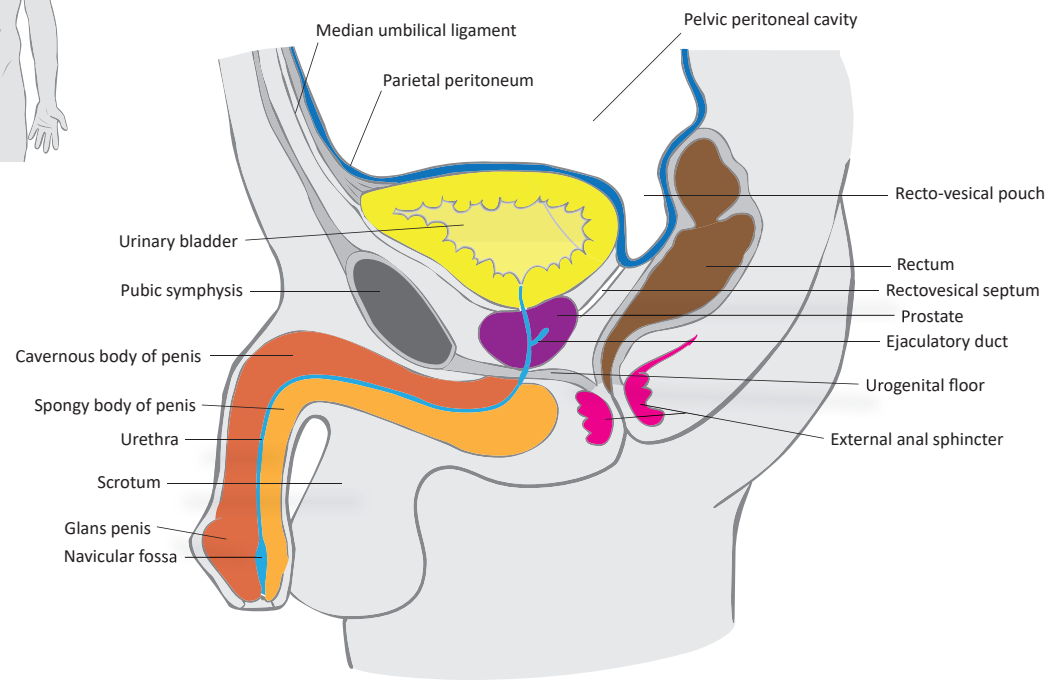

Sagittal section of the male pelvis

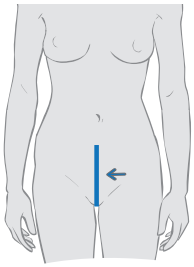

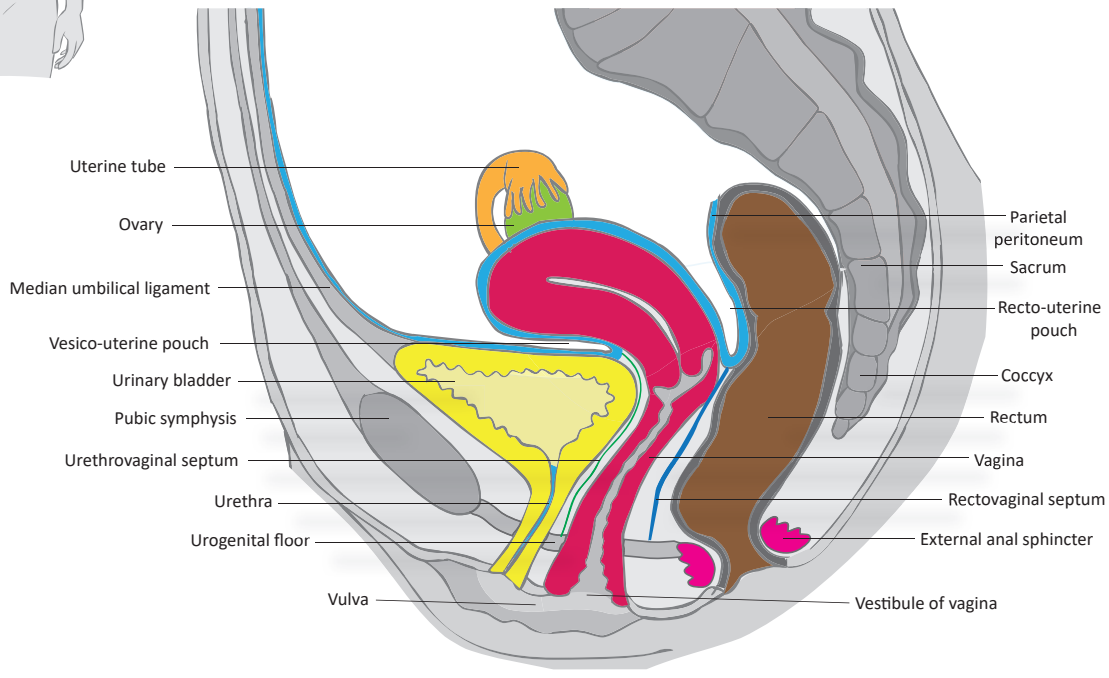

Sagittal section of the female pelvis



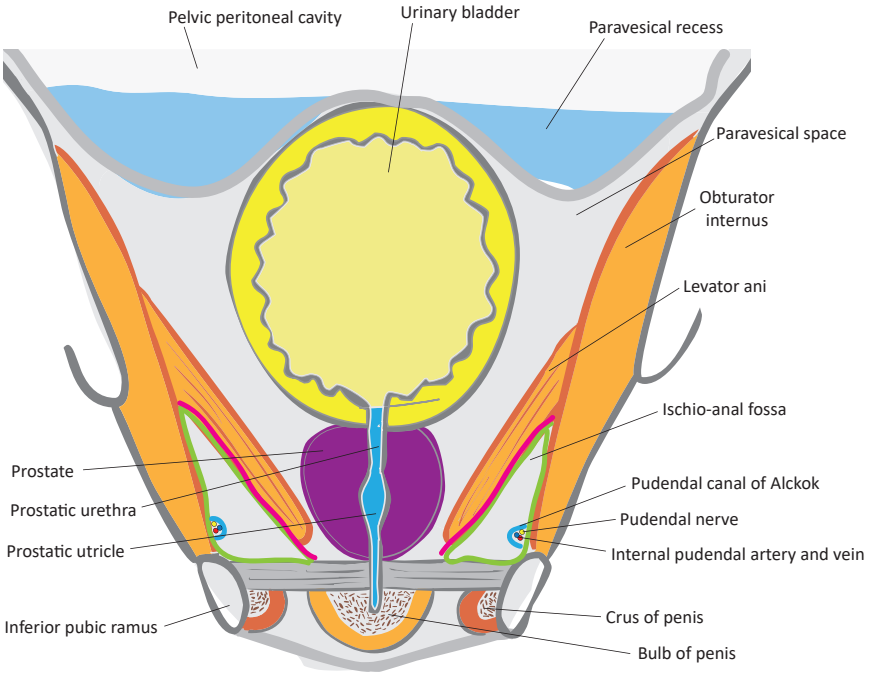

Frontal section of the male pelvis (urinary bladder is full)

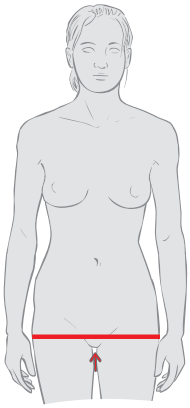

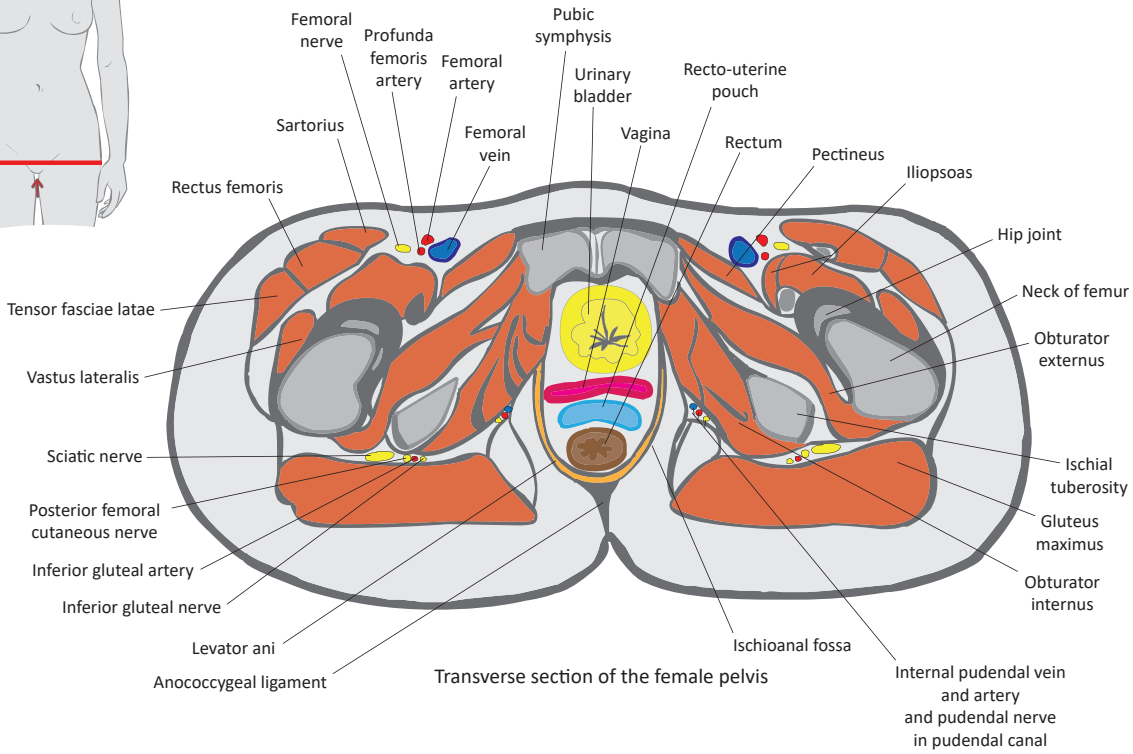

Transverse section of the female pelvis

This copy belongs to ali yaghoubi

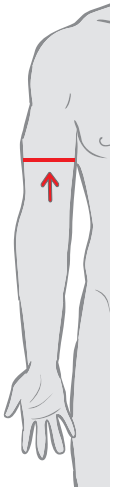

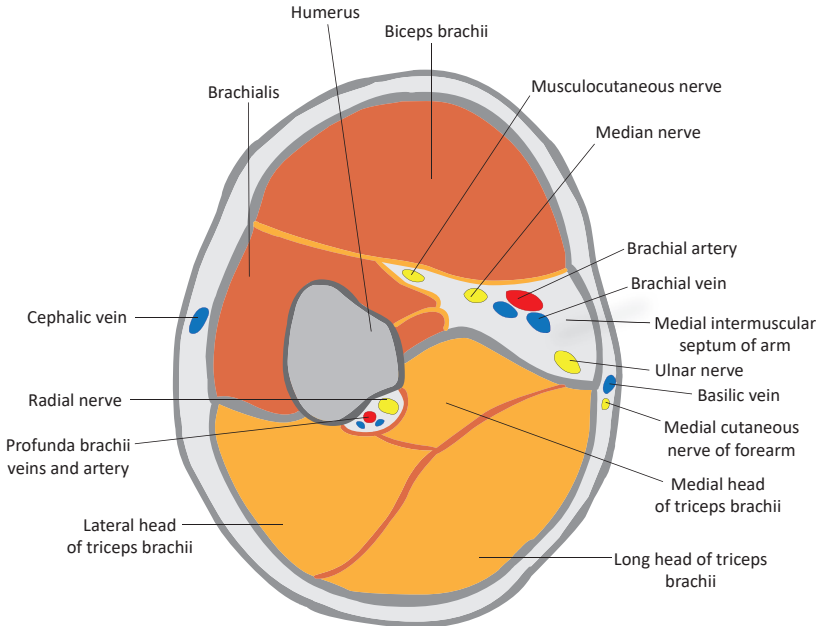

Transverse section of the right arm

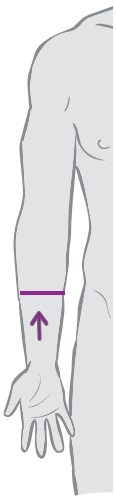

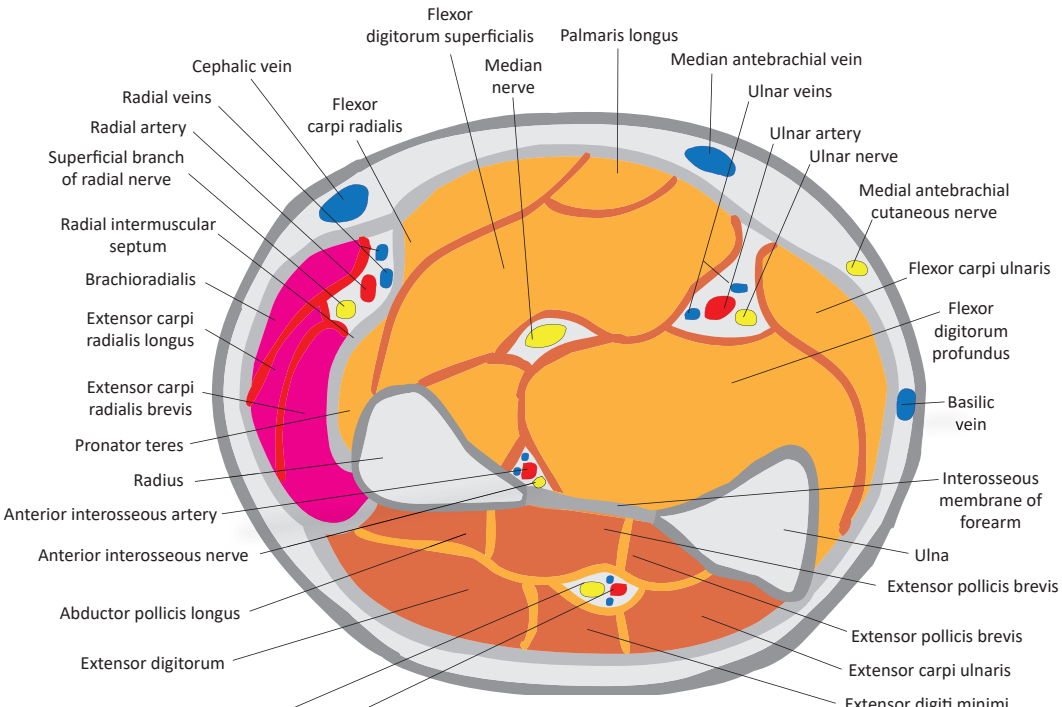

Transverse section of the right forearm

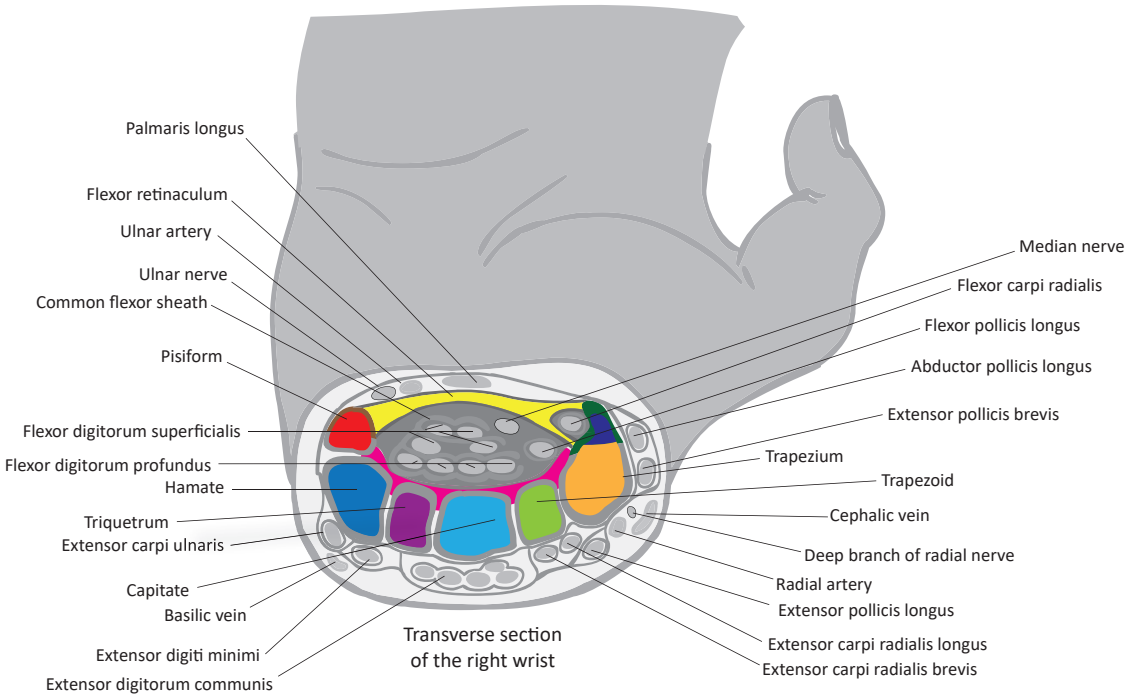

Transverse section of the right wrist

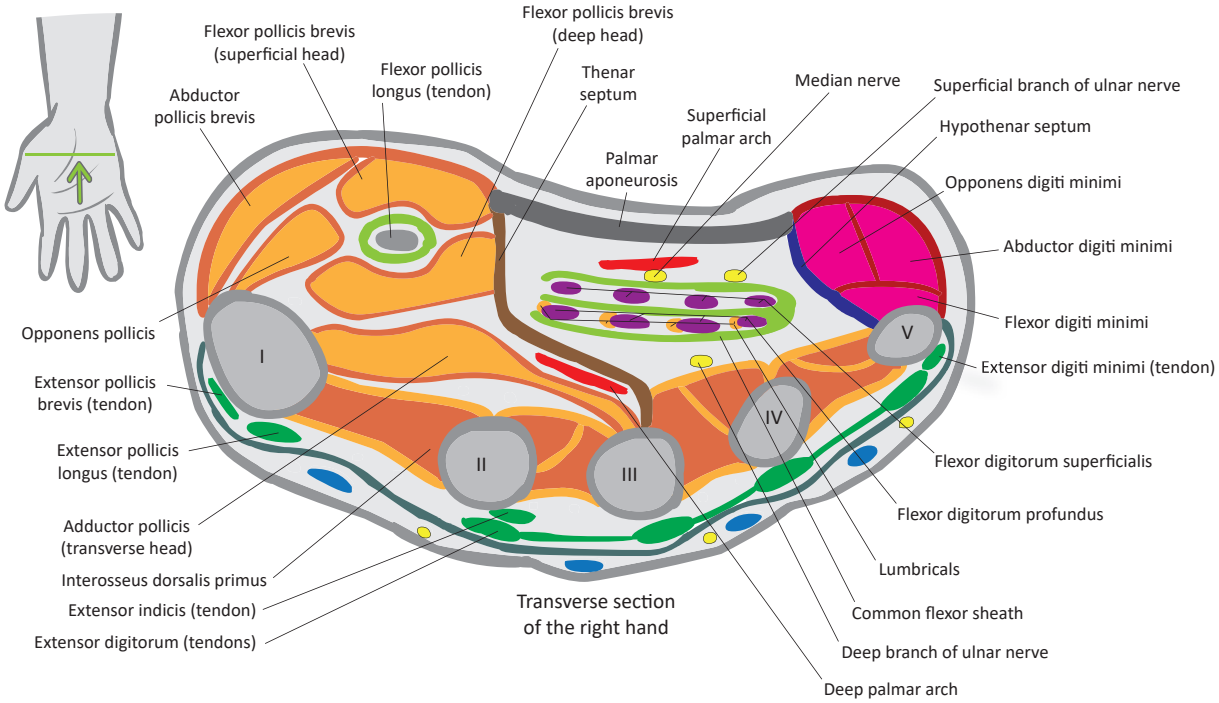

Transverse section of the right hand

This copy belongs to ali yaghoubi

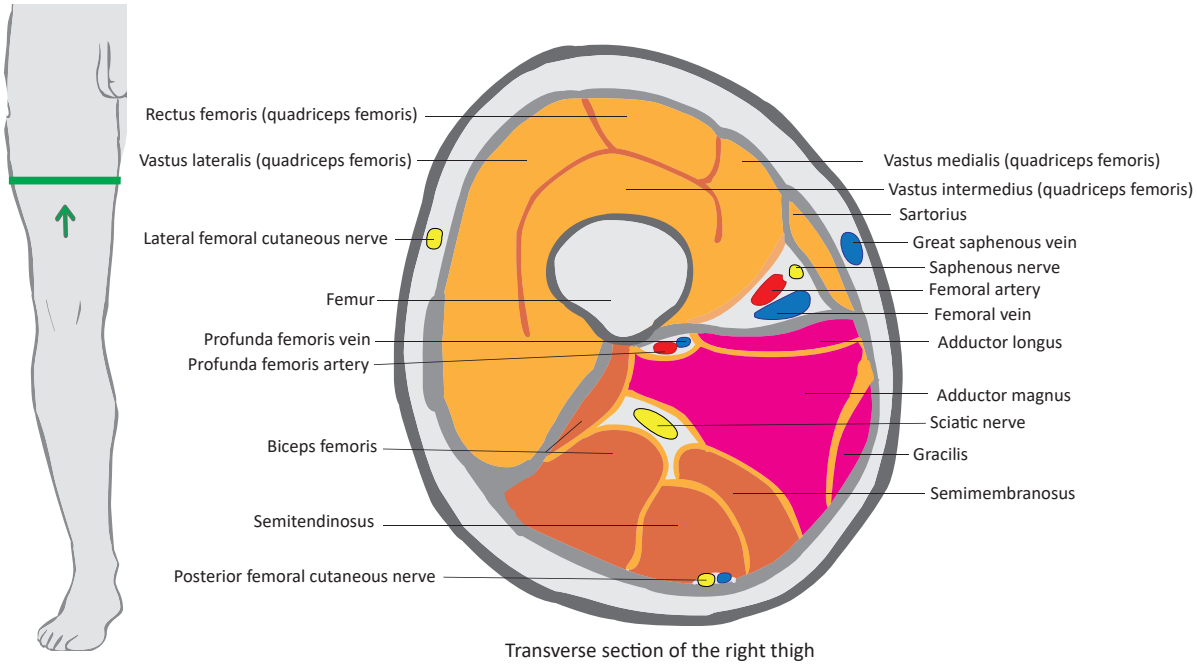

Transverse section of the right thigh

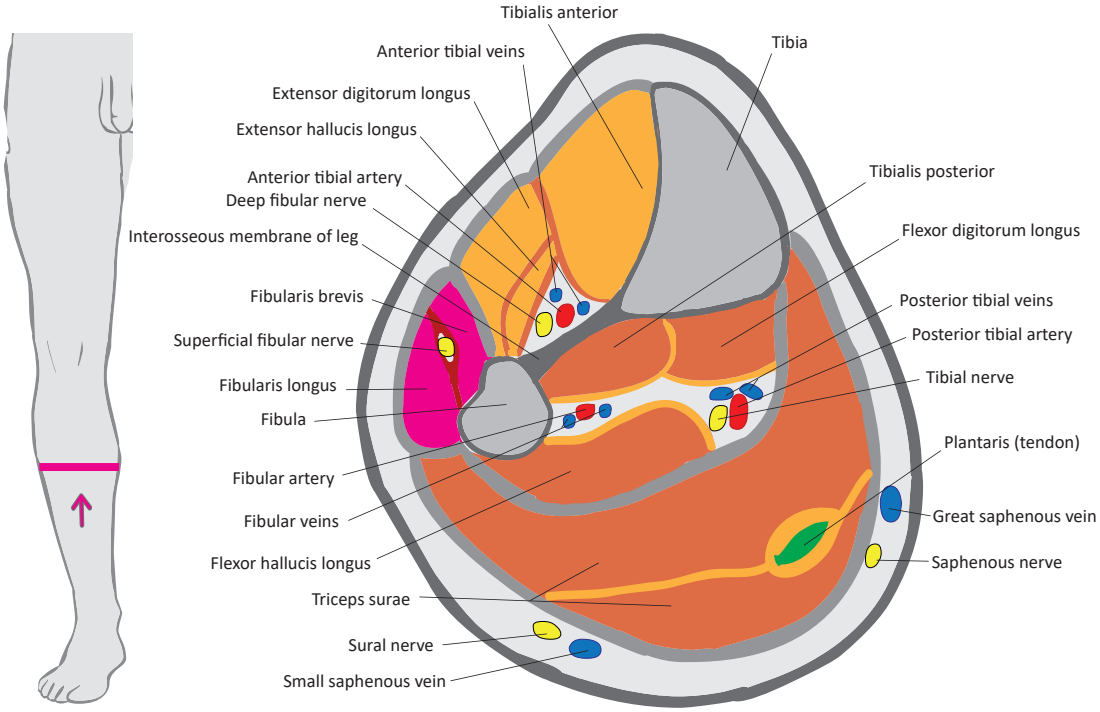

Transverse section of the right leg

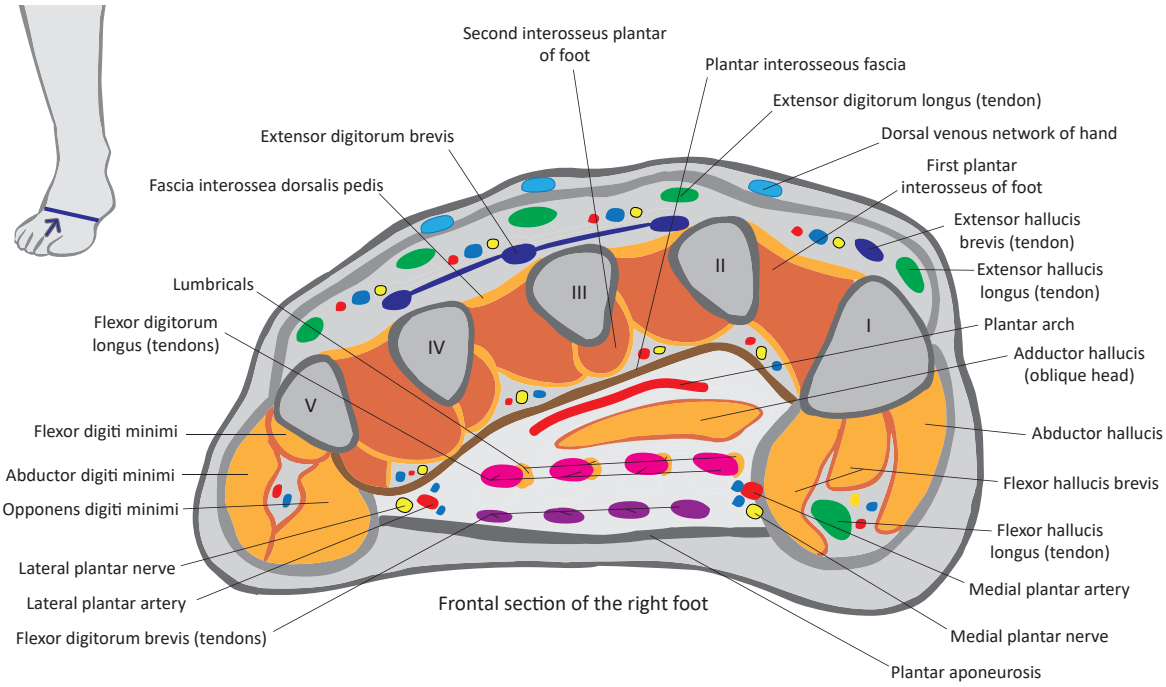

Frontal section of the right foot

10.1 Review questions and figures – Topography of the head

1. List the main openings through which the cranial cavity communicates with the nasal cavity, orbit, pterygopalatine fossa and infratemporal fossa. (p. 530)
2. State the name of the gland which duct pierces from the subcutaneous layer through the muscles and opens into the oral cavity. (p. 531)
3. Describe the medial border of the orbit. (p. 532)
4. List the content of the superior orbital fissure. (p. 532)
5. List 4 muscles that we can find in the mid-level of the orbit. (p. 533)
6. State the muscle that does not originate from the common tendinous ring. (p. 534)
7. Describe the quadrants of the internal acoustic meatus and their content. (p. 534)
8. Describe the borders of the tympanic cavity. (p. 535)
9. State the nerve that continues as the lesser petrosal nerve. (p. 535)
10. State the structures that pass through the petrotympanic fissure. (p. 535)
11. Describe the nasal septum and other structures that contribute to its structure. (p. 536)
12. State the paranasal cavity that opens into the inferior nasal meatus. (p. 536)
13. List the content of the jugular foramen. (p. 537)
14. State the openings through which the maxillary nerve passes. (p. 537)
15. Describe the borders of the infratemporal fossa. (p. 538)
16. State the space where we can find the sphenopetrosal synchondrosis. (p. 538)
17. List the content of the foramen spinosum. (p. 539)
18. Describe which nerves pass through the pterygopalatine fossa. (p. 539)
19. Propose an access to the pterygopalatine fossa. (p. 539)
20. State the segments of the infratemporal fossa. (p. 540)
21. List the arteries within the prestyloid space. (p. 541)

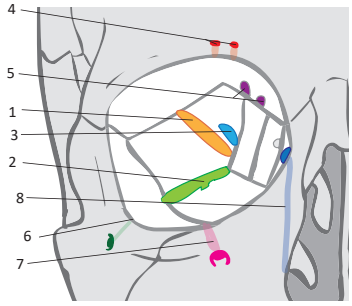

List the passages into the orbit

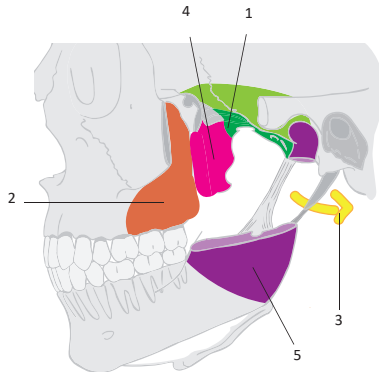

Describe the borders of the infratemporal fossa

This copy belongs to ali yaghoubi

1. Describe the organ projection at the C6 level (p. 542)
2. State the muscle which course divides the neck into regions. (p. 542)
3. List 4 parts of the anterior cervical region. (p. 542)
4. State the topographical site in which we can measure pulse on the carotid artery. (p. 542)
5. Describe the borders of the submandibular triangle. (p. 543)
6. State at what level according to the cervical part of the vertebral column the common carotid artery divides into the internal and external carotid arteries. (p. 543)
7. Describe which nerves run through the carotid triangle outside of the carotid sheath. (p. 543)
8. State the name of the artery that gives the facial artery. (p. 543)
9. Describe the main structure that we can find in the submental triangle. (p. 544)
10. Describe the borders of the muscular triangle. (p. 544)
11. State the structure that lies under the lesser supraclavicular fossa. (p. 544)
12. List the structures that pass through the scalene fissure. (p. 545)
13. Describe the structure of the carotid sheath and its content including the positions in the carotid sheath. (p. 547)
14. State the differences between the spaces of the neck and its triangles (p. 546)
15. List the spaces of the neck and the structure that divides them. (p. 546)
16. State the topographic site of the head that communicates with the paravisceral space. (p. 546)
17. List the 3 layers of the cervical fascia (p. 547)
18. List the structures that the superficial layer of the cervical fascia envelopes. (p. 547)
19. Describe the space in which the thyroid gland is located. (page 546)

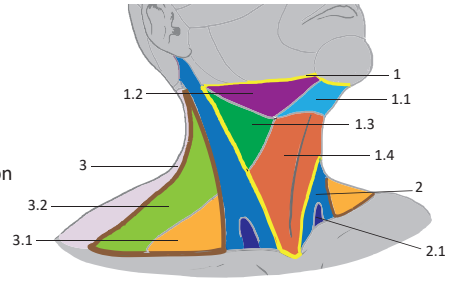

Describe the regions and the triangles of the neck

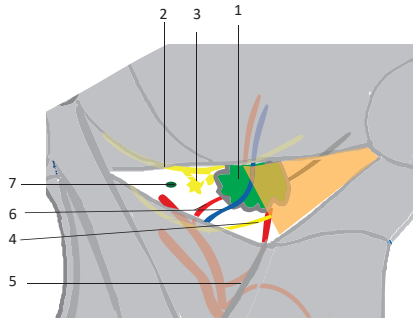

Describe the content of the submandibular triangle

10.3 Review questions and figures – Topography of the thorax

1. Describe the relationship between the mediastinum and the pleuroperitoneal space. (p. 548)
2. Describe the cranial border of the thorax. (p. 548)
3. Describe the external intercostal membrane. (p. 548)
4. List the 4 fasciae of the thorax. (p. 548)
5. State where we can find the fascia of Sibson. (p. 548)
6. List the structures within the intercostal neurovascular bundle in craniocaudal order. (p. 549)
7. State the organ projections at the T2 level. (p. 549)
8. Describe the most caudal point of the pleura. (p. 549)
9. Explain what the term mediastinum means and describe its location. (p. 550)
10. Explain the difference between the anatomical and clinical division of the mediastinum. (p. 550)
11. State the name of the structure dividing the anterior and posterior mediastinum of clinical division. (p. 550)
12. Order these structures in the superior mediatinum (oesophagus, trachea, superior vena cava, arch of aorta) ventrodorsally. (p. 551)
13. State the content of the inferior posterior mediastinum. (p. 551)
14. List the names of the nerves that join the oesophagus during its descent through the mediastinum. (p. 552)
15. Describe the course of the right recurrent laryngeal nerve. (p. 552)
16. List the structures that pass through the aortic hiatus. At what level according to the thoracic part of the vertebral column lies this hiatus. (p. 553)
17. Explain the relationship between the oesophagus and trachea. (p. 552)
18. List the openings in the diaphragm through which the phrenic nerves pass. (p. 553)
19. State the term of the internal thoracic artery and vein after they pass to the anterior abdominal wall. (p. 553)

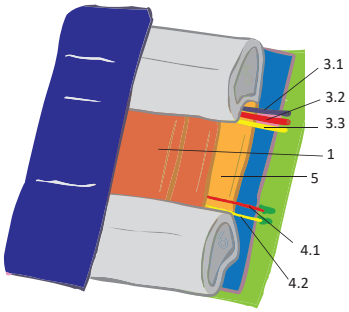

Describe the intercostal space

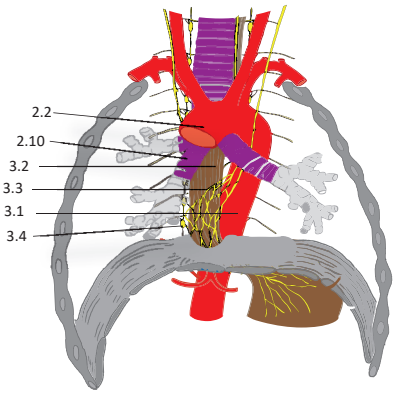

List the structures in the posterior mediastinum

1. State the anatomical and clinical regions of the abdomen. (p. 554)
2. Give the name of the organ that lies under the point of McBurney. (p. 554)
3. Describe the layers of the ventrolateral abdominal wall. (p. 555)
4. Explain the difference in the rectus sheath below and above the umbilicus. (p. 555)
5. State the structures that form the posterior part of the rectus sheath above the umbilicus. (p. 555)
6. Describe what the line of Douglas represents. (p. 555)
7. Explain the relationship between the inguinal ligament and the inguinal canal. (p. 556)
8. Describe what descends down the inguinal canal during the embryonic period in male. (p. 556)
9. Describe the walls of the inguinal canal. (p. 556)
10. State the nerves comprised within the inguinal canal. (p. 556)
11. Explain the structure of the superficial inguinal ring. (p. 557)
12. State the structure that is the base for the medial umbilical fold. (p. 558)
13. List all the places where a hernia can occur. (p. 558)
14. Explain the developmental origin of the secondary retroperitoneal organs. (p. 558)
15. State the primary retroperitoneal organs. (p. 559)
16. Describe the position of the omental bursa and its relationship to the transverse mesocolon. (p. 561)
17. List 3 branches of the abdominal aorta that supply organs of the peritoneal cavity. (p. 561)
18. Describe the ventral wall of the omental bursa. (p. 561)
19. State the content of the hepatoduodenal ligament. (p. 562)
20. Explain the purpose of the peritoneal attachments (mesos) for intraperitoneal organs. (p. 563)
21. State 3 peritoneal duplications of the liver. (p. 563)
22. Describe the position and components of the lesser omentum. (p. 563)

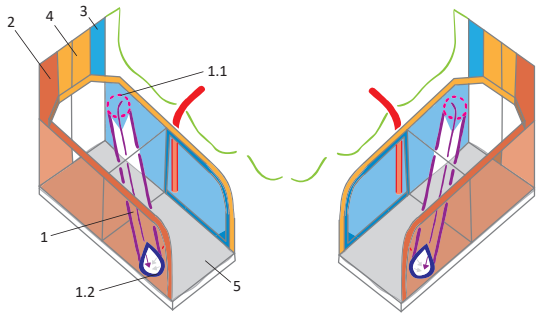

Describe the walls of the inguinal canal

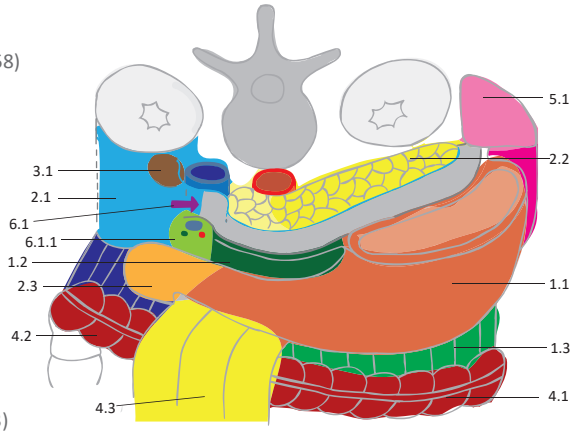

Describe the walls of the omental bursa

10.5 Review questions and figures – Topography of the pelvis and back

Topography of the pelvis

1. Describe the border between the greater and lesser pelvis. (p. 564)
2. Describe the deepest point of the male and female peritoneal cavity. (p. 564)
3. Describe the ways of examination of the space of Douglas. (p. 564)
4. Explain the relationship between the ovarian fossa and fossa of Claudius. (p. 564)
5. State the organs located in the lesser pelvis. (p. 565)
6. List 6 parts of the pelvic fascia. (p. 565)
7. State the structure found only in female within the genital lamina of the visceral fascia of the pelvis. (p. 565)
8. List the content of the male and female urogenital triangle. (p. 566)
9. Which muscle is located above the urogenital triangle? (p. 566)
10. Explain the term perineum. (p. 566)
11. The subcutaneous tissue of the perineum is a continuation of which layer of the abdominal wall? (p. 566)
12. Explain the term episiotomy. (p. 566)
13. State the nerve, artery and vein that run in the pudendal canal. (p. 567)
14. Describe the borders of the ischio-anal fossa. (p. 567)
15. List the structures that we can find in the scrotum. (p. 567)
16. Describe the structure of the scrotum wall. (p. 567)

Topography of the back

17. Explain the functions of the vertebral canal. (p. 568)
18. State in which topographical place we can find the vertebral artery. (p. 569)
19. List the two weakened points of the back. (p. 569).

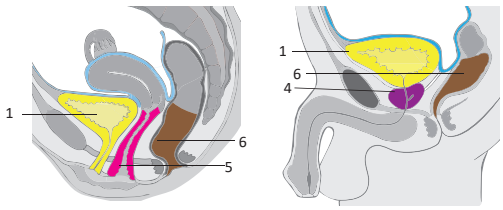

List the subperitoneal organs

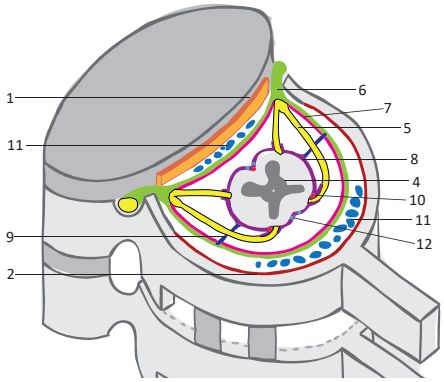

List the content of the vertebral canal

This copy belongs to ali yaghoubi

1. Describe the course of the brachial plexus and axillary vessels to the axilla. (p. 570)
2. State the ligament that spans across the suprascapular notch. (p. 570)
3. List the content of the suprascapular notch. (p. 570)
4. Describe which structures run together through the spinoglenoid notch. (p. 570)
5. Outline the borders of the axillary fossa. (p. 571)
6. List 7 branches of the axillary artery. (p. 571)
7. List 3 cords of the brachial plexus. (p. 571)
8. State the cord from which the median nerve originate. (p. 571)
9. State the muscles that outline the triangular space. (p. 572)
10. Give the nerve that runs in the quadrangular space. (p. 572)
11. Describe the topographic place and its borders through which the posterior circumflex humeral artery runs. (p. 572)
12. State the relationship between the clavipectoral triangle and infraclavicular fossa. (p. 572)
13. Explain the term osteofascial compartment. (p. 573)
14. List the content of the medial intermuscular septum of the arm. (p. 573)
15. State the artery and vein that make up a neurovascular bundle running with the radial nerve. (p. 573)
16. Outline the borders of the cubital fossa. (p. 574)
17. List 2 nerves that cross the cubital fossa. (p. 574)
18. Describe the branching of the brachial artery in the cubital fossa. (p. 574)
19. State the neurovascular bundle that supplies the posterior compartment of the forearm. (p. 575)
20. Explain how the ulnar nerve bypasses the cubital fossa. (p. 575)
21. Outline the borders of the pronator canal. (p. 575).
22. List the content of the supinator canal. (p. 575)
23. List 4 neurovascular bundles of the forearm. (p. 575)
24. Explain the term wrist and structures which it comprises. (p. 576)
25. Outline the borders of the anatomical snuff box. (p. 576)
26. State the topographical place at the wirst in which we can find the ulnar neurovascular bundle. (p. 576)
27. Explain the term carpal tunnel syndrome. (p. 577)
28. List 3 osteofascial compartments of the hand. (p. 577)
29. State the osteofascial compartment in which the deep palmar arch is located. (p. 577)

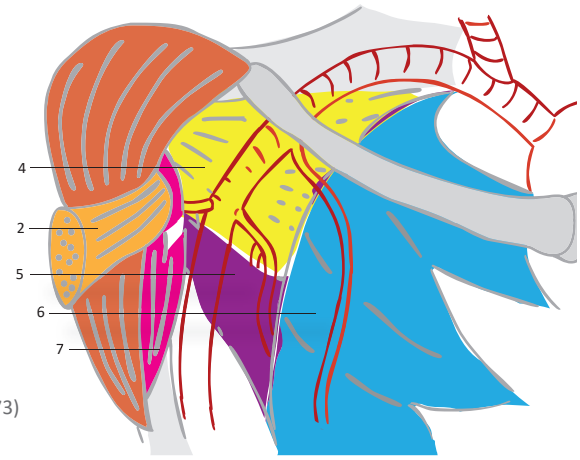

Outline the borders of the axillary fossa

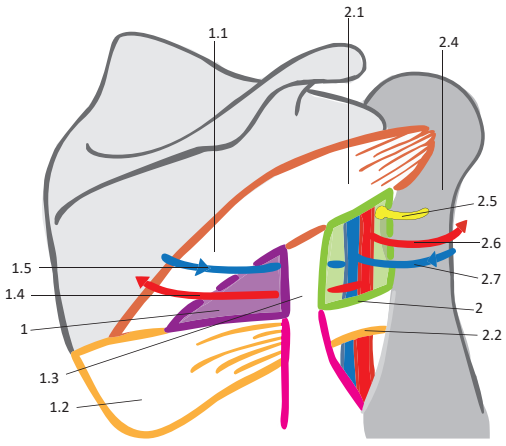

Describe the triangular and quadrangular space

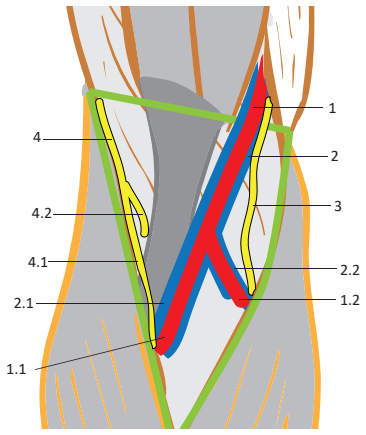

Describe the content of the cubital fossa

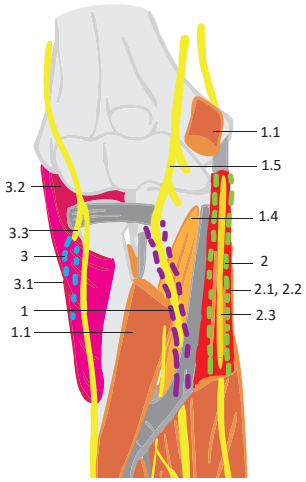

Describe the topographic canals of the forearm

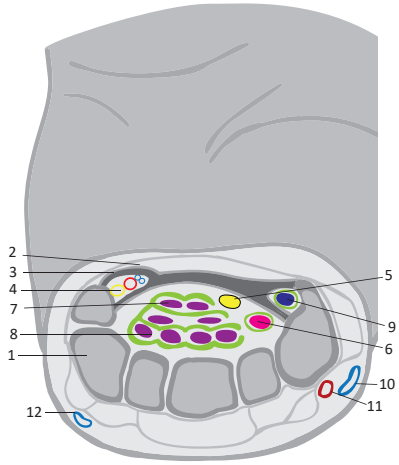

Describe the transverse section of the wrist

1. State 2 spaces through which the anterior compartment of the thigh communicates with the subperitoneal space. (p. 578)
2. State the ligaments that outline the greater sciatic foramen. (p. 578)
3. State the muscle that divides the greater sciatic foramen into the suprapiriform and infrapiriform foramina. (p. 578)
4. List the structures on the hip bone that outline the suprapiriform foramen. (p. 579)
5. Outline the borders of the infrapiriform foramen. (p. 579)
6. List 4 nerves passing through the infrapiriform foramen. (p. 579)
7. Outline the borders of the vascular space. (p. 579)
8. List 4 structures in the vascular space in the mediolateral order. (p. 579)
9. State the eponym for the inguinal ligament. (p. 579)
10. State the artery that runs through the muscular space. (p. 579)
11. Explain which group of muscles is supplied by the obturator nerve, artery and vein. (p. 580)
12. List 3 osteofascial compartments of the thigh. (p. 580)
13. State the topographic place through which the superficially running long saphenous vein pass into the depth. (p. 581)
14. Describe the course of the femoral artery through all topographical spaces of the lower limb (p. 581)
15. Describe the content and boundaries of the trigonum femorale. (p. 581)
16. Outline the borders of the popliteal fossa. (p. 582)
17. List the content of the popliteal fossa from the most superficial to the deepest structure. (p. 582)
18. Describe the branching of the sciatic nerve and possible places of the lower limb where its bifurcation can occur. (p. 582)
19. State 2 neurovascular bundles of the leg. (p. 582)
20. Explain the course and branching of the common fibular nerve in the fibular canal. (p. 583)
21. State what neurovascular bundle pass through the tendinous arch of the soleus. (p. 583)
22. Describe the borders of the musculofibular canal of Hyrtl. (p. 583)
23. State the nerve and the vein that run behind the lateral ankle. (p. 583)
24. List the content of the malleolar canal. (5) (p. 584)
25. State the nerve and the vein that run above the extensor retinaculum. (p. 584)
26. Explain the function of the longitudinal and transverse arch of the foot. (p. 585)
27. Explain the difference between the medial and lateral neurovascular bundles of the foot. (p. 585)

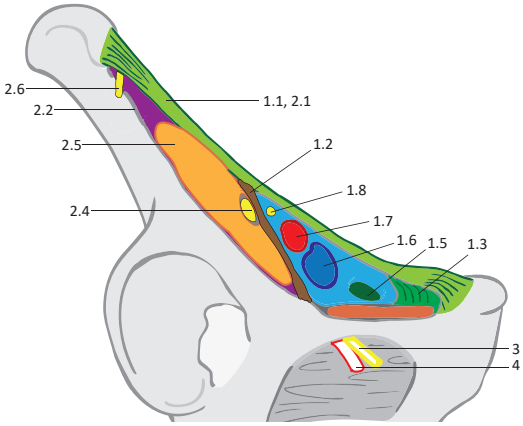

Describe the content of the vascular space, muscular space and obturator canal

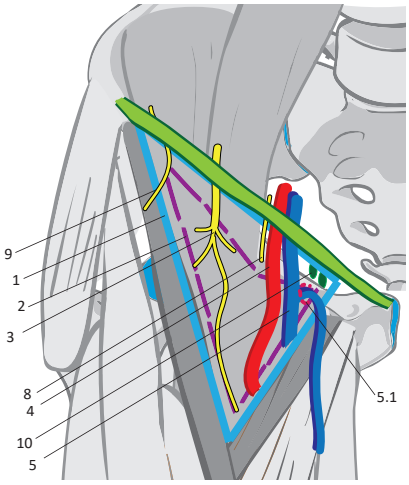

Describe the content of the femoral triangle and iliopectineal fossa

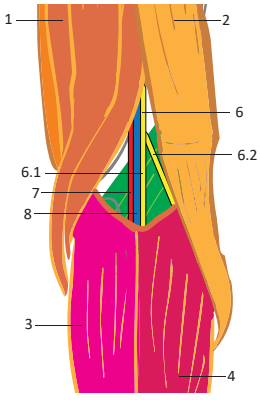

Describe the borders and content of the popliteal fossa

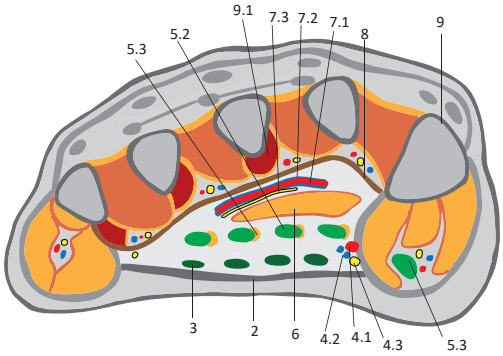

Describe the transverse section of the foot

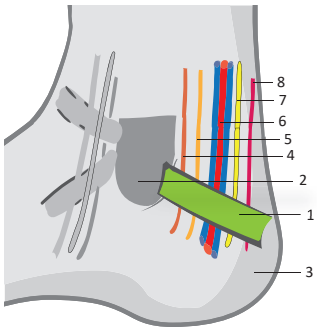

Describe the content of the malleolar canal

This copy belongs to ali yaghoubi

We would like to **thank the following anatomists, clinicians and medical students** for their invaluable help, devotion and feedback in the preparation of this chapter.

Anatomists

Assoc. prof. Václav Báča, MD, PhD – Department of Anatomy, Third Faculty of Medicine, Prague, Czech Republic
Assoc. prof. Květuše Lovásová, VDM, PhD – Department of Anatomy, Pavol Jozef Šafárik University, Košice, Slovakia
Georg Feigl, Univ.-Ass. OA Priv.-Doz. Dr.med.univ. – Medical University of Graz, Institute of Anatomy, Austria
Prof. Susana N. Biasutto, MD – Faculty of Medical Sciences, National University of Córdoba, Argentina
Quentin Fogg, PhD – Centre for Human Anatomy Education, Monash University, Melbourne, Australia

Clinicians

Eva Plaňanská, MD – Neurology Department, General University Hospital and Charles University in Prague
Aravind Ganesh, MD – Department of Neurology, Foothills Medical Centre and University of Calgary, Calgary, Canada

Medical students

Jakub Ivan Němec
Dominik Paugsch
Danil Yershov
James Sherrington
Daniel Slovák

11 References

1. ABRAHAMS, P. H.; SPRATT, J. D.; LOUKAS, M. and A. N. van SCHOOR. McMinn and Abrahams' Clinical Atlas of Human Anatomy: with Student Consult Online Access (Mcminn's Color Atlas of Human Anatomy). 7th Ed. Philadelphia: Mosby Elsevier, 2013, 388 p. ISBN 978-0723-43697-3.
2. AGUR, A. M. R. and A. F. DALLEY. Grant's Atlas of Anatomy. 13th Ed. Philadelphia: Lippincot Williams & Wilkins, 2012, 888 p. ISBN 978-1-60831-756-1.
3. CHUNG, K. W.; CHUNG, H. M. and N. L. HALLIDAY. BRS Gross Anatomy. 8th Ed. Philadelphia: Lippincott Williams & Wilkins, 2015. 544 p. ISBN 978-1-4511-9307-7.
4. DOYLE, J. R. and M. J. BOTTE, eds. Surgical anatomy of the hand and upper extremity. Philadelphia: Lippincott Williams & Wilkins, 2002, 721 p. ISBN 0-3975-1725-4.
5. LANZ, T. and W. WACHSMUTH. Praktische Anatomie. 7 bands. Berlin: Springer, 2003, 3658 p. ISBN 978-3-540-40571-9.
6. MOORE, K. L.; DALLEY, A. F. and A. AGUR. Clinically oriented anatomy. 7th Ed. Philadelphia: Lippincot Williams & Wilkins, 2014. 1139 p. ISBN 978-1-4511-1945-3.
7. NETTER, F. H. Atlas of Human Anatomy. Professional Edition. 6th Ed. Oxford: Elsevier. 2014. 640 p. ISBN 978-1-455-75888-3.
8. ROHEN, J. W. LUTJEN-DRECOLL, E. and C. YOKOCHI. Color Atlas of Anatomy: A Photographic Study of the Human Body. 7th Ed. Stuttgart: Lippincot Williams & Wilkins, 532 p. ISBN 978-1-58255-856-1.
9. SNELL, R. S. Clinical anatomy by regions. 9th Ed. Philadelphia: Lippincott Williams & Wilkins, 2012. 768 p. ISBN 978-1-60913-446-4.
10. TANK, P. W. Grant's dissector. 15th Ed. Philadelphia: Lippincot Williams & Wilkins, 2013, 288 p. ISBN 978-1-60913-606-3.
11. WILLIAMS, P. L., ed. Gray´s Anatomy: the anatomical basis of medicine and surgery. 38th Ed. New York: Churchill Livingstone, 1995, 2092 p. ISBN 0-443-05717-6.

A

abduction (movement) 71
acetabulum 51
acetylcholine (ACh) 477, 478
acinus (acini) 196
acromion 42, 43, 60
ACTH (adrenocorticotrophin) 527
actin 99, 100
adduction (movement) 71
adenohypophysis 523
adenoid (nasopharyngeal tonsil) 322
adhesion
 interthalamic 426, 469, 487
aditus
 laryngis 182, 210,
 mastoid 506
 orbitae 532
 pelvis 49
air sac (see alveolus) 217
air, paranasal sinuses 208, 536
ala(e)
 nasi 206
 majores ossis sphenoidalis 24
 ossis ilii 50
aldosterone 526, 527
allantois 528
allocortex 434
alveolar bone 174
alveolus (alveoli)
 dentales 174
 pulmonis 217
Alzheimer's disease
ampulla
 ductus deferentis 243
 hepatopancreatic 199
 recti 195
 urethrae 248
amygdala 440, 446, 447
anastomosis
 cavocaval, cavo-caval 264, 299, 312
 portocaval, porto-caval
  185, 299, 313
 magna 288
angina pectoris 274
angle (angulus)
 costae (rib) 41
 mandibular 34
 oris 173
 pubic 48
 sternal 41
ansa
 cervicalis superficilalis 340
 cervicalis profunda 341, 375
 subclavia 368
antagonists (muscle) 101
antrum
 mastoid 506
 pyloricum 186
anulus
 aorticus 273
 fibrosus 273
 inguinalis profundus 557
 inguinalis superficialis 557
 tympanicus 27
 umbilicalis 128
anus 195
aorta 277
 abdominal 287
 arch 277
 ascending 277
 thoracic 286
apertura
 aqueductus vestibuli 28
 canaliculi cochleae 29
 piriformis 207
 sinus sphenoidalis 24
 thoracis superior 41, 548
 thoracis inferior 41, 548
apex
 capitis fibulae 54
 cordis 267
 dentis 174
 linguae 176
 nasi 206
 orbitae 532
 ossis sacri 40
 prostatae 245
 pulmonis 216
 pyramidis 28
 patellae 53
 radicis dentis 174
appendix (-ces)
 epididymidis 238
 fibrosa hepatis 196
 testis 238
 vermiformis 193
aponeurosis
 linguae 177
 palatina 179
apparatus
 Golgi 4
 juxtaglomerular 228
 lacrimal 514
 vestibular 504, 507
appendix
 epididymal 238
 epiploicae 191
 testicular 238
 vermiform 191, 193
aqueduct
 cerebral 408, 468, 524
 cochlear 506
 vestibular 506
arachnoid mater 398, 471
arbor vitae 418, 486
arch(es)
 aortic 277
 cartilaginis cricoideae 211
 dentalis superior 175
 palmaris profundus 285
 palmaris superficialis 285
 plantaris 293
 palatoglossus 179
 palatopharyngeus 179
 costalis 41
 pubicus 48
 vertebrae 37
 zygomaticus 31
archicerebellum 420
archicortex 434
area(e)
 cortical (cerebral) 396, 435
 gastricae 187
 intercondylaris anterior 53
 intercondylaris posterior 53
 interpleuralis inferior 221
 interpleuralis superior 221
 nuda 197
artery(ies)
 alveolar (dental) 175, 281, 305
 appendicular 289
 arcuate 292
 auricular
  deep 281, 305
  posterior 278, 280
 axillary 284, 306, 571
 basilar 282, 472, 489,523
 bronchial 219, 286, 304
 buccal 281
 carotid
  common 277, 278,
   304, 472, 543, 547
  external 278–280, 304, 369,
   541, 543
  internal 278, 472–473, 489, 543
 cerebellar
  inferior 472, 476, 489
  superior 472, 489
 cerebral
  anterior 472–473, 489
  middle 472–473, 489
  posterior 472–473, 489
 cervical
  ascending 283, 305, 545
  deep 283, 305, 476, 545
  transverse 283, 305, 342, 545
 choroidal 472, 489,
 ciliares 511
 circumflex
  deep iliac 291, 309
  humeral 284, 306
  femoral 292, 309
  scapular 284, 306
  superficial iliac 292, 309
 colic 192, 289, 307
 coronary 275–277, 303
 cystic 199, 288, 307
 dorsalis pedis 293
 ductus deferentis 291
 epigastric
  inferior 290, 291, 309, 558
  superficial 292, 309
  superior 283, 553
 facial 278, 279, 304, 531, 543
 femoral 291, 292, 309, 579, 580
 fibular 293, 583, 594
 gastric 187, 288, 307
 gastroduodenal 187, 189, 288
 gastroepiploic/gastro-omental
  187, 288, 307
 hepatic
  common 187, 288, 307
  proper 196, 288, 298, 307, 589
 hypophysial 472, 523
 ileal 190, 289, 307
 ileocolic 190, 192, 289
 iliac
  common 290, 308
  external 290, 309
  internal 290, 308, 565
 iliolumbar 290, 308
 infraorbital 281, 532, 533, 539
 intercostal
  posterior 286, 304, 549
  supreme 283
 jejunal 190, 289, 307
 labial 173, 279
 labyrinthine 489, 506
 lacrimal 511
 laryngeal
  superior 211, 279
  inferior 211, 283
 lingual 180, 181, 279, 542
 lumbar 287, 308
 maxillary 278, 281, 305, 538, 539
 median 284
 medullary
 meningeal
  anterior 537
  middle 281, 359, 432, 537, 538
  posterior 279, 537
 mesenteric
  inferior 287, 289, 307
  superior 287, 289, 307
 metacarpal 285, 306
 metatarsal 293, 309
 musculophrenic 283
 nasal 281
 obturator 290, 308, 581
 occipital 278, 280
 ophthalmic 472, 511, 532, 534
 ovarian 250, 287, 291,
 palatine 208, 281
 pancreatic, greater 200, 288
 pancreaticoduodenal
  superior 171, 288, 307
  inferior 171, 289, 307
 penis 247, 291
 pericardiacophrenic 266, 283
 perineal 291
 pharyngeal
  ascending 278, 279, 541
 phrenic
  superior 286
  inferior 287
 plantar 293, 309
 pontine 472, 489
 popliteal 292, 309, 582
 princeps pollicis 284
 profunda brachii 284, 573, 592
 profunda femoris 292, 594
 profunda linguae 279
 pudendal
  externa 292, 309
  internal 291, 308
 pulmonary 219
 pyloric 187, 288
 radial 284, 285, 306, 574, 575
 radicular 476
 rectal
  inferior 192, 291
  middle 192, 291
  superior 192, 289
 recurrent
  ulnar 285, 306
  tibial 293
  radial 285, 306
 renal 228, 229, 287, 308
 retinal, central 354, 510, 511
 sacral median 287
 scapular dorsal 283
 sigmoid 289
 sinu-atrial nodal 275
 sphenopalatine 281, 305
 spinal 282, 476, 568,
 splenic 288, 307, 321
 subclavian 282–283, 284,
  305, 546, 570
 subcostal 286
 sublingualis 279
 subscapular 284
 supraorbital 532

This copy belongs to ali yaghoubi

suprarenal 526, 287
suprascapular 283
tarsal 293
temporal
  middle 280
  superficialis 280, 304
testicular 287
thoracic
  internal 283
  lateral 284
  superior 284
thoracoacromial 284
thoracodorsal 284
thyroid
  inferior 283, 525
  superior 279, 525
tibial 293
tympanic 279, 280
ulnar 285, 306
umbilical 291
urethral 291
uterine 291
vaginal 291
ventricular, anterior 275
vertebral 282
vertebrobasilar 282
vesical 291
arthroses 68
articulatio(joint) 68
 acromioclavicularis 76
 atlantoaxialis 74
 calcaneocuboidea 87
 costovertebrales 75
 coxae 83
 cricoarytenoidea 212
 cricothyroidea 212
 cubiti 78
 genus 84
 humeri 77
 intervertebrales 73
 manus 80
 pedis 87
 radiocarpalis 79
 sacroiliaca 82
 sternoclavicularis 76
 sternocostales 75
 subtalaris 87
 talocruralis 87
 tarsi transversa 89
 temporomandibularis 72
ataxia 422
astrocyt 391
atlas (C1 vertebra) 38
atrium (atria)
  of the lateral ventricle 469
  left 270
  right 268
auricle
 ear 505
 heart 268, 270
axilla 571
axis (C2 vertebra) 38
axon 390

B

baroreceptors 522
Barrett's oesophagus 170
barrier(s)
 blood-brain 390, 391, 468
basal nuclei/ganglia 391, 432, 439–441
base
 arytenoid cartilage 211
 cranial 21, 57
 lungs 216
 prostate 245
bile duct 198, 199
biliary colic 170
biliary tree 170, 196
bladder
 gall 199
 urinary 231–232
body (bodies)
 aortic 522
 carotid 522
 ciliary 510
 of gallbladder 199
 geniculate 424
 of incus 506
 of ischium 51
 mammillary 431
 of mandible 34
 of maxilla 33
 Nissl
 Pacchionian
 of pancreas 200
 para-aortic 522
 of penis 247
 perineal 256
 of pubis 51
 restiform 404
 of sphenoid bone 24
 of sternum 41
 vertebral 37
 vitreous 510
bone (general) 18–19
bone marrow 19, 320
brachium 10
brain (general) 390
brain stem 402
breast 517
breathing 221
bregma 36, 34
bridge
 nasal
Brodmann's (cortical) areas 435
bronchioles 217
bronchopulmonary segments 217
bronchoscopy 214
bronchospasm
bronchus (bronchi) 215
bud(s)
 limb 48, 100
 liver 171
 prostatic 238
 taste 502, 503
 ureteric 228
Budge's center 463
bulb / bulbus
 aortic 277
 hair 516
 internal jugular vein 295, 522
 olfactory 354, 503
 penis 247
 vestibule 255
bulla ethmoidalis 30
bursa(e)
 anserine 84
 gastrocnemius-semimembranosus 84
 infrapatellaris 84
 of calcaneal tendon 158
 omentalis (omental, omentis) 561
 praepatellaris 84
 subacromial 77
 subcutanea infrapatellar 84
 subcutanea preapatellar 84
 subdeltoidea 77
 subtendinous of subscapularis 77
 subtendinous of triceps brachii 78
 suprapatellar 84
 synovial 70, 71, 99

C

caecum 192
calcaneus 55
calcar calcanei 54
calvaria 21
calyx (calyces) renal 230
canal(s)
 adductor 581
 Alcock's (pudendal) 567
 alveolar 174
 anal 195
 carotid 29
 central (of spinal cord) 399, 470
 cervicis uteri 252
 cochlear 507
 Dorello's 360
 facial (Fallopian) 29, 361
 femoral 558
 Hunter's (adductor) 581
 incisive 33
 infraorbital 33
 inguinal 556
 mandibular 34
 nasolacrimal 514
 obturator 580
 optic 25
 palatine 32
 palatovaginal 538
 pterygoid 25
 root (radicular)
 sacral 40
 Schlemm (scleral venous sinus) 509
 semicircular 507
 spiral, of modiolus 507
 tarsal 584
 vertebral 568
 Volkmann's 19
canaliculus (canaliculi)
 bile 198
 chorda tympani 506, 535
 cochlear 29, 507
 innominatus 24
 lacrimal 514
 mastoid 27, 29
 tympanic 506, 535
 vestibular 28, 507
canines 175
cap duodenal 189
capillary (capillaries) 264
capitate 47
capitulum humeri 45
capsule(s)
 Bowman's 228
 extreme 439, 442
 fibrous (of joints) 70
 of Glisson 196
 internal 439, 442, 443
 of lens 510
 of liver 196
 of node 323
 renal 227
 splenic 321
 of suprarenal gland 526
 Tenon's
 of thyroid gland 525
 of tonsils 322
caput
 medusae 299
 succedaneum 530
cardia 186
carpal bones 47
carpus 47
cartilage (general) 68
 arytenoid 211
 corniculate 211
 costal 41
 cricoid 211
 cuneiform 211
 epiglottic 211
 laryngeal 211
 nasal 206
 of sternum 75
 thyroid 211
 of trachea 214
caruncle, lacrimal 514
cauda equina 398
caudate lobe 196
caudate nucleus 440
cavity (cavities)
 abdominal 559
 amniotic 258
 cranial 530
 dental 174
 glenoid 43
 laryngeal 210
 nasal 207
 oral 172
 orbital (see orbit) 532
 pelvic 564
 pericardial 265
 peritoneal 560
 pleural 220
 pulp, of teeth 174
 synovial 70
 thoracic 41
 tympanic 506, 535
cells (general) 4
cementum 174
cerebellum 418
cerebral hemisphere 432
cerebrospinal fluid 470
cerebrum 432
cerumen (ear wax) 515
cervix
 uterine 252
 vesical 231
chamber(s)
 anterior 511
 aqueous 511
 posterior 511
 vitreous 510
cheek(s) 172, 531
chiasma, optic 354
choanae 207
chordae
 tendineae 269, 271

tympanic 359
chorion 258
choroid (eye) 509
choroid plexus 470
cilia 516
ciliary body 509
cingulum 445, 448
circuit, Papez 423
circulation
fetal 274
portal 198
pulmonary 219, 265
system 264
circulus arteriosus
(circle of Willis) 473
circumduction 71
cirrhosis 170
cisterna(e) (cistern)
chyli 319
interpeduncular 470
of lamina terminalis 470
magna 470
pontine 470
postchiasmatic 470
prechiasmatic 470
subarachnoid 470
claustrum 440
clavicle 42
clitoris 255
clivus 23
cloaca 226
coccyx 40
cochlea 507
colic 191
collar bone 42
colliculus (colliculi)
facial 406
inferior 408
seminalis
superior 408
colon 191
column(s)
anal 195
cerebral cortex 434
renal 227
vaginal 255
vertebral 568
commissure(s)
of brain
anterior 443, 447
anterior grey 399
anterior white 391
of fornix 443, 446
habenular 425
posterior grey 399
posterior white 391
posterior 413, 425
labial (labia majora) 255
of heart valves 265, 270, 272
concha(e)
auricle 505
nasal 30
conducting system 273
condyles
femoral 52
humerus 44
occipitalis 23
tibial 53
cone(s)
confluens sinuum 475
conjunctiva 512
contraction, muscular 100
contracture 99, 100
conus
arteriosus 269
elasticus 212
medullaris 398
cord(s)
brachial plexus 342
spermatic 243
spinal 398
umbilical 258
vocal 210
cornea 509
cornu (cornua, cornus)
Ammonis 445
coccygeal 40
of hyoid bone 35
of lateral ventricles 469
sacral 40
of thyroid cartilage 211
corona
ciliaris 509
dental 174
of glans penis 247
radiata 442
corpus (corpora)
albicans 249
callosum 443
cavernosum (cavernosa) 247
geniculatum laterale 424
geniculatum mediale 424
luteum 249
pineale 425
spongiosum 247
striatum 440
uteri 252
corpuscle(s)
renal 228
cortex
cerebral 434
renal 227
ovarian 250
Corti, organ of 507
cranioschisis
cranium 21
crest or crista(e)
conchal 33
ethmoidal 32
frontal 22
galli 30
iliac 50
infratemporal 25, 415, 529
intertrochanteric 52
interureteric 231
lacrimal 31
nasal 32
neural 392
obturator 51
occipital 23
palatine 32
phallic 51
pubic 51
rib 41
sacral 40
sphenoidal 24
of greater tubercle 44
of lesser tubercle 44
supinator 45
supramastoid 27
supraventricular 269
temporal 34
terminalis 268
urethral 245
crown, of teeth 174
crus (crura)
ampullaris 507
of antihelix 505
cerebral 408
of clitoris 255
dextrum 127
of diaphragm 127
of fornix 355
of penis 247
sinistrum 127
crypt(s)
anal 195
intestinal 188
of Lieberkühn 188
tonsillar 322
cryptorchidism 556
cuboid bone 56
cuneiform bones 56
cupula
of diaphragm 127
pleural 220
curvatures
major 186
minor 186
prepubica 248
of spine 37
subpubica 248
cusp(s)
heart 272

D

decidua 175
decussation
lemniscal 404
pyramidal 402, 404
dendrit 56
dens axis 390
dentes 174
dentine 174
depression, mandibular 72
dermatom 350
dermis 515
desmocranium 20
diabetes mellitus 524
dialysis, peritoneal 564
diameter
obliqua 49
recta 49
transversa 49
diaphragm
muscle 127
oris 172
pelvis 131
sellae 471
diarthroses 68
diastole 272
diencephalon 424
digits
of foot (pedis) 56
of hand (manus) 48
diploë 531
disc(s)
articular 71
interpubic 82
intervertebral 73
optic 510
distantia
bicristal 48
bispinal 48
intertrochanteric 49
diverticulum (diverticula)
allantoenteric 230
Meckel's (ileal) 170
ureteric 228
dome of pleura 220
dopamine 477
dorsiflexion 71
dorsum
nasi 206
pedis 585
sellae 24
of tongue 176
drum, ear 505
duct(s) or ductus
alveolar 217
arteriosus 274
bile (biliary) 199
choledochus 199
collecting 228
cystic 199
deferens 242, 243, 565
ejaculatory 243
endolymphatic
epididymis 242
excretory 244
hepatic 199
lactiferous 517
lymphatic 319
Müllerian 226
nasolacrimal 208, 514
pancreatic 200
papillary 228
parotid 181
salivary glands 180
thoracic 319
venosus 274
Wolffian 226
ductules
aberrant 238
efferent 242
of testes 240
duodenum 188
Dupuytren's disease 146
dura mater 471
dysphagia 276

E

ear 504
echocardiography 276
ectocervix 252
ectoderm 5
efector 338
ejaculation 248
electrocardiography 276
elevation, mandibular 72
embryo 259
embryogenesis 5
eminence
arcuate 28
carpi radialis 47
carpi ulnaris 47

This copy belongs to ali yaghoubi

collateral 469
cruciformis 23
hypothenar 142
iliopubic 51
intercondylar 53
median 403, 430, 490
pyramidal 506
retropubica 49
thenar 142
enamel 174
encephalon 390
endocardium 265
endoderm 5
endolymph 506
endometrium 252
endomysium 99
endoneurium 336
endoplasmic reticulum 4
endosteum 19
endothelium 4
ependyma 468
epicanthus
epicardium 265
epicondylus
medialis femoris 52
medialis humeri 45
lateralis femoris 52
lateralis humeri 45
epidermis 516
epididymis 242
epigastrium 554
epiglottis 211
epilepsy 390
epimysium 99
epiphyses 18
episiotomy 256
epispadias 248
epithalamus 425
epithelium 4
eponychium 517
erection 248
eruption, of teeth 175
erythropoiesis 320
erythropoietin 228
ethmoid bone 30
excavatio rectouterina 254
exitus pelvis 49
exophthalmos
expiration 221
extremitas
acromial 42
sternal 42
eye and eyeball 508
eyebrows 516
eyelashes 516
eyelids 512

F

fabella 158
face 9
facies
anterolateralis (humeri) 44
anteromedialis (humeri) 44
articularis
acromialis (claviculae) 42
acromii (scapulae) 43
calcanearis anterior 55
calcanearis media 55
calcanearis posterior 55
carpalis (radii) 46
cuboidea 56
fibularis 53
inferior 53
malleoli lateralis 54
malleoli medialis 53
talaris anterior 55
talaris media 55
talaris posterior 55
tuberculi costae 41
auricularis ossis iliii 50
ossis sacri 40
cerebralis 25
dorsalis (sacri) 40
glutea 50
infratemporalis allae majoris 24
maxillae 25
intervertebralis 37
lateralis ossis
zygomatici 31
radii 46
tibiae 53
lunata acetabuli 51
maxillaris 32
medialis (ulnae) 45
(tibiae) 53
nasalis (corporis maxillae) 33
(ossis palatini) 32
orbitalis (alae majoris) 25
(corporis maxillae) 33
(ossis frontalis) 22
(ossis zygomatici) 31
patellaris 52
partis petrosae 28
pelvica 40
poplitea 52
posterior (fibulae) 54
facies posterior (humeri) 44
(partis petrosae) 29
(radii) 46
(scapulae) 43
(tibiae) 53
(ulnae) 45
sacropelvica 50
superior (tibiae) 53
symphysialis 51
temporalis (alae majoris) 25
(ossis zygomatici) 31
facet 68, 70
Fallot's tetralogy
falx
cerebelli 471
cerebri 471
inguinalis 557
fascia
abdominal 130
antebrachii 147
axillaris 147
brachii 147
buccopharyngea 109
cervicalis 115
clavipectoralis 127
cribrosa 165
cruris 165
deltoidea 147
diaphragmatica 127
diaphragmatis pelvis inferior 132
pelvis superior 132
dorsalis manus interossea 147
manus intertendinea 147
manus superficialis 147
dorsalis pedis interossea 165
pedis superficialis 165
endoabdominal 130
endopelvic 132
endothoracic 127
glutea 165
iliopectinea 165
lata femoris 165
manus 147
masseterica 109
nuchae 123
palmaris interossea 147
palmaris superficialis 147
parotidea 109
parotideomasseteric 109
pectinea 165
pectoralis superficialis 127
pedis 165
pelvis parietalis 132
perinei superficialis 132
plantaris 165
plantaris interossea 165
poplitea 165
Scarpae 130
spermatica externa 246
spermatica interna 246
subcutanea 130
superficialis dorsi 123
temporal 109
thoracic 127
thoracolumbal 123
transversal 130
umbilical 130
fascicle(s)
of atrioventricular bundle 273
of cochlear nerve 362
of olfactory neurones 354
subendocardial 273
vestibulocochlear 362
fasciculus (fasciculi)
cuneatus 399
fronto-occipital 443
gracilis 399
intrafusal 101
lenticularis 425
longitudinal 74
medial longitudinal 413
proprii 400
subcallosal 442
subthalamic 425
tegmental, central
thalamic 425
uncinate 442
fastigium 469
fat pads
articular 71
acetabular 83
infrapatellar 84
fauces
isthmus of 172
femur 52
fenestra(ae)
cochleae (rotunda) 506
vestibuli (ovalis) 506
α-fetoprotein
fetus 259
fibre(s)
muscle 98
nerve 336
olivocerebellar 423
Sharpey's 19
fibrae intercrurales 557
fibrocartilago navicularis 87
palmaris 81
plantaris 88
fibula 54
field(s)
of Forel (subthalamic) 424, 425
frontal eye (FEF) 436
'H', of Forel 424, 425
nail 159
supplementary eye (SEF) 664
visual 437
fila olfactoria 354
fimbria(e)
of fornix
of hippocampus 444, 445
ovarian 250
of uterine tube 251
fissure(s)
anal 195
azygos 218
of cerebellum 418
of cerebral hemisphere 432
great longitudinal 432
hepatic 197
interlobar (lung) 217
lateral (Sylvian) 435
for ligamentum teres hepatis 197
for ligamentum venosum 197
median 401
orbital
superior 532
inferior 532
palpebral 510
petrosquamos 27
petrotympanic 27
pterygomaxillary 538
scalenorum 545
tympanomastoidea 27
tympanosquamosa 27
fistula
recto-vaginal 254
tracheo-oesphageal 214
flexion (movement) 71
flexure(s)
cervical 393
colic
left (splenic) 194
right (hepatic) 193
duodenal 188
duodenojejunalis 188
mesencephalic 393
perineal, of rectum 195
pontine 393
sacral, of rectum 195
flocculus 418
fold(s)
alar, of knee 84
aryepiglottic 210
duodenal 189
genital 255
glossoepiglottic 176
horizontal, of rectum 195
infrapatellar 84
inter-ureteric 231
nail 516
nasolabial 172
palatoglossal 178

palatopharyngeal 178
peritoneal 563
recto-uterine 564
rectovaginal 564
of rectum 195
of stomach (magenstrasse; rugae) 187
sublingual 176
synovial, of elbow joint 78
umbilical 558
ureterovesical 231
vestibular 507
folia of cerebellum 418
follicle(s) 249
fontanelle(s) 35
fonticulus anterior 35
posterior 35
foramen (-ina)
alveolaria 33
caecum 22, 176
cribrosa 30
emissary 25
epiploic (of Winslow) 561
ethmoidal
anterius 30
posterius 30
frontal 22
genial (lingual) 176
humerotricipitale 572
incisive 33
infraorbital 33
infrapiriforme 579
intervertebral 37
ischiadicum
majus 578
minus 578
jugular 23, 28
lacerum 28
of Luschka 469
of Magendie 469
magnum 23
mandibular 34
mastoid 29
mental 34
nasale 31
nutricium femoris 52
humeri 44
obturator 51
omotricipitale 572
ovale 25
palatine lesser 32
palatinum greater 32
parietal 26
petrosum 25
processus transversi 37
rotundum 25
sacral posterior 40
sphenopalatine 32
spinosum 25
stylomastoid 29
supraorbital 22
suprapiriforme 579
transversarium 38
venae cavae 553
venosum 25
vertebral 37
of *Vesalius 24*
zygomatico-facial 31
zygomatico-orbital 31
zygomatico-temporal 31
forebrain (see prosencephalon) 393
foreskin (see prepuce) 247
formation (formatio)
hippocampal 445
reticular 414
fornix (fornices)
of brain 446
humeri 76
vaginal 254
fossa (-ae)
acetabular 51
axillar 571
canine 33
cerebellar 23
cerebral 23
condylar 23
coronoidea 45
cranial
anterior 537
media 537
posterior 537
digastric 34
glandulae lacrimalis 22
hypophysial 24
iliac 50
iliopectinea 581
infraspinous 43
infratemporal 538
inguinal
lateralis 558
medialis 558
intercondylar 52
ischioanal 567
fossa jugularis 29
malleoli lateralis 54
mandibular 34
olecranon 45
ovale 268
ovarian 546
poplitea 582
pterygoidea 25
pterygopalatine 539
radial 46
sacci lacrimalis 31
scaphoidea 25
subarcuate 28
subscapular 43
subtrochanteric 52
supraclavicular
major 544
minor 544
supraspinous 43
supravesical 558
temporal 537
trochanteric 52
fossula petrosa 29
fovea(ae)
articularis (radii) 46
capitis femoris 52
costal 41
costal
inferior 41
processus transversi 41
superior 41
dentis 38
pterygoidea 34
sublingual 34
submandibular 34
trochlear 22
foveola radialis 46
frenulum (frenula)
clitoris 255
of ileocaecal valve 192
of labia minora 255
of labia minora 255
labial 173
lingual 176
of penis 247
of prepuce 247
frontal bone 22
frontal plane 8
fundus
gallbladder 199
meatus acustici interni 507
of stomach 186
uterus 252
funiculus
of medulla oblongata, ventral 404
separans 403
of spinal cord 399
spermaticus 243

G

GABA (gamma-aminobutyric acid) 478
galea aponeurotica 103
gallbladder 199
gallstones198
GALT (gut-associated lymphoid tissue) 522
ganglion (ganglia)
accessory nerve 366
aorticorenal 502
autonomic 367
cranial 371
basal 439
cervicale 368
cervicothoracic 368
ciliary 355
cochlear 362
coeliac 373
enteric 374
geniculate 361
inferior 365
lumbar 368
mesenteric 373
otic 371
parasympathetic 371
pterygopalatine 371
sacral 368
spinal 337
spiral 362
splanchnic 374
stellate 368
submandibular 359
superior 364
sympathetic 368
thoracic 369
trigeminale *Gasseri* 356
vestibular (Scarpa's) 362
vestibulocochlear 362
geniculum nervi facialis 361
genu 84
gingiva 172
ginglymus 69
girdle(s)
shoulder/pectoral 42
pelvic 48
glabella 22
gland(s)
adrena 562l
anal 195
apocrine 515
Bartholin's (greater vestibular) 255
Brunner's (submucosal) 188
buccal 172
bulbourethral 244
ceruminous 505
ciliary 512
endocervical 252
endocrine 515
epicrine (merocrine) 515
exocrine 515
gastric 186
holocrine 515
intestinal (crypts) 188
labial 173
lacrimal 514
lingual 176
Meibomian 512
merocrine 515
of Moll 512
of Montgomery (areolar) 517
oesophagus 185
palatine 173
parotid 181
parathyroidea 525
pineal 524
pituitary 523
preputial 247
pyloric 186
Skene's
sublingual 180
submandibular 181
suprarenal 526
thyroid 525
vestibular, greater 255
of Zeis 512
glans
clitoris 255
penis 247
glenoid 43
glia 391
Glisson, capsule of 196
globus pallidus 440
glomera aortica 502
glomerulus (glomeruli)
cerebellum 419
renal 228
glomus caroticum 502
glucagon 478
glutamate 478
glycogen 524
gomphosis 68
gonads 238
granulations, arachnoid 471, 475
grey matter 391
groove(s)
atrioventricular (coronary) 267
buccolabial 173
carpal 47
caval, of liver 196
costal 41
deltopectoral 572
gingival 173
for greater petrosal nerve 24
for inferior petrosal sinus 24
for vena cava 197
infraorbital 33
interventricular 267
nasolabial 173
neural 393
subclavian 41
for subclavius 42
for superior petrosal sinus 28
for superior sagittal sinus 23

This copy belongs to ali yaghoubi

for superior vena cava 218
for transverse sinus 23
gubernaculum 238
gyri cerebri 433

H

habenula 425
haemorrhoids 194
haemothorax 220
hair 516
hallux 10
hamate bone 47
hamulus
of hamate 47
lacrimal 31
pterygoid 25
haustra of large intestin 190
heart 266
helicotrema 507
helix 505
hemiplegia 410
hemisphere 432
hepar 196
hernia 558
herpes
hiatus
adductor 581
aortic 553
maxillar 32
oesophageus 553
sacral 40
saphenus 301
semilunaris 208
urogenital 566
hilum (hila; hilus)
of kidney 227
of lung 216
of ovary 250
of testis 240
hinge 69
hip joint 83
hippocampus 445
histamine 478
homunculus 456
hordeolum 512
horns
Ammon's 445
of lateral meniscus 84
of lateral ventricle 469
of medial meniscus 84
humerus 44
humour
aqueous 511
vitreus 510
hydrocephalus 470
hymen vaginae 255
hyoid bone 35
hyponychium 515
hypopharynx 182
hypothenar 577
hypophysis 523
hypospadias 248
hypothalamus 430
hysteroscopy 252

I

ileum 190
ilium 51
impression
of liver 218
of spleen 218
of stomach 218
trigeminal 28
Inca bone 22
incisura (ae)
angularis 186
acetabuli 51
cardiaca 186
clavicularis sterni 76
costales 41
fibularis 53
frontalis 22
ischiadica
major 51
minor 51
jugularis
ossis occipitalis 23
ossis temporalis 28
sterni 41
lacrimalis 33
mandibulare 34
mastoidea 29
radialis ulnae 45
scapulare 43
sphenopalatina 32
supraorbital 22
thyroid 21
trochlearis 45
tympanic 27
ulnaris radii 46
vertebral
inferior 37
superior 37
incus 506
index (indices) 10
infundibulum
of ethmoidal bone 30
of hypophysis 523
of hypothalamus 430
of right ventricle 269
of uterine tube 251
insertion, of muscles 99
inspiration 221
insula (lobus insularis) 433
insulin 524, 527
intestine 170
introitus 524
iris 508
ischium 51
islet, of Langerhans 524
isthmus
aortic 274
of cervix uteri 252
faucium 172
uterine tube 251

J

jaw 174
jejunum 190
jelly 258
joints (general) 70
joints
acromioclavicular 76
ankle 86
atlanto-axial 74
atlanto-occipital 74
calcaneocuboid 86
carpal 80
carpometacarpal 80
chondrosternal 75
costotransverse 75
costovertebral 75
craniovertebral 74
cricoarytenoid 212
cricothyroid 212
cuboideonavicular 87
cuneocuboid 87
elbow 78
glenohumeral 77
hip 83
intercarpal 80
interchondral 75
intercuneiform 87
intermetacarpal 80
intermetatarsal 87
interphalangeal 80
intervertebral 74
knee 84
mandibular 72
manubriosternal 75
metacarpal 80
metacarpophalangeal 80
metatarsophalangeal 87
midcarpal 80
patellofemoral 84
radio-ulnar 78
radiocarpal 80
sacroiliac 82
sternoclavicular 76
sternocostal 75
symphysis 82
talocalcaneal 86
talocalcaneonavicular 86
talocrural 86
tarsal 86
tarsometatarsal 87
temporomandibular 72
tibiofibular 86
zygapophysial 74
juga alveolaria 33
junction(s)
anorectal 195
atrioventricular 267
cartilaginea 68
corneoscleral 510
corticomedullary 227
dermo-epidermal 515
gastro-oesophageal 185
ileocaecal 192
pharyngo-oesophageal 184

K

kidney 227
knee 84
kyphosis 37

L

labium (labia)
majus (majora) 249
minus (minora) 249
labrum (labra)
acetabular 83
articulare 69
glenoid 77
labyrinth(s)
bony 507
ethmoidal 30
membranous 507
lacertus fibrosus 135
lacrimal bone 31
lactation 517
lacuna(ae)
of bone 19
musculorum 579
vasorum 579
lamella(ae)
of bone 19
lamina(ae)
affixa 426
basal 4
cribrosa 30
cribrosa sclerae 509
Descemet's 506
fusca 509
horizontalis osssis palatini 32
lateralis processus pterygoidei 25
limiting 509
medialis processus pterygoidei 25
of palatine bone 32
papyracea 30
Rexed's 401
of superior colliculus 408
terminalis 468
vastoadductoria 581
larynx 210
layer(s)
anterior border, of iris 509
Bowman's 509
of cerebellar cortex 434
choriocapillaris
dartos 246
derma 515
granular, of cerebellar cortex 419
retinal 510
of scalp 531
of skin 515
lemniscus
lateralis 465
medialis 451
trigeminal 409, 451
lens 508
lien 321
ligamentum(a)
acetabular 62, 83
acromioclavicular 76
anular radii 78
anococcygeal 131, 591
arcuate 54, 82, 85
arteriosum 274, 303
aryepiglottic 210
calcaneocuboid 55, 86, 87, 89
calcaneonavicular 87, 89
capitis costae 75
cardinal 253
cervical 253
conoideum 76
coracoacromiale 76
coracoclavicular 43, 76
coracohumeral 77
coronary 563
costoclavicular 76
costotransverse 74, 75
costoxiphoid 74
cricoarytenoid 212, 213
cricothyroid 212

cricotracheal 212
cruciate
  anterius 85
  posterius 85
cruciform 74
deltoid 87
denticulatum 398
flavum (interarcualia) 73
fundiform 247
gastrocolic 187
gastrohepatic 187
gastrophrenic 187, 201
gastrosplenic 187
glenohumeral 77
hepatocolic 193
hepatoduodenal 562
hepatogastric 197, 201
hepatorenale 561
hyoepiglottic 212
iliofemoral 83
iliolumbal 130
inguinal 128
interspinous 73
intertransversaria 73
ischiofemorale 83
lacunar 579
latum uteri 253
Lisfranc's 86
longitudinal
  anterius 73
  posterius 73
of Mackenrodt 253
mandibulostylohyoid 108
palmar 79, 81
palpebral 105
patellae 85
pterygomandibular 72
pterygospinal 24
pubic
  inferius 82
  superius 82
pubofemoral 83
reflexum 557
sacrospinal 82
sacrotuberal 82
stylohyoideum 72
stylomandibulare 72
teres
  uteri 253
  hepatis 196
transversum
  acetabuli 83
  atlantis 74
  genus 85
  scapulae inferius 570
  scapulae superius 570
trapezoideum 76
umbilical 231
venosum 197
vestibular 210
vocal 210
limbus acetabuli 51
limen nasi 207
line(s) (linae)
 alba 128
 Andresen
 arcuate 49, 50, 555
 aspera 52
 'bloodless', of Brödel 228
 dentate 195
 gluteal 50
 intercondylaris 52
 intertrochanterica 52
 mylohyoid 34
 nuchal 23
 pectinate 194, 195
lingual bone 35
lingula 216
lip(s) 173
liver 196, 197, 198
lobe(s)
 of cerebellum 418
 of cerebral hemispheres 432
 frontal 432
 of liver 196
 of lungs 217
 occipital 432
 parietal 432
 of prostate 245
 temporal 432
 of thymus 320
 of thyroid gland 525
lobule(s)
 of auricle 505
 of carotid body
 central, of cerebellum 418
 of kidney 227
 of liver 196
 of lungs 217
 of mammary gland 517
 paracentral, of cerebral hemisphere 436
 of parietal lobe 433
 posterior biventral,
  of cerebellum 418
 of testis 240
lordosis 37
lunate bone 47
lung(s) 216–219
lymph 318
lymphatic vessels 319
lymph nodes 323
lymphoedema 323
lymphography 318
lymphoid follicles
lymph trunk 319

m

macula(e)
  cribrosa 507
  densa 228
  of eye 508
  of inner ear 507
  of saccule 507
  of utricle 507
malleolus 53, 54
malleus 506
MALT (mucosa-associated
  lymphoid tissue) 522
mandible 34
manubrium of sternum 41
margin
 infraorbital 33
 lambdoideus 23
 supraorbital 22
marrow, of bone 320
mass laterales 38
mater
 arachnoid 471
 dura 471
 pia 471
matrix of bone 19
matter
 grey 391
 white 391
maxilla 33
meatus
 acoustic external 27
 acoustic internal 507
 nasal communis 208
 nasal inferior 208
 nasal medius 208
 nasal superior 208
 nasopharyngeus 208
Meckel's diverticulum 170
mediastinum 550
medulla
 oblongata 404
 spinalis 398
membrane (membrana)
 atlanto-ocipital 38
 buccopharyngeal 540
 cricothyroid 212
 intercostal 75
 obturator 82
 synovial 70
 tectoria 507
meninges 471
meniscus
 articularis 71
 lateralis 85
 medialis 85
mesencephalon (midbrain) 408
mesenchyme 5
mesentery 188
mesoappendix 563
mesocolon 563
mesoderm 5
mesogastrium 562
mesometrium 253
mesonephros 226
mesorectum 563
mesosalpinx 253
mesosigmoid 563
mesovarium 253
metacarpal bones 47
metatarsal bones 54
metathalamus 424
midgut 171
miosis 509
mitochondria 4
modiolus 531
molars 173
mons pubis 253
Morton's neuroma 56
mouth 172
musculus(i) (muscles)
 of abdomen 128
 biceps
  brachii 135
  femoris 155
 brachialis 135
 brachioradialis 139
 buccinator 107
 coracobrachialis 135
 cremaster 129
 deltoideus 133
 digastricus 112
 epicranius 103
 fibularis brevis 157
  longus 157
gastrocnemius 158
geniohyoideus 112
gluteus
  maximus 150
  medius 150
  minimus 150
gracilis 154
hyoglossus 177
iliacus 149
iliococcygeus 131
iliocostalis 120
iliopsoas 148
infraspinatus 133
intercostales externi 126
  interni 126
  intimi 126
latissimus dorsi 117
levator anguli oris 107
  ani 131
  labii superioris 106
  scapulae 116
longus capitis 115
  colli 115
lumbricales manus 145
  pedis 163
masseter 108
mentalis 107
multifidi 122
mylohyoideus 112
obturatorius externus 155
  internus 151
occipitofrontalis 103
omohyoideus 113
opponens pollicis 143
  digiti minimi 144
orbicularis
  oculi 105
  oris 106
palmaris brevis 144
  longus 137
pectineus 154
pectoralis major 125
  minor 125
piriformis 151
plantaris 158
procerus 105
pronator teres 137
  quadratus 138
popliteus 159
psoas major 149
  minor 149
pterygoideus
  lateralis 109
  medialis 109
pubococcygeus 131
puborectalis 131
pyramidalis 128
quadratus femoris 151
  lumborum 130
  plantae 162
quadriceps femoris 153
recus
  abdominis 128
  capitis anterior 115
  capitis lateralis 115
  femoris 153
rhomboidei 118
risorius 107
sartorius 153
scaleni 114
scalenus anterior 114

This copy belongs to ali yaghoubi

medius 114
minimus 114
posterior 114
semimembranosus 155
semispinalis capitis 121
cervicis 121
thoracis 121
semitendinosus 155
serratus anterior 125
posterior superior 118
posterior inferior 118
soleus 158
sphincter ani externus 195
splenius capitis 119
cervicis 119
stapedius 506
sternocleidomastoideus 111
sternohyoideus 113
sternothyroideus 113
stylohyoideus 112
subclavius 125
subscapularis 134
supinator 139
supraspinatus 133
temporalis 108
tensor fasciae latae 150
teres
major 134
minor 134
thyrohyoideus 113
tibialis anterior 157
posterior 159
transversus abdominis 129
trapezius 117
triceps brachii 135
surae 158
vastus intermedius 153
lateralis 153
medialis 153
mydriasis
myelencephalon
myocardium 265
myometrium 252

n

nail 515
nares (naris) 206
nasal bone 31
nasion 36
nasopharynx 182
navicular bone 55
neocortex 434
nephron(s) 228
nervus (i) (nerves)
abducens 360
accessorius 366
alveolar
inferior 359
superior 358
auricular
great 340
posterior 361
auriculotemporal 359
axillaris 345
buccal 359
canalis pterygoidei 369
cardiaci thoracici 370
cardiacus cervicalis superior 369
medius 369
inferior 369
caroticotympanic 369
carotid, internal 369
chorda tympani 360
ciliary
long 357
short 355
clunium inferiores 348
medii 339
superiores 339
coccygeal 339
cochlear 362
cranial 352
cutaneous antebrachii
lateral 343
medial 344
posterior 345
cutaneus brachii
inferior 345
lateralis 345
medialis 344
posterior 345
superior 345
cutaneus femoris
lateralis 347
posterior 348
cutaneus surae
lateralis 349
medialis 349
dorsal
clitoridis 348
penis 348
scapular 342
ethmoidal
anterior 357
posterior 357
facial 360
femoral 347
fibular
commun 349
deep 349
superficial 349
frontal 357
genitofemoral 347
glossopharyngeus 363
gluteal
inferior 34
superior 348
hypoglossal 366
iliohypogastric 347
ilioinguinalis 347
infraorbital 358
infratrochlear 357
intercostal 351
intercostobrachial 346
intermedius 360
ischiadic 349
jugularis 369
lacrimal 357
laryngeal
reccurent 365
superior 365
lingual 359
mandibular 359
masseteric 359
maxillary 358
median 343
mental 359
musculocutaneus 343
mylohyoideus 359
nasociliaris 357
obturatorius 347
occipital
major 339
minor 340
tertius 339
oculomotor 355
olfactorius 354
ophthalmicus 357
opticus 254
pectoral 342
petrosal
major 361
minor 363
peroneus
profundus 349
superficialis 349
phrenic 341
plantaris
lateral 349
medial 349
pterygoid
lateral 359
medial 359
pudendal 348
radial 345
saphenous 347
sciatic 349
spinal 337
spinal accessory 366
splanchnic 370
subcostal 346
subscapular 342
supraclavicular 340
supraorbital 357
suprascapular 342
sural 349
thoracic, long 342
thoracodorsal 342
tibialis 349
transversus colli 340
trigeminal 356
trochlear 355
tympanicus 363
ulnar 344
vagus 364
vestibular 362
vestibulocochlearis 362
zygomaticus 358
neural crest 392
neurohypophysis 523
neuromuscular spindles 101
neurone 390
nipple 517
nociception 514
node(s) (nodus(i))
atrioventricularis 273
(lymphoideus –i)
axillares 325
Clocqueti 579
coeliaci 327
iliaci 328
inguinales 328
lumbales 327
mediastinales 328
mesenterici 327
paracolici 192
parauterini 328
pectorales 330
noradrenaline (norepinephrine) 477
nose 206
nostril 206
notochord 392
nucleus (nuclei)
abducens 360
accessory 366
accumbens 446
ambiguus 410
amygdaloid 446
apicalis 401
arcuate 412
basalis (of Meynert) 439
of Cajal 412
caudate 440
cerebellar 419
cochlear 362
cranial nerve 410
cuneate 421
of Darkschewitsch 412
Deiter's 410
dentate 419
dorsal vagal 364
Edinger-Westphal 355
emboliform 419
facial 360
fastigial 419
gigantocellular 414
globose 419
gracilis 412
gustatory 410
habenular 425
hypoglossal 366
inferior olivary 412
interpeduncular 412
interstitial 412
intralaminar 426
lateral geniculate 426
lateral lemniscus 412
lentiform 439
magnocellular (gigantocellular) 414
mammillary 431
oculomotor 355
olivary 412
of Onuf 415
paraventricular 431
phrenic 417
pontine (pontis) 406
pretectal 412
propositus hypoglossi 366
proprius 400
pulposus 73
pulvinar 427
red 412
ruber 412
salivary (salivatory) 410
solitarius 410
subthalamic 425
suprachiasmatic 431
supraopticus 431
thalamic 427
thoracicus 401
trapezoid 412
trigeminal 356
trochlear 355
vagal 364
vestibulocochlearis 362
nystagmus 362

o

obex 403
occipital bone 23

occiput 10
oesophagus 185
olecranon 45
olive 404
omentum
  greater 201
  lesser 201
Ondine's curse 416
oocyte(s) 249
ophthalmoscopy 510
opposition (movement) 71
ora serrata 510
orbicularis ciliaris 509
orbit 532
organum vasculosum 502
oropharynx 182
os (ossa) 18
  antebrachii 45, 46
  bregmaticum 34
  capitatum 47
  carpi 47
  cruris 53, 54
  coccygis 40
  coxae 49
  cuboideum 55
  cuneiforme
    intermedium 56
    mediale 56
    laterale 56
  digitorum manus 48
    pedis 56
  ethmoidale 30
  frontale 22
  hamatum 47
  hyoideum 35
  ilium 50
  incisivum 33
  lunatum 47
  manus 47
  membri
    inferioris 48
    superioris 42
  metacarpi 47
  metatarsi56
  nasale 31
  naviculare 47
  occipitale 23
  palatinum 32
  parietale 26
  pedis 54
  pisiforme 47
  pubis 51
  sacrum 40
  scaphoideum 47
  sphenoidale 24
  tarsi 55
  temporale 27
  trapezium 47
  trapezoideum 47
  triquetrum 47
  zygomaticum 31
ossiculum (-a) auditus 506
ossification 20
osteofascial
  compartments 147
  septum 99
ostium (ostia)
  atrioventriculare
    dextrum 268
    sinistrum 270
  pharyngeum tubae auditivae 183
  pyloricum 187
  sinus coronarii 268
  trunci pulmonalis 269
  urethrae
    externum 233, 247
    internum 231, 233
  uteri 252
  uterinum tubae uterinae 251
  vaginae 254
  venae cavae
    inferioris 268
    superioris 268
otoliths 507
otosclerosis 506
ovary 250

P

palate
  durum (hard) 178
  molle (soft) 179
paleocortex (paleopallium) 434
pallidum 440
pallium 434
palma manus 10
palpebra 512
pancreas 200, 524
papilla(ae)
  dermal 515
  duodenal
    major 189
    minor 189
  gingival 172
  interdental 515
  parotidea 181
  vallate 176
paraganglia 522
parenchyma, liver 196
parietal bone 26
Parkinson's disease 476
paronychia 516
paroophoron 238
pars (partes)
  compacta 412
  flaccida 505
  labialis (m. orbicularis oris) 106
  lacrimalis (m. orbicularis oculi) 105
  laterales ossis occipitalis 23
  marginalis (m. orbicularis oris) 106
  orbitales ossis frontalis 22
  orbitalis (m. orbicularis oculi) 105
  palatina 33
  palpebralis
    (m. orbicularis oculi) 105
  petrosa ossis temporalis 28
  pubica (m. levator ani) 131
  squamosa ossis temporalis 27
  sternalis (diaphragma) 127
  sternocostal
    (m. pectoralis major) 125
  tibionavicularis 55
  tibiotalaris anterior 87
    posterior 87
  tuberalis, of pituitary gland 523
  tympanica ossis temporalis 27
  vertebralis (m. latissimus dorsi) 117
patch(es) Peyer's 188
patella 53
pecten pubis 51
pectus 10
pedicle 37
peduncle(s)
  cerebellar 418
pelvis
  major 49
  minor 49
penis 247
pericardium 266
perilymph 506
perimysium 98
perineum 256
perineurium 336
periosteum 19
peritoneum 201
pes anserinus major 154
phalanx (phalanges)
  foot 56
  hand 47
phallus (see penis) 247
pharynx 182
philtrum 173
photoreceptors 508
pia mater 471
pinna (see auricle) 505
pisiform 47
pit(s)
  gastric 187
placenta 258
planta pedis 10
plantar flexion 71
plate(s)
  alar 392
  basal 392
  cribriform 30
  epiphysial 18
  growth 18
  hepatic 196
  horizontal, of palatine bone 32
  nail 516
  neural 392
  orbital 30
  perpendicular 32
pleura 220
plexus
  abdominal 373
  aortic 373
  Auerbach's (myenteric) 374
  autonomic 367
  basilar 475
  brachial 342
  cardiac 372
  carotid autonomic 369
  cervical 340
  choroid 468
  coeliac 373
  cystic 373
  hepatic 373
  hypogastric 374
  lumbal 346
  mesenteric 373
  myenteric 374
  oesophageal 365
  ovarian 373
  parotid 361
  pelvic 374
  preprostatic 300
  prevertebral 476
  prostatic 300
  pterygoid 295
  pulmonary 372
  rectal 299
  renal 373
  sacral 348
  solar (coeliac) 373
  splenic 373
  suprarenal 373
  ureteric 373
  uterine 300
  vaginal 300
  vesical 300
plica(ae)
  alares 84
  aryepiglottica 210
  axillaris
    anterior 124
    posterior 116
  infrapatellar 84
  lacrimalis 511
  semilunaris 190
  sublingualis 176
  umbilicales laterales 558
    mediales 558
    mediana 558
  see also fold(s)
pneumothorax 220
pons 406
pore(s) skin 515
porus acusticus internus 28
porta hepatis 197
precuneus 433
premaxilla 33
prepuce
  of clitoris 255
  of penis 247
presubiculum 444
primordium 238
processus(us)
  accessorius 39
  alveolaris maxillae 33
  articulares
    superiores (vertebrae) 37
    inferiores (vertebrae) 37
  calcanearis 55
  clinoid
    anteriores 25
    posteriores 24
  condylaris 34
  coracoideus 43
  coronoideus mandibulae 34
    ulnae 45
  costales 41
  ethmoidalis 30
  frontalis maxillae 33
    ossis zygomatici 31
  intrajugularis ossis occipitalis 23
    ossis temporalis 28
  lacrimalis 30
  lateralis tali 55
  mammillaris 39
  mastoideus 29
  maxillaris 30
  medialis tuberis calcanei 55
  orbitalis 32
  palatinus maxillae 33
  posterior tali 55
  pterygoideus 25
  pyramidalis ossis palatini 32
  sphenoidalis 32
  spinosus 37
  styloideus ossis temporalis 29
    ossis metacarpi III 48
    radii 46
    ulnae 45
  supracondylaris 574
  temporalis ossis zygomatici 31
  transversi 37

This copy belongs to ali yaghoubi

tuberis calcanei 55
uncinatus
conchae nasalis mediae 30
corporis vertebrae 38
xiphoideus 41
zygomaticus maxillae 33
ossis temporalis 27
prominentia canalis facialis 506
canalis semicircularis lateralis 506
promontorium ossis temporalis 506
prosencephalon (forebrain) 393
prostate 245
protuberance
mentalis 34
occipitalis externa 23
occipitalis interna 23
pubis 51
pulp 321
pulvinar
acetabuli 83
thalami 426
pupil (of eye) 508
putamen 439
pylorus 186
pyramis 404

R

radius 446
radix
dentis 174
linguae 184
mesenterii 201
ramus(i)
anterior nervi obturatorii 347
auricularis nervi vagi 365
colli nervi facialis 361
dorsales nn. sacrales 339
dorsalis nervi coccygei 339
nervi ulnaris 344
inferior ossis pubis 51
intercostales anteriores
(a. thoracica interna) 283
malleolares laterales 293
mandibulae 34
mylohyoideus 281
nasales posteriores 358
ossis ischii 51
posterior nervi obturatorii 347
profundus
nervi plantaris lateralis 349
nervi radialis 345
nervi ulnaris 344
pubic 51
superficialis nervi radialis 345
raphe
buccopharyngea 531
mylohyoidea 544
palatine 178
perineal 256
pharyngeal 184
pterygomandibular 72
of scrotum 246
of soft palate 179
recess(es)
costodiaphragmatic 220
costomediastinal 220
duodenal 563
duodenojejunal 563
epitympanic 506
hypophysial (pouch of Rathke) 522
ileocaecal (superior and inferior) 563
inferior, of bursa omentalis 561
infundibular, of third ventricle 469
intersigmoid 563
lateral, of fourth ventricle 469
paraduodenal 563
retrocaecal 563
retroduodenal 563
sacciform 73
splenic 561
subpopliteal 84
suprapatellaris 84
rectum 195
reflex(es) 338
reflux 184
region(s)
abdominal 554
colli
anterior 542
laterale 542
posterior 543
epigastrica 554
gluteal 11
hypochondriaca 554
infrahyoidea 340
inguinal 558
laryngea 544
olfactoria 207
parotideomasseterica 11
sternocleidomastoidea 544
suprasternalis 544
rete
articulare cubiti 284
articulare genus 292
testis 240
retina 510
retinaculum(a)
musculorum extensorum 147
extensorum superius 165
extensorum inferius 165
fibularium inferius 165
fibularium superius 165
flexorum 81, 147
patellae 85
retraction 71
retroperitoneum 559
retroflexion 71
rhombencephalon (hindbrain) 393
ribs 41
rim
acetabular 50
glottidis 210
oris 172
rostrum sphenoidale 24
rotation (movement) 71
rotator cuff 77

S

sac(s)
alveolar (air) 217
dental 172
hernial 558
lacrimal 511
lesser 561
yolk 171
sacrum 40
saliva 180
salpinx 201
scala
media 507
tympani 507
vestibuli 507
scaphoid 47
scapula 43
sclera 509
scoliosis 37
scrotum 246
segment(s)
bronchopulmonary 217
of liver 196
sella turcica 24
septum(a)
atrial 268
atrioventricular 268
femoral 130
intermusculare brachii laterale 147
interventricular 269
nasal 206
pellucidum 446
primum (of atria) 267
rectovaginal 254
secundum (of atria) 267
transversum 265
urethrovaginal 267
serosa 171
sesamoid bones 81
shaft
of femur 52
of fibula 54
of humerus 44
of metacarpals 47
of phalanges 47
of radius 46
of rib 41
of tibia 53
of ulna 45
sheath(s)
carotid 547
of eyeball, fascial 512
hair 516
rectus (abdominis) 555
sinus(es)
air 208
aortic (of Valsalva) 275
cavernosus 475
coronary 275
durae matris 475
frontal 22
maxillary 33
occipital 471
paranasal 208
petrosal 471
sagittal 471
sigmoid 471
sphenoidal 24
sphenoparietal 471
straight 471
tarsi 55
transverse 471
urogenital 226
venosus 471
sinusoid
of bone 20
hepatic 196
spleen 321
skeleton 18
skin 515
skull 21
spatium (-a)
intercostale 549
palmare medium 577
parapharyngeum 540
paraviscerale 546
plantare
laterale 165
mediale 165
medium 165
prestyloideum 541
retrostyloideum 541
retropharyngeum 541
sublinguale 180
submandibulare 181
sphenoid bone 24
sphincter(s)
anal 195
bile duct 199
cardio-oesophageal 186
of Oddi 199
pyloric 186
urethral 233, 248
urethrovaginalis 233
spine (or spina)
iliaca 50
ischiadica 51
nasalis anterior 33
spleen 321
splenium 443
stapes 506
sternum 41
stomach 186
stratum (strata)
basale 515
corneum 515
fibrosum 70
granulosum 419
lucidum 515
moleculare 419
nervosum 510
pigmentosum 510
purkinjese 419
spinosum 515
synoviale 70
see also layer(s)
stria(e) medullaris 403
striatum 440
subcortex 396
subiculum 445
substantia
gelatinosa 401
nigra 412
subthalamus 425
styloid septum 540
sulcus (sulci)
arteriae meningeae mediae 26
arteriae subclaviae 41
arteriae vertebralis 38
carotid 24
carpi 47
centralis 432
gingival 173
hypothalamic 424
infraorbital 33
limitans 403
linguogingival
nasolabial 273
nervi petrosi majoris 28
petrosi minoris 28
radialis 44
spinalis 38

ulnaris 44
obturatorius 51
optic 24
precentral 488
salivarius 187
sinus
occipitalis 23
petrosi inferioris 23
petrosi superioris 28
sagittalis superioris 26
sigmoidei 23
transversi 23
see also groove(s)
supination (movement) 71
sustentaculum tali 55
suture(s) 72
coronal 72
frontal 72
incisiva 33
lambdoidea 72
mendosa 22
metopica 22
plana 68
sagittalis 72
serrata 68
squamosal 72
zygomaticotemporal
symphysis(es)
intervertebrales 73
manubriosternalis 75
pubic 82
xiphisternalis 75
synchondroses 68
syncytium 99
synostosis 68

T

taenia
coli 191
thalami 426
talus 55
tarsal tunnel 584
tarsus 54
taste 503
taste buds 503
tectum 408
teeth 174
tegmen tympani 28
tegmentum mesencephali 408
tela choroidea 468
tela subcutanea 515
telencephalon (endbrain) 432
temporal bone 27
tendon(s) 99
tentorium cerebelli 418
Terminologia anatomica 2
testis (testes) 240
thalamus 426
thorax 41
thymus 320
tibia 53
tissue 4
tongue 176
tonsil
cerebelli 418
palatine 183
pharyngeal 183
torus
levatorius 209
tubarius 209
trabecula(e)
bone 19
carneae 267
hepatic 196
of penis 247
splenic 321
trachea 214
tract(s)
ascending 452
auditory 465
gastrointestinal 170
iliotibial 149
descending 458
olfactory 466
optic 462
vestibular 465
corticospinal (pyramidal) 459
olivocerebellar 421
reticulospinal 460
rubrospinal 461
solitarius 411
spinocerebellar 455
spinomesencephalic
spinotectal 454
spinothalamic 454
tectospinal 461
vestibulospinal 460
see also fasciculus (fasciculi),
fibre(s)
tragus 505
trapezium 47
trias hepatica 196
triangle(s)
anal 566
Calot's 562
carotid 543
colli 542
femoral 581
habenulare 425
inguinale (Hesselbachi) 558
lumbale (Petiti) 569
olfactorium 433
omoclaviculare 545
omotrapezium 572
submandibulare 543
submentale 544
suboccipitale 569
urogenitale 566
trochanter
greater 52
lesser 52
trochlea
fibularis 55
humeri 45
tali 55
truncus
brachiocephalicus 277
pulmonalis 219
tube(s)
auditory, Eustachian,
pharyngotympanic 506
Fallopian 251
neural 392
uterine 249
tuber
cinereum 430
frontal 22
ischiadicum 51
parietal 26
tubercle(s), tuberculum(a)
cuneate 400
genital 238
gracile 400
of humerus 44
infraglenoid 43
mental 34
pharyngeal 23
pubic 51
tibial 53
ulnar 45
vertebral 37
tuberosity
deltoidea 44
gluteal 52
iliac 50
masseteric 34
phalangis distalis 48
pterygoidea 34
radii 46
tibiae 53
tractus iliotibialis 53
ulnae 45
tunica
albuginea 240
bulbi 508
dartos 567
vaginalis testis 240
tunnel
carpal 577
ulnar 576
tarsal 584

U

ulna 45
umbilicus 10
uncus
corporis vertebrae cervicalis 38
gyri hippocampi 445
urachus 230
ureter 230
urethra
feminina 233
masculina 248
uterus 252
utriculus prostaticus 245
uvula palatina 179

V

vagina(ae)
carotica 542
musculi recti abdominis 555
valve(s)
aortic 271
bicuspidalis (mitral) 271
pulmonary 269
semilunar 272
sinuatrial
tricuspid 269
vein, vena(ae)
alveolar (dental) 296
angular 296
appendicular 298
axillary 296
azygos 299
basal 474
basillic 297
brachial 297
brachiocephalica 294
bronchial 294
buccal 296
cardiac
magna 276
media 276
parva 276
cava inferior 297
cava superior 296
cephalica 297
epigastrica inferior 301
facialis 295
femoralis 301
gastricae 298
hemiazygos 299
hepaticae 297
iliaca communis 300
jugularis
externa 296
interna 295
lienalis 298
mesenterica
inferior 298
superior 298
ovarica 297
poplitea 301
portae 298
renalis 297
retromandibularis 295
saphena magna 301
subclavia 296
temporalis superficialis 295
tibiales posteriores 301
umbilicalis 275
vertebralis 294
ventricle(s) 269, 271
vermis, of cerebellum 418
vertebra(ae)
cervicales 38
coccygeae 40
lumbales 39
prominens 38
sacrales 40
thoracicae 39
vesica
fellea 199
urinaria 231
vesicle(s)
seminal 244
vestibule
laryngis 210
nasi 207
oris 172
villi synoviales 70
vincula tendinum 99
viscerocranium 21
vomer 31
vulva 255

W

Wharton's jelly 258
wrist 79

This copy belongs to ali yaghoubi

Radovan Hudák, David Kachlík, Ondřej Volný et al.
MEMORIX ANATOMY

Published MEMORIX in Prague, 2015
1st edition
E-book version,
Last edit: 23. 10. 2016

Illustrations: Jan Balko, Simona Felšőová, Šárka Zavázalová, Radovan Hudák
Typesetting: Radovan Hudák, Matej Halaj, Vojtěch Kunc, Daniel Slovák
Chiefs of copy editing and proofreading: Petr Vaněk, Adam Whitley
Copy editing and proofreading: Zuzana Balážová, Pavel Filip, Michal Vilímovský
Design: Radovan Hudák, Karel Novotný
Cover: Jan Balko, Karel Novotný, Radovan Hudák, Renata Brtnická

www.memorix.co.uk

ISBN: 978-80-906331-0-0

Be an Anatomist from the heart

Book contents:

1. General anatomy 1
2. Bones 17
3. Joints 67
4. Muscles 97
5. Digestive system 169
6. Respiratory system 205
7. Urinary system 225
8. Genital system 237
9. Heart and blood vessels 263
10. Lymphatic and immune systems 317
11. Peripheral nervous system 335
12. Central nervous system 389
13. Senses and skin 501
14. Endocrine system 521
15. Topography 529

Practice anatomy with personalized questions.
Free web app – www.PracticeAnatomy.com

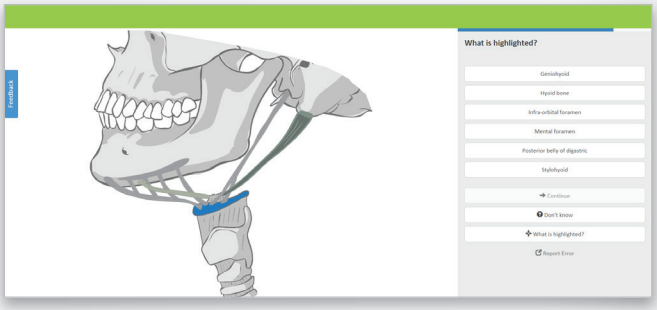

Anatomy terms in free online dictionary
www.AnatomicalTerms.co.uk

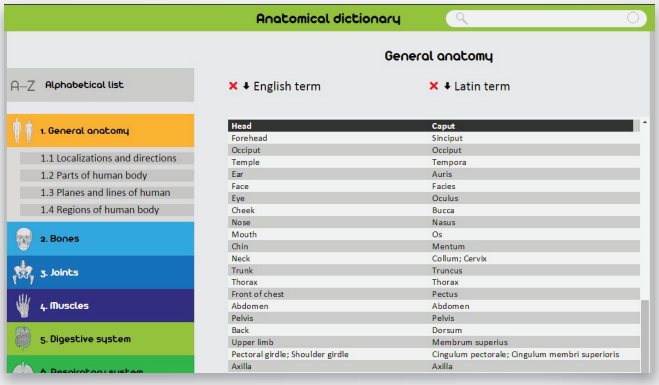

Practice anatomy anywhere and anytime
Mobile app coming soon



More information at

www.memorix.co.uk

This copy belongs to ali yaghoubi